

# **Childhood tuberculous meningitis: Challenging current management strategies**

Dissertation presented by


**Ronald van Toorn**

For a PhD degree in Paediatrics and Child Health  
at  
Stellenbosch University

Promoter: Prof JF Schoeman

Co-promoter: Prof HS Schaaf

March 2015



## Declaration

I, the undersigned, hereby declare that the work contained in this dissertation is my own original work and that I have not previously in its entirety or in part submitted it at any other university for a degree.

Signature

Date

## **Dedication**

I dedicate this thesis to my parents, family and my wife Hesmari for their constant support and unconditional love. Thank you, Lord, for always being there for me.

## Summary

Tuberculous meningitis (TBM) continues to be an important cause of mortality and neurological disability in resource-limited countries. Many questions remain about the best approaches to prevent, diagnose, and treat TBM, and there are still too few answers.

The aim of this dissertation was to challenge current management strategies in childhood TBM.

Accurate prediction of outcome in TBM is of critical importance when assessing the efficacy of different interventions. I conducted a retrospective cohort study of 554 children with TBM less than 13 years of age admitted to Tygerberg Children's Hospital over a 20 year period (1985-2005) and reclassified all patients according to the criteria of all the currently available staging systems in childhood TBM (chapter 4). In this study, I found that the "Refined Medical Research Council (MRC) staging system after 1 week" had the highest predictive value of all TBM staging systems. It is created by subdivision of stage 2 (2a and 2b) of the existing MRC staging system. Additionally, I proposed and validated a simplified TBM staging system which is less dependent on clinical ability and neurological expertise than current staging systems. The simplified staging system was termed the "Tygerberg Children's Hospital Scale" (TCH) and relies solely on the patient's ability to visually fixate and follow and the motor response to pain on both sides. It demonstrated excellent predictive power of outcome after 1 week and did not differ significantly from the "Refined MRC staging system" in this regard.

The optimal anti-TB drug regimen and duration of treatment for TBM is unknown. It has been suggested that intensive short-course (6 months) anti-TB therapy may be sufficient and safe. I conducted a prospective descriptive study of 184 consecutively treated children with TBM and found that short-course intensified anti-TB therapy aimed at treating TBM patients (anti-TBM therapy) is sufficient and safe in both HIV-uninfected and HIV-infected children with drug susceptible TBM (chapter 5). The overall study mortality of 3.8% at completion of treatment compares favourably with the median mortality rate of 33%

(range 5-65%) reported in a recent review describing outcome in TBM treatment studies.

TB-immune reconstitution inflammatory syndrome (IRIS) is a potentially life-threatening complication in HIV-infected children with TB of the central nervous system. Little is known about the incidence, case fatality, underlying immunopathology and treatment approaches in HIV-infected children with neurological TB-IRIS. In a case series, I found that neurological TB-IRIS should be considered when new neurological signs develop after initiation of antiretroviral therapy (ART) in children with TBM (chapter 6.1). Manifestations of neurological TB-IRIS include headache, seizures, meningeal irritation, a decreased level of consciousness, ataxia and focal motor deficit. I also discussed the rationale for using certain treatment modalities, including thalidomide.

Neurological tuberculous mass lesions (tuberculomas and pseudo-abscesses) may develop or enlarge in children on anti-TBM treatment. These lesions respond poorly to therapy, and may require surgical excision, but may be responsive to thalidomide, a potent inhibitor of tumour necrosis factor-alpha (TNF-alpha). The optimal dose and duration of thalidomide therapy and the correlation with magnetic resonance imaging (MRI) is yet to be explored. The primary objective of our next study was to investigate whether serial MRI is useful in evaluating treatment response and duration of thalidomide therapy (chapter 6.2). A secondary objective was to determine the value of thalidomide in the treatment of these lesions. In a prospective observational study over three years, serial MRI was performed in 16 consecutive children compromised by TB pseudo-abscesses who were treated with thalidomide. The rapid clinical response of most patients suggests that thalidomide provides substantial clinical benefit in this clinical context. I also identified a MRI marker of cure that is evolution of lesions from early stage "T2 bright" with edema to "T2 black." This finding could be useful in the future management of these patients.

Transcranial Doppler imaging (TCDI) is potentially a valuable investigational tool in children with TBM, a condition often complicated by pathology relevant to Doppler imaging such as raised intracranial pressure (ICP) and cerebral vasculopathies. Serial TCDI was performed on 20 TBM children with the aim of investigating cerebral haemodynamics

and the relationship between pulsatility index (PI) and ICP (chapter 6.3). In this study, I found that TCDI-derived pulsatility index (PI) is not a reliable indicator of raised ICP in children with tuberculous hydrocephalus which I attributed this to individual variation of tuberculous vascular disease, possibly compromising cerebral vascular compliance and resistance. The study did confirm the efficacy of medical therapy in children with tuberculous communicating hydrocephalus. In all cases, the ICP normalized within 7 days after initiation of acetazolamide and furosemide.

In the same cohort of children with TBM I also measured cerebral blood flow velocities (BFV) in the anterior cerebral artery (ACA), middle cerebral artery (MCA) and posterior cerebral artery (PCA) on admission and after day 3 and 7. I found persistent high BFV in all the basal cerebral arteries suggesting stenosis due to vasculitis rather than functional vasospasm. Additionally, I found that complete MCA occlusion, subnormal mean MCA velocities (less than 40 cm/s) and a reduced PI (less than 0.4) correlated with radiological proven large cerebral infarcts. No side-to-side differences in MCA BFV or subnormal PI's were detected in four TBM children with territory infarcts on admission. I attributed this to the occlusion of a limited number (one or two) of the 9 MCA perforators which has been shown not to affect the hemodynamics of the MCA.

I concluded by highlighting the many questions that remain about the best approaches to prevent, diagnose, and treat TBM (chapter 2). In a second literature review, aimed at clinicians working in resource-limited countries, I describe novel approaches to the management of childhood TBM, including a treatment algorithm for tuberculous hydrocephalus, the role for short-course intensified anti-TBM treatment and home-based anti-TBM treatment (chapter 3).

Even with the best diagnostic and treatment modalities, outcome in childhood TBM will remain poor if diagnosis is delayed. Our efforts should be on increased awareness and earlier diagnosis.

## Opsomming

Tuberkuleuse meningitis (TBM) bly 'n belangrike oorsaak van mortaliteit en neurologiese ongeskiktheid in lande met beperkte hulpbronne. Baie vrae oor die beste benaderings tot voorkoming, diagnose en behandeling van TBM bly bestaan en daar is steeds te min antwoorde.

Die doel van die verhandeling was om huidige behandelingstrategieë van tuberkuleuse meningitis (TBM) in kinders uit te daag.

Akkurate voorspelling oor die uitkoms van TBM is van kritieke belang wanneer doeltreffendheid van verskillende ingrypings beoordeel word. Ek het 'n retrospektiewe kohort studie van 554 kinders jonger as 13 jaar met TBM wat in Tygerberg Kinderhospitaal toegelaat is oor 'n tydperk van twintig jaar (1985 tot 2005) uitgevoer en al die pasiënte volgens die kriteria van al die huidige beskikbare stadiëringsisteme vir kinder TBM geherklassifiseer (hoofstuk 4). Die waarde van die verskillende stadiëringsisteme in die voorspelling van neurologiese uitkoms is toe bepaal. In hierdie studie het ek bevind dat die "Verfynde Mediese Navorsings Raad (MNR) stadiëringsstelsel na 1 week" die TBM stadiëringsstelsel met die hoogste voorspellende waarde was om neurologiese uitkoms te voorspel. Dit is geskep deur onderverdeling van stadium 2 (2a en 2b) van die bestaande gemodifiseerde MNR stadiëringsstelsel. Daarbenewens het ek 'n vereenvoudigde stadiëringsstelsel vir TBM wat minder afhanklik van kliniese vermoëns en neurologiese kundigheid sal wees as die bestaande stadiëringsisteme daargestel en getoets. Die vereenvoudigde stadiëringsstelsel is die "Tygerberg Kinderhospitaal Skaal (TKH)" genoem en dit is slegs gebaseer op 'n pasiënt se vermoë om visueel te fikseer en te volg en die motoriese respons tot pyn aan beide kante van die liggaam. Dit het uitstekende voorspellingswaarde gehad vir uitkoms na die eerste week van siekte en het in hierdie verband nie betekenisvol verskil van die "Verfynde MNR stadiëringsstelsel" nie.

Die optimale anti-TB middel regimen en duurte van behandeling vir TBM is onbekend. Sommige kenners stel voor dat 'n intensiewe kort-kursus (6 maande) van anti-TB behandeling veilig en voldoende mag wees. Ek het 'n prospektiewe beskrywende studie op 184 opeenvolgende kinders met TBM uitgevoer en bevind dat intensiewe kort-kursus anti-TB behandeling gemik op die behandeling van kinders met TBM (anti-TBM behandeling) in

beide menslike immuniteitgebrekvirus (MIV)-ongeïnfekteerde en MIV-geïnfekteerde kinders met middel-gevoelige TBM voldoende en veilig was (hoofstuk 5 ). Die mortaliteit in my studie met voltooiing van behandeling vergelyk gunstig met die mediane mortaliteit van 33% (reikwydte 5-65%) wat onlangs in 'n oorsig van uitkoms in TBM gerapporteer is.

TB immuun rekonstitusie inflammatoriese sindrome (IRIS) is 'n potensieël lewensbedreigende komplikasie in MIV-geïnfekteerde kinders met TB van die sentrale senuwee sisteem (SSS). Min is oor die voorkoms, mortaliteit, onderliggende immunopatologie en behandelingsbenaderings in MIV-geïnfekteerde kinders met neurologiese TB-IRIS bekend. In 'n gevalle-reeks het ek gevind dat neurologiese TB-IRIS oorweeg moet word as nuwe neurologiese tekens na aanvang van antiretrovirale terapie (ART) in MIV-geïnfekteerde kinders met TBM ontwikkel (hoofstuk 6.1). Simptome en tekens van neurologiese TB-IRIS behels hoofpyn, konvulsies, meningiale prikkeling, 'n verlaagde vlak van bewussyn, ataksie en fokale motoriese uitval. Ons bespreek ook die rasionaal vir die gebruik van sekere behandelingsmodaliteite, insluitende thalidomied.

Neurologiese tuberkuleuse massaletsels (tuberkulome en pseudo-absesse) mag ontwikkel of vergroot in kinders op anti-TBM behandeling. Hierdie letsels reageer swak op terapie, vereis soms chirurgiese verwydering, maar kan op thalidomied behandeling reageer, 'n kragtige inhibeerder van tumor nekrose faktor-alfa (TNF- $\alpha$ ). Die optimale dosis en duurte van thalidomied behandeling en die korrelasie met magnetiese resonansbeelding (MRB) moet nog ondersoek word. Die primêre doel van my volgende studie was om te bepaal of seriële MRB van waarde is om die respons op behandeling te evalueer asook die duurte van thalidomied behandeling. Die sekondêre doelwit was om die waarde van thalidomied in die behandeling van hierdie letsels te bepaal. In 'n prospektiewe waarnemingstudie wat oor 3 jaar gestrek het is seriële MRB uitgevoer op 16 opeenvolgende kinders met TB pseudo-absesse wat behandel is met thalidomied (hoofstuk 6.2). Die spoedige kliniese verbetering van die meeste pasiënte dui daarop dat thalidomied 'n aansienlike kliniese voordeel bied in hierdie kliniese konteks. Verder het ek 'n MRB merker van genesing geïdentifiseer naamlik evolusie van die letsel van vroeë stadium "T2 helder" met edeem na "T2 swart". Hierdie bevinding is van groot waarde in die toekomstige behandeling van TBM pasiënte wat hierdie komplikasie ontwikkel.

Transkraniale Doppler beelding (TKDB) is potensieël 'n waardevolle ondersoekmetode in kinders met TBM, 'n toestand wat dikwels gekompliseer word deur patologie verwant aan



Doppler beelding soos verhoogde intrakraniale druk (IKP) en serebrale vaskulopatieë. Seriële TKBD is op 20 TBM kinders uitgevoer om serebrale hemodinamika en die verband tussen die pulsatiele indeks (PI) en IKP te ondersoek (hoofstuk 6.3). In hierdie studie het ek gevind dat TKDB-afgeleide PI nie 'n betroubare aanduiding van verhoogde IKD in kinders met tuberkuleuse hidrokefalus is nie en dit aan individuele variasies van tuberkuleuse vaskulêre siekte toegeskryf, wat serebrale vaskulêre toegeeflikheid en weerstand benadeel. Die studie het die doeltreffendheid van mediese behandeling in kinders met kommunikerende tuberkuleuse hidrokefalus bevestig. In alle gevalle het die IKP binne 7 dae na aanvang van asetosoolamied en furosemied genormaliseer.

In dieselfde groep TBM kinders het ek die serebrale bloedvloei-snelhede (BVS) in die anterior serebrale arterie (ASA), middel serebrale arterie (MSA) en posterior serebrale arterie (PSA) met toelating en na dag 3 en 7 gemeet. Ek het volgehoue hoë BVS in al die basale arteries gevind wat op stenose sekondêr tot vaskulitis eerder as funksionele vasospasme dui. Daarbenewens het ek gevind dat volledige MSA afsluiting, subnormale gemiddelde MSA snelhede (minder as 40 sentimeter per sekonde) en 'n verminderde PI (minder as 0.4) met radiologies-bewysde groot serebrale infarkties gekorreleer het. Geen kant-tot-kant verskille in MSA BVS of subnormale PI's is in vier TBM kinders met kleiner infarkties met toelating bespeur nie. Ek skryf dit toe aan die afsluiting van 'n beperkte aantal (een of twee) van die nege MSA perforators wat nie die hemodinamika van die MSA beïnvloed nie.

Ek het afgesluit om al die vrae wat nog bestaan oor die beste benadering ten opsigte van voorkoming, diagnose and behandeling van TBM uit te wys (hoofstuk 2). In die tweede literatuuroorsig, wat gemik is op dokters wat werk in hulpbron-beperkte lande, beskryf ek nuwe benaderings tot die hantering van pediatriese TBM, insluitend 'n behandelingsalgoritme vir tuberkuleuse hidrokefalus, die rol van kort- kursus versterkte anti-TB behandeling vir TBM en tuis-gebaseerde anti-TBM behandeling (hoofstuk 3).

Selfs met die beste diagnostiese en behandelingsmodaliteite, is die uitkoms van kinder TBM swak indien diagnose vertraag word. Ons pogings moet daarom op groter bewustheid en vroeër diagnose berus.

## Table of Contents

<b>Chapter 1</b>	Introduction	1
<b>Chapter 2</b>	Tuberculous meningitis: more questions, still too few answers	13
<b>Chapter 3</b>	Update on the diagnosis and management of tuberculous meningitis in children residing in resource-limited countries.	26
<b>Chapter 4</b>	Prediction of prognosis in children with tuberculous meningitis	34
	1. Value of different staging systems for predicting neurological outcome in childhood tuberculous meningitis	
<b>Chapter 5</b>	Treatment duration of tuberculous meningitis	41
	1. Short intensified treatment in children with drug-susceptible tuberculous meningitis.	
	2. Letter to the Editor: In Reply: Short intensified treatment in children with drug-susceptible tuberculous meningitis	
<b>Chapter 6</b>	Management of complications of tuberculous meningitis	49
	1. Neurological manifestations of TB-immune reconstitution inflammatory syndrome (IRIS): A report of 4 children	
	2. Clinico-radiological response of neurological tuberculous mass lesions in children treated with thalidomide	
	3. The value of transcranial Doppler imaging in children with tuberculous meningitis	
<b>Chapter 7</b>	Conclusion	73
	<b>Other tuberculosis-related manuscripts completed during the study period</b>	83
	<b>Acknowledgements</b>	84
	<b>Funding</b>	85
	<b>List of abbreviations</b>	86

# **Chapter 1**

## **Introduction**

## Introduction

The true worldwide burden of childhood tuberculosis (TB) remains unknown. In 2012, the World Health Organization (WHO) estimated the global burden of TB in children (under 15 years of age) at 530 000.<sup>1</sup> However, the actual burden of childhood TB is thought to be much higher due to the difficulties related to accurate diagnosis of TB in young children. South Africa is one of the 22 high TB burden countries that account for 80% of the world's TB cases.<sup>1</sup> The annual risk of TB infection (ARTI) in Southern African townships has been reported to be as high as 4% per annum.<sup>2</sup> Epidemiological studies report a good correlation between the incidence of tuberculous meningitis (TBM) in children 0-4 years of age per 100 000 population and the percentage ARTI multiplied by five.<sup>3</sup> This implies an annual childhood TBM incidence in these townships of 20 per 100 000 children. A recent study in the Western Cape province of South Africa further highlighted the importance of TBM by finding it to be the commonest cause of paediatric bacterial meningitis.<sup>4</sup>

The aim of this dissertation was to challenge current management strategies in childhood TBM. Unlike pulmonary TB, which has been the subject of numerous clinical trials in adults and children, the evidence base of various aspects of TBM diagnosis, management and prognosis is limited leading to substantial differences and uncertainties in management protocols.

Eight years ago in a review in *The Lancet Neurology*, Dr Guy Thwaites argued that prevention and treatment of TBM posed many questions for which there were too few answers<sup>5</sup>. Last year, my colleague Prof Johan Schoeman was invited by *The Lancet Neurology* to write an updated review on TBM in adults and children. He kindly invited Dr Guy Thwaites (for his expertise on adult TBM) and me to join him. The aim of the review (see chapter 2), in which all three authors contributed equally, was to determine whether there are now answers to the questions that were previously posed and to reassess the challenges that face those tasked with the prevention, diagnosis, and treatment of TBM in children and adults. We concluded that many questions remain about the best approaches to prevent, diagnose and treat TBM, and there are still too few answers.<sup>6</sup>

TBM continues to be an important cause of neurological disability in resource-limited countries. In a second review article (see chapter 3), aimed at clinicians working in resource-limited countries, I describe novel approaches to the management of childhood TBM,

including a treatment algorithm for tuberculous hydrocephalus, the role for short-course intensified anti-TB treatment and home-based treatment for childhood TBM cases.<sup>7</sup>

The first challenge that confronts a physician managing a very ill child with TBM relates to accurate prediction of outcome. Parents expect physicians to prognosticate outcome as accurately as possible, which is often difficult because of limited information in this regard. Accurate outcome prediction is also critically important when assessing the efficacy of interventions, such as different anti-TB drug regimens and the benefits of adjuvant therapy such as immune-modulating agents. However, accurate prediction of outcome in childhood TBM is difficult due to the protracted course of the disease, diversity of underlying pathological mechanisms, unpredictability of injury-induced cerebral plasticity and variation of host immunity.

Several different staging systems, including the modified Medical Research Council (MRC), the Glasgow Coma Scales (GCS) on its own, Acute Physiological and Chronic Health Evaluation (APACHE) II and the TBM acute neurology score (TBAN) have been proposed to predict outcome in TBM.<sup>8-11</sup> It is unclear from the literature which of these staging systems has the highest predictive value.

The most widely used “modified MRC staging system” does not distinguish unilateral from bilateral motor involvement, which is important, as bilateral cerebral infarction often occurs in children with advanced TBM.<sup>12</sup> My previous clinical experience suggests that the modified stage 2 disease-category is too inclusive, as children without neurological deficit and only slight drowsiness (GCS 14/15) are grouped together with children with neurological deficit and GCS of 10-13/15.

The benefit of clinical staging systems is that it can be applied to patients in both developed and developing countries, as it does not rely on radiologic or laboratory findings. Limitations of staging systems are that staging criteria may be difficult to apply in a standard manner for children in whom assessment of the sensorium is difficult. Accurate staging often requires skilled medical personnel. There is a need for a simplified, universal clinical staging system that can be applied to patients with TBM in resource-limited countries.

The initial staging may be influenced by other factors apart from the TBM itself which may affect level of consciousness on presentation. These include the effect of seizures, drugs and

hydration state. It is therefore possible that staging once the patient is stabilized may be of more value prognostically than the staging at first contact.

The hypothesis of the first study (chapter 4) was that more accurate prediction of outcome in childhood TBM is achievable by refinement of the current staging systems. Additionally, I believed that a simplified TBM outcome system is achievable. Study questions were: Which of the current TBM staging systems has the highest predictive value? Is more accurate predicting of outcome in TBM possible by refinement of the modified MRC staging system? Is a simplified TBM staging system achievable for use by unskilled health care workers in resource-poor countries? Does staging after 1 week of diagnosis improve outcome prediction? Which clinical factors are associated with significant stage improvement after the first week of treatment?

The second challenge relates to what the most appropriate antimicrobial treatment is for childhood TBM. Effective antimicrobial treatment must treat the active infection by eliminating actively replicating bacilli, thus reducing the probability of sequelae and death. It must prevent relapse by eliminating dormant bacilli and be safe to use over prolonged periods.

The optimal anti-TB drug regimen and duration of treatment for TBM is unknown.<sup>13</sup> Current treatment regimens for TBM are based on expert opinion rather than randomized controlled trials.<sup>14</sup> The WHO guidelines recommend that TBM should be treated for 12 months: a two-month four-drug intensive phase (RHZE, comprising rifampicin [R], isoniazid [H], pyrazinamide [Z] and ethambutol [E]) followed by a 10-month two-drug (HR) continuation phase treatment regimen.<sup>15</sup> As the WHO has to consider the circumstances under which TB will be treated worldwide, the suggested regimen is most likely based on the importance of preventing relapse, the unavailability of certain drugs (e.g. ethionamide) and an unwillingness to give pyrazinamide for more than 2 months in many settings. After meningeal inflammation has subsided, rifampicin has poor cerebrospinal fluid (CSF) penetration leaving the child effectively on isoniazid (INH) monotherapy for most of their treatment. This can be problematic in areas with high prevalence of INH resistance. In addition, the poor CSF penetration of ethambutol renders its inclusion in the regimen questionable.

Some authors have suggested that intensive short-course (6 months) chemotherapy may be safe and sufficient in children with TBM.<sup>16</sup> The short intensified treatment regimen advocated in the Western Cape with higher INH and pyrazinamide dosages, longer administration of

pyrazinamide and substitution of ethambutol with ethionamide provides higher CSF concentrations of anti-TB drugs for the entire duration of treatment. An additional benefit is that it may also overcome INH-monoresistance.<sup>17</sup> It may thus be superior to the regimen currently advocated by the WHO. However, change of international policy would require a comparative randomized controlled trial (RCT). Although a RCT would be the preferred study method, a large sample size would be required to separate out the effects of combination treatments. Wolbers et al. addressed this question by comparing 2 approaches (RCT vs. 2x2 factorial design) using a design of a new trial in TBM as an example.<sup>18</sup> In their trial example, the combination of 2 drugs added to standard treatment is assumed to reduce the hazard of death by 30% and the sample size of the combination trial to achieve 80% power was 750 patients. An adequately powered 2x2 factorial design (to detect the effect of individual drugs) would require at least 8-fold the sample size (6000 patients) of the combination trial. Another issue is that of ethics: would it be ethically acceptable for a study site, which has a good outcome and low mortality amongst their TBM cases, to participate in a RCT comparing regimens that may be inferior to what they currently use?<sup>19</sup> Recruitment of patients for the longer WHO regimen may also be difficult if an alternative option of 6 months of treatment is available.

Although it is desirable to solely rely on RCT to guide clinical practice, in some cases it is simply not feasible. RCT are typically restricted to evaluating specific discrete interventions one at a time.<sup>20</sup> This restriction limits their ability to directly assess complex interactions within a study arm (presence of raised intracranial pressure (ICP)/hydrocephalus, degree of vasculitis, HIV co-infection), and whether the benefits or harm of a treatment are drug-specific or disease specific. Such issues can only be addressed when each factor is evaluated in isolation from the others, which can make the cost to conduct RCT that evaluate all these issues prohibitive.

The challenges of conducting a RCT and our hesitancy to change our standard anti-TB treatment regimen, led me to conduct a non-inferiority trial with the aim of comparing efficacy and safety of our short-course intensified anti-TB regimen with other published regimens. The hypothesis of the second study (chapter 5) was that our short intensified anti-TB treatment is safe and sufficient in both HIV-uninfected and HIV-infected children with drug-susceptible TBM.

It is uncertain whether HIV-infected and uninfected children with TBM have different outcomes. Although one study found that the in-hospital mortality differed significantly between HIV-infected and HIV-uninfected patients (63% versus 18%, odds ratio 7.4, 95% confidence interval 3.0-18.5,  $p < 0.0001$ ), several other studies reported similar death rates during hospitalization between HIV-infected patients (13-72%) and HIV-uninfected patients (21-64%).<sup>21, 22</sup> This is why I explored the question whether there is a difference in survival prior to treatment completion between the two groups.

No studies have explored the risk of TB relapse and mortality after treatment completion between HIV-infected and HIV-uninfected children. This is why I explored the question of whether there is a difference in outcome between HIV-infected and HIV-uninfected children after treatment completion.

The literature regarding the optimal management of tuberculous hydrocephalus is confusing.<sup>23</sup> Although there is general agreement that the hydrocephalus should be treated, modes of therapy (medical or surgical) and the timing of surgery are unclear. Most studies do not determine the type of hydrocephalus before shunt surgery is performed. Complications of shunt surgery in children with tuberculous hydrocephalus are high with frequent shunt obstructions and shunt infections requiring repeated revisions. It is my experience that knowledge of the type of hydrocephalus is the key to the rational management of tuberculous hydrocephalus and that the majority of children with communicating tuberculous hydrocephalus can effectively be treated solely by diuretic therapy. A previous study at our institution found no difference in outcome between medically treated or shunted TBM children.<sup>24</sup> My study hypothesis was that there is no difference in outcome (after correcting for stage of disease, age and HIV status) between children with tuberculous hydrocephalus who were medically treated or shunted.

In-hospital treatment is widely recognized as the gold standard of treatment for children with TBM due to the complexity of care and serious consequences of non-compliance.<sup>25</sup> Long-term in-hospital TBM treatment is seldom feasible in resource-poor countries due to bed shortages and budgetary constraints. A previous study at our institution found that home-based treatment after initial hospital stabilization is feasible in selected patients under close supervision.<sup>25</sup> No studies have compared whether there is a difference in outcome (after correcting for stage of disease, HIV-status and age) between in-hospital and home-based treated children with drug-susceptible TBM. My study hypothesis was that there is no



difference in outcome between in-hospital and home-based treated children with drug-susceptible TBM (after correcting for stage of disease, age and HIV status).

The treatment of TBM-related complications is often challenging, particularly in HIV co-infected patients. TB-immune reconstitution inflammatory syndrome (IRIS) is a potentially life-threatening complication in HIV-infected children with TB of the central nervous system (CNS). Only a few case reports and one case series of TB-IRIS of the CNS have been reported in adults, but none in children.<sup>26, 27</sup> The aim of the third study (chapter 6.1) was to describe the neurological and neuro-radiological features of CNS TB-IRIS in HIV-infected children on antiretroviral therapy (ART) and to discuss possible management strategies. Study questions were: What are the neurological signs and symptoms associated with childhood CNS TB-IRIS? What are the neuro-radiological signs associated with childhood CNS TB-IRIS?

Neurological tuberculous mass lesions (tuberculomas and pseudo-abscesses) may develop or enlarge in children on anti-TB treatment.<sup>28</sup> The pathogenesis underlying these lesions remains unclear but is thought to be immune mediated.<sup>29</sup> Treatment is complicated by the fact that the lesions are unresponsive to conventional anti-TB treatment and corticosteroids. Adjunctive thalidomide, a potent inhibitor of tumour necrosis factor-alpha (TNF- $\alpha$ ) has been shown to enhance resolution of chronic tuberculous pseudoabscesses and optochiasmatic arachnoiditis.<sup>30, 31</sup> Standard practice at our hospital is to treat children with these complications with thalidomide. The optimal duration of thalidomide therapy and the correlation with magnetic resonance imaging (MRI) is yet to be explored. In a prospective observational study over 3 years (chapter 6.2), I requested that serial MRI's be performed in 16 consecutive children compromised by TB pseudoabscesses who were treated with thalidomide. My hypothesis was that tuberculous pseudo-abscesses that clinically progress despite conventional anti-TB therapy are responsive to adjuvant thalidomide and that sequential MRI may provide a marker for cure. Study questions were: Are neurological tuberculous pseudo-abscesses responsive to adjuvant thalidomide? What are the adverse effects associated with thalidomide treatment? Does serial MRI in children with pseudo-abscesses contribute to the evaluation of treatment response and duration? Can MRI assist in identifying the nature of the necrotizing process with tuberculous mass lesions? Is there a MRI marker that indicates cure?

Tuberculous hydrocephalus is often complicated by raised intracranial pressure (ICP).<sup>32</sup> In

children with TBM, especially when comatose, it is desirable to have knowledge of the ICP as elevated ICP can be life threatening. A non-invasive method of measuring ICP in children with TBM would potentially be of great value, as it may assist with assessment of shunt function, confirm fenestration patency in patients with non-communicating tuberculous hydrocephalus who underwent endoscopic third ventriculostomy and assist with evaluating the therapeutic effects of ICP-lowering drugs such as acetazolamide and furosemide.

Vascular involvement in the course of TBM has long been established in pathological as well as angiographic studies.<sup>33</sup> Cerebrovascular changes are thought to be manifold, including narrowing of large basal arteries, probably representing vasospasm and diameter alterations of small to medium-sized arteries and arterioles by arteritis.<sup>34</sup> Opinion is divided as to whether narrowing of the large basal arteries represents functional spasm or organic stenosis.<sup>34</sup> Angiographic studies do not differentiate stenosis from spasm as a cause of vessel narrowing.

Transcranial Doppler imaging (TCDI) is a safe, portable, non-invasive and inexpensive method of assessing cerebral hydro- and haemodynamics.<sup>35</sup> It can be repeated multiple times and can be used for serial monitoring. TCDI has the potential to become a valuable investigational tool in children with TBM; a condition often complicated by pathology relevant to Doppler imaging such as raised ICP/hydrocephalus and vascular stenosis/occlusion. The hypothesis of my fifth study (chapter 6.3) was that TCDI is a valuable investigative tool in the monitoring of children with tuberculous hydrocephalus and vasculopathy. Serial TCDI recordings were performed on 20 TBM children by one investigator as a bedside investigation using a GE Healthcare Vivid S5 high-end ultrasound machine with a 2-Mhz probe.<sup>36</sup> Recordings were performed on admission and repeated on day 3 and 7. Lumbar CSF pressure was recorded immediately after TCDI upon admission, and after 3 and 7 days. In the same cohort of TBM children I also measured cerebral blood flow velocity (BFV) in the anterior cerebral artery (ACA), middle cerebral artery (MCA) and posterior cerebral artery (PCA) on admission and after day 3 and 7. Study questions were: Can TCDI predict raised ICP in children with TBM? Can TCDI detect the level of the CSF block in children with TBM? Can TCDI identify shunt dysfunction in children with tuberculous hydrocephalus? How effective is diuretic therapy at reducing raised ICP in TBM children with communicating hydrocephalus? Does diuretic therapy affect cerebral BFV? Can TCDI predict the development of infarcts? Does vasospasm mediate stroke early in the course of TBM disease?

## References

1. World Health Organization. Global tuberculosis report 2013. WHO, Geneva, Switzerland. WHO/HTM/TB/2013.11
2. Wood R, Johnson-Robertson S, Uys P et al. Tuberculosis transmission to young children in a South African community: modeling household and community infection risks. *Clin Infect Dis* 2010; 51:401-408
3. Shima T. Surveillance of tuberculosis. *Bull Int Union Tuberc* 1983; 58:48-52
4. Wolzak NK, Cooke ML, Orth H, et al. The changing profile of pediatric meningitis at a referral centre in Cape Town, South Africa. *J Trop Pediatr* 2012; 58:491-495.
5. Thwaites GE, Tran TH. Tuberculous meningitis: many questions, too few answers. *Lancet Neurol* 2005; 4:160-170.
6. Thwaites GE, van Toorn R, Schoeman JF. Tuberculous meningitis: more questions, still too few answers. *Lancet Neurol* 2013; 12:999-1010.
7. van Toorn R, Solomons R. Update on the diagnosis and management of tuberculous meningitis in children. *Semin Pediatr Neurol* 2014; 21:12-18.
8. van Toorn R, Springer P, JA Loubser et al. Value of different staging systems for predicting neurological outcome in childhood tuberculous meningitis. *Int J Tuberc Lung Dis* 2012; 16:628-632.
9. Teasdale G, Jennet B. Assessment of coma and impaired consciousness. A practical scale. *Lancet* 1974; 2:81-84.
10. Chou C-H, Lin G-M, Ku C-H et al. Comparison of the APACHE II, GCS and MRC scores in predicting outcomes in patients with tuberculous meningitis. *Int J Tuberc Lung Dis* 2010; 14:86-92.

11. Saitoh A, Pong A, Waecker NJ et al. Prediction of neurologic sequelae in childhood tuberculous meningitis: a review of 20 cases and proposal of a novel scoring system. *Pediatr Infect Dis J* 2005; 24:207-212.
12. Medical Research Council Streptomycin in Tuberculous Trials Committee. Streptomycin treatment of tuberculous meningitis. *Lancet* 1948; 1:582-596.
13. Jacobs RF, Sunakorn P. Tuberculous meningitis in children: an evaluation of chemotherapeutic regimens. *Am Rev Respir Dis* 1990; 141:A337.
14. Woodfield J, Argent A. Evidence behind the WHO guidelines: hospital care for children: what is the most appropriate treatment for tuberculous meningitis? *J Trop Pediatr* 2008; 54:220-224.
15. World Health Organization. Rapid advice: treatment of tuberculosis in children. WHO, Geneva, Switzerland. WHO/HTM/TB/2010.13
16. Donald PR, Schoeman JF, Van Zyl LE et al. Intensive short course chemotherapy in the management of tuberculous meningitis. *Int J Tuberc Lung Dis* 1998; 2:704-711.
17. Seddon JA, Visser DH, Bartens M et al. Impact of drug resistance on clinical outcome in children with tuberculous meningitis. *Pediatr Infect Dis J* 2012; 31:711-716.
18. Wolbers M, Heemskerk D, Chau TT et al. Sample size requirements for separating out the effects of combination treatments: a randomised controlled trial of combination therapy vs. standard treatment compared to factorial designs for patients with tuberculous meningitis. *Trials* 2011; 12:26
19. van Toorn R, Schaaf HS, Schoeman JF. In Reply: short intensified treatment in children with drug-susceptible tuberculous meningitis. *Pediatr Infect Dis J* 2014; 33:993-994.
20. Stanley K. Evaluation of randomized controlled trials. *Circulation* 2007; 115:1819-1822.
21. van der Weert, Hartgers NM, Schaaf HS et al. Comparison of diagnostic criteria of tuberculous meningitis in Human Immunodeficiency Virus-infected and uninfected

children. *Pediatr Infect Dis J* 2006; 25:65-69.

22. Marais S, Pepper DJ, Marais BJ et al. HIV-associated tuberculous meningitis-diagnostic and therapeutic challenges. *Tuberculosis* 2010; 90:367-374.

23. Marwaha R. Role of shunt surgery in pediatric tubercular meningitis with hydrocephalus. *Indian Pediatrics* 2005; 42:735-736.

24. Schoeman JF, Laubscher JA, Donald PR. Serial lumbar CSF pressure measurements and cranial computed tomographic findings in childhood tuberculous meningitis. *Child Nerv Sys* 2000; 16:203-209.

25. Schoeman JF, Malan G, van Toorn R, et al. Home-based treatment of childhood neurotuberculosis. *J Trop Pediatr* 2009; 55:149-154.

26. Pepper DJ, Marais S, Maartens G, et al. Neurologic manifestations of paradoxical tuberculosis-associated immune reconstitution inflammatory syndrome: a case series. *Clin Infect Dis* 2009; 48:e96-107.

27. Dautremer J, Pacanowski J, Girard PM et al. A new presentation of immune reconstitution inflammatory syndrome followed by a severe paradoxical reaction in an HIV-1-infected patient with tuberculous meningitis. *AIDS* 2007; 21:381-382.

28. Afghani B, Lieberman JM. Paradoxical enlargement or development of intracranial tuberculomas during therapy: case report and review. *Clin Infect Dis* 1994; 19:1092-1099.

29. Chambers ST, Hendrikse WA, Record C et al. Paradoxical expansion of intracranial tuberculomas during chemotherapy. *Lancet* 1984; 2:181-184.

30. Schoeman JF, Ravenscroft A, Hartzenberg HB. Possible role of adjunctive thalidomide therapy in the resolution of a massive intracranial tuberculous abscess. *Childs Nerv Syst* 2001; 17:370-371.

31. Schoeman JF, Andronikou S, Stefan DC, Freeman N et al. Tuberculous meningitis-related optic neuritis: recovery of vision with thalidomide in 4 consecutive cases. *J Child Neurol* 2010; 25:822-828.

32. van Well GT, Paes BF, Terwee CB et al. Twenty years of pediatric tuberculous meningitis: a retrospective cohort study in the Western Cape of South Africa. *Pediatrics* 2009; 123(1):e1-8
33. Kalita J, Prasad S, Maurya PK et al. Kumar S, Misra UK. MR angiography in tuberculous meningitis. *Acta Radiol* 2012; 53:324-329.
34. Lammie GA, Hewlett RH, Schoeman JF et al. Tuberculous cerebrovascular disease: a review. *J Infect* 2009; 59:156-166.
35. Kassab MY, Majid A, Farooq M et al. Transcranial Doppler: An introduction for primary care physicians. *J Am Board Fam Med* 2007; 20:65-71.
36. Van Toorn R, Schaaf HS, Solomons R et al. The value of Transcranial Doppler imaging in children with tuberculous meningitis. *Childs Nerv Syst* 2014; 30:1711-1716.

## **Chapter 2**

**Tuberculous meningitis: more questions, still too few answers**

# Tuberculous meningitis: more questions, still too few answers



Guy E Thwaites, Ronald van Toorn, Johan Schoeman

Tuberculous meningitis is especially common in young children and people with untreated HIV infection, and it kills or disables roughly half of everyone affected. Childhood disease can be prevented by vaccination and by giving prophylactic isoniazid to children exposed to infectious adults, although improvements in worldwide tuberculosis control would lead to more effective prevention. Diagnosis is difficult because clinical features are non-specific and laboratory tests are insensitive, and treatment delay is the strongest risk factor for death. Large doses of rifampicin and fluoroquinolones might improve outcome, and the beneficial effect of adjunctive corticosteroids on survival might be augmented by aspirin and could be predicted by screening for a polymorphism in *LTA4H*, which encodes an enzyme involved in eicosanoid synthesis. However, these advances are insufficient in the face of drug-resistant tuberculosis and HIV co-infection. Many questions remain about the best approaches to prevent, diagnose, and treat tuberculous meningitis, and there are still too few answers.

## Introduction

8 years ago in a Review in *The Lancet Neurology*,<sup>1</sup> Thwaites and Hien argued that the prevention and treatment of tuberculous meningitis posed many questions for which there were too few answers. The aim of this update Review is to determine whether there are now answers to those questions and to reassess the challenges that face those tasked with the prevention, diagnosis, and treatment of tuberculous meningitis in children and adults.

## Are we doing better at preventing tuberculous meningitis?

Tuberculous meningitis represents roughly 1% of all cases of tuberculosis, but is disproportionately important because it kills or severely disables about half of the people affected. The successful prevention of pyogenic bacterial meningitis through vaccination has also meant that in many parts of the world tuberculosis is the most common cause of bacterial meningitis.<sup>2</sup> Tuberculous meningitis affects all age groups, but is especially common in young children and in people with untreated HIV infection. Incidence is directly related to the prevalence of pulmonary tuberculosis; therefore, optimisation of global tuberculosis control is the key to prevention.<sup>3,4</sup> WHO estimated that in 2010 there were 8.8 million new cases of tuberculosis of all forms worldwide and 1.45 million deaths from the infection.<sup>5</sup> The absolute numbers of new tuberculosis cases started to fall from a peak around 2006–07, and tuberculosis mortality has been falling from a peak of about 3 million deaths per year in the late 1990s. Although these numbers are encouraging, they disguise great regional variation. In metropolitan London, UK, for example, the number of new tuberculosis cases has doubled in the past 10 years.<sup>6</sup> A similar increase has been seen in the Western Cape province of South Africa, where tuberculous meningitis is the most common childhood meningitis.<sup>7</sup>

One of the unequivocal benefits of *Bacillus Calmette–Guérin* (BCG) vaccination is protection against disseminated forms of childhood tuberculosis, especially meningitis.<sup>8</sup> Several new tuberculosis vaccines have entered phase 1 and phase 2 clinical trials with the aim of

providing enhanced protection against pulmonary tuberculosis,<sup>9</sup> which if successful will also reduce the incidence of tuberculous meningitis. The identification and treatment of individuals with latent tuberculosis also helps to prevent tuberculous meningitis. In particular, isoniazid prophylaxis is highly effective for the prevention of tuberculous meningitis in young children exposed to household contacts with pulmonary tuberculosis.<sup>10</sup>

## Have we improved the two-step model of the pathogenesis of tuberculous meningitis?

Eight decades ago Rich and McCordock<sup>11</sup> showed experimentally that tuberculous meningitis does not result from direct haematogenous spread of *Mycobacterium tuberculosis* to the meninges. In serial autopsies of fatal childhood tuberculous meningitis they identified tuberculous granulomas (or Rich foci) that released bacteria into the subarachnoid space.<sup>11</sup> This two-step model of tuberculous meningitis pathogenesis has remained largely unchallenged ever since.<sup>12</sup>

However, how *M tuberculosis* leaves the lung, enters the brain, and causes the subsequent cerebral pathology remains unclear. Haematogenous dissemination probably occurs early in the infection, before it has been controlled by the adaptive immune response.<sup>13</sup> In human beings, this early haematogenous dissemination explains why individuals with impaired T-cell responses (eg, untreated HIV infection) are especially susceptible to disseminated disease; why children with BCG-primed T-cell responses are protected against miliary tuberculosis and meningitis; and why polymorphisms in genes involved in the early, innate immune response (*TIRAP*,<sup>14</sup> *TLR2*<sup>15</sup>) are associated with the development of tuberculous meningitis. Although a few studies have shown no benefit for vitamin D supplementation in active pulmonary tuberculosis,<sup>16</sup> an association between tuberculous meningitis and low sunshine hours 3 months before disease<sup>17</sup> suggests a possible role for vitamin D in bacterial dissemination.

Findings from epidemiological studies lend support to the hypothesis that some strains of *M tuberculosis* are more likely than others to cause tuberculous meningitis.

*Lancet Neurol* 2013;  
12: 999–1010

Published Online  
August 23, 2013  
[http://dx.doi.org/10.1016/S1474-4422\(13\)70168-6](http://dx.doi.org/10.1016/S1474-4422(13)70168-6)

Centre for Clinical Infection and Diagnostics Research, Guy's and St Thomas' Hospital, London, UK (G E Thwaites PhD); Department of Infectious Diseases, King's College London, London, UK (G E Thwaites); and Department of Paediatrics and Child Health, Faculty of Medicine and Health Sciences, University of Stellenbosch, Cape Town, South Africa (R van Toorn MBChB, Prof J Schoeman MD)

Correspondence to:  
Dr Guy Thwaites, Centre for Clinical Infection and Diagnostics Research, St Thomas' Hospital, Westminster Bridge Road, London SE1 7EH, UK  
[guy.thwaites@btinternet.com](mailto:guy.thwaites@btinternet.com)



Investigators of a case-control study in Vietnam reported that strains from the Euro-American lineage of *M tuberculosis* were significantly less likely than those of the Indo-Oceanic or East Asian Beijing lineages to cause meningitis,<sup>18</sup> although they could not provide a mechanistic explanation for this finding.<sup>19</sup> The genes that enable the bacteria to cross the blood–brain barrier have been investigated with transposon mutants and in-vitro and in-vivo models,<sup>20–22</sup> culminating in the identification of one bacterial gene, *Rv0931c* (also known as *pknD*), that encodes a serine/threonine protein kinase necessary for brain endothelial invasion.<sup>23</sup> Whether or not naturally occurring variants of this gene in *M tuberculosis* isolates affect the development of tuberculous meningitis is unknown.

### Why are there still delays in clinical recognition and diagnosis?

The peak incidence of tuberculous meningitis is in children aged 2–4 years.<sup>24</sup> Early clinical diagnosis is notoriously difficult and often delayed, with disastrous consequences for patients. Early diagnosis and treatment of tuberculous meningitis has long been recognised as the single most important factor determining outcome.<sup>25</sup>

The clinical features of tuberculous meningitis are well described (table 1).<sup>1</sup> The classic presentation is as a subacute meningitic illness. The difficulty is that neck stiffness is usually absent during early disease in patients of all ages.<sup>25,26</sup> Tuberculous meningitis therefore needs to be recognised early from non-specific symptoms of general ill health, rather than from classic signs of

meningitis. In young children these non-specific symptoms include poor weight gain, low-grade fever, and listlessness.<sup>27</sup> In infants, most early symptoms are related to the primary pulmonary infection, which occurs before development of tuberculous meningitis. In adults, malaise and anorexia precede worsening headache and vomiting. The only factor that differentiates the symptoms of tuberculous meningitis from common illnesses such as influenza is their persistence,<sup>28</sup> although this feature is often missed if a patient does not see the same health professional consistently.<sup>28</sup> Thus early, curable tuberculous meningitis can progress to the final stages of coma, opisthotonus, and death.

Although the neurological manifestations of advanced tuberculous meningitis are well described,<sup>1,29</sup> once the signs of advanced disease (including meningeal irritation, coma, seizures, signs of raised intracranial pressure, cranial nerve palsies, hemiparesis, and movement disorders) are seen the diagnosis is usually apparent, but at a serious cost to the patient. Occasionally tuberculous meningitis can present acutely, with these normally late signs already apparent and without a distinct prodromal period.<sup>25</sup> Organism genotype,<sup>30,31</sup> drug resistance,<sup>32</sup> HIV co-infection,<sup>33,34</sup> and BCG immunisation status<sup>35,36</sup> do not consistently modify disease presentation.

Several studies have defined the clinical features most predictive of tuberculous meningitis (table 2).<sup>37–43</sup> The strongest of these features, across all studies, is symptom duration longer than 5 days. Diagnostic rules have been developed on the basis of these predictive

	Symptoms	Clinical signs	CSF examination
Children	Early symptoms are non-specific and include cough, fever, vomiting (without diarrhoea), malaise, and weight faltering	Initial apathy or irritability that progresses to meningism, decreased level of consciousness, signs of raised intracranial pressure (often bulging anterior fontanelle and abducens nerve palsy), and focal neurological signs (most often hemiplegia)	Usually clear and colourless; raised numbers of white cells ( $0.05 \times 10^9$ – $1.00 \times 10^9$ /L), with mixture of neutrophils and lymphocytes; raised protein ( $0.5$ – $2.5$ g/L); ratio of CSF to plasma glucose $<0.5$ in 95% of cases
Adults	Non-specific prodrome of malaise, weight loss, low-grade fever, and gradual onset of headache over 1–2 weeks; followed by worsening headache, vomiting, and confusion, leading to coma and death if untreated	Variable degrees of neck stiffness; cranial nerve palsies (VI>III>IV>VII) develop as disease progresses and confusion and coma deepen; monoplegia, hemiplegia, or paraplegia in about 20% of cases	High opening pressure ( $>25$ cm H <sub>2</sub> O) in 50% of cases; raised numbers of white cells ( $0.05 \times 10^9$ – $1.00 \times 10^9$ /L), with mixture of neutrophils and lymphocytes; raised protein ( $0.5$ – $2.5$ g/L); ratio of CSF to plasma glucose $<0.5$ in 95% of cases

**Table 1: Common clinical features of tuberculous meningitis in children and adults<sup>1</sup>**

	Children <sup>37</sup>	Children and adults <sup>38,40</sup>	Adults <sup>39,41–43</sup>
History and examination	Duration of symptoms $>6$ days; optic atrophy; abnormal movements; focal neurological deficit	Duration of symptoms $>5$ days; Glasgow coma score $<15$ or focal neurological deficit	Duration of symptoms $\geq 6$ days; age $<36$ years; rural dwelling; focal neurological deficit; fever*; neck stiffness*; coma*
CSF findings	Neutrophils $<50\%$ of total white cells	Clear appearance; white cell count $>1.00 \times 10^9$ /L; lymphocytes $>30\%$ of total white cells; protein $>1.0$ g/L; ratio of CSF to plasma glucose $<0.5$	Clear appearance; white cell count $<0.75 \times 10^9$ /L; neutrophils $<90\%$ of total white cells; ratio of CSF to serum glucose $\leq 0.2$ ; lymphocytes $>0.20 \times 10^9$ /L; low CSF pressure*; raised leucocyte numbers*
Other findings	..	..	Blood white cell count $<15 \times 10^9$ /L; if HIV infected, CD4 cell count $<200$ per $\mu$ L; negative cryptococcal antigen test

\*Compared with cryptococcal meningitis in HIV-infected individuals.

**Table 2: Discriminatory clinical features for the diagnosis of tuberculous meningitis in children and adults**

variables, but only the rule developed in Vietnam has been tested in different populations (panel).<sup>39</sup> The Vietnam rule was originally described as 86% sensitive and 79% specific for tuberculous meningitis diagnosis in adults; subsequent studies in Turkey,<sup>44</sup> Vietnam,<sup>45</sup> and India<sup>41</sup> have reported sensitivities ranging from 96% to 98% and specificities ranging from 68% to 88%. The major limitation of the rule, however, was exposed by a study of 86 HIV-infected Malawian adults with meningitis, in which it was 78% sensitive and 43% specific.<sup>46</sup> Cryptococcal meningitis accounted for the 12 false positive results.

Two studies<sup>42,43</sup> have identified clinical features that distinguish tuberculous meningitis from cryptococcal meningitis in HIV-infected patients. The first<sup>43</sup> showed that tuberculous meningitis could be diagnosed with 98% specificity and 47% sensitivity if the patient had a CD4 cell count of less than 200 per  $\mu\text{L}$ , a ratio of CSF to plasma glucose of 0.2 or less, a total number of CSF lymphocytes greater than 200 cells per  $\mu\text{L}$ , and a negative CSF cryptococcal antigen test. The second<sup>42</sup> reported that, compared with cryptococcal meningitis, tuberculous meningitis was associated with more neck stiffness, higher body temperature, reduced consciousness, lower CSF pressures, and higher CSF leucocyte numbers. A CSF cryptococcal antigen test has high positive and negative predictive value and is an essential test in patients with a protracted meningitic illness.<sup>47</sup>

## Has laboratory diagnosis of tuberculous meningitis improved?

### Microscopy

The diagnostic utility of CSF Ziehl-Neelsen staining and microscopy for acid-fast bacilli is variable and often very poor. Meticulous microscopy of large CSF volumes improves sensitivity,<sup>48</sup> but it rarely exceeds 60%.<sup>49</sup> Investigators of a study from China reported that simple modification to the Ziehl-Neelsen stain, through enhancement of CSF intracellular bacterial staining by pretreatment with Triton X-100, resulted in acid-fast bacilli, most of which were intracellular, being seen in 48 of 48 CSF samples from 29 patients with tuberculous meningitis.<sup>50</sup> These impressive results need to be replicated in larger studies, but the modification could be a simple solution to a longstanding problem.

### Nucleic acid amplification techniques

In a meta-analysis<sup>51</sup> of studies reported before 2002 that examined the use of nucleic acid amplification techniques (NAATs) for the diagnosis of tuberculous meningitis, the investigators calculated that commercial NAATs were 56% sensitive (95% CI 46–66) and 98% specific (97–99). Guidelines recommend NAATs can confirm a diagnosis of tuberculous meningitis, but cannot rule it out.<sup>52</sup> More recent data suggest that sensitivity might be improved by real-time PCR,<sup>53–57</sup> and by assaying CSF filtrates rather than sediments,<sup>58</sup> although these findings need to be confirmed.

### Panel: The Vietnam diagnostic rule<sup>39</sup>

#### Entry criteria

- Adult (age >15 years) with meningitis and ratio of CSF to plasma glucose <0.5

#### Clinical features and scores

- Age  $\geq 36$  years (score +2)
- Age <36 years (score 0)
- Blood white cell count  $\geq 15 \times 10^9/\text{L}$  (score +4)
- Blood white cell count < $15 \times 10^9/\text{L}$  (score 0)
- History of illness  $\geq 6$  days (score –5)
- History of illness <6 days (score 0)
- CSF white cell count  $\geq 0.75 \times 10^9/\text{L}$  (score +3)
- CSF white cell count < $0.75 \times 10^9/\text{L}$  (score 0)
- CSF neutrophils  $\geq 90\%$  of total white cells (score +4)
- CSF neutrophils <90% of total white cells (score 0)

#### Interpretation

- Total score  $\leq 4$  = tuberculous meningitis
- Total score >4 = alternative diagnosis

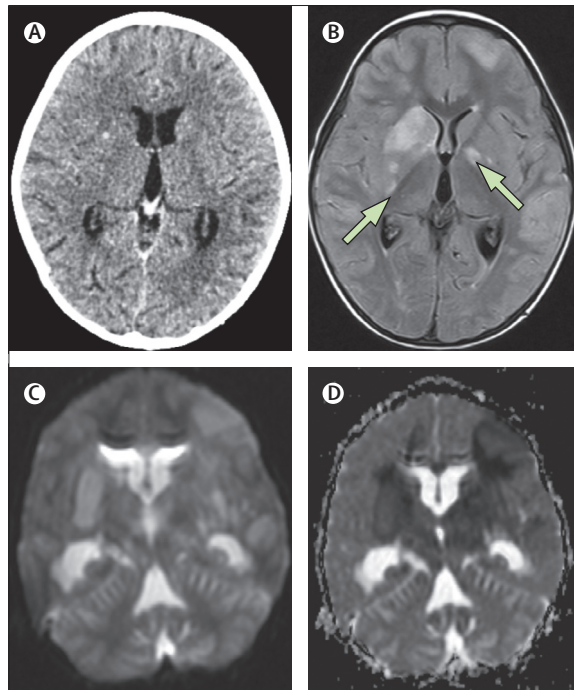
The Xpert MTB/RIF assay (Cepheid, Sunnyvale, CA, USA) uses real-time PCR and is set to become the cornerstone of commercial molecular diagnosis of tuberculosis.<sup>59</sup> It potentially has sensitivity and specificity values equivalent to those from in-vitro CSF culture, confirming *M tuberculosis* in CSF and its susceptibility to rifampicin within 2 h, although its value in the diagnosis of tuberculous meningitis is uncertain. A meta-analysis<sup>60</sup> of studies reported up to October, 2011, estimated that Xpert MTB/RIF was 80.4% sensitive compared with culture for the diagnosis of extrapulmonary tuberculosis. A study in India of Xpert MTB/RIF for the diagnosis of extrapulmonary tuberculosis<sup>61</sup> included 142 CSF samples and reported that the assay was nearly 12 times more sensitive than microscopy for the diagnosis of tuberculous meningitis. The cost of processing one Xpert MTB/RIF test, however, was 82 times higher than the cost of microscopy. Larger studies to assess Xpert MTB/RIF for the diagnosis of tuberculous meningitis are urgently needed.

### Interferon-gamma release assays

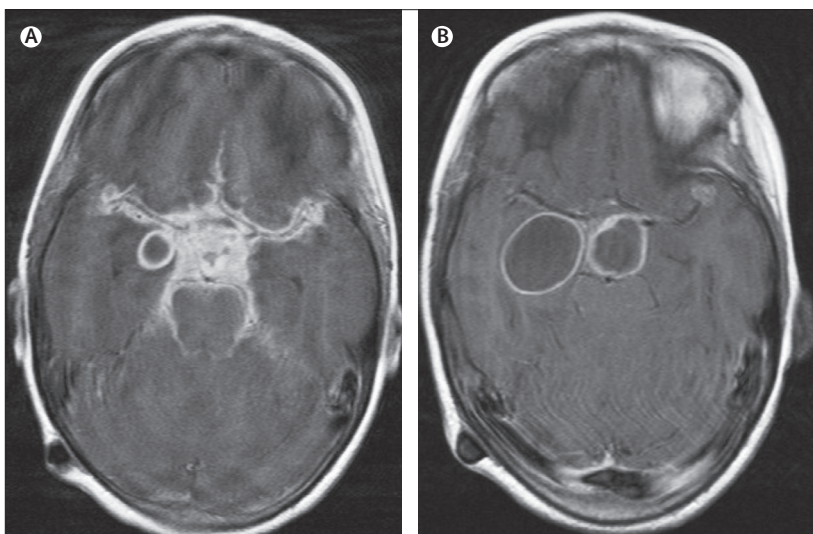
A few studies have examined the diagnostic use of interferon-gamma release assays on CSF for the diagnosis of tuberculous meningitis.<sup>62–65</sup> Their findings suggest that indeterminate results are common, unless CSF volumes of 5–10 mL are tested, and that the assays are specific (70–90%), but have low sensitivity (50–70%). South African investigators have suggested that the specificity of CSF interferon-gamma release assays is sufficiently high, when combined with other negative microbiological tests, to make a useful rule-in test.<sup>62</sup> In view of the CSF volumes necessary, however, whether these assays have any advantage compared with NAATs is unclear.

### Rapid detection of drug resistance

The standard laboratory methods to test for drug susceptibility in *M tuberculosis* are too slow to support



**Figure 1: The value of MRI for detection of tuberculous meningitis**  
(A) Normal brain CT scan of a 3-year-old child with stage 3 tuberculous meningitis. (B) A T2-weighted, fluid-attenuated, inverse-recovery MRI image taken 5 days later showed several infarcts (arrows) in the basal ganglia. MRIs with diffusion-weighted imaging (C) and apparent diffusion coefficient (D) show restriction of diffusion and bilateral cytotoxic oedema in the basal ganglia.



**Figure 2: Tuberculous meningitis-associated optochiasmatic arachnoiditis**

(A) Initial T1-weighted post-gadolinium MRI scan of a 7-year-old boy with blindness caused by severe tuberculous meningitis-related optochiasmatic arachnoiditis shows enhancement of the whole suprasellar cistern with displacement and compression of the optic nerve anteriorly. A ring-enhancing tuberculous abscess is also visible in the right temporal lobe. (B) After 3 months of adjuvant thalidomide the patient regained full vision and follow-up MRI shows a substantial improvement of the optochiasmatic arachnoiditis despite asymptomatic enlargement of suprasellar and temporal lobe abscesses.

clinical decision making in tuberculous meningitis. Patients with drug-resistant disease have usually died before the results are returned.<sup>66–68</sup> The microscopic observational drug susceptibility assay has the potential to deliver timely resistance results,<sup>69</sup> although findings from one study<sup>70</sup> suggested that the assay detected *M tuberculosis* within CSF, but could not simultaneously define its resistance profile. Therefore, the only way to diagnose drug-resistant tuberculous meningitis with sufficient speed at present is through CSF NAATs and the detection of genetic mutations that confer drug resistance. However, this approach is limited by the low sensitivity of CSF NAATs and uncertainty about which mutations best predict resistance for some drugs. Commercial NAATs for the concurrent detection of bacterial presence and rifampicin resistance are available (eg, INNO-LiPA Rif.TB and Xpert MTB/RIF), since almost all the mutations that confer rifampicin resistance are contained within a well-defined segment of the *rpoB* gene. Resistance to other drugs is less easily detected by these methods. For example, the resistance genes identified in 20% of isoniazid-resistant strains are diverse and poorly characterised.

### Neuroimaging

Brain CT can reveal basal hyperdense exudates on precontrast scans, and basal meningeal enhancement, infarcts, hydrocephalus, and tuberculomas can be seen in contrast-enhanced CT. In combination, these features are highly suggestive of tuberculous meningitis in both adults and children.<sup>24,71</sup> However, about 30% of children with early tuberculous meningitis will have a normal brain CT.<sup>72</sup>

MRI is superior to CT at defining the neuroradiological features of tuberculous meningitis, especially when they involve the brainstem (figure 1).<sup>73</sup> MRI with diffusion-weighted imaging enhances the detection of early infarcts and border-zone encephalitis (cytotoxic oedema that underlies the tuberculous exudates).<sup>73</sup> Gadolinium-enhanced MRI allows visualisation of leptomeningeal tubercles, which are present in about 90% of children<sup>74</sup> and 70% of adults with the disease.<sup>75</sup> MRI is also valuable for the identification and monitoring of tuberculous meningitis-related cranial neuropathies. The most important of these neuropathies is optochiasmatic arachnoiditis, which requires urgent intervention to reduce the risk of blindness (figure 2).<sup>74</sup> Magnetic resonance angiography can be used to identify vascular involvement, which is present in 60% of cases and most often affects the terminal portions of the internal carotid arteries and proximal parts of the middle and anterior cerebral arteries.<sup>76</sup>

The MRI appearances of intracranial tuberculomas depend on the pathological maturation of the lesion.<sup>77</sup> Non-caseating (non-necrotising) tuberculomas are usually hypointense on T1-weighted images and hyperintense on T2-weighted images; the entire lesion shows homogeneous enhancement after contrast administration. Solid caseating (necrotising) tuberculomas appear hypointense or

isointense on T1-weighted images and isointense to hypointense on T2-weighted images (T2 black), with rim enhancement. Liquefied caseating tuberculomas have the MRI appearance of an abscess; the liquefied centre becomes hypointense on T1-weighted images and hyperintense on T2-weighted images, with rim enhancement after contrast administration. Tuberculous abscesses are larger than tuberculomas (often >3 cm in diameter), solitary, thin walled, and often multi-loculated.<sup>77</sup> Magnetic resonance spectroscopy can help to discriminate tuberculous and non-tuberculous brain lesions, since tuberculous lesions have raised lipid peaks.<sup>78</sup>

### Are we using the right drugs and doses in antituberculosis chemotherapy?

The principles of tuberculous meningitis treatment are still derived from observational studies and clinical practice rather than from controlled trials. They include the importance of starting antituberculosis chemotherapy early; the recognition that isoniazid and rifampicin are the key components of the regimen; the potentially fatal consequences of interrupting treatment during the first 2 months; and the perceived need for long-term treatment (9–12 months) to prevent disease relapse.

Table 3 shows the recommended first-line treatment regimens for children and adults with tuberculous meningitis.<sup>52,79–81</sup> The ability of the blood–brain barrier to limit intracerebral concentrations of antituberculosis drugs is an important consideration in the treatment of tuberculous meningitis. Table 4 shows the estimated CSF penetration of first-line and second-line antituberculosis agents.<sup>82–85</sup> CSF penetration has particular relevance for consideration of which drug should accompany rifampicin, isoniazid, and

pyrazinamide in the standard regimen, and for the treatment of drug-resistant tuberculous meningitis.

Most regulatory bodies recommend either streptomycin or ethambutol as the fourth drug in standard treatment, although neither penetrates the CSF well in the absence of inflammation,<sup>83</sup> and both can produce serious adverse reactions, especially in patients with impaired renal function. Streptomycin should not be given to patients who are pregnant or who have renal impairment, and streptomycin resistance is fairly common worldwide.<sup>5</sup> Ethambutol-induced optic neuritis is a concern, especially in the treatment of comatose patients, although at the standard dose of 15–20 mg/kg the incidence is less than 3%.<sup>86</sup> Some centres, including our own in Cape Town, South Africa (Department of Paediatrics and Child Health, Tygerberg Children's Hospital, University of Stellenbosch), advocate ethionamide, which can penetrate healthy and inflamed blood–brain barriers and is safer than ethambutol and streptomycin.<sup>87</sup>

The fluoroquinolones could represent highly effective fourth drugs and are an essential component of treatment regimens for multidrug-resistant cases. Investigators of a randomised comparison<sup>88</sup> of ciprofloxacin (750 mg every 12 h), levofloxacin (500 mg every 12 h), and gatifloxacin (400 mg every 12 h) added to conventional four-drug tuberculous meningitis treatment noted that CSF penetration (measured by the ratio of plasma to CSF area under the concentration-time curve) was greater for levofloxacin (median 0.74) than for gatifloxacin (median 0.48) or ciprofloxacin (median 0.26). Ciprofloxacin has the least in-vitro activity against *M tuberculosis* and, in view of its poor CSF penetration, should never be used for treatment of tuberculous meningitis. Overall, however, fluoroquinolones seemed to add antituberculosis activity

	WHO <sup>79,80</sup> and UK <sup>82</sup> recommendations				Cape Town paediatric intensive regimen <sup>81</sup>		
	Daily dose in children	Daily dose in adults	Route of administration	Duration	Daily dose	Route	Duration
<b>Antituberculosis drugs</b>							
Isoniazid	10–20 mg/kg (maximum 500 mg)	300 mg	Oral	12 months	20 mg/kg (maximum 400 mg)	Oral	6 months
Rifampicin	10–20 mg/kg (maximum 600 mg)	450 mg (weight <50 kg) or 600 mg (weight ≥50 kg)	Oral	12 months	20 mg/kg (maximum 600 mg)	Oral	6 months
Pyrazinamide	15–30 mg/kg (maximum 2 g)	1.5 g (weight <50 kg) or 2.0 g (weight ≥50 kg)	Oral	2 months	40 mg/kg (maximum 2 g)	Oral	6 months
Ethambutol	15–20 mg/kg (maximum 1 g)	15 mg/kg	Oral	2 months	Not recommended		
Ethionamide	Not recommended	..			20 mg/kg (maximum 1 g)	Oral	6 months
<b>Adjunctive corticosteroids</b>							
Prednisolone	4 mg/kg*	2.5 mg/kg*	Intravenous initially, then switch to oral when safe to do so	4 weeks then reduce to stop over 4 weeks	2 mg/kg (maximum 60 mg)	Oral	1 month, then reduce to stop over 2 weeks
Dexamethasone	0.6 mg/kg*	0.4 mg/kg*	Intravenous initially, then switch to oral when safe to do so	Reducing each week to stop over 6–8 weeks	..	..	..

\*No data exist to compare the relative efficacy of dexamethasone with prednisolone, but they are widely regarded as equivalent for the treatment of tuberculous meningitis; either can be used, with the choice based on ease of administration.

**Table 3: First-line treatment regimens for tuberculous meningitis in children and adults**



## Review

	Standard daily dose for adults	Estimated ratio of CSF to plasma concentration	Comments
Isoniazid	300 mg	80–90%	Essential drug; good CSF penetration throughout treatment
Rifampicin	450 mg (weight <50 kg) or 600 mg (weight ≥50 kg)	10–20%	Essential drug, despite relatively poor CSF penetration; higher doses might improve effectiveness
Pyrazinamide	1.5 g (weight <50 kg) or 2.0 g (weight ≥50 kg)	90–100%	Excellent CSF penetration throughout treatment
Ethambutol	15 mg/kg	20–30%	Poor CSF penetration once meningeal inflammation resolves
Streptomycin	15 mg/kg (1 g maximum)	10–20%	Poor CSF penetration once meningeal inflammation resolves
Kanamycin	15 mg/kg	10–20%	Poor CSF penetration once meningeal inflammation resolves
Amikacin	15–20 mg/kg	10–20%	Poor CSF penetration once meningeal inflammation resolves
Moxifloxacin	400 mg	70–80%	Good CSF penetration
Levofloxacin	1000 mg	70–80%	Good CSF penetration
p-Aminosalicylic acid	10–12 g	No data	Probably very poor CSF penetration unless meninges are inflamed
Ethionamide or prothionamide	15–20 mg/kg (1 g maximum)	80–90%	Good CSF penetration
Cycloserine	10–15 mg/kg	80–90%	Good CSF penetration
Linezolid	1200 mg	40–70%	Variable interindividual CSF pharmacokinetics
Capreomycin	15–20 mg/kg	No data	..

**Table 4: CSF penetration of first-line and second-line antituberculosis drugs<sup>82–85</sup>**

to the standard regimen and to improve outcome, provided they were started before the onset of coma. Moxifloxacin probably penetrates the CSF at least as well as levofloxacin, possibly accumulates in the CSF, and has the theoretical advantage of greater in-vitro activity against *M. tuberculosis* than levofloxacin.<sup>89</sup> In high doses, fluoroquinolones can cause seizures;<sup>90</sup> whether such seizures are more likely to occur in the treatment of tuberculous meningitis than in the treatment of non-meningitic or neurological infection is uncertain.

Investigators in Indonesia have tested the hypothesis that treatment intensification, through use of high-dose intravenous rifampicin and the addition of moxifloxacin, would enhance bacterial killing and improve outcome.<sup>91</sup> 60 adults with tuberculous meningitis were randomly allocated to treatment with daily rifampicin at either standard dose (450 mg, about 10 mg/kg) orally or high dose (600 mg, about 13 mg/kg) intravenously, and either 400 mg or 800 mg oral moxifloxacin or 750 mg ethambutol for the first 14 days of treatment. High-dose intravenous rifampicin led to a three-times increase in the plasma and CSF area under the concentration-time curve compared with the standard oral dose and was associated with a substantial drop in mortality (65% vs 35%), which could not be accounted for by HIV status or baseline disease severity.

This finding provides compelling evidence that the chemotherapeutic regimen for tuberculous meningitis

needs to be optimised and that the recommended doses of rifampicin might be too low because of its poor CSF penetration.<sup>82</sup> The results of a large randomised controlled trial (ISRCTN61649292) to compare standard with intensive therapy (rifampicin 15 mg/kg every 24 h and levofloxacin 500 mg every 12 h as the fourth drug) are eagerly awaited.<sup>92</sup>

Lengthy in-hospital treatment of tuberculous meningitis is not possible in many low-resource settings. Home-based treatment, after initial in-hospital stabilisation, is feasible in selected patients and under close supervision.<sup>93</sup> The optimum treatment regimen is uncertain, and despite recommendations for 9–12 months of treatment,<sup>52,79</sup> some evidence suggests that 6 months of intensified therapy is safe and effective in HIV-uninfected children with drug-susceptible disease (table 3).<sup>81,94,95</sup>

### What challenges does drug-resistant tuberculous meningitis present?

Drug-resistant tuberculous meningitis is a serious and increasingly widespread clinical problem. The challenge is to detect drug-resistant disease quickly enough to start alternative drugs and thereby prevent death.<sup>66,68</sup> Isoniazid-resistant tuberculous meningitis has been associated with significantly longer times to CSF sterility,<sup>96</sup> but a detrimental effect on outcome was not seen so long as pyrazinamide was used throughout treatment.<sup>68</sup> However, data from the USA<sup>97</sup> and from a prospective study of HIV-infected Vietnamese adults with tuberculous meningitis<sup>66</sup> suggest that isoniazid-resistant disease has a higher mortality than drug-susceptible disease when treated with standard regimens. When isoniazid resistance is combined with rifampicin resistance (ie, multidrug resistance), death occurs in almost all patients before the results of conventional drug susceptibility tests are returned.<sup>32,66,68</sup>

Table 5 lists some potentially effective regimens for the treatment of drug-resistant tuberculous meningitis. Use of pyrazinamide throughout treatment might counter the potential adverse effect of isoniazid resistance,<sup>68</sup> as might the substitution of isoniazid with either levofloxacin or moxifloxacin (although no clinical data have been reported to support this strategy). Multidrug-resistant tuberculous meningitis requires the early use of second-line antituberculosis drugs to prevent death.<sup>68</sup> WHO guidelines recommend an injectable drug (eg, amikacin, capreomycin) with a fluoroquinolone (eg, moxifloxacin), and at least two other active drugs for the initial phase of treatment of multidrug-resistant pulmonary tuberculosis.<sup>80,98</sup> No equivalent recommendations exist for tuberculous meningitis; choice of drug should be determined by probable susceptibility and CSF penetration (table 4).<sup>84</sup>

### When, why, and how should adjunctive anti-inflammatory therapy be used?

Over the past 60 years, seven randomised controlled trials involving 1140 people with tuberculous meningitis have established that adjunctive corticosteroids reduce

	Regimens	Comments
Isoniazid resistance (with or without streptomycin resistance)	2REZFq followed by 10REZ, or 2REZ followed by 10RE	Studies <sup>68</sup> suggest that isoniazid resistance has little effect on outcome as long as pyrazinamide is used for 6 months; fluoroquinolones (either moxifloxacin or levofloxacin) might improve outcome in meningitis
Rifampicin mono-resistance	2HZEf followed by 10HZE, or 2HZEla followed by 10HZE	An injectable drug (eg, streptomycin or amikacin) or a fluoroquinolone for the first 2 months might improve outcomes in severe disease; if possible, serum concentrations of aminoglycosides (streptomycin and amikacin) should be monitored, and hearing loss should be checked for by audiology if treatment is used long term (>1 month)
Resistance to isoniazid and rifampicin (multidrug resistance)	6ZE*FqlaX followed by 18ZEf	Regimens should be tailored to individual susceptibility patterns when possible; a 6-month intensive phase with an injectable drug, a fluoroquinolone, and at least three other active drugs, followed by a continuation phase of 12–18 months with at least three active drugs (one of them a fluoroquinolone) is suggested by WHO <sup>38</sup>

Numbers in the regimen abbreviations indicate the number of months of treatment with the specified drug combination. R=rifampicin. Z=pyrazinamide. E=ethambutol. Fq=fluoroquinolone. H=isoniazid. la=injectable agent. X=another drug (eg, ethionamide, cycloserine, or linezolid). \*Use both Z and E if susceptible; replace either with other drugs (eg, ethionamide, cycloserine, linezolid,) if not susceptible to make a total of at least five active drugs in the initial phase of treatment.

**Table 5: Potential regimens for the treatment of tuberculous meningitis, by pattern of drug resistance**

death and disability from tuberculous meningitis by about 30%.<sup>99</sup> National guidelines recommend adjunctive corticosteroids for all patients with the disease (table 3).<sup>52,80</sup>

How corticosteroids reduce mortality from tuberculous meningitis is an important question, since such knowledge could help in the identification of key inflammatory pathways and suggest targeted treatments, but until recently the mechanism of action was unknown.<sup>75,100</sup> A polymorphism in *LTA4H*, which encodes the enzyme leukotriene A4 hydrolase that controls the balance of proinflammatory and anti-inflammatory eicosanoids and determines expression of tumour necrosis factor  $\alpha$  (TNF $\alpha$ ), affects tuberculosis susceptibility in both zebrafish and human beings.<sup>101</sup> Zebrafish were unable to control mycobacterial replication within granulomas if they had genetically determined high expression of *LTA4H* (TT homozygote) and an excessive inflammatory response, or low expression of *LTA4H* (CC homozygote) and an inadequate inflammatory response. Heterozygous (CT) zebrafish had an intermediate inflammatory response and were able to control the infection. Furthermore, in human beings adjunctive corticosteroids were only of benefit to major allele homozygous adults (hyperinflammatory) with tuberculous meningitis, and corticosteroid treatment of those with a hypoinflammatory phenotype was detrimental.<sup>102</sup>

These findings need to be replicated in a different population, but they lend support to the assertion that future adjunctive therapies should target eicosanoids and TNF $\alpha$  more precisely. Some clinical data suggest that thalidomide (a TNF $\alpha$  antagonist) and anti-TNF $\alpha$  antibodies might be more effective than corticosteroids in controlling adverse inflammatory complications of tuberculous meningitis. Small case series have suggested adjunctive thalidomide could be effective in the treatment of intractable tuberculomas and vision-threatening optochiasmatic arachnoiditis.<sup>103–105</sup>

Aspirin too might have a role—it inhibits the expression of proinflammatory eicosanoids and TNF $\alpha$  in zebrafish with the hyperinflammatory phenotype and thereby reduces mycobacterial burden.<sup>102</sup> Furthermore, two controlled trials showed that adjunctive aspirin

reduced the incidence of hemiplegia, stroke, and death from tuberculous meningitis.<sup>106,107</sup> These findings are too preliminary to lead to changes in treatment guidelines, but they should stimulate research into the potential role of aspirin in the treatment of tuberculous meningitis and into whether the selection of all immunomodulatory therapies for the disease should be determined by *LTA4H* genotype. New adjunctive drugs for further study include chloroquine,<sup>108</sup> interferon gamma,<sup>109</sup> alisporivir, and desipramine (alisporivir and desipramine might control inflammation by inhibiting mitochondrial reactive oxygen species).<sup>110</sup>

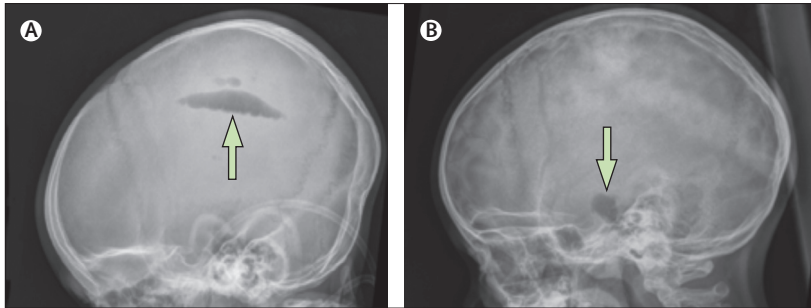
## When do complications of tuberculous meningitis require neurosurgery?

### Common complications

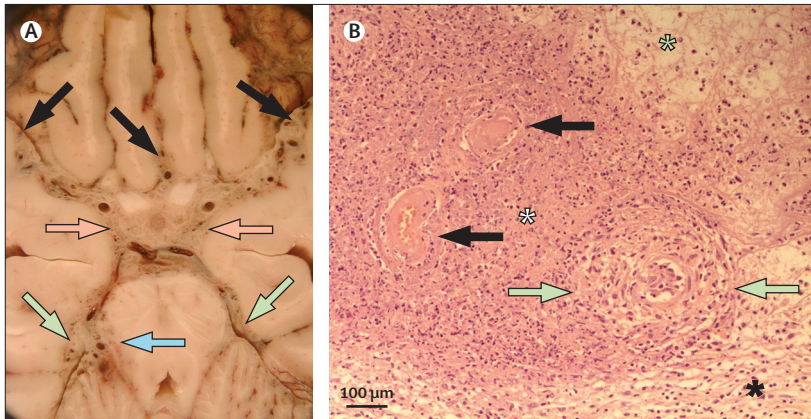
The major complications of tuberculous meningitis are hydrocephalus, stroke, and tuberculoma formation. All generally present within the first 3 months of treatment and can be fatal if not detected and treated quickly. Some require the immediate attentions of a neurosurgeon; others can be managed pharmacologically. Little evidence exists to help to define the best approach for each complication.

### Tuberculous hydrocephalus

Hydrocephalus is the most common serious complication of tuberculous meningitis. It is more common in children than adults, occurring in more than 80% of paediatric patients at presentation.<sup>111,112</sup> Hydrocephalus is rare in early tuberculous meningitis (Medical Research Council stage 1), but almost invariably present once neck stiffness and loss of consciousness have developed, and can present with any sign of acute or chronic intracranial hypertension. Often, however, hydrocephalus is not suspected clinically and the diagnosis is only evident on cranial CT. Imaging can be normal in early-onset CSF obstruction, in which case the diagnosis of developing hydrocephalus is suggested by high opening lumbar CSF pressures.<sup>113</sup> In children with tuberculous meningitis, clinical signs of raised intracranial pressure are poorly associated with hydrocephalus as shown by CT.<sup>114</sup> The



**Figure 3: Air encephalography to determine the level of the block that is causing hydrocephalus**  
(A) Air present in the lateral ventricle (arrow) on a lateral skull radiograph suggests communicating hydrocephalus in a child with tuberculous meningitis. (B) Air present in basal cisterns (arrow), but not in the ventricular system, is typical of non-communicating hydrocephalus in a child with tuberculous meningitis. The absence of air supratentorially (over the cerebral convexities) in both (A) and (B) is typical in tuberculous meningitis because of the associated basal cisterns block.



**Figure 4: Pathogenesis of tuberculous meningitis-associated stroke**  
(A) Axial section of fixed brain at the level of the suprasellar and ambient cisterns from a patient with tuberculous meningitis. In the predominantly proliferative form of tuberculous vasculitis, the inflammatory reaction entirely fills the interstices of the basal cisterns (pink arrows=suprasellar; green arrows=ambient), infiltrating the blood vessels and frequently affecting them. The reaction in the proximal parts of the sylvian and interhemispheric cisterns is attenuated (black arrows). The border-zone reaction (blue arrow) shows the composite changes of persisting inflammatory ischaemia, including congestion, vasoproliferation, astrogliosis, phagocytosis, and oedema. Nerve cells in the region are invariably affected. (B) The inflammatory reaction (haematoxylin and eosin preparation) in a micrograph of brain tissue from another patient with tuberculous meningitis. The micrograph shows the exudative (green star), necrotising (white star), and proliferative (black star) components of the inflammatory reaction in tuberculous meningitis. The blood vessels (black arrows) have undergone coagulative or gummatous necrosis, including thrombosis. The artery (green arrows) shows substantial proliferative reaction and inflammatory infiltration, including near-occlusion of the lumen, consistent with so-called Heubner's endarteritis.

association between lumbar CSF pressure and extent of hydrocephalus is also poor.<sup>113</sup>

No optimum management strategy for tuberculous hydrocephalus is universally accepted.<sup>115</sup> In our centre in Cape Town, South Africa, the treatment protocol is based on insights gained from investigating the associations between many serial lumbar CSF pressure recordings and CT findings, different treatment methods, and clinical outcomes.<sup>113,116,117</sup> Most cases (70–80%) have communicating hydrocephalus (basal cistern block); the rest have non-communicating hydrocephalus (mainly fourth-ventricular outlet obstruction). The level of CSF block is assessed by contrast ventriculography or air encephalography and not by conventional imaging

alone.<sup>118</sup> Air encephalography (5–10 mL of air injected via lumbar puncture) can be safe, effective, and inexpensive for this purpose (figure 3).<sup>119</sup>

Medical treatment (acetazolamide and furosemide) normalises intracranial pressure in 80% of children with communicating hydrocephalus within a month, and most have normal lumbar CSF pressure (<15 cm H<sub>2</sub>O) after a week of treatment.<sup>113,116</sup> Indications for ventriculoperitoneal shunting in tuberculous meningitis include failed medical treatment and non-communicating hydrocephalus.<sup>120</sup> Shunt complications are common (30% of cases), thus endoscopic third ventriculostomy has become an alternative surgical treatment option.<sup>120,121</sup> Success rates of this procedure are roughly 65%, with failure often caused by distorted anatomy of the third ventricle floor in the acute phase of the disease.<sup>122</sup>

### Tuberculous vasculitis and stroke

The poor outcome from tuberculous meningitis is mainly a manifestation of the extent of ischaemic brain damage at presentation, resulting from inflammation, necrosis, and thrombosis of blood vessels involved in the basal cisternal meningeal reaction (figure 4).<sup>111,116</sup> The distal internal carotid and proximal middle cerebral arteries, and the perforating branches of the proximal middle cerebral arteries, are preferentially involved.<sup>123</sup> Intimal proliferation leads to an obliterative vasculopathy that is particularly prominent in chronic, partly treated tuberculous meningitis (figure 4).<sup>124</sup> Despite the frequency of vasculitis and associated hypercoagulability in acute tuberculous meningitis, pathological evidence for superimposed arterial thrombosis is scarce.<sup>123,125</sup> Cerebral vasospasm might cause stroke, but this possibility has been difficult to prove. Infarcts, particularly at the basal ganglia, have been seen in children (about 40% of fatal paediatric cases) and adults (about 30% of fatal adult cases) at autopsy.<sup>122</sup>

The most common clinical manifestation of tuberculous meningitis-related stroke is hemiplegia, which is more common in young children than in adults, and in patients with advanced disease.<sup>106,107,126</sup> The course of hemiplegia varies; even severe hemiplegia can fully resolve, whereas new hemiplegia can sometimes develop during treatment.<sup>25,126,127</sup> Size, morphology, and number (but not location) of infarcts on CT are related to clinical recovery.<sup>126</sup>

No adjunctive treatment has consistently reduced the incidence of stroke or changed the course of hemiplegia in tuberculous meningitis. Corticosteroids did not significantly affect the number of new infarcts seen on CT or MRI, or the extent of residual hemiplegia in children or adults.<sup>75,128</sup> Only aspirin might reduce the incidence of stroke,<sup>106,107</sup> but this effect needs to be confirmed in larger studies.

### Tuberculomas

Cerebral tuberculomas can occur in isolation or in association with tuberculous meningitis, and their location and size determines their clinical presentation.

They are often silent and unsuspected; a focal seizure in an otherwise healthy child is the most common mode of presentation in tuberculosis-endemic populations.<sup>129</sup> Tuberculomas can also manifest with focal neurological signs or raised intracranial pressure due to obstruction of CSF pathways.

Tuberculomas can develop or enlarge despite appropriate antituberculosis treatment. This development usually occurs within 3 months of treatment and should not be ascribed to drug resistance.<sup>130</sup> Indeed, clinically silent tuberculomas are evident on MRI in about 80% of adults with tuberculous meningitis after 9 months of successful treatment.<sup>75</sup>

Intracranial tuberculous abscesses present similarly to tuberculomas, but tend to have a more accelerated clinical course and are notoriously resistant to therapy, sometimes requiring total surgical excision for cure.<sup>131</sup> In our experience, children with tuberculous abscesses respond well to treatment with adjuvant thalidomide (2–5 mg/kg daily),<sup>131</sup> although treatment might be needed for several months. Clinical improvement follows a reduction in perilesional oedema and precedes regression of lesion size on MRI. Occasionally, abscesses can enlarge despite treatment and persist for years in children who remain clinically well. Adjuvant interferon gamma has been used with success to treat two adults with intractable cerebral abscesses.<sup>109</sup>

### When is the best time to start antiretroviral therapy for HIV-associated tuberculous meningitis?

HIV-associated tuberculous meningitis is fatal in more than 60% of cases.<sup>132</sup> One of the key clinical questions is whether to start antiretroviral therapy at the same time as antituberculosis chemotherapy, or to wait until the brain infection has been controlled. Immediate antiretroviral therapy could increase the risks of drug toxicity and the development of immune reconstitution inflammatory syndrome; however, a deferred start could allow other opportunistic infections to develop and complicate management. Investigators of a controlled trial that compared immediate with deferred antiretroviral therapy in 253 Vietnamese adults with HIV-associated tuberculous meningitis reported that timing of antiretroviral therapy did not affect 9-month mortality or the time to new AIDS events or death.<sup>132</sup> However, significantly more grade 4 adverse events occurred in the group given immediate antiretroviral therapy, providing some support for the delayed option, especially in patients with CD4 cell counts higher than 100 per  $\mu\text{L}$ .

Tuberculous meningitis-associated immune reconstitution syndrome after the start of antiretroviral therapy remains a serious clinical concern.<sup>108,133</sup> The clinical predictors of its development were studied in a cohort of 34 South African patients with HIV-associated tuberculous meningitis who started antiretroviral therapy 2 weeks after the start of antituberculosis chemotherapy (given with

#### Search strategy and selection criteria

We searched PubMed using the search terms “tuberculous meningitis”, “tuberculosis”, “meningeal”, and “prevention”, “diagnosis”, and “treatment” for articles published between Jan 1, 1966, and Feb 28, 2013. We identified additional articles through searches of our own files. Only publications in English were reviewed. The final reference list was selected on the basis of originality and relevance to the broad scope of this Review.

adjunctive corticosteroids).<sup>134</sup> 16 of the 34 patients developed tuberculous meningitis-associated immune reconstitution inflammatory syndrome a median of 14 days after starting antiretroviral therapy, the most common manifestations being worsening headache and neck stiffness. Compared with the patients who did not develop tuberculous meningitis-associated immune reconstitution inflammatory syndrome, those who did had a significantly longer illness duration, more extraneural tuberculosis, and higher CSF neutrophil numbers, and a higher proportion had *M tuberculosis* cultured from CSF. The combination of high CSF TNF $\alpha$  and low interferon  $\gamma$  concentrations at diagnosis was predictive of immune reconstitution inflammatory syndrome.

Corticosteroids are the mainstay of treatment for immune reconstitution inflammatory syndrome, with interruption of antiretroviral therapy reserved for life-threatening complications.<sup>135</sup> Other immunomodulatory agents have been used, including thalidomide, chloroquine, mycophenolate mofetil, and cyclosporine.<sup>108,133</sup>

### Conclusions

Although great strides have been made in our understanding of tuberculous meningitis in the 8 years since the previous Review,<sup>1</sup> there are still many unanswered questions. Tuberculous meningitis remains the most lethal form of tuberculosis. The best way to improve survival is through early diagnosis and treatment, but this goal will remain elusive without replacement of the poor diagnostic tests currently available. New diagnostic approaches are urgently needed, especially with the evidence that intracerebral killing of bacteria might be enhanced by use of fluoroquinolones and increased doses of rifampicin. The benefits of these treatment advances will not be fully realised unless given early in the disease. The link between *LTA4H* genotype and the effect of corticosteroids on survival offers a glimpse of the future, when targeted immunomodulatory treatments could potentially be selected on the basis of a patient's genotype. These advances present new questions, which join those still unanswered, such as how to improve survival in HIV-infected patients and those with drug-resistant organisms, and how best to manage the common complications of tuberculous meningitis.

#### Contributors

The Review was written by all three authors, who contributed equally.



**Conflicts of interest**

We declare that we have no conflicts of interest.

**Acknowledgments**

We thank Richard Hewlett (University of Cape Town, Cape Town, South Africa) for the pathology slides shown in figure 4.

**References**

- Thwaites GE, Hien TT. Tuberculous meningitis: many questions, too few answers. *Lancet Neurol* 2005; **4**: 160–70.
- Jarvis JN, Meintjes G, Williams A, Brown Y, Crede T, Harrison TS. Adult meningitis in a setting of high HIV and TB prevalence: findings from 4961 suspected cases. *BMC Infect Dis* 2010; **10**: 67.
- Zhang LX, Tu DH, Enarson DA. The impact of directly-observed treatment on the epidemiology of tuberculosis in Beijing. *Int J Tuberc Lung Dis* 2000; **4**: 904–10.
- Raviglione M, Marais B, Floyd K, et al. Scaling up interventions to achieve global tuberculosis control: progress and new developments. *Lancet* 2012; **379**: 1902–13.
- WHO. Global tuberculosis control 2011. Geneva: World Health Organization, 2011.
- Abubakar I, Lipman M, Anderson C, Davies P, Zumla A. Tuberculosis in the UK—time to regain control. *BMJ* 2011; **343**: d4281.
- Wolzack NK, Cooke ML, Orth H, van Toorn R. The changing profile of pediatric meningitis at a referral centre in Cape Town, South Africa. *J Trop Pediatr* 2012; **58**: 491–95.
- Trunz BB, Fine PEM, Dye C. Effect of BCG vaccination on childhood tuberculous meningitis and miliary tuberculosis worldwide: a meta-analysis and assessment of cost-effectiveness. *Lancet* 2006; **367**: 1173–80.
- McShane H. Tuberculosis vaccines: beyond bacille Calmette–Guérin. *Philos Trans R Soc Lond B Biol Sci* 2011; **366**: 2782–89.
- National Collaborating Centre for Chronic Conditions. Tuberculosis: clinical diagnosis and management of tuberculosis, and measures for its prevention and control. London: Royal College of Physicians, 2006.
- Rich AR, McCordock HA. The pathogenesis of tuberculous meningitis. *Bull Johns Hopkins Hosp* 1933; **52**: 5–37.
- Donald PR, Schaaf HS, Schoeman JF. Tuberculous meningitis and miliary tuberculosis: the Rich focus revisited. *J Infect* 2005; **50**: 193–95.
- Krishnan N, Robertson BD, Thwaites G. The mechanisms and consequences of the extra-pulmonary dissemination of *Mycobacterium tuberculosis*. *Tuberculosis (Edinb)* 2010; **90**: 361–66.
- Hawn TR, Dunstan SJ, Thwaites GE, et al. A polymorphism in Toll-interleukin 1 receptor domain containing adaptor protein is associated with susceptibility to meningeal tuberculosis. *J Infect Dis* 2006; **194**: 1127–34.
- Thuong NT, Hawn TR, Thwaites GE, et al. A polymorphism in human TLR2 is associated with increased susceptibility to tuberculous meningitis. *Genes Immun* 2007; **8**: 422–28.
- Ralph AP, Lucas RM, Norval M. Vitamin D and solar ultraviolet radiation in the risk and treatment of tuberculosis. *Lancet Infect Dis* 2013; **13**: 77–88.
- Visser DH, Schoeman JF, van Furth AM. Seasonal variation in the incidence rate of tuberculous meningitis is associated with sunshine hours. *Epidemiol Infect* 2013; **141**: 459–62.
- Caws M, Thwaites G, Dunstan S, et al. The influence of host and bacterial genotype on the development of disseminated disease with *Mycobacterium tuberculosis*. *PLoS Pathog* 2008; **4**: e1000034.
- Krishnan N, Malaga W, Constant P, et al. *Mycobacterium tuberculosis* lineage influences innate immune response and virulence and is associated with distinct cell envelope lipid profiles. *PLoS One* 2011; **6**: e23870.
- Jain SK, Paul-Satyaseela M, Lamichhane G, Kim KS, Bishai WR. *Mycobacterium tuberculosis* invasion and traversal across an in vitro human blood-brain barrier as a pathogenic mechanism for central nervous system tuberculosis. *J Infect Dis* 2006; **193**: 1287–95.
- Jain SK, Hernandez-Abanto SM, Cheng QJ, et al. Accelerated detection of *Mycobacterium tuberculosis* genes essential for bacterial survival in guinea pigs, compared with mice. *J Infect Dis* 2007; **195**: 1634–42.
- Be NA, Lamichhane G, Grosset J, et al. Murine model to study the invasion and survival of *Mycobacterium tuberculosis* in the central nervous system. *J Infect Dis* 2008; **198**: 1520–28.
- Be NA, Bishai WR, Jain SK. Role of *Mycobacterium tuberculosis* *pknD* in the pathogenesis of central nervous system tuberculosis. *BMC Microbiol* 2012; **12**: 7.
- van Well GT, Paes BF, Terwee CB, et al. Twenty years of pediatric tuberculous meningitis: a retrospective cohort study in the western cape of South Africa. *Pediatrics* 2009; **123**: e1–8.
- Lincoln EM, Sordillo SUR, Davies PA. Tuberculous meningitis in children. *J Pediatr* 1960; **57**: 807–23.
- Smith HV, Vollum RL. The diagnosis of tuberculous meningitis. *Br Med Bull* 1954; **10**: 140–44.
- Donald PR, Schoeman JF, van Schalkwyk HJ. The ‘Road to Health’ card in tuberculous meningitis. *J Trop Pediatr* 1985; **31**: 117–20.
- Smith HV. Tuberculous meningitis. *Int J Neurol* 1964; **4**: 134–57.
- Garg RK. Tuberculosis of the central nervous system. *Postgrad Med J* 1999; **75**: 133–40.
- Thwaites G, Caws M, Chau TT, et al. The relationship between *Mycobacterium tuberculosis* genotype and the clinical phenotype of pulmonary and meningeal tuberculosis. *J Clin Microbiol* 2008; **46**: 1363–68.
- Maree F, Hesselting AC, Schaaf HS, et al. Absence of an association between *Mycobacterium tuberculosis* genotype and clinical features in children with tuberculous meningitis. *Pediatr Infect Dis J* 2007; **26**: 13–18.
- Seddon JA, Visser DH, Bartens M, et al. Impact of drug resistance on clinical outcome in children with tuberculous meningitis. *Pediatr Infect Dis J* 2012; **31**: 711–16.
- Thwaites GE, Duc Bang N, Huy Dung N, et al. The influence of HIV infection on clinical presentation, response to treatment, and outcome in adults with tuberculous meningitis. *J Infect Dis* 2005; **192**: 2134–41.
- van der Weert EM, Hartgers NM, Schaaf HS, et al. Comparison of diagnostic criteria of tuberculous meningitis in human immunodeficiency virus-infected and uninfected children. *Pediatr Infect Dis J* 2006; **25**: 65–69.
- Kumar R, Dwivedi A, Kumar P, Kohli N. Tuberculous meningitis in BCG vaccinated and unvaccinated children. *J Neurol Neurosurg Psychiatry* 2005; **76**: 1550–54.
- Wasay M, Ajmal S, Taqui AM, et al. Impact of bacille Calmette–Guérin vaccination on neuro-radiological manifestations of pediatric tuberculous meningitis. *J Child Neurol* 2010; **25**: 581–86.
- Kumar R, Singh SN, Kohli N. A diagnostic rule for tuberculous meningitis. *Arch Dis Child* 1999; **81**: 221–24.
- Youssef FG, Afifi SA, Azab AM, et al. Differentiation of tuberculous meningitis from acute bacterial meningitis using simple clinical and laboratory parameters. *Diagn Microbiol Infect Dis* 2006; **55**: 275–78.
- Thwaites GE, Chau TT, Stepniewska K, et al. Diagnosis of adult tuberculous meningitis by use of clinical and laboratory features. *Lancet* 2002; **360**: 1287–92.
- Hristea A, Olaru ID, Baicus C, Moroti R, Arama V, Ion M. Clinical prediction rule for differentiating tuberculous from viral meningitis. *Int J Tuberc Lung Dis* 2012; **16**: 793–98.
- Vibha D, Bhatia R, Prasad K, et al. Validation of diagnostic algorithm to differentiate between tuberculous meningitis and acute bacterial meningitis. *Clin Neurol Neurosurg* 2012; **114**: 639–44.
- Cohen DB, Zijlstra EE, Mukaka M, et al. Diagnosis of cryptococcal and tuberculous meningitis in a resource-limited African setting. *Trop Med Int Health* 2010; **15**: 910–17.
- Patel VB, Singh R, Connolly C, et al. Comparison of a clinical prediction rule and a LAM antigen-detection assay for the rapid diagnosis of TBM in a high HIV prevalence setting. *PLoS One* 2010; **5**: e15664.
- Sunbul M, Atilla A, Esen S, Eroglu C, Leblebicioglu H. Thwaites’ diagnostic scoring and the prediction of tuberculous meningitis. *Med Princ Pract* 2005; **14**: 151–54.
- Török ME, Nghia HD, Chau TT, et al. Validation of a diagnostic algorithm for adult tuberculous meningitis. *Am J Trop Med Hyg* 2007; **77**: 555–59.
- Checkley AM, Njalale Y, Scarborough M. Sensitivity and specificity of an index for the diagnosis of TB meningitis in patients in an urban teaching hospital in Malawi. *Trop Med Int Health* 2008; **13**: 1042–46.
- Jackson A, van der Horst C. New insights in the prevention, diagnosis, and treatment of cryptococcal meningitis. *Curr HIV/AIDS Rep* 2012; **9**: 267–77.

- 48 Stewart SM. The bacteriological diagnosis of tuberculous meningitis. *J Clin Pathol* 1953; 6: 241–42.
- 49 Thwaites GE, Chau TT, Farrar JJ. Improving the bacteriological diagnosis of tuberculous meningitis. *J Clin Microbiol* 2004; 42: 378–79.
- 50 Chen P, Shi M, Feng GD, et al. A highly efficient Ziehl-Neelsen stain: identifying de novo intracellular *Mycobacterium tuberculosis* and improving detection of extracellular *M tuberculosis* in cerebrospinal fluid. *J Clin Microbiol* 2012; 50: 1166–70.
- 51 Pai M, Flores LL, Pai N, Hubbard A, Riley LW, Colford JM. Diagnostic accuracy of nucleic acid amplification tests for tuberculous meningitis: a systematic review and meta-analysis. *Lancet Infect Dis* 2003; 3: 633–43.
- 52 Thwaites G, Fisher M, Hemingway C, Scott G, Solomon T, Innes J. British Infection Society guidelines for the diagnosis and treatment of tuberculosis of the central nervous system in adults and children. *J Infect* 2009; 59: 167–87.
- 53 Takahashi T, Nakayama T. Novel technique of quantitative nested real-time PCR assay for *Mycobacterium tuberculosis* DNA. *J Clin Microbiol* 2006; 44: 1029–39.
- 54 Takahashi T, Tamura M, Asami Y, et al. Novel “wide range” quantitative nested real-time PCR assay for *Mycobacterium tuberculosis* DNA—development and methodology. *J Clin Microbiol* 2008; 46: 1708–15.
- 55 Haldar S, Sankhyani N, Sharma N, et al. Detection of *Mycobacterium tuberculosis* GlcB or HspX antigens or devR DNA impacts the rapid diagnosis of tuberculous meningitis in children. *PLoS One* 2012; 7: e44630.
- 56 Chaidir L, Ganiem AR, Vander Zanden A, et al. Comparison of real time IS6110-PCR, microscopy, and culture for diagnosis of tuberculous meningitis in a cohort of adult patients in Indonesia. *PLoS One* 2012; 7: e52001.
- 57 Bhigjee AI, Padayachee R, Paruk H, Hallwirth-Pillay KD, Marais S, Connolly C. Diagnosis of tuberculous meningitis: clinical and laboratory parameters. *Int J Infect Dis* 2007; 11: 348–54.
- 58 Haldar S, Sharma N, Gupta VK, Tyagi JS. Efficient diagnosis of tuberculous meningitis by detection of *Mycobacterium tuberculosis* DNA in cerebrospinal fluid filtrates using PCR. *J Med Microbiol* 2009; 58: 616–24.
- 59 Lawn SD, Nicol MP. Xpert MTB/RIF assay: development, evaluation and implementation of a new rapid molecular diagnostic for tuberculosis and rifampicin resistance. *Future Microbiol* 2011; 6: 1067–82.
- 60 Chang K, Lu W, Wang J, et al. Rapid and effective diagnosis of tuberculosis and rifampicin resistance with Xpert MTB/RIF assay: a meta-analysis. *J Infect* 2012; 64: 580–88.
- 61 Alvarez-Uria G, Azcona JM, Midde M, Naik PK, Reddy S, Reddy R. Rapid diagnosis of pulmonary and extrapulmonary tuberculosis in HIV-infected patients. Comparison of LED fluorescent microscopy and the GeneXpert MTB/RIF assay in a district hospital in India. *Tuberc Res Treat* 2012; 2012: 932862.
- 62 Patel VB, Singh R, Connolly C, et al. Cerebrospinal T-cell responses aid in the diagnosis of tuberculous meningitis in a human immunodeficiency virus- and tuberculosis-endemic population. *Am J Respir Crit Care Med* 2010; 182: 569–77.
- 63 Kim SH, Cho OH, Park SJ, et al. Rapid diagnosis of tuberculous meningitis by T cell-based assays on peripheral blood and cerebrospinal fluid mononuclear cells. *Clin Infect Dis* 2010; 50: 1349–58.
- 64 Vidhate MR, Singh MK, Garg RK, et al. Diagnostic and prognostic value of *Mycobacterium tuberculosis* complex specific interferon gamma release assay in patients with tuberculous meningitis. *J Infect* 2011; 62: 400–03.
- 65 Park KH, Cho OH, Lee EM, et al. T-cell-based assays on cerebrospinal fluid and PBMCs for rapid diagnosis of TB meningitis in non-HIV patients. *Eur Respir J* 2012; 39: 768–70.
- 66 Tho DQ, Török ME, Yen NT, et al. Influence of antituberculosis drug resistance and *Mycobacterium tuberculosis* lineage on outcome in HIV-associated tuberculous meningitis. *Antimicrob Agents Chemother* 2012; 56: 3074–79.
- 67 Padayatchi N, Bamber S, Dawood H, Bobat R. Multidrug-resistant tuberculous meningitis in children in Durban, South Africa. *Pediatr Infect Dis J* 2006; 25: 147–50.
- 68 Thwaites GE, Lan NT, Dung NH, et al. Effect of antituberculosis drug resistance on response to treatment and outcome in adults with tuberculous meningitis. *J Infect Dis* 2005; 192: 79–88.
- 69 Moore DA, Evans CA, Gilman RH, et al. Microscopic-observation drug-susceptibility assay for the diagnosis of TB. *N Engl J Med* 2006; 355: 1539–50.
- 70 Caws M, Ha DT, Török E, et al. Evaluation of the MODS culture technique for the diagnosis of tuberculous meningitis. *PLoS One* 2007; 2: e1173.
- 71 Botha H, Ackerman C, Candy S, Carr JA, Griffith-Richards S, Bateman KJ. Reliability and diagnostic performance of CT imaging criteria in the diagnosis of tuberculous meningitis. *PLoS One* 2012; 7: e38982.
- 72 Andronikou S, Smith B, Hatherhill M, Douis H, Wilmshurst J. Definitive neuroradiological diagnostic features of tuberculous meningitis in children. *Pediatr Radiol* 2004; 34: 876–85.
- 73 van der Merwe DJ, Andronikou S, Van Toorn R, Pienaar M. Brainstem ischemic lesions on MRI in children with tuberculous meningitis: with diffusion weighted confirmation. *Childs Nerv Syst* 2009; 25: 949–54.
- 74 Janse van Rensburg P, Andronikou S, van Toorn R, Pienaar M. Magnetic resonance imaging of miliary tuberculosis of the central nervous system in children with tuberculous meningitis. *Pediatr Radiol* 2008; 38: 1306–13.
- 75 Thwaites GE, Macmullen-Price J, Tran TH, et al. Serial MRI to determine the effect of dexamethasone on the cerebral pathology of tuberculous meningitis: an observational study. *Lancet Neurol* 2007; 6: 230–36.
- 76 Kalita J, Prasad S, Maurya PK, Kumar S, Misra UK. MR angiography in tuberculous meningitis. *Acta Radiol* 2012; 53: 324–29.
- 77 Bernaerts A, Vanhoenacker FM, Parizel PM, et al. Tuberculosis of the central nervous system: overview of neuroradiological findings. *Eur Radiol* 2003; 13: 1876–90.
- 78 Santy K, Nan P, Chantana Y, Laurent D, Nadal D, Richner B. The diagnosis of brain tuberculoma by <sup>1</sup>H-magnetic resonance spectroscopy. *Eur J Pediatr* 2011; 170: 379–87.
- 79 WHO. Guidelines for national tuberculosis programmes on the management of tuberculosis in children. Geneva: World Health Organization, 2006.
- 80 WHO. Treatment of tuberculosis guidelines, 4th edn. Geneva: World Health Organization, 2010.
- 81 Donald PR, Schoeman JF, Van Zyl LE, De Villiers JN, Pretorius M, Springer P. Intensive short course chemotherapy in the management of tuberculous meningitis. *Int J Tuberc Lung Dis* 1998; 2: 704–11.
- 82 Donald PR. The chemotherapy of tuberculous meningitis in children and adults. *Tuberculosis (Edinb)* 2010; 90: 375–92.
- 83 Ellard GA, Humphries MJ, Allen BW. Cerebrospinal fluid drug concentrations and the treatment of tuberculous meningitis. *Am Rev Respir Dis* 1993; 148: 650–55.
- 84 Holdiness MR. Cerebrospinal fluid pharmacokinetics of the antituberculous drugs. *Clin Pharmacokinet* 1985; 10: 532–34.
- 85 Kaojarern S, Supmonchai K, Phuapradit P, Mokkavesa C, Krittiyanunt S. Effect of steroids on cerebrospinal fluid penetration of antituberculous drugs in tuberculous meningitis. *Clin Pharmacol Ther* 1991; 49: 6–12.
- 86 Donald PR, Maher D, Maritz JS, Qazi S. Ethambutol dosage for the treatment of children: literature review and recommendations. *Int J Tuberc Lung Dis* 2006; 10: 1318–30.
- 87 Donald PR, Seifart HI. Cerebrospinal fluid concentrations of ethionamide in children with tuberculous meningitis. *J Pediatr* 1989; 115: 483–86.
- 88 Thwaites GE, Bhavnani SM, Chau TT, et al. Randomized pharmacokinetic and pharmacodynamic comparison of fluoroquinolones for tuberculous meningitis. *Antimicrob Agents Chemother* 2011; 55: 3244–53.
- 89 Alffenaar JW, van Altena R, Bokkerink HJ, et al. Pharmacokinetics of moxifloxacin in cerebrospinal fluid and plasma in patients with tuberculous meningitis. *Clin Infect Dis* 2009; 49: 1080–82.
- 90 Mehlhorn AJ, Brown DA. Safety concerns with fluoroquinolones. *Ann Pharmacother* 2007; 41: 1859–66.
- 91 Ruslami R, Ganiem AR, Dian S, et al. Intensified regimen containing rifampicin and moxifloxacin for tuberculous meningitis: an open-label, randomised controlled phase 2 trial. *Lancet Infect Dis* 2013; 13: 27–35.

- 92 Heemskerck D, Day J, Chau TT, et al. Intensified treatment with high dose rifampicin and levofloxacin compared to standard treatment for adult patients with tuberculous meningitis (TBM-IT): protocol for a randomized controlled trial. *Trials* 2011; **12**: 25.
- 93 Schoeman J, Malan G, van Toorn R, Springer P, Parker F, Booysen J. Home-based treatment of childhood neurotuberculosis. *J Trop Pediatr* 2009; **55**: 149–54.
- 94 Jacobs RF, Sunakorn P, Chotpitayasunonah T, Pope S, Kelleher K. Intensive short course chemotherapy for tuberculous meningitis. *Pediatr Infect Dis J* 1992; **11**: 194–98.
- 95 Woodfield J, Argent A. Evidence behind the WHO guidelines: hospital care for children: what is the most appropriate antimicrobial treatment for tuberculous meningitis? *J Trop Pediatr* 2008; **54**: 220–24.
- 96 Thwaites GE, Caws M, Chau TT, et al. Comparison of conventional bacteriology with nucleic acid amplification (amplified mycobacterium direct test) for diagnosis of tuberculous meningitis before and after inception of antituberculosis chemotherapy. *J Clin Microbiol* 2004; **42**: 996–1002.
- 97 Vinnard C, Winston CA, Wileyto EP, Macgregor RR, Bisson GP. Isoniazid resistance and death in patients with tuberculous meningitis: retrospective cohort study. *BMJ* 2010; **341**: c4451.
- 98 WHO. Guidelines for the pragmatic management of drug-resistant tuberculosis. Geneva: World Health Organization, 2006.
- 99 Prasad K, Singh MB. Corticosteroids for managing tuberculous meningitis. *Cochrane Database Syst Rev* 2008; **1**: CD002244.
- 100 Simmons CP, Thwaites GE, Quyen NT, et al. The clinical benefit of adjunctive dexamethasone in tuberculous meningitis is not associated with measurable attenuation of peripheral or local immune responses. *J Immunol* 2005; **175**: 579–90.
- 101 Tobin DM, Vary JC Jr, Ray JP, et al. The It4h locus modulates susceptibility to mycobacterial infection in zebrafish and humans. *Cell* 2010; **140**: 717–30.
- 102 Tobin DM, Roca FJ, Oh SF, et al. Host genotype-specific therapies can optimize the inflammatory response to mycobacterial infections. *Cell* 2012; **148**: 434–46.
- 103 Schoeman JF, Andronikou S, Stefan DC, Freeman N, van Toorn R. Tuberculous meningitis-related optic neuritis: recovery of vision with thalidomide in 4 consecutive cases. *J Child Neurol* 2010; **25**: 822–28.
- 104 Schoeman JF, Ravenscroft A, Hartzenberg HB. Possible role of adjunctive thalidomide therapy in the resolution of a massive intracranial tuberculous abscess. *Childs Nerv Syst* 2001; **17**: 370–72.
- 105 Lee HS, Lee Y, Lee SO, et al. Adalimumab treatment may replace or enhance the activity of steroids in steroid-refractory tuberculous meningitis. *J Infect Chemother* 2012; **18**: 555–57.
- 106 Misra UK, Kalita J, Nair PP. Role of aspirin in tuberculous meningitis: a randomized open label placebo controlled trial. *J Neurol Sci* 2010; **293**: 12–17.
- 107 Schoeman JF, Janse van Rensburg A, Laubscher JA, Springer P. The role of aspirin in childhood tuberculous meningitis. *J Child Neurol* 2011; **26**: 956–62.
- 108 van Toorn R, Rabie H, Dramowski A, Schoeman JF. Neurological manifestations of TB-IRIS: a report of 4 children. *Eur J Paediatr Neurol* 2012; **16**: 676–82.
- 109 Lee JY, Yim JJ, Yoon BW. Adjuvant interferon- $\gamma$  treatment in two cases of refractory tuberculosis of the brain. *Clin Neurol Neurosurg* 2012; **114**: 732–34.
- 110 Roca FJ, Ramakrishnan L. TNF dually mediates resistance and susceptibility to mycobacteria via mitochondrial reactive oxygen species. *Cell* 2013; **153**: 521–34.
- 111 Schoeman JF, Van Zyl LE, Laubscher JA, Donald PR. Serial CT scanning in childhood tuberculous meningitis: prognostic features in 198 cases. *J Child Neurol* 1995; **10**: 320–29.
- 112 Yaramis A, Gurkan F, Eylevi M, et al. Central nervous system tuberculosis in children: a review of 214 cases. *Pediatrics* 1998; **102**: E49.
- 113 Schoeman JF, Laubscher JA, Donald PR. Serial lumbar CSF pressure measurements and cranial computed tomographic findings in childhood tuberculous meningitis. *Childs Nerv Syst* 2000; **16**: 203–08.
- 114 Schoeman JF, le Roux D, Bezuidenhout PB, Donald PR. Intracranial pressure monitoring in tuberculous meningitis: clinical and computerized tomographic correlation. *Dev Med Child Neurol* 1985; **27**: 644–54.
- 115 Figaji AA, Fieggen AG. The neurosurgical and acute care management of tuberculous meningitis: evidence and current practice. *Tuberculosis (Edinb)* 2010; **90**: 393–400.
- 116 Schoeman J, Donald P, van Zyl L, Keet M, Wait J. Tuberculous hydrocephalus: comparison of different treatments with regard to ICP, ventricular size and clinical outcome. *Dev Med Child Neurol* 1991; **33**: 396–405.
- 117 Bruwer GE, Van der Westhuizen S, Lombard CJ, Schoeman JF. Can CT predict the level of CSF block in tuberculous hydrocephalus? *Childs Nerv Syst* 2004; **20**: 183–87.
- 118 Lamprecht D, Schoeman J, Donald P, Hartzenberg H. Ventriculoperitoneal shunting in childhood tuberculous meningitis. *Br J Neurosurg* 2001; **15**: 119–25.
- 119 Sifontes JE, Sordillo SV, Lincoln EM. Pneumoencephalography in tuberculous meningitis. *J Pediatr* 1957; **50**: 695–707.
- 120 Bhagwati S, Mehta N, Shah S. Use of endoscopic third ventriculostomy in hydrocephalus of tubercular origin. *Childs Nerv Syst* 2010; **26**: 1675–82.
- 121 Figaji AA, Fieggen AG, Peter JC. Endoscopy for tuberculous hydrocephalus. *Childs Nerv Syst* 2007; **23**: 79–84.
- 122 Misra UK, Kalita J, Prabhakar S, Chakravarty A, Kochar D, Nair PP. Endoscopic third ventriculostomy in tuberculous meningitis needs more evidence. *Ann Indian Acad Neurol* 2012; **15**: 233.
- 123 Dastur DK, Lalitha VS, Udani PM, Parekh U. The brain and meninges in tuberculous meningitis—gross pathology in 100 cases and pathogenesis. *Neurol India* 1970; **18**: 86–100.
- 124 Lammie GA, Hewlett RH, Schoeman JF, Donald PR. Tuberculous cerebrovascular disease: a review. *J Infect* 2009; **59**: 156–66.
- 125 Schoeman J, Mansvelt E, Springer P, van Rensburg AJ, Carlini S, Fourie E. Coagulant and fibrinolytic status in tuberculous meningitis. *Pediatr Infect Dis J* 2007; **26**: 428–31.
- 126 Springer P, Swanevelder S, van Toorn R, van Rensburg AJ, Schoeman J. Cerebral infarction and neurodevelopmental outcome in childhood tuberculous meningitis. *Eur J Paediatr Neurol* 2009; **13**: 343–49.
- 127 Sheu JJ, Hsu CY, Yuan RY, Yang CC. Clinical characteristics and treatment delay of cerebral infarction in tuberculous meningitis. *Intern Med J* 2012; **42**: 294–300.
- 128 Schoeman JF, Van Zyl LE, Laubscher JA, Donald PR. Effect of corticosteroids on intracranial pressure, computed tomographic findings, and clinical outcome in young children with tuberculous meningitis. *Pediatrics* 1997; **99**: 226–31.
- 129 Ravenscroft A, Schoeman JF, Donald PR. Tuberculous granulomas in childhood tuberculous meningitis: radiological features and course. *J Trop Pediatr* 2001; **47**: 5–12.
- 130 Afghani B, Lieberman JM. Paradoxical enlargement or development of intracranial tuberculomas during therapy: case report and review. *Clin Infect Dis* 1994; **19**: 1092–99.
- 131 Schoeman JF, Fieggen G, Sella N, Mendelson M, Hartzenberg B. Intractable intracranial tuberculous infection responsive to thalidomide: report of four cases. *J Child Neurol* 2006; **21**: 301–08.
- 132 Török ME, Yen NT, Chau TT, et al. Timing of initiation of antiretroviral therapy in human immunodeficiency virus (HIV)-associated tuberculous meningitis. *Clin Infect Dis* 2011; **52**: 1374–83.
- 133 Pepper DJ, Marais S, Maartens G, et al. Neurologic manifestations of paradoxical tuberculosis-associated immune reconstitution inflammatory syndrome: a case series. *Clin Infect Dis* 2009; **48**: e96–107.
- 134 Marais S, Meintjes G, Pepper DJ, et al. Frequency, severity, and prediction of tuberculous meningitis immune reconstitution inflammatory syndrome. *Clin Infect Dis* 2013; **56**: 450–60.
- 135 Meintjes G, Scriven J, Marais S. Management of the immune reconstitution inflammatory syndrome. *Curr HIV/AIDS Rep* 2012; **9**: 238–50.

## **Chapter 3**

### **Update on the diagnosis and management of tuberculous meningitis in children residing in resource-limited countries**



# Update on the Diagnosis and Management of Tuberculous Meningitis in Children

Ronald van Toorn, FCP and Regan Solomons, MMED

Tuberculous meningitis (TBM), the most devastating manifestation of tuberculosis, is often missed or overlooked because of nonspecific symptoms and difficulties in diagnosis. It continues to be an important cause of neurologic handicap in resource-poor countries. Owing to the suboptimal performance of diagnostic tests of TBM, diagnosis relies on thorough history, clinical examination, and relevant investigations. The development of affordable, accurate diagnostic tests for TBM in resource-poor settings remains a priority. Short intensified treatment is safe and effective in both human immunodeficiency virus (HIV)-infected and HIV-uninfected children. Treatment of tuberculous hydrocephalus depends on the level of the cerebrospinal fluid obstruction. Corticosteroids reduce risk of neurodisability and death in HIV-uninfected children. Thalidomide should be considered in children compromised by tuberculosis abscesses and tuberculous-related optochiasmatic arachnoiditis. In resource-poor countries, home-based TBM treatment after initial in-hospital stabilization is feasible in carefully selected patients. Early diagnosis and treatment of TBM is the single most important factor determining outcome. *Semin Pediatr Neurol* 21:12-18 © 2014 Elsevier Inc. All rights reserved.

## Introduction

Tuberculous meningitis (TBM) is the most devastating manifestation of tuberculosis (TB) and it continues to be an important cause of neurologic handicap in resource-poor countries.

A recent study in the Western Cape Province of South Africa (SA) found TBM to be the commonest cause of pediatric meningitis.<sup>1</sup> SA is one of the 22 high-TB burden countries that account for 80% of all TB cases. The estimated incidence of TB in SA is 1000 or more per 100,000 people. One of the Millennium Development Goals targets is to halt and start to reverse the rising incidence of TB and halve the 1990 prevalence and death rates by 2015.<sup>2</sup> Unfortunately, most African regions, including SA, are not on track to achieve this objective owing to reasons such as resource constraints, conflict and instability, and generalized human immunodeficiency virus (HIV) epidemics.

The bacille Calmette-Guerin (BCG) vaccine is currently the only available vaccine against TB and is widely administered within the Expanded Programme for Immunization by the World Health Organization (WHO). It provides protection

against disseminated TB and TBM (73%; 95% confidence limits 67%-79%) but has highly variable and often low efficacy against pulmonary TB in adults.<sup>3</sup> The effect of BCG vaccination on transmission of *Mycobacterium tuberculosis* (*M.tb*) is therefore limited. The variable efficacy of BCG vaccination together with the not inconsequential threat of multidrug-resistant (MDR) TB highlights the necessity of new vaccine development, but this is hindered by the lack of immune correlates, suboptimal animal models, and limited funding.<sup>4</sup>

## Clinical Manifestations

TBM may present at any age but is less common at the extremes of life. The peak incidence is in children between 2 and 4 years of age.<sup>5</sup> Early clinical diagnosis is notoriously difficult and often delayed, with disastrous consequences. Although delayed diagnosis of TBM is common, very young infants, patients with another coexisting illness, and those from non-TB-endemic regions carry the highest risk for missed diagnosis. The classic presentation of TBM is as a subacute meningitic illness. The resulting dilemma is that the classic sign of meningitis, neck stiffness, is usually absent during the early disease stage in children and adults.<sup>6</sup> Early diagnosis and treatment of TBM has been long recognized as the single most important factor determining outcome.<sup>5</sup>

Although much effort has gone into improving diagnostic investigations, these may not be requested if the possibility

Department of Paediatrics and Child Health, Stellenbosch University, Western Cape, South Africa.

Both authors contributed equally.

Address reprint requests to Ronald van Toorn, FCP, Department of Paediatrics and Child Health, Stellenbosch University, PO Box 19063, Tygerberg 7505, Western Cape, South Africa. E-mail: [vtoorn@sun.ac.za](mailto:vtoorn@sun.ac.za)



of meningitis has not crossed the physician's mind. This is applicable to health practitioners in resource-poor as well as resource-equipped countries where the increase in migrant populations could potentially lead to an increased incidence of TBM. It is therefore important to recognize TBM during the early stage, mainly characterized by nonspecific symptoms of general ill health rather than specific, classic signs of meningitis. In young children, these include poor weight gain, low-grade fever, and listlessness. Most early symptoms relate to underlying pulmonary TB present in most infants who develop TBM as a complication of primary infection. The only factor differentiating these symptoms of TBM from common illnesses such as influenza is their persistence<sup>7</sup>; however, this is often not recognized because caregivers may not return to the same health professional (especially if the treatment failed) and often do not inform subsequent doctors of previous diagnoses and treatments of the current illness.<sup>7</sup> Thus early-stage, fully curable TBM may progress to the final stages of coma, opisthotonus, and death following this course of events.

In older children, common nonspecific symptoms of early TBM are fever, headache, and vomiting, closely representing a flu-like illness. Recent close contact with an infectious pulmonary TB patient is an important diagnostic clue. Once the classic neurologic signs of advanced TBM (including meningeal irritation, coma, seizures, signs of raised intracranial pressure [ICP], cranial nerve palsies, hemiparesis, and movement disorders) appear, the diagnosis is usually apparent but at a considerable cost to the patient. However, it should be noted that the initial presentation of TBM may be severe and accompanied by any of the aforementioned "late" signs and without a distinct prodromal period. Organism genotype, resistance patterns (MDR TB), coinfection with HIV, or BCG immunization status do not consistently modify the disease presentation as described earlier.<sup>6</sup>

## Complications of TBM

### Tuberculous Hydrocephalus and Raised Intracranial Pressure

Hydrocephalus occurs in up to 80% of patients with TBM.<sup>5</sup> In 70% of cases, the hydrocephalus is of a communicating nature. This occurs when the exudate that fills the basal cisterns causes a bottleneck obstruction of the cerebrospinal fluid (CSF) pathways at the level of the tentorium. In 20% of cases, CSF obstruction occurs when the basal exudates obstruct the outflow foramina of the fourth ventricle leading to a non-communicating hydrocephalus. Other rare causes of non-communicating hydrocephalus are obstruction of the foramen of Monro or the aqueduct by strategically located tuberculomas.

Tuberculous hydrocephalus is often complicated by raised ICP.<sup>5</sup> Studies have shown that clinical diagnosis of the presence and degree of raised ICP is unreliable, especially in children with closed anterior fontanels.<sup>8</sup> The value of computed tomography (CT) is limited by the poor correlation that exists between the degree of hydrocephalus (ventricular size) and severity of ICP.<sup>9</sup> Signs of raised ICP may also mimic signs of brainstem dysfunction.<sup>10</sup> It is therefore often difficult to

distinguish between raised ICP and brainstem ischemia in a deeply comatose child with stage III TBM.

### Tuberculous Cerebrovascular Disease

Stroke is a common, most devastating complication of TBM. Vessel pathology appears to be a consequence of its immersion in the local inflammatory exudate.<sup>11</sup> The terminal segments of internal carotid artery and proximal portions of the middle and anterior cerebral arteries are most frequently involved. Anti-tuberculous chemotherapy is relatively ineffective in preventing the vascular complications, suggesting an immune mechanism. This has led to clinical intervention studies aimed at halting the progressive nature of the vasculitis.<sup>12</sup>

### Tuberculosis–Immune Reconstitution Inflammatory Syndrome

TB-immune reconstitution inflammatory syndrome (IRIS) of the central nervous system often manifests as a life-threatening condition and should be considered when new neurologic symptoms or signs develop shortly after initiation of antiretroviral therapy (ART) in children.<sup>13</sup> Two clinical scenarios may occur: "unmasking" IRIS, when subclinical, previously unrecognized TB infection flares up after starting ART, and "paradoxical" IRIS, diagnosed when new or worsening symptoms of TB develop despite adherence to appropriate anti-tuberculous treatment in a patient in whom combination ART was initiated.<sup>13</sup> The neurologic manifestations described include neck stiffness, intracranial and spinal tuberculous mass lesions, radiculomyelitis, hydrocephalus, visual compromise, and seizures.<sup>13</sup> Paradoxical TBM-IRIS tends to occur within 3 weeks of initiation of ART in children.<sup>13</sup>

The frequency and mortality of neurologic TB-IRIS in children is not well documented; only 1 case series has been published.<sup>14</sup> In adults, TBM-IRIS complicates the course of treatment of HIV-associated TBM in 47% of cases, despite the use of adjunctive corticosteroid therapy.<sup>15</sup> Mortality is high (up to 30%) in those affected.<sup>14</sup>

As yet, no means exist to predict the syndrome. The optimal time to initiate ART in children or adults with HIV-associated TBM is unknown. A recent randomized, double-blind, placebo-controlled trial of immediate vs deferred ART in adult Vietnamese patients with TBM showed that HIV-associated TBM in the study population had such a poor prognosis that the timing of ART made no appreciable difference regarding survival probability.<sup>16</sup> Early initiation of ART was not associated with an increased risk of IRIS. Corticosteroids are the mainstay of treatment for TBM-IRIS, with interruption of ART reserved for life-threatening complications. Other immunomodulatory agents that have been used to treat IRIS in a limited number of patients include thalidomide, chloroquine, mycophenolate mofetil, and cyclosporine.<sup>13</sup>

### TB Mass Lesions

Tuberculomas of the central nervous system may occur in isolation or in association with TBM. Intracranial tuberculomas

are often silent and unsuspected, especially if no clinical evidence of TB is present. A focal seizure in an otherwise normal child is the most common mode of presentation in TB endemic populations. Tuberculomas may also manifest with focal neurologic signs or raised ICP due to obstruction of cerebrospinal pathways. The diagnosis is dependent on neuroimaging as the evaluation of CSF and cultures had unremarkable findings in most patients. Most tuberculomas resolve uneventfully in response to antituberculous treatment. Corticosteroids (prednisone 2 mg/kg/d) should be reserved for cases with paradoxically enlarging tuberculomas.

TB mass lesions (large tuberculomas or abscesses) are known to develop or enlarge despite appropriate anti-TB treatment. This phenomenon, the result of IRIS, is often more severe in the setting of HIV coinfection and may be life threatening.<sup>13</sup> The clinical manifestations depend on the size and location of the lesion(s) and include focal neurologic signs, ataxia, spastic paraplegia, and raised ICP due to obstruction of CSF pathways. In our experience, TB abscesses are responsive to thalidomide, a potent tumor necrosis factor alpha (TNF- $\alpha$ ) inhibitor.<sup>12</sup>

## Diagnosis

Owing to the suboptimal performance of diagnostic tests of TBM, the diagnosis in children relies on a thorough assessment of all the evidence derived from a careful evaluation of medical history, clinical examination, and relevant investigations. Approximately 60% of children with TBM have radiological evidence of pulmonary TB.<sup>5</sup>

There have been efforts to create clinical prediction rules to differentiate TBM from other forms of meningitis, especially in resource-poor settings. When comparing TBM and bacterial meningitis in adults using a composite clinical reference standard, sensitivities of 86%-97% and specificities of 71%-97% were obtained.<sup>17,18</sup> When using a microbiologically proven *M.tb* reference standard, sensitivities (86%-96%) and specificities (71%-79%) were similar.<sup>17,19</sup> However, a prediction rule performed less well in an area of high HIV seroprevalence (sensitivity 78% and specificity 43%).<sup>20</sup>

As the CSF in both TBM and viral meningitis is clear and lymphocyte predominant, distinguishing between them is more difficult. A recent prediction rule, consisting of a diagnostic scoring system, performed well with sensitivity of 92% and specificity of 94%.<sup>21</sup>

Despite numerous reports in the literature describing clinical prediction rules, standardized diagnostic criteria are lacking.<sup>22</sup>

The tuberculin skin test showed a sensitivity of 61% in a large retrospective cohort of children with TBM.<sup>5</sup> However, sensitivity decreases (34%) when HIV coinfection is present because of the high rate of false-negative results.<sup>23</sup> In a population of young BCG vaccinated infants (<6 months), specificity was found to be decreased owing to high false positivity. Furthermore, a positive tuberculin skin test implies exposure to TB, but it cannot delineate active TB disease.<sup>24</sup>

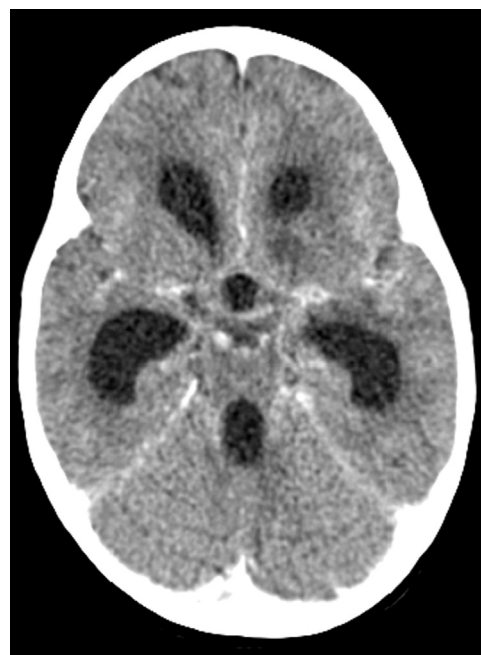
Although a meta-analysis of the use of interferon gamma release assays (IGRAs) in adults with pulmonary TB performed

in 2011 showed that there is no value for the diagnosis of active TB,<sup>25</sup> CSF IGRA showed sensitivities of 59%-84% and specificities of 73%-89%.<sup>26-29</sup> However, the large volume of CSF needed to obtain enough cells to perform IGRA<sup>30</sup> is a limiting factor in children where much smaller CSF volumes are obtained.

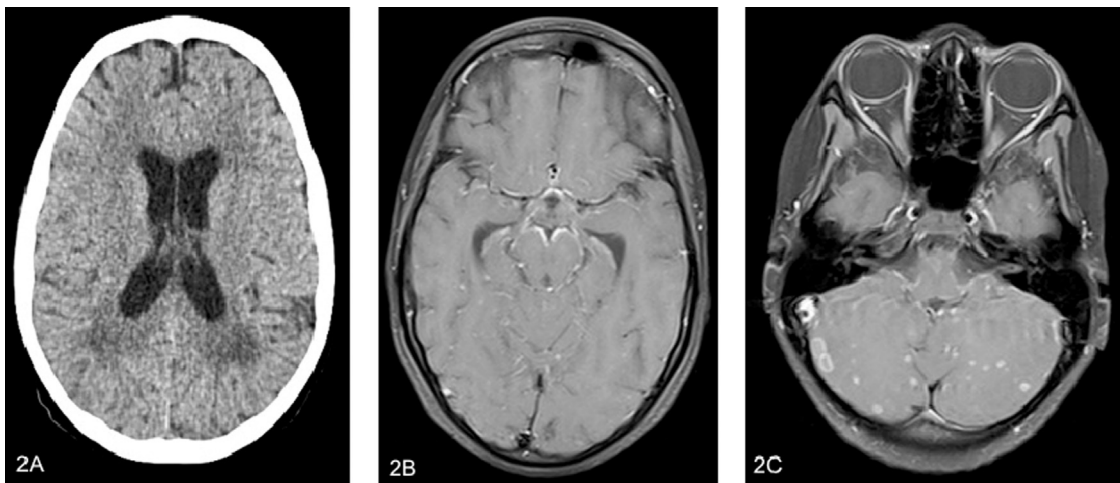
A systematic review conducted in 2003 evaluated the test accuracy of nucleic acid amplification tests (NAATs) in the diagnosis of TBM.<sup>31</sup> The studies with commercial NAATs revealed a pooled sensitivity and specificity of 56% and 99%, respectively. The review concluded that commercial NAATs provided valuable information when positive; however, owing to poor sensitivity, a negative result did not exclude TBM.<sup>31</sup> The WHO has recently endorsed the Xpert MTB/RIF assay (Xpert; Cepheid, Sunnyvale, CA) for both smear microscopy-positive and -negative sputum specimens.<sup>32</sup> When using Xpert for CSF specimens, promising sensitivities of 59%-84% and specificities 73%-89% were obtained.<sup>33,34</sup>

Neuroimaging plays an important role in the diagnosis of TBM, especially during the early stage of the disease and in cases of diagnostic uncertainty. CT is most often used in resource-poor countries and a combination of hyperdense exudates on precontrast CT, basal meningeal enhancement, infarctions, and hydrocephalus is highly suggestive (Fig. 1).<sup>35</sup> Bilateral basal ganglia infarcts are particularly characteristic of TBM, and this finding on CT suggest a high likelihood of brainstem involvement. Approximately one-third of children with stage 1 TBM disease have normal findings on a CT scan.<sup>6</sup>

In case of TBM, magnetic resonance imaging (MRI) is superior to CT for diagnosis, by detecting basal enhancement and granulomas in more patients, and for prognosis, by detecting many more infarcts in strategic locations such as the brainstem (Fig. 2).<sup>36</sup> Gadolinium-enhanced MRI allows



**Figure 1** Contrasted computed tomography image showing a combination of hydrocephalus, basal meningeal enhancement, and infarction.



**Figure 2** (A) Computed tomography scan of a 13-year-old child presenting with disseminated TB and loss of consciousness. The initial CT image only revealed bilateral periventricular hypodensities and hydrocephalus. (B and C) T1-weighted postgadolinium MR image obtained 2 days later revealed basal meningeal enhancement and multiple ring enhancing lesions (miliary nodules) in the cerebellar hemispheres. MR, magnetic resonance.

detection of miliary leptomeningeal tubercles, which have been reported to be present in 88% of children with TBM.<sup>37</sup> MRI is also valuable for identification of optochiasmatic arachnoiditis, which requires urgent intervention to reduce the risk of blindness.<sup>38</sup> Magnetic resonance angiography is useful for the assessment of vascular involvement. The vessels most commonly affected include the terminal portions of the internal carotid arteries as well as the proximal parts of the middle and anterior cerebral arteries.

## Treatment

### Fluid Management

Hyponatremia occurs in up to 85% of children with TBM and is thought to be secondary to either syndrome of inappropriate antidiuretic hormone or cerebral salt wasting.

Fluid restriction has traditionally been recommended to counter the presumed threat of syndrome of inappropriate antidiuretic hormone and reduce the risk of cerebral edema. However, there is no evidence that indicates that fluid restriction is beneficial in children with meningitis. It may precipitate hypovolemia, which should be avoided at all costs as maintenance of adequate cerebral perfusion is of critical importance in patients with TBM. TBM is known to induce a hypercoagulable state, which would then increase the risk of venous thrombosis and infarction in the setting of inadequate cerebral perfusion.<sup>39</sup> A safer option is to partially correct symptomatic hyponatremia (associated with seizures) by slow infusion of 5% hypertonic saline.

### Antimicrobial Therapy

There is limited evidence regarding the most appropriate treatment regimen for TBM or optimal duration of treatment.<sup>40</sup> The WHO recommends a 12-month treatment plan (2RHZE/10RH) for children with suspected or confirmed TBM. Short,

intensified anti-TBM therapy is advocated by several groups as similar completion and relapse rates have been reported when a 6-month therapy was compared with a 1-year therapy.<sup>41</sup> High-dose intravenous rifampicin may also be associated with a survival benefit in adult patients with severe disease.

Local experience is that short, intensified therapy (6RHZEth for HIV-uninfected and 9RHZEth for HIV-infected children) is safe and effective in children with drug-susceptible TBM.<sup>41</sup> This regimen was prospectively evaluated in 184 consecutive children with TBM and resulted in a good outcome in 80% of cases and mortality of 3.8%.<sup>41</sup> The incidence of antituberculous drug-induced hepatotoxicity in the study was low (5%), and in all cases, the original regimen was restarted without recurrence.<sup>41</sup> The rationale for using ethionamide as the fourth drug is that it has good CSF penetration and less adverse effects compared with those of streptomycin and ethambutol. Another advantage is that isoniazid monoresistant TBM may be overcome when ethionamide and pyrazinamide are used continuously for a 6-month period.<sup>42</sup>

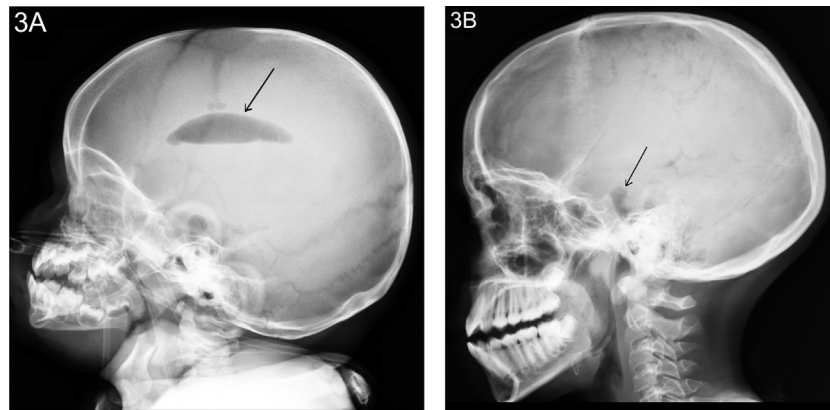
In resource-poor countries, lengthy in-hospital treatment of TBM is often not a realistic option. Local experience is that home-based TBM treatment after initial in-hospital stabilization is feasible in carefully selected patients under close supervision.<sup>43</sup>

MDR TBM should be considered in cases where there is deterioration despite compliance with adequate antituberculous treatment. In such cases, it is vitally important to obtain cultures from source contacts. Newer NAATs allows detection of resistance against rifampicin and isoniazid. Second-line agents for MDR TBM include levofloxacin, amikacin, terizadone, and para-aminosalicylic acid.

### Treatment of Tuberculous Hydrocephalus

Treatment of tuberculous hydrocephalus depends on the level of CSF obstruction. Air encephalography is the most reliable way of determining the level of CSF obstruction (Fig. 3).<sup>44</sup> CT





**Figure 3** (3A) The lateral skull X-ray shows air in the basal cistern and lateral ventricles. This indicates communicating hydrocephalus (arrow) due to basal cistern obstruction to the flow of cerebrospinal fluid. (3B) The lateral skull X-ray shows only air at the level of the basal cistern (arrow). This indicates non-communicating hydrocephalus due to obstruction of the 4th ventricle outlet foramen.

is not a useful tool as panventricular dilatation occurs in both communicating and noncommunicating types of hydrocephalus.<sup>44</sup> Communicating hydrocephalus can be treated with medical therapy consisting of 50 mg/kg/d of acetazolamide and 1 mg/kg/d of furosemide in 3 divided doses) for a period of 4 weeks.<sup>9</sup> This drug combination reduces CSF production by blocking carbonic anhydrase activity and reduces ICP by decreasing the rate of CSF production. It is our experience that normalization of ICP occurs within days in more than 90% of children. Figure 4 illustrates our suggested treatment algorithm for children with tuberculous hydrocephalus.

## Adjunctive Anti-inflammatory Therapy

### Corticosteroids

A Cochrane systematic review of 7 clinical trials involving 1140 participants conducted in 2008 found that corticosteroids reduce the risk of death (relative risk = 0.78, 95% CI: 0.67-0.91) or disabling neurologic deficit (relative risk = 0.82, 95% CI: 0.70-0.97) in HIV-uninfected TBM patients.<sup>45</sup> The benefit of corticosteroids in HIV-infected patients has not been demonstrated. There are also no controlled trials comparing corticosteroid regimens. Local preference is to prescribe a dose of 2 mg/kg/d of prednisone (maximum 60 mg/d) for the first month of treatment and then to gradually wean over the next 2 weeks.

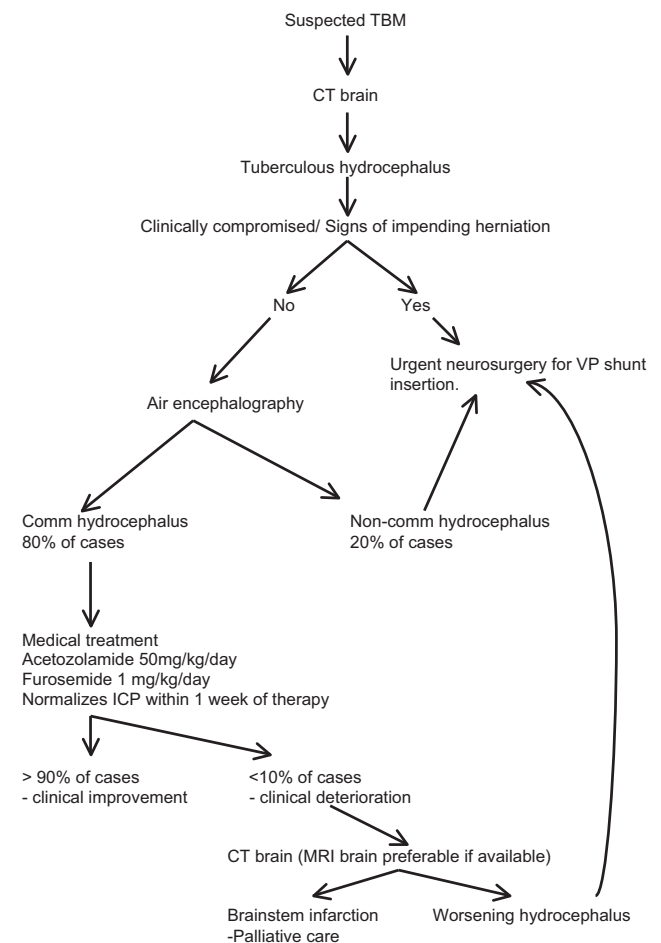
### Aspirin

The value of aspirin's antithrombotic, anti-ischemic, and anti-inflammatory properties in TBM was explored in 2 studies. A TBM study in adults reported a significant reduction in mortality at 3 months ( $P = 0.02$ ).<sup>46</sup> In contrast, a TBM study on children found no significant benefit in morbidity (hemiparesis and developmental outcome) or mortality at 6 months.<sup>39</sup>

### Thalidomide

TB abscesses are notoriously resistant to therapy and require total surgical excision for cure.<sup>47</sup> Surgical excision is often not achievable because of the proximity of the abscesses to vital

brain structures and the lack of neurosurgical care in resource-poor countries. TB abscesses often teem with tubercle bacilli, which induce a strong cytokine response. The most important cytokine implicated is TNF- $\alpha$ . Insufficient TNF- $\alpha$  production delays granuloma formation, which is required for control of



**Figure 4** Tygerberg Children's Hospital treatment algorithm for tuberculous hydrocephalus. Comm = communicating, Non-comm = non-communicating, VPS = ventriculo-peritoneal shunt, ICP = intracranial pressure

bacillary growth whereas excessive production leads to extensive liquefaction necrosis as is evident in TB abscesses. Thalidomide, 3-5 mg/kg/d, given orally, is our drug of choice in children who develop life-threatening TB mass lesions (IRIS) despite the use of corticosteroids.<sup>12</sup> The use of thalidomide should also be considered in children with visual compromise due to tuberculous optochiasmatic arachnoiditis.<sup>38</sup>

## Outcome in Childhood TBM

Prognosis in TBM largely depends on the stage the disease has reached at the time of treatment intervention. Children with stage I TBM disease are likely to have a normal outcome, whereas children with stage III disease have a high risk of mortality.<sup>41</sup> MDR TBM in children has a poor clinical outcome and is often associated with death.<sup>42</sup> Inpatient mortality rates are generally similar between HIV-infected and HIV-uninfected children with TBM.<sup>41</sup> However, mortality after hospital discharge is substantially worse in HIV-infected children with TBM because of HIV-related illnesses. Long-term behavioral complications of TBM survivors include general behavioral disinhibitions and internalized emotional disorders.<sup>48</sup>

## References

- Wolzak NK, Cooke ML, Orth H, et al: The changing profile of pediatric meningitis at a referral centre in Cape Town, South Africa. *J Trop Pediatr* 58:491-495, 2012
- World Health Organization: Global tuberculosis report. Geneva, Switzerland, 2013
- Rieder HL: Contacts of tuberculosis patients in high-incidence countries. *Int J Tuberc Lung Dis* 7:S333-S336, 2003
- Hokey DA, Ginsberg A: The current state of tuberculosis vaccines. *Hum Vaccin Immunother* 9:2142-2146, 2013
- van Well GT, Paes BF, Terwee CB, et al: Twenty years of pediatric tuberculous meningitis: A retrospective cohort study in the western cape of South Africa. *Pediatrics* 123:e1-e8, 2009
- Thwaites GE, van Toorn R, Schoeman JF: Tuberculous meningitis: More questions, still too few answers. *Lancet Neurol* 12:999-1010, 2013
- Smith HV: Tuberculous meningitis. *Int J Neurol* 4:134-157, 1964
- Schoeman JF, le Roux D, Bezuidenhout PB, et al: Intracranial pressure monitoring in tuberculous meningitis: Clinical and computerized tomographic correlation. *Dev Med Child Neurol* 27:644-654, 1985
- Schoeman JF, Van Zyl LE, Laubscher JA, et al: Serial CT scanning in childhood tuberculous meningitis: Prognostic features in 198 cases. *J Child Neurol* 10:320-329, 1995
- van Toorn R, Springer P, Laubscher JA, et al: Value of different staging systems for predicting neurological outcome in childhood tuberculous meningitis. *Int J Tuberc Lung Dis* 16:628-632, 2012
- Lammie GA, Hewlett RH, Schoeman JF, et al: Tuberculous cerebrovascular disease: A review. *J Infect* 59:156-166, 2009
- Schoeman JF, Fieggen G, Seller N, et al: Intractable intracranial tuberculous infection responsive to thalidomide: Report of four cases. *J Child Neurol* 21:301-308, 2006
- van Toorn R, Rabie H, Dramowski A, et al: Neurological manifestations of TB-IRIS: A report of 4 children. *Eur J Paediatr Neurol* 16:676-682, 2012
- Pepper DJ, Marais S, Maartens G, et al: Neurologic manifestations of paradoxical tuberculosis-associated immune reconstitution inflammatory syndrome: A case series. *Clin Infect Dis* 48:e96-e107, 2009
- Marais S, Meintjes G, Pepper DJ, et al: Frequency, severity, and prediction of tuberculous meningitis immune reconstitution inflammatory syndrome. *Clin Infect Dis* 56:450-460, 2013
- Thwaites GE, Nguyen DB, Nguyen HD, et al: Dexamethasone for the treatment of tuberculous meningitis in adolescents and adults. *N Engl J Med* 351:1741-1751, 2004
- Sunbul M, Atilla A, Esen S, et al: Thwaites' diagnostic scoring and the prediction of tuberculous meningitis. *Med Princ Pract* 14:151-154, 2005
- Thwaites G, Chau T, Stepniewska K, et al: Diagnosis of adult tuberculous meningitis by use of clinical and laboratory features. *Lancet* 360:1287-1292, 2002
- Youssef F, Afifi S, Azab A, et al: Differentiation of tuberculous meningitis from acute bacterial meningitis using simple clinical and laboratory parameters. *Diagn Microbiol Infect Dis* 55:275-278, 2006
- Checkley AM, Njalale Y, Scarborough M, et al: Sensitivity and specificity of an index for the diagnosis of TB meningitis in patients in an urban teaching hospital in Malawi. *Trop Med Int Health* 13:1042-1046, 2008
- Hristea A, Olaru ID, Baicus C, et al: Clinical prediction rule for differentiating tuberculous from viral meningitis. *Int J Tuberc Lung Dis* 16:793-798, 2012
- Marais S, Thwaites G, Schoeman J, et al: Tuberculous meningitis: A uniform case definition for use in clinical research. *Lancet Infect Dis* 10:803-812, 2010
- Mandalakas AM, van Wyk S, Kirchner HL, et al: Detecting tuberculosis infection in HIV-infected children: A study of diagnostic accuracy, confounding and interaction. *Pediatr Infect Dis J* 32:e111-e118, 2013
- McConkey SJ, Youssef FG, Azem E, et al: Evaluation of a rapid-format antibody test and the tuberculin skin test for diagnosis of tuberculosis in two contrasting endemic settings. *Int J Tuberc Lung Dis* 6:246-252, 2002
- Metcalfe JZ, Everett CK, Steingart KR, et al: Interferon-gamma release assays for active pulmonary tuberculosis diagnosis in adults in low- and middle income countries: Systematic review and meta-analysis. *J Infect Dis* 204:S1120-S1129, 2011
- Kim SH, Cho OH, Park SJ, et al: Rapid diagnosis of tuberculous meningitis by T cell-based assays on peripheral blood and cerebrospinal fluid mononuclear cells. *Clin Infect Dis* 50:1349-1358, 2010
- Patel VB, Singh R, Connolly C, et al: Cerebrospinal T-cell responses aid in the diagnosis of tuberculous meningitis in a human immunodeficiency virus- and tuberculosis-endemic population. *Am J Respir Crit Care Med* 182:569-577, 2010
- Vidhate MR, Singh MK, Garg RK, et al: Diagnostic and prognostic value of *Mycobacterium tuberculosis* complex specific interferon gamma release assay in patients with tuberculous meningitis. *J Infect* 62:400-403, 2011
- Park KH, Cho OH, Lee EM, et al: T-cell-based assays on cerebrospinal fluid and PBMCs for rapid diagnosis of TB meningitis in non-HIV patients. *Eur Respir J* 39:768-770, 2012
- Thwaites GE: Advances in the diagnosis and treatment of tuberculous meningitis. *Curr Opin Neurol* 26:295-300, 2013
- Pai M, Flores LL, Pai N, et al: Diagnostic accuracy of nucleic acid amplification tests for tuberculous meningitis: A systematic review and meta-analysis. *Lancet Infect Dis* 3:633-643, 2003
- World Health Organization: Molecular line probe assays for rapid screening of patients at risk of multi-drug resistant tuberculosis (MDR-TB). Geneva, Switzerland, 2008
- Tortoli E, Russo C, Piersimoni C, et al: Clinical validation of Xpert MTB/RIF for the diagnosis of extrapulmonary tuberculosis. *Eur Respir J* 40:442-447, 2012
- Patel VB, Theron G, Lenders L, et al: Diagnostic accuracy of quantitative PCR (Xpert MTB/RIF) for tuberculous meningitis in a high burden setting: A prospective study. *PLoS Med* 10:e1001536, 2013
- Andronikou S, Smith B, Hatherhill M, et al: Definitive neuroradiological diagnostic features of tuberculous meningitis in children. *Pediatr Radiol* 34:876-885, 2004
- Pienaar M, Andronikou S, van Toorn R: MRI to demonstrate features and complications of TBM not seen with CT. *Childs Nerv Syst* 25:941-947, 2009
- Janse van Rensburg P, Andronikou S, van Toorn R, et al: Magnetic resonance imaging of the central nervous system in children with tuberculous meningitis. *Pediatr Radiol* 38:1306-1313, 2008
- Schoeman JF, Andronikou S, Stefan DC, et al: Tuberculous meningitis-related optic neuritis: Recovery of vision with thalidomide in 4 consecutive cases. *J Child Neurol* 25:822-828, 2010

39. Schoeman JF, Janse van Rensburg A, Laubscher JA, et al: The role of aspirin in childhood tuberculous meningitis. *J Child Neurol* 26:956-962, 2011
40. Woodfield J, Argent A, et al: Evidence behind the WHO guidelines: Hospital care for children: What is the most appropriate treatment for tuberculous meningitis? *J Trop Pediatr* 54:220-224, 2008
41. van Toorn R, Schaaf HS, Laubscher JA, et al: Short intensified treatment in children with drug-susceptible tuberculous meningitis. *Pediatr Infect Dis J* 33:248-252, 2013
42. Seddon JA, Visser DH, Bartens M, et al: Impact of drug resistance on clinical outcome in children with tuberculous meningitis. *Pediatr Infect Dis J* 31:711-716, 2012
43. Schoeman J, Malan G, van Toorn R, et al: Home-based treatment of childhood neurotuberculosis. *J Trop Pediatr* 55:149-154, 2009
44. Bruwer GE, van der Westhuizen S, Lombard CJ, et al: Can CT predict the level of CSF block in tuberculous hydrocephalus? *Childs Nerv Syst* 20:183-187, 2004
45. Prasad K, Singh MB: Corticosteroids for managing tuberculous meningitis. *Cochrane Database Syst Rev* 23:CD002244
46. Misra UK, Kalita J, Nair PP: Role of aspirin in tuberculous meningitis: A randomized open label placebo controlled trial. *J Neurol Sci* 293:12-17, 2010
47. Patnaik A, Mishra SS, Senapati SB: Surgical management of double giant tuberculomas of brain involving both supratentorial and infratentorial compartments. *J Pediatr Neurosci* 8:84-85, 2013
48. Wait JW, Schoeman JF: Behavioural profiles after tuberculous meningitis. *J Trop Pediatr* 56:166-171, 2010

## **Chapter 4**

### **Prediction of prognosis in children with tuberculous meningitis**

#### **1. Value of different staging systems for predicting neurological outcome in childhood tuberculous meningitis**

# Value of different staging systems for predicting neurological outcome in childhood tuberculous meningitis

R. van Toorn,\* P. Springer,\* J. A. Laubscher,† J. F. Schoeman\*

\*Department of Paediatrics and Child Health, Tygerberg Children's Hospital, Faculty of Health Sciences, Stellenbosch University, Cape Town, Western Cape, †Biostatistics Unit, Medical Research Council of South Africa, Tygerberg, Cape Town, Western Cape, South Africa

## SUMMARY

**BACKGROUND:** The stage of tuberculous meningitis (TBM) at presentation is strongly associated with prognosis.

**OBJECTIVE:** To compare different staging systems for TBM in predicting outcome.

**METHODS:** The associations of different staging systems with neurological outcome were assessed using clinical, diagnostic and outcome data of 554 TBM children admitted to Tygerberg Children's Hospital from January 1985 to April 2005.

**RESULTS:** The refined Medical Research Council (MRC) scale after 1 week (84%, 95% CI 81–88) had the highest discriminatory power in predicting neurological morbidity. The Glasgow Coma Score (GCS) on admission, GCS after 1 week, the 'refined' MRC scale on admission

and Tygerberg Children's Hospital (TCH) staging method all had excellent discriminatory powers in predicting outcome. Improvement of staging after 1 week occurred in children who did not have signs of raised intracranial pressure ( $P = 0.004$ ) or brainstem dysfunction on admission ( $P = 0.030$ ).

**CONCLUSIONS:** The 'refined' MRC scale 1 week after diagnosis showed the best association with neurological outcome after 6 months of treatment. The excellent discriminatory power of the TCH scale and its simplicity of use make it the ideal scale for use in resource-poor settings.

**KEY WORDS:** tuberculous meningitis; staging systems; neurological outcome

THE MORTALITY and morbidity of childhood tuberculous meningitis (TBM) remains high despite the availability of effective anti-tuberculosis medication and improvements in neurosurgical critical care. Neurological sequelae from TBM include cognitive impairment and cerebral palsy.

Prediction of prognosis in children with TBM is difficult because of the protracted course of the disease, the diversity of underlying pathological mechanisms, the unpredictability of injury-induced plasticity and variations in host immunity. Other factors that contribute to poor outcome are multidrug resistance (MDR) and human immunodeficiency virus (HIV) co-infection. Several studies have shown that the severity of TBM at presentation is strongly associated with prognosis.<sup>1–3</sup> Accurate staging is important when accessing the efficacy of interventions, such as comparing different anti-tuberculosis drug regimens and the benefits of adjuvant therapy such as immunomodulating agents.

Initially, only clinical indices were used to predict outcome in TBM, such as level of consciousness, general condition and presence or absence of paresis.

The British Medical Research Council (MRC) was the first to propose a TBM staging system in 1948 based on clinical assessment with three defined stages (early, medium and late) for patients on streptomycin (SM) treatment.<sup>1</sup> Patients with early stage disease had a good outcome in 42% of cases compared to only 7% of those with advanced disease. Mortality was 46% in early disease and 86% in advanced disease.<sup>1</sup>

First published in 1974, the Glasgow Coma Scale (GCS) was initially used to assess level of consciousness in patients with traumatic head injury.<sup>4</sup> Shortly thereafter, the GCS was used as part of several other scoring systems, including the British MRC TBM staging system. The MRC staging system using GCS scores to define level of consciousness is thus referred to as the 'modified' MRC staging system.

More recently, different scoring systems, including the GCS on its own, Acute Physiology and Chronic Health Evaluation (APACHE) II and the TBM acute neurological score (TBAN) have been proposed to predict the outcome of TBM.<sup>5,6</sup> The use of the GCS has also been validated in several studies that found it a useful predictor of outcome after 6 months in

Correspondence to: Ronald van Toorn, Department of Pediatrics and Child Health, Tygerberg Children's Hospital, Stellenbosch University, Tygerberg 7505, Western Cape, South Africa. Tel: (+27) 21 938 4234. Fax: (+27) 21 938 9138. e-mail: [vtoorn@sun.ac.za](mailto:vtoorn@sun.ac.za)

Article submitted 21 September 2011. Final version accepted 23 October 2011.

both adult and childhood TBM.<sup>7–10</sup> In a retrospective analysis of 43 adult TBM patients, the APACHE II scoring system was found to be at least as effective as the GCS and superior to the MRC system in predicting discharge outcomes of adult patients.<sup>5</sup> Among children with TBM, the sensitivity and specificity of the TBAN score on day 0 (75% and 92%) and day 3 (88% and 100%) was found to be superior to the MRC score (63% and 58%) with regard to prediction of severe neurological sequelae.<sup>6</sup>

The benefit of clinical staging or scoring systems is that they can be applied to patients in both industrialised and developing countries, as they do not rely on radiological or laboratory findings. Limitations of staging systems are that staging criteria may be difficult to apply in a standard manner for children in whom assessment of the sensorium is difficult. In addition, the initial staging may be influenced by factors other than TBM itself, which may affect levels of consciousness on presentation. These include the effect of seizures, drugs and hydration state. It is therefore possible that staging once the patient is stabilised may be of greater prognostic value than staging at first contact.

The aim of this present study was to evaluate the predictive value of several different scoring/staging systems in children with TBM at first contact and after the first week of hospitalisation.

## METHODOLOGY

Clinical data were obtained from a previous prospective study of 554 children aged <13 years with TBM admitted to Tygerberg Children's Hospital from January 1985 to April 2005. These data were used to reclassify patients according to the criteria of all the currently available staging systems in childhood TBM. The associations of the different staging systems with neurological outcome were then assessed.

The following scoring systems were evaluated. 1) Paediatric GCS. 2) The 'modified' MRC scale, which categorises patients into three clinical stages: Stage 1 refers to patients who are alert and orientated (GCS 15) without focal neurological deficit; Stage 2 refers to patients with GCS 10–14, with or without focal neurological deficit or GCS 15 with neurological deficit; while Stage 3 patients have a GCS <10, with or without focal neurological deficit. 3) The 'refined' MRC scale is similar to the 'modified' MRC scale, with the exception that it divides Stage 2 into Stage 2a (patients with GCS 15 with neurological deficit or GCS 13–14, with or without neurological deficit) and Stage 2b (GCS 10–12, with or without focal neurological deficit). 4) The TBAN (Tuberculosis Acute Neurology) score was devised by researchers from the University of California as an objective marker for predicting severe neurological sequelae.<sup>6</sup> Weighted scores are assigned for clinical features such

as mental status, seizures, cranial nerve abnormalities, focal motor abnormalities and increased muscle tone. A TBAN score of  $\geq 4$  was found to be predictive of severe neurological sequelae. 5) The Tygerberg Children's Hospital (TCH) scale is a simplified clinical staging system proposed by clinicians at the study site. Patients are categorised into four stages according to visual (fixation and following) and motor (localisation of pain) ability: Stage 1 (able to fixate and follow and localise on both sides); Stage 2a (fixates and follows but only localises pain on one side); Stage 2b (does not fixate and follow but able to localise pain on one or both sides); and Stage 3 (does not fixate and unable to localise pain).

Clinical data available allowed for evaluation of the Paediatric GCS on admission and after 1 week, the modified MRC scale on admission and after 1 week, the refined MRC scale on admission and after 1 week, the TBAN score on admission and the TCH scale after 1 week.

## Diagnosis of TBM

A definite diagnosis of TBM was made when *Mycobacterium tuberculosis* was isolated from cerebrospinal fluid (CSF). In all other cases, the diagnosis was 'probable TBM', based on clinical signs of meningitis in the presence of characteristic CSF findings (macroscopically clear, pleocytosis, elevated protein and reduced glucose). In addition, two of the following criteria had to be present: 1) recent poor weight gain (crossing of percentiles on Road to Health Card), 2) household contact with sputum smear-positive TB, 3) computed tomography (CT) scan compatible with TBM, 4) chest radiography compatible with primary TB, 5) positive tuberculin skin test and 6) other clinical specimens positive for acid-fast bacilli.

## Treatment of TBM

All children with TBM were treated according to local standard of care with a short, intensive four-drug regimen consisting of daily isoniazid 20 mg/kg, rifampicin 20 mg/kg, pyrazinamide 40 mg/kg and ethionamide 20 mg/kg for 6 months. Prednisone 2 mg/kg/day was given for the first month of treatment. Institutional practice is to perform lumbar puncture on all children with suspected TBM, even those with signs of raised intracranial pressure (ICP). Air encephalography is then performed to determine whether the hydrocephalus is of communicating or non-communicating nature. TBM cases with non-communicating hydrocephalus are treated by ventriculoperitoneal (VP) shunting or third ventriculostomy, while communicating hydrocephalus is managed medically with diuretics (50 mg/kg/day of acetazolamide and 1 mg/kg/day of furosemide). Children presenting with signs of impending herniation are referred for emergency VP shunting (lumbar puncture contra-indicated).



### Outcome of TBM

After completing 6 months of treatment, motor function, intelligence, vision and hearing were tested. Developmental quotient (DQ) was measured by the Bayley test or Griffiths test depending on the age of the child. Patients were grouped as 'normal' (DQ > 80), 'mild intellectual impairment' (DQ 50–80), or 'severe intellectual impairment' (DQ < 50). Vision and hearing were classified as normal, impaired vision or hearing, and blindness or deafness. Neurological outcome was divided into four categories: 1) normal, including normal motor function, intelligence, vision and hearing; 2) mild sequelae, including hemiparesis, mild intellectual impairment and impaired vision and/or hearing; 3) severe sequelae, including quadriplegia, severe intellectual impairment, blindness and/or deafness; and 4) death. Clinical outcome was defined as 'good' in the case of mild neurological sequelae or normal neurological outcome and 'poor' in the case of severe neurological sequelae or death.

### Statistical analysis

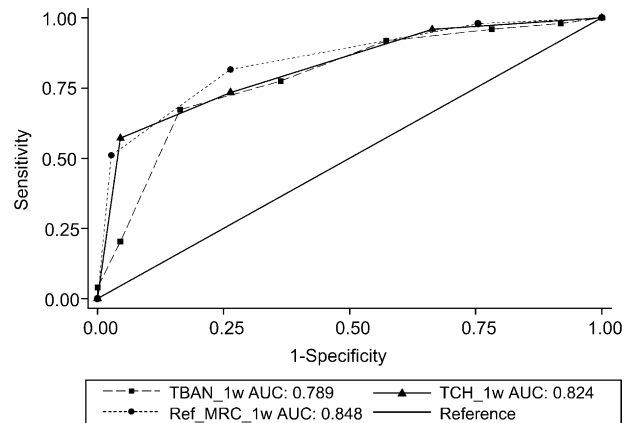
Discrimination between the different scoring systems was tested using the area under the receiver operating curves (AUC). An AUC between 0.7 and 0.8 was classified as 'acceptable', between 0.8 and 0.9 as 'excellent', and between 0.9 and 1.0 as 'outstanding discrimination'. The best cut-off point was that which maximised the sum of specificity and sensitivity.

A maximum-likelihood model was fitted to the data with the group whose stage did not change between admission and 1 week later and, as the reference group. Variables included in this model, with the reference categories in brackets, were: age, convulsions (no), clinical signs of raised ICP (no), brain stem signs (no), cranial nerve palsy on admission (no), serum sodium level (normal), hydrocephalus (no) and need for VP shunting (yes).  $P < 0.05$  was indicative of statistical significance.

The study was approved by the Human Research Ethics Committee of Stellenbosch University, Cape Town, Western Cape, South Africa.

## RESULTS

The refined MRC scale after 1 week (84%, 95% confidence interval [CI] 81–88) has the highest discriminatory power in predicting outcome in terms of AUC. GCS on admission (80%, 95%CI 74–85), GCS after 1 week (83%, 95%CI 78–88), the modified MRC scale after 1 week (82%, 95%CI 78–86) and the TCH scale (82%, 95%CI 75–89) all had excellent discriminatory power in predicting outcome. The discriminatory power of the modified MRC scale on admission (75%, 95%CI 71–79), the refined MRC scale on admission (74%, 95%CI 70–79) and the TBAN score on admission (78%, 95%CI 75–89) was acceptable in terms of AUC.



**Figure** Comparison of the predictive values of refined MRC staging after 1 week with the TCH and TBAN scores. Refined MRC staging had the highest predictive value, significantly higher than TBAN, but not significantly higher than the TCH score. TBAN\_1 wk = Tuberculous Meningitis Acute Neurology Score after 1 week; AUC = area under the receiver operating curves; TCH\_1w = Tygerberg Children's Hospital score after 1 week; Ref\_MRC\_1w = refined MRC score after 1 week; MRC = British Medical Research Council.

There was no significant difference in predictive power between the GCS on admission and that after 1 week ( $P = 0.096$ ). In contrast, the AUC significantly improved in the modified MRC scale after 1 week ( $P = 0.001$ ) and the refined MRC scale after 1 week ( $P < 0.001$ ). The predictive power of the refined MRC scale after 1 week was not significantly higher than the TCH score ( $P = 0.242$ ). It was, however, significantly higher than the TBAN score ( $P = 0.027$ ; Figure).

Table 1 shows the motor outcome after 6 months using the refined MRC staging system after 1 week. Of note was that significantly more children with severe motor disability (spastic quadriplegia) were classified as Stage 2b ( $P = 0.028$ ) compared to Stage 2a. No difference was noted between Stages 2a and 2b regarding hemiplegics and normal motor outcome ( $P = 0.75$ ). Table 2 compares mean DQ after 6 months in refined MRC Stage 2a and 2b patients. Of note is that the mean developmental quotient of children in Stage 2b was significantly lower than that of Stage 2a children ( $P = 0.001$ ). Tables 3 and 4 compare motor and cognitive outcomes after 6 months between the different stages using the TCH staging system.

**Table 1** Motor outcome after 6 months using the refined MRC scale after 1 week ( $n = 483$ )

	<i>n</i>	Stage 1 %	Stage 2a %	Stage 2b %	Stage 3 %
Normal	243	39.1	26.7	24.7	9.5
Left hemiparesis	71	1.4	33.8	33.8	31.0
Right hemiparesis	58	0	34.5	41.3	24.1
Quadriplegia	60	0	3.3	23.3	73.3
Death	51	0	1.9	1.9	96.0

MRC = British Medical Research Council.

**Table 2** Mean developmental quotient of children ( $n = 353$ ) using refined MRC staging after 1 week

	Mean DQ	95%CI
Stage 1	78.6	75.8–81.3
Stage 2a	68.3	65.0–71.4
Stage 2b	58.9	54.5–63.6
Stage 3	44.3	38.0–50.4

MRC = British Medical Research Council; DQ = development quotient; CI = confidence interval.

**Table 3** Motor outcome after 6 months using TCH staging after 1 week ( $n = 162$ )

	<i>n</i>	Stage 1 %	Stage 2a %	Stage 2b %	Stage 3 %
Normal	72	50.0	27.7	20.8	1.4
Left hemiparesis	32	3.1	53.3	28.1	15.6
Right hemiparesis	27	3.7	51.8	22.2	22.2
Quadripareisis	24	0	12.5	16.6	70.8
Death	7	0	2.8	1.4	57.1

TCH = Tygerberg Children's Hospital.

**Table 4** Developmental outcome after 6 months using TCH staging ( $n = 162$ )

	Mean DQ	95%CI
Stage 1	76.3	71.4–81.6
Stage 2a	64.1	59.1–69.0
Stage 2b	57.7	50.8–64.6
Stage 3	28.1	19.4–36.7

TCH = Tygerberg Children's Hospital; DQ = development quotient; CI = confidence interval.

Comparing the refined MRC staging system on admission and after 1 week, 51.1% ( $n = 269$ ) of patients did not change stage and 45.1% ( $n = 237$ ) improved their staging, while only 3.8% ( $n = 20$ ) deteriorated; 13% ( $n = 71$ ) of the patients improved their staging by two or more categories.

Variables analysed to determine their significance regarding change of staging included age, convulsions, cranial nerve palsy, raised ICP, presence of brain stem signs, serum sodium level, hydrocephalus and need for VP shunting. Improvement of staging occurred in children who did not have raised ICP on admission ( $P = 0.004$ ) or who did not have brain stem signs ( $P = 0.030$ ).

## DISCUSSION

The steep decline in mortality from TBM has been paralleled by a marked increase in the number of survivors, many with severe neurological sequelae. A recent large childhood TBM study documented neurological disability in as many as 75% of survivors, despite an exceptionally low mortality rate of only 13%.<sup>8</sup>

This study found that all the staging/scoring systems evaluated had discriminatory power in predict-

ing outcome after 6 months, ranging from acceptable to excellent. Refined MRC staging after 1 week had the highest discriminatory power in predicting outcome in terms of AUC. Delaying the staging by 1 week significantly improved the predictive power of both the modified MRC staging system ( $P = 0.001$ ) and the refined MRC staging system ( $P < 0.001$ ), but not the GCS ( $P = 0.096$ ). This can be attributed to the fact that the GCS best motor response is determined using only the best unilateral response. Even severe residual unilateral motor involvement on follow-up would therefore not necessarily be accounted for on the GCS on admission.

The TCH staging system is a simplified staging system that relies only on a patient's ability to visually fixate and follow and to localise pain on both sides. It is less dependent on clinical ability and neurological expertise than other staging systems, which makes it ideally suited for use in resource-poor environments that also have the highest TB burdens. It has the further advantage of distinguishing unilateral from bilateral motor involvement, which is important, as bilateral cerebral infarction often occurs in advanced TBM. The scale also illustrates the poor outcome that can be expected in TBM children who are not able to fixate or localise on either side (Stage 3) 1 week after admission (Tables 3 and 4). The TCH staging system showed excellent predictive power for outcome after 1 week, and did not differ significantly from the refined MRC staging system in this regard ( $P = 0.242$ ).

The motivation for refining Stage 2 of the modified MRC staging system was to more accurately delineate disease severity, as children without neurological deficit and only slight drowsiness (GCS 14) are staged together with children with neurological deficit and a GCS of 10–13. This study found that the risk of severe motor deficit (spastic quadriplegia;  $P = 0.028$ ) and the degree of intellectual disability ( $P = 0.001$ ) were higher in children classified as Stage 2b compared to 2a (Tables 1 and 2). No difference was found between Stages 2a and 2b regarding the risk of hemiplegia, a finding most likely related to young children's ability to overcome focal neurological deficits (neuroplasticity).

The majority of the children either improved their initial staging (45%) or stayed the same (51%); <4% regressed to a lower stage after 1 week. Neurological deterioration during the first week of treatment has been described as a result of the progressive nature of TBM-associated vasculitis (development of new infarcts), which may occur despite optimal treatment. Clinical improvement may occur when comorbid factors are addressed, including correction of dehydration and electrolyte imbalances, control of seizures and relief of raised ICP. This study, however, found that factors such as age, convulsions, cranial nerve palsy, hydrocephalus (irrespective of type) and serum

sodium (both high and low) did not change stage of disease after 1 week. The only variable associated with significant stage improvement was absence of signs of brainstem dysfunction on admission. Persistent brainstem dysfunction as a poor prognostic indicator is confirmed by magnetic resonance imaging studies which found that the presence of ischaemic brainstem lesions in children with TBM invariably leads to severe cognitive and motor deficits.<sup>11</sup> Studies have also shown that a poor correlation exists between clinical signs of raised ICP in children with TBM and monitored CSF pressure.<sup>12</sup> This finding can be explained by the fact that parenchymal brain stem damage in TBM may mimic the signs of raised ICP.

## CONCLUSION

The 'refined' MRC scale 1 week after diagnosis showed the best association with neurological outcome after 6 months of treatment. The excellent predictive power of the TCH scale and its simplicity of use make it ideal for use in resource-poor settings. Persistent brainstem dysfunction is an indicator of poor prognosis in children with TBM.

## References

- 1 Medical Research Council Streptomycin in Tuberculous Trials Committee. Streptomycin treatment of tuberculous meningitis. *Lancet* 1948; 1: 582–596.
- 2 Kalita J, Misra U K. Outcome of tuberculous meningitis at 6 and 12 months: a multiple regression analysis. *Int J Tuberc Lung Dis* 1999; 3: 261–265.
- 3 Sheu J J, Yuan R Y, Yang C C. Predictors for outcome and treatment delay in patients with tuberculous meningitis. *Am J Med* 2009; 338: 134–139.
- 4 Teasdale G, Jennet B. Assessment of coma and impaired consciousness. A practical scale. *Lancet* 1974; 2: 81–84.
- 5 Chou C-H, Lin G-M, Ku C-H, Chang F-Y. Comparison of the APACHE II, GCS and MRC scores in predicting outcomes in patients with tuberculous meningitis. *Int J Tuberc Lung Dis* 2010; 14: 86–92.
- 6 Saitoh A, Pong A, Waecker N J, Leake J A D. Prediction of neurologic sequelae in childhood tuberculous meningitis: a review of 20 cases and proposal of a novel scoring system. *Pediatr Infect Dis J* 2005; 24: 207–212.
- 7 Springer P, Swanevelder S, van Toorn R, van Rensburg A J. Cerebral infarction and neurodevelopmental outcome in childhood tuberculous meningitis. *Eur J Paediatr Neurol* 2009; 13: 343–349.
- 8 van Well G T, Paes B F, Terwee C B, Springer P, et al. Twenty years of pediatric tuberculous meningitis: a retrospective cohort study in the Western Cape of South Africa. *Pediatrics* 2009; 123: e1–8.
- 9 Kalita J, Misra U K, Ranjan P. Predictors of long-term neurological sequelae of tuberculous meningitis: a multivariate analysis. *Eur J Neurol* 2007; 14: 33–37.
- 10 Misra U K, Kalita J, Srivastava M, Mandal S K. Prognosis of tuberculous meningitis: a multivariate analysis. *J Neurol Sci* 1996; 137: 57–61.
- 11 van der Merwe D J, Andronikou S, van Toorn R, Pienaar M. Brainstem ischemic lesions on MRI in children with tuberculous meningitis: with diffusion weighted confirmation. *Childs Nerv Syst* 2009; 25: 949–954.
- 12 Schoeman J F, le Roux D, Bezuidenhout P B, Donald P R. Intracranial pressure monitoring in tuberculous meningitis: clinical and computerized tomographic correlation. *Dev Med Child Neurol* 1985; 27: 644–654.

## R É S U M É

**CONTEXTE :** Le pronostic de la méningite tuberculeuse (TBM) est en association étroite avec le stade de la maladie.

**OBJECTIF :** Comparer les différents systèmes de stadification de la TBM en matière de prédiction des résultats.

**MÉTHODES :** Les associations des différents systèmes de stadification avec les résultats neurologiques ont été évaluées en utilisant les données cliniques, celles de diagnostic et celles des résultats chez 554 enfants atteints de TBM et admis à l'Hôpital des Enfants de Tygerberg (TCH) entre janvier 1985 et avril 2005.

**RÉSULTATS :** Le système affiné du Medical Research Council (MRC) après 1 semaine a le pouvoir discriminatoire le plus élevé pour prédire une morbidité neurologique (84% ; IC95% 81–88). Le Score de Coma de

Glasgow (GCS) à l'admission, le GCS après 1 semaine, l'échelle affinée du MRC à l'admission et la méthode de stadification du TCH ont tous un pouvoir discriminatoire excellent pour la prédiction du résultat. L'amélioration du stade après 1 semaine est survenue chez les enfants qui à l'admission n'avaient pas de signes d'augmentation de la pression intracrânienne ( $P = 0,004$ ) ou de dysfonctionnement du tronc cérébral ( $P = 0,030$ ).

**CONCLUSIONS :** La stadification affinée du MRC une semaine après le diagnostic s'est avérée avoir la meilleure association avec le résultat neurologique après 6 mois de traitement. La puissance discriminatoire excellente de l'échelle TCH et sa simplicité d'emploi en font une échelle idéale pour l'utilisation dans les contextes à faibles ressources.

## R E S U M E N

**MARCO DE REFERENCIA:** La fase clínica de la meningitis tuberculosa (TBM) en el momento de la consulta presenta una estrecha correlación con el pronóstico.

**OBJETIVO:** Comparar los diferentes sistemas de clasificación evolutiva de la TBM con respecto al pronóstico del desenlace.

**MÉTODOS:** Se evaluó la relación de los diferentes sistemas de clasificación con el desenlace neurológico a partir de datos clínicos, diagnósticos y de desenlace de 554 niños con TBM que ingresaron al hospital pediátrico Tygerberg (TCH) entre enero de 1985 y abril del 2005.

**RESULTADOS:** La escala 'modificada' definida por el Medical Research Council (MRC) después de 1 semana (84%; IC95% 81–88) ofreció el mayor poder discriminatorio en materia de pronóstico de la morbilidad neu-

rológica. La escala del coma de Glasgow (GCS) en el momento de la hospitalización y después de una semana, la escala 'modificada' del MRC al ingreso y el método de clasificación del TCH exhibieron un excelente poder discriminatorio en la predicción del desenlace. En los niños que no presentaban hipertensión intracraneal ( $P = 0,004$ ) ni disfunción del tronco encefálico ( $P = 0,030$ ) al ingreso, se observó una mejoría de la clasificación después de 1 semana.

**CONCLUSIÓN:** La escala 'modificada' del MRC 1 semana después del diagnóstico ofreció la mejor correlación con el desenlace clínico 6 meses después del tratamiento. El gran poder discriminatorio de la escala y su facilidad de aplicación la convierten en un método ideal en los entornos con escasos recursos.

## **Chapter 5**

### **Treatment duration of tuberculous meningitis**

- 1. Short intensified treatment in children with drug-susceptible tuberculous meningitis**
  
- 2. Letter to the Editor: In reply: Short intensified treatment in children with drug-susceptible tuberculous meningitis**

# Short Intensified Treatment in Children with Drug-susceptible Tuberculous Meningitis

Ronald van Toorn, FCP,\* H. Simon Schaaf, MD,\* Jacoba A. Laubscher, BCOMM,† Sabine L. van Elsland, MSc,\*‡ Peter R. Donald, MD,\* and Johan F. Schoeman, MD\*

**Background:** The World Health Organization recommends 12-month treatment (2RHZE/10RH) for children with tuberculous meningitis (TBM). Studies evaluating length of antituberculous treatment for TBM report similar completion and relapse rates comparing 6-month treatment with 12-month treatment.

**Methods:** A prospective evaluation to determine whether short-course intensified treatment (6 RHZEth for HIV-infected and 9RHZEth for HIV-uninfected) is sufficient and safe in children with drug-susceptible TBM.

**Results:** Of 184 children with TBM, median age 58 months and 90 (49%) male, 98 children (53%) presented at stage II TBM, 64 (35%) at stage III TBM and only 22 (12%) at stage I TBM. Ninety (49%) children were treated at home after the first month of therapy; all others received their full treatment in hospital. The HIV prevalence was 14% (22/155 children tested). Anti-TB drug-induced hepatotoxicity occurred in 5% (8 of 143 children tested), all tested negative for viral hepatitis; in all 8 cases, the original regimen was restarted without recurrence. After treatment completion, 147 (80%) children had a good outcome, 7 (3.8%) died. There was no difference in outcome between HIV-infected and HIV-uninfected children who completed treatment ( $P = 0.986$ ) nor between TBM-hydrocephalic children who were medically treated or shunted ( $P = 0.166$ ).

**Conclusion:** Short intensified treatment is safe and effective in both HIV-infected and HIV-uninfected children with drug-susceptible TBM.

**Key Words:** pediatric, children, tuberculous meningitis, treatment

(*Pediatr Infect Dis J* 2014;33:248–252)

Recent World Health Organization (WHO) guidelines recommend that children with tuberculous meningitis (TBM) should be treated with 2 months of isoniazid (INH), rifampicin (RMP), pyrazinamide (PZA) and ethambutol followed by 10 months of INH and RMP.<sup>1</sup> As the WHO has to consider the circumstances under which TB will be treated worldwide, this long duration of treatment was a compromise between the importance of preventing relapse and the unavailability of certain drugs (eg, ethionamide) and an unwillingness to give PZA for >2 months in many settings (personal communication P.R.D.).

However, a recent review found that all existing trials assessing anti-TB treatment for TBM had limited power, poor methodology and used varying treatment regimens with conflicting results.<sup>2</sup>

Accepted for publication August 23, 2013.

From the \*Department of Pediatrics and Child Health, Stellenbosch University and Tygerberg Children's Hospital, Western Cape; †Biostatistics Unit, Medical Research Council of South Africa, Tygerberg, Cape Town, South Africa; and ‡Department of Pediatric Infectious Diseases and Immunology, VU University Medical Center, Amsterdam, The Netherlands.

The authors have no funding or conflicts of interest to disclose.

Address for correspondence: Ronald van Toorn, Department of Pediatrics and Child Health, Stellenbosch University, PO Box 19063, Tygerberg, 7505, South Africa. E-mail: [vtoorn@sun.ac.za](mailto:vtoorn@sun.ac.za).

Supplemental digital content is available for this article. Direct URL citations appear in the printed text and are provided in the HTML and PDF versions of this article on the journal's website ([www.pidj.com](http://www.pidj.com)).

Copyright © 2013 by Lippincott Williams & Wilkins

ISSN: 0891-3668/14/3303-0248

DOI: 10.1097/INF.0000000000000065

The studies reviewed reported similar completion and relapse rates when 6 months therapy with at least INH, RMP and PZA was compared with longer treatment regimens, suggesting that 6-month therapy for TBM may be sufficient. Shorter treatment regimens are cheaper, less labor-intensive and may improve patient compliance.

This study describes local experience with intensive short-course anti-TB treatment of at least 6-month duration in a large cohort of children with drug-susceptible TBM over a 4-year period. The aim was to demonstrate noninferiority of our short-course intensive regimen compared with other published treatment regimens.

## MATERIALS AND METHODS

### Setting

Tygerberg Children's Hospital, a referral hospital in the Western Cape province of South Africa, provides specialized care to half the province's 1.2 million children. A recent pediatric meningitis survey identified TBM as the most common form of bacterial meningitis in the Western Cape province.<sup>3</sup>

### Study Population and TBM Definition

All children admitted consecutively to Tygerberg Children's Hospital with TBM from January 1, 2006, through December 31, 2009, aged 0–13 years, were included in the study. Children with multidrug-resistant TB (MDR-TB; ie, resistance to at least INH and RMP) were excluded but INH-mono-resistant TBM cases were included. A definite diagnosis of TBM was made when *Mycobacterium tuberculosis* was cultured from cerebrospinal fluid (CSF) and/or polymerase chain reaction for *M. tuberculosis* tested positive in CSF. In all other cases, the diagnosis was "probable TBM" based on clinical signs of meningitis in the presence of characteristic CSF findings (macroscopically clear, pleocytosis usually with lymphocyte predominance, elevated protein and reduced glucose). In addition, two of the following criteria were required: other clinical specimens culture positive for *M. tuberculosis* and/or positive TB histology, a positive tuberculin skin test, a chest radiograph compatible with TB, a cranial computerized tomography or magnetic resonance imaging compatible with TBM, growth failure with crossing of weight-for-age percentiles or finally, household contact with sputum smear-positive pulmonary TB. TBM stage was classified as TBM stage I [Glasgow Coma Scale (GCS) 15 with no focal signs], TBM stage II (GCS 11–14 or GCS 15 with focal neurology) or TBM stage III (GCS < 11).

### Treatment of TBM

Local practice is to treat TBM with a short, intensive 4-drug regimen consisting of daily INH 20mg/kg (maximum 400mg daily), RMP 20mg/kg (maximum 600mg daily), PZA 40mg/kg (maximum 2g daily) and ethionamide (ETH) 20mg/kg (maximum 750mg daily), all given in a single daily dose, for 6 months duration. HIV-infected children, however, are treated for 9 months because of perceived slower response to treatment. Prednisone 2mg/kg/d (maximum 60mg/d) is given for the first month of treatment and gradually discontinued over the next 2 weeks. If the child's isolate of *M. tuberculosis* or that of the source case is resistant to any of the drugs used or if the child deteriorates clinically on this regimen, alternative



anti-TB treatment is considered. Treatment of INH-monoresistant TB involves the addition of a fluoroquinolone and terizidone with treatment for 9 months. Air-encephalography is used to distinguish between communicating and noncommunicating types of obstructive hydrocephalus. Institutional preference is to treat noncommunicating hydrocephalus by ventriculo-peritoneal (VP) shunting or endoscopic third ventriculostomy, whilst communicating hydrocephalus is treated medically with diuretics (acetazolamide 50 mg/kg/d and furosemide 1 mg/kg/d) during the first month of therapy to expedite normalization of intracranial pressure.

Once clinically stable, the child is medically evaluated and the family is screened by a social worker to determine suitability for home-based therapy.<sup>4</sup> Definite exclusion criteria for home-based treatment included: no reliable caregiver; insufficient income and support network; regular visits to TB-clinic not possible and no other directly observed therapy supporter available and MDR-TB or untreated household TB source case.<sup>4</sup> Caregivers of eligible patients were offered the choice of either in-hospital or home-based treatment. During the 6-month, home-based therapy, the mother and child were reviewed monthly assessing the clinical wellbeing of the child, adherence to treatment and adverse effects.

### Evaluation for Adverse Effects

Local practice is to perform liver function tests [serum aspartate aminotransferase, alanine aminotransferase (ALT) and bilirubin] on admission and during the first 2 weeks of treatment. Thereafter, children are observed clinically for symptoms of hepatotoxicity (jaundice, abdominal pain, new onset nausea and vomiting).

Anti-TB drug-induced hepatotoxicity (ADIH) severity was classified according to WHO adverse drug reaction terminology<sup>5</sup>: grade 1 (mild): ALT <2.5 times upper limit normal (ALT 51–125 U/L); grade 2 (mild) ALT 2.5–5 times upper limit normal (ALT 126–250 U/L); grade 3 (moderate): ALT 5–10 times upper limit normal (ALT 251–500 U/L); grade 4 (severe): ALT >10 times upper limit normal (ALT >500 U/L). First-line treatment (with liver enzyme monitoring) is continued in asymptomatic children with WHO grade 1 hepatotoxicity. Children who developed more severe degrees of liver toxicity are commenced on liver-friendly regimens that include amikacin, ofloxacin, ethambutol and terizidone (terizidone for good CSF penetration). Once the liver enzymes have normalized, stepwise rechallenge with first-line drugs is attempted. Nausea and vomiting was considered significant if vomiting occurred for >2 consecutive days and where intervention such as administering ETH in the evenings or antiemetics was required. Combination antiretroviral therapy (cART) consisting of stavudine, lamivudine and efavirenz was initiated as soon after HIV diagnosis as possible.

### Outcome

After treatment completion, motor function, intelligence, vision and hearing were tested. Developmental quotient (DQ) was measured by Griffith's developmental scales. Patients were grouped as "normal" (DQ: > 80), "mild intellectual impairment" (DQ: 50–80) or "severe intellectual impairment" (DQ: <50). Vision and hearing were classified as normal, impaired and blindness or deafness.

Neurological outcome was divided into 4 categories: (1) normal, including normal intelligence, motor function, vision and hearing; (2) mild sequelae, including mild intellectual impairment, hemiparesis and impaired vision and/or hearing; (3) severe sequelae, including severe intellectual impairment, quadriparesis, blindness and/or deafness and (4) death. Clinical outcome was defined as "good" in the case of normal outcome or mild neurological sequelae and defined "poor" in the case of severe neurological sequelae or death.

### Relapse Rate

Patients who remained disease free (any form of TB) for a period of >2 years after treatment completion were considered cured. Relapse rate was determined by telephonic contact with the child's caregiver at least 2 years after therapy completion or if the patient was reviewed in our neurology outpatient clinic after this time. The caregiver was requested to confirm the child's identity by date of birth and questions were asked relating to the child's clinical wellbeing and scholastic performance. If the caregiver expressed any concern, clinical review in neurology outpatients was offered.

### Statistical Analysis

Outcome was categorized into good (normal/mild) and poor (severe/death) outcome. Bivariate associations with outcome were assessed by either the  $\chi^2$  test or Fisher's exact test (categorical variables) or an analysis of variance (continuous variables). A *P*-value <0.05 was indicative of statistical significance. Logistic regression was used to assess the association between outcome ("good" is reference) and either type of hydrocephalus or HIV infection. Results were expressed as odds ratios with 95% confidence intervals (CI). A multinomial logistic regression was used to assess the association between outcome (normal as reference, mild and severe/death) and where the patients were treated (home based as reference versus in-hospital), adjusted for the stage of the disease. Results were expressed as relative risk ratios with 95% CI.

### Ethics

Ethical approval (N11/07/244) was obtained from the Stellenbosch University Human Research Ethics Committee.

## RESULTS

Table 1 demonstrates the demographics, TBM staging, clinical features, selected diagnostic tests and outcome of 184 consecutive children <13 years of age with TBM. All children with stage I TBM had a good outcome compared with 97% with stage II disease and 47% with stage III disease. There was no difference in outcome after completion of treatment between HIV-infected and HIV-uninfected children (odds ratios: 1.01, 95% CI: 0.34–2.96, *P* = 0.986). The overall mortality before completion of anti-TB therapy was 3.8% (7 of 184 children). All seven children who died were moribund on admission (stage III disease) and three children died within 8-days of starting treatment. Cranial computerized tomography on admission revealed extensive bilateral basal ganglia infarction (suggesting brainstem involvement) in all seven cases; only one of those who died was HIV infected.

Table 2 demonstrates the disease complications and drug adverse effects of the 184 TBM children. None of the children with communicating hydrocephalus required VP shunting and their outcome after completion of therapy was similar to those children with noncommunicating hydrocephalus who required VP shunting. (odds ratios: 0.55, 95% CI: 0.23–1.28, *P* = 0.166).

Liver enzyme levels before initiation of treatment were normal in 75 (90%) of the 83 children tested; none with baseline abnormal liver functions had ALT levels >2.5 times the normal upper limit. Only eight (5.6%) of the 143 children who underwent liver enzyme testing during treatment experienced ADIH (grade 3 or 4 hepatotoxicity); viral hepatitis serology proved negative in all and none of the children were clinically jaundiced or had elevated serum bilirubin levels. The median age of the ADIH children was 34 months (range 15–156 months) and the median duration on therapy was 44 days (range 8–105 days). In all cases, change to liver-friendly regimens resulted in normalization of liver enzymes (median duration 7 days, range 3–16 days) and the original regimen was restarted (stepwise) without recurrence. None of the

**TABLE 1.** Demographics, TBM Staging, Clinical Features, Selected Diagnostic Tests and Outcome of 184 Consecutive Children <13 Years of Age With TBM

Characteristic	Number (%) Unless Specified
Age (median in months)	58 months (3–156 months)
Gender: Female	94 (51)
Stage of TBM (n = 184)	
TBM Stage 1	22 (11.9)
TBM Stage 2	98 (53.3)
TBM Stage 3	64 (34.8)
Definite TBM	16 (8.7)
Probable TBM	168 (91.3)
HIV status (n = 155)	(as % of those tested)
Uninfected	128 (82.6%)
Infected	22 (14.2%)
Exposed uninfected	5 (3.2%)
Not tested	29
Positive TB cultures	(as % of those tested)
Gastric washings (155 tested)	43 (27.7%)
Cerebrospinal fluid (136 tested)	16 (11.8%)—2 also polymerase chain reaction positive†
Treatment	
In-hospital treatment only	94 (51%)
Home-based treatment after stabilization	90 (49%)
Outcome after end of treatment	
Normal	79 (42.9%)
Mild sequelae	68 (36.9%)
Severe sequelae	30 (16.3%)
Death	7 (3.8%)
Relapse rate of treatment survivors*	
Home-based treatment (n = 90)	
No relapses (cured)	88
Death	2
Lost to follow up	0
In-hospital treatment (n = 87)	
No relapses (cured)	52
Death	6
Lost to follow up	29

\*Relapse rate: children who remained disease free (any form of TB) for a period of >2 years after treatment completion were considered cured.

†CSF polymerase chain reaction testing for TB is not routinely performed.

22 HIV-infected children on cART developed grade 3 or 4 hepatotoxicity. All eight children with grade 3 or 4 hepatotoxicity experienced significant new onset vomiting. The prevalence of significant vomiting in children without ADIH was 6% (n = 11). In these cases, substituting ETH with ethambutol (three cases) or administering the ETH at night rather than in the morning solved the problem.

Table 3 demonstrates the duration of therapy and reasons for prolonged treatment (longer than 6 months) in the 177 TBM children who survived TBM upon completion of therapy. Figure 1 illustrates the baseline and outcomes of the 184 TBM children who intended and received 6 months of treatment compared with those who required prolonged treatment because of other reasons. Table, Supplemental Digital Content 1, <http://links.lww.com/INF/B704>, demonstrates the characteristics of home-based treatment versus hospital-based treatment of all children presenting with TBM by stage of disease. In-hospital treated TBM children had a higher risk of a poor outcome, after adjustment for the stage of disease (relative risk = 4.55, 95% CI: 1.46–14.15,  $P = 0.009$ ). No relapses were reported in 88 of the 90 children who completed home-based treatment. Two children on home-based treatment demised after completion of treatment; 1 had stage III disease and the other was HIV infected (postmortems not performed). Fifty-one children were clinically reviewed in the neurology outpatient department  $\geq 2$  years after treatment completion. In all other cases, the caregiver(s) or patient him/herself reported clinical wellbeing. Five

**TABLE 2.** Disease Complications and Drug Adverse Effects of 184 TBM Children

Complication/Adverse Effect	Number (%)
Hydrocephalus	
No hydrocephalus	75 (40.8)
Communicating hydrocephalus	72 (39.1)
Noncommunicating hydrocephalus	37 (20.1)
VP shunted	34
Endoscopic third ventriculostomy	3
Anti-TB drug-induced hepatotoxicity	
Not tested	41 (22.3)
Normal ALT < 50 U/L	111 (60.4)
Grade 1 (mild) ALT 51–125 U/L	18 (9.8)
Grade 2 (mild) ALT 126–250 U/L	6 (3.2)
Grade 3 (moderate) ALT 251–500 U/L	6 (3.2)
Grade 4 (severe) ALT > 500 U/L	2 (1.1)
Significant nausea and vomiting *	19 (10.3)

\*Significant vomiting: vomiting occurring for >2 consecutive days and where separation of drug administration (ETH in the evenings) or additional treatment (antiemetics) was required. Of the 19 patients, 8 with significant vomiting had anti-TB drug-induced hepatotoxicity.

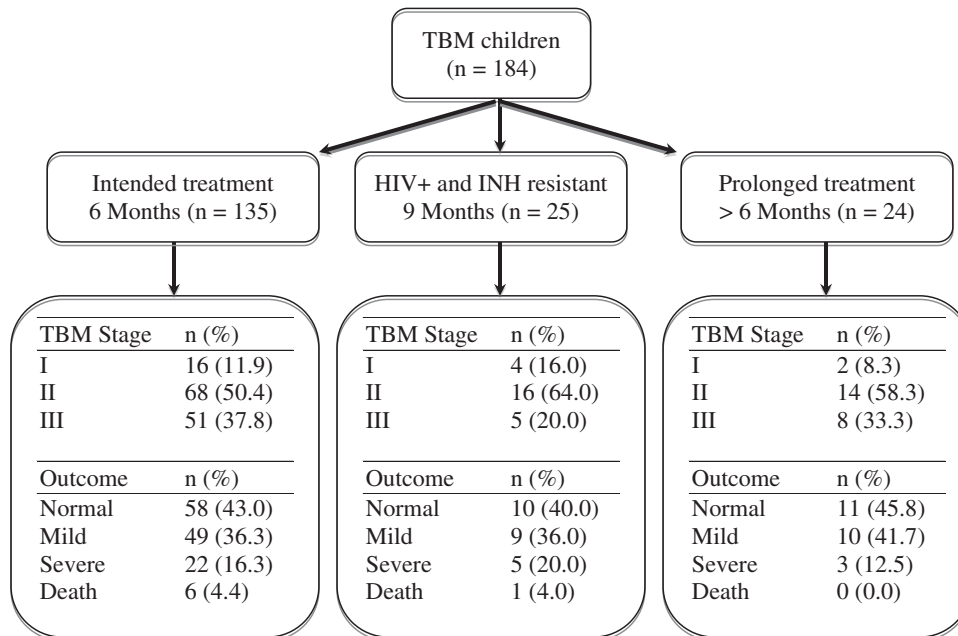
children who qualified for home-based treatment were readmitted for hospital-based treatment. Reasons for readmission included: development of nonrelated ocular myasthenia gravis, paradoxical enlargement of a tuberculoma, TB immune reconstitution inflammatory syndrome, poor adherence and parental request (struggling to provide care). Of the 87 TBM children who survived in-hospital treatment, we established that no relapses occurred in 52 children, but the caregivers of 29 children could not be contacted. Six children demised: five had previous stage III TBM and four of these (66%) were HIV-infected. Postmortems were not requested; death certificates stated either HIV infection or post-TBM complications. One child with stage III TBM died of HIV-related pneumonia >2 years after completion of therapy.

**TABLE 3.** Duration of Treatment and Reasons for Prolonged Treatment (>6 Months) in the 177 TBM Children Who Survived Completion of Therapy

Treatment Duration	HIV Negative and Not Tested (n = 156)		HIV Positive (n = 21)	
6 months	130 (83.3%)	—	6* (28.6%)	—
7 months	6 (3.9%)	6 ADIH	0 (0.0%)	—
8 months	5 (3.2%)	2 ADIH	0 (0.0%)	—
9 months	11 (7.1%)	3 poor adherence 1 INH monoresistance 1 HIV-exposed uninfected 4 TB- immune reconstitution inflammatory syndrome 5 TB mass lesions	12 (57.1%)	—
12 months	2 (1.3%)	2 TB mass lesions	2 (9.5%)	2 TB mass lesions
15 months	0 (0.0%)	—	1 (4.8%)	1 TB mass lesion
17 months	1 (0.6%)	1 INH resistance with TB mass lesion	0 (0.0%)	—
18 months	1 (0.6%)	1 TB mass lesion	0 (0.0%)	—

TB mass lesion refers to either large tuberculoma(s) or TB abscesses.

\*All the HIV-infected TBM children who were treated for 6 months had either stage I or stage II disease.



**FIGURE 1.** The baseline and outcomes of TBM children who intended and received 6 months of treatment; who intended and received 9 months of treatment and those who required prolonged treatment because of other reasons.

## DISCUSSION

Treatment response in TBM is judged by early morbidity, mortality and relapse rates.<sup>6</sup> The importance of early diagnosis and treatment is confirmed by the good outcome of stage I (100%) and stage II TBM (97%) cases compared with only 47% in stage III TBM. The overall mortality of 3.8% at completion of treatment compares favorably with the median mortality rate of 33% (range 5–65%) reported in a recent review describing outcome in TBM treatment studies.<sup>2</sup>

The WHO recommends that children with TBM should be hospitalized, preferably for at least the first 2 months of treatment.<sup>1</sup> Long-term in-hospital TBM treatment, however, is seldom feasible in resource-poor countries due to bed shortages and budgetary constraints. A previously conducted observational study at our hospital found that childhood TBM can be successfully treated at home, provided that patients are carefully selected and meticulously followed up by a dedicated health care team.<sup>4</sup> The efficacy of home-based treatment and our intensive short-course anti-TB regimen is highlighted by the absence of relapses in the 88 children that completed home-based TBM treatment (follow-up period 2–5 years). The fact that not a single patient was lost to follow up in the home-based treatment group can be ascribed to the initial selection qualifying criteria for home-based treatment.

The prevalence of ADIH in the study population who underwent liver function testing was 5.6% and only 4.3% developed symptomatic ADIH. In most resource-poor countries with high TB burden, liver function tests cannot be routinely performed. In those situations, one has to rely on clinical symptoms of hepatotoxicity, such as jaundice, abdominal pain, nausea and vomiting. Of interest was that none of the children with ADIH developed jaundice or had elevated serum bilirubin levels. This is much lower than the incidence of abnormal liver functions (52.9%) and jaundice (10.8%) reported in a recent literature review of 717 TBM children.<sup>7</sup> All of the children who developed ADIH experienced new onset vomiting, which suggests that it is a more reliable clinical marker of hepatotoxicity compared with clinical jaundice.

Reported risk factors for ADIH in children are female sex, slow acetylator status, malnutrition, disseminated TB disease and pre-existent liver disease.<sup>7</sup> The low prevalence of ADIH could be attributed to the high frequency of fast acetylator status (approximately 60%) in the study population.<sup>8</sup> Baseline liver function testing also did not demonstrate evidence of preexistent liver disease. Whether HIV-infected children with TBM have an increased risk of ADIH is not determined; overlapping drug toxicities, drug-drug interactions and malnutrition are factors likely to increase the risk of ADIH in HIV-infected TBM children. However, none of the HIV-infected children in the study developed ADIH. Studies from developing countries report high rates of infectious viral hepatitis in children with suspected ADIH.<sup>9</sup> Viral hepatitis serology proved negative in all study children with ADIH. This can partly be attributed to universal hepatitis B vaccination policy in South Africa since 1995. Although ADIH occurred within the first 2 months of treatment in 6 of the 8 children, the remaining 2 children developed ADIH during their final month of treatment confirming that ADIH can occur at any time during treatment.<sup>9</sup>

Whether intensified treatment improves the outcome of TBM is still to be determined. A recent Indonesian adult TBM study reported a 50% reduction in 6-month mortality without any increase in toxicity when high-dose intravenous RMP (13 mg/kg/d) was given for the first 2 weeks of treatment.<sup>10</sup> Our experience is that high oral dose RMP (20 mg/kg/d) for 6–9 months duration is well-tolerated by children.

The rationale for using ETH as 4th drug in the regimen is that it has good CSF penetration (healthy and inflamed meninges) compared with streptomycin (20% in inflamed meninges only) or ethambutol (25–50% in inflamed meninges only).<sup>11</sup> This is important as tuberculomas may occur in the absence of meningeal inflammation. Another advantage is that INH-monoresistant TBM may be overcome when ETH and PZA are used continuously together with RMP for a 6-month period. This was confirmed by a recent study which reported no differences in outcome between children with INH-monoresistant TBM and those with

drug-susceptible TBM.<sup>9</sup> The inclusion of ETH should therefore be considered in areas with high INH monoresistance (> 4% in primary TB cases) or in resource limited settings where drug resistance rates are unknown.<sup>9</sup> Use of ETH is also preferable to the use of an aminoglycoside with poor CSF penetration and considerable risk of hearing loss.<sup>12</sup> The most frequent adverse effect observed during treatment with ETH is nausea and vomiting. Our experience is that almost all children respond favorably to administration of ETH at night separately from the other anti-TB medications. Recent studies found the prevalence of ETH-induced hypothyroidism (20–50%) to be more common than previously recognized in children on second-line anti-TB drugs including ETH.<sup>13,14</sup> Regular screening of thyroid functions is therefore indicated in TBM children on prolonged or high-dose ETH.

Management of TBM in the setting of HIV is complex. Additional treatment considerations for HIV-infected children include the timing of initiation of cART and the potential for drug interactions. The optimal time to initiate cART in children with HIV-associated TBM is unknown.<sup>15</sup> We will usually delay cART by 2–4 weeks to reduce the risk of TB immune reconstitution inflammatory syndrome.<sup>16</sup> Therapy is also prolonged for an additional 3 months in HIV-infected cases because of perceived slower response to treatment. The similar result in outcome between HIV-infected and HIV-uninfected children at completion of treatment can be attributed to the benefits derived from cART and/or longer treatment duration of TBM.

Limitations of the study include the inability to contact the caregivers of the 29 children in the hospital-based treatment group and the fact that it was not a randomized controlled study comparing longer/shorter treatment regimens or home-based versus hospital-based treatment.

We believe that short intensified chemotherapy is sufficient and safe in HIV-infected and HIV-uninfected children with drug-susceptible TBM. Home-based treatment can be recommended for the management of childhood TBM following adequate screening, counseling and support.

## REFERENCES

1. World Health Organization. Rapid advice: treatment of tuberculosis in children. Geneva: World Health Organization; 2010. WHO/HTM/TB/2010.13.
2. Woodfield J, Argent A. Evidence behind the WHO guidelines: hospital care for children: what is the most appropriate anti-microbial treatment for tuberculous meningitis? *J Trop Pediatr*. 2008;54:220–224.
3. Wolzak NK, Cooke ML, Orth H, et al. The changing profile of pediatric meningitis at a referral centre in Cape Town, South Africa. *J Trop Pediatr*. 2012;58:491–495.
4. Schoeman J, Malan G, van Toorn R, et al. Home-based treatment of childhood neurotuberculosis. *J Trop Pediatr*. 2009;55:149–154.
5. Tostmann A, Boeree MJ, Aarnoutse RE, et al. Antituberculosis drug-induced hepatotoxicity: concise up-to-date review. *J Gastroenterol Hepatol*. 2008;23:192–202.
6. Donald PR. The chemotherapy of tuberculous meningitis in children and adults. *Tuberculosis (Edinb)*. 2010;90:375–392.
7. Donald PR. Antituberculosis drug-induced hepatotoxicity in children. *Pediatr Rep*. 2011;3:e16.
8. Schaaf HS, Parkin DP, Seifart HI, et al. Isoniazid pharmacokinetics in children treated for respiratory tuberculosis. *Arch Dis Child*. 2005;90:614–618.
9. Seddon JA, Visser DH, Bartens M, et al. Impact of drug resistance on clinical outcome in children with tuberculous meningitis. *Pediatr Infect Dis J*. 2012;31:711–716.
10. Ruslami R, Ganiem AR, Dian S, et al. Intensified regimen containing rifampicin and moxifloxacin for tuberculous meningitis: an open-label, randomised controlled phase 2 trial. *Lancet Infect Dis*. 2013;13:27–35.
11. Donald PR. Cerebrospinal fluid concentrations of antituberculosis agents in adults and children. *Tuberculosis (Edinb)*. 2010;90:279–292.
12. Seddon JA, Thee S, Jacobs K, et al. Hearing loss in children treated for multidrug-resistant tuberculosis. *J Infect*. 2013;66:320–329.
13. Thee S, Zöllner EW, Willemse M, et al. Abnormal thyroid function tests in children on ethionamide treatment. *Int J Tuberc Lung Dis*. 2011;15:1191–1193.
14. Hallbauer UM, Schaaf HS. Ethionamide-induced hypothyroidism in children. *South Afr J Epidemiol Infect*. 2011; 26:161–163.
15. Marais S, Meintjes G, Pepper DJ, et al. Frequency, severity, and prediction of tuberculous meningitis immune reconstitution inflammatory syndrome. *Clin Infect Dis*. 2013;56:450–460.
16. van Toorn R, Rabie H, Dramowski A, et al. Neurological manifestations of TB-IRIS: a report of 4 children. *Eur J Paediatr Neurol*. 2012;16:676–682.



**Aslınur Ozkaya-Parlakay, MD**Ankara Hematology and Oncology  
Research Hospital**Hasan Tezer, MD**Gazi University  
Pediatric Infectious Disease Department  
Ankara, Turkey

## REFERENCES

1. Enweronu-Laryea CC, Sagoe KW, Mwenda JM, et al. Severe acute rotavirus gastroenteritis in children less than 5 years in southern Ghana: 2006–2011. *Pediatr Infect Dis J*. 2014;33(suppl 1):S9–S13.
2. World population prospects: the 2004 revision. New York: United Nations Population Division, Department of Economic and Social Affairs, 2005. Available at: [http://www.un.org/esa/population/publications/WPP2004/2004Highlights\\_finalrevised.pdf](http://www.un.org/esa/population/publications/WPP2004/2004Highlights_finalrevised.pdf).
3. Parashar UD, Bresee JS, Glass RI. The global burden of diarrhoeal disease in children. *Bull World Health Organ*. 2003;81:236.
4. Gurbuz F, Tezer H, Revide-Sayli T. Etiologic factors and clinical findings of patients hospitalized children for acute gastroenteritis: epidemiologic study. *Turkish J Pediatr Dis*. 2010;4:211–218.
5. Ceyhan M, Alhan E, Salman N, et al. Multicenter prospective study on the burden of rotavirus gastroenteritis in Turkey, 2005–2006: a hospital-based study. *J Infect Dis*. 2009;200(suppl 1):S234–S238.

## OPEN Short Intensified Treatment in Children with Drug-susceptible Tuberculous Meningitis

## To the Editors:

We read with interest the results of the study by van Toorn et al. describing short intensified treatment for children with drug-susceptible tuberculous meningitis (TBM).<sup>1</sup> The paper raises important questions regarding the most appropriate antimicrobial treatment regimen for children with TBM.

The World Health Organization (WHO) recommends giving 2 months of isoniazid, rifampin, pyrazinamide and ethambutol followed by 10 months of isoniazid and rifampin. After meningeal inflammation has subsided, rifampin has poor penetration into the cerebrospinal fluid (CSF)<sup>2</sup> leaving the

child effectively on isoniazid monotherapy for most of their treatment. This can be a problem in areas with high prevalence of isoniazid resistance. In addition, the poor CSF penetration of ethambutol<sup>2</sup> renders its inclusion in the regimen questionable.

The short intensified treatment regimen used in the Western Cape for nearly 2 decades with higher isoniazid and rifampin dosages, longer administration of pyrazinamide and substitution of ethambutol with ethionamide provides higher CSF concentrations of anti-tuberculosis drugs for the entire duration of treatment.<sup>2</sup> It may also overcome isoniazid-monoresistance<sup>3</sup> and children appear to tolerate combination treatment with pyrazinamide better than adults.

Twelve years before the most recent WHO recommendations in 2010, this group published their experience with the same treatment regimen, showing that it was effective and associated with one of the lowest mortality rates reported.<sup>4</sup> It is disappointing that this regimen has not been evaluated further in other centers and that most authorities still recommend only 2 months of intensive treatment.

Despite demonstrating good outcomes and a shorter duration of treatment, the study by van Toorn is observational without a randomized control group for comparison; it thus may provide insufficient evidence to change international policy. In addition, the regimen employs a drug usually reserved for second-line treatment, which could have implications for acceptability by tuberculosis programs. Further, recent WHO dosing recommendations may make it difficult to use the higher dosages described in the study, given the shortage of single drug formulations in many settings.<sup>5</sup>

However, these operational obstacles should not impede the identification of the best possible treatment regimen. An appropriately powered randomized controlled trial to address this question is long overdue. One-hundred eighty-four children with TBM were enrolled in this study from a single center in 4 years; patient numbers, although limited, should not be an impediment to conducting a multicenter trial. Such a trial should compare the standard WHO-recommended regimen with a shortened regimen using drugs with good CSF penetration for the full duration. Consideration should be given to using a fluoroquinolone (levofloxacin or moxifloxacin) instead of ethionamide, as many pediatricians are hesitant to use ethionamide because of its side-effect profile as well as cross-resistance with isoniazid. Particular attention should be paid to using standardized assessments of neurologic outcome and toxicity and the issue of blinding. Until better evidence is provided, children with TBM will continue to be treated with what is likely to be a suboptimal regimen.

**Anna Turkova, MRCPCH**Imperial College Healthcare NHS Trust  
London**James A. Seddon, PhD**Department of Academic Paediatrics  
Imperial College London**Andrew J. Nunn, MSc****Diana M. Gibb, MD****Patrick P.J. Phillips, PhD**MRC Clinical Trials Unit at UCL  
Institute of Clinical Trials and Methodology  
London, United Kingdom  
On behalf of the North London  
TB Journal Club

## REFERENCES

1. van Toorn R, Schaaf HS, Laubscher JA, et al. Short intensified treatment in children with drug-susceptible tuberculous meningitis. *Pediatr Infect Dis J*. 2014;33:248–252.
2. Donald PR. Cerebrospinal fluid concentrations of antituberculosis agents in adults and children. *Tuberculosis (Edinb)*. 2010;90:279–292.
3. Seddon JA, Visser DH, Bartens M, et al. Impact of drug resistance on clinical outcome in children with tuberculous meningitis. *Pediatr Infect Dis J*. 2012;31:711–716.
4. Donald PR, Schoeman JF, Van Zyl LE, et al. Intensive short course chemotherapy in the management of tuberculous meningitis. *Int J Tuberc Lung Dis*. 1998;2:704–711.
5. Detjen A, Macé C, Perrin C, et al. Adoption of revised dosage recommendations for childhood tuberculosis in countries with different childhood tuberculosis burdens. *Public Health Action*. 2012;2:126–132.

## In Reply: Short Intensified Treatment in Children With Drug-Susceptible Tuberculous Meningitis

## Reply:

We agree with the North London TB journal club about the importance of trials that would determine the most appropriate antimicrobial regimen for children with tuberculous meningitis (TBM). The study design advocated by the authors is a randomized controlled trial (RCT) of short intensified versus standard treatment (as advised by the World Health Organization).

Although a RCT would be the preferred study method, a large sample size

The authors have no funding or conflicts of interest to disclose.

Copyright © 2014 by Lippincott Williams & Wilkins. This is an open access article distributed under the Creative Commons Attribution License, which permits unrestricted use, distribution, and reproduction in any medium, provided the original work is properly cited.

ISSN: 0891-3668/14/3309-0993

DOI: 10.1097/INF.0000000000000371

The authors have no funding or conflicts of interest to disclose.

Copyright © 2014 by Lippincott Williams & Wilkins  
ISSN: 0891-3668/14/3309-0993

DOI: 10.1097/INF.0000000000000409

would be required to separate out the effects of combination treatments. Wolbers et al<sup>1</sup> addressed this question by comparing 2 approaches (RCT vs.  $2 \times 2$  factorial design) using a design of a new trial in TBM as an example. In their trial example, the combination of 2 drugs added to standard treatment is assumed to reduce the hazard of death by 30% and the sample size of the combination trial to achieve 80% power was 750 patients. An adequately powered  $2 \times 2$  factorial design (to detect effects of individual drugs) would require at least 8-fold the sample size (6000 patients) of the combination trial.

The short intensified TBM treatment regimen used in the Western Cape for nearly

three decades is associated with a 3.8% mortality rate and a good outcome in greater than 80% of cases. A comparative superiority trial would require an even larger sample size than in the examples above.

Another issue is that of ethics: would it be ethically acceptable for a study site, which has a good outcome and low mortality amongst their TBM cases, to participate in a RCT comparing regimens that may be inferior to what they currently use? We have recently declined participation in a TBM study for this reason. Such a RCT would only be acceptable if another regimen (such as the World Health Organization 12-month regimen) has at least shown similar or better results in other study sites.

**Ronald van Toorn, FCP**

**H. Simon Schaaf, MD**

**Johan F. Schoeman MD**

Department of Pediatrics and Child Health  
Stellenbosch University and Tygerberg  
Children's hospital  
Western Cape, South Africa

#### REFERENCE

1. Wolbers M, Heemskerk D, Chau TT, et al. Sample size requirements for separating out the effects of combination treatments: randomised controlled trials of combination therapy vs. standard treatment compared to factorial designs for patients with tuberculous meningitis. *Trials*. 2011;12:26.




## **Chapter 6**

### **Management of complications of tuberculous meningitis**

- 1. Neurological manifestations of TB-IRIS: A report of 4 children**
- 2. Clinico-radiological response of neurological tuberculous mass lesions in children treated with thalidomide**
- 3. The value of transcranial Doppler imaging in children with tuberculous meningitis**



Official Journal of the European Paediatric Neurology Society



## Original article

## Neurological manifestations of TB-IRIS: A report of 4 children

Ronald van Toorn\*, Helena Rabie, Angela Dramowski, Johan F. Schoeman

Department of Paediatrics and Child Health, Tygerberg Children's Hospital, Faculty of Health Sciences, Stellenbosch University, Francie van Zyl Avenue, Tygerberg 7550, Western Cape, South Africa

## ARTICLE INFO

## Article history:

Received 10 October 2011

Received in revised form

7 February 2012

Accepted 21 April 2012

## Keywords:

Tuberculosis

Immune reconstitution inflammatory syndrome

Human immune deficiency virus

## ABSTRACT

**Introduction:** Tuberculosis-associated immune reconstitution inflammatory syndrome (TB-IRIS) is a potentially life-threatening complication in HIV infected children with tuberculosis (TB) of the central nervous system. HIV-associated TB-IRIS has not been previously described in children with neurotuberculosis.

**Objective:** To describe the neurological and neuro-radiological features of 4 consecutive cases of TB-IRIS in children with neurotuberculosis and to discuss possible management strategies.

**Results:** Three patients treated for tuberculosis of the central nervous system experienced paradoxical worsening of neurological symptoms when combination antiretroviral therapy (cART) was initiated. Intracranial tuberculomas were unmasked in the 4th patient. All patients developed new neurological signs within 10 days of cART initiation. Neurological symptoms and signs included headache, seizures, meningeal irritation, decreased level of consciousness, ataxia and focal motor deficit. Interventions included the temporary discontinuation of cART and the use of corticosteroids in all patients. Three patients received thalidomide and 1 chloroquine and mycophenolate mofetil. One patient died and the others experienced prolonged hospitalization.

**Conclusion:** TB-IRIS should be considered when new neurological signs develop shortly after initiation of cART in children. There is little data to guide the timing of initiation of cART and the management of complications in children.

© 2012 European Paediatric Neurology Society. Published by Elsevier Ltd. All rights reserved.

## 1. Introduction

Tuberculosis (TB) associated immune reconstitution inflammatory syndrome (TB-IRIS) is a potentially life-threatening complication in HIV infected children.

Paradoxical TB-IRIS refers to the development of new or worsening symptoms of TB despite adherence to appropriate TB treatment in a patient who initiated combination antiretroviral therapy (cART). The deterioration usually occurs in

the first 3 months after cART initiation. Unmasking TB-IRIS occurs in patients where cART precedes tuberculosis diagnosis by up to 3 months.<sup>1</sup> In resource-limited settings the diagnosis of TB-IRIS is based on clinical and radiological signs and its temporal relationship to the initiation of cART, no specific diagnostic tests exist for the condition.<sup>2</sup> Neither recovery of CD4 cells or decline in viral load need to be present for diagnosis.<sup>2</sup> Differential diagnosis of TB-IRIS includes drug resistant TB and other potential causes of failure of anti-TB

\* Corresponding author. Tel.: +27 21 938 9113; fax: +27 21 938 4858.

E-mail address: [vtoorn@sun.ac.za](mailto:vtoorn@sun.ac.za) (R. van Toorn).

treatment, other infections, drug toxicity and HIV-related conditions.

Risk factors for paradoxical TB-IRIS are disseminated TB, low CD4 count at initiation of cART, and shorter interval from TB treatment to cART initiation. Only a few case reports and one case series of TB-IRIS of central nervous system have been reported in adults and there are no published descriptions in children.<sup>1,3,4</sup> Neurologic deterioration has been reported in 12% of adult paradoxical TB-IRIS cases, manifestations included radiculomyelopathy, new meningitis or exacerbations of meningitis and or enlarging granulomas.<sup>3,4</sup> In contrast to other forms of paradoxical IRIS the morbidity and mortality is high.

Unmasking TB-IRIS may be difficult to distinguish from incident TB cases but is thought to be associated with increased inflammatory responses. Few cases are clearly described in literature.

The main stay of therapy in TB-IRIS in adults are corticosteroids with interruption of cART reserved for patients with severe life-threatening complications or where the complication can cause disability.<sup>5</sup> It is not clear whether the use of corticosteroids for TB meningitis, the current standard of care, prevents any cases of paradoxical TB-IRIS. Other immunomodulating treatments are only described in case reports with no reports in children. In the present paper we describe our experience of CNS-related TB-IRIS in 4 HIV-infected children.

## 2. Case 1

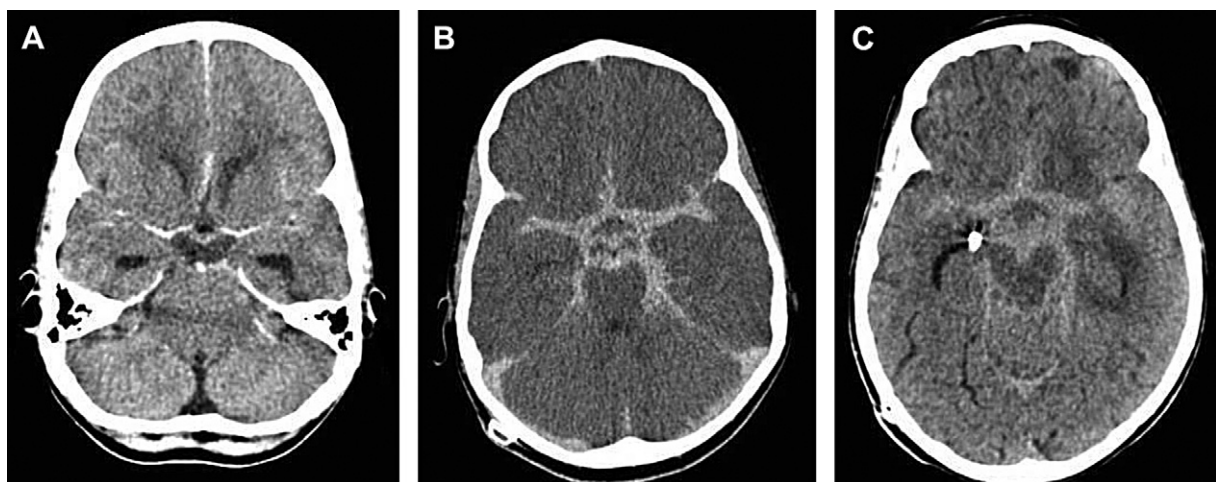
A 10 year old girl presented with a 1 day history of left-sided partial seizures and vomiting. Clinical examination revealed meningism and lethargy (Glasgow Coma Score 14/15). The cerebrospinal fluid (CSF) findings were compatible with TB meningitis and the computerized tomographic (CT) scan of the brain showed mild meningovascular enhancement and communicating hydrocephalus (Fig. 1 A). Chest X ray demonstrated paratracheal lymphadenopathy supportive of

primary pulmonary TB. There was no household TB contact and mantoux skin test proved unreactive. The patient was started on rifampicin 20 mg/kg/day, isoniazid 20 mg/kg/day, pyrazinamide 40 mg/kg/day, ethionamide 20 mg/kg/day and prednisone 2mg/kg/day as well as acetazolamide 50 mg/kg/day and furosemide 1 mg/kg/day. Insertion of a ventriculoperitoneal shunt resulted in improvement of the level of consciousness but the patient remained lethargic and irritable.

The serum Elisa test for HIV was reported as positive with an absolute CD4 positive T-cell count of 55/ $\mu$ L (7%). The patient was started on cART with stavudine, lamivudine and efavirenz three weeks after TB therapy. Seven days later the patient became drowsy and developed temperature spikes. A repeat CT scan showed that the basal meningovascular enhancement had increased from the previous scan (Fig. 1 B). The repeat CD 4 positive T-cell count showed an absolute count of 171/ $\mu$ L (11.7%) Paradoxical TB-IRIS was suspected and the cART was stopped. Over the next 3 days the patient developed severe neck stiffness, ataxia and bilateral upper motor signs. Oral corticosteroids were replaced by high dose intravenous dexamethazone. An uncontrasted CT scan now showed that the basal cisterns were obliterated by granulomatous tissue. In addition, low density changes in the adjacent brain parenchyma and brainstem, indicative of tuberculous borderzone encephalopathy were noted (Fig. 1 C). Adjunctive thalidomide (2 mg/kg/day) were given during the last week of illness but the patient continued to deteriorate and died 2 weeks later.

## 3. Case 2

A 12 year old boy recently diagnosed with HIV infection (absolute CD4 count 274/ $\mu$ L) presented with culture negative TB meningitis. Initial response to anti-TB medication proved favourable and cART consisting of abacavir, lamivudine and efavirenz was introduced after 4 weeks of anti-TB therapy.



**Fig. 1 – A:** Contrasted CT scan on admission showing mild basal meningeal enhancement and obstructive hydrocephalus. **B:** Contrasted CT scan 1 week following initiation of cART. Marked basal meningeal enhancement is present. **C:** Uncontrasted CT scan 1 week after discontinuation of cART. The basal cisterns and Sylvian fissures are filled with dense granulomatous tissue obliterating the CSF spaces.

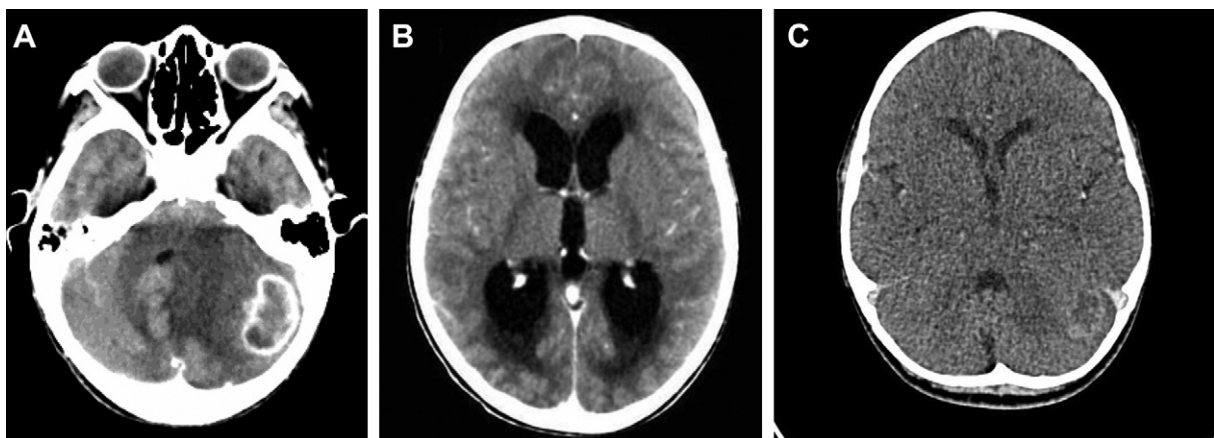
Following 1 week of cART, the patient complained of headache, vomiting and drowsiness. Neurological examination revealed features suggestive of raised intracranial pressure (papilloedema) and cerebellar dysfunction (intention tremor and dysdiadokinesis). Brain CT scan showed a large ring-enhancing lesion in the left cerebellar hemisphere with marked peri-lesional oedema (Fig. 2 A). The morphology of the lesion (isodense intensity with irregular rim enhancement) indicated a tuberculoma rather than a brain abscess. The 4th ventricle was compressed, displaced and obstructive hydrocephalus was present (Fig. 2 B). Unfortunately no imaging was done pre-cART, but the clinical and radiological findings suggested that the tuberculoma and especially the peri-lesional oedema probably increased on cART. A repeat absolute CD4 count after 10 days of antiretroviral treatment was 90  $\mu$ /L (8.3%). cART was stopped and high dose intravenous dexamethasone initiated. In spite of these measures, the patient developed projectile vomiting and an emergency endoscopic third ventriculostomy was required to stabilize the patient. Biopsy of the lesion was not attempted because of the danger of increasing the amount of cerebellar swelling and possible pressure on the brainstem. The patient responded dramatically to surgery and was awake and ambulant one day post-operatively. Oral prednisone 2 mg/kg/day was continued with the anti-TB chemotherapy. A MRI scan 10 days post-surgery and 9 days post-cART interruption showed resolution of the hydrocephalus and marked reduction of the peri-lesional oedema and mass effect in the left cerebellar hemisphere (Fig. 2 C).

Since he remained severely immunosuppressed and at risk of further life-threatening opportunistic infections, it was considered urgent to re-initiate his cART. Repeat MRI a month later demonstrated decreasing mass effect from the tuberculoma and thus re-initiation of cART with the same regimen was attempted. Within 5 days he developed severe CNS IRIS with raised intracranial pressure despite high dose prednisone. He was again treated with intravenous (IV) dexamethasone 0.15 mg/kg/day but his symptoms persisted. Repeat MRI showed increasing mass effect with midline shift and thus cART was again discontinued 6 days after initiation. Despite

the interruption of cART the child had ongoing deterioration of his neurological condition prompting the use of pulse IV methylprednisolone at 10 mg/kg/day for 3 days. No multi-drug resistant (MDR)-tuberculosis source case was ever identified. However, since a CSF TB culture with drug-susceptibility testing (DST) had never been obtained, the possibility of drug resistant TB was considered and therapy was upgraded to a multi-drug resistant (MDR) regimen, with additional amikacin 20 mg/kg/day, ofloxacin 20 mg/kg/day and terizidone 20 mg/kg/day. In view of the failed 2nd attempt at cART initiation due to CNS TB-IRIS, thalidomide 2 mg/kg/day was introduced as an additional anti-inflammatory drug. Unfortunately the patient then developed Stevens Johnson reaction temporally associated with the initiation of the additional MDR-TB drugs and thalidomide which necessitated interruption of all drug therapy for a few days. In addition, he also received intravenous immunoglobulin and his anti-TB therapy was switched back to a drug-sensitive regimen. Immunotherapy consisted of cyclosporin 6 mg/kg/day together with chloroquine 3 mg/kg/day, in addition to the ongoing high dose prednisone 2 mg/kg/day. A third attempt at re-initiation of cART was made 2 weeks later but he again developed symptoms of raised intracranial pressure with severe headache and vomiting after 48 h, and the cART was discontinued. Finally, the introduction of mycophenylate mofetil (MMF) 1200 mg/m<sup>2</sup>/day allowed for the cART resumption without further relapse. Due to repeated therapy interruptions, the cART regime was changed to ABC, 3 TC and Lopinavir/r with additional ritonavir.

#### 4. Case 3

A 14 year old HIV infected female on 2 months of anti-TB therapy for culture negative stage 1 TBM developed fever and left sided weakness within 5 days following the introduction of cART (stavudine, lamivudine, efavirenz). Neurological examination revealed a dense left sided hemiparesis in isolation. Contrasted CT imaging confirmed a right sided basal



**Fig. 2 – A:** Axial CT scan after 5 days of cART showing a large tuberculoma in the left cerebral hemisphere with peri-lesional oedema causing mass effect. Displacement of the 4th ventricle resulted in obstructive hydrocephalus. **B:** Acute obstructive hydrocephalus resulting from obstruction of CSF by tuberculoma in cerebellum. **C:** Contrasted axial CT done 20 days after third ventriculostomy and 26 days after cART was stopped. The IRIS-related findings have markedly improved.



ganglia infarct, with hydrocephalus, basal meningeal enhancement and multiple ring-enhancing lesions predominantly in the medial aspect of the right temporal lobe (Fig. 3 A). A repeat lumbar puncture showed clear CSF, 56 lymphocytes/mm<sup>3</sup>, 19 polymorphs/mm<sup>3</sup>, protein of 1.83 g/L and glucose of 1.2 mmol/L. HIV RNA viral load was 27 copies/ml. The patient was severely immune-compromised with an absolute CD4 count of 61 cells/mm<sup>3</sup> (11.2%). The clinical and CT findings suggested HIV-related tuberculosis IRIS and cART was stopped. Multi-drug resistant tuberculosis was deemed unlikely due to the absence of a MDR source case and since the initial response to TB treatment was favourable. Therapy consisted of ventriculoperitoneal shunt insertion, high dose corticosteroids (2 mg/kg/day) and continuation of the same 4 drug anti-TB regime at a nearby TB hospital.

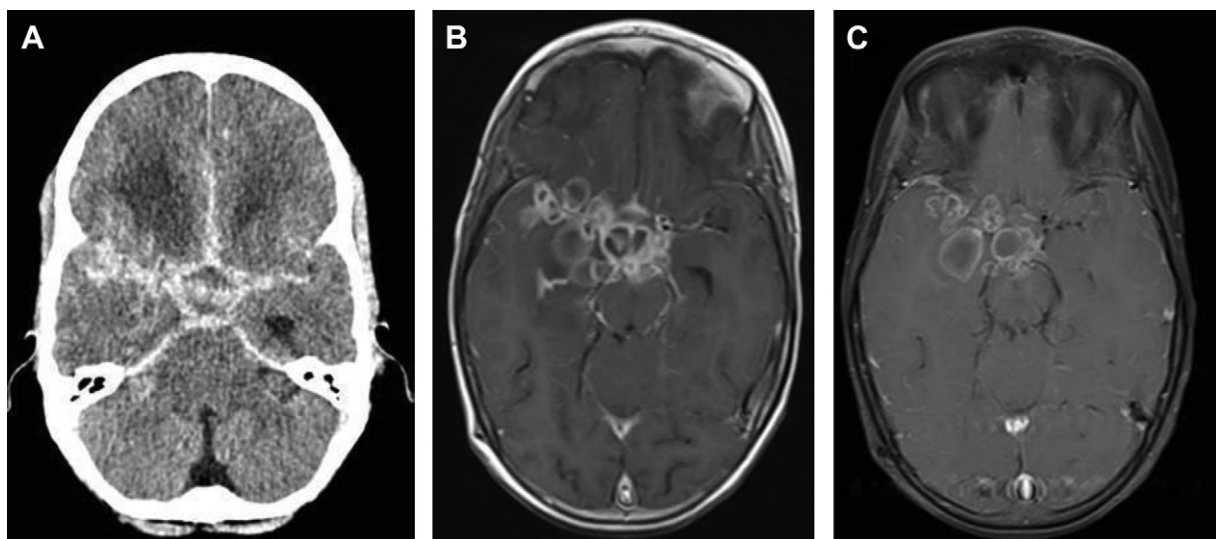
One month later, the child was re-admitted with progressive headaches and irritability. Bilateral horizontal nystagmus, intention tremor and dysidiadokinesis of the left arm were evident on examination in addition to a markedly improved left hemiplegia. CSF analysis once again confirmed a lymphocytic meningitis but with an increased CSF protein (4.8 g/L). Repeat CT showed improvement of the previously reported hydrocephalus, less intense basal meningeal enhancement but more numerous ring-enhancing cystic structures filling the suprasellar, interpeduncular, as well as prepontine and right cerebellar-pontine angle cisterns. MR imaging 2 days later confirmed these lesions as multiple intraparenchymal and subarachnoid TB abscesses (Fig. 3 B). Antituberculosis treatment was empirically expanded with terizidone 20 mg/kg/day, amikacin 20 mg/kg/day, ofloxacin 20 mg/kg/day and ethambutol 20 mg/kg/day. Thalidomide 2 mg/kg/day was added as an additional anti-inflammatory drug.

Clinical review one month later revealed marked improvement of cerebellar function. Two months later, the

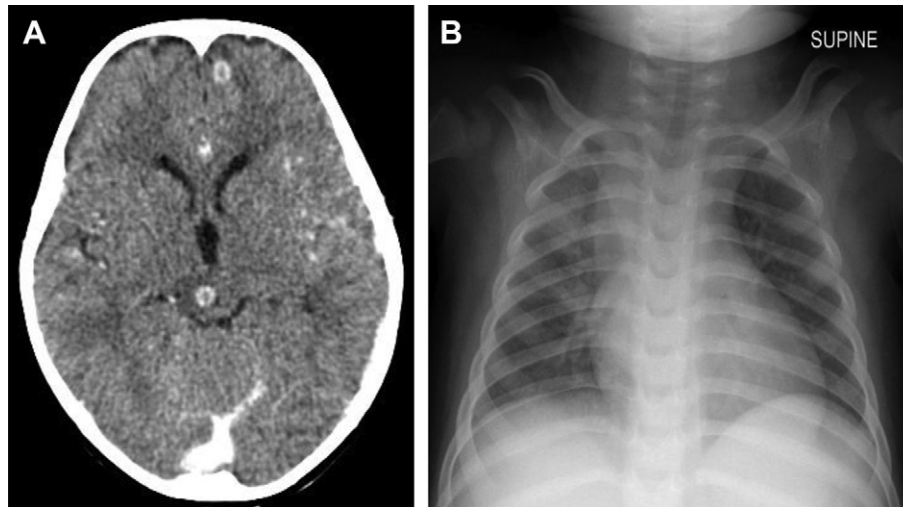
cerebellar signs had completely resolved despite unchanged MR imaging. Three months thereafter, following 6 months of thalidomide (total dosage 18 g); the patient remained asymptomatic with only a mild left sided hemiplegia evident on exercise. Repeat MRI showed decrease in size of all TB abscesses and decreased intensity of the ring-enhancement (Fig. 3 C). Thalidomide was discontinued, whilst the MDR-TB regime was continued for another 6 months. (TB was never cultured). The patient remains clinically well.

## 5. Case 4

A 21 month old girl presented with an unprovoked right-sided seizure lasting 10 min. She was known to be HIV-infected and cART was interrupted due to prolonged poor adherence. She had an undocumented TB contact during this time for which no preventative therapy was given. cART was reinitiated 3 weeks prior to her current presentation. On examination she was afebrile, well-nourished and not acutely ill. Her neurological examination proved normal. Chest radiography demonstrated pulmonary hilar and subcarinal lymphadenopathy (chest radiograph 3 weeks ago was normal) and the Mantoux skin test was strongly reactive (>20 mm). Lumbar puncture showed a clear and colourless CSF with a lymphocyte count of 382/mm<sup>3</sup>, protein of 0.95 g/L and glucose of 4.1 mmol/L (blood glucose was not done at the time of the lumbar puncture). No organisms were seen on microscopy or cultured. CT brain showed multiple ring-enhancing lesions with surrounding oedema bilaterally in the frontal-, temporal-, occipital and cerebellar areas (Fig. 4 (A) and (B)). A single lesion was present in the posterior midbrain. No basal enhancement or hydrocephalus could be demonstrated. An absolute CD4 positive T-cell count 10 days before presentation (about 10 days after cART was reintroduced) was 1496  $\mu$ /L (33%). The clinical and radiological features



**Fig. 3 – A:** Initial contrasted CT imaging showing hydrocephalus with transependymal fluid shift, a right sided basal ganglia infarct, significant basal meningeal enhancement and multiple ring-enhancing lesions predominantly in the medial aspect of the right temporal lobe. **B:** MR imaging after 4 weeks showing multiple intraparenchymal and subarachnoid TB abscesses. **C:** Repeat MRI 3 months later showing decrease in size of all TB abscesses and decreased intensity of the ring-enhancement.



**Fig. 4 – A: CT scan of the brain showing multiple tuberculomas, unmasked after 1 week of cART. B: Chest radiograph showing concomitant IRIS-related hilar and subcarinal lymphadenopathy.**

were consistent with a diagnosis of multiple intracranial tuberculomas which became symptomatic (unmasked) as a result of TB-IRIS. cART was discontinued and 4 drug anti-TB treatment and prednisone (2 mg/kg/day) was started. The patient responded well to this treatment and no further seizures or neurological deterioration was noted.

## 6. Discussion

TB is a common infection in HIV-infected African children with rates of 53.3 cases/100 patient-years reported in children not on cART.<sup>6</sup> The overall incidence of CNS TB-IRIS in children is unknown. A study amongst adults from Cape Town found that neurological TB-IRIS accounts for more than 10% of paradoxical TB-IRIS cases in a hospital setting.<sup>1</sup> The study reported a mortality rate between 13 and 30%. No data exists on the mortality rate of CNS TB-IRIS in children. A previously conducted study from the Western Cape reported a mortality of 23.5% in children with HIV-associated TBM without IRIS<sup>7</sup> who were not treated with cART. The authors documented full recovery in 10/34 in HIV-infected versus 33/55 in uninfected children (OR 0.28, 95% CI 0.11–0.69).

The immunopathogenesis of TB-IRIS remains poorly understood. Recent studies suggest that cytokine release contributes to the pathology in TB-IRIS.<sup>8,9</sup> Tadokera et al reported higher concentrations of tumour necrosis factor alpha (TNF $\alpha$ ), interleukin 6 (IL6) and interferon gamma (IFN  $\gamma$ ) in TB-IRIS patients.<sup>9</sup> Corticosteroid therapy resulted in decreased IL6 and TNF levels. Specific blockade of selected cytokines may thus be a rational approach to immunomodulation in TB-IRIS. Studies are still pending to determine whether inflammatory biomarkers are useful in predicting or diagnosing IRIS. Risk factors for TB-IRIS include starting cART within 6 weeks of TB treatment; disseminated extra pulmonary disease, low baseline CD 4 count, rise in CD4%; fall in viral load and high bacillary burden.<sup>10,11</sup> Viral load reduction has been associated with IRIS but is not always present.

Paradoxical IRIS usually occurs soon after start of cART, in both adults and children.<sup>12</sup> All 3 study children with paradoxical CNS TB-IRIS became symptomatic within 7 days of cART initiation. In case 4, unmasking TB-IRIS occurred within 10 days of cART initiation. CNS TB-IRIS may also occur in HIV uninfected patients but tend to occur later with paradoxical enlargement of tuberculomas most commonly occurring after 2–3 months on therapy.<sup>13</sup> All three children who developed paradoxical TB-IRIS suffered from severe immunodeficiency at the time of diagnosis (Table 1) In contrast, case 4 (the child with unmasking TB-IRIS) was not significantly immunodeficient. However this child was probably recently infected by a smear positive contact therefore at high risk for disease. In this case the unmasking of tuberculosis may have occurred whilst incident disease was in the process of developing.

In all our cases the diagnosis of IRIS was made on the basis of new clinical signs in proximity of the initiation of cART.

Case 4 had a positive tuberculin skin test (TST); however up to 60% of children with confirmed TBM diseases have positive TST. TST conversion is a potential diagnostic tool in TB-IRIS. However the use of TST to identify persons at risk has not been studied.

Clinical diagnosis of TB-IRIS remains the gold standard in poor resource settings.<sup>2</sup> Criteria required for diagnosis include (1) Diagnosis of neurotuberculosis with initial response to anti-tuberculosis treatment (2) the recurrence/new onset of tuberculosis disease manifestations within 24 weeks of anti-tuberculosis treatment, and (3) exclusion of alternative explanations for clinical deterioration (such as anti-tuberculosis drug resistance, poor adherence, drug toxicity or reaction, or an additional infection).

Manifestations of TB-IRIS at other organ sites also support a diagnosis of CNS TB-IRIS. These include fever, concomitant transient worsening of chest radiographs (new pulmonary infiltrates, mediastinal lymphadenopathy) especially if old radiographs are available for comparison. This is evidenced in case 4 with unmasking TB-IRIS whose chest radiograph changed from normal (3 weeks prior) to showing mediastinal



**Table 1 – Demographic characteristics, HIV-1 data, neurological and MRI manifestations in 4 children with CNS TB-IRIS.**

Pt	Age & Gender	Type of TB-IRIS	Baseline CD4+ count	CD4+ count (cell/ul) and percentage at diagnosis of IRIS	Duration from TB treatment to cART, weeks	Duration from cART to TB IRIS, days	Neurological symptoms and signs of IRIS	CT/MRI findings of IRIS	Immune modulation agents used.	Outcome
1	10 years F	Paradoxical TBM	55 (7%)	171 (11.7%)	3	7 days	Decreased LOC, neck stiffness, ataxia, bilateral UMN signs	Increased basal cistern and meningovascular enhancement	Corticosteroids Thalidomide	Death
2	12 years M	Paradoxical TBM	274 (8%)	90 (8.3%)	4	6 days	Headache, vomiting, papilloedema, decreased LOC, neck stiffness, ataxia	Cerebellar tuberculoma causing obstructive hydrocephalus	Thalidomide Cyclosporin Chloroquine Mycophenylate mofetil	Normal
3	14 years M	Paradoxical TBM	Not done	61 (11.2%)	8	5 days	Headache, left-sided hemiplegia. One month later nystagmus and intention tremor.	Hydrocephalus, basal ganglia infarct, multi-loculated abscess	Corticosteroids Thalidomide	Mild left sided hemiplegia
4	19 months F	Unmasking of tuberculomas	Not done	1496 (33%)	N/A	10 days	Focal seizure.	Multiple tuberculomas	Corticosteroids	Normal

CNS: central nervous system; ATB: tuberculosis; HIV-1: human immunodeficiency type 1; IRIS: immune reconstitution inflammatory syndrome; LOC: level of consciousness; UMN: upper motor neuron.

lymphadenopathy during the appearance of neurological symptoms (Fig. 4 c) The diagnosis of TBM is often “probable” as is illustrated by the initial negative CSF cultures in all 3 cases with paradoxical TB-IRIS. This paucity of positive culture complicates exclusion of multi-drug resistant tuberculosis. Though previous studies report that microbiological TB cultures are often negative in patients with paradoxical TB-IRIS<sup>1</sup>; all attempts should be made to isolate the organism to ensure effective antimicrobial therapy.

Antiretroviral therapy is recommended for all HIV infected children diagnosed with CNS TB. There are no randomized studies to guide optimal timing of therapy initiation. Retrospective reviews suggest that waiting 30–60 days may be safe, but such data should be interpreted with caution.<sup>14</sup> The optimal time to initiate cART in children with HIV-associated TB meningitis is unknown. Strategy trials examining the optimum timing of cART in adults with mostly pulmonary TB report benefit from early cART especially if the CD4 count is less than 50 cells mm<sup>3</sup>.<sup>15</sup> A recent randomized double blind placebo-controlled trial of immediate versus deferred cART in adult Vietnamese patients with TBM showed that HIV-associated TB meningitis in the study population had such a poor prognosis that the timing of cART made no appreciable difference regarding survival probability.<sup>16</sup> Early initiation was not associated with an increased risk of CNS TB-IRIS. Adverse events were common in both groups; however the prevalence of hepatitis was higher in the early therapy group. The authors comment that the concomitant use of oral steroids may have reduced the risk for IRIS in these patients. In our 3 children with paradoxical IRIS, steroids did not prevent deterioration, but we have no comparative group.

With regards to therapy for patients experiencing IRIS, a randomized placebo-controlled trial of prednisone for paradoxical tuberculosis-associated IRIS reported faster recovery and reduced need for hospitalization.<sup>5</sup> The study excluded patients suffering life-threatening TB-IRIS, including those with CNS TB-IRIS.

Thalidomide has powerful anti-inflammatory properties and mediates its action by selectively inhibiting TNF $\alpha$  secretion by monocytes and macrophages. The routine use of adjunctive high dose thalidomide is not advocated in children with TB meningitis as a randomized study had to be terminated early because of adverse events.<sup>17</sup> More recently, low dose (5mg/kg/day) thalidomide has been shown to enhance the resolution of chronic tuberculous mass lesions (abscesses and tuberculomas) and optochiasmatic arachnoiditis.<sup>18,19</sup> Thalidomide failed to halt the progressive tuberculous meningeal inflammation in case 1. In case 2, thalidomide was temporally related to an episode of Steven's Johnson syndrome and had to be withdrawn. Adjunctive thalidomide therapy hastened resolution of the tuberculous abscesses in case 3. The rationale for the use of mycophenolate mofetil in case 2 was that mycophenolic acid selectively inhibits the synthesis of guanosine nucleotides in lymphocytes resulting in inhibition of activated T-cell proliferation.<sup>20</sup> This may have allowed re-introduction of cART without further complications. Mycophenolic acid is also a potent inhibitor of the expression of TNF alpha and tumour necrosis factor-receptor superfamily costimulatory molecules.<sup>21</sup>

Ideally, cART should be continued in children suffering mild manifestations of TB-IRIS rather than risk the interruption of treatment. In life-threatening cases, interruption of cART is unavoidable and safer. Life-threatening neurological symptoms necessitated interruption of cART in all three study cases with paradoxical TB-IRIS.

## 7. Conclusion

As the availability of cART increases in resource poor countries with high TB burdens, the incidence of CNS TB-IRIS is likely to increase. Studies are warranted to determine the optimal time of cART initiation in HIV infected children with neurotuberculosis. The extrapolation of adult data that support therapeutic delay may not always be appropriate in young children who experience higher mortality in the absence of cART.

## REFERENCES

1. Pepper DJ, Marais S, Maartens G, et al. Neurologic manifestations of paradoxical tuberculosis-associated immune reconstitution inflammatory syndrome: a case series. *Clin Infect Dis* 2009 Jun 1;48(11):e96–107.
2. Meintjes G, Lawn SD, Scano F, et al. Tuberculosis-associated immune reconstitution inflammatory syndrome: case definitions for use in resource-limited settings. *Lancet Infect Dis* 2008;(8):516–23.
3. Dautremere J, Pacanowski J, Girard PM, et al. A presentation of immune reconstitution inflammatory syndrome followed by a severe paradoxical reaction in an HIV-1-infected patient with tuberculous meningitis. *AIDS* 2007 Jan 30;21(3):381–2.
4. Lee CH, Lui CC, Liu JW. Immune reconstitution syndrome in a patient with AIDS with paradoxically deteriorating brain tuberculoma. *AIDS Patient Care STDS* 2007 Apr;21(4):234–9.
5. Meintjes G, Wilkinson RJ, Morroni C, et al. Randomized placebo-controlled trial of prednisone for paradoxical tuberculosis-associated immune reconstitution inflammatory syndrome. *AIDS* 2010;24(15):2381–90.
6. Walters E, Cotton MF, Rabie H, Schaaf HS, Walters LO, Marais BJ. Clinical presentation and outcome of tuberculosis in human immunodeficiency virus infected children on antiretroviral therapy. *BMC Pediatr* 2008;1(11):1.
7. van der Weert EM, Hartgers NM, Schaaf SH, et al. Comparison of diagnostic criteria of tuberculous meningitis in human immunodeficiency virus-infected and uninfected children. *PIDJ* 2006;25(1):65–9.
8. Sereti I, Rodger AJ, French MA. Biomarkers in immune reconstitution inflammatory syndrome: signals from pathogenesis. *Curr Opin HIV AIDS* 2010;5(6):504–10.
9. Tadokera R, Meintjes G, Skolimowska KH, Wilkonson KA, et al. Hypercytokinaemia accompanies HIV-tuberculosis immune reconstitution inflammatory syndrome. *Eur Respir J* 2011;37(5):1248–59.
10. Murdoch DM, Venter WDF, Feldman C, van Rie A. Incidence and risk factors for immune reconstitution inflammatory syndrome in HIV patients in South Africa: a prospective study. *AIDS* 2008;22:601–10.
11. Shelburne SA, Visnegarwala F, Darcourt J, et al. Incidence and risk factors for immune reconstitution inflammatory syndrome during highly active antiretroviral therapy. *AIDS* 2005;19:399–406.
12. Asselman V, Thienemann F. Central nervous system disorders after starting ART in South Africa. *AIDS* 2010;24(18):2871–6.
13. Afghani B, Lieberman JM. Paradoxical enlargement or development of intracranial tuberculomas during therapy: case report and review. *Clin Infect Dis* 1994;19(6):1092–9.
14. Abdool Karim SS, Naidoo K, Grobler A. Timing of initiation of antiretroviral drugs during tuberculous therapy. *N Engl J Med* 2010;362:697–706.
15. Torok ME, Yen NT, Chau TT, et al. Timing of initiation of antiretroviral therapy in human immunodeficiency virus-associated tuberculous meningitis. *Clin Infect Dis* 2011;52(11):1374–83.
16. Lawn SD, Wood R. Poor prognosis of HIV-associated Tuberculous meningitis regardless of timing of antiretroviral therapy. *CID* 2011;52(11):1384–7.
17. Schoeman JF, Springer P, van Rensburg AJ, et al. Adjunctive thalidomide therapy for childhood tuberculous meningitis: results of a randomized study. *J Child Neurol* 2004;19(4):250–7.
18. Schoeman JF, Andronikou S, Stefan DC, et al. Tuberculous meningitis-related optic neuritis: recovery of vision with thalidomide in 4 consecutive cases. *J Child Neurol* 2010;25(7):822–8.
19. Schoeman JF, Ravenscroft A, Hartzenberg HB. Possible role of adjunctive thalidomide therapy in the resolution of a massive intracranial tuberculous abscess. *Childs Nerv Syst* 2001;17(6):370–1.
20. Garcia F, Plana M, Ardeco M, et al. Effect of Mycophenolate Mofetil on immune response and plasma and lymphatic tissue viral load during and after interruption of highly active antiretroviral therapy for patients with chronic HIV infection: a randomized pilot study. *J Acquir Immune Defic Syndr* 2004;36(3):823–30.
21. van Rijen MM, Metselaar HJ, Hommes M, Ijzermans JN, et al. Mycophenolic acid is a potent inhibitor of the expression of tumour necrosis factor and tumour necrosis factor-receptor superfamily costimulatory molecules. *Immunology* 2003;109(1):109–16.

# Clinicoradiologic Response of Neurologic Tuberculous Mass Lesions in Children Treated With Thalidomide

Ronald van Toorn, FCP,\* Anne-Marie du Plessis, FCRad,† Hendrik Simon Schaaf, MD,\* Heliose Buys, FCP,‡  
Richard H. Hewlett, PhD,§ and Johan F. Schoeman, MD\*

**Abstract:** Neurologic tuberculous pseudoabscesses that clinically progress despite conventional antituberculosis therapy may be responsive to adjuvant thalidomide, a potent tumor necrosis factor- $\alpha$  inhibitor. In this study, the addition of thalidomide provided substantial clinical benefit in the majority of patients, and magnetic resonance imaging evolution of lesions from early-stage “T2 bright” with edema to “T2 black” represented a marker of cure.

**Key Words:** tuberculous meningitis, tuberculous pseudoabscess, thalidomide, tumor necrosis factor- $\alpha$

(*Pediatr Infect Dis J* 2015;34:214–218)

Neurologic tuberculous granulomas (tuberculomas) displaying evidence of liquefactive necrosis, that is, tuberculosis (TB) pseudoabscesses, identified on account of marked computed tomography central hypointensity and magnetic resonance (MR) T2-weighted hyperintensity, are known to develop or enlarge despite appropriate antituberculosis (anti-TB) treatment. This form of TB, assumed to be associated with immune reconstitution inflammatory syndrome (IRIS), is often more severe in the setting of HIV coinfection and can be life threatening.<sup>1</sup> It typically occurs within the first 3 months of anti-TB therapy.<sup>1</sup>

Clinical manifestations depend on the size and location of the lesion(s) and include focal neurologic signs, ataxia, spastic paraplegia and raised intracranial pressure due to cerebrospinal fluid obstruction.<sup>1</sup> Most TB granulomas will resolve during anti-TB treatment and corticosteroids, and duration of therapy is guided by clinicoradiologic response. In contrast, TB pseudoabscesses tend to have a more accelerated clinical course and are unresponsive to standard therapy. Drainage and excision may offer the only chance of cure,<sup>2</sup> but lesion location within the basal cisterns and inadequate neurosurgical facilities usually combine to preclude surgical management. In our experience, TB pseudoabscesses respond to thalidomide, a potent tumor necrosis factor (TNF)- $\alpha$  inhibitor.<sup>3</sup>

## PATIENTS AND METHODS

Tygerberg Children's Hospital in the Western Cape province, South Africa, provides specialized care to half of the province's 1.2 million children. All children (aged 0–14 years) with neurological TB mass lesions (including both tuberculomas and TB pseudoabscesses) presenting from January 2011 through January 2014 who were treated with thalidomide were included in a prospective observational study.

At Tygerberg Children's Hospital, children with TB meningitis (TBM) are treated with isoniazid (20 mg/kg, maximum 400 mg daily), rifampin (20 mg/kg, maximum 600 mg daily), pyrazinamide (40 mg/kg, maximum 2 g daily) and ethionamide (20 mg/kg, maximum 750 mg daily) for 6 months.<sup>4</sup> Treatment is prolonged to 9 months in cases with HIV coinfection and isoniazid monoresistance. In children with TB mass lesions, duration of treatment is determined by clinicoradiologic response. Corticosteroids (prednisone 2 mg/kg, maximum 60 mg daily) are prescribed for the first 4 weeks of therapy in all children with suspected TBM. HIV testing is routinely done on all children with suspected TB following informed consent from the parent or legal guardian.

Standard practice at our hospital is to prescribe 3–5 mg/kg/d of thalidomide (50-mg or 100-mg capsules, Thalidomide Celgene; Celgene Europe Limited, Stokely, London) to all children who develop life-threatening TB mass lesions and TB-related optochiasmatic arachnoiditis despite anti-TB treatment and corticosteroids. Thalidomide, an unregistered drug in South Africa, is supplied under section 21 from the South African Medicines Control Council. Informed consent to use it was obtained from the parents/legal guardians and Tygerberg Hospital Drug-and-Therapeutics Committee. Nerve conduction studies were performed in all children when the cumulative drug dose exceeded 20 g.

1.5T MR imaging was used for the routine examination of T2 weighted imaging, fluid attenuation inversion recovery (FLAIR) and T1 weighted imaging without and with contrast, with identical fields of view. In all children compromised by neurologic TB mass lesions, MR imaging is performed at 3 monthly intervals or earlier when clinically indicated. The study was approved by the Health Research Ethics Committee of Stellenbosch University (N12/07/041).

## RESULTS

The median age of the 16 consecutive children studied was 39 months (range, 8–168 months); 8 (50%) were female and 4 (25%) were HIV-infected children. No parent/legal guardian refused thalidomide treatment. Table 1 illustrates patient demographics, duration of anti-TB therapy until occurrence of neurological TB mass lesions, site of the lesions, clinical presentation, thalidomide dosages, *Mycobacterium tuberculosis* culture results, duration of TB therapy and outcome of the 4 HIV-infected children treated for neurologic tuberculous mass lesions. Table 2 illustrates the same information in the 12 HIV-uninfected children. The mean duration for development of the TB mass lesion (paradoxical

Accepted for publication July 29, 2014.

From the \*Department of Paediatrics and Child Health, Stellenbosch University and Tygerberg Children's Hospital; †Division of Radiodiagnosis, Stellenbosch University and Tygerberg Hospital; ‡Department of Paediatrics, New-Somerset Hospital; and §Department of neuropathology, University of Cape Town, Cape Town, South Africa.

H.S.S. received financial support from South African National Research Foundation.

The authors have no other funding or conflicts of interest to disclose.

Address for correspondence: Ronald van Toorn, FCP, Department of Paediatrics and Child Health, Stellenbosch University, Tygerberg Children's Hospital, Tygerberg, 7505, Western Cape, South Africa. E-mail: [vtoorn@sun.ac.za](mailto:vtoorn@sun.ac.za).

Supplemental digital content is available for this article. Direct URL citations appear in the printed text and are provided in the HTML and PDF versions of this article on the journal's website ([www.pidj.com](http://www.pidj.com)).

Copyright © 2014 by Wolters Kluwer Health, Inc. All rights reserved.

ISSN: 0891-3668/15/3402-0214

DOI: 10.1097/INF.0000000000000539

**TABLE 1.** Demographic Data, Clinical Data, Thalidomide Treatment and Response to Treatment of 4 HIV-infected Children Treated for Neurologic Tuberculous Mass Lesions

Case Number	Age (Months)	Sex	Duration on Anti-TB Rx and ART Before IRIS	Lesion Site	Clinical Presentation	Thalidomide Dose, Treatment Duration and Cumulative Dose	Clinical Response	Duration of TB Rx	Outcome
1	120	Female	3 weeks Not yet on ART	R parietal lobe	Headache L hemiparesis	4 mg/kg/d for 2 months (3 g)	Gradual improvement of headaches; then developed symptoms of impending herniation that required surgical drainage of TB abscess	9 months Culture-negative TB	Full recovery Remains asymptomatic 3 months after completion of TB therapy
3	96	Male	2 months ART 6 weeks	Frontoparietal cortex	Epilepsia partialis continua R hemiparesis	4.8 mg/kg/d for 5 months (7.5 g)	EPC resolved within 2 weeks	18 months (pre-XDR TB INH, rifampin and ofloxacin resistant)	Mild R hemiplegia Still on anti-TB therapy
4	168	Male	2 months ART 2 months	Suprasellar fossa Temporal lobe Cerebellum	L hemiplegia Cerebellar dysfunction	4 mg/kg/d for 6 months (18 g) 2 mg/kg/d for past 4 months (6 g)	Ataxia resolved within 2 months Developed new TB abscesses 21 months after treatment completion with visual impairment	18 months + 9 months (MDR regimen × 2) Culture-negative TB	Mild L hemiplegia Visual impairment Endocrine dysfunction Requires thyroxine and growth hormone replacement Still on thalidomide and MDR anti-TB therapy
11	144	Male	2 months ART 4 weeks	Cerebellum	L cerebellar signs	3.3 mg/kg/d for 6 months (18 g)	Ataxia resolved within 2 months	18 months (MDR regimen) Culture-negative TB	Full recovery Remains asymptomatic 14 months after completion of TB therapy

ART indicates antiretroviral therapy; EPC, epilepsy partialis continua; INH, isoniazid; L, left sided; R, right sided; XDR, extensively drug-resistant.

**TABLE 2.** Demographic Data, Clinical Data, Thalidomide Treatment and Response to Treatment of 12 HIV-uninfected Children Treated for Neurologic Tuberculous Mass Lesions

Case Number	Age (Months)	Sex	Duration on Anti-TB Rx Before IRIS	Lesion Site	Clinical Presentation	Thalidomide Dose, Treatment Duration and Cumulative Dose	Clinical Response	Duration of TB Rx	Outcome
2	64	Male	3 months	R occipitoparietal hemisphere	Loss of consciousness Dense L hemiplegia R gaze palsy	3 mg/kg/d for 3 months (9 g)	Rapid improvement of consciousness and gaze palsy	9 months DS-TB	Still on anti-TB Rx Moderate L hemiplegia
5	24	Male	6 weeks	Optic chiasm Suprasellar fossa Brainstem	Asymmetrical quadriparesis Blindness	3.2 mg/kg/d for 3 months (4.5 g) 5 mg/kg/d for 9 months (27 g)	Vision improved to 6/12 within 1 month of therapy. New TB abscesses developed 6 months after completion of drug-susceptible therapy	21 months (15 months on MDR regimen) Culture-negative TB	Died
6	26	Female	4 months	Suprasellar fossa	Bilateral abducens palsies Diabetes insipidus Hypothyroidism	4.3 mg/kg/d for 7 months (10.5 g)	Abducens palsies resolved within 2 weeks	18 months INH-resistant TB	Asymptomatic Endocrine dysfunction Desmopressin acetate and thyroxine replacement therapy
7	48	Female	5 months	Spinal cord Suprasellar fossa	Spastic paraplegia	3.2 mg/kg/d for 6 months (9 g)	Lower limb power improved to 3/5 after 3 months and 4/5 after 6 months of thalidomide	9 months DS-TB	Full recovery Remains asymptomatic 2 years after completion of anti-TB Rx
8	30	Female	On admission	Periventricular white matter	Loss of consciousness Communicating hydrocephalus	4.1 mg/kg/d for 5 months (7.5 g)	Normal level of consciousness within 1 week	15 months INH-resistant TB	Full recovery Remains asymptomatic 2 years after completion of TB Rx
9	27	Male	11 days	Basal ganglia Periventricular white matter	L hemiparesis	3.5 mg/kg/d for 3 months (4.5 g)	Left hemiplegia improved from moderate to mild after 1 month	18 months (MDR regimen) Culture-negative TB	Full recovery Remains asymptomatic 2 years after completion of TB Rx
10	84	Female	3 months	Suprasellar fossa Brainstem	R cerebellar signs	5 mg/kg/d for 8 months (24 g)	Ataxia resolved within 2 months	18 months (MDR regimen) Culture-negative TB	Full recovery Remains asymptomatic 18 months after completion of TB Rx
12	26	Male	3 months	Brainstem	R oculomotor palsy	3.2 mg/kg/d for 3 months (4.5 g)	Oculomotor palsy resolved after 2 weeks	6 months DS-TB	Full recovery Remains asymptomatic 2 years after completion of TB Rx
13	72	Female	4 months	Cerebellum	Ataxia Headache	4.1 mg/kg/d for 9 months (27 g)	Cerebellar signs gradually resolved over 5 months	12 months Culture-negative TB	Full recovery Remains asymptomatic 2 years after completion of Rx
14	8	Male	5 weeks	Suprasellar fossa Spinal cord and brainstem	Spastic paraplegia	3.2 mg/kg/d for 9 months (13.5 g)	Gradual improvement in lower limb function; able to walk after 6 months	15 months DS-TB	Full recovery Remains asymptomatic 2 years after completion of TB RX
15	12	Female	4 months	Temporal lobe	Headaches Raised ICP EPC	4.5 mg/kg/d for 2 months (3 g)	EPC resolved within 2 weeks	6 months DS-TB	Full recovery Remains asymptomatic 1 year after completion of TB Rx
16	48	Female	4 months	Suprasellar fossa L temporal lobe	Right hemiparesis	2.2 mg/kg/d for 5 months (7.5 g)	Hemiparesis resolved within 4 weeks	9 months DS-TB	Full recovery Remains asymptomatic 6 months after completion of TB Rx

DS-TB indicates drug-susceptible tuberculosis; EPC, epilepsy partialis; ICP, intracranial pressure; INH, isoniazid; Rx, treatment.



TB-IRIS) after initiation of anti-TB treatment was 3 months (range, 0–5 months). HIV-related paradoxical TB-IRIS occurred within 8 weeks of antiretroviral therapy initiation in all of the HIV-infected children.<sup>5</sup>

The most common lesion sites demonstrated by neuroradiology were suprasellar cisternal ( $n = 7$ ), followed by brainstem ( $n = 4$ ), temporal lobe ( $n = 3$ ), cerebellum ( $n = 3$ ) and spinal cord ( $n = 2$ ). Three of the 16 children presented with convexity disease (large dural-based lesions) without radiologic evidence of basal meningeal disease (cases 1–3).

The median thalidomide dose was 3.8 mg/kg/d (range, 2.2–5.0 mg/kg/d), the median duration of administration was 6 months (range, 2–12 months) and median cumulative dose was 9 g (range, 3–31.5 g). Nerve conduction studies proved normal in the 4 children when the cumulative thalidomide dose exceeded 20 g. None of the study children experienced rashes, hepatitis or hematologic derangements or complained of leg cramps. The median duration of anti-TB treatment was 15 months (range, 6–27 months). Nine of the 16 cases (56%) had culture-confirmed TB; 6 children had drug-susceptible TB, 2 had isoniazid monoresistant TB and 1 child had multidrug-resistant (MDR)-TB (resistance to isoniazid and rifampin) (case 3). Four children were treated as MDR-TB without culture confirmation due to deterioration on first-line drugs.

Thirteen children (81%) made a complete recovery, but 1 virally suppressed HIV-infected child had reactivation of disease 14 months after completing 18 months of MDR-TB treatment and is again on treatment (case 4). Two children (13%) are still on treatment and doing well, and 1 child died (case 5). Following introduction of thalidomide, there was cessation of TB mass lesion-associated epilepsy partialis continua within 2 weeks of therapy in both cases, resolution of ataxia within 4 weeks and restoration of walking in previously paraplegic children after 6 months. Of the 5 children who presented with hemiplegia, 3 recovered fully while 2 children have a remaining mild motor deficit. One HIV-uninfected child died (case 5): this child presented with blindness, initially had clinical and radiologic improvement, but then progressed to florid TB-IRIS-related basal enhancement (MR T1+C) with brainstem signal alteration consistent with ischemia. Two children with extensive suprasellar granulomatous inflammation developed hypopituitarism, which necessitated growth hormone and thyroxine replacement therapy (cases 4 and 6).

Despite thalidomide, 2 HIV-infected children developed further paradoxical enlargement of pseudoabscesses, requiring surgical drainage during treatment (cases 1 and 3). In one of the children, enlargement of a right-sided parietal lobe pseudoabscess (central T2 hyperintensity, ring enhancement) resulted in obstructive hydrocephalus (case 1). This occurred after 4 weeks of anti-TB treatment and thalidomide with rapid clinical improvement following drainage. The fluid exudate from this lesion contained no visible organisms or neutrophils and was culture-negative and polymerase chain reaction-negative for *M. tuberculosis* (Xpert MTB/RIF; Cepheid, Sunnyvale, CA). In another HIV-infected patient, progression of a large dural-based TB mass lesion necessitating surgical drainage occurred despite 9 months of MDR-TB treatment, 3 months of thalidomide and 4 months of mycophenolate mofetil, another anti-inflammatory drug (case 3). The aspirate contained moderate numbers of TB bacilli but was culture negative. This child had failed MDR-TB treatment, becoming again *M. tuberculosis* culture positive on sputum specimen after being culture negative for 8 months; the drug-susceptibility test result showed additional resistance to ofloxacin. His anti-TB treatment regimen was changed, his sputum became culture negative (now >15 months culture negative), and he is still on treatment.

In all children, clinical improvement followed a reduction in perilesional edema and preceded regression in lesion size on MR imaging (see Figs., Supplemental Digital Content 1–4, <http://links.lww.com/INF/C10>).

MR imaging revealed mass lesions in different locations, as well as displaying different signal intensities on the T2WI. In the majority of cases ( $n = 13$ ), paradoxically enlarging mass lesions arose within the interpeduncular-suprasellar cistern and its immediate environment during the course of the basal meningeal inflammatory reaction (TBM). Three of the 16 children presented with large, dural-based convexity lesions (see Fig., Supplemental Digital Content 1, <http://links.lww.com/INF/C10>), without concomitant basal meningeal disease, consistent with origin from a superficial meningocerebral necrotic granuloma or Rich focus.<sup>6</sup>

As has been observed before, the majority of intracranial tuberculomas display central, nonenhancing, inhomogeneous T2 hypointensity, which has been shown to represent necrosis of inflammatory granulation tissue, that is, gummatous necrosis.<sup>7</sup> Less commonly, the nonenhancing core is strongly, homogeneously T2 hyperintense, that is, T2 bright, and the fluid necrotic-apoptotic substrate is demonstrably macrophage-predominant, neutrophil-poor, consistent with pseudoabscess formation.<sup>7</sup> In all those children with such “T2-bright” lesions, treatment resulted in a gradual conversion of T2 hyperintensity to hypointensity (see Figs., Supplemental Digital Content 1–4, <http://links.lww.com/INF/C10>, <http://links.lww.com/INF/C11>, <http://links.lww.com/INF/C12>, <http://links.lww.com/INF/C13>). These resultant, homogeneous “T2-black” granulomas (with peripheral or capsular T1 contrast enhancement) tended to persist for many months in asymptomatic children without relapse (see Fig. E and F, Supplemental Digital Content 1, <http://links.lww.com/INF/C11>).

## DISCUSSION

In all the study patients, marked clinical improvement associated with imaging evidence of reduction in perilesional edema and regression in lesion size was observed after thalidomide was added to the anti-TB regimen (see Figs., Supplemental Digital Content 1–4, <http://links.lww.com/INF/C10>, <http://links.lww.com/INF/C11>, <http://links.lww.com/INF/C12>, <http://links.lww.com/INF/C13>). In 5 children, enlargement of the mass lesion and appearance of new discrete mass lesions occurred on thalidomide treatment despite clinical improvement and was attributed to further IRIS response.

Regression was associated with fibrosis, mineralization (calcification) and finally disappearance, usually with no structural residuum (see Fig. F, Supplemental Digital Content 1, <http://links.lww.com/INF/C12>). Neither primary T2 signal shortening in “T2-black” granulomas nor its evolution in the course of pseudoabscess regression has been explained, although change in the concentration of free radicals have been suspected.<sup>8</sup> We assume that the varying imaging T2-FLAIR signal intensities of these granulomas may be attributed to individual cytokine profiles which determine the character of the necrotizing process and the extent of the surrounding inflammatory edema. Thus, each granuloma may be expected to have a different outcome depending on the patient's immunophenotype and the probability that liquefactive necrosis is the result of TNF- $\alpha$  production excess. This must represent an unsatisfactory immune response, since pseudoabscess formation (ie, macrophage-predominant exudation) is known to be rich with bacilli, as well as following a progressive, treatment-unresponsive course. In the child presenting with blindness, serial MR imaging showing resolution of optochiasmatic and perivascular enhancement on the introduction of thalidomide was assumed to represent



a specific anti-inflammatory effect (see Fig., Supplemental Digital Content 1, <http://links.lww.com/INF/C14>).

Although the beneficial response of TB pseudoabscesses to thalidomide appears to be consistent in our cases, the exact mechanism of action remains unclear. Thalidomide activates natural killer T cells, inhibits apoptosis of lymphocytes and ameliorates the interaction of T cells and dendritic cells.<sup>9</sup> It also affects monocyte cytokine levels by inducing Th2 cytokine production (interleukin-4 and interleukin-5) while concomitantly inhibiting Th1 cytokine production (interferon- $\gamma$ ), thereby switching the immune response from Th1 to Th2 type.<sup>10</sup> Schoeman et al<sup>11</sup> reported marked decreased levels of TNF- $\alpha$  in the cerebrospinal fluid of TBM patients on thalidomide treatment. Thalidomide also reduced TNF- $\alpha$  levels in the lungs of mice and cerebrospinal fluid of rabbits which led to less necrosis and decrease in granuloma size.<sup>12</sup>

Thalidomide can be safely used in HIV-infected TBM children as it has been shown to enhance HIV-specific CD8 T-cell function without affecting the viral load.<sup>13</sup> An additional benefit is reduction of HIV-associated wasting.<sup>14</sup> Prolonged thalidomide therapy can cause sensory axonal neuropathy, which may be exacerbated by the combined use of TB drugs and antiretroviral therapy.<sup>15</sup> This complication was not observed in any of the children in our study.

TB reactivation occurred in 1 of the HIV-infected, virally suppressed, TB culture-negative study patient (case 4). This child's failure to control *M. tuberculosis* infection was assumed to be in some way associated with HIV infection or possibly drug-resistant TB. Studies have shown that the life-long risk of TB disease is 50% in subjects coinfecting with *M. tuberculosis* and HIV, compared with 10% in HIV-uninfected subjects,<sup>16</sup> a status directly related to the degree of CD4 T cells loss.<sup>16</sup> Of interest in this patient was imaging evidence of white-matter signal alteration (see Fig. E, Supplemental Digital Content 1, <http://links.lww.com/INF/C12>) assumed to represent inflammatory edema, which preceded the appearance of clinical symptoms by 7 months, emphasizing the importance of serial MR imaging, even in asymptomatic patients.

It is our experience that adjuvant thalidomide therapy should be reserved for children who develop neurologic compromise from enlarging TB pseudoabscesses. This complication is most frequently encountered in cisternal and dural-based lesions as they expand into areas of lesser resistance. Small, asymptomatic cerebral parenchymal TB pseudoabscesses usually resolve on standard TBM therapy. The rate of clinical improvement following initiation of thalidomide varies according to the location, number and size of the TB pseudoabscesses. In the majority of cases, clinical improvement ensues within 2 weeks of therapy. Local practice is to perform serial MR imaging at 3 monthly intervals; satisfactory radiologic response represents a reduction in perilesional edema and a lesser degree of T2 brightness (after 3 months) and regression in lesion size with loss T2 signal (after 6 months). We believe that evolution of TB pseudoabscesses from early-stage "T2 bright" with edema to "T2 black" lesions represents a marker for cure (see Figs., Supplemental Digital Content 1-4, <http://links.lww.com/INF/C10>, <http://links.lww.com/INF/C11>, <http://links.lww.com/INF/C12>, <http://links.lww.com/INF/C13>). Children on thalidomide require regular (weekly) monitoring for skin rashes, neutropenia, thrombocytopenia and hepatitis. Nerve conduction studies should be performed

where the cumulative thalidomide dose exceeds 20 g. Neuroendocrine evaluation should be performed in all children with suprasellar TB pseudoabscesses.

The study highlights the importance of serial MR imaging in identifying the nature of the necrotizing process and evaluating treatment response and duration. Thalidomide should be considered as adjunctive therapy in all children with TB pseudoabscesses that clinically progress despite conventional anti-TB therapy.

## REFERENCES

1. van Toorn R, Rabie H, Dramowski A, et al. Neurological manifestations of TB-IRIS: a report of 4 children. *Eur J Paediatr Neurol*. 2012;16:676–682.
2. Vidal JE, Oliveira AC, Daurar RF. Cerebral tuberculomas or tuberculous brain abscess: the dilemma continues. *Clin Infect Dis*. 2005;40:1072; author reply 1073.
3. Schoeman JF, Fieggen G, Sellar N, et al. Intractable intracranial tuberculous infection responsive to thalidomide: report of four cases. *J Child Neurol*. 2006;21:301–308.
4. van Toorn R, Schaaf HS, Laubscher JA, et al. Short intensified treatment in children with drug-susceptible tuberculous meningitis. *Pediatr Infect Dis J*. 2014;33:248–252.
5. Meintjes G, Lawn SD, Scano F, et al; International Network for the Study of HIV-associated IRIS. Tuberculosis-associated immune reconstitution inflammatory syndrome: case definitions for use in resource-limited settings. *Lancet Infect Dis*. 2008;8:516–523.
6. Donald PR, Schaaf HS, Schoeman JF. Tuberculous meningitis and miliary tuberculosis: the Rich focus revisited. *J Infect*. 2005;50:193–195.
7. Rutherford GS, Hewlett RH. *Atlas of Correlative Neuropathology and Imaging*. Current Histopathology, Volume 24. Norwell, MA: Kluwer Academic Publishers; 2001.
8. Saunders BM, Britton WJ. Life and death in the granuloma: immunopathology of tuberculosis. *Immunol Cell Biol*. 2007;85:103–111.
9. Paravar T, Lee DJ. Thalidomide: mechanisms of action. *Int Rev Immunol*. 2008;27:111–135.
10. McHugh SM, Rifkin IR, Deighton J, et al. The immunosuppressive drug thalidomide induces T helper cell type 2 (Th2) and concomitantly inhibits Th1 cytokine production in mitogen- and antigen-stimulated human peripheral blood mononuclear cell cultures. *Clin Exp Immunol*. 1995;99:160–167.
11. Schoeman JF, Springer P, Ravenscroft A, et al. Adjuvant thalidomide therapy of childhood tuberculous meningitis: possible anti-inflammatory role. *J Child Neurol*. 2000;15:497–503.
12. Tsenova L, Sokol K, Freedman VH, et al. A combination of thalidomide plus antibiotics protects rabbits from mycobacterial meningitis-associated death. *J Infect Dis*. 1998;177:1563–1572.
13. Reyes-Terán G, Sierra-Madero JG, Martínez del Cerro V, et al. Effects of thalidomide on HIV-associated wasting syndrome: a randomized, double-blind, placebo-controlled clinical trial. *AIDS*. 1996;10:1501–1507.
14. Kaplan G, Thomas S, Fierer DS, et al. Thalidomide for the treatment of AIDS-associated wasting. *AIDS Res Hum Retroviruses*. 2000;16:1345–1355.
15. Zara G, Ermani M, Rondinone R, et al. Thalidomide and sensory neurotoxicity: a neurophysiological study. *J Neurol Neurosurg Psychiatry*. 2008;79:1258–1261.
16. Corbett EL, Watt CJ, Walker N, et al. The growing burden of tuberculosis: global trends and interactions with the HIV epidemic. *Arch Intern Med*. 2003;163:1009–1021.

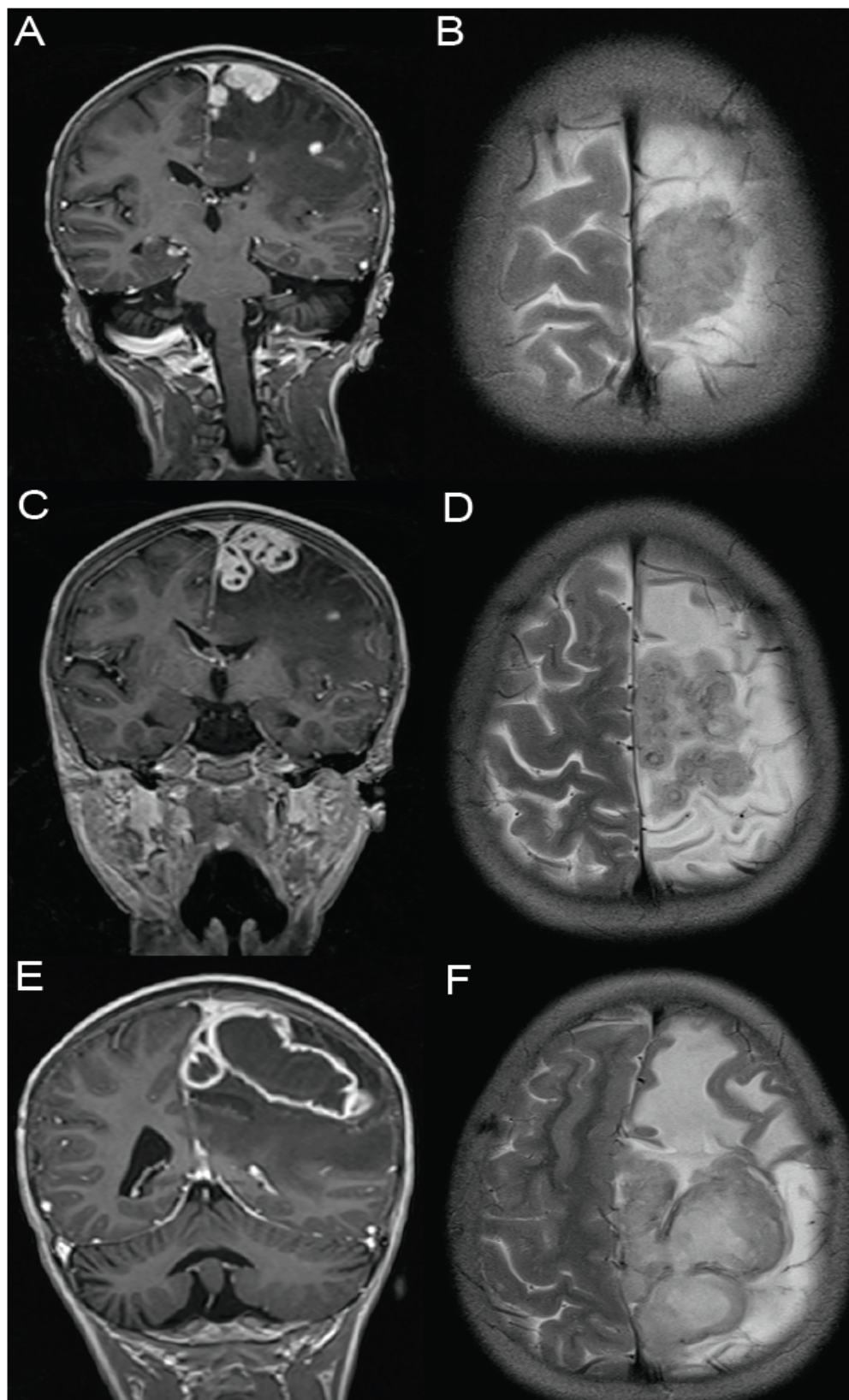


Figure 1 A-F: Sequential magnetic resonance imaging (MRI) of an 8-year-old HIV-infected male with tuberculous meningitis (case 3). Figure 1 A&B. MRI Coronal T1WI post-gadolinium and axial T2WI demonstrating a heterogenous lobulated dural-based lesion in the left parafalcine region with intense enhancement 9 months after starting TB treatment. Figure 1 C&D. MRI Coronal T1WI post-gadolinium and axial T2WI shows the patient 3 months later with an impression of T2 hypo-intense ring lesions, with associated hyper-intense centres within the lobulated mass. Post contrast appearance is that of a cluster of ring-enhancing smaller lesions. Figure 1 E&F. MRI Coronal T1WI post-gadolinium and axial T2WI done at a further 4-month interval demonstrate deterioration with enlargement and posterior extent of the lesion. There are large areas of confluence of hyper-intensity within the mass and it now has an appearance similar to large ring-enhancing collections.

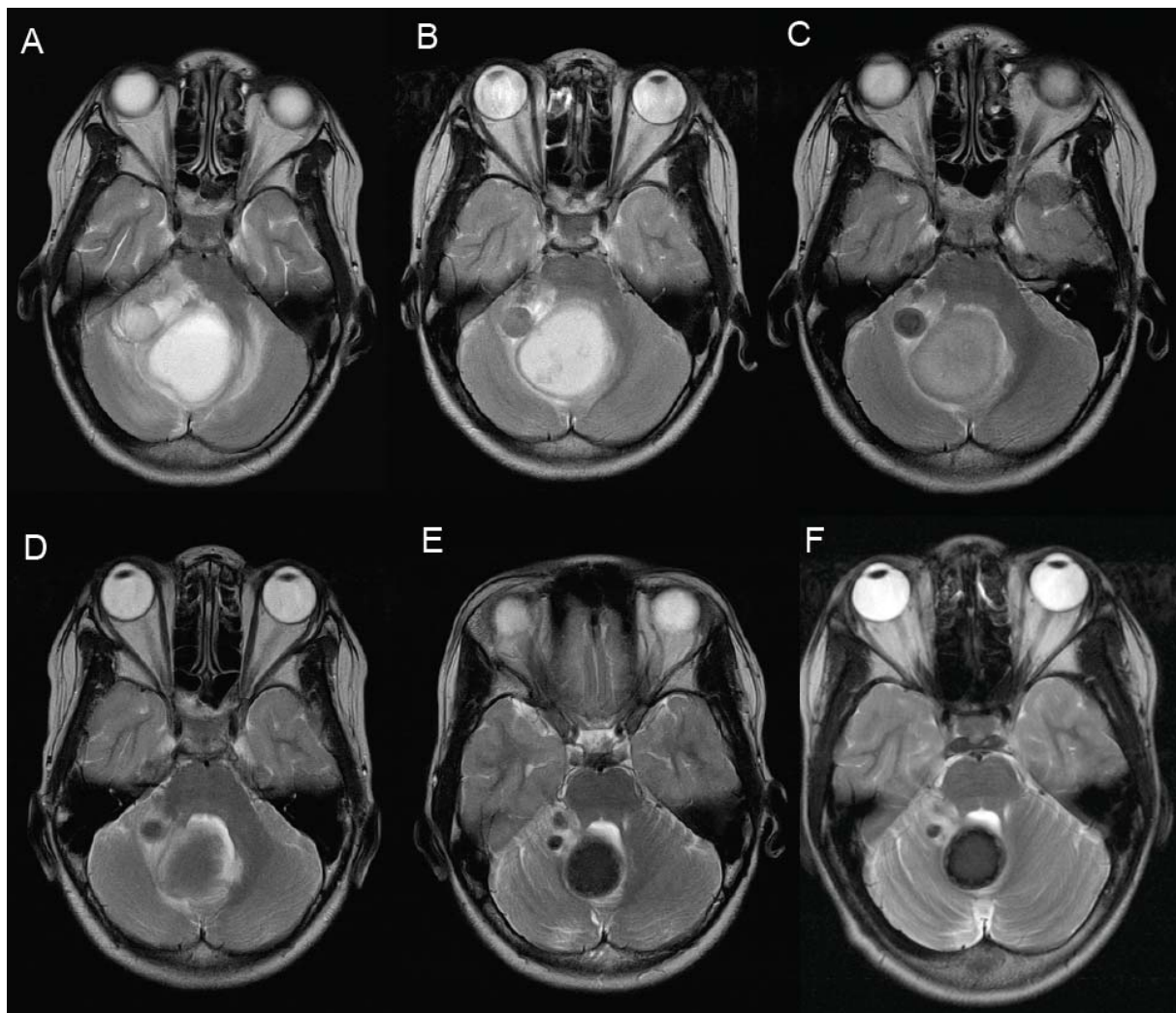


Figure 2A: Magnetic resonance axial T2-weighted imaging on admission (pre-treatment) in a 6-year-old ataxic female with a large cerebellar TB abscess surrounded by smaller abscesses (case 13). 1B: Reduction in perilesional edema after 3 months of thalidomide. Figure 1C-F demonstrates gradual loss of T2-signal and reduction in lesion size after 6, 10, 31 and 41 months. The patient was asymptomatic within 5 months and thalidomide was stopped at 9 months and anti-TB drugs at 12 months. Figure 2A-F demonstrates the gradual evolution, on sequential studies, of all these abscesses to homogenous hypo-intense lesions with reduction in size and perilesional edema.



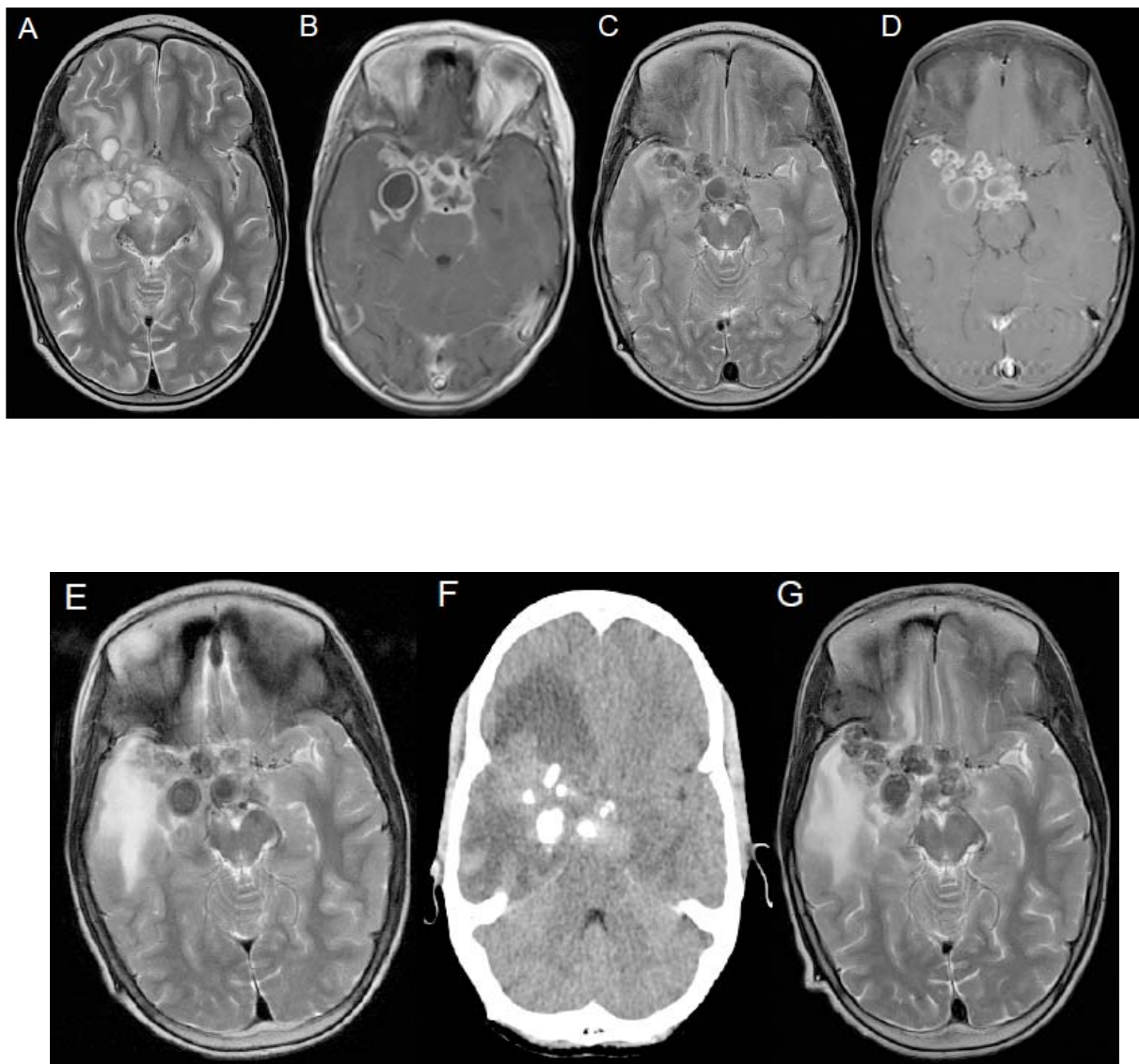


Figure 3A&B: Magnetic resonance Axial T2 and T1-weighted post-gadolinium images on admission in a 14-year-old HIV-infected male (case 4) demonstrating multiple small T2 hyper-intense, ring-enhancing lesions in the suprasellar and right middle cerebral artery cisterns with significant perilesional edema. Figure 3C&D: Axial T2 and T1-weighted post-gadolinium images depicts the evolution to T2 hypo-intensity with reduction in surrounding edema but significant residual ring enhancement one year later. Figure 3E: Axial T2-weighted image shows recurrent increase in the perilesional edema, a further 10 months post treatment in an asymptomatic child, with the signal characteristics of the lesions unchanged. Figure 3F: The patient presents 19 months after previous imaging and is now symptomatic. Post contrast axial CT demonstrating coarse calcification in the evolved lesions although significant oedema is now demonstrated. Figure 3G: Corresponding T2-weighted axial image demonstrating no hyper-intense lesions but significant perilesional edema.

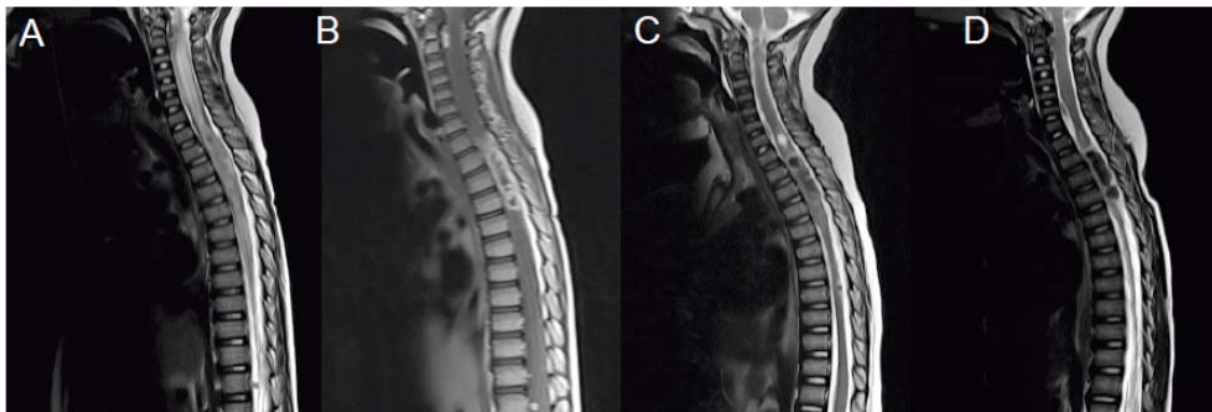


Figure 4A&B: Magnetic resonance T2WI and T1WI sagittal post-gadolinium images of a 4-year-old female (case 7) presenting with a spastic paraplegia demonstrated a lobulated heterogeneous ring-enhancing intramedullary TB granulomas extending from T2-T4. An associated syrinx is seen extending from C1-7 level. Figure 4C: MRI T2WI after 5 months of thalidomide shows gradual loss of T2 with the syrinx markedly decreased in size. The patient is now able to walk. Figure 4D: MRI T2WI 14 months later, 8 months after completion of anti-TB treatment and 7 months after completion of thalidomide. The granulomas are now T2 hypo-intense, with nearly no distinguishable syrinx. The patient is asymptomatic with no functional impairment.

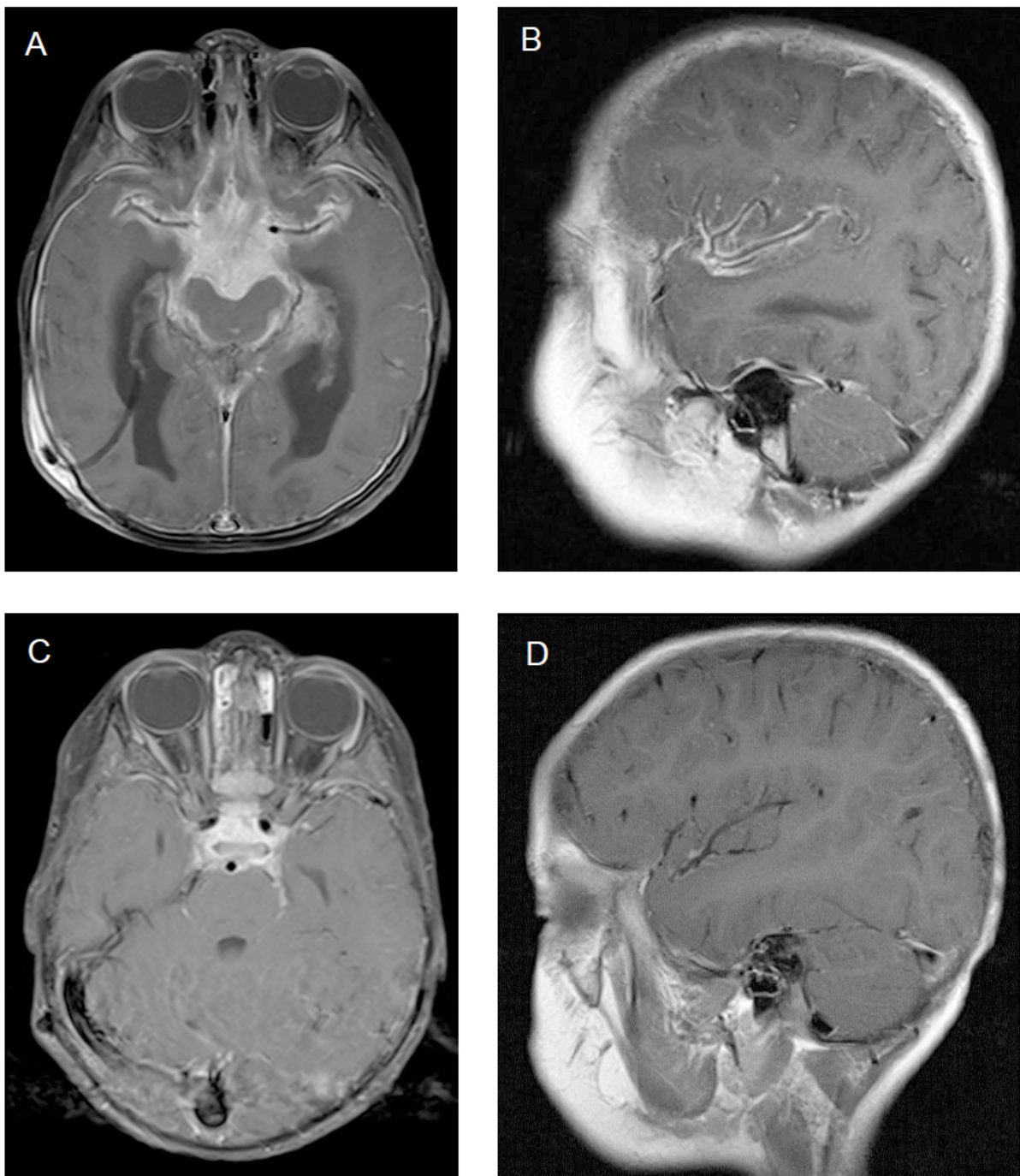


Figure 5A&B: Magnetic resonance imaging axial (A) and sagittal (B) T1WI post-gadolinium images of a 2-year-old male (case 5) with visual impairment secondary to tuberculous optochiasmatic arachnoiditis. This shows extensive severe suprasellar enhancing exudates involving the optic chiasm and proximal optic nerves as well as extending into bilateral middle cerebral artery and interpeduncular cisterns. The sagittal image demonstrates the perivascular inflammation in the middle cerebral artery cistern. Figure 5C&D: Repeat MRI axial (C) and sagittal (D) T1WI post-gadolinium images following 3 months of thalidomide demonstrating marked interval improvement with reduction in the extent of the exudates as well as near complete resolution of perivascular inflammation, depicted on the sagittal image (D).



# The value of transcranial Doppler imaging in children with tuberculous meningitis

Ronald van Toorn · H. Simon Schaaf · Regan Solomons ·  
Jacoba A. Laubscher · Johan F. Schoeman

Received: 23 April 2014 / Accepted: 2 May 2014  
© Springer-Verlag Berlin Heidelberg 2014

## Abstract

**Purpose** Transcranial Doppler imaging (TCDI) is potentially a valuable investigational tool in children with tuberculous meningitis (TBM), a condition often complicated by pathology relevant to Doppler imaging such as raised intracranial pressure (ICP) and cerebral vasculopathies.

**Methods** Serial TCDI was performed on 20 TBM children with the aim of investigating cerebrovascular haemodynamics and the relationship between pulsatility index (PI) and ICP.

**Results** We observed a poor correlation between ICP and PI in children with communicating hydrocephalus ( $p=0.72$ ). No decline in PI was noted following 7 days of medical therapy for communicating hydrocephalus ( $p=0.78$ ) despite a concomitant decline in ICP. Conversely, a decline in PI was noted in all four children with non-communicating hydrocephalus who underwent cerebrospinal fluid diversion. High blood flow velocities (BFV) in all the basal cerebral arteries were observed in 14 children (70 %). The high BFV persisted for 7 days suggesting stenosis due to vasculitis rather than functional vasospasm. Complete middle cerebral artery (MCA) occlusion, subnormal mean MCA velocities ( $<40$  cm/s) and PIs ( $<0.4$ ) correlated with radiologically proven large cerebral infarcts.

**Conclusions** TCDI-derived PI is not a reliable indicator of raised ICP in children with tuberculous hydrocephalus. This may be attributed to individual variation of tuberculous vascular disease, possibly compromising cerebral vascular

compliance and resistance. Basal artery stenosis secondary to vasculitis is observed during the acute stage of TBM in the majority of children.

**Keywords** Tuberculous meningitis · Transcranial Doppler · Pulsatility index · Intracranial pressure · Mean blood flow velocity

## Introduction

Transcranial Doppler imaging (TCDI) is a safe, portable, non-invasive, inexpensive and non-ionizing method of assessing cerebral hydrodynamics and haemodynamics [1]. It can be repeated multiple times and used for serial monitoring. TCDI may provide accurate information on intracranial pressure (ICP) and cerebral blood flow velocities (BFV) which may help guide therapy in critically ill patients [1]. This applies especially to resource-poor countries where expensive monitoring equipment is often not available. However, controversy exists whether TCDI-derived pulsatility index (PI) is a reliable marker of raised ICP. Some studies report a linear relationship between the PI and measured ICP in hydrocephalic children, whilst others have failed to find such correlation [2–6].

To date, only one study examined the potential role of TCDI in tuberculous hydrocephalus [7]. Two groups of 15 children with tuberculous hydrocephalus and congenital hydrocephalus were prospectively examined by TCDI before and after cerebrospinal fluid (CSF) diversion. A clinically relevant fall in PI after CSF diversion only occurred in children with congenital hydrocephalus ( $p=0.007$ ). In tuberculous meningitis (TBM) patients with infarcts, there was no statistically significant drop in the PI pre- and post-shunt procedure.

TCDI also allows evaluation and monitoring of cerebral basal artery haemodynamics. Studies report an inverse

R. van Toorn (✉) · H. S. Schaaf · R. Solomons · J. F. Schoeman  
Department of Paediatrics and Child Health, Stellenbosch University  
and Tygerberg Children's Hospital, PO Box 19063, Tygerberg, Cape  
Town 7505, Western Cape, South Africa  
e-mail: vtoorn@sun.ac.za

J. A. Laubscher  
Biostatistics Unit, Medical Research Council of South Africa,  
Tygerberg, Cape Town, South Africa

relationship between ICP and cerebral blood flow (CBF) in young children with meningitis and hydrocephalus [8, 9]. Ventricular peritoneal shunting permits a sudden increase in CBF and BFV, and increases of above 30 % have been reported [10]. Only one study investigated the use of TCDI in tuberculous cerebral vasculopathy [11]. This study found that TCDI allows distinction of three phases of arteriopathy (i.e. vasospasm, vasodilatation and stenosis). The study found a good correlation between each of the three stages with clinical findings (Glasgow coma score), radiological findings (ischemia on magnetic resonance imaging [MRI]) and outcome.

The present study sought to investigate the potential role of serial TCDI in the assessment of tuberculous hydrocephalus-related raised ICP and interventions aimed at reducing ICP, and the role of serial TCDI as a dynamic modality in the assessment of TBM-related vasculopathy and its possible predictive value in terms of the development of infarcts.

## Material and methods

The study was conducted at Tygerberg Children's Hospital, a tertiary referral hospital in Cape Town, South Africa. The study population comprised 20 children less than 13 years of age who were admitted for TBM from June 2012 to June 2013.

A definite diagnosis of TBM was made when *Mycobacterium tuberculosis* was cultured and/or polymerase chain reaction (PCR)-positive from CSF. In all other cases, the diagnosis was "probable TBM" based on clinical signs of meningitis in the presence of characteristic CSF findings (macroscopically clear, pleocytosis usually with lymphocyte predominance, elevated protein and reduced glucose). In addition, two of the following criteria were required: other clinical specimens culture-positive for *M. tuberculosis* and/or positive TB histology, a positive tuberculin skin test, a chest radiograph compatible with TB, a cranial computerized tomography (CT) or MRI compatible with TBM, growth failure with crossing of weight-for-age percentiles or finally, household contact with a sputum smear-positive pulmonary TB case.

The severity of disease was classified according to the refined Medical Research Council classification [12]. All children underwent contrasted CT imaging at admission. The degree of hydrocephalus was expressed as the Evans ratio (maximum ventricular width divided by the largest biparietal distance between the inner tables of the skull); a ratio of larger than 0.3 is indicative of hydrocephalus [13]. The site and size of all infarcts were recorded.

All children underwent short intensified anti-TB treatment (6 months of rifampicin, isoniazid, pyrazinamide and ethionamide [RHZEth] for HIV-uninfected and 9 months RHZEth for HIV-infected children. Children with non-communicating hydrocephalus, as determined by air encephalography, were referred for immediate ventriculoperitoneal shunting (VPS) or endoscopic third ventriculostomy (ETV). All children with communicating hydrocephalus were treated medically with acetazolamide (50 mg/kg/day) and furosemide (1 mg/kg/day) during the first month of therapy to expedite normalization of ICP.

All TCDI studies were performed by one investigator (RVT) as a bedside investigation using a GE Healthcare Vivid S5 high-end Ultrasound machine (General Electric Medical Systems, Milwaukee, USA) with a 2-MHz probe. Recordings were performed on admission and repeated after 3 and 7 days. The transtemporal window was used to isonate the anterior cerebral artery (ACA), middle cerebral artery (MCA) and posterior cerebral artery (PCA). The main horizontal section of the MCA from its origin to the limen insulae was isonated. This M1 segment of the MCA gives rise to numerous, small lenticostriate or perforating branches which are most commonly affected in TBM. Different depth range, flow direction and normal age-related flow velocity ranges have been established for each vessel [14]. The vessels were identified using these parameters.

Recorded parameters included peak, mean and diastolic flow velocities and PI. The PI is calculated by the Gosling index ( $PI = \text{peak systolic velocity} - \text{end diastolic velocity}$ ) divided by the mean velocity. The normal range of PI in the MCA is 0.5–1.1 [14]. Studies evaluating the variability in normal individuals found the PI to vary between 0.69 and 0.71 for the MCA, ACA and PCA, and there were no significant (>20 %) side-to-side or day-to-day differences [14]. The PI is automatically calculated and displayed on the TCDI instrument. Sample volumes were taken at a standardized distance from the Circle of Willis in all vessels bilaterally to allow for meaningful interpretation on follow-up examinations. At least three readings per vessel were made at each evaluation and the average measurement was used. Indices were determined using at least three cardiac cycles of visually and audibly good quality. In children with focal neurological deficits or radiological proven infarcts, PI measurements from the unaffected side (cerebral hemisphere) were used.

The peak systolic velocity was used to define the presence of stenosis. A peak systolic velocity of less than 140 cm/s was considered to indicate a normal artery [14]. The degree of stenosis was qualified according to the published criteria and was graded into three categories: grade I (140–209 cm/s), grade II (210 to 280 cm/s) and grade III (>280 cm/s). MCA occlusion was diagnosed if all the basal arteries except the MCA in question were detectable or if the asymmetry index of the symptomatic MCA was <21 % compared with that of the

contralateral MCA. The Lindegaard index (the ratio of the MCA velocity to the extracranial internal carotid artery velocity) was used to distinguish cerebral vasospasm from hyperemia [14]. Vasospasm was diagnosed in cases where the mean MCA flow velocity exceeded 120 cm/s, and the Lindegaard ratio was more than 3.

TCDI measurements may be influenced by different physiological and pathological factors such as age, gender, hematocrit, fever, hypoglycemia, heart rate, blood pressure and drugs with either vasodilatation or vasoconstriction properties. All physiological parameters were kept stable during the TCDI examination. Carbon dioxide ( $\text{PaCO}_2$ ) levels were not measured as angiographic studies have demonstrated that the larger human basal cerebral arteries are unresponsive (at least within the tolerances of measurements) to changes in  $\text{PaCO}_2$ , while arteries that had diameters less than 1 mm responded [15]. None of the TBM children were ventilated or exhibited abnormal breathing patterns during the TCDI.

Lumbar CSF pressure was recorded immediately after TCDI upon admission, after 3 and 7 days. The opening pressure measurement was determined using the highest resting CSF level, in centimetres  $\text{H}_2\text{O}$ , when sustained for at least 10 s. A CSF baseline pressure of greater than 20 cm  $\text{H}_2\text{O}$  was considered indicative of raised ICP in children with communicating hydrocephalus.

Neurological outcome at 6 months was divided into the following four categories: (1) normal, including normal motor function, intelligence, vision and hearing; (2) mild sequelae, including hemiparesis, mild intellectual impairment and impaired vision and/or hearing; (3) severe sequelae, including quadriplegia, severe intellectual impairment, blindness and/or deafness; and (4) death. Clinical outcome was defined as “good” in the case of normal and mild neurological sequelae and “poor” in children with severe neurological sequelae or death.

The study was approved by the Health Research Ethics Committee of Stellenbosch University (N12/07/041).

## Results

Of the 20 children with TBM, median age of 37 months (range 4–140 months), 12 (60 %) were male. Sixteen (80 %) of the children presented with stage II TBM, three (15 %) with stage III TBM and one (5 %) had stage I TBM; three (15 %) were HIV-infected. In seven children (35 %), *M. tuberculosis* was isolated from gastric aspirates ( $n=6$ ) or CSF ( $n=1$ ); six isolates proved drug-susceptible and one was isoniazid-monoresistant.

Sixteen (80 %) children had communicating hydrocephalus; in the four (20 %) children with non-communicating hydrocephalus, three underwent VPS and one ETV. Ten of the 16 (62 %) children with communicating hydrocephalus

had elevated ICP on admission (median ICP 35 cm  $\text{H}_2\text{O}$ , range 22–55). Eight (40 %) had visible infarcts on admission cranial CT imaging. No correlation was found between the ventricular size (Evans’ index) on CT and ICP in children with communicating hydrocephalus ( $p=0.73$ ).

Figure 1 illustrates the poor correlation between serial ICP and PI (43 measurements) in the 16 children with communicating tuberculous hydrocephalus ( $p=0.72$ ). Cases with confirmed non-communicating hydrocephalus were not included in this correlation because lumbar CSF pressure does not necessarily reflect ICP in this condition. Figure 2 illustrates the change in ICP on days 1, 3 and 7 in the 16 children who underwent medical treatment for communicating hydrocephalus. In all cases, the ICP normalized within 7 days after initiation of acetazolamide and furosemide. In contrast, there was no significant decline in the PI after 7 days of medical therapy ( $p=0.78$ ). However, in all four children with non-communicating hydrocephalus, the PI decreased following CSF diversion (Fig. 3).

Bilateral MCA stenosis on admission was detected in 14 (70 %) of the 20 TBM children; 10 had grade I stenosis and 4 had grade II stenosis (Fig. 4). Serial TCDI on days 1, 3 and 7 showed no change in the grade of stenosis in 11 children, improvement in 2 and deterioration in 1. One child initially presented with a grade II MCA stenosis (Lindegaard index  $>3$ ) which normalized on day 3 and remained normal on day 7. This indicates vasospasm. There was no significant difference in peak systolic flow velocities on day 1 compared to day 7 in the 20 TBM patients ( $p=0.80$ ). Similarly, there was no significant difference in the mean MCA BFV on day 1 compared to day 7 in the 16 children with communicating hydrocephalus ( $p=0.18$ ).

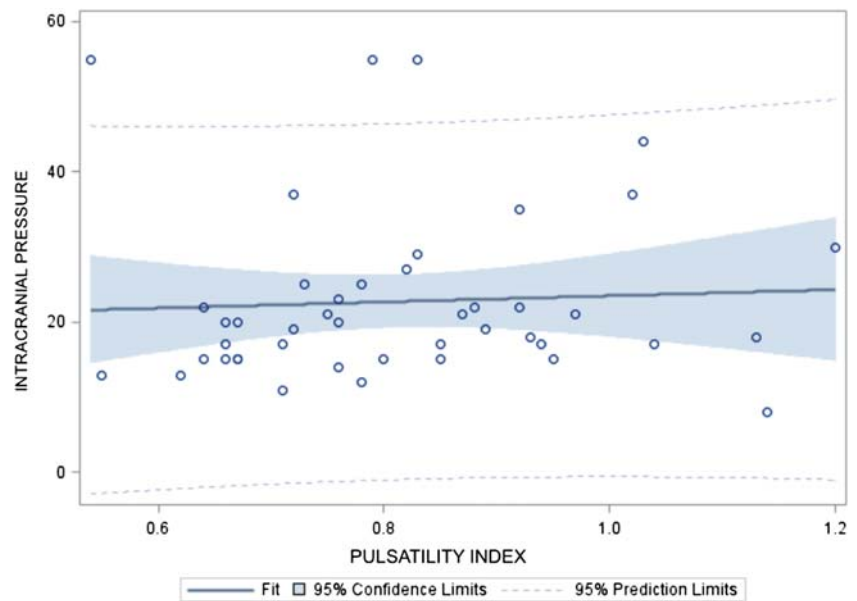
Side-to-side differences in MCA flow velocities were detected in four of the eight children with radiologically proven infarcts. In two of the children, subnormal mean MCA velocities ( $\leq 40$  cm/s) and PI ( $\leq 0.4$ ) resulted in ipsilateral infarction. Complete MCA occlusion (all other basal arteries detectable except the MCA in question) occurred in the other two children; both had large MCA infarcts on CT and severe hemiplegias.

Eighteen (90 %) of the 20 children had a good outcome after 6 months of treatment. The two children with poor outcome both had stage III disease, infarcts on CT and subnormal and declining PI and mean MCA velocities on TCDI. All children with a good outcome had normal TCDI.

## Discussion

For optimal management of acute TBM in children, ICP should be measured in order to determine its contribution to the patient’s neurological state (e.g. coma) and because it is treatable. Studies have shown that clinical diagnosis of the

**Fig. 1** Fit plot for intracranial pressure (ICP). Illustration of the poor correlation between ICP and pulsatility index in the 16 children with communicating hydrocephalus on days 1, 3 and 7

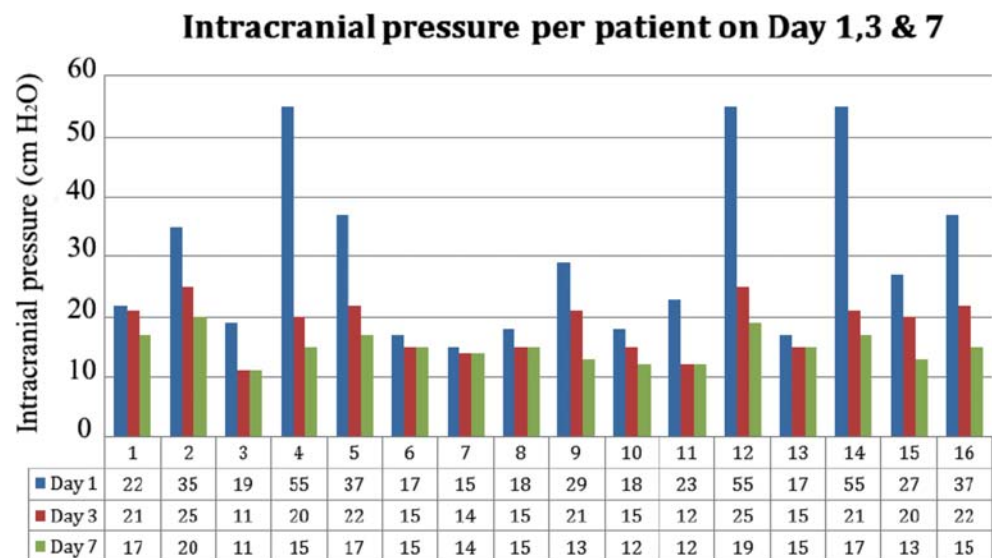


presence and degree of raised ICP is unreliable, especially in children with closed anterior fontanels [16]. The value of CT imaging is limited by the poor correlation between the degree of hydrocephalus (ventricular size) and ICP [16]. Similarly, in this study, no correlation was found between ventricular size on CT and the degree of raised ICP ( $p=0.73$ ).

Many non-invasive techniques of measuring ICP have been evaluated, such as intraocular pressure, tympanic membrane displacement and measurement of intracranial blood flow [17]. None has been found reliable enough to replace invasive procedures. Lumbar CSF pressure measurement in TBM accurately reflects ICP in children with communicating tuberculous hydrocephalus. In this condition, it can be repeatedly done to monitor the course without any danger to the patient; repeated

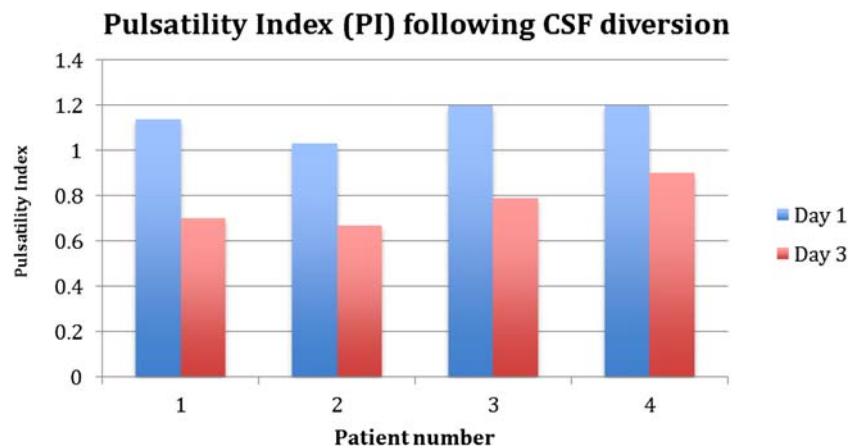
lumbar puncture has even been advocated as a safe although invasive treatment option for communicating hydrocephalus in TBM [18]. In contrast, lumbar CSF pressure does not reflect ICP in non-communicating tuberculous hydrocephalus; in this condition, a lumbar puncture may result in cerebral transtentorial or uncal herniation with dire consequences for the patient. A non-invasive method of measuring ICP in children with TBM would therefore potentially be of great value, as it may assist with identification of hydrocephalic children who require CSF drainage procedures, assist with assessment of shunt function, confirm fenestration patency in patients with non-communicating tuberculous hydrocephalus who underwent ETV and assist with evaluating the therapeutic effects of ICP-lowering drugs such as mannitol and diuretics.

**Fig. 2** Illustration of the ICP on days 1, 3 and 7 in 16 TBM children with communicating hydrocephalus following medical therapy consisting of acetazolamide and furosemide





**Fig. 3** Illustration of the change in pulsatility index before and after cerebrospinal fluid diversion in four tuberculous meningitis children with non-communicating hydrocephalus. Patients 1–3 underwent ventriculoperitoneal shunting and patient 4 underwent endoscopic third ventriculostomy



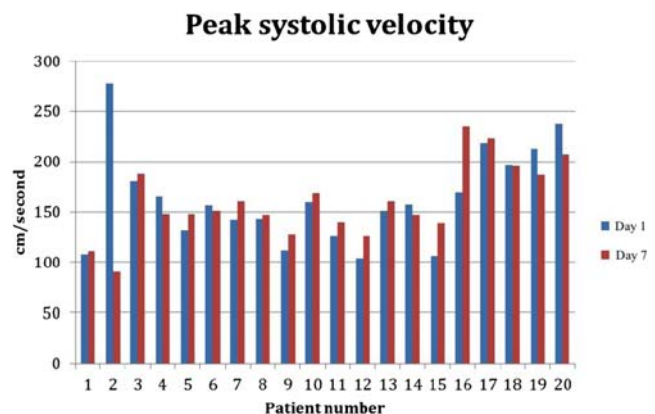
In our study, TCDI-related PI was found not to be an accurate method of assessing ICP in children with communicating tuberculous hydrocephalus. No linear correlation was found between PI and ICP ( $p=0.72$ ). This may be attributed to individual variation of tuberculous vascular disease, possibly compromising cerebral vascular compliance and resistance. It has been suggested that absolute PI values should be read with extreme caution, even at the extremes of ICP values, and that TCDI can play an important role as a means of monitoring pressure changes over time [3]. In our study, no decline in PI was noted following 7 days of medical therapy for communicating hydrocephalus, despite a confirmed decline in ICP. Conversely, a decline in PI was noted in all four children with non-communicating hydrocephalus who underwent CSF diversion, most likely as a result of a more dramatic fall in ICP in this group (Fig. 3). Larger studies are warranted to investigate this finding and should ideally include pre- and post-surgical ICP monitoring.

Carbonic anhydrase inhibitors (acetazolamide) and loop diuretics (furosemide) exert their effect on ICP by reducing CSF production at the choroid plexus [19]. Acetazolamide has a rapid onset of action and has been found to reduce CSF production in humans by 6–50 % [20]. Inhibition of CSF flow occurs once 99.5 % of choroid plexus carbonic anhydrase is inhibited [21]. In children with communicating tuberculous hydrocephalus, acetazolamide and furosemide in combination have been found to be more effective in achieving normal ICP than antituberculous drugs alone [16]. In this study, rapid normalization of ICP occurred within 7 days of therapy in all 10 cases of communicating tuberculous hydrocephalus who had elevated ICP (Fig. 2). Acetazolamide has also been shown not to alter the cerebral metabolic rate of oxygen, which is beneficial in children with TBM-related ischemic brain disease [22].

Acetazolamide also increases CBF by 5–80 % [22]. High bilateral MCA BFV upon admission was observed in 70 % of the TBM children. This occurred prior to acetazolamide administration and CSF sampling and can be ascribed to vessel

narrowing (or stretching on account of acute hydrocephalus (ventricular dilatation) or spasm because of meningeal involvement (as in acute subarachnoid haemorrhage)). In almost all the children, high BFV persisted after 1 week which supports vessel narrowing secondary to organic stenosis rather than functional vasospasm. Functional vasospasm was observed in only one child. In this child, no infarcts were observed on CT and outcome after 6 months was normal.

Information regarding the sensitivity and specificity of TCDI in the diagnosis of cerebral ischemia in general is limited [23]. In this study, subnormal mean MCA BFV ( $\leq 40$  cm/s) and PI ( $\leq 0.4$ ) were associated with CT infarction in two children. The diminished MCA BFV reflects decreased perfusion (demand) to the infarcted area. Tuberculous vasculopathy of the distal internal carotid artery may also account for the diminished MCA BFV. In four children with territory infarcts on admission, no side-to-side differences in MCA BFV or subnormal PIs were detected. This can be attributed to the occlusion of a limited number (one or two) of the nine MCA perforators which has been shown not to affect the haemodynamics of the MCA [23]. This could unfortunately not be confirmed due to lack of concomitant MR angiography.



**Fig. 4** Illustration of the peak middle cerebral artery systolic blood flow velocity on admission compared to day 7 in 20 children with TBM

**Acknowledgments** The study received financial support from the National Research Foundation—HS Schaaf.

**Conflict of interest** None

## References

- Kassab MY, Majid A, Farooq M, Azhary H, Hershey LA, Bednarczyk EM, Graybeal DF, Johnson MD (2007) Transcranial Doppler: an introduction for primary care physicians. *J Am Board Fam Med* 20:65–71
- Bellner J, Rommer B, Reinstrup P, Kristiansson KA, Ryding E, Brandt L (2004) Transcranial Doppler sonography pulsatility index (PI) reflects intracranial pressure (ICP). *Surg Neurol* 62:45–51
- Wakerley BR, Sharma VK (2013) Transcranial Doppler derived pulsatility index in the assessment of intracranial pressure: the trend is your friend. *Neurosurgery* 72(2):E319–E320
- Hanlo PW, Gooskens RH, Nijhuis IJ, Faber JA, Peters RJ, van Huffelen AC, Tulleken CA, Willemse J (1995) Value of transcranial Doppler indices in predicting raised ICP in infantile hydrocephalus. A study with review of the literature. *Childs Nerv Syst* 11(10):595–603
- Behrens A, Lenfeldt N, Ambarki K, Malm J, Eklund A, Koskinen LO (2011) Intracranial pressure and pulsatility index. *Neurosurgery* 69(4):E1033–E1034
- Figaji AA, Zwane E, Fieggen AG, Siesjo P, Peter JC (2009) Transcranial Doppler pulsatility index is not a reliable indicator of intracranial pressure in children with severe traumatic brain injury. *Surg Neurol* 4:389–394
- Nadvi SS, Du Trevous MD, Van Dellen JR, Gouws E (1994) The use of transcranial Doppler ultrasonography as a method of assessing intracranial pressure in hydrocephalic children. *Br J Neurosurg* 8(5): 573–577
- Goh D, Minns RA (1993) Cerebral blood flow velocity monitoring in pyogenic meningitis. *Arch Dis Child* 68(1):111–119
- McMenamin JB, Volpe JJ (1984) Bacterial meningitis in infancy: effects on intracranial pressure and cerebral blood flow velocity. *Neurology* 34(4):500–504
- Pople IK, Quinn MW, Bayson R, Hayward RD (1991) The Doppler pulsatility index as a screening test for blocked ventriculo-peritoneal shunts. *Eur J Pediatr Surg* 1(1 Suppl):27–29
- Kilic T, Elmaci I, Ozek MM, Pamir MN (2002) Utility of transcranial Doppler ultrasonography in the diagnosis and follow-up of tuberculous meningitis-related vasculopathy. *Childs Nerv Syst* 18(3–4):142–146
- van Toorn R, Springer P, Laubscher JA, Schoeman JF (2012) Value of different staging systems for predicting neurological outcome in children with tuberculous meningitis. *Int J Tuberc Lung Dis* 16(5): 628–632
- von Benzing H, Andronikou S, van Toorn R, Douglas T (2012) Are axial measurements and computerized volumetric ratios determined from axial MRI useful for diagnosing hydrocephalus in children with tuberculous meningitis? *Childs Nerv Syst* 28(1):79–85
- Arnolds BJ, von Reutern GM (1986) Transcranial Doppler sonography. Examination technique and normal reference values. *Ultrasound Med Biol* 12(2):115–123
- Huber P, Handa J (1967) Effect of contrast material, hypercapnia, hyperventilation, hypertonic saline and papaverine on the diameter of the cerebral arteries. *Invest Radiol* 2(1):17–32
- Schoeman J, Donald P, van Zyl L, Keet M, Wait J (1991) Tuberculous hydrocephalus: comparison of different treatment with regard to ICP, ventricular size and clinical outcome. *Dev Med Child Neuro* 33(5):396–405
- Rosenberg JB, Shiloh AL, Savel RH, Eisen LA (2011) Non-invasive methods of estimating intracranial pressure. *Neurocrit Care* 15(3): 599–608
- Visudhiphan P, Chiemchanya S (1979) Hydrocephalus in tuberculous meningitis in children: treatment with acetazolamide and repeated lumbar puncture. *J Pediatr* 95(4):657–660
- Carrion E, Hertzog JH, Medlock MD, Hauser GJ, Dalton HJ (2001) Use of acetazolamide to decrease cerebrospinal fluid production in chronically ventilated patients with ventriculoperitoneal shunts. *Arch Dis Child* 84(1):68–71
- Rubin RC, Henderson ES, Ommaya AK, Walker MD, Rall DP (1966) The production of cerebrospinal fluid in man and its modification by acetazolamide. *J Neurosurg* 25(4):430–436
- McCarthy KD, Reed DJ (1974) The effect of acetazolamide and furosemide on CSF production and carbonic anhydrase activity. *J Pharmacol Exp Ther* 189:194–201
- Vorstrup S, Hendriksen L, Paulson OB (1984) Effect of acetazolamide on cerebral blood flow and cerebral metabolic rate of oxygen. *J Clin Invest* 74(5):1634–1639
- Zanette EM, Fieschi C, Bozzao L, Roberti C, Toni D, Argentino C, Lenzi GL (1989) Comparison of cerebral angiography and transcranial Doppler sonography in acute stroke. *Stroke* 20(7):899–903



## **Chapter 7**

## **Conclusion**

## Chapter 7

### General Conclusions

Prognosis in tuberculous meningitis (TBM) is directly related to the clinical stage of disease. Other factors associated with poor outcome are multidrug-resistant tuberculosis (MDR-TB) and human immunodeficiency virus (HIV) co-infection.

My first study concluded that outcome prognostication in childhood TBM can be improved by usage of the refined MRC staging system.<sup>1</sup> This staging system has the highest predictive value (84%, 95% confidence interval [CI] 81-88) of all TBM staging systems. The modified MRC stage 2 disease-category is too inclusive as children without neurological deficit and only slight drowsiness (Glasgow Coma Scale [GCS] 14/15) are grouped together with children with neurological deficit and GCS of 10-13/15. This was confirmed by our study which found that the risk of severe motor deficit (spastic quadriplegia;  $p=0.028$ ) and the degree of intellectual disability ( $p=0.001$ ) were higher in children classified as stage 2b compared to stage 2a. The excellent predictive power of the simplified staging system (Tygerberg Children's Hospital staging system) that I proposed makes it ideal for use in resource-poor settings. It is based on the patient's ability to visually fixate and follow and the motor response to pain on both sides. The importance of early diagnosis in TBM is highlighted by the decline of 10 development quotient (DQ) points with every change to a lower disease category.

Limitations of the TBM outcome study are the short period of follow-up (6 months), failure to evaluate behavioural outcome and lack of baseline neuroimaging. Long-term TBM outcome studies are lacking and no study has yet explored the effect of childhood TBM on adult survivors. Very few studies have investigated behavioural outcome after TBM. One study reported general behavioral disinhibitions as well as internalized emotional disorder are long-term complications in more than 10% of TBM survivors.<sup>2</sup> Accurate cognitive assessment is also notoriously difficult in young children. About a third of all children with advanced TBM will develop stroke.<sup>3</sup> Most of these strokes are due to infarcts located in the middle cerebral artery (MCA) territories, particularly in the so-called "TB zone" which comprised of the caudate, anterior thalamus, anterior limb and genu of the internal capsule.<sup>4</sup> Dysfunction of the basal ganglia may produce changes in a variety of behavioural and cognitive functions including learning, language, personality and social behaviour. This suggests that prospective TBM outcome studies should include baseline and sequential MRI imaging.

The optimal anti-TB drug regimen and duration of treatment for TBM remains unknown.

A recent health review on “Evidence behind the WHO guidelines: hospital care for children: what is the most appropriate treatment for tuberculous meningitis?” emphasized the need for further studies that investigate the efficacy and safety of intensive short-course chemotherapy in children with TBM residing in resource-poor settings.<sup>5</sup> This review found that there were no published studies that investigated relapse rate in children who completed anti-TB treatment. The authors recommended that all trials assessing anti-TB treatment for TBM should include death and sequelae as primary outcome measures and a follow-up period of at least two years to assess relapses.<sup>5</sup>

A recent systematic review and meta-analysis of childhood TBM studies published up to October 2012 reported a 19.3% (95% CI 14.0-26.1) risk of death and probability of survival without neurological sequelae of 36.7% (95% CI 27.9-46.4).<sup>6</sup> Among survivors, risk of neurological sequelae was 53.9% (95% CI 42.6-64.9). The overall mortality of our short intensified regimen (3.8% at completion of treatment and good outcome in 80% of survivors) compares favorably with the above reported outcome.<sup>6</sup> No relapses were encountered in any of the 179 study patients who survived treatment; 29 patients were lost to follow-up between treatment completion and the two-year follow-up period, which was the censoring period for relapse. Our short intensified regimen appears to be safe as anti-TB drug induced hepatotoxicity occurred in only 5% (8 out of 143 children tested) of the children, all tested negative for viral hepatitis; in all 8 cases the original regimen was restarted without recurrence.

The short intensified treatment study, despite demonstrating good outcomes and a shorter duration of treatment, is observational without a randomized control group for comparison. It thus may provide insufficient evidence to change international policy. Our anti-TBM regimen also employs a drug (ethionamide) usually reserved for second-line treatment. This could have implications for acceptability by TB programmes.

The potential benefit of intensified anti-TBM treatment was recently explored in two adult TBM randomized controlled trials (RCT). In an open-label, phase 2 trial with a factorial design, patients (aged > 14 years) with TBM were randomly assigned to receive, according to a computer-generated schedule, first rifampicin standard dose (450 mg, about 10 mg/kg) orally or high dose (600 mg, about 13 mg/kg) intravenously, and second oral moxifloxacin

400 mg, moxifloxacin 800 mg, or ethambutol 750 mg once daily.<sup>8</sup> All patients were given standard-dose isoniazid, pyrazinamide, and adjunctive corticosteroids. After 14 days of treatment all patients continued with standard treatment for tuberculosis. Intensified treatment was associated with lower 6-month mortality (35% versus 65%) without increased toxicity which could not be explained by HIV status or severity of disease at the time of presentation.

In another open-label, RCT from India, sixty patients on standard therapy consisting of isoniazid, pyrazinamide, ethambutol and adjunctive corticosteroids and aspirin, were randomized to receive either levofloxacin (10 mg/kg, maximum 500 mg) or rifampicin (10 mg/kg, maximum 450 mg).<sup>9</sup> The primary outcome was death and secondary outcome measures were 6 month disability and serious adverse effects. Levofloxacin was superior to rifampicin in reducing 6 months death but not disability. The preliminary findings from adult studies highlight the need for a childhood RCT, evaluating alternative, and better palatable anti-TB drugs with fewer adverse effects but with at least similar efficacy to the regimen we currently advocate.

Fluoroquinolones possibly offer an alternative option to ethionamide as they demonstrate in vitro activity, tolerability, good bioavailability also in the cerebrospinal fluid and ease of administration.<sup>10</sup> Increasing the dose of rifampicin may result in higher mycobacteriocidal activity in the brain and possibly greater survival.<sup>8</sup>

Immune reconstitution inflammatory syndrome (IRIS) is a potentially life-threatening complication of antiretroviral therapy (ART) in HIV associated TBM.<sup>11</sup> Little is known about the incidence, case fatality, underlying immunopathology and treatment approaches in HIV-infected children with neurological TB-IRIS. In my case series, I found that neurological TB-IRIS should be considered when new neurological signs develop after initiation of ART in children with TBM.<sup>12</sup> Manifestations of neurological TB-IRIS include headache, seizures, meningeal irritation, decreased level of consciousness, ataxia and focal motor deficit.

The mainstay of therapy in TB-IRIS in adults are corticosteroids with interruption of ART reserved for patients with severe life threatening complications or where the complication can cause disability.<sup>13</sup> Other immune-modulating treatments are only described in adults with no reports in children. Studies are thus warranted to determine the optimal time of ART initiation in HIV-infected children with TBM. The extrapolation of adult data that support therapeutic

delay may not always be appropriate in young children who experience higher mortality in the absence of ART.

Neurological TB mass lesions (tuberculomas/TB pseudo-abscesses) are known to develop or enlarge despite appropriate anti-TB treatment.<sup>14</sup> This form of TB, assumed to be associated with IRIS, is often more severe in the setting of HIV co-infection and may be life threatening. It typically occurs within the first three months of anti-TB therapy.<sup>12</sup> These lesions respond poorly to anti-TB treatment, and may require surgical excision, but may be responsive to thalidomide, a potent tumour necrosis factor-alpha (TNF- $\alpha$ ) inhibitor.<sup>15</sup> I found that serial magnetic resonance imaging (MRI) is of critical importance in identifying the nature of the necrotizing process, and evaluating treatment response and duration.<sup>16</sup> The rapid clinical response of our patients supports our interpretation that thalidomide provides substantial clinical benefit. I also identified a MRI marker of cure i.e. evolution of lesions from early stage “T2 bright” with oedema to “T2 black.” This finding will be useful to clinicians managing these patients.

The thalidomide study was an uncontrolled study by choice as a control group receiving a placebo would have been ethically unjustified. All the TB pseudo-abscess children were critically ill and the lesion location within the basal cisterns precluded surgical management. A study limitation was failure to evaluate CSF cytokine profiles (especially TNF- $\alpha$  and interferon [IFN]- $\gamma$  levels) at baseline (onset of disease), onset of TB-IRIS and after adjuvant thalidomide therapy. Studies have shown that hypercytokinemia contribute to the pathology of TBM-IRIS.<sup>17</sup> Recently, a combination of high CSF TNF- $\alpha$  and low IFN- $\gamma$  concentrations was found to be predictive of TBM-IRIS.<sup>18</sup> Larger prospective studies are needed to elucidate the predictive and diagnostic value of IRIS biomarkers in children with TBM and advance them to clinical practice.

The in-vitro down-regulating ability of thalidomide has not always been reproducible in-vivo.<sup>19</sup> Some studies even report no reduction in plasma TNF- $\alpha$  level in patients on thalidomide treatment.<sup>20-21</sup> Accurate measurement of TNF- $\alpha$  is difficult as it has a short half life; the normal circulating level has not been defined, its release in response to systemic infection is often phasic and serum or CSF levels may not accurately reflect TNF- $\alpha$  activity.<sup>19</sup> The latter is due to the fact that only the circulating form (not the membrane bound fraction) is typically measured. It furthermore remains a mystery how the brain-blood-barrier (BBB) is breached in human TBM infected patients. No animal study has yet achieved breach of the

BBB from experimental systemic infection as is the case in natural human infection. Animal studies thus represent artificial models of infection and TNF- $\alpha$  levels obtained from animal TBM studies should be interpreted with caution.

Host genetics (polymorphisms in TLR2, TIRAP and LTA4H genes) has been shown to influence susceptibility to TBM.<sup>22</sup> Recently, a functional single nucleotide polymorphisms (SNP) was identified in a gene (LTA4H locus) which controls the balance of pro-and anti-inflammatory eicosanoids.<sup>23</sup> In TBM patients, the SNP (LTA4H-high genotype) was associated with inflammatory cell recruitment, increased TNF- $\alpha$  production and patient survival. In this study, only those patients with the LTA4H-high genotype benefited from adjunctive corticosteroids. The impact of LTA4H genotype on corticosteroid effect requires further exploration. If validated, it opens up the exciting prospect of genotype-directed adjunctive therapy. These findings lend support to the assertion that future adjunctive therapies should target eicosanoids and TNF- $\alpha$  more precisely. It is my experience that thalidomide (a TNF- $\alpha$  antagonist) might be effective in controlling the adverse inflammatory complications of TBM where other treatment modalities such as corticosteroids have failed.

A previously conducted RCT evaluating adjunctive thalidomide therapy for childhood TBM at our site had to be terminated early because all adverse events and deaths occurred in the thalidomide study group.<sup>24</sup> Of importance, is that all the deaths (n=4) in this study occurred in children with severe neurological compromise on admission and that the prescribed thalidomide dose was 24 mg/kg/day. Subsequent studies at our site suggest that low dose thalidomide (3-5 mg/kg/day) is safe and effective in the treatment of TB mass lesions and vision-threatening optochiasmic arachnoiditis.<sup>15, 25</sup> In the near future, we hope to obtain funding and ethical approval to carry out a RCT evaluating efficacy of low dose adjunctive thalidomide (with LTA4H genotyping) in children with TBM.

The value of aspirin's antithrombotic, anti-ischemic and anti-inflammatory properties in TBM was explored in two studies. An adult TBM study reported a significant reduction in mortality at 3 months.<sup>26</sup> In contrast, a RCT in children found no significant benefit in mortality and morbidity at 6 months.<sup>27</sup> Acetylsalicylic acid (ASA), the active ingredient of aspirin, has been shown to decrease infection in LTA4H-high animals while increasing it in their LTA4H-low siblings.<sup>23</sup> This finding highlights the importance of LTA4H-genotyping in future aspirin intervention trials.



My Transcranial Doppler imaging (TCDI) study found that the pulsatility index (PI) is not a useful index of identifying raised intracranial pressure (ICP) in children with TBM.<sup>28</sup> No decline in PI was noted in all four children who underwent CSF diversion. Larger studies are warranted to investigate this finding and should ideally include pre-and post surgical ICP monitoring. The study re-affirmed my previous experience that diuretic and anti-TBM therapy rapidly normalizes ICP in children with tuberculous hydrocephalus.

Previously, opinion was divided as to whether narrowing of the large basal arteries in TBM represents functional spasm or organic stenosis.<sup>29</sup> Angiographic studies do not differentiate stenosis or spasm as a cause of vessel narrowing. Our finding of persistent high blood flow velocities (BFV) in all the basal cerebral arteries suggests stenosis due to vasculitis rather than functional vasospasm.

Regarding the use of TCDI in children with tuberculous cerebral vasculopathy, complete middle cerebral artery (MCA) occlusion, subnormal mean MCA velocities (less than 40 cm/s) and reduced PI (less than 0.4) correlated with radiological proven large cerebral infarcts. TCDI is therefore not sensitive enough to detect smaller territory infarcts; a finding that I attributed to the fact that the hemodynamics of the MCA is not affected by occlusion of a limited number (one or two) of the 9 MCA perforators.

A limitation of the TCDI study was the small sample size and the fact that only 4 children with non-communicating tuberculous hydrocephalus were included. Another limitation was that blood flow velocities in the basal cerebral arteries were only monitored for 7 days. Prolonged monitoring may have provided additional information on the duration of the stenosis. Lack of concomitant magnetic resonance angiography (MRA) also limited our ability to identify occlusion of the MCA perforators.

Even with the best medicines and diagnostic/treatment modalities, outcomes in TBM will remain poor if diagnosis is delayed. Our efforts should be on increased awareness and earlier diagnosis.

## References

1. van Toorn R, Springer P, JA Loubser et al. Value of different staging systems for predicting neurological outcome in childhood tuberculous meningitis. *Int J Tuberc Lung Dis* 2012; 16:628-632.
2. Wait JW, Schoeman JF. Behaviour profiles after tuberculous meningitis. *J Trop Pediatr* 2010;56:166-171.
3. van Well GT, Paes BF, Terwee CB et al. Twenty years of pediatric tuberculous meningitis:a retrospective cohort study in the Western Cape of South Africa. *Pediatrics* 2009; 123(1):e1-8
4. Misra UK, Kalita J, Maurya PK. Stroke in tuberculous meningitis. *J Neurol Sci* 2011;303:22-30.
5. Woodfield J, Argent A. Evidence behind the WHO guidelines: hospital care for children: what is the most appropriate treatment for tuberculous meningitis? *J Trop Pediatr* 2008; 54:220-224.
6. Chiang SS, Khan FA, Milstein BM et al. Treatment outcomes of childhood tuberculous meningitis; a systematic review and meta-analysis. *Lancet Infect Dis* 2014; 10:947-957.
7. van Toorn R, Schaaf HS, Laubsher JA et al. Short intensified treatment in children with drug-susceptible tuberculous meningitis. *Pediatr Infect Dis J* 2014; 33:248-252.
8. Ruslami R, Ganiem AR, Dian S, et al. Intensified regimen containing rifampicin and moxifloxacin for tuberculous meningitis: an open-label randomised controlled phase 2 trail. *Lancet Infect Dis* 2013; 13:27-35.
9. Kalita J, Misra UK, Prasad S et al. Safety and efficacy of levofloxacin versus rifampicin in tuberculous meningitis: an open-label randomized controlled trail. *J Antimicrob Chemother* 2014; 69:2246-2251.

10. Thwaites GE, Bhavnani SM, Chau TT, et al. Randomized pharmacokinetic and pharmacodynamic comparison of fluoroquinolones for tuberculous meningitis. *Antimicrob Agents Chemother* 2011; 55:3244-3253.
11. Link-Gelles R, Moultrie H, Sawry S et al. Tuberculosis Immune Reconstitution Inflammatory Syndrome in children initiating antiretroviral therapy for HIV infection: a systematic literature review. *Pediatr Infect Dis J* 2014; 33:499-503.
12. van Toorn R, Rabie H, Dramowski A et al. Neurological manifestations of TB-IRIS: a report of 4 children. *Eur J Paediatr Neurol* 2012; 16:676-82.
13. Marais S, Wilkinson RJ, Pepper DJ et al. Management of patients with immune reconstitution inflammatory syndrome. *Curr HIV/AIDS* 2009; 6:162-171.
14. Afghani B, Lieberman JM. Paradoxical enlargement or development of intracranial tuberculomas during therapy: case report and review. *Clin Infect Dis* 1994; 19:1092-1099.
15. Schoeman JF, Fieggen G, Sella N et al. Intractable intracranial tuberculous infection responsive to thalidomide: report of 4 cases. *J Child Neurol* 2006; 21:301-308.
16. van Toorn R, du Plessis A, Schaaf HS et al. Clinico-radiological response of neurological tuberculous mass lesions in children treated with thalidomide. *Pediatr Infect Dis J* 2015; 34:214-218.
17. Tadokera R, Meintjies G, Skolimowska KH et al. Hypercytokinemia accompanies HIV-tuberculosis immune reconstitution inflammatory syndrome. *Eur Respir J* 2011; 37:1248-1259.
18. Marais S, Wilkinson KA, Lesosky M et al. Neutrophil-associated central nervous system inflammation in tuberculous meningitis immune reconstitution inflammatory syndrome. *Clin Infect Dis* 2014; 59:1638-1647.
19. Calabrese L, Reszak K. Thalidomide revisited: pharmacology and clinical applications. *Expert Opin Investig Drugs*. 1998;7:2043-2060.

20. Bekker LG, Haslett P, Maartens G et al. Thalidomide-induced antigen specific immune stimulation in patients with human immunodeficiency virus type 1 and tuberculosis. *J Infect Dis* 2000; 181:954-965.
21. Gori A, Rossi MC, Trabattoni D et al. Tumour necrosis factor- $\alpha$  increased production during thalidomide treatment in patients with tuberculosis and human immunodeficiency virus co-infection. *J Infect Dis* 2000; 182:639-640
22. Tobin DM, Vary JC, Ray JP, et al. The ITA4H locus modulates susceptibility to mycobacterial infection in zebrafish and humans. *Cell* 2010; 140:717-730.
23. Tobin DM, Roca FJ, Oh SF, et al. Host genotype-specific therapies can optimize the inflammatory response to mycobacterial infections. *Cell* 2012; 148:434-446.
24. Schoeman JF, Springer P, van Rensburg AJ et al. Adjunctive thalidomide for childhood tuberculous meningitis: results from a randomized study. *J Child Neurol* 2004;19:250-257.
25. Schoeman JF, Andronikou S, Stefan DC, et al. Tuberculous meningitis-related optic neuritis: recovery of vision with thalidomide in 4 consecutive cases. *J Child Neurol* 2010; 25:822-888.
26. Misra UK, Kalita J, Nair PP. Role of aspirin in tuberculous meningitis: a randomized open label controlled trial. *J Neurol Sci* 2010; 293:12-17.
27. Schoeman JF, Janse van Rensburg A, Laubsher JA et al. The role of aspirin in childhood tuberculous meningitis. *J Child Neurol* 2011; 26:956-962.
28. Van Toorn R, Schaaf HS, Solomons R et al. The value of transcranial Doppler imaging in children with tuberculous meningitis. *Childs Nerv Syst* 2014;30:1711-1716.
29. Lammie GA, Hewlett RH, Schoeman JF ET AL. Tuberculous cerebrovascular disease: a review. *J Infect* 2009; 59:156-166.

**Other tuberculosis meningitis-related manuscripts completed during the study period**

1. Omar N, Andronikou S, van Toorn R, Pienaar M. Diffusion-weighted magnetic resonance imaging of borderzone necrosis in paediatric tuberculous meningitis. *J Med Imaging Radiat Oncol* 2011;55(6):563-70
2. Wolzak NK, Cooke ML, Orth H, van Toorn R. The changing profile of pediatric meningitis at a referral centre in Cape Town, South Africa. *J Trop Pediatr* 2012;58(6):491-5
3. Andronikou S, Govender N, Ramdass A, van Toorn R. MRI appearances of tuberculosis meningitis in HIV-infected children: a paradoxically protective mechanism? *Imaging Med* 2012;4(3):359-366
4. Schoeman JF, van Toorn R. Tuberculosis. *Central Nervous System Infections in Childhood. International Review of Child Neurology Series*. 2014;14, 202-218



## **Acknowledgements**

The work involved in this thesis could not have been carried out without enormous help from a number of persons, to whom I owe a great debt of gratitude:

Professors Johan Schoeman, and Simon Schaaf, my PHD promoters, for supporting me during the past three years; for their insightful guidance, persistent encouragement and willingness to help. I consider myself very fortunate to have two world experts in the field of childhood tuberculous meningitis as my mentors.

Mrs. Rosemary Meyer: for teaching me the basics of transcranial Doppler ultrasonography.

Mrs. Ria Laubscher: for statistical analysis in three of the publications.

Professors Peter Donald, Richard Hewlett, Drs Regan Solomons, Pricilla Springer, Anne-Marie du Plessis and Guy Thwaites: for their intellectual contributions to the design, analysis and writing of the various publications.

Professor Mariana Kruger, for her constant encouragement and willingness to allow 3 months of sabbatical leave during Dec 2012-Feb 2013 which led to the completion of 2 of the manuscripts.

The financial support of the University of Stellenbosch, the Harry Crossley Foundation and the Rotary Club of Blouberg.

## **Funding**

This project was made possible by the following generous contributions which allowed for the purchase of low frequency Transcranial Doppler probes.

1. The Rotary Club of Blouberg, Cape Town, District 9350: R 50 000
2. Department of Pediatrics and Child Health Trust fund, Stellenbosch University: R28 000
3. The Harry and Doris Crossley foundation: R14 000

### List of abbreviations

ACA	anterior cerebral artery
APACHE	Acute Physiology and Chronic Health Evaluation
ADIH	Anti-TB drug-induced hepatotoxicity
ALT	alanine transferase
AUC	area under curve
BCG	Bacillus Calmette-Guerin
BFV	blood flow velocities
cART	combination antiretroviral therapy
CBF	Cerebral blood flow
CI	confidence interval
CNS	central nervous system
CSF	cerebrospinal fluid
CT	computed tomography
CXR	chest radiograph
DQ	developmental quotient
ETH	ethionamide
ETV	endoscopic third ventriculostomy
GCS	Glasgow coma score
HIV	human immune deficiency virus
ICP	intracranial pressure
IGRAs	interferon gamma release assays
INH	isoniazid
IRIS	immune reconstitution inflammatory syndrome
MCA	middle cerebral artery
MDR	multi-drug resistance
MMF	mycophenylate mofetil
MRA	magnetic resonance angiography
MRC	medical research council
MRI	magnetic resonance Imaging
NAATs	nucleic acid amplification techniques
PCA	posterior cerebral artery
PCR	polymerase chain reaction
PI	pulsatility index
PZA	pyrazinamide
RMP	rifampicin
SA	South Africa
TBAN	tuberculosis meningitis acute neurology score
TBM	tuberculous meningitis
TCDI	transcranial doppler imaging
TCH	Tygerberg Children's hospital
TNF- $\alpha$	tumour necrosis factor alpha
TST	tuberculin skin test
VPS	ventriculoperitoneal shunt
WHO	World Health Organization