

# Pancreatic transplantation in a patient with severe insulin resistance

## A case report

D. F. DU TOIT, J. J. HEYDENRYCH, A. R. COETZEE, M. WEIGHT

### Summary

A 22-year-old white woman with insulin-dependent diabetes mellitus of 20 years' duration and advanced secondary complications underwent pancreatic transplantation for severe insulin resistance and rapidly progressive nephropathy. Resistance to all forms and strengths of subcutaneously administered insulin had necessitated almost permanent hospitalisation for the previous 10 years. Short-term improvement of the endocrine and metabolic status was achieved by initial segmental and subsequent whole pancreatic transplantation.

*S Afr Med J* 1988; 73: 723-725.

Since the early unsuccessful attempts 20 years ago, significant progress has been made in pancreatic transplantation for the treatment of selected insulin-dependent diabetics with secondary complications. In most units pancreatic transplantation has been reserved for uraemic diabetics undergoing renal transplantation for end-stage renal failure and is performed either synchronously or dysynchronously with the kidney transplant.<sup>1-4</sup> More recently, researchers have performed pancreatic transplantation without concomitant renal transplantation at an earlier stage in diabetics with rapidly progressive nephropathy in the pre-uraemic phase of the disease.<sup>5,6</sup> The object of earlier transplantation is to normalise glucose homeostasis and thus forestall progression of the micro-angiopathy which results in secondary complications affecting the retina, nerves and kidneys. In contrast with those uraemic patients undergoing combined renal and pancreatic transplantation these non-uraemic recipients undergo engraftment of the pancreas without kidney transplantation.

The metabolic and endocrine changes after initial segmental and subsequent whole pancreatic transplantation are reported.

### Case report

A 22-year-old woman who had had insulin-dependent diabetes mellitus for 20 years and now had advanced secondary compli-

cations and severe insulin resistance was admitted to Tygerberg Hospital for evaluation and pancreatic transplantation. Complications included advanced coronary artery disease, autonomic and peripheral neuropathy, progressive nephropathy in the pre-uraemic phase and partial blindness together with background retinopathy. Complete resistance to all forms and strengths of subcutaneously administered insulin for the previous 10 years had necessitated almost permanent hospitalisation for intraperitoneal or intravenous administration of insulin. Continuous or intermittent insulin administration via intraperitoneal Tenkhoff catheters or intravenous central lines was plagued by peritonitis or septicaemia. Insulin pumps proved impractical in the long term and only functioned effectively for short periods. The patient's average intravenous and intraperitoneal insulin requirement ranged from 90 U to 150 U/d and her blood glucose levels fluctuated between 15 mmol/l and 30 mmol/l. Adequate control of the diabetes on a long-term basis, despite the use of insulin pumps, intraperitoneal insulin and near-permanent hospitalisation, had never been achieved.

The patient received a segmental, cadaveric, HLA-DR mismatched, intraperitoneal, Ethibloc duct-occluded allograft which was anastomosed to the left iliac vessels. An opiate-diazepam relaxant anaesthetic technique was used and a pulmonary artery catheter was required to quantify the cardiopulmonary status intra- and postoperatively.

The postoperative course was uneventful and no technical complications were experienced. An intact graft was demonstrated on a technetium-99m scan (Fig. 1) and on computed tomography of the pelvis.

Segmental pancreatic transplantation made the patient mildly hyperglycaemic, less insulin-dependent, easily manageable and non-ketotic for 2 months, at which stage graft deterioration became apparent, reflected by an increased daily insulin requirement. The immunosuppressive agents administered were triple drug therapy with cyclosporin A (CSA), azathioprine and prednisone. T-cell subsets after segmental pancreatic transplantation are shown in Table I. Frequent CSA blood level determinations were performed by radio-immunoassay to maintain levels between 200 ng/ml and 400 ng/ml. Moderate improvement of the lipid profile (Table II), nerve velocity conduction studies, exercise tolerance and cardiac status was observed. Two months after transplantation the Hb A<sub>1c</sub> level was 9,5%. Retinopathy and renal status remained unchanged. In the short term, the patient's quality of life was dramatically improved.

An additional intraperitoneal cadaveric whole pancreas with Ethibloc duct occlusion but without duodenum was engrafted in the right iliac fossa after 10 weeks. The patient received anti-

**TABLE I. T-CELL SUBSETS (%) AFTER SEGMENTAL PANCREATIC TRANSPLANTATION AND IMMUNOSUPPRESSION WITH CSA, AZATHIOPRINE AND PREDNISONE**

Subset	Before transplant	Days after transplantation		
		Day 5	Day 20	Day 37
OKT3	—	75	66	83
OKT4	47	34	23	32
OKT8	33	33	48	48
OKT11	75	79	68	77
T4/T8 ratio	1,4	1,03	0,47	0,66

Departments of Surgery and Anaesthetics, University of Stellenbosch and Tygerberg Hospital, Parowvallei, CP

D. F. DU TOIT, D.PHIL., PH.D., F.C.S. (S.A.), F.R.C.S.

J. J. HEYDENRYCH, M.S.C., M.MED. (PAED. SURG.)

A. R. COETZEE, M.D., PH.D., M.MED. (ANAES.), F.F.A., F.F.A. R.C.S.

Research Institute for Nutritional Diseases of the South African Medical Research Council, Parowvallei, CP

M. WEIGHT, PH.D.

Accepted: 22 Jan 1988.

Reprint requests to: Professor D. F. du Toit, Dept of Surgery, Tygerberg Hospital, PO Box 63, Tygerberg, 7505 RSA.

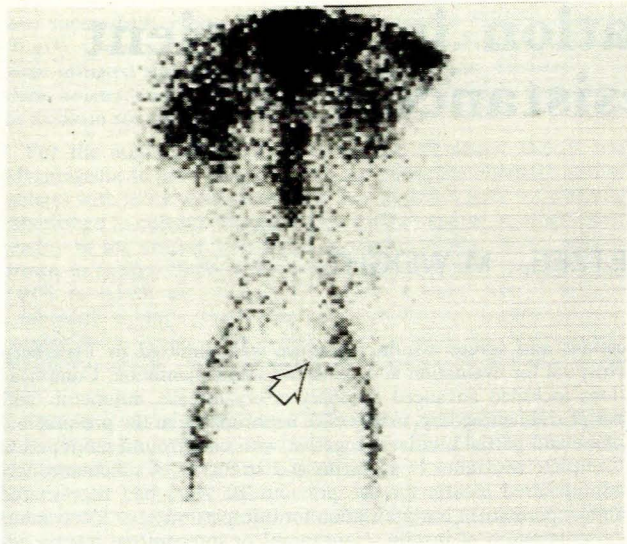


Fig. 1. Technetium-99m pancreatic scan 1 week after transplantation showing uptake in the segmental allograft (arrow).

coagulants and the cold ischaemic time of the graft was 3,5 hours. Postoperatively the patient was rendered normoglycaemic and insulin-independent without glycosuria or ketonuria after 24 hours. No technical complications were encountered.

Graft rejection on day 10 postoperatively necessitated its removal. Histology showed features of acute rejection. Rejection was suspected on the 8th postoperative day because of a sudden increase in the plasma amylase levels but steroid pulse antirejection therapy failed to counteract rejection. An intravenous glucose tolerance test (IVGTT) performed 5 days after whole-organ transplantation (Fig. 2) revealed normoglycaemia (plasma glucose < 8 mmol/l), near-normal glucose tolerance with improved K values (1,26 mmol/min), near-normal fasting values (0,9 ng/ml), stimulated plasma C-peptide levels (2,1 ng/ml) and an improved C-peptide/body mass index (BMI) score (2,75), C-peptide/glucose score (1,00) and glucose/BMI score 278. BMI (kg/m<sup>2</sup>) was 36,3 kg/m<sup>2</sup>. Modest improvement of plasma cholesterol and triglyceride fractions was observed while the graft functioned (Table II). C-peptide and glucagon release during IVGTT is reflected in Fig. 3.

After removal of the graft, the patient had recurrent pulmonary emboli, persistent pyrexia, superficial wound infection and septicaemia directly related to an indwelling intravenous subclavian catheter. The patient died of a cerebral haemorrhage 5 months after admission to hospital. Before the cerebral haemorrhage she required insulin 50 U intravenously daily, which indicated some residual function of the segmental allograft because her pre-transplant requirement had fluctuated between 90 U and 150 U/d. Low levels of C-peptide remained detectable in the urine.

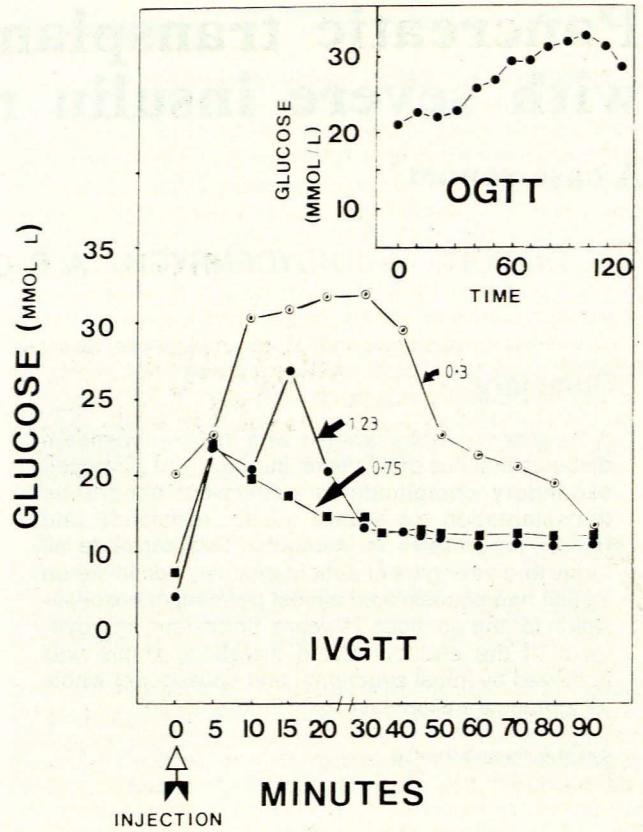


Fig. 2. IVGTT before transplantation ○—○; after segmental ◻—◻; and whole pancreatic transplantation ●—●. (Insert: oral glucose tolerance test 1 month after segmental pancreatic transplantation.)

### Discussion

This case shows that segmental pancreatic transplantation can stabilise the brittle endocrine status of selected insulin-dependent diabetics with severe insulin resistance who are refractory to more conventional forms of treatment. However, despite initial good function, segmental transplantation could not make the patient insulin-independent or normalise the plasma glucose values. This was attributed to the graft having an insufficient islet cell mass.

Subsequent transplantation of a whole pancreas did, in the short term, make the patient normoglycaemic and restored the

TABLE II. PLASMA LIPOPROTEIN FRACTIONS AFTER SEGMENTAL AND WHOLE PANCREATIC TRANSPLANTATION (mg/dl)

Transplant	Fraction	VLDL	IDL	LLDL	LDL	HDL	HDL3	HDL2	Plasma
Segmental pancreas	Cholesterol	28	15	23	102	46	32	14	224
	Triglyceride	120	45	28	26	14	5	9	243
	APO A1	—	—	—	—	100	84	16	104
	APO A11	—	—	—	—	25	21	4	26
	APO B	—	—	—	—	—	—	—	95
Whole pancreas	Cholesterol	20	10	28	54	58	35	23	180
	Triglyceride	97	20	15	12	6	2	4	149
	APO A1	—	—	—	—	83	54	29	85
	APO A11	—	—	—	—	25	22	3	25
	APO B	—	—	—	—	—	—	—	72

Pre-transplant values: cholesterol 320 mg/dl and triglyceride 280 mg/dl (fractions not performed). VLDL = very-light density lipoprotein; IDL = intermediate-density lipoprotein; LLDL = light low-density lipoprotein; LDL = low-density lipoprotein; HDL = high-density lipoprotein; APO = apolipoprotein.

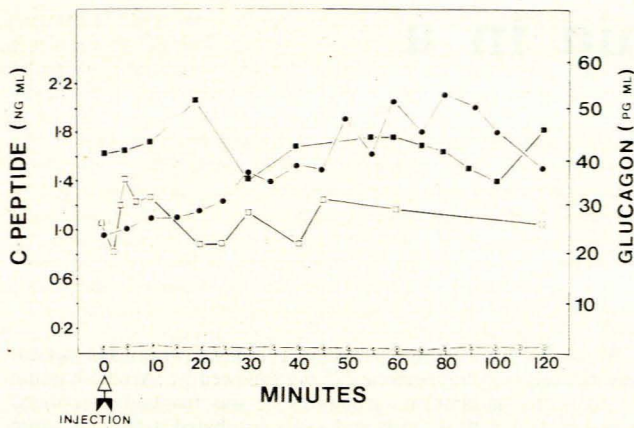


Fig. 3. IVGTT showing C-peptide release before transplantation ○—○, and after whole pancreas transplantation ●—●, together with glucagon stimulation after segmental □—□, and whole organ replacement ■—■.

endocrine profile to near normal while the graft functioned. Experience by other groups indicates that about 60-70% of pancreatic allograft recipients will have normal glucose tolerance and only a small proportion will be insulin-dependent.<sup>7</sup>

In our patient pancreatic transplantation was performed at an advanced stage of the disease at a time which was possibly too late to expect any significant effect on the outcome or degree of secondary complications. Although the observation period was short, the improvement in vision, peripheral neuritis, abnormal lipid profile, general well-being and cardiac status was important and indicates that some of the secondary complications are potentially reversible even at a late stage. Other groups have documented similar findings in the short term.<sup>1-4</sup> However, although stabilisation of advanced retinopathy and nephropathy has been observed, the reversal of these advanced lesions has not been shown.

The type of immunosuppression needed for pancreatic allograft recipients has remained controversial, but recent reports from the Minnesota group<sup>8</sup> indicate that triple-drug therapy consisting of a combination of CSA, azathioprine and prednisone may provide better graft survival rates. These results may be enhanced by the application of total lymphoid irradiation — as reported by the Johannesburg group<sup>9</sup> in renal allograft recipients, and the Stellenbosch group<sup>10,11</sup> in an experimental pancreatic transplantation model.

The international Pancreas Transplant Registry figures show that about 45% of combined kidney and pancreatic grafts are

functioning 2 years after engraftment and that combined grafting is now a relatively safe procedure.<sup>8</sup> A number of individual units have recently reported a 1-year pancreatic graft survival rate in excess of 60% which indicates that in future a greater number of successful grafts will be achieved.<sup>2</sup> The recent reports<sup>12,13</sup> referring to methods of diagnosing rejection at an earlier stage should also result in more grafts being salvaged.

This work was supported in part by grants from the Harry Crossley Fund and the South African Medical Research Council.

We thank the medical and nursing staff of Ward A1, Tygerberg Hospital, Drs J. A. Groenewald, C. F. Pretorius, M. Greef, B. Barnard and W. van der Merwe, the Departments of Nuclear Medicine, Radiology, Chemical Pathology and Haematology, Messrs D. Els, A. Weideman, H. Davids, J. Matthyse and Mrs M. Marais for technical assistance. We also thank Professor W. J. Kalk for referring the patient, Dr B. Ford for advice, Dr J. G. L. Strauss, Medical Superintendent of Tygerberg Hospital, for permission to publish, and Professor F. S. Hough for reviewing the manuscript.

#### REFERENCES

- Sutherland DER, Goetz FC, Najarian JS. 100 pancreas transplants at a single institution. *Ann Surg* 1984; **200**: 414-438.
- Tyden G, Lundgren G, Ost L, Kojima Y, Gunnarson R, Ostman J, Groth CG. Progress in segmental pancreatic transplantation. *World J Surg* 1986; **10**: 404-409.
- Corry RJ, Nghiem DD, Schulak JA, Beutel WD, Gonwa TA. Surgical treatment of diabetic nephropathy with simultaneous pancreaticoduodenal and renal transplantation. *Surg Gynecol Obstet* 1986; **162**: 547-555.
- Traeger J, Dubernard JM, Monti MD *et al*. Clinical experience with long-term studies of degenerative complications in man after pancreas transplantation. *Transplant Proc* 1986; **18**: 1750-1751.
- Sutherland DER, Goetz FC, Najarian JS. Pancreas transplantation. *Clin Chem* 1986; **32**: B83-B96.
- Sutherland DER. Pancreas transplantation in non-uraemic diabetic patients. *Transplant Proc* 1986; **18**: 1747-1749.
- Groth CG. Is pancreatic transplantation a justifiable form of treatment for diabetes mellitus. *Transplant Proc* 1986; **17**: 1737-1738.
- Sutherland DER, Moudry K. Pancreas Transplant Registry Report. *Transplant Proc* 1986; **17**: 1739-1746.
- Myburgh JA, Smit JA, Meyers AM, Botha JR, Browde S, Thompson PD. Total lymphoid irradiation in renal transplantation. *World J Surg* 1986; **10**: 369-380.
- Du Toit DF, Heydenrych JJ, Louw G *et al*. Prolongation of intraperitoneal segmental pancreatic allografts in primates receiving cyclosporin-A. *Surgery* 1984; **96**: 14-22.
- Du Toit DF, Heydenrych JJ, Smit B *et al*. Prolongation of segmental and pancreaticoduodenal allografts in the primate with total lymphoid irradiation and cyclosporin. *Transplantation* 1987; **44**: 346-350.
- Munda R, Tom WW, First MR, Gaartsides P, Alexander JW. Pancreatic allograft exocrine urinary tract diversion. *Transplantation* 1987; **43**: 95-99.
- Prieto M, Sutherland DER, Fernandez-Cruz L, Heil J, Najarian JS. Experimental and clinical experience with urine amylase monitoring for early diagnosis of rejection in pancreas transplantation. *Transplantation* 1987; **43**: 73-78.