

# Acute febrile neutrophilic dermatosis (Sweet's syndrome)

## A report of 2 cases

H. F. JORDAAN, F. H. DE GOEDE, M. SANDLER

### Summary

Two cases of Sweet's syndrome are described. The diagnostic criteria, clinical spectrum, complications, pertinent differential diagnoses and treatment modalities of this relatively rare clinical condition are described. The association of Sweet's syndrome with underlying haematological malignant disease is stressed.

*S Afr Med J* 1989; 75: 336-338.

In 1964 Sweet<sup>1</sup> reported 8 cases of a condition he called acute febrile neutrophilic dermatosis; this later became known as Sweet's syndrome. A diagnosis of Sweet's syndrome involves satisfying the 2 major criteria and at least 2 of the minor criteria.<sup>2</sup> The major criteria include: (i) the abrupt onset of a cutaneous eruption consisting of tender erythematous or violaceous plaques or nodules confined predominantly to sun-exposed areas; and (ii) neutrophilic infiltration in the dermis without evidence of a leucocytoclastic vasculitis. Minor criteria include: (i) a fever or infection which antedates the onset of the skin eruption; (ii) fever, polyarthralgia, conjunctivitis, haematuria and/or proteinuria accompanying the skin lesions; (iii) leucocytosis or underlying haematological malignant disease; and (iv) a good clinical response to systemic steroids in a lesion previously unresponsive to antibiotic therapy.

Two cases of Sweet's syndrome, 1 accompanied by fatal haematological malignant disease, are described.

### Case reports

#### Case 1

A 40-year-old woman presented to hospital with sudden onset of fever, diffuse myalgia, polyarthralgia and the development of painful skin lesions over the anterior chest wall and shoulders which later spread to involve the dorsal surfaces of the arms and legs. One month before, the patient had been treated for an upper respiratory tract infection.

On examination the patient was acutely ill, pyrexial and had a marked skin eruption involving the anterior and posterior thorax. This consisted of red papules and nodules approximately 0,5 - 2 cm in diameter, some of which had central vesicle formation (Fig. 1). Evidence of polyarthralgia was manifested by a reduced range of movement and tenderness to

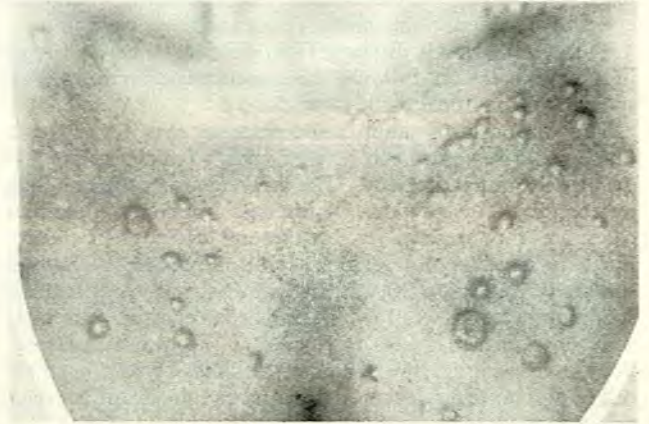


Fig. 1. Case 1 — red papules and nodules on the upper chest wall.

palpation of the following joints: shoulders, elbows, wrists, proximal interphalangeal, knees and ankles. Cardiovascular, abdominal and neurological examinations revealed no abnormalities.

**Special investigations:** A full blood count showed haemoglobin 11,9 g/dl, white cell count  $13 \times 10^9/l$  with 85% neutrophils, and erythrocyte sedimentation rate (ESR) 120 mm/1st h (Westergen). Urinalysis revealed haematuria, proteinuria, hyaline and granular casts. The following tests were either normal or negative: ECG, chest radiography, blood culture, protein electrophoresis, serology for viral and rickettsial infections, and collagen vascular disorder investigations which were negative for antinuclear and rheumatoid factors. Examination of biopsy specimens of the skin lesions revealed typical neutrophilic infiltrates without evidence of vasculitis; these were indicative of Sweet's syndrome (Fig. 2).



Fig. 2. Case 1 — histological section of a skin lesion showing spongiosis, sub-epidermal oedema and a nodular infiltrate of lymphocytes, mature neutrophils and nuclear dust.

Departments of Dermatology and Internal Medicine,  
University of Stellenbosch and Tygerberg Hospital, Parow-  
vallei, CP

H. F. JORDAAN, M.B. CH.B., M.MED. (DERM.)

F. H. DE GOEDE, M.B. CH.B.

M. SANDLER, M.B. CH.B., PH.D., M.R.C.P.

Reprint requests to: Dr M. Sandler, Dept of Internal Medicine, Tygerberg Hospital, PO Box 63, Tygerberg, 7505 RSA.

Accepted 10 Nov 1988.



Although the polyarthralgia improved slightly with the initial treatment of intramuscular injections of diclofenac sodium, once corticosteroids were started (prednisone 60 mg daily) the patient responded within 72 hours and the fever, skin lesions, polyarthralgia and myalgia abated. The steroids were gradually tapered off over the next month by which time the patient was asymptomatic and the skin lesions had completely cleared. The patient was followed up for a further month, found to be asymptomatic and then returned home to the Netherlands. She was subsequently lost to further follow-up.

## Case 2

A 73-year-old man presented to hospital with a 4-week history of intermittent fever, malaise, progressive loss of weight and the development of painful skin lesions on the side of the neck. He had no significant past medical history. Treatment by his general practitioner with tetracycline 250 mg 4 times daily had not altered the clinical course or affected the skin lesions and he was therefore referred to Tygerberg Hospital for further evaluation.

On examination the patient was afebrile, clinically anaemic with the presence of generalised lymphadenopathy, especially prominent in both axillae. Examination of the skin revealed the presence of two reddish-purple firm non-tender lesions approximately 3 x 3 cm in diameter on the right side of the neck. Both lesions showed evidence of early blister formation (Fig. 3). Examination showed that the cardiovascular, respiratory, abdominal and neurological systems were normal. A full blood count revealed the presence of a pancytopenia; the ESR was 140 mm/1st h (Westergren). The following investigations were normal or negative: urinalysis, blood chemistry, repeated blood cultures, liver function and chest radiography. Bone marrow aspirate and trephine biopsy showed the presence of acute myeloid leukaemia, which had developed against a background of myeloid dysplasia. Skin biopsy showed the presence of diffuse neutrophilic infiltration in the dermis without evidence of leucocytoclastic vasculitis. No immature cells were noted. A diagnosis of Sweet's syndrome was made in association with an underlying haematological malignant disease. Despite extensive therapy with fresh whole blood, granulocyte and platelet support in addition to numerous intravenous antibiotic regimens, the patient's course was that of rapidly progressive deterioration and subsequent death.

## Discussion

These 2 cases were chosen for discussion because: (i) both cases adequately fulfil the criteria for the diagnosis of Sweet's syndrome as set out by Su and Liu;<sup>2</sup> (ii) they emphasise the range of skin lesions found in Sweet's syndrome (case 1 — multiple, small, tender red nodules on sun exposed areas; case 2 — 2 large violaceous non-tender nodules); and (iii) the association of Sweet's syndrome with underlying haematological malignant disease is highlighted.

The majority of cases of Sweet's syndrome described thus far have involved women aged between 30 years and 60 years. However, cases involving children<sup>3</sup> and men<sup>4</sup> have been reported. Although in most cases the aetiology was idiopathic, the associations with Sweet's syndrome have included, among others, bronchiectasis,<sup>5</sup> lupus erythematosus,<sup>6</sup> rheumatoid arthritis,<sup>7</sup> sub-acute thyroiditis,<sup>8</sup> Dressler's syndrome,<sup>9</sup> and Behçet's disease.<sup>10</sup> However, the most important association with Sweet's syndrome is undoubtedly the presence of underlying malignant disease. In this context it must be noted that of all the cases of Sweet's syndrome described to date, 10-12% were associated with malignant disease.<sup>11</sup> These authors

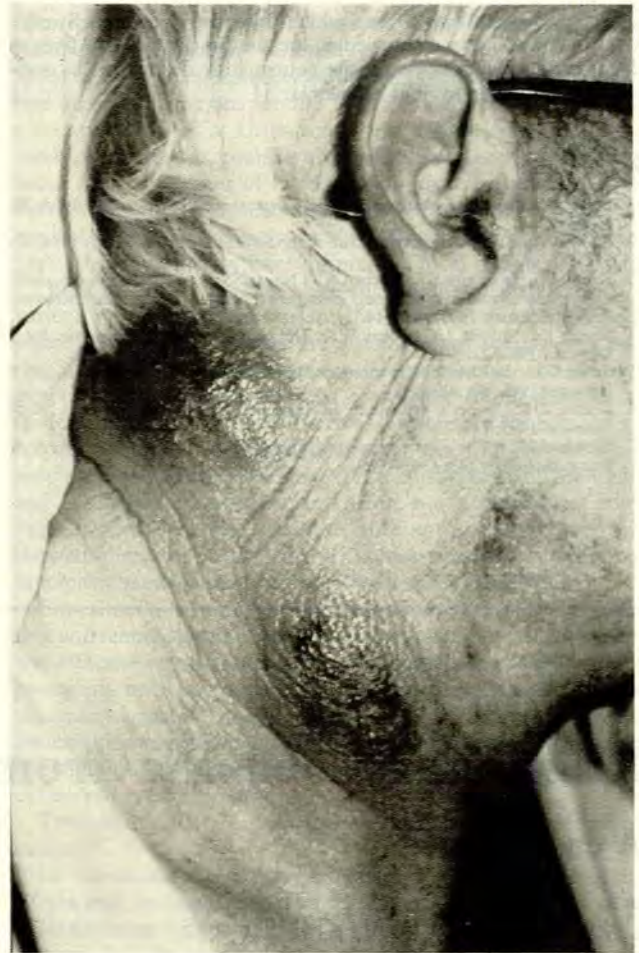

Fig. 3. Case 2 — two reddish purple tumours on the side of the neck.

reported 40 cases of Sweet's syndrome in association with malignant disease; 35 of these patients had evidence of a blood dyscrasia and the remaining 5 had solid neoplasms. In almost 50% of the patients with haematological malignant disease the diagnosis was acute myeloid leukemia.<sup>11</sup> Over the past decade Sweet's syndrome, atypical Sweet's syndrome, pyoderma gangrenosum and atypical pyoderma gangrenosum have been reported in association with various forms of leukaemia. These conditions most probably represent points on a continuum of non-infectious non-metastatic inflammatory neutrophilic dermatoses, which occur in patients with derangements in myeloid cell proliferation.<sup>12</sup> Since the clinical picture of Sweet's syndrome includes the presence of a fever, polyarthralgia, diffuse myalgia, conjunctivitis, painful skin rashes and a leucocytosis, the most relevant conditions to be considered in the differential diagnosis must include acute systemic infections (bacterial, rickettsial), collagen vascular disorders and acute blood dyscrasias. Successful treatment regimens for Sweet's syndrome have included the use of potassium iodide,<sup>13</sup> colchicine,<sup>14</sup> dapsone<sup>15</sup> and indomethacin.<sup>16</sup> However, short courses of high-dose corticosteroids are considered to be the treatment of choice.<sup>4</sup> The suggested dosage regimen involves a starting dose of 1 mg/kg/d which is gradually reduced in step-wise fashion over a period of 10-14 days. Although recurrences have been reported to occur in approximately 30% of cases owing to inadequate therapy,<sup>4</sup> in our experience (40 cases over 7 years) the relapse rate after completion of steroid therapy on the above dosage regimen occurred in less than 10% of cases.



We have described 2 cases which fulfil the criteria of Sweet's syndrome and, to our knowledge, are the first in South Africa to document a case of acute febrile neutrophilic dermatosis in association with acute myeloid leukaemia.

#### REFERENCES

1. Sweet RD. An acute febrile neutrophilic dermatosis. *Br J Dermatol* 1964; **76**: 349-356.
2. Su WPD, Liu HH. Diagnostic criteria for Sweet's syndrome. *Cutis* 1986; **37**: 167-174.
3. Kibbi AG, Zaynoun ST, Kurban AK, Najjar SS. Acute febrile neutrophilic dermatosis (Sweet's syndrome): case report and review of the literature. *Pediatr Dermatol* 1985; **3**: 40-44.
4. Storer JS, Nesbitt LT, Galen WK, DeLeo VA. Sweet's syndrome. *Int J Dermatol* 1983; **22**: 8-12.
5. Sweet RD. Further observations on acute neutrophilic dermatosis. *Br J Dermatol* 1968; **80**: 800-805.
6. Goette DK. Sweet's syndrome in subacute lupus erythematosus. *Arch Dermatol* 1985; **121**: 789-791.
7. Harary AM. Sweet's syndrome associated with rheumatoid arthritis. *Arch Intern Med* 1983; **143**: 1993-1995.
8. Alcalay J, Filhaber A, David M, Sandbank M. Sweet's syndrome and subacute thyroiditis. *Dermatologica* 1987; **174**: 28-29.
9. Rodriguez-de la Serna A, Domingo-Pedrol P, Blanch-Torra L, Perez-Perez A, Obrador-Mayol D. Acute febrile neutrophilic dermatosis (Sweet's syndrome) associated with post-myocardial infarction syndrome (Dressler's syndrome). *Arch Intern Med* 1985; **145**: 1522-1524.
10. Mizoguchi M, Chikakane K, Goh K, Asahina Y, Masuda K. Acute febrile neutrophilic dermatosis (Sweet's syndrome) in Behçet's disease. *Br J Dermatol* 1987; **116**: 727-734.
11. Cohen PR, Kurzrock R. Sweet's syndrome and malignancy. *Am J Med* 1987; **82**: 1220-1226.
12. Caughman W, Stern R, Haynes H. Neutrophilic dermatosis of myeloproliferative disorders: atypical forms of pyoderma gangrenosum and Sweet's syndrome associated with myeloproliferative disorders. *J Am Acad Dermatol* 1983; **9**: 751-758.
13. Horio T, Inamura S, Dunro K, Furukawa F, Ofuji S. Treatment of acute febrile neutrophilic dermatosis (Sweet's syndrome) with potassium iodide. *Dermatologica* 1980; **160**: 341-347.
14. Suehiza S, Tagami H, Inoue F, Matsumoto K, Yoshikuni K. Colchicine in the treatment of acute febrile neutrophilic dermatosis (Sweet's syndrome). *Br J Dermatol* 1983; **108**: 99-101.
15. Aram H. Acute febrile neutrophilic dermatosis (Sweet's syndrome): response to dapsone. *Arch Dermatol* 1984; **120**: 245-247.
16. Hoffman GS. Treatment of Sweet's syndrome (acute febrile neutrophilic dermatosis) with indomethacin. *J Rheumatol* 1977; **4**: 201-206.

## Pulmonary oedema from a widow spider bite

### A case report

L. H. VISSER, S. N. KHUSI

#### Summary

The clinical course of a patient bitten by a widow spider (*Latrodectus indistinctus* Pickard-Cambridge (Araneae: Theridiidae)) is described. Although this spider is common in southern Africa, case reports are rare. To date details of the development of pulmonary oedema after a bite have not been published in South Africa.

*S Afr Med J* 1989; **75**: 338-339.

Spiders are ubiquitous in southern Africa; however, most spider bites are either unrecognised or require little medical attention. A recent review<sup>1</sup> described the four spiders known to be medically important in southern Africa. They are divided into two categories according to the action of their venom — neurotoxic and cytotoxic.

The widow spider (*Latrodectus indistinctus* Pickard-Cambridge (Araneae: Theridiidae)) belongs to the neurotoxic group.<sup>1</sup>

The signs and symptoms that appeared in a healthy young woman after she had been bitten by *L. indistinctus* are described. The development of pulmonary oedema was an unusual complication; it has only been described once before.<sup>2</sup>

#### Case report

On 18 January 1988 a 24-year-old black woman was bitten on the left thigh by a spider. Severe pain was immediately experienced at the bite site. On the way to hospital she felt nauseous and vomited once.

On arrival at Tshilidzini Hospital the patient appeared very anxious and complained of generalised body pain and weakness. The blood pressure was 200/140 mmHg, pulse 88/min and temperature 36,6°C. No cellular reaction was seen at the bite site. The remainder of the physical examination was unremarkable. She was admitted for observation. Mepyramine maleate 50 mg and pethidine 50 mg were administered intramuscularly.

Over the next 24 hours the blood pressure normalised (120/80 mmHg), but the general malaise persisted and the patient developed a continuous headache, periods of shivering and profuse sweating. Intravenous fluids were then given.

Laboratory investigations showed a negative malaria smear and a white cell count of  $15,3 \times 10^9/l$ .

On the afternoon of 19 January the patient complained of difficulty in breathing with coughing of frothy sputum. On examination she appeared to be tachypnoeic and had bilateral basal crepitations on auscultation.

A chest radiograph showed obvious lung oedema. By that time a total amount of 450 ml of Ringer's lactate had been given intravenously. Urine output was good and there were no signs of cardiac failure. Immediate treatment with morphine 10 mg intramuscularly and aminophylline 250 mg slowly was started. Oxygen was administered and furosemide 40 mg was given intravenously 8 hourly.

Tshilidzini Hospital, PO Shayandima, Venda

L. H. VISSER, ARTS EXAMEN NEDERLAND

S. N. KHUSI, M.B.CH.B.