

Leiomyoma: a rare cause of adrenal incidentaloma

Alteer M, MBChB, Registrar; Department of Medicine, Endocrine Division, Tygerberg Academic Hospital.
Ascott-Evans BH, MBChB, FCP(SA), Head; Conradie M, MBChB, PhD, Consultant
Department of Medicine and Endocrine Division Tygerberg Academic Hospital
University of Stellenbosch, Cape Town
Correspondence to: Mohamed Alteer, e-mail: m_attir2000@yahoo.com
Keywords: leiomyoma, adrenal incidentaloma, HIV, Epstein-Barr virus, tumour

Abstract

A 40-year-old, treatment-naïve, human immunodeficiency virus- (HIV) positive male was found to have a large right adrenal incidentaloma on ultrasound of the abdomen, which was confirmed on adrenal computed tomography imaging. The laboratory workup excluded functionality of the mass lesion. As the radiological examination of the mass raised the suspicion of a non-benign lesion, the patient underwent a right adrenalectomy. Histology, supported by a panel of immunohistochemical stains, confirmed the diagnosis of an adrenal leiomyoma. Most of the reported cases of adrenal leiomyomas in the literature are of patients with HIV and/or latent Epstein-Barr virus infections. This case illustrates that benign tumours, such as leiomyomas, can mimic the imaging phenotype of adrenal cortical carcinomas, and should be included in the differential diagnosis of adrenal incidentalomas, especially in the HIV-positive population.

Peer reviewed. (Submitted: 2012-09-19. Accepted: 2013-01-24.) © SEMDSA

JEMDSA 2013;18(1):71-74

Introduction

An adrenal incidentaloma is a clinically inapparent adrenal mass, generally 1 cm or more in diameter, that is discovered inadvertently during a radiological examination performed for indications other than an adrenal disease evaluation.¹⁻³ These unsuspected adrenal incidentalomas are increasingly found because of the widespread use of technologically advanced imaging modalities.^{1,4} The majority of adrenal incidentalomas are either adrenal cortical tumours (adenomas or carcinomas) or adrenal medullary tumours (pheochromocytomas). A benign, clinically nonfunctioning adrenocortical adenoma is the most common cause of an incidentally discovered adrenal mass.⁵ However, the adrenal gland can give rise to a broad range of other tumour types. When an adrenal mass is incidentally discovered, a major concern is the possibility of an underlying malignant process, or the presence of a clinically silent pheochromocytoma. Certain radiological characteristics can indicate a high likelihood of malignancy. On computed tomography (CT) imaging, malignancy is suggested by a diameter that is greater than 4 cm, an irregular border, inhomogeneity, high pre-contrast Hounsfield units (HUs) (> 10) and limited washout of contrast after 10-15 minutes (< 50%).^{1,2,4}

In this case report, we describe a human immunodeficiency virus- (HIV) positive patient with an incidentally discovered adrenal mass who had an imaging phenotype that was suggestive of malignancy, but received a very different diagnosis on pathological examination.

Case presentation

A 40-year-old HIV-positive male presented to the neurologists at a tertiary hospital with a spastic paraparesis which had evolved over the preceding months, and a more recent onset of urinary incontinence. The patient was not on antiretroviral therapy and had a presenting CD4 count of 457. Likely causes of myelopathy were investigated. Spinal magnetic resonance imaging (MRI) showed no specific lesion, or any altered signals in the cord. Significant brain atrophy was noted on CT scan. A cerebrospinal fluid examination ruled out tuberculosis meningitis. The rapid plasma reagin test for *Treponema pallidum* was negative and vitamin B₁₂ deficiency was ruled out. His neurological picture stabilised, but the aetiology of his paraparesis remained obscure. The patient had abnormal liver function tests and complained of discomfort in the liver area. An ultrasound of his abdomen was performed and demonstrated a large

mass in the right hypochondrium. An abdominal CT scan confirmed this mass to be located in the right adrenal gland. He was referred for an endocrine assessment. A physical examination revealed the patient to be normotensive, without any stigmata of Cushing's syndrome.

The laboratory evaluation aimed to exclude subclinical Cushing's syndrome primarily, as well as an asymptomatic pheochromocytoma. A late-night serum cortisol, a serum dehydroepiandrosterone sulphate level, 24-hour urine total metanephrines and 24-hour urine cortisol determinations were performed, all of which were within normal limits. A serum cortisol undertaken at 08h00 (after 1 mg bethamethasone the night before) was 33 nmol/l, and effectively ruled out the presence of a cortisol-producing adenoma. Evaluation for Conn's tumour was not deemed to be necessary as the patient's normotensive state was confirmed repeatedly during admission. Therefore, the mass was assessed as nonfunctional.

A contrasted CT scan showed a right adrenal mass measuring 49 x 55 x 60 mm (Figure 1). The lesion demonstrated heterogeneous contrast enhancement with a clear central area of decreased attenuation, suggesting tumour necrosis. The periphery of the lesion measured 40 HUs pre-contrast. The centre of the mass measured approximately 14 HUs. Very limited washout of contrast was noted on delayed images. No regional lymphadenopathy, nor any other intra-abdominal pathology, was noted on the CT images. The radiological differential diagnosis included an adrenal cortical carcinoma or a pheochromocytoma with central necrosis.

The patient was referred for surgery because of the size of the lesion and the non-benign radiological appearance of the mass. The surgeon obtained open access below the right costal margin and the tumour was completely removed without any intra- or perioperative complications. The resected specimen weighed 91 g and measured 80 x 70 x 50 mm. Macroscopically, the tissue had a white appearance and there was no bleeding, ulceration or necrosis. Histology revealed a well-circumscribed and encapsulated smooth muscle tumour comprising bland, spindle-shaped cells. No features of mitosis, areas of necrosis or pleomorphism were present. The following panel of immunohistochemical stains supported the diagnosis of an adrenal gland leiomyoma: muscle-specific actin and desmin showed diffuse staining within the smooth muscle cells. CD 117, a marker for gastrointestinal stromal tumours, and S100, a neural and melanocytic marker, were both negative within the tumour cells.

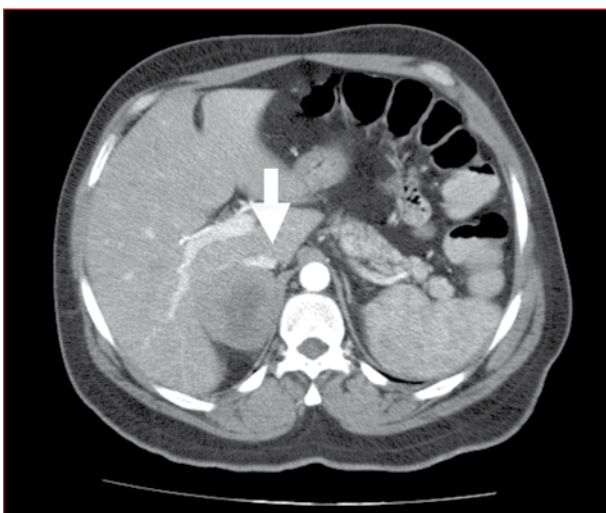


Figure 1: Contrast-enhanced computed tomography showing a large, right adrenal mass (arrow) with a central region of low enhancement

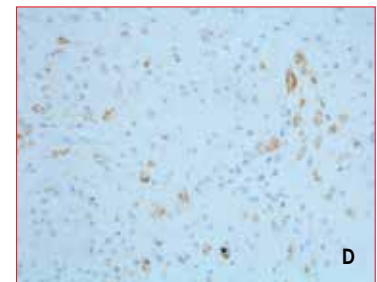
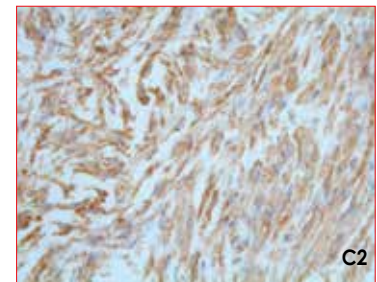
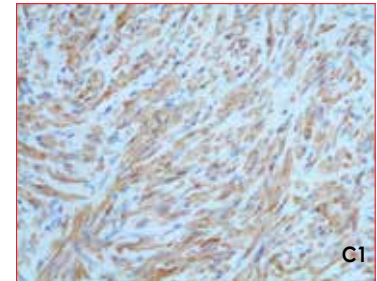
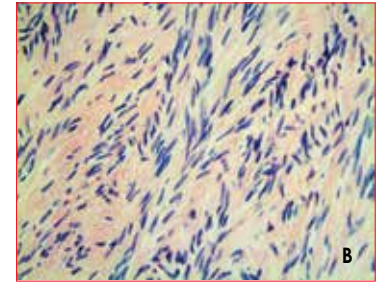
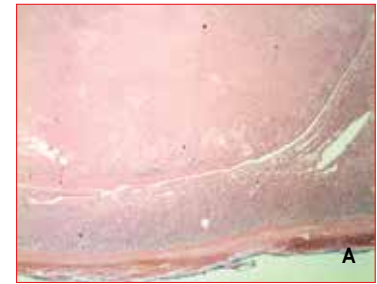


Figure 2 a-e: Histopathology and immunochemistry. *Figure 2 a:* A low-power view indicating a well-encapsulated white tumour with central scarring (haematoxylin and eosin staining). *Figure 2 b:* A high-power view of the leiomyoma showing bland, spindle-shaped cells with no mitotic figures. Immunohistochemistry for desmin (*Figure 2 c*) and muscle-specific actin (*Figure 2 d*) demonstrating diffuse cytoplasmic staining within the tumour cells. *Figure 2 e:* Immunohistochemistry for latent membrane protein-1 was positive for the presence of the Epstein-Barr virus.

Immunohistochemistry for latent membrane protein-1 of Epstein-Barr virus confirmed the presence of the Epstein-Barr virus (Figure 2 a-e).

Discussion

The term “adrenal incidentaloma” is used to describe an adrenal mass that is discovered during imaging that was requested for indications unrelated to the adrenal glands. Adrenal masses have been identified in up to 8.7% of individuals in an autopsy series.⁶ The widespread use of CT scan and MRI is expected to increase the number of incidentally discovered adrenal masses.

An adrenal leiomyoma is a rare cause of an adrenal mass. There are less than 20 reported cases in the literature worldwide (Table I). Leiomyomas are benign, smooth muscle tumours that can originate anywhere in the body where smooth muscle layers exist. They arise from uterine and gastrointestinal tissue mostly.^{7,8} The adrenal leiomyomas reported in the literature were large on diagnosis (a range of 30-110 mm in diameter), tended to occur more frequently in females (61%), and affected subjects over a wide age range, from early childhood to late adulthood (an age range from 2-72 years). Most were solitary (unilateral) adrenal masses (14 of 17). The sizes of the tumours in the reported cases, or elsewhere, may not be a true reflection of the average size of leiomyomas of the adrenals as these

cases probably represent a subset of lesions that were operated on, based on size. Many of the reported cases of adrenal leiomyomas occurred in patients with HIV or acquired immune deficiency syndrome^{7,9-12} and/or latent Epstein-Barr infection.¹³

Leiomyomas have been found in different sites, including the adrenals, in both children and adults with HIV.^{18,24} An association between Epstein-Barr virus infection and an increased incidence of smooth muscle tumours has been observed in immunocompromised patients.¹⁸ The basis of the association between viral infections and the increased incidence of smooth muscle tumours is presently unclear. It has been suggested that both Kaposi’s sarcoma and smooth-muscle tumours might arise from a common stem cell under the influence of some unknown factor that is produced during HIV infection.¹² The association between low CD4 counts and adrenal leiomyomas has not been studied. In our case, the leiomyoma manifested with imaging characteristics suggestive of a nonadenomatous lesion. Several of the other case reports also described a radiological phenotype similar to ours. An interesting aspect of our case was that the measured HUs in the periphery of the lesion were exactly in keeping with the literature-reported HUs for muscle tissue (Table II).

Table I: Reported cases of adrenal leiomyoma

Reported cases	Patient demographics		Tumour characteristics		AIDS-positive	Epstein-Barr virus-positive
	Age (year)	Sex	Function	Size (mm)		
Chang TH et al ⁹	53	Female	No	55 x 45 x 35	Yes	
Gibbs KE, White A, Kaley R ¹⁴	49	Female	No	30 x 35 x 30		
Jacobs IA, Kagan SA ¹⁵	65	Female	No	50 x 31 x 42		
Parola P et al ¹⁶	35	Female	Unknown	35	Yes	
Jimenez-Heffernan JA et al ¹³	2	Male	Unknown	70 x 50 x 50	Yes	Yes
Nishida S et al ⁸	48	Female	No	55 x 50 x 45		
Goldman RL, Brody PA ¹⁷	72	Male	No	90 x 70 x 60		
Dahan H et al ¹⁰	32	Male	No	30	Yes	
Mouchet F et al ¹⁸	10	Female	Unknown	50 x 40 x 30		
Rosenfeld DL, Girgis WS, Underberg-Davis SJ ¹¹	11	Female	Unknown	Left: 50; R: 30	Yes	
Demirel S et al ¹⁹	15	Male	No	Left: 40 x 50 x 35 Right: 80 x 50 x 30		
Chao CS, Zhou ZG, Liao E ²⁰	40	Female	No	Unknown		
Jurczak F et al ²¹	56	Male	No	72		
Lin J et al ⁷	31	Female	No	110 x 90 x 70	Yes	
Al-Masri AA, Aladily TN, Younes NA ²²	38	Female	No	Unknown		
Radin DR, Kiyabu M ¹²	28	Male	Unknown	30	Yes	
Mouchet F et al ²³	10	Female	Unknown	Unknown		
Current	40	Male	No	49 x 55 x 60	Yes	Yes

AIDS: acquired immune deficiency syndrome

Table II: The Hounsfield units of common substances

Substance	Hounsfield units
Air	- 1 000
Lung	- 700
Soft tissue	- 300 to -100
Fat	- 84
Water	0
CSF	+15
Blood	+ 30 to + 45
Muscle	+ 40
Cancellous bone	+ 700
Dense bone	+ 3 000

In summary, adrenal leiomyoma is a rare adrenal tumour, but should be considered in the differential diagnosis of adrenal incidentalomas, especially in the HIV-positive population. These tumours can vary greatly in size and can display radiological features that are indistinguishable from other nonadenomatous adrenal lesions, such as carcinoma and pheochromocytoma. Our patient was HIV-positive. To the best of our knowledge, this is the first case of an adrenal leiomyoma where the basal and post-washout HUs have been characterised.

Acknowledgements

We thank William Bates and Jackie Chokwe for the histological evaluation, performing the immunohistochemical stains and preparing the histology slides.

References

- Bovio S, Cataldi A, Reimondo G, et al. Prevalence of adrenal incidentaloma in a contemporary computerized tomography series. *J Endocrinol Invest.* 2006;29(4):298-302.
- Young WF. The incidentally discovered adrenal mass. *New Engl J Med.* 2007;356(6):601-610.
- NIH state-of-the science statement on management of the clinically inapparent adrenal masses ("incidentaloma"). *NIH Consens State Sci Statements.* 2002;19(2):1-25.
- Nieman LK. Approach to the patient with an adrenal incidentaloma. *J Clin Endocrinol Metab.* 2010;95(9):4106-4113.
- Comlekci A, Yener S, Ertlav S, et al. Adrenal incidentaloma, clinical, metabolic, follow-up aspects: single center experience. *Endocrine.* 2010;37(1):40-46.
- Singh PK, Buch HN. Adrenal incidentaloma: evaluation and management. *J Clin Pathol.* 2008;61:1168-73. thus all the references have to move one down
- Lin J, Wasco MJ, Korobkin M, et al. Leiomyoma of the adrenal gland presenting as a non-functioning adrenal incidentaloma: case report and review of the literature. *Endocr Pathol.* 2007;18(4):239-243.
- Nishida S, Tanimura A, Takasaki S, et al. Surgically resected adrenal leiomyoma: report of a case. *Surg Today.* 1995;25(5):455-457.
- Chang TH, Lee YC, Liu CC, et al. Adrenal leiomyoma treated by hand-assisted laparoscopic adrenalectomy: a case report. *Kaohsiung J Med Sci.* 2006;22(11):575-579.
- Dahan H, Bèges C, Weiss L, et al. Leiomyoma of the adrenal gland in a patient with AIDS. *Abdom Imaging.* 1994;19(3):259-261.
- Rosenfeld DL, Girgis WS, Underberg-Davis SJ. Bilateral smooth-muscle tumours of the adrenals in a child with AIDS. *Pediatr Radiol.* 1999;29(5):376-378.
- Radin DR, Kiyabu M. Multiple smooth-muscle tumours of the colon and adrenal gland in an adult with AIDS. *Am J Roentgenol.* 1992;159(3):545-546.
- Jimenez-Heffernan JA, Hardisson D, Palacios J, et al. Adrenal gland leiomyoma in a child with acquired immunodeficiency syndrome. *Pediatr Pathol Lab Med.* 1995;15(6):923-929.
- Gibbs KE, White A, Kaleya R. Laparoscopic management of an adrenal leiomyoma in an AIDS patient. A case report and review of the literature. *JLS.* 2005;9(3):345-348.
- Jacobs IA, Kagan SA. Adrenal leiomyoma: a case report and review of the literature. *J Surg Oncol.* 1998;69(2):111-112.
- Parola P, Petit N, Azzedine A, et al. Symptomatic leiomyoma of the adrenal gland in a woman with AIDS. *AIDS.* 1996;10(3):340-341.
- Goldman RL, Brody PA. Symptomatic leiomyoma of the adrenal. *Clin Imaging.* 1994;18(4):277-278.
- Mouchet F, Ninane J, Gosseye S, et al. Leiomyoma of the suprarenal gland in a child with ataxia-telangiectasia. *Pediatr Hematol Oncol.* 1991;8(3):235-241.
- Demirel S, Erk O, Akkaya V, et al. Multiple vascular leiomyomas involving bilateral adrenal glands, spleen, and epicardium, associated with bilateral testicular microlithiasis and empty sella turcica. *J Pediatr Surg.* 1997;32(9):1365-1367.
- Chao CS, Zhou ZG, Liao EY. The diagnosis and management of adrenal "incidentaloma". *Zhonghua Nei Ke Za Zhi.* 1994;33(6):395-397.
- Jurczak F, Hamy A, Paineau J, et al. An unusual "incidentaloma": adrenal leiomyoma. *J Chir (Paris).* 1994;131(8-9):391.
- Al-Masri AA, Aladily TN, Younes NA. Unusual association between adrenal leiomyoma and autoimmune disease. *Saudi Med J.* 2010;31(2):199-201.
- Mouchet F, Ninane J, Gosseye S, et al. Leiomyoma of the suprarenal gland in a child with ataxia-telangiectasia. *Pediatr Hematol Oncol.* 1991;8(3):235-241.
- Wachsberg RH, Cho KC, Adekosoan A. Two leiomyomas of the liver in an adult with AIDS: CT and MR appearance. *J Comput Assist Tomogr.* 1994;18(1):156-157.