

# Malacoplakia of the Vagina\*

## FIRST CASE REPORT

J. J. VAN DER WALT, M.MED. (PATH.), P. B. MARCUS, M.MED. (ANAT. PATH.), *Department of Anatomical Pathology*, J. J. DE WET, F.R.C.O.G. AND A. J. J. BURGER, M.B. CH.B., *Department of Obstetrics and Gynaecology, Tygerberg Hospital, Tielvelei, CP*

### SUMMARY

The first case of malacoplakia known to have affected the female genital tract is presented. This lesion involved the upper vagina and presented clinically as an infiltrating carcinoma. No evidence of malacoplakia of the urinary tract was found. A strong positive culture of *E. coli*, the light and electron microscopic findings, as well as the patient's rapid response to a broad-spectrum antibiotic, lend support to the current theory that malacoplakia may represent a peculiar response to infection with *E. coli*.

*S. Afr. Med. J.*, 47, 1342 (1973).

Malacoplakia, first described by Michaelis and Gutmann in 1902,<sup>1</sup> is a rare though well-documented condition that most commonly affects the urinary tract, but it has also been described in the male genital and gastrointestinal tracts *inter alia*. We present the first case of this disorder occurring in the female genital tract, more specifically in the vagina.

### CASE REPORT

A 65-year-old nulliparous White woman presented with episodes of vaginal bleeding of 3 months' duration and with a yellow, offensive, vaginal discharge that had been present for a slightly longer period. The patient complained, too, of dyspareunia which had been present for a year. Other ailments included chronic bronchitis, slight stress incontinence, mild anorexia, and weight loss during the previous year.

Physical examination showed a woman in fairly good general health. A slight, bloody, vaginal discharge was seen. The vagina was atrophic and extremely narrow, and in the upper third and involving chiefly the anterior fornix and wall, was a firm, partially necrotic, ulcerated, bleeding, nodular lesion, with a surface measuring approximately 2 cm by 6 cm. The lesion did not involve the cervix.

The uterus was small and curettage yielded no endometrium, and the parametria were clinically normal.

Auscultation of the lungs revealed bilateral, diffuse rhonchi and the chest X-ray findings suggested bilateral bronchopneumonia with underlying bronchiectasis.

\*Date received: 17 January 1973.

Reprint requests to: Dr J. J. van der Walt, Department of Anatomical Pathology, Tygerberg Hospital, Tielvelei, CP.

Haematology showed a total white cell count of 13 100/mm<sup>3</sup> and an erythrocyte sedimentation rate of 45 mm in the first hour (Westergren). No bacterial growth was obtained from vaginal swabs and a midstream urine specimen.

Biopsy of the lesion showed vascular connective tissue with a marked plasma cell and slight neutrophil infiltrate, as well as numerous histiocytes with a pale, foamy cytoplasm (von Hanseman cells), many of them arranged in sheets, which contained the Michaelis-Gutmann bodies, pathognomonic of malacoplakia, in the cytoplasm. These round, basophilic and concentrically-laminated bodies measured 1-20 μm in diameter and also lay free in places (Fig. 1).

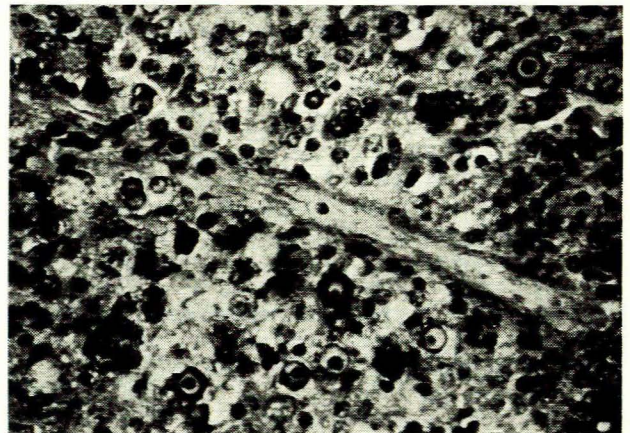


Fig. 1. Vaginal biopsy specimen showing inflammatory cells and concentrically laminated Michaelis-Gutmann bodies. (Alcian blue—periodic-acid-Schiff × 250.)

The Michaelis-Gutmann bodies showed positive staining for iron with Perl's Prussian blue reaction, for calcium with the von Kossa method and stained negatively (intensely red) with the Gram stain. They also stained positively for neutral mucopolysaccharides with the periodic-acid-Schiff stain, while the innermost portion, showing the most prominent concentric lamination, stained positively for acid mucopolysaccharides with the Alcian blue method.

Many of the histiocytes, in addition to the typical Michaelis-Gutmann bodies, contained periodic-acid-Schiff-positive granules of varying size in the cytoplasm,



similar to those described in 1971 by Di Silvio and Bartlett in a case of malacoplakia of the colon.<sup>2</sup>

These granules showed negative staining for iron, calcium and acid mucopolysaccharides.

Occasional histiocytes contained clusters in their cytoplasm of what appeared to be large bacillary bodies, which, in the case of these particular cells, hardly stained at all and had a pale, foamy look (Fig. 2). These rod-like structures were, like the Michaelis-Gutmann bodies, Gram-negative.

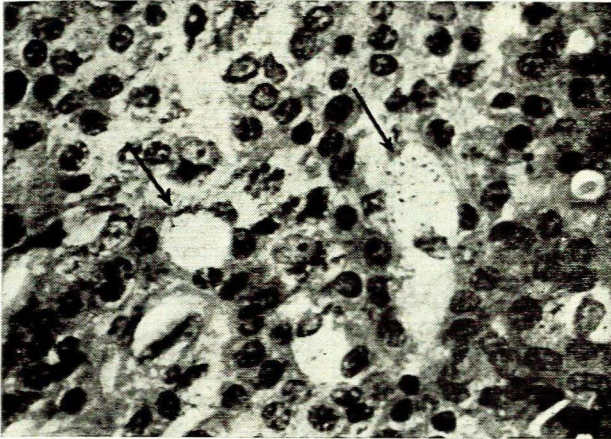


Fig. 2. Histiocytes (indicated by arrows) with pale, foamy cytoplasm containing clusters of bacillary structures. (Alcian blue—periodic-acid-Schiff  $\times$  400.)

No tumour tissue was found in the biopsy specimen. A clinically normal area of vaginal mucosa was also examined and histology showed a slight acute-on-chronic non-specific vaginitis, but no signs of malacoplakia.

Material for electron microscopic examination was fixed initially in phosphate-buffered glutaraldehyde and subsequently in Palade's osmium tetroxide, the pH of both fixatives being about 7.2. This tissue, taken from the vaginal lesion, was embedded in Spurr's resin and cut on a L.K.B. ultramicrotome, stained with uranyl nitrate and lead citrate, and examined with a Zeiss 9S2 electron microscope. The two main cell types were plasma cells and von Hansemann cells. Some of the latter contained typically laminated Michaelis-Gutmann bodies showing varying degrees of mineralization. In the cytoplasm in the vicinity of the Michaelis-Gutmann bodies numerous whorled structures were found, some of which were partially or wholly mineralized (Fig. 3). In several of the blocks examined, bacillary structures with a morphology consistent with that of *E. coli* were found lying in clear vacuoles in the cytoplasm of von Hansemann cells (Fig. 4). Cytological smears were taken simultaneously with the biopsy specimen, and the findings were also diagnostic of malacoplakia.

Cystoscopy showed a trigonitis, but no lesion resembling that in the vagina. Rectal examination proved negative.

The patient was treated with doxycycline (100 mg daily for 30 days), a vaginal cream containing tetracy-

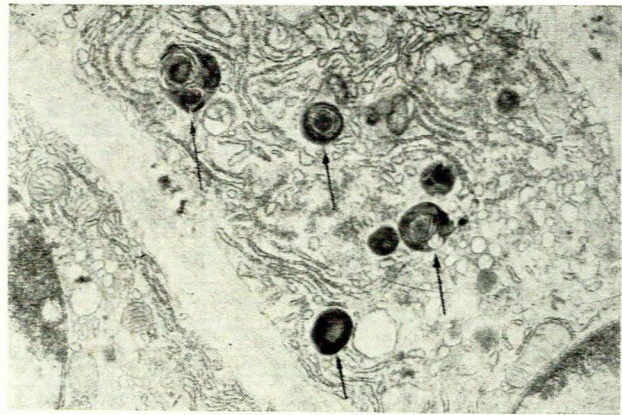

Fig. 3. Whorled structures (indicated by arrows) showing varying degrees of mineralization ( $\times$  22 500).

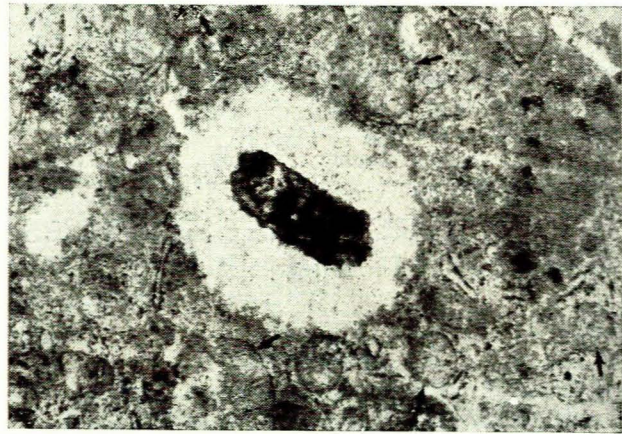


Fig. 4. Bacillary structure lying in a clear vacuole in the cytoplasm of a von Hansemann cell. Arrows indicate whorled structures ( $\times$  47 500).

cline and amphotericin-B (3 applications daily for 30 days) and an oral oestrogen preparation (0.625 mg daily for 30 days) and was seen again a month later when she was found to be asymptomatic. On re-examination the vagina no longer appeared atrophic and in the place of the former, ulcerated lesion, two reddish-yellow, well-circumscribed and slightly raised areas, both approximately 1 cm in diameter, were found. Biopsy showed a chronic, non-specific vaginitis (Fig. 5), but no signs of malacoplakia. Cytological smears also, were free from signs of malacoplakia. However, a good growth of *E. coli* was still obtained from a vaginal swab taken at this stage.

Antibiotic therapy was continued with a diminished dosage.

## DISCUSSION

This case is the first documented instance of malacoplakia of the female genital tract, more specifically of the vagina, and is added to the growing list of anatomical



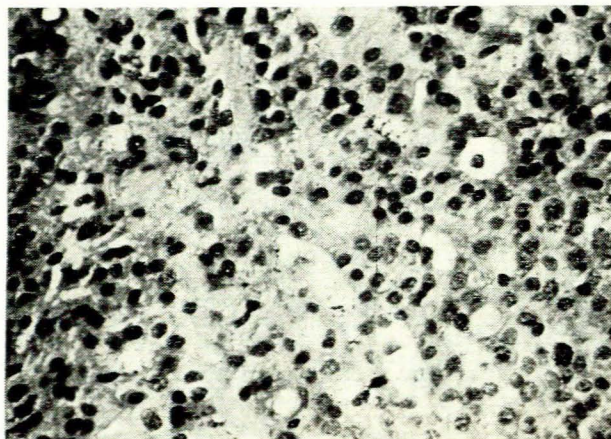


Fig. 5. Vaginal biopsy specimen after treatment, showing a chronic, non-specific vaginitis, but no malacoplakia. (Alcian blue—periodic-acid-Schiff  $\times 250$ .)

sites known to have been affected by this disorder. Some of the more recent additions to this list were reported by Gupta *et al.*<sup>3</sup> who found the lesions of malacoplakia in the lungs, bones, urinary bladder and kidneys of a 61-year-old woman.

The case we report clinically resembled a malignant tumour.

Indeed, the fact that malacoplakia can mimic a cancer was emphasized by Di Silvio and Bartlett<sup>2</sup> who reported

a case of colonic malacoplakia that resembled a carcinoma. Colonic malacoplakia was associated with an adenocarcinoma in 2 cases reported by Finlay-Jones *et al.*<sup>4</sup>

The ultrastructural features of our case accord broadly with those described by other authors. Whorled structures similar to those we have demonstrated are reported in several articles.<sup>4-7</sup> However, particularly noteworthy in our material were the bacillary structures seen on both light and electron microscopy. Finlay-Jones *et al.*<sup>4</sup> reported ultrastructures resembling portions of bacterial bodies in their cases, and our findings (which include the strongly positive *E. coli* culture obtained and the patient's rapid response to antibiotic therapy) tend to favour their theory, namely that malacoplakia probably represents a peculiar chronic inflammatory response to infection by a coliform organism.

We wish to thank the Medical Superintendents of Karl Bremer and Tygerberg Hospitals, for permission to publish; Mr E. Truter for his assistance with the electron microscopy; and the Medical Illustration Department of the Stellenbosch University Medical School, for preparing the photomicrographs.

#### REFERENCES

1. Michaelis, L. and Gutmann, C. (1902): *Z. klin. Med.*, **47**, 208.
2. Di Silvio, T. V. and Barlett, E. F. (1971): *Arch. Path.*, **92**, 167.
3. Gupta, R. K., Schuster, R. A. and Christian, W. D. (1972): *Ibid.*, **93**, 42.
4. Finlay-Jones, L. R., Blackwell, J. B. and Papadimitriou, J. M. (1968): *Amer. J. Clin. Path.*, **50**, 320.
5. Waisman, J. and Rampton, J. B. (1968): *Arch. Path.*, **86**, 431.
6. Ranchod, M. and Kahn, L. B. (1972): *Ibid.*, **94**, 90.
7. Kerr, J. F. R., Gaffney, T. J., McGeary, H. M., Duhig, R. E. T. and Nicolaides, N. J. (1972): *J. Path.*, **107**, 289.

## Boeke Ontvang : Books Received

**Cardiac Arrhythmias.** The 25th Hahnemann Symposium. Ed. by L. S. Dreifus, M.D. and W. Likoff, M.D. Pp. xiii + 681. Illustrated. \$29.75. New York and London: Grune & Stratton. 1973.

**Heritable Disorders of Connective Tissue.** 4th ed. By V. A. McKusick, M.D. Pp. xv + 878. Illustrated. \$32.50. St Louis, Missouri: C. V. Mosby. 1972.

**Minimal Cerebral Dysfunction in Children.** Seminars in Psychiatry. Ed. by S. Walzer, M.D. and P. H. Wolff, M.D. Pp. 117. Illustrated. \$7.50. New York and London: Grune & Stratton. 1973.

**World Review of Nutrition and Dietetics.** Vol. 16. Food, Nutrition and Health. Ed. by M. Rechcigl, jnr, B.S., M.N.S., Ph.D. Pp. xxxii + 511. SFr. 180.-. Basel and London: S. Karger. 1972.

**Clinical Endocrinology.** Articles published in the *British Medical Journal*. Pp. vi + 175. Illustrated. £1.25. London: British Medical Association. 1973.

**The Pharmacology of Thermoregulation.** Proceedings of a Satellite Symposium held in conjunction with the 5th International Congress on Pharmacology, San Francisco, July 1972. Ed. by E. Schönbaum and P. Lomax. Pp. xiv + 583. SFr. 188.-. Basel and London: S. Karger. 1973.

**Vertebral Manipulation.** 3rd ed. By G. D. Maitland, A.U.A., F.C.S.P., M.A.P.A. Pp. x + 269. Illustrated. R11.00 hardcover; R7.00 softcover. London and Durban: Butterworths. 1973.

**Principles of Electronics in Medical Research.** 2nd ed. By D. W. Hill, M.Sc., Ph.D., F. Inst.P., F.I.E.E. Pp. xii + 369. Illustrated. R12.00. London and Durban: Butterworths. 1973.

**Analgesia and Anaesthesia in Obstetrics.** By O. M. Plantevin, M.B., Ch.B., F.F.A.R.C.S. Pp. vii + 182. R3.00. London and Durban: Butterworths. 1973.

**EPH-Gestosis.** Ed. by E. T. Rippmann and Ch. Rippert. Pp. 368. Illustrated. Zürich: Hommel. 1972.