

CASE REPORT

Berg adder (*Bitis atropos*): An unusual case of acute poisoning

C A Wium, MSc (Pharmacology); C J Marks, MSc (Pharmacology); C E du Plessis, BSc;
G J Müller, MB ChB, MMed (Anaes), PhD (Toxicology)

Tygerberg Poison Information Centre, Division of Clinical Pharmacology, Faculty of Medicine and Health Sciences,
Stellenbosch University, Cape Town, South Africa

Corresponding author: C A Wium (caw@sun.ac.za)

A 5-year-old boy presented to hospital with mild local cytotoxic and severe neurotoxic symptoms. The neurotoxic symptoms included ptosis, fixed dilated pupils and flaccid paralysis with respiratory failure. Mild hyponatraemia was also a clinical feature. After various unsuccessful treatment options were followed, the Tygerberg Poison Information Centre was contacted and a diagnosis of berg adder bite was made. Berg adder bites are uncommon and therefore not usually considered in the differential diagnosis of a patient presenting with an unexplained clinical picture. A timeous poison information helpline consultation is recommended in this situation.

S Afr Med J 2017;107(12):1075-1077. DOI:10.7196/SAMJ.2017.v107i12.12763

Case report

At midday, a 5-year-old boy was walking with his grandfather over the sand dunes on a path through the fynbos (natural shrubland or heathland vegetation) in the Betty's Bay area of the Western Cape Province, South Africa. He felt a sharp pain on the lateral side of the left foot. The boy and his grandfather thought that he had stepped onto a stick with big thorns, and he limped home. The local injury looked like a scratch mark. Shortly thereafter (within 1 - 2 hours) he started vomiting and said that he felt tired. These symptoms continued for several hours. He appeared unwell and had difficulty in keeping his eyes open.

The family were scheduled to fly from Cape Town to Johannesburg at 17h00 on the same day. Before boarding, the boy had difficulty in walking and had to be carried on board. His eyes remained half closed throughout the flight, and it was reported that he had 'slept' during the journey. On arrival in Johannesburg, now 8 - 9 hours after the incident, he was immediately taken to a medical facility. He had difficulty in breathing and was resuscitated, intubated and ventilated. He had prominent fixed dilated pupils and his left foot was red and slightly swollen (Fig. 1).

A cranial computed tomography scan of the brain was normal. Standard routine laboratory blood tests (Table 1) as well as

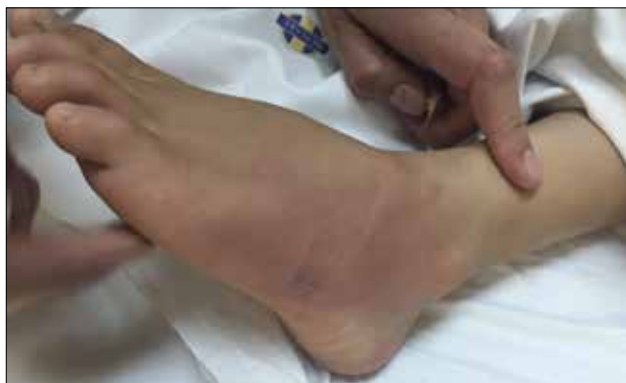

Fig. 1. The left foot, red and slightly swollen (photo: R Grantham).

serum and urine toxicology screens were done. A high level of benzodiazepines (>200 ng/mL) was detected in the serum and in the urine. The presence of benzodiazepines led medical personnel to consider the possibility of a benzodiazepine overdose. The patient was subsequently transferred to a paediatric intensive care unit where flumazenil, the antidote for benzodiazepine overdose, was administered. Six hours after administration there was no response to the flumazenil. It was then assumed that the high benzodiazepine level was probably due to the midazolam given prior to intubation, and therefore not responsible for the clinical picture.

Lumbar puncture was performed, and the results were found to be normal. A full blood count showed the presence of a neutrophil leucocytosis. Liver functions were normal. The pupils were still severely dilated 24 hours after the incident, and an ophthalmologist was therefore consulted. A magnetic resonance imaging scan of the brain and brainstem was normal. A Cape cobra bite was then considered a possible cause of the toxicity, based on a possible snakebite mark on the foot and the accompanying flaccid paralysis. The Cape cobra (*Naja nivea*) has neurotoxic venom that can cause severe, descending flaccid paralysis due to postsynaptic somatic nerve block.^[1] Eight vials (8 × 10 mL) of Polyvalent Snakebite Antiserum (South African Vaccine Producers) were administered. However, the patient did not respond to the antivenom, and the Tygerberg Poison Information Centre (TPIC) was consulted with regard to the unusual clinical presentation.

A diagnosis of berg adder bite was made by the TPIC based on the following:

- The 'scratch mark' and the swelling of the foot, which were considered to be the result of a snakebite^[2-4]
- Ptosis^[2-7]
- Marked fixed dilated pupils^[2,4,5-7]
- Flaccid paralysis with respiratory failure^[1,4,9]
- Negative response to the Polyvalent Snakebite Antiserum, which is not effective in berg adder envenomation^[1]
- The geographical area in which the incident took place. Over a 12-year period, four of the 14 cases of berg adder envenomation dealt with by the TPIC have been from the Betty's Bay region.^[8,9]

Table 1. Urea and electrolyte results while the patient was being ventilated

Urea and electrolytes	Day 1, 20h45	Day 2, 10h30	Day 3, 05h33	Day 4, 11h46	Day 5, 10h30	Normal range
Sodium (mmol/L)	141	136	130	132	132	136 - 145
Potassium (mmol/L)	3.8	4.1	4.3	4	4.5	3.4 - 4.7
Chloride (mmol/L)	104	101	-	97	95	98 - 107
CO ₂ (mmol/L)	21	22	-	20	29	21 - 29
Anion gap (mmol/L)	20	-	-	-	-	8 - 20
Urea (mmol/L)	6.8	3.6	4.1	5.4	5	1.8 - 6.4
Creatinine (µmol/L)	28	26	23	22	22	<43
Calcium (mmol/L)	2.49	-	-	2.31	-	2.2 - 2.7
Albumin (g/L)	46	-	36	36	-	35 - 54
Magnesium (mmol/L)	0.95	-	0.82	-	-	0.70 - 0.95
Phosphate (mmol/L)	1.86	-	0.99	1.33	-	1.03 - 1.87
Procalcitonin (ng/mL)	-	<0.5	95.32	58.03	30.87	>10 severe infection

- The lack of response to flumazenil^[10]
- The development of hyponatraemia has been described as a complication of berg adder bite, and confirmed the diagnosis.^[9]

On the recommendation of the TPIC, management was supportive and the hyponatraemia was corrected with normal saline. The patient responded well and was extubated 5 days after the incident.

Fig. 2 compares the pupils 3 weeks after the incident with the pupils 6 months after the incident. The dilated pupils were still present 6 months after the incident, and the ophthalmologist prescribed pilocarpine. The senses of taste and smell could not be assessed in this patient during hospitalisation. Loss of sense of taste and smell are usually prominent features of berg adder bite.^[1,7,9] However, when specifically asked, the parents reported that after the incident the boy had said on numerous occasions that his favourite food 'did not taste right'. About a month after the incident,

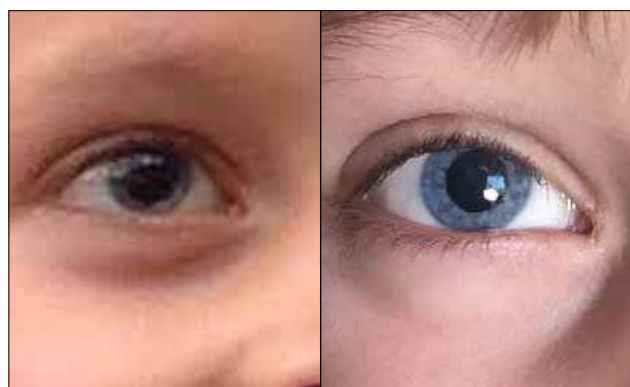

Fig. 2. The pupils 3 weeks after the incident (left) compared with the pupils 6 months after the incident (right) (photo: R Grantham).

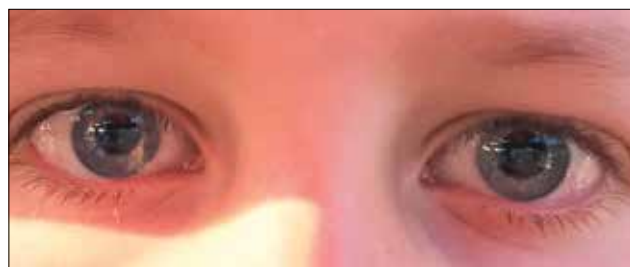


Fig. 3. The pupils 1 year after the incident (photo: R Grantham).

he said that 'it tastes like it used to'. Fig. 3 shows that the pupils were still dilated after 1 year.

Discussion

The berg adder (*Bitis atropos*) is a relatively small snake (one of the dwarf/minor adders), with an average adult length of 30 - 40 cm. It is greyish to dark brown with a white dorsolateral line on both sides of the body, with a series of sub-triangular pale-edged markings above the line (Fig. 4).^[8]

The berg adder is known to be aggressive, and will strike without undue provocation. Its preferred habitat is montane grassland up to a level of 3 000 m, as well as coastal fynbos.^[2,8] Berg adder envenomation causes a unique syndrome of cytotoxic and neurotoxic symptoms and signs.^[1,2] Local effects include initial pain in the region of the bite mark and swelling.^[4,6,7] Systemic effects include paraesthesiae of the tongue and lips, ophthalmoplegia characterised by visual disturbances, ptosis, fixed dilated pupils and loss of eye movements and accommodation, as well as loss of the sense of smell (anosmia) and taste. The dilated pupils and loss of the sense of smell and taste may take weeks to months to resolve. Late-onset respiratory failure is a complication 6 - 36 hours after the bite, often at a stage when it is not anticipated or expected.^[1,4-7] Hyponatraemia, which may lead to convulsions, often develops 2 - 3 days after the bite and should not be interpreted as a syndrome of inappropriate antidiuretic hormone secretion (SIADH).^[11] Hyponatraemia is probably the result of a natriuretic peptide in the venom that induces renal



Fig. 4. Berg adder (*Bitis atropos*) from the Western Cape (photo: J Marais).

sodium loss. It has been shown by Van Zyl *et al.*^[12] that berg adder venom contains at least two phospholipase A₂ enzymes, suggesting that the toxic effects are not due to a single component but to the activities of various components.

There is no antivenom for berg adder bite.^[1,7] Management is symptomatic and supportive, with specific attention given to respiratory function and correction of plasma sodium levels. The sodium level should be recorded at regular intervals and hyponatraemia treated with normal saline. Fluids should not be restricted, and ophthalmological consultation is recommended.^[1]

Conclusion

This case highlights the importance of contacting a poison information helpline timeously, especially in cases where the reason for the presenting symptoms and signs is unknown. This case illustrates that various ineffective and costly treatment modalities could have been avoided with simple symptomatic and supportive care. Berg adder envenomation is uncommon and therefore not usually considered in the differential diagnosis of snakebite or any other unexplained symptoms and signs. Berg adder envenomation may cause life-threatening toxic effects such as respiratory failure and hyponatraemia, and it is therefore recommended that it be considered in the differential diagnosis of patients presenting with both cytotoxic and neurotoxic symptoms.

The Poison Information Helpline number is 0861 555 777.

Acknowledgements. We thank Drs D J H Veale and E Deloedt for editing the final manuscript.

Author contributions. All the authors contributed to the original discussions regarding the unusual presentation before the diagnosis was made. CAW wrote the article, and CJM, CEduP and GJM critically reviewed it from the beginning of the writing process.

Funding. None.

Conflicts of interest. None.

1. Muller GJ, Modler H, Wium CA, Veale DJH, Marks CJ. Snake bite in southern Africa: Diagnosis and management. *CME* 2012;30(10):362-381. <http://www.cmej.org.za/index.php/cmej/article/view/2546/2581> (accessed 5 November 2017).
2. Ellis CG. Special Report: Snakes alive. The berg adder: A unique snake. *Practitioner* 1979;223(1336):544-547.
3. Paget D, Cock EV. Case history of a berg adder bite. *Cent Afr J Med* 1979;25(2):30-33.
4. Hurter J. *Bitis atropos* (berg adder): Envenomation. *J Herp Assoc Afr* 1986;32(1):33-33.
5. Hurwitz BJ, Hull PR. Berg adder bite. *S Afr Med J* 1971;45(4 Sept):969-971.
6. Montgomery J. Two cases of ophthalmoplegia due to berg adder bite. *Cent Afr J Med* 1959;5(4):173-177.
7. Palmer NG. *Bitis atropos* (berg adder): Envenomation. *J Herp Assoc Afr* 1986;32(1):31-32.
8. Marais J. *Snakes of Southern Africa*. 2nd ed. Cape Town: Struik Publishers, 2004:100-101.
9. Muller GJ, van Zyl JM. The unique syndrome of berg adder (*Bitis atropos*) envenoming. Presented at the World Congress on Animal, Plant & Microbial Toxins, Adelaide, Australia, 14 - 19 September 2003. <https://doi.org/10.21236/ada418029> (accessed 14 September 2016).
10. Sivillotti MLA. Flumazenil, naloxone and the 'coma cocktail'. *Br J Clin Pharmacol* 2016;81(3):428-436. <https://doi.org/10.1111/bcp.12731>
11. Cotton MF, Shanhak E, Muller GJ, Heyes L, Lalis NN. The syndrome of inappropriate antidiuretic hormone secretion, an unusual association with presumed snakebite. *S Afr Med J* 1991;79(12):735-736.
12. Van Zyl JM, Muller GJ, van der Merwe MJ. Purification and properties of two phospholipase A₂ enzymes from berg adder (*Bitis atropos*) venom. *S Afr J Sci* 2001;97(9-10):437-444.

Accepted 23 August 2017.