

The anatomy and movements of the pyloric sphincteric cylinder

A. D. KEET, J. J. HEYDENRYCH

Summary

Disagreement about various aspects of the structure and function of the pylorus persists. Morbid anatomical, living anatomical, manometric and radiographic studies were done in an attempt to clarify some problems. It is shown that the pyloric ring (sphincteric ring) is not a separate anatomical structure, but that it constitutes the aboral end of the pyloric sphincteric cylinder, a muscular tube several centimetres in length. The ring does not function independently and conventional peristaltic waves do not proceed as far as the ring. Consequently the ring does not relax reciprocally with an oncoming peristaltic wave in the sense that a wave travels up to the ring, which relaxes upon its arrival. Each peristaltic wave stops on arrival at the oral end of the cylinder, simultaneously initiating a concentric or systolic contraction of the entire cylinder, including the ring. The cylinder, including the ring, is open at rest.

S Afr Med J 1982; 62: 15-18.

There has long been disagreement about various aspects of the structure and function of the 'gatekeeper' (Greek *pyloros*, from *pyle* = gate and *ouros* = guard). For many years it had been accepted that the narrow (3 - 4 mm) annular band of thickened muscularis externa palpable in the wall of the gut at the gastroduodenal junction, i.e. the pyloric ring, was synonymous with the pyloric sphincter. It was thought that it was contracted most of the time, opening intermittently to allow the passage of chyme into the duodenum. This implied that it was more or less a separate anatomical structure, capable of acting independently. This view was no doubt supported by the interpretation of the image seen on radiographs. Surely the deep annular constriction between the stomach and duodenum constituted a sphincter? (Fig. 1).

In contradistinction to the above, it has been shown convincingly in physiology that the pylorus is open most of the time, closing fleetingly during 'cycles' of contraction.¹⁻⁴ In anatomy, again, it has been shown that the pyloric ring *per se* is not a sphincter, although it does form part of the sphincteric mechanism, which is more intricate than would appear at first sight.⁵⁻⁸ To compound matters, these anatomical findings are almost universally ignored in the interpretation of recent manometric and motility studies.⁹⁻¹¹

Departments of Radiology and Surgery, University of Stellenbosch and Tygerberg Hospital, Parowvallei, CP

A. D. KEET, M.D., PH.D.

J. J. HEYDENRYCH, M.MED. (SURG.)

Date received: 4 September 1981.

Reprint requests to: Dr A. D. Keet, C4 Dept of Radiology, Tygerberg Hospital, Tygerberg, 7505 RSA.

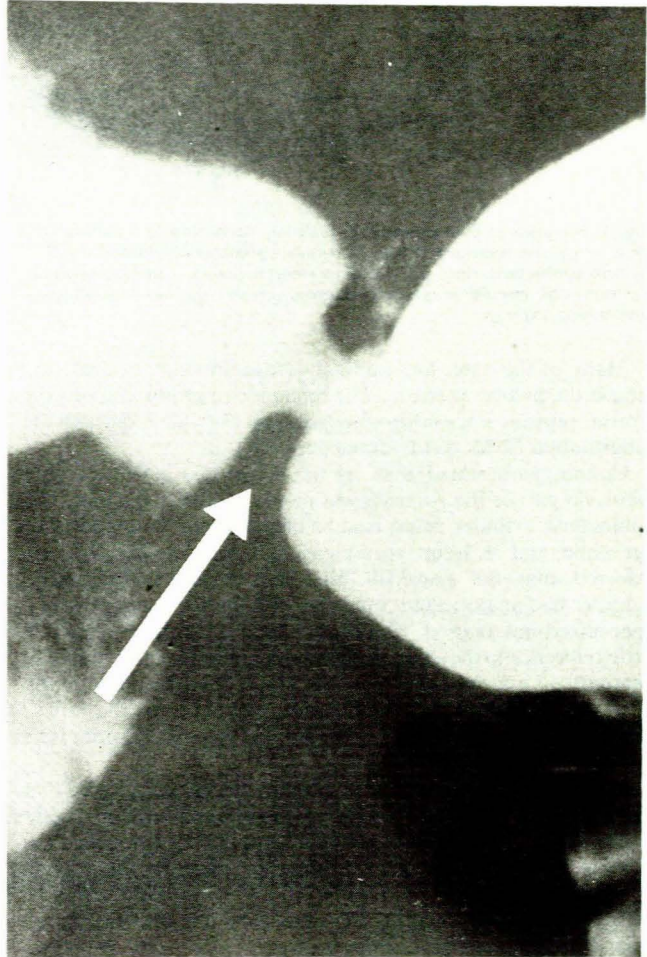


Fig. 1. Radiograph showing pyloric ring (arrowed). The ring is usually equated with the pyloric sphincter.

Previous anatomical findings

As long ago as 1906 Cunningham⁵ showed that the sphincteric (i.e. pyloric) ring in man and the anthropoid ape was not a separate anatomical structure, but that it constituted the aboral thickening of the pyloric sphincteric cylinder. The cylinder, again, was a tubular structure of circular muscularis externa, 3 - 4 cm in length, extending from the sulcus intermedius (a constant furrow on the greater curvature in anatomical specimens) to the pyloric aperture. On the aboral side the circular fibres of the ring were sharply demarcated from those of the duodenum by a fibrous septum, but on the gastric side they merged imperceptibly with the circular fibres of the cylinder, which in turn merged with the remainder of the circular coat. On the gastric side, therefore, there was no boundary or division between the circular fibres of the ring, the cylinder and the remainder of the circular coat (Fig. 2).

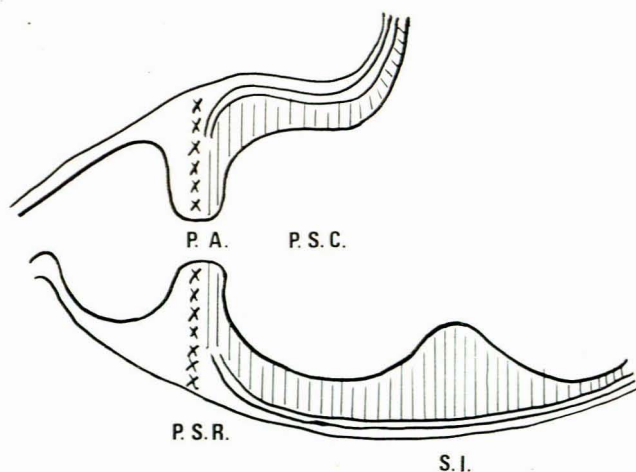


Fig. 2. Diagram of pyloroduodenal junction according to Cunningham⁵ (P.A. = pyloric aperture; P.S.C. = pyloric sphincteric cylinder; P.S.R. = pyloric sphincteric ring; S.I. = sulcus intermedius; x = fibrous septum). Vertical lines: circular muscularis externa. Longitudinal lines: longitudinal muscularis externa.

Many of the outer longitudinal gastric fibres dipped into the ring at the pyloric aperture. The remainder continued across the fibrous septum at the gastroduodenal junction, to merge with the longitudinal fibres of the duodenum (Fig. 2).

Cunningham stated that, as far as the muscular structure went, no part of the stomach was more definite or distinct. The sphincteric cylinder could best be demonstrated in the fetus or the child and in adult specimens hardened in formalin. He inferred that the powerful musculature of the sphincteric cylinder had an important function, probably under control of a specialized innervation. (Strangely enough, Cunningham made little reference to the sphincteric cylinder in his later textbooks of anatomy — one surmises that this might have been due to the lack of physiological confirmatory evidence at the time.) Cunningham called the part of the stomach on the oral side of the cylinder, the 'pyloric vestibule'.

In his classic anatomical studies, Forssell⁶ in 1913 showed that the pyloric part of the stomach formed a separate muscular compartment, several centimetres in length, which he called the 'canalis egestorius'. The pyloric ring was shown to be an inherent part of the canalis, being the thickening of its aboral end. The entire canalis, including the ring, acted as a unit. (Forssell found that the stomach could be divided into four muscular compartments. From above downwards these were the fornix, corpus, sinus and canalis egestorius. The canalis corresponded to Cunningham's sphincteric cylinder, and the sinus to the pyloric vestibule.)

Cole⁷ in 1928 found that the 'pyloric canal' (not to be confused with the pyloric aperture), was surrounded by a dense, thick, fan- or harp-shaped muscle, which was apparently a continuation of the circular muscle coat. It seemed to fan out from a narrow area on the lesser curvature to a relatively wider area on the greater curvature. When contracting, it did so in a segmental, concentric rather than in a peristaltic way. Full contraction of this muscular tube caused the formation of the pyloric canal which, in the normal stomach, was a dynamic structure.

In 1942 Torgersen⁸ confirmed Forssell's findings. The canalis egestorius was shown to consist of two loops of circular muscularis externa, diverging from a third loop or muscle 'torus' on the lesser curvature. The right canalis loop formed the pyloric ring. As in Cunningham's dissections, the circular fibres of the ring were shown to be separated from those of the duodenum by a fibrous septum. The left loop, which was much less well developed, encircled the greater curvature a few centimetres orally to the ring (Fig. 3). The canalis egestorius consisted of the

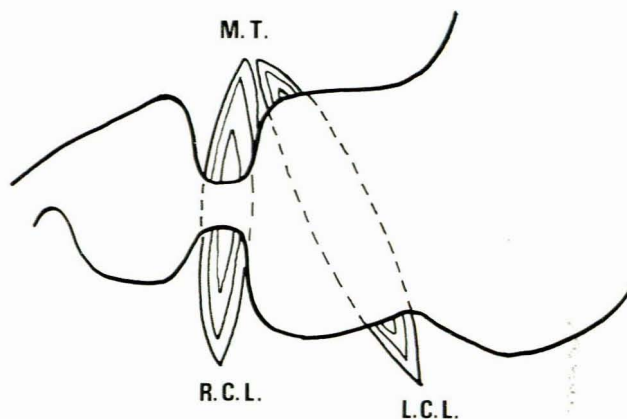


Fig. 3. Diagram of Torgersen's muscle loops (M.T. = muscle torus; R.C.L. = right canalis loop; L.C.L. = left canalis loop).

muscle torus, the right and left loops with the intervening circular fibres, and the overlying longitudinal fibres. Contraction of the circular fibres narrowed the lumen, while contraction of the longitudinal fibres approximated the loops. The loops did not contract separately, the entire structure functioning as a unit.

It is clear that Cunningham's sphincteric cylinder, Cole's fan-shaped muscle and the canalis egestorius of Forssell and Torgersen are the same muscular structure, forming a tube-like anatomical compartment when contracted. Cunningham's sphincteric ring corresponds to Torgersen's right loop, and the sulcus intermedius to the left loop. In 1957 McNaught¹² confirmed the presence of the left loop in fresh gastric resection specimens.

Because of the fact that the above findings are poorly known or not generally accepted, the following additional studies were done in an effort to elucidate the structure and forms of movement of the pylorus.

Materials, patients and methods

Owing to the speed with which autolysis occurs after death, the postmortem study of the stomach is in many respects unrewarding. In these specimens the stomach is flaccid, and while the pyloric ring may still be palpable, no other macroscopic differentiation is evident in the remainder of the gastric musculature. Owing to autodigestion, moreover, the luminal surface of the mucosa, and the smaller mucosal folds, are soon destroyed.

Morbid anatomy

In morbid anatomical specimens fixed in formalin, however, the gastric musculature is contracted. Five adult specimens were studied. Having identified the pyloric ring by means of a wire marker, the lumen of the stomach and duodenum was filled with barium. A narrow layer of barium paste was painted on the serosal surface of the lesser curvature, and another on the greater curvature. Radiographs of each specimen were taken in the anteroposterior position (Fig. 4). The space between the luminal barium and that on the external surface indicated the thickness of the wall, consisting of mucosa, submucosa, muscularis and serosa. As the mucosal, submucosal and serosal layers were uniformly thick (the remaining mucosal folds being more or less equally thick in all parts of the stomach), any variation in wall thickness was due to a thickening of the muscular coat.

Extending orally from the pyloric ring, a cylindrical segment approximately 3 cm in length was seen, in which the wall had a thickness of 6 - 7 mm. In the remainder of the stomach the wall

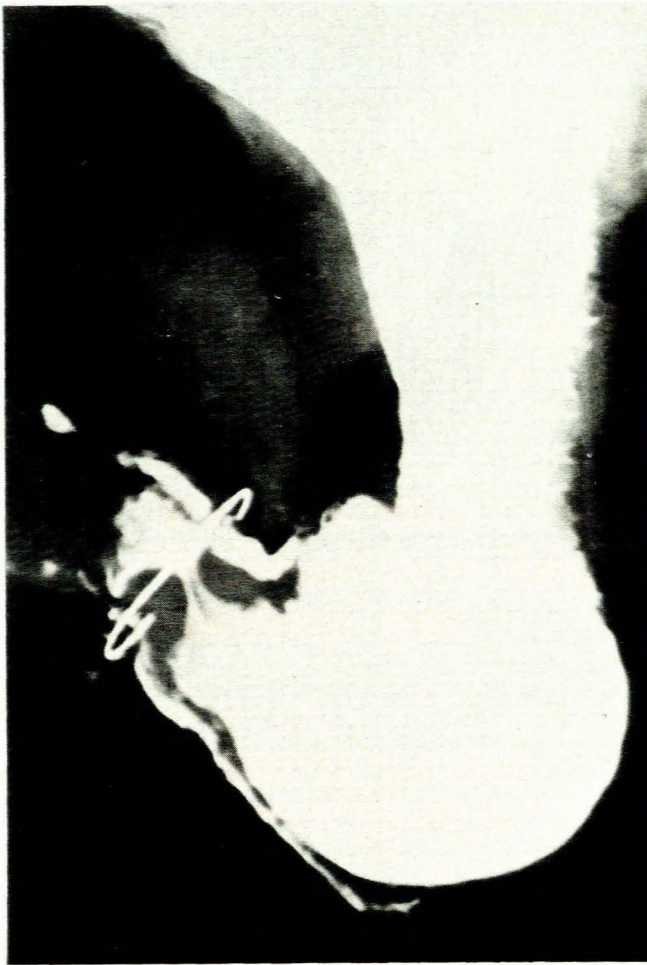

Fig. 4. Radiograph of morbid anatomical specimen, with metal marker on pyloric ring. Barium fills the lumen and outlines the serosa of the lesser and greater curvatures. A short tube of thickened muscularis externa extends orally from the ring.

thickness was 2 - 3 mm. The pyloric ring formed the aboral part of the muscular thickening.

It is concluded that there is a tube of thickened pyloric musculature, approximately 3 cm in length and incorporating the pyloric ring, in the morbid anatomical specimen.

Living anatomy

In the usual radiological barium studies, only the contrast in the lumen is visible. The actual walls of the stomach, for instance, are not seen. It is accepted in radiology that a temporary, symmetrical, physiological narrowing of the barium column in the lumen of a hollow muscular tube is due to muscular contraction in the walls of the tube. This supposition is not universally accepted, and it has been argued, especially in physiology, that a barium column may become narrowed by incomplete filling of the lumen. Alternatively, even with complete filling, a passive 'falling together' of the walls, without active contraction, may narrow the contrast column. These objections may be overcome by specially devised living anatomical studies, or by simultaneous intraluminal pressure determinations.

The living anatomy was investigated in 6 volunteers: informed, adult White patients, who had to undergo cholecystectomy in the ordinary course of events (see footnote* re ethical questions). On completion of the cholecystectomy, and before closure of the abdomen, the stomach and duodenum were shown to be normal

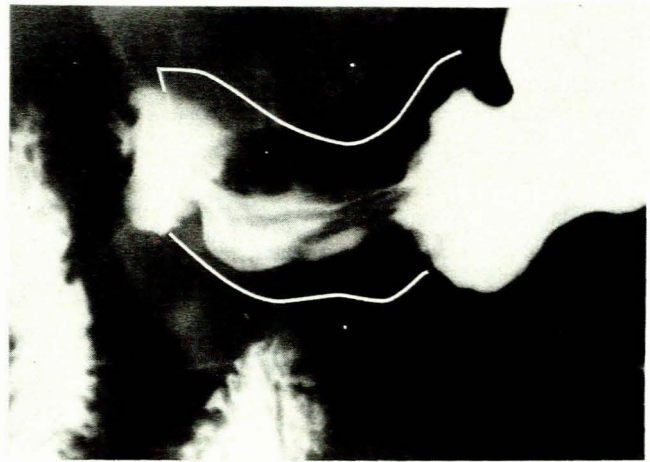


Fig. 5. Radiograph showing living anatomy. Two fine, flexible metal wires (retouched) are attached to the serosal surfaces of the greater and lesser curvatures. The space between the wires and the barium in the lumen indicates the cylindrical muscular contraction.

by means of external inspection and palpation. Two fine, flexible stainless metal wires, similar to the wires in the leads of myocardial pacemakers, were attached to the serosal surface of the pyloric region of the stomach and first part of the duodenum by means of superficial interrupted absorbable sutures (Fig. 5). One wire was attached to the lesser and the other to the greater curvature, the free 'duodenal' ends of both wires being brought to the surface through the cholecystectomy incision, which was subsequently closed in the usual way.

On the day before discharge each patient had a limited barium meal as follows: after an overnight fast a liquid barium sulphate suspension was swallowed in the erect position so as to outline the horizontal part of the gastric lumen and to extend well up into the vertical part. After emptying into the duodenum had commenced, gastric contractions were studied by means of radiographic TV monitoring and appropriate radiographs. The space between the metal wires on the serosal surfaces and the luminal barium indicated the thickness of the walls, which at rest was approximately 4 - 5 mm. Narrow, circumferential indentations of the barium column appeared in the body of the stomach and proceeded to move in a caudal direction. Opposite the indentations the wires remained in their original position, showing that these indentations were indeed peristaltic contraction waves and not a passive 'falling together' of the walls. At a point 3 - 4 cm orally to the ring (encircling the aperture) each wave became stationary, at the same time initiating a cylindrical or segmental narrowing of the barium column in the remaining part of the stomach, as far as and including the area of the ring. Again the wires remained in their original position. The space between the wires and the luminal barium widened to approximately 8 - 10 mm all round, indicating an active, tube-like or cylindrical contraction of the muscular walls, 3 - 4 cm in length (Fig. 5). After a second or two of maximal contraction, the walls relaxed slowly and the cycle was repeated.

On completion of the radiological examination the wires were removed by gentle traction on their external ends. None of the patients suffered any discomfort or untoward sequelae.

It is concluded that 'conventional' peristaltic waves in the stomach do not travel as far as the pyloric aperture, but that such a wave initiates a segmental, tube-like contraction, 3 - 4 cm in

*The 'wire studies' were done after repeated and careful consideration of all aspects, and after we had satisfied ourselves that absolutely no harm would accrue to any of the participants. At the time the Ethical Committee of this institution had not come into being. Had the Committee been in existence, the project would have been submitted to it beforehand.

Recently the procedure was submitted to the present Ethical Committee for a retrospective opinion. The Committee reported that it took cognizance of the investigations, and advised that the results could be published.

length, of the distal stomach up to and including the pyloric ring. This implies the existence of a specialized, cylindrical muscular compartment in the distal stomach. It is clear that the contraction can be explained on the anatomical concept of the pyloric sphincteric cylinder, and that it can be likened to 'systole' of the cylinder.

Intraluminal pressure profiles

In a combined radiological-manometric study in normal subjects documented previously,¹³ it was shown that characteristic contractions of the sphincteric cylinder (or *canalis egestorius*), as described above, cause intraluminal pressure increases varying from 9 to 34 mmHg (the majority being in the 12 - 25 mmHg range). The waves lasted from 5 to 21 seconds (the majority being in the 6 - 10-second range). Maximal contraction (the peak of a wave) lasted a second or two.

Prior to these studies Carlson *et al.*¹⁴ described 'terminal antral contractions' in canines, causing sharp rises in intraluminal pressure. These contractions appear to conform to the above waves in human subjects.

Radiographic contraction patterns

The radiographically visible contraction patterns were studied in 20 normal adult subjects. The subjects were considered to be normal if clinical and radiological examination failed to show evidence of an organic lesion in the oesophagus, stomach and duodenum. In view of the 'wire studies' and pressure measurements mentioned above, the relevance of the radiologically visible contraction patterns could now be accepted. The movements were identical to those documented in previous studies.^{15,16}

In all subjects it was seen that the pyloric aperture did not open (i.e. the ring did not relax) reciprocally with an oncoming peristaltic wave, in the sense that a wave travelled up to the ring, which then relaxed. Gastric 'peristaltic' waves, i.e. narrow annular waves commencing in the corpus and moving in a caudal direction, never proceeded as far as the ring (or aperture). At a point 3 - 4 cm orally to the ring, the peristaltic wave became stationary, at the same time initiating a tube-like, cylindrical contraction of the remainder of the stomach, i.e. of the pyloric sphincteric cylinder (Fig. 6). During active contractions the diameter of the pyloric aperture varied in direct proportion to the diameter of the sphincteric cylinder. With the cylinder relaxed, the diameter of the aperture was wide, i.e. it was patent. Contraction of the cylinder narrowed the diameter of the aperture, and with maximal contraction of the cylinder the aperture closed.

In other words, closing and opening of the pyloric aperture (which is surrounded by the ring) were seen to be a function of contraction and relaxation, respectively, of the sphincteric cylinder. Being an inherent part of the cylinder, the ring showed an identical contraction pattern and did not function independently.

Conclusions

Anatomical, manometric and radiographic evidence points to the existence of a sphincteric cylinder at the pylorus. Anatomically the pyloric ring (sphincteric ring) is not a separate structure but an inherent part of the sphincteric cylinder.

The studies show that the ring surrounding the pyloric aperture does not function independently. Neither does it relax reciprocally with an oncoming peristaltic wave, in the sense that a wave travels up to the ring, which relaxes upon its arrival.

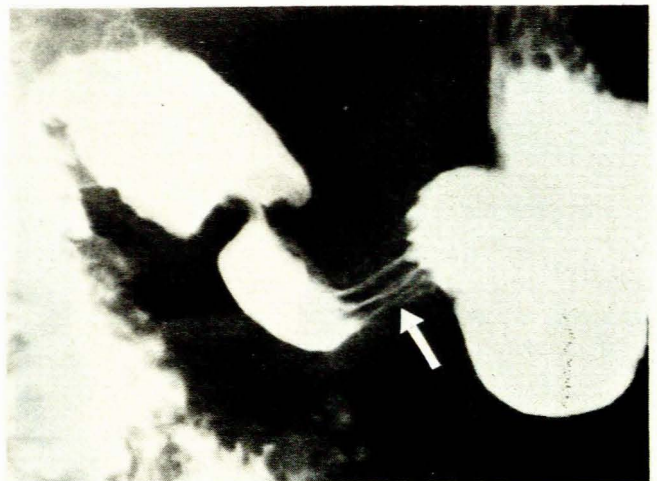


Fig. 6. Radiograph showing normal tube-like contraction of pyloric sphincteric cylinder. Arrow denotes point at which peristaltic wave becomes stationary.

Conventional, annular peristaltic waves, commencing in the corpus, do not proceed as far as the pyloric ring but stop at a point approximately 3 - 4 cm orally to the ring. Each wave then initiates a characteristic segmental or tube-like contraction of the sphincteric cylinder.

At rest the cylinder, including the ring, is relaxed and the aperture is open. During contractile activity the entire cylinder, including the ring, functions as a unit. Contraction of the cylinder narrows the diameter of the ring and closes the aperture. Contraction and relaxation of the ring, i.e. closing and opening of the pyloric aperture, are functions of similar movements of the cylinder.

These findings confirm the physiological view that the pylorus is open at rest, and that it closes intermittently during gastric emptying.

REFERENCES

1. Edwards DAW. Physiological concepts of the pylorus. *Proc R Soc Med* 1961; **54**: 930-933.
2. Edwards DAW, Rowlands EN. Physiology of the gastroduodenal junction. In: Code CF, ed. *Handbook of Physiology*, section 6, vol. 4. Washington: American Physiological Society, 1968: 1985-2000.
3. Shepard RS. The digestive system (motility). In: Shepard RS, ed. *Human Physiology*. Philadelphia: JB Lippincott, 1971: 415-420.
4. Ruch TC. Motility of the gastrointestinal tract. In: Ruch TC, Patton HD, eds. *Physiology and Biophysics*, vol. 3. 20th ed. Philadelphia: WB Saunders, 1973: 14-21.
5. Cunningham DJ. The varying form of the stomach in man and the anthropoid ape. *Trans R Soc Edin* 1906; **45**: 9-47.
6. Forssell G. Ueber die Beziehung der Röntgenbilder des menschlichen Magens zu seinem anatomischen Bau. *Fortschritte auf dem Gebiet der Röntgenstrahlen* 1913; suppl. 30.
7. Cole LG. The living stomach and its motor phenomenon. *Acta Radiol* 1928; **9**: 533-545.
8. Torgersen J. The muscular build and movements of the stomach and duodenal bulb. *Acta Radiol* 1942; suppl. 45.
9. Fisher R, Cohen S. Physiological characteristics of the human pyloric sphincter. *Gastroenterology* 1973; **64**: 67-75.
10. Kaye MD, Mehta SJ, Showalter JP. Manometric studies of the human pylorus. *Gastroenterology* 1976; **70**: 477-480.
11. Rees WDW, Go VLW, Malagelada JR. Simultaneous measurement of antroduodenal motility, gastric emptying and duodeno-gastric reflux in man. *Gut* 1979; **20**: 963-970.
12. McNaught GHD. Simple pyloric hypertrophy in the adult. *J R Coll Surg Edin* 1957; **3**: 35-41.
13. Keet AD, Vermaak JC, Mouton J. Intraluminal pressure profiles and mucosal movements in the stomach and duodenum. *Am J Gastroenterol* 1978; **69**: 144-148.
14. Carlson HC, Code CF, Nelson RA. Motor action of the canine gastroduodenal junction: a cineradiographic, pressure and electric study. *Am J Dig Dis* 1966; **11**: 155-172.
15. Keet AD. The prepyloric contractions in the normal stomach. *Acta Radiol* 1957; **48**: 413-424.
16. Keet AD. Diameter of the pyloric aperture in relation to the contraction of the *canalis egestorius*. *Acta Radiol* 1962; **57**: 31-44.