



## CLINICAL IMAGES

### Pentastomiasis (*Armillifer armillatus* infestation)

Vicci du Plessis, Andrew J Birnie, Ivor Eloff, Helmuth Reuter, Savvas Andronikou

Pentastomiasis, also known as 'tongue worm' infestation or porocephalosis, is a parasitic zoonosis endemic to western and central Africa. In 1847, Pruner described the first human infection by a pentastomid in Cairo.<sup>1</sup> The definitive hosts are snakes and other reptiles, while the intermediate hosts are carnivorous mammals and, rarely, humans. Most cases of human pentastomiasis are caused by two species of pentastomids, both of which have characteristics of arthropods and annelids, viz. *Armillifer armillatus* and *Linguatula serrata*. Adult pentastomids parasitise the upper respiratory tracts of snakes, lizards and other reptiles (definitive hosts). Humans become intermediate hosts by ingesting ova or larvae in contaminated food or water. Transmission may occur by handling or eating infected snakes (via respiratory discharges, saliva or faeces). *A. armillatus* infection is mostly asymptomatic in humans and is therefore an incidental finding either during surgery, at postmortem<sup>2</sup> or by radiological investigation

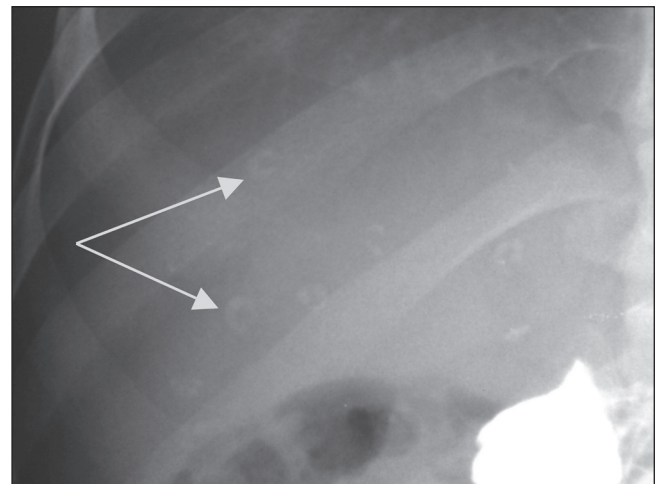


Fig. 1. Plain X-ray of the liver (following barium meal) demonstrates the numerous comma-shaped calcified nymphs of *Armillifer armillatus*.

*Vicci du Plessis (né Smith) graduated at Stellenbosch University in 2003 and is in her first year as a registrar in radiology at Grey's Hospital in Pietermaritzburg.*

*Andrew Birnie graduated at the University of Bristol in 2000 and is in his final year of dermatology training at Nottingham University Hospitals NHS Trust, UK. His interests include skin cancer and dermatological surgery.*

*Ivor Eloff graduated at the University of the Witwatersrand in 1962, started a career in radiology in 1974, and is currently Head of the Department of Radiology at the East London Hospital Complex.*

*Professor Helmuth Reuter is a consultant in infectious diseases in Cape Town. His research interests include tuberculosis and HIV.*

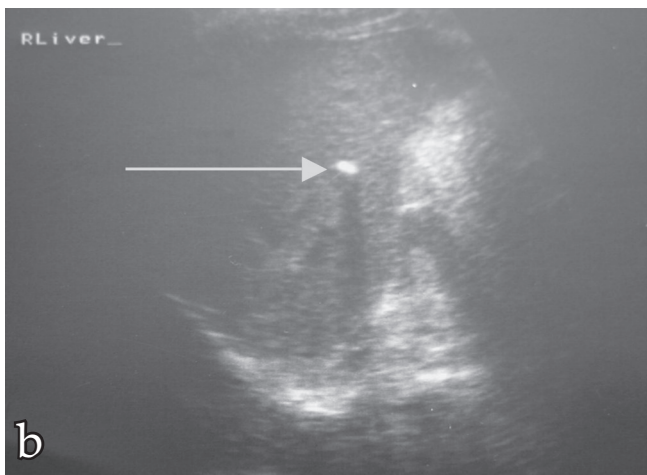
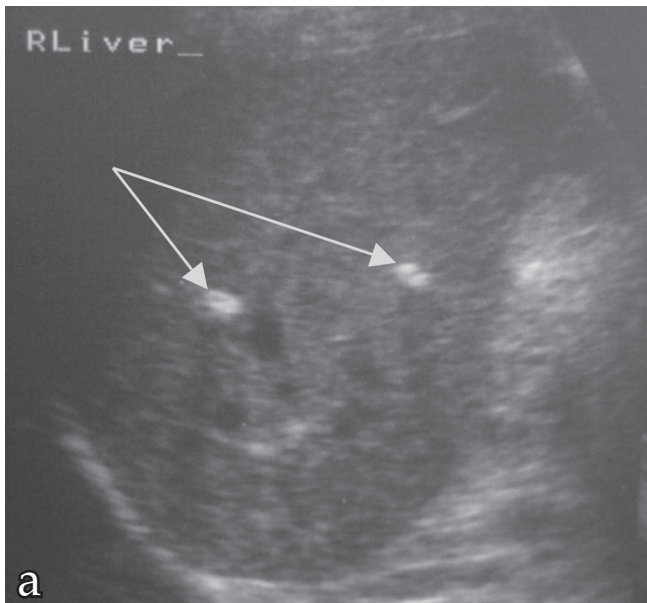
*Savvas Andronikou is Chair Professor of Radiology at Stellenbosch University, Head of the Department of Radiology at Tygerberg Hospital, chief editor of the South African Journal of Radiology and secretary of the College of Radiologists. His research fields are TB and HIV novel imaging techniques.*

for unrelated pathology.<sup>3-6</sup> A few cases of infected patients presenting with abdominal discomfort,<sup>7-9</sup> a patient presenting with an acute abdominal emergency,<sup>10</sup> two isolated cases of lethal infection,<sup>11</sup> and infection of the human eye<sup>12,13</sup> have been reported.

#### Case report

A 39-year-old Nigerian man, who emigrated to South Africa in 2001, presented with a 1-year history suggestive of hiatus hernia or gastro-oesophageal reflux disease (GORD). A barium meal examination was normal apart from the incidental finding of a number of calcifications in the liver, predominantly in the right upper quadrant, and a few in the mid-abdominal area. These were crescent-shaped, characteristic of the calcified cysts of *A. armillatus* (Fig. 1). The patient confirmed that snake had been a regular part of his diet while he was living in Nigeria. Typical preparation of the snake involved cutting it into sizeable pieces, then boiling the pieces in hot water before slicing them, adding spices and cooking over an open fire.

Abdominal ultrasound revealed multiple small calcified granulomas in the right lobe of the liver (Figs 2a and b). The kidneys, spleen and pancreas were normal. Radiographs of the chest and thighs revealed no parasitic calcifications. A gastroscopy revealed early grade A reflux oesophagitis.



Figs 2a and b. Ultrasound scan of the liver shows echogenic foci with posterior acoustic shadowing, caused by calcifications of parasitic nymphs concentrated in the right lobe.

## Discussion

*Armillifer* parasites occupy the tracheae and bronchi of African rock pythons, puff adders and Mozambiquan spitting cobras.<sup>14</sup> Several hours after the *Armillifer* ova reach the intestinal tract of the intermediate host, an embryo emerges to become a first-stage larva. These penetrate the intestinal walls and migrate along the peritoneum and pleura but cause little or no significant clinical reaction, although pneumonitis, bronchitis, pleuritis, pericarditis, hepatitis and peritonitis have been noted in patients with severe infection. The larvae become encysted in various subperitoneal tissues such as the liver, spleen,

mesentery and lungs.<sup>15</sup> Usually they die and calcify within two years of infection of a human host.<sup>16</sup> They rarely produce extensive tissue damage or clinical symptoms, except in cases of heavy infestation when the migration of many live *A. armillatus* larvae beneath the peritoneum or pleura may cause sufficient irritation and pain to mimic an acute abdominal condition. The developing cysts can be harmful if they increase in size and volume and cause pressure on structures such as bile ducts or bronchi, leading to obstruction<sup>10</sup> and infection. In Ibadan in Nigeria, pentastomiasis was found to be the third most common cause of hepatic fibrosis after tuberculosis and schistosomiasis.<sup>17</sup> Calcified nymphs of *Armillifer* are easily recognised radiologically; they are crescent-, horseshoe- or comma-shaped, or coiled when seen face-on. They vary from 4 mm to 8 mm in size, are always multiple and are generally localised to the chest and upper abdomen (Figs 1 and 2a, b).

*Armillifer* calcifications are not found in muscle, which distinguishes them from the calcified cysts of cysticercosis. *Armillifer* calcifications may be confused with calcified mesenteric lymph nodes, or calculi, but the parasites are invariably multiple.

Pentastomiasis can only be treated by surgical removal of the parasites, which is performed only when it becomes a serious medical condition.

The authors thank Dr Alison Horsell for assistance with ultrasonography.

1. Cannon DA. Linguatid infestation of man. *Ann Trop Med* 1942; 36: 160-167.
2. Guardia SN, Sepp H, Scholten T, Morava-Protzner I. Pentastomiasis in Canada. *Arch Pathol Lab Med* 1991; 115: 515-517.
3. Nzeh DA, Akinlembola JK, Nzeh GC. Incidence of *Armillifer armillatus* (pentastome) calcification in the abdomen. *Cent Afr J Med* 1996 42(1): 29-31.
4. Tiendrebeogo H, Levy D, Schmidt D. Human pentastomiasis in Abidjan. A report on 29 cases. *Revue Française des Maladies Respiratoires* 1982; 10: 351-358.
5. Pieron R, Mafart Y, Lesobre B, Meyniel D. Two cases of pentastomiasis observed in Paris. *Semaine des Hôpitaux* 1982; 58: 1047-1048.
6. Ancelle T, Daireaux P, Chemoul F, Lapiere J. A case of porocephalosis disclosed by echography during evaluation of hepatic amebiasis. *Presse Med* 1988; 17: 437.
7. Obengui, Moyen G, Mbika-Cardorelle A, Assambo-Kieli C. Porocephalosis: still a rare diagnosis. *Sante* 1999; 9: 357-360.
8. Fisch A, Lepout J, Bloch F, Sebag A, Frija J, Petite JP. Human pentastomiasis: clinical, radiological and X-ray computed tomographic study of a case. *Gastroenterol Clin Biol* 1985; 9: 263-265.
9. Mulder K. Porocephalosis. *Dtsch Med Wochenschr* 1989; 114: 1921-1923.
10. Herzog U, Marty P, Zak F. Pentastomiasis: case report of an acute abdominal emergency. *Acta Trop* 1985; 42: 261-271.
11. Lavarde V, Fornes P. Lethal infection due to *Armillifer armillatus* (Porocephalida): A snake-related parasitic disease. *Clin Infect Dis* 1999; 29: 1346-1347.
12. Lazar M, Traub Z. *Armillifer armillatus* in a human eye. *Am J Ophthalmol* 1967; 63: 1799-1800.
13. Neumann E, Gratz NG. Eyelid infestation by *Armillifer armillatus*. *Am J Ophthalmol* 1962; 54: 305-307.
14. De Meneghi D. Pentastomes (Pentastomida, *Armillifer armillatus* Wyman, 1848) in snakes from Zambia. *Parassitologia* 1999; 41: 573-574.
15. Hopps HC, Howard C. Pentastomiasis. In: Marcial-Rojas RA, ed. *Pathology of Protozoal and Helminthic Diseases*. Baltimore: Williams and Wilkins, 1971.
16. Drabick JJ. Pentastomiasis. *Rev Infect Dis* 1987; 9: 1087-1094.
17. Smith JA, Oladiran B, Lagundoye SB. Pentastomiasis and malignancy. *Ann Trop Med Parasitol* 1975; 69: 503-512.
18. Pentastomiasis. <http://www.stanford.edu/class/humbio103/ParaSites2001/pentastomiasis/Erica%20parawebiste.html> (last accessed September 2006).