


The Application of 3D Printing in reconstructive surgery

by
John Robert Honiball

*Dissertation presented in fulfilment of the requirements for the degree
MscIng in Industrial Engineering at the
University of Stellenbosch*



Promotor: Prof Dimi Dimitrov
Department of Industrial Engineering

March 2010

Declaration

By submitting this dissertation electronically, I declare that the entirety of the work contained therein is my own, original work, that I am the owner of the copyright thereof (unless to the extent explicitly otherwise stated) and that I have not previously in its entirety or in part submitted it for obtaining any qualification.

March 2010

Copyright © 2010 Stellenbosch University

All rights reserved

Synopsis

As part of a growing trend in the medical industry of patient specific solutions, a need arises for means and methods that could grant surgeons the ability to improve their pre-operative planning, and help streamline their intra-operative proceedings relative to each individual patient.

A suitable solution has emerged in the form of Additive Fabrication. Most of the traditional layer manufacturing technologies have been considered to be too expensive for medical application, and could not always be justified. However, more cost effective technologies, such as 3D Printing, have recently come to the scene and definitely require a fresh re-consideration for medical applications.

In this report the research results are presented that look at the applications of 3D Printing in various fields of reconstructive surgery. Based on a variety of case studies the outcome strongly suggests that 3D Printing might become part of standard protocol in medical practice in the near future.

Opsomming

Tans beweeg die mediese veld al hoe meer in die rigting van pasiënt uniekheid. Dit beteken dat behandeling begin weg beweeg van standaard prosedures en soveel moontlik aangepas word om aan te pas by elke unieke pasiënt. As deel hiervan ontstaan die behoefte by chirurge om hul operasies ook beter te beplan spesifiek tot elke individu, en sodoende te verseker dat die prosedures in teater so glad moontlik verloop.

Daar is reeds tegnologies in die vorm van Additiewe Vervaardiging wat hierdie probleem aanspreek. Tot op hede was die finansiële implikasies vir meeste van die onderskeie tegnologies 'n struikelblok wanneer dit kom by mediese toepassings. Tog, danksy meer koste effektiewe tegnologies soos 3D Drukwerk, is dit die moeite werd om weer op nuut te kyk na die moontlikhede wat die tegnologies kan bied.

In hierdie verslag word daar gekyk na die verskillende toepassings van 3D Drukwerk in die veld van rekonstruktiewe chirurgie. Op grond van die resultate verkry vanaf 'n wye verskeidenheid gevalle studies word die gevolgtrekking gemaak dat bekostigbare tegnologies soos 3D Drukwerk 'n baie goeie kans het om in die nabye toekoms deel te word van standaard prosedure in die mediese praktyk.

Acknowledgements

I would like to acknowledge the following people and companies for their contribution to this project:

Prof. Jean Morkel (Oral & Maxillofacial Surgeon, Tygerberg Hospital, University of the Western Cape)

Dr. Daan Botes (Orthopaedic Surgeon, Paarl Medi-Clinic)

Prof. Hartzenberg (Neurosurgeon, Tygerberg Hospital, University of Stellenbosch)

Dr. Hanno Vivier (Neurosurgeon, Tygerberg Hospital, University of Stellenbosch)

Dr. Ian Vlok (Neurosurgeon, Tygerberg Hospital, University of Stellenbosch)

Prof. Gert Vlok (Orthopaedic Surgeon, Tygerberg Hospital, University of Stellenbosch)

Dr. Paul Botha (Periodontist)

Prof. Frank Graewe (Plastic & Reconstructive Surgeon, Tygerberg Hospital, University of Stellenbosch)

Prof. Dimi Dimitrov (RPD Laboratory, University of Stellenbosch)

Mr. Neal De Bear (RPD Laboratory, University of Stellenbosch)

ISQU Orthopaedics (Orthopaedic implant manufacturers, Cape Town)

Physical 3D Modelling (Manufacturers of anatomical models and surgical tooling, Stellenbosch)

Table of Contents

Declaration	i
Synopsis	iii
Opsomming	iv
Acknowledgements	v
List of figures	ix
List of tables	xi
Glossary	xii
1. Introduction	15
1.1. <i>Problem statement</i>	15
1.2. <i>Research objective</i>	15
1.3. <i>Research approach</i>	16
2. Literature review	17
2.1. <i>Background</i>	17
2.2. <i>Advantages</i>	18
2.3. <i>Additive manufacturing in South Africa</i>	18
2.4. <i>Technologies applicable to the medical industry</i>	19
2.4.1. Stereolithography	19
2.4.2. Selective Laser Sintering	20
2.4.3. Fused Deposition Modelling	21
2.4.4. Three-Dimensional Printing	22
2.4.5. Electron Beam Melting	23
2.4.6. Selective Laser Melting	23
2.5. <i>Current medical applications</i>	24
3. Materials & Methods	27
3.1. <i>Data acquisitioning: CT and MRI</i>	27
3.1.1. Computed Axial Tomography (CT)	27

3.1.2.	Cone Beam CT	28
3.1.3.	Three-dimensional Computed Tomography Imaging	28
3.1.4.	Magnetic Resonance Imaging (MRI)	29
3.1.5.	Scanning for the purpose of medical modelling	29
3.2.	<i>Data manipulation: Medical image processing</i>	29
3.3.	<i>Manufacturing: 3D Printing</i>	33
4.	Process chain	36
4.1.	<i>Image processing process steps</i>	37
4.2.	<i>3D Printing process steps</i>	40
5.	Suitability of 3D Printing materials for surgical applications	44
5.1.	<i>Accuracy</i>	44
5.2.	<i>Mechanical properties (Appendix A)</i>	45
5.3.	<i>Sterilization</i>	46
5.4.	<i>Conclusion</i>	47
6.	Application areas: A selection of case studies	48
6.1.	<i>Orthopaedic surgery</i>	48
6.1.1.	Acetabulum pelvic fracture	48
6.1.2.	Hip revision of complex acetabulum fracture	51
6.1.3.	Elbow arthritis due to an old injury	54
6.1.4.	Echinococcosis cyst spine	56
6.1.5.	Patient specific implant design	58
6.1.5.1.	Custom hip replacement after excision of pelvic tumour	58
6.1.5.2.	Custom hip replacement after excision of infected bone	60
6.1.5.3.	Conclusion: Case Studies 1 and 2	62
6.2.	<i>Neurosurgery</i>	63
6.2.1.	Cranioplasty after trauma	64
6.2.1.1.	Cranioplasty of a small cranial defect	64
6.2.1.2.	Cranioplasty of a large cranial defect	66
6.2.1.3.	Conclusion: Case Studies 1 and 2	67
6.2.2.	Revision surgery cranioplasty	68
6.2.3.	Tumour excision and cranioplasty	70
6.2.3.1.	Excision of a meningioma followed by cranioplasty	70
6.2.3.2.	Debulking of a large meningioma followed by cranioplasty	73
6.2.3.3.	Conclusion: Case Studies 1 and 2	75
6.3.	<i>Oral & Maxillofacial surgery</i>	76
6.3.1.	Overview of fibula free-flap reconstructive surgery of ameloblastoma tumours	76
6.3.2.	Application of 3D printed models in fibula free-flap reconstructive surgery of ameloblastoma tumours	80

6.3.2.1.	Excision of an ameloblastoma from the right half of the mandible followed by fibula free-flap reconstruction	80
6.3.2.2.	Excision of a large ameloblastoma followed by fibula free-flap reconstruction	84
6.3.2.3.	Surgeon's opinion on Case Studies 1 and 2	86
6.3.2.4.	Conclusion: Case Studies 1 and 2	86
6.4.	<i>Plastic & Reconstructive surgery</i>	88
6.5.	<i>Periodontics</i>	91
7.	Summary of results	94
8.	Conclusions	97
9.	Outlook	101
	References	102
	Appendix A: Mechanical tests for medical suitability of 3D printed parts	104
	Appendix B: Sample of form used to gather case study data	110
	Appendix C: Example of work presented at a Medical Congress	111

List of figures

FIGURE 1: ADDITIVE MANUFACTURING IN SOUTH AFRICA	18
FIGURE 2: STEREOLITHOGRAPHY PROCESS	20
FIGURE 3: SELECTIVE LASER SINTERING PROCESS	20
FIGURE 4: FUSED DEPOSITION MODELLING PROCESS	21
FIGURE 5: 3D PRINTING PROCESS	22
FIGURE 6: SELECTIVE LASER MELTING PROCESS	23
FIGURE 7 : CT SCANNER	27
FIGURE 8: 2D SLICED IMAGE OF A FACIAL CT SCAN	27
FIGURE 9: 3D IMAGE OBTAINED WITH THREE-DIMENSIONAL CT IMAGING	28
FIGURE 10: ZPRINTER 310 FROM Z CORPORATION.....	34
FIGURE 11: PROCESS CHAIN	36
FIGURE 12: IMPORTING AN IMAGE.....	37
FIGURE 13: VIEW OF THE IMPORTED CT IMAGE.....	37
FIGURE 14: CREATING A MASK BY SETTING THE THRESHOLD.....	38
FIGURE 15: CREATING A 3D IMAGE OF THE MASK	38
FIGURE 16: EDITING THE MASK TO CREATE A NEW MASK.....	39
FIGURE 17: CREATING A 3D IMAGE OF THE NEW MASK.....	39
FIGURE 18: FINAL 3D IMAGE READY TO BE EXPORTED AS A STL.....	40
FIGURE 19: SIMULATION OF THE STL MODEL ON ZPRINT SOFTWARE	40
FIGURE 20: REMOVING THE PART FROM THE 3D PRINTER	41
FIGURE 21: OVEN SET AT 70°C.....	41
FIGURE 22: AUTOMATED WAXER	42
FIGURE 23: FINAL MODEL	43
FIGURE 24: TRUE MANDIBLE AND 3D PRINTED REPLICA	45
FIGURE 25: 3D PRINTED MODEL OF FRACTURED PELVIS.....	49
FIGURE 26: SURGEONS PLANNING THE SURGICAL PROCEDURE.....	49
FIGURE 27: MODEL BEING USED AS AN AID OF COMMUNICATION AND ORIENTATION.....	50
FIGURE 28: 3D PRINTED MODEL OF FRACTURED ACETABULUM	51
FIGURE 29: THREE SURGEONS USING THE 3D PRINTED MODEL TO DISCUSS THE SURGICAL PROCEDURE	52
FIGURE 30: 3D PRINTED MODEL USED FOR ORIENTING ONE OF THE SURGEONS RELATIVE TO THE PATIENT'S ANATOMY	52
FIGURE 31: USING THE 3D PRINTED MODEL TO DISCUSS IMPLANT PLACEMENT	53
FIGURE 32: 3D PRINTED MODEL OF ELBOW JOINT	54
FIGURE 33: SIMULATING ELBOW MOTION.....	55
FIGURE 34: 3D PRINTED MODEL BEING USED FOR PRE-OPERATIVE VISUALIZATION AND PLANNING.....	56
FIGURE 35: MODEL BEING USED AS AN ORIENTING AID AND MEANS OF COMMUNICATION	57
FIGURE 36: SELECTING THE IMPLANT AND INSERTING IT INTO THE PATIENT'S SPINE.....	57
FIGURE 37: VIRTUAL 3D OF PELVIS.....	58
FIGURE 38: CLOSE-UP VIEW OF DEFECT.....	59
FIGURE 39: IMPLANT DESIGN	59
FIGURE 40: PATIENT SPECIFIC IMPLANTS.....	59
FIGURE 41: POST-OPERATIVE X-RAYS SHOWING THE FINAL IMPLANT PLACEMENT	60
FIGURE 42: VIRTUAL MODEL OF PELVIS WITH PATIENT SPECIFIC IMPLANT	60
FIGURE 43: ANTERIOR AND SIDE VIEWS OF 3D PRINTED MODEL.....	61
FIGURE 44: VIRTUAL DESIGN AND POSITIONING OF PATIENT SPECIFIC IMPLANT.....	61
FIGURE 45: POST-OPERATIVE X-RAY SHOWING IMPLANT PLACEMENT	62
FIGURE 46: CENTRAL AND PERIPHERAL NERVOUS SYSTEM	63
FIGURE 47: 3D IMAGES OF CRANIUM WITH DEFECT.....	64
FIGURE 48: ORIENTATING THE 3DP RELATIVE TO THE DEFECT OF THE PATIENT	65
FIGURE 49: PATIENT SPECIFIC IMPLANT FIXATED INTO DEFECT	65
FIGURE 50: CRANIUM WITH TRAUMA DEFECT	66
FIGURE 51: VIRTUAL AND PHYSICAL 3D MODELS OF DEFECT.....	66

FIGURE 52: IMPLANT DESIGN AND FITMENT	67
FIGURE 53: IMPLANT PLACED IN DEFECT WITH A PERFECT FIT	67
FIGURE 54: VIRTUAL AND 3DP MODELS OF DEFECT AND POROUS MATERIAL.....	68
FIGURE 55: VIRTUAL AND PHYSICAL 3D MODELS OF DEFECT AND PATIENT SPECIFIC IMPLANT PROTOTYPE...	69
FIGURE 56: PATIENT SPECIFIC IMPLANT POSITIONED ON CRANIUM.....	69
FIGURE 57: VIRTUAL 3D OF CRANIUM WITH MENINGIOMA	71
FIGURE 58: 3D PRINTED MODEL WITH PLANNED AREA OF RESECTION	71
FIGURE 59: FITTING THE PATIENT SPECIFIC CUTTING GUIDE.....	72
FIGURE 60: USING CUTTING GUIDE TO MARK OFF AND RESECT THE TUMOUR INFECTED BONE	72
FIGURE 61: PATIENT SPECIFIC IMPLANT POSITIONED IN DEFECT WITH A PERFECT FIT.....	72
FIGURE 62: PRE-OPERATIVE PHOTOS OF THE PATIENT	73
FIGURE 63: VIRTUAL 3D VIEWS OF CRANIUM WITH MENINGIOMA.....	73
FIGURE 64: 3DP MODEL AND PATIENT SPECIFIC CUTTING GUIDE	74
FIGURE 65: MARKING OFF THE PLANNED AREA OF RESECTION AND REMOVING THE TUMOUR INFECTED BONE	74
FIGURE 66: POSITIONING THE PATIENT SPECIFIC IMPLANT	75
FIGURE 67: FIBULA FREE FLAP RECONSTRUCTION OF THE MANDIBLE	77
FIGURE 68: PATIENT WITH LARGE AMELOBLASTOMA	77
FIGURE 69: RADIOGRAPHIC IMAGES.....	78
FIGURE 70: BLOCK RESECTION OF AMELOBLASTOMA OF THE MANDIBLE.....	79
FIGURE 71: CONSTRUCTION OF NEW MANDIBLE FROM THE FIBULA	79
FIGURE 72: PATIENT IMMEDIATELY AFTER SURGERY,	80
FIGURE 73: PANTOMOGRAPH AND 3D	80
FIGURE 74: 3D PRINTED MODEL OF NORMAL VIEW	81
FIGURE 75: 3D PRINTED MODEL OF MIRRORED HALF	81
FIGURE 76: PLANNED AREA OF PARTIAL RESECTION	82
FIGURE 77: PRE-OPERATIVE DESIGN OF BONE GRAFT OSTEOTOMIES	82
FIGURE 78: BLOCK RESECTION OF TUMOUR INFECTED MANDIBLE.....	82
FIGURE 79: HARVESTING BONE FROM THE FIBULA TO RECONSTRUCT THE MANDIBLE.....	83
FIGURE 80: BONE GRAFT MANDIBLE RECONSTRUCTED FROM FIBULA (STILL CONNECTED TO BLOOD SUPPLY OF LEG).....	83
FIGURE 81: POST-OPERATIVE PANTOMOGRAPH.....	83
FIGURE 82: LATERAL RADIOGRAPH OF MANDIBLE AND 3D IMAGE OF PATIENT BEFORE SURGERY	84
FIGURE 83: 3DP MODEL	85
FIGURE 84: DESIGN OF THE PLANNED BONE GRAFT MANDIBLE	85
FIGURE 85: SURGEON STUDYING THE MODEL DURING A TIME-OUT PERIOD IN THE SURGERY	85
FIGURE 86: BONE GRAFT MANDIBLE (STILL CONNECTED TO BLOOD SUPPLY OF LEG) RECONSTRUCTED FROM FIBULA.....	86
FIGURE 87: 3D IMAGE OF FACIAL DEFORMITY.....	88
FIGURE 88: VIRTUAL RECONSTRUCTION TO RESTORE FACIAL SYMMETRY	89
FIGURE 89: MODEL SHOWING DEFECT.....	89
FIGURE 90: PROTOTYPE USED TO SHOW FACIAL RECONSTRUCTION.....	89
FIGURE 91: 3D IMAGE OF TOOTHLESS MANDIBLE AND MAXILLA.....	91
FIGURE 92: TOP AND BOTTOM VIEWS OF 3D PRINTED MODEL ON WHICH THE SURGEON PERFORMED HIS SURGICAL PLANNING	92
FIGURE 93: CLOSE-UP VIEW OF THE PLANNED POSITIONS FOR PLACING THE IMPLANTS.....	92
FIGURE 94: SURGICAL PROCEDURE	93
FIGURE 95: TEST BAR SAMPLES PRESENTED TO SURGEONS	104
FIGURE 96: WORK PRESENTED AT SAOA CONGRESS, CAPE TOWN, SEPTEMBER 2008	114

List of tables

TABLE 1: LIST OF AM TECHNOLOGIES AND THEIR BASE MATERIALS.....	19
TABLE 2: PROCESSES WITH MATERIALS THAT UNDERWENT USP CLASS VI TESTING	25
TABLE 3: CONVERSION SOFTWARE	30
TABLE 4: MIMICS FUNCTIONALITIES.....	33
TABLE 5: ACCURACY AND QUALITY OF ZCORPORATION'S 3D PRINTING.....	44
TABLE 6: SUMMARY OF RESULTS.....	46
TABLE 7: DIRECT COST IMPACT ANALYSIS.....	100
TABLE 8: COMBINATION OF SAMPLES PRESENTED TO THE SURGEONS	104

Glossary

Acetabulum	A concave surface on the pelvis forming part of the hip joint.
Additive Fabrication	A manufacturing technology used to form parts through the addition of material.
Ameloblastoma	An ameloblastoma is a slow growing tumour that is generally painless and benign in nature.
Arthritis	It is a group of conditions which involves damage to the joints of the body.
Autoclave	A device used to sterilize equipment or supplies by subjecting them to high pressure steam at 121°C or more.
CBCT	CBCT stands for Cone Beam CT. CBCT is one of the most modern X-ray technologies on the market and is used to produce detailed 3D images of the head, jaw, and neck.
CNS	Central nervous system.
Cranioplasty	A surgical repair of a defect or deformity of the skull.
Cranium	The bony structure of the head that protects the brain.
CT	CT stands for Computed Axial Tomography. CT is simply another technique of X-ray making use of a series of pictures taken off a patient's body to construct 2D or 3D images.
Echinococcosis cyst	A potentially fatal parasitic disease resulting from infection by tapeworm larvae.
Femur	The bone of a person's upper leg.
Fibula	The smaller one of the two bones in the lower leg.
Free-flap reconstruction	The movement of tissue from one part of the body to another

	part of the body for the purpose of reconstruction.
Implant	An implant is a device which is manufactured with the purpose of replacing, supporting, or enhancing a biological structure.
Mandible	The bone structure of the lower jaw.
Maxilla	The bone structure of the upper jaw.
Meningioma	One of the most common tumours of the central nervous system, usually benign in nature.
MRI	Stands for Magnetic Resonance Imaging. MRI is similar to CT but makes use of magnetism and radio waves to construct cross sectional images.
MTT	A system manufacturing group in England
Osteotomy	A surgical procedure whereby a bone is cut in order to shorten, lengthen, or change its alignment.
Parry-Romberg syndrome	A rare condition characterized by slowly progressive deterioration (atrophy) of the skin and soft tissues of half of the face.
Pelvis	The bone structure of the human body in the transition area between the trunk and the legs.
PNS	Peripheral nervous system.
Prototype	A model used to test or verify certain aspects of an intended design.
Proximal femur	Top part of the femur.
Reconstructive surgery	All the disciplines of surgery involving the treatment and or reconstruction of an injured, mutilated, or deformed part of the body by means of surgical intervention.
Radiographic data	Data obtained using medical imaging technologies to view internal structures in the body.

Radiographic imaging	Medical imaging procedures used to view internal body structures such as bone and organs.
Radius	A long bone extending from the lateral side of the elbow to the thumb side of the wrist.
Sterilization	The elimination of microbiological organisms.
Temporomandibular Joint (TMJ)	The joint that enables mastication (chewing).
Ulna	A long bone in the medial side of the forearm.
USP	The United States Pharmacopeia (USP) is a non-governmental, official public standards-setting authority for prescription and over-the-counter medicines and other healthcare products manufactured or sold in the United States.

1. Introduction

Additive Fabrication is a fast growing technology finding new areas of application in many fields of industry.

Globally a lot of research is being done on the applications of this technology in the medical field. Thus it is a necessity for South African researchers and medical force to familiarize itself with the relevant applications of this technology and the advantages it has to offer.

1.1. Problem statement

Reconstructive surgery involves the restoration of an injured, mutilated, or deformed part of the body. These can be present at birth or be the result of trauma, tumour, aging, infection, or disease.

Each reconstruction is case specific and requires a unique solution. As a result, the final outcome of the surgery is largely dependent on the surgeon's preparation and planning for the case.

Currently, surgeons are making use of aids like radiographic imaging to assist them in their pre-operative planning, and to guide them during execution of the surgery. The better the surgeon is able to plan and simulate the procedure, the easier it gets to approach the surgery with confidence and to avoid mistakes or complications. Still, however, surgeons are left with the challenge of having only 2D, or at most 3D virtual images which they need to apply in a physical environment with high levels of risk involving patient safety and health.

Thus, a need arises for means that could grant surgeons the ability to improve their pre-operative planning, and help streamline their intra-operative proceedings. Ultimately, the need is for a solution that could help minimise surgical risk and help deliver a service that would offer patients a better chance to full recovery.

As part of a growing trend in the medical industry of patient specific treatment, a solution to the above mentioned problem becomes available in the form of rapid prototyping. The applications of the various available technologies are vast and have already proved successful in various stages of the surgical process chain: pre-, intra-, and post-operative. However, most technologies are costly and cannot always be justified for use before and during surgery. Still, cost effective technologies, like 3D Printing, require a fresh consideration.

1.2. Research objective

The objective of this study is to look at the Additive Fabrication methods as a whole, 3D Printing in particular, and the advantages it has to offer for the field of reconstructive surgery. The work looks at various surgical fields and analyzes the results of using 3D printed models before, during and after the actual surgical procedures.

1.3. *Research approach*

The research starts with a literature review on the available Additive Fabrication technologies with medical applications, along with a few examples of successful implementations.

The materials used for producing 3D printed medical models are investigated under the particular aspect of their suitability.

Various surgical fields are studied to determine the possible areas of application of 3D printed models.

The advantages offered by 3D Printing to the field of reconstructive surgery become clearly visible through the case studies.

The results obtained are summarised, and the study is concluded with recommendations on the way forward.

2. Literature review

2.1. Background

Additive Fabrication (AF), also known as Additive Manufacturing (AM), Rapid Prototyping (RP) or Layered Manufacturing (LM), refers to the group of technologies that rely on a layer by layer process for building physical 3D objects, prototypes, tooling components, and final production parts. Unlike machining processes which are subtractive in nature, layered manufacturing involves processes that join together liquid, plastics, powder, or sheet materials to form parts. This enables the generation of parts which would otherwise be very difficult or even impossible to make.

The first commercially available RP technology was developed by 3D Systems in 1987. The technology was called Stereolithography (SLA). The first commercially available machine from 3D Systems was the SLA-1, which became the forerunner for some of today's popular machines.

The origin of Additive Fabrication can be traced to two areas namely topography and photosculpture. Topography is a layered method that was proposed by Blather in the early 1890s for making moulds for topographical relief maps. Photosculpture is a technique proposed in the 19th century for creating replicas of 3D objects. Development work in the area of Additive Fabrication continued in the 1960s and 1970s and led to the filing of a number of patents based on different methods and systems [1].

Today, Additive Fabrication systems are widely available. They are used mainly by engineers as a communication aid to improve understanding of new or different products, as well as for rapidly creating tooling used to manufacture final products.

Parts produced by Additive Fabrication have their origin in 3D CAD software, data retrieved from CT and MRI, or other scanning systems. All the technologies are based on the concept of thin horizontal cross-sections that are taken from the 3D data, and constructed one on top of the other to form a physical 3D part.

The standard data interface between the CAD software, and the Additive Fabrication machines, is known as Standard Triangulation Language (STL) file format. It is supported by every CAD vendor and has been adopted by all the RPM system suppliers as the primary interface with their system software [2].

When an STL file is created, all the boundary surfaces of the CAD model is transformed so that the whole surface is covered by a series of interlocking triangles. This allows for the whole part to be represented by a set of X, Y and Z coordinates at each of the three vertices of these triangles. There is a fourth piece of information that is included along with the coordinates. This is an index that describes the orientation of the surface normal. This feature makes it possible to ensure that a clear distinction can be made between the inner and outer surfaces of the triangles. The triangles used may be as large or as small as desired, but smaller triangles results in finer resolution of curved surfaces which improves the part accuracy. However, smaller triangles increase the amount of data necessary

to describe the part, and this can drastically increase the part's file size. This thus leads to a trade-off between storage space and part accuracy which will be determined by the user's needs and preference [2].

2.2. Advantages

The primary advantage of Additive Fabrication is as the term suggests: Material is added rather than taken away.

Due to this additive nature of the technology:

- The geometric complexities of parts that can be produced are almost without limit.
- The machine setup procedure is remarkably simplified when compared to contemporary milling procedures.
- Parts produced do not require fixtures (as is the case with machining). This allows the simultaneous production of various shaped parts at any relative x, y, or z position in the manufacturing area of the machine.
- Material wastage is reduced to a minimum.

Another huge advantage is speed. Contemporary methods for producing prototypes and/or final parts may require several days. With Additive Fabrication, however, build times, depending on the specific machine and technology used, typically range from a few minutes to several hours.

2.3. Additive manufacturing in South Africa

Additive Manufacturing technologies and applications continue to grow in SA. In 2008, 24 new machines were sold, with industry owned machines now far outnumbering the number of machines owned by academic institutions. At present, roughly 88% of all machines are 3D printers. The growth of AM systems in SA is shown in the graph below (Figure 1).

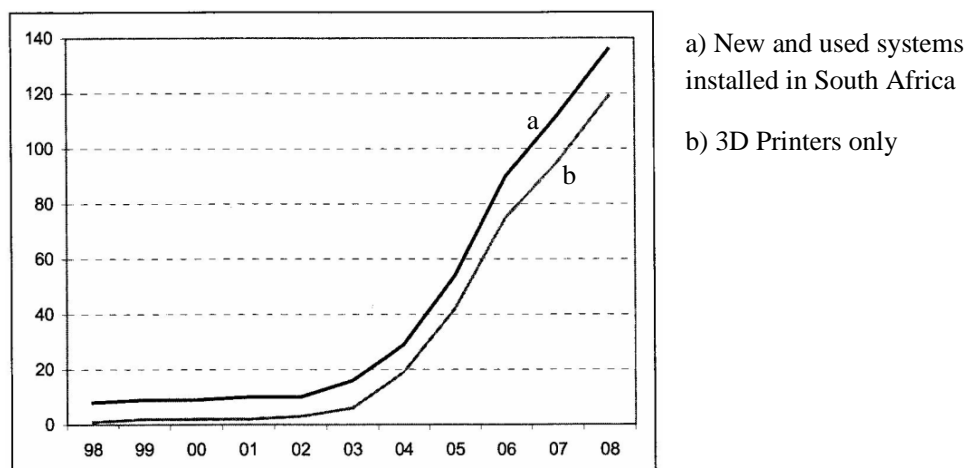


Figure 1: Additive Manufacturing in South Africa [2]

(Courtesy of Deon de Beer, Vaal University of Technology)

One of the national challenges is now to take AM into secondary schools and for learners to become aware of the career possibilities in manufacturing.

2.4. Technologies applicable to the medical industry

There are a large number of competing technologies available on the market, each with their own set of advantages and drawbacks. The technologies that have already proved themselves in the medical industry are:

- Stereolithography (SLA),
- Selective Laser Sintering (SLS),
- Fused Deposition Modelling (FDM),
- Inkjet-based systems and Three Dimensional Printing (3DP),
- Electron Beam Melting (EBM),
- Selective Laser Melting (SLM)

The main differences of these technologies are found in the processes and materials they use to construct layers to form physical 3D parts. Some make use of melting or softening of materials (SLS, FDM), others operate through the curing of liquid material (SLA), whereas others lay down powder materials which are “glued” together (3DP).

These technologies and their base material are listed (Table 1).

Prototyping Technologies	Base Materials
Stereolithography (SLA)	Photopolymer
Selective Laser Sintering (SLS)	Thermoplastics, metals powders
Fused Deposition Modelling (FDM)	Thermoplastics, metals.
3D Printing (3DP)	Specialized powder and binder materials
Electron Beam Melting (EBM)	Titanium alloys
Selective Laser Melting (SLM)	Metal alloys

Table 1: List of AM technologies and their base materials

2.4.1. Stereolithography

SLA is an Additive Fabrication process that makes use of liquid UV-curable photopolymer resin and a UV laser. The laser is used to construct parts by curing the resin one layer at a time (Figure 2).

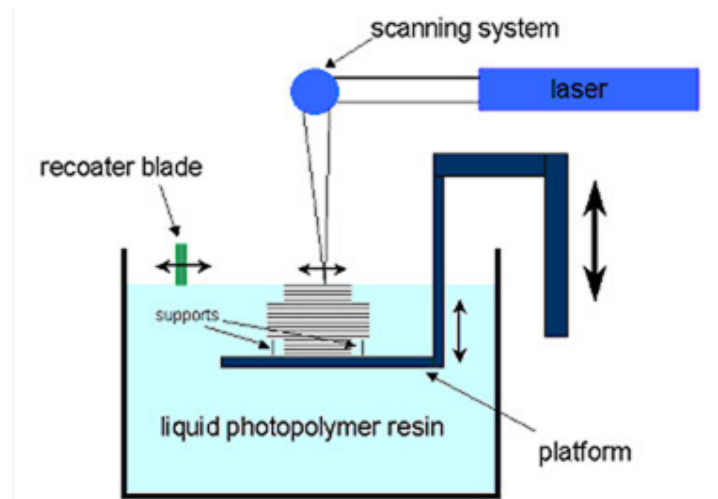


Figure 2: Stereolithography process [3]

Parts are formed by a UV laser beam tracing cross sectional layers on the surface of the UV-curable photopolymer resin. When the resin is exposed to the UV laser, it cures/solidifies according to the pattern traced on it by the laser and adheres to the layer produced before it.

Once the pattern has been traced, the tray containing the part is lowered by a single layer thickness. Next, a resin-filled blade sweeps across the part cross-section and re-coats it with fresh material. The subsequent cross-sectional layer is then traced on the new liquid surface and adhered to the previous layer. This process is repeated for all the layers until finally a complete 3D part is produced.

2.4.2. Selective Laser Sintering

Selective Laser Sintering is an additive process which fuses together small particles of powder by means of a high powered laser (Figure 3).

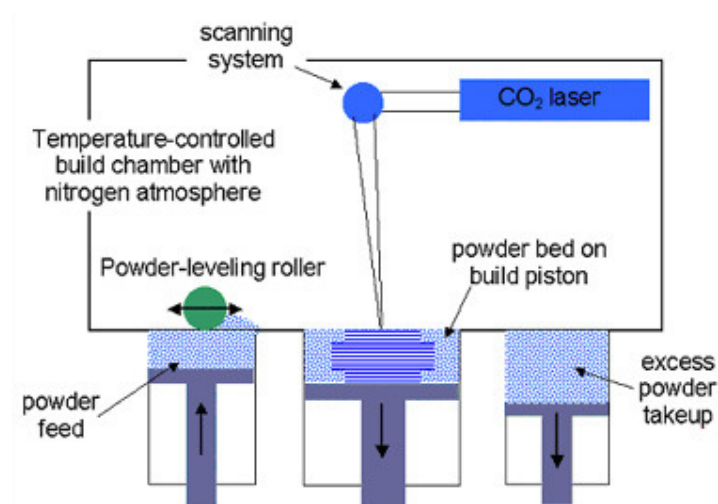


Figure 3: Selective Laser Sintering process [3]

A process similar to SLS was invented by R.F. Housholder. He patented the concept in 1979 but never commercialize it. SLS as it is known today was developed and patented by Dr. Carl Deckard at the University of Texas at Austin in the mid-1980s [4]. It first became available in 1992.

SLS has two basic sets of operations. The first is that of the laser. Thermal energy from the high powered laser enables the scanning system to fuse together the particles of powder material. Scanning is performed on the surface of a powder bed, in 2D cross sections, which are generated from a 3D digital image of the part.

The second set of operations is that of the platforms. The platforms are controlled by three pistons. Two are feed pistons responsible for controlling the powder supply, the third is a build platform which gradually moves downwards one layer thickness at a time as the subsequent layers of powder are added, and the 2D cross-sectional solidification is completed. A new layer of material is applied and all the operations are repeated.

The powder is maintained at a temperature just below its melting point. This helps to minimize the laser output required for fusion [5].

2.4.3. Fused Deposition Modelling

FDM is an additive process making use of a movable head to deposit a strand of molten material onto a substrate (Figure 4).

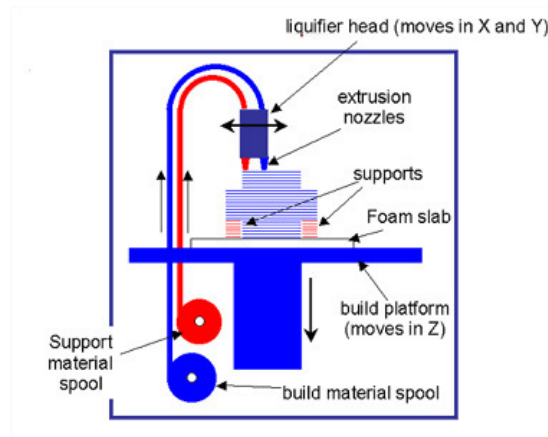


Figure 4: Fused Deposition Modelling process [3]

FDM was developed by S. Scott Crump in the late 1980s. It was commercialized in 1990 and is marked commercially by Stratasys Inc. [4]

A temperature controlled head is used to extrude material layer by layer. This is done with a plastic filament or metal wire that is unwound from a coil and supplied to an extrusion nozzle which can turn on and off the flow. This nozzle is heated and melts the material. The material temperature is kept just above melting point before extrusion, so that it solidifies very quickly after it has been extruded.

The nozzle is capable of moving both horizontally and vertically by means of a numerically controlled mechanism

2.4.4. Three-Dimensional Printing

3D Printing is an additive process making use of a powder based material and adhesive liquid binder for realizing a physical 3D object (Figure 5). 3D printers are generally faster, cheaper and easier to use than other additive processes [2].

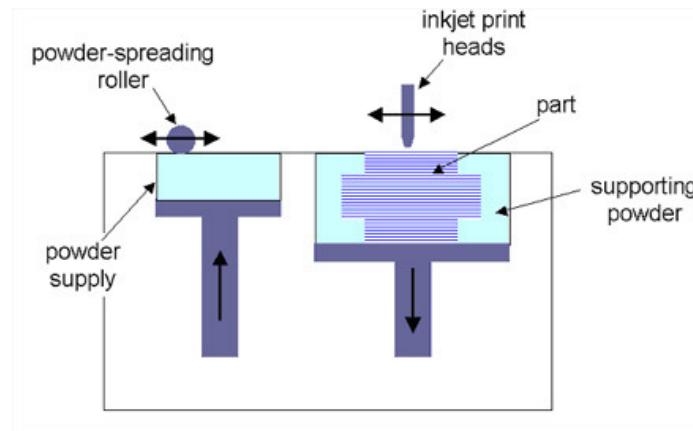


Figure 5: 3D Printing process [3]

3D Printing forms part of a range of deposition technologies that have been introduced in recent years. All these techniques have their roots in the ink jet printing technology with the use of a printer head being the only element they have in common.

The process of 3D Printing was invented and patented in December 1989 by Sachs et al. from the Massachusetts Institute of Technology (MIT). It was licensed to Z Corporation in 1994 and in 1996, the first system, the Z402, was commercialized.

3D Printing makes use of two basic building materials: a powder based material and a liquid binder. The 3D printer has two trays, a building tray and a feeding tray (Figure 5). The feeding tray contains the supply of powder. The building tray offers the platform on which the part is printed. A mechanical arm spreads the powder from the feeding tray onto the building tray, one layer at a time. A printing head is used to print two-dimensional cross-sections of liquid binder on top of each new layer of powder. As the successive layers are printed, the feeding tray moves up and the building tray moves down, one layer thickness at a time. The trays are controlled by pistons. This process repeats itself for each new layer until the final 3D model is complete.

When removed from the printer, the model is still fragile and requires further post processing to add to its mechanical strength.

2.4.5. Electron Beam Melting

Electron Beam Melting (EBM) is a type of RP technology that specifically produces metal parts which are 100% dense. EBM uses an electron beam gun in a vacuum, to produce parts by melting metal powder one layer at a time [2, 6].

It offers the capability to produce parts, with full mechanical properties, which does not require additional thermal treatment.

Arcam's EBM process can produce parts that are made of implantable-grade titanium and cobalt-chrome alloys.

It uses standard biocompatible material, like Ti6Al4V ELI, Ti Grade 2 and Cobalt-Chrome.

2.4.6. Selective Laser Melting

Selective Laser Melting (SLM) uses a 40µm beam spot fibre laser to fuse small particles of metal powders into a mass representing a desired 3D object (Figure 6).

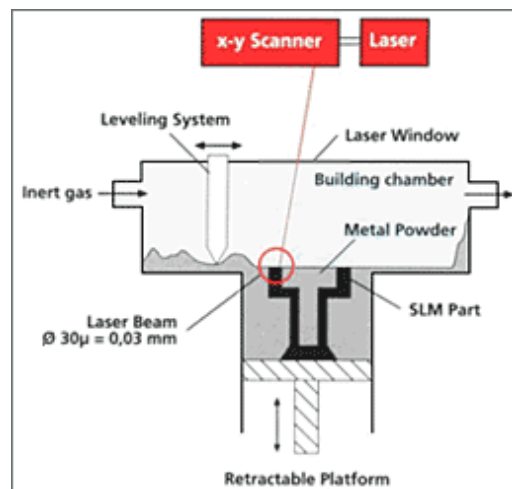


Figure 6: Selective Laser Melting process [7]

The laser selectively fuses powdered material by scanning cross-sections generated from a 3D CAD model of the part on the surface of a powder bed. After each cross-section is scanned, the powder bed is lowered by one layer thickness, a new layer of material is applied on top, and the process is repeated until the part is completed.

2.5. *Current medical applications [2]*

Hearing instruments

The hearing aids industry currently has one of the most successful production applications of additive manufacturing. AM, typically SL or the Perfactory system from Envisiontec, are used for producing hearing aid shells which, according to patients, fit more securely and are more comfortable. They also prevent acoustic feedback.

All top manufacturers are now using the technology to produce products in volume. Due to the large competition in the industry, it is believed that hearing aid manufacturers without AM technology are at a competitive disadvantage.

Dental restorations

Within the \$8.5 billion market, 3DP technology, licensed from MIT, is used to produce gold copings. The copings are then coated with porcelain to match patient's teeth. Compared to dark metals, gold copings produce much more realistic replacement teeth.

Using the SLM process from MTT, companies can produce 70 cobalt-chrome dental copings in eight hours. Meanwhile, it is possible to produce 380 cobalt chrome copings per 20 hours using Direct Metal Laser Sintering (DMLS) from EOS.

Surgical drill guides

Several companies produce drill guides for accurate drilling and placing of dental implants. These guides are manufactured from CT or CBCT.

Anatomical models

Anatomical models are physical replicas of patient's internal or external hard or soft-tissue structures. They help surgeons to improve their planning of complex surgical procedures, which results in a reduction of surgical time and more predictable surgical outcomes.

These models are produced using CT, CBCT, or MRI. The most common applications for these models include bending metallic reconstruction plates, creating patient specific facial implants, and measuring and fitting of complex devices meant to lengthen shortened bone such as the leg or jawbones.

Certain processes produce models in a USP Class VI-tested material, which may allow for sterilization of the model and limited in vivo exposure to human tissue (for periods less than 24 hours). This does not imply that these materials can be implanted. At present, no known commercially available material from non-metal additive processes is implantable. The materials that have undergone USP Class VI testing are listed (Table 2).

Additive process	Material (vendor name)	Method of sterilization
Stereolithography	YC-9300, YC-9500, YC-9500FT, HC-9100 and SL7810 (Huntsman). Somos 11122 (DSM Somos).	Autoclave, gamma irradiation, ethylene oxide, or hydrogen peroxide plasma
Selective Laser Sintering	DuraForm Polyamide (3DSystems)	Autoclave
Fused Deposition Modelling	ABS-M30i and PC-ISO (Stratasys)	Gamma irradiation or ethylene oxide
Multi-Jet modelling	VisiJet (3D Systems)	Unknown
PolyJet	FullCure/FullCureHA (Objet Geometries)	Unknown
Perfactory	e-Shell 200/e-Shell 300 (Envisiontec)	Unknown

Table 2: Processes with materials that underwent USP Class VI testing

SL was the first additive process to produce accurate anatomical replica models. Some surgeons prefer translucent models over opaque models, but the trend has been over the past few years for lower cost machines such as the Dimension from Stratasys, Eden from Objet, and the ZPrinter 310 Plus from Z Corp. This trend towards cost effective AM methods is likely to continue as manufacturers focus on users that cannot afford expensive machines.

Orthopaedic implants

The first range of series production orthopaedic implants was launched in the second half of 2007 by Ala Ortho of Italy. These implants are produced using EBM in titanium alloy Ti6-Al4-V. Since March 2009, Ala Ortho and another manufacturer of orthopaedic implants have used EBM to produce 10,000 metal hip implants of which about 2000 had been implanted into patients.

Bio manufacturing

A large number of organizations are investigating the use of Laser Sintering, Fused Deposition Modelling, and 3D Printing technologies to create scaffolds for tissue engineering, dental implants, and implants for bone reconstruction.

Tissue engineering is currently a subject of intensive research. Tissue engineering begins with living cells that are multiplied through cell culture. The cells are seeded into a 3D containment structure (scaffold) that facilitates the directed 3D growth and proliferation. The manufacturing of these scaffolds is the subject of AM research. Regenerative medicine is expected to provide replacement tissue and quite possibly entire organs. It is widely seen as one of the next great breakthroughs in medical treatment.

3. *Materials & Methods*

3.1. *Data acquisitioning: CT and MRI*

The three main non-invasive techniques for viewing internal structures are Computed Axial Tomography (CT), Cone Beam CT (CBCT) and Magnetic Resonance Imaging (MRI). CT and CBCT are the preferred techniques when it comes to viewing bony structures, with CBCT focusing specifically on the head, jaw, and neck. MRI on the other hand gives a better presentation of soft tissue structures.

3.1.1. Computed Axial Tomography (CT)

A CT or "Cat" scan stands for Computed Axial Tomography. CT is simply another technique of X-ray making use of a series of pictures taken off a patient's body to construct 2D or a 3D image. Detectors rotating around the patient receive the X-rays from a low-dose X-ray tube after they pass through the patient's body (Figure 7).

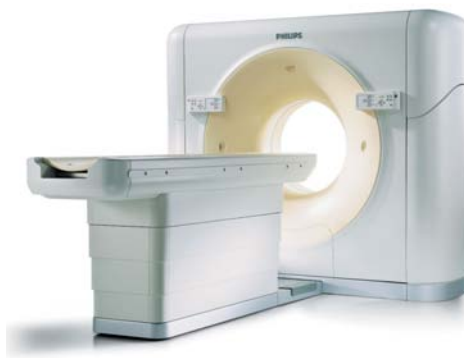

Figure 7 : CT scanner [8]

This results in data from multiple angles. These X-rays are then presented as images on a computer screen (Figure 8).

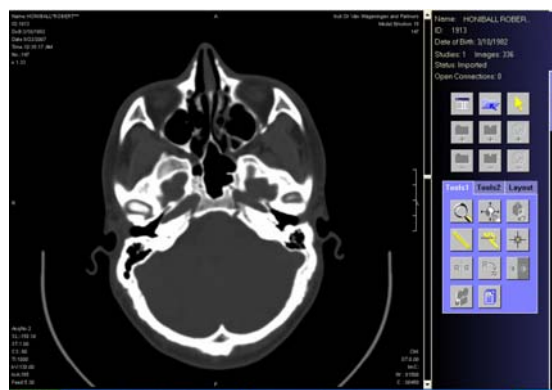

Figure 8: 2D sliced image of a facial CT scan

CT scanning is typically done to evaluate bone pathology including tumours and fractures, as well as viewing internal areas of the head, chest and abdomen [9]. It allows for accurate assessment of tumour size, composition, calcifications, subtle bony interruption, and extra osseous extension of spread [8].

Risk involved

A patient undergoing CT scanning is exposed to a certain amount of radiation from the X-rays. The level of radiation is kept to a minimum to prevent damage to body cells. The dose is said to be about the same as the average person receives from background radiation in three years. Pregnant woman should not undergo CT scanning as there is a small risk that it might cause abnormality in the unborn child [10].

3.1.2. Cone Beam CT

Cone Beam CT (CBCT) is one of the most modern X-ray technologies on the market and is used to produce detailed 3D images of the head, jaw, and neck. Whilst being scanned, the patient sits in an upright position instead of lying down as with conventional CT. The scanning procedure takes only about 18 seconds and the radiation dosage is about 97% lower than that of conventional CT.

3.1.3. Three-dimensional Computed Tomography Imaging

This is a post-processing technique based upon a volumetric data set. It consists of a stacked 0.5 to 2mm slices. Data separation of relevant tissue soft and bony structures is done from this data volume by means of a combination of threshold and exclusion techniques of non-relevant tissue. It allows for the isolation of separate bones, referred to as disarticulation, as well as for the assigning of colours to different structures, or cutting off of parts of a structure. These 3D models provide a detailed overview to allow specialists to comprehend the location, shape and extent of the pathology (Figure 9) [8].

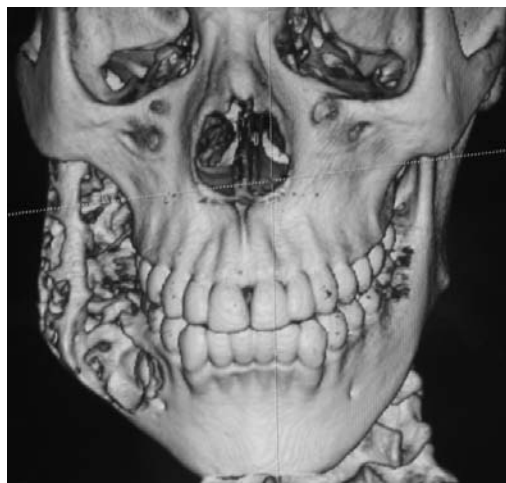

Figure 9: 3D image obtained with three-dimensional CT imaging

3.1.4. Magnetic Resonance Imaging (MRI)

MRI is similar to CT but makes use of magnetism and radio waves to construct cross sectional images. However, MRI is more costly and more time consuming than CT or X-ray.

3.1.5. Scanning for the purpose of medical modelling

More often than not, surgeons are interested in replicating bone anatomy. This means that CT and CBCT are generally the methods of choice.

The largest factor affecting the quality of the output of Additive Fabrication is the quality of the input data obtained from the scan.

The main factors affecting the quality of the scan are:

- The resolution settings of the scan performed.
- Metallic artefacts in the scanned area.

Resolution

The resolution is set by the radiologist. A resolution of 1mm slices or less is preferred for an excellent surface finish, but a resolution of up to 2.5mm slices will also be sufficient for accurate geometry. Slices thicker than 2.5mm start resulting in loss of detail and accuracy. However, the thinner the slices, the longer it takes to perform the scan. It is small enough to be neglected with CT, but with MRI, thinner slices can significantly prolong the scanning procedure.

Metallic artefacts

The presence of metallic artefacts in the scanned area results in scattering of the scan images. Scattering can be partially removed with the scanning software by the person performing the scan. It can also be partially compensated for whilst doing the data manipulation using MIP software, but usually results in a certain amount of loss of detail.

3.2. *Data manipulation: Medical image processing*

Most radiographic technologies used as input to Additive Fabrication processes produce data in serial section format in the form of 2D images. These images represent finite thicknesses of data taken at increments along the body being scanned.

Currently the most common format used to represent this data is the open-source DICOM3.0. (DICOM standing for Digital Imaging and Communications in Medicine) [2].

The primary tasks within the field of image processing for Additive Fabrication include [2]:

1. Import of native medical images
2. Threshold of images

3. Slice/volume editing
4. Region growing
5. STL file generation

Specialised software have been developed for this purpose

Some of the available products are listed (Table 3).

Product Manufacturer Website			Description
Mimics	Materialise	www.materialise.com	Imports from various medical-imaging modalities, processes the images, and exports to STL and native additive-manufacturing formats
3Matic	Materialise	www.materialise.com	Allows for digital design by manipulation of STL files. Useful in design and manufacture of complex prosthetic devices
RapidForm	INUS Technology	www.rapidform.com	Imports DICOM image data, processes the images, and exports to various formats
Velocity	Javelin3D	www.javelin3d.com	Imports from various medical-imaging modalities, processes the images, and exports to STL format
Analyze	Direct	www.analyzedirect.com	Imports from various medical-imaging modalities, processes the images, and exports to STL format (intended primarily for research)
3D Doctor	Able Software	www.ablesw.com	Imports from various medical-imaging modalities, processes the images, and exports to STL format

Table 3: Conversion Software [2]

The modelling software that was used for this project is MIMICS by Materialise. MIMICS stands for Medical Image Control System (MIMICS). MIMICS allows 3D reconstruction from any stacked 2D images. The only restriction is the computer memory. Common known examples are CT, TechCT, MRI and Microscopy data. This enables the planning and simulating of complex surgery, preparation of patient specific implants and construction of physical parts.

MIMICS consists of the following tools and functionalities: Segmentation tools, visualization & measurement tools, cutting, splitting, merging, mirroring and repositioning (Table 4).

Function	Description
Segmentation tools	<p>Segmentation masks are used to highlight certain regions of interest. The following functions are used for modification and editing of these masks:</p> <p>Threshold: Highlights and creates a mask of those pixels that fall within a specified grey value range.</p> <p>Region Growing: Eliminate noise and separate structures that are not connected.</p> <p>Editing (Draw, Erase, and Local Threshold): Manual editing functions make it possible to draw, erase or restore parts of images with a local threshold value. This is typically used for elimination of artefacts and separate structures.</p> <p>Dynamic region growing: Segmenting of an object based on the connectivity of grey values in a certain grey value range. It allows for easy segmentation of tendons and nerves in CT images.</p> <p>Morphology Operations: Morphology operations remove or add pixels from the source mask and copy the results to a target mask. This tool is extremely effective when working with MRI images.</p> <p>Boolean Operations: Allow the combination of two segmentation masks (Subtraction, Union and Intersection). These operations are very useful for reducing the work needed to separate two joints.</p> <p>Cavity Fill: Fills the internal gaps of a selected mask and copies the result to a new mask.</p> <p>Cavity Fill from Polyline: Creates a segmentation mask, starting from a polyline set. This tool is very useful for filling internal cavities.</p>
Visualisation & measurement	Visualisation:

Continued on next page

tools	<p>The screen is divided into three views: the original axial view and the resliced data consisting of the coronal and sagittal views. There are several visualisation functions such as contrast enhancement, panning, zooming and rotating of calculated 3D images. Colour scales are used to enhance small differences in the soft tissue or the bone. MIMICS displays the alignment or scout image and indicates the position of the axial slices in it.</p> <p>3D Rendering and 3D information: The 3D model can be displayed in any of the windows with visualisation functions that include real-time rotation, pan, zoom and transparency.</p> <p>Two RESLICING tools: Allows the user to display cross-sectional and parallel images along a user-drawn curve in the axial view. Users can define several different curves that are saved in the Mimics project. This line can be drawn in any view and in any direction.</p> <p>Measurement:</p> <p>Point to point: The user can perform point-to-point measurements on both the 2D slices and the 3D reconstructions.</p> <p>Profile line and grey value measurement: These methods are ideal for technical CT-users.</p> <p>Density measurements: Area, mean, grey value and standard deviation are displayed.</p> <p>Labels: Can be used to add information to 3D models.</p> <p>Reporting: The enhanced Print function allows you to print a complete report with general project information, 3D views and all axial and resliced images. You can make screenshots from all views and print them or save them to a file (BMP or JPEG). You can also export images in BMP or JPEG format in 1:1 scale.</p>
Cut	<p>Two Cutting methods are available: a Polyline Cut and a Polyline Cut with Cutting Plane.</p>

Continued on next page

Split	This operation splits the selected objects into their non-connected parts and generates a new 3D object for each of these parts.
Merge	This operation merges the selected objects into one part
Mirror	The Mirror function mirrors all selected objects around an indicated plane or around an existing plane.
Reposition	Parts can be moved in 2D using the mouse. Objects can be either translated or rotated. For each type of manipulation, positioning can be adjusted.

Table 4: MIMICS functionalities [11]

3.3. *Manufacturing: 3D Printing*

Wohlers [2] suggested that SL is still the preferred technology in the area of medical modelling. According to Wohlers, surgeons prefer translucent models over opaque models.

However, the question has to be placed as to what has been the most limiting obstacle for the penetration of layer manufacturing technologies into the medical field for the purpose of pre-operative planning. Tedious discussions with medical aid schemes and health institutions have shown that it all boils down to cost.

With this in mind, the line must be drawn between that which is desired, and that which is required.

The need to have would be accurate and cost effective medical models that could help surgeons improve their pre-operative planning and streamline their intra-operative procedures relative to each individual patient.

The desirable, being subjective to individual surgeons, would be translucency.

Taking these factors into strong consideration, it becomes clear why 3DP was selected for the purpose of this project.

Advantages

- 3D Printing is one of the fastest Additive Fabrication processes available. In some cases the time required to produce 3D printed parts can be up to ten times less than that of other additive processes [2, 12, 13].
- 3D printed parts are much cheaper than similar parts from other additive processes. The typical costs are less than half the price of parts produced by SLS and SLA [2, 12, 13].

- For the purpose of medical modelling, surrounding loose powder in the building tray offers sufficient support, and do not require support structures.
- 3D Printers are easy to use.
- 3D Printers are generally office friendly.

Disadvantages

- The variety of materials available for 3D Printing is very limited compared to some of the other additive processes, resulting in a limited range of mechanical properties.
- As mentioned earlier, 3D printed parts are still very fragile directly after being built, and require post processing (infiltration and heating) to achieve better mechanical strength.
- 3D Printing is not as accurate as some of the other additive processes[14, 15]

The Machine

The machine used for this project is the ZPrinter 310 (Figure 10) from ZCorporation.



Figure 10: ZPrinter 310 from Z Corporation

It is a monochrome machine with a build size of 203 x 254 x 203mm, resolution of 300 x 450 dpi, and a vertical build speed of 25mm/hour. The layer thickness range from 0.089 – 0.203mm.

Materials

The ZPrinter 310 allows the use of different material offering different mechanical characteristics [16]:

- **High performance material:**
 - zp131: A multi-purpose composite material that delivers strong, high definition parts
 - zp140: A composite material that require no further treatment or equipment to reach their finished strength.
 - zp150: A composite that delivers the strongest parts with the best resolution.
- **Casting materials:**
 - Direct Metal Casting: The ZCast 501 Direct Metal Casting process enables you to print moulds and cores directly from digital data, eliminating the pattern and core box production step used in traditional sand-casting processes. Metal is poured directly into the 3D printed moulds. Direct Casting Material can also be used to create sand casting patterns.
 - Investment Casting: zp 14 Investment Casting Material can be used to fabricate parts that can be dipped in wax to produce investment casting patterns. The material consists of a mix of cellulose, specialty fibres.
- **Elastomeric materials:** Elastomeric material is optimized for infiltration with an elastomer to create parts with rubber-like properties. The material consists of a mix of cellulose, specialty fibers, and other additives.

Materials used for this project

The materials used during this project were high performance:

Powder: Zp130 and Zp131 (A plaster-based material)

Binder: zb58 and zb60

Infiltrating agent: Epoxy resin slow hardener and wax

4. *Process chain*

The process chain used to manufacture 3D printed anatomical models is shown (Figure11).

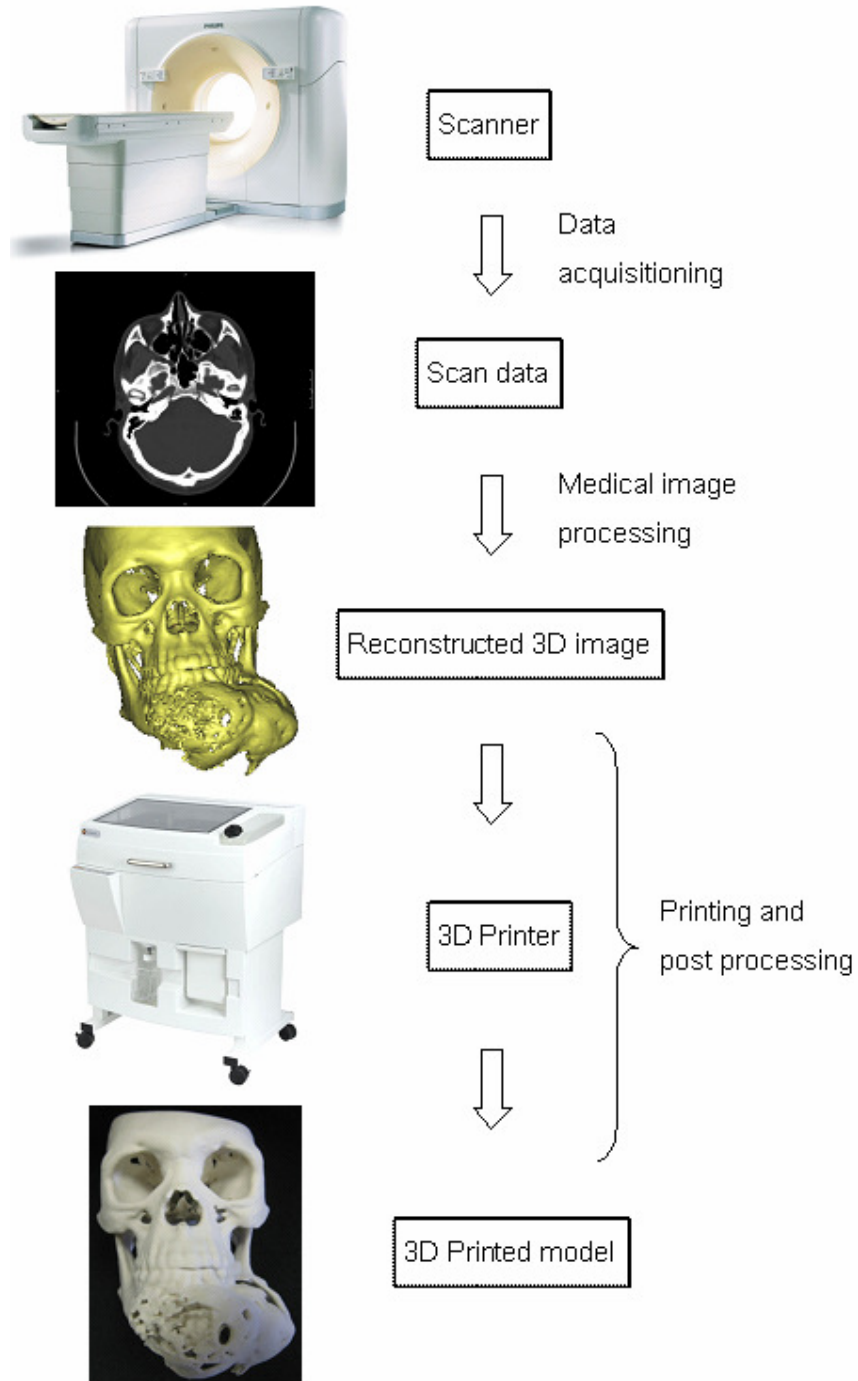


Figure 11: Process chain

4.1. Image processing process steps

- **Importing the CT image**

The first step is importing the CT image (Figure 12).

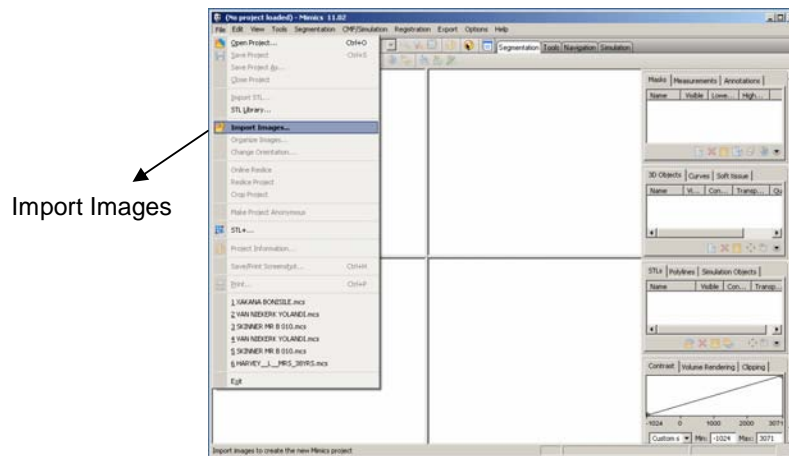


Figure 12: Importing an image

Having imported the desired CT image, the CT is displayed in three different views in separate windows on the screen (Figure 13). These views show the original axial view and the resliced data consisting of the coronal and sagittal views. The windows have scroll bars at the side which makes it possible to scroll through the imported CT image one slice at a time.

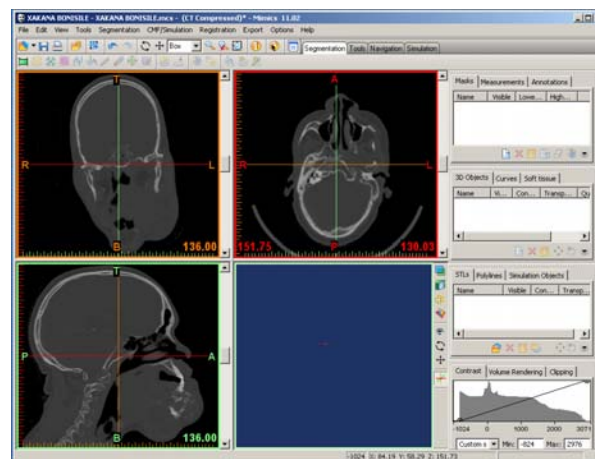


Figure 13: View of the imported CT image

- **Selecting the threshold and creating a mask**

3D Modelling now starts with the selection of threshold values, in the "Thresholding" toolbar (Figure 14), to highlight certain structures. These threshold values can be adjusted to highlight different hard and soft tissue structures. For this project, the focus is on bony structures. MIMICS has a standard

“Bone(CT)” threshold value, which is usually a good value to start from. All hard tissue/bony structures on the CT are then highlighted in colour.

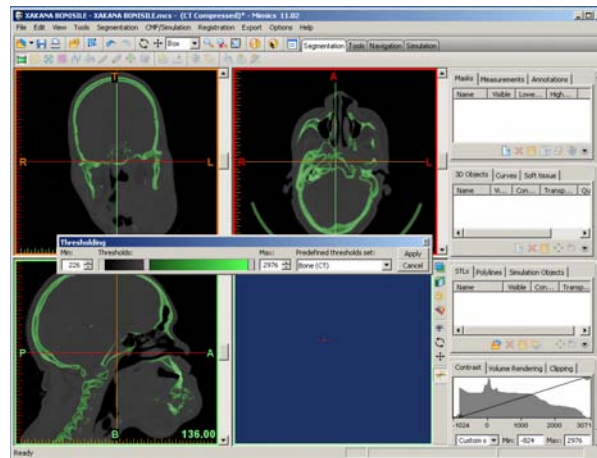


Figure 14: Creating a mask by setting the threshold

By clicking on the “Apply” button, a mask is created of the highlighted structures and is displayed in the “Masks” window in the top right hand corner of the screen.

- **Creating a 3D image**

Once the mask has been created, a 3D image can be generated by selecting the “Calculate 3D” tool. A menu box appears containing the available masks from which a 3D image can be created (Figure 15). At this stage there is still only the original mask (Green). The first iteration 3D image can now be obtained by clicking on the “Calculate” button.

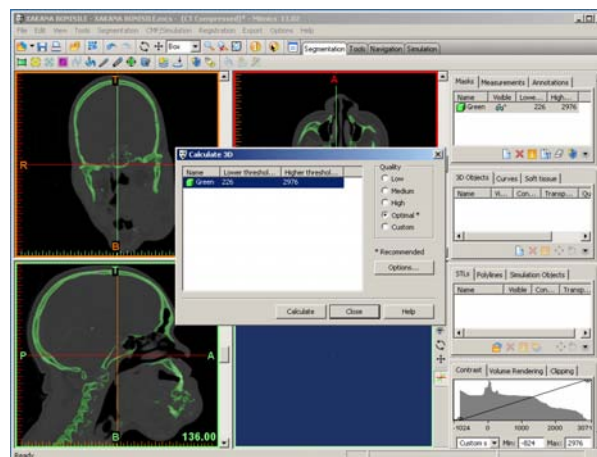


Figure 15: Creating a 3D image of the mask

- **Mask editing & iteration**

A 3D image appears in the fourth (blue) window. This image contains all the hard/bony structures that were highlighted in colour on the CT image. This image can be rotated, flipped, and enlarged to be

viewed from different proximities and angles. It is very seldom that the whole image is required for the purpose of Rapid Prototyping, and thus image manipulation is usually required before the final 3D image is achieved. “Edit Masks” is one of the tools offered by MIMICS for image manipulation (Figure 16). It allows the user to highlight (by selecting new threshold values), draw, and erase different features of the 3D image, and once the user is satisfied, creates a new mask of the modified 3D image. Other tools and functionalities (Table 4) are also available for image manipulation.

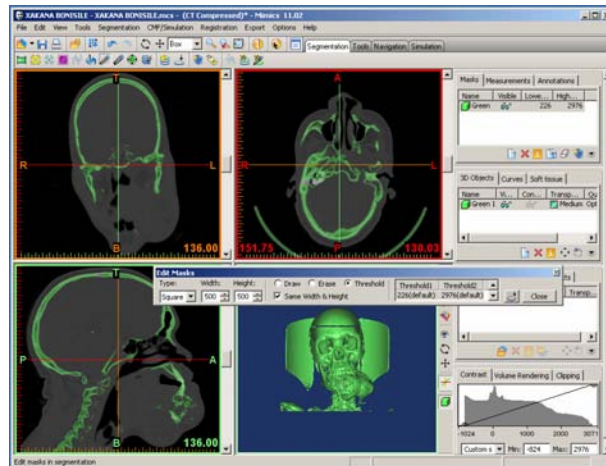


Figure 16: Editing the mask to create a new mask

The new mask (yellow) is now displayed in the “Masks” window (Figure 17). A new 3D image can now be created by selecting the new mask (yellow) in the “Calculate 3D” menu. Clicking on “Calculate” generates a new iteration 3D image.

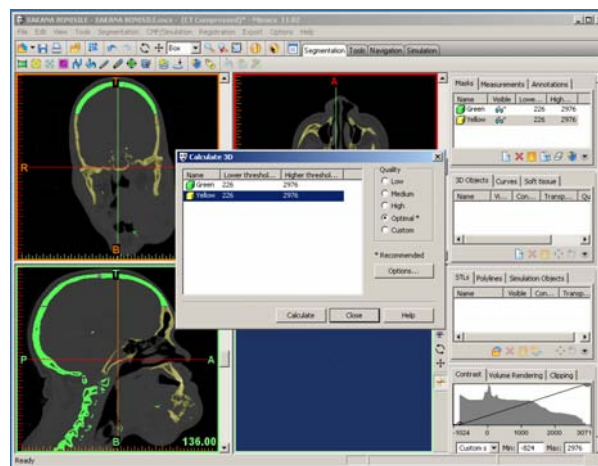


Figure 17: Creating a 3D image of the new mask

There is not a limit to the number of masks and 3D images that can be created, and thus the process of mask editing and iteration can be repeated until the final desired 3D image is obtained (Figure 18).

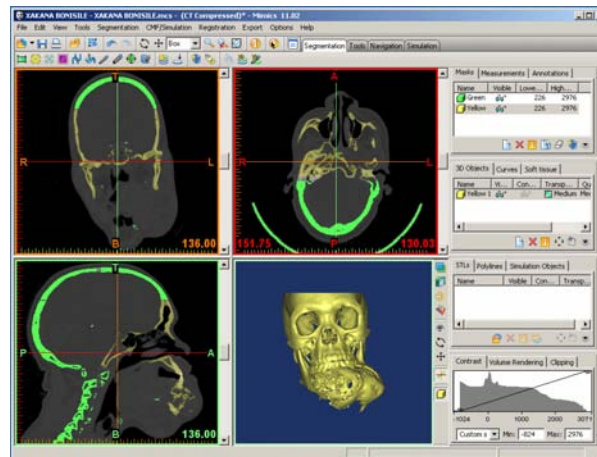


Figure 18: Final 3D image ready to be exported as a STL

- **Exporting the 3D image**

The final 3D image is exported and saved as a STL file by selecting the “Export” toolbar. The STL file can now be imported by Rapid Prototyping software, which is responsible for creating the physical 3D part.

4.2. 3D Printing process steps

- **Importing the STL**

The process starts by importing the STL file that was exported from the medical modelling software. The specific software used to import the STL is the ZPrint software supplied by ZCorporation.

The parts are displayed in three different windows (Figure 19).

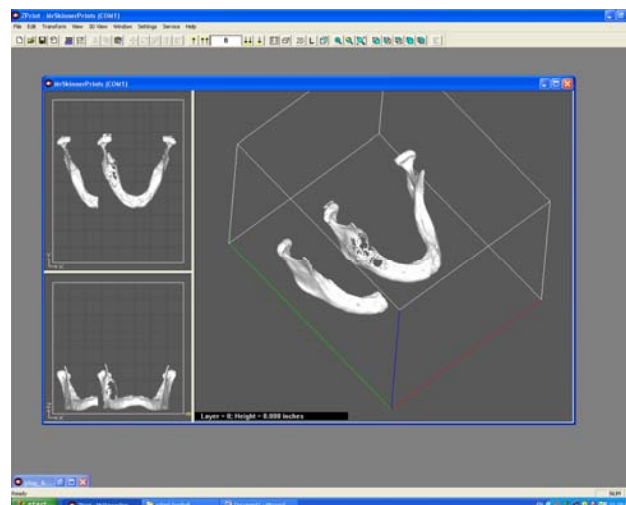


Figure 19: Simulation of the STL model on ZPrint software

The two windows on the left are used for orienting and positioning the parts in the building tray. The large window is used for viewing the parts from different angles.

Before printing starts, the ZPrint software goes through a few set of routines to estimate for example the volume of the parts to be built, the build time, and amount of binder required. Once the full setup is complete and all the routine checks have been performed, building is ready to start.

- **Building the object**
- **Part removal and post-processing**

Once printing has finished, the model is removed from the printer. This is done by slowly raising the build platform and carefully removing the bulk of loose powder surrounding it. Remaining powder is removed with Z Corporation's specialised blower/vacuum cleaner (Figure 20).




Figure 20: Removing the part from the 3D printer

After the part is removed, it is placed in a 70°C oven (Figure 21) for approximately one hour to allow the binder material to harden.



Figure 21: Oven set at 70°C

If some loose powder was intentionally left on or underneath the model to serve as support while the model was in the oven, it can now be removed. If a substantial amount of powder was left as support, the model can be placed in the oven for another hour, as extra precaution to make sure the binding material hardens properly.

- **Epoxy resin infiltration:**

After the part is removed from the 70°C oven, it is dry and needs to be infiltrated. The dry printed model is porous, which allows it to be soaked in or soaked with special infiltrating agents that are absorbed by it.

Once absorbed, the infiltrating agents harden inside the model, giving it extra strength.

To speed up the hardening process, the model can again be placed in the 70°C oven until the epoxy mixture has completely hardened.

- **Wax infiltration:**

Waxing is done with an automated waxer (Figure 22), also developed by ZCorporation.



Figure 22: Automated waxer

The waxer consists of a tray inside a specialized soaking oven containing melted wax. The model is placed on the tray and the tray is lowered into a bucket with melted wax. The model is submerged in the melted wax for a few seconds, giving the wax time to properly infiltrate it. The model is then raised, and removed from the waxing oven. It is put in a cool dry place to allow the wax inside the model to cool and harden.

Wax infiltration takes up much less time than infiltrating the model with the epoxy mixture, but the final model is not as strong as that of the epoxy mixture. Another disadvantage of the wax infiltrated model is that it is sensitive to high temperatures due to the low melting point of wax.

If necessary, the model can be rubbed with sand paper to give it a smoother finish.

The final model (Figure 23) is now ready to be presented to the doctor for medical planning.

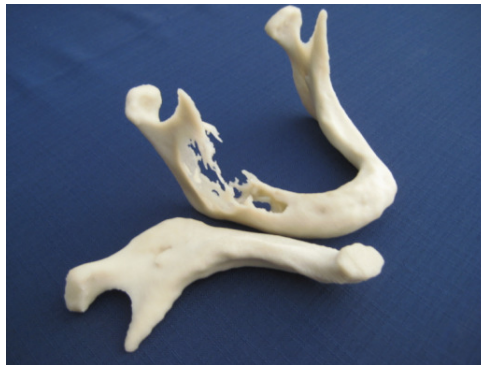

Figure 23: Final model

5. *Suitability of 3D Printing materials for surgical applications*

5.1. Accuracy

Even the finest accuracy (about 0.5mm) obtained from radiographic data such as CT or MRI is fairly crude by engineering standards. This means that the main limitation lies not with the accuracy of 3D Printing (Table 5), but with the modalities used to obtain the raw data.

Reported Accuracy [mm]				Layer thickness [mm]	Surface roughness [μm]	Tensile Strength [MPa]		Elongation at Break				
In-house study zp102 with Zi580 resin				0.076 – 0.254	In-house study	Wohlers Report	In-house study	In-house study				
					10.38 – 12.64 (Ra)	8.6 – 14.8 (zp100)	0.127 (zp100)	0.19%				
									Axis	X	Y	Z
									Max	0.405	0.179	0.189
									Avg	-0.05	-0.05	-0.15
Min	-0.47	-0.36	-0.56									

Table 5: Accuracy and quality of ZCorporation's 3D Printing [15]

Of all medical application areas discussed in this report, procedures involving placement of dental implants require the highest levels of accuracy. Generally dental implants placed in the mandible need to be at least 2mm – 3mm clear of the nerve canal. Thus, if the Nyquist-Shannon sampling theorem is used to determine the largest allowable margin of error, the maximum allowable error would be 1mm.

A case study was conducted to confirm the anatomical accuracy of 3D printed models produced from radiographic data.

A section of a real mandible, with the inferior alveolar nerve and nerve canal still in tact, was scanned using a Cone Beam CT (Figure 24). A 3D printed model was produced of the open section of the mandible, showing the nerve canal.

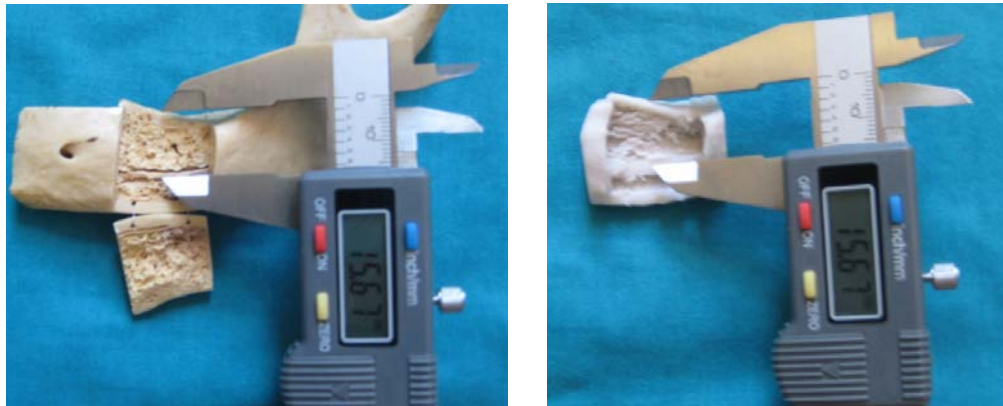

Figure 24: True mandible and 3D printed replica

The depth from the top of the true mandible biting area to the start of the true nerve canal was measured and compared to the depth measured on the 3D printed model (Figure 24).

Accuracy was confirmed to be within specification.

5.2. Mechanical properties (Appendix A)

A case study was conducted to determine how 3D printed parts would respond to the mechanical drilling by surgical tools and the placement of surgical screws. The outcome would determine whether 3D printed parts would be suitable to physically simulate the planned surgical procedure.

For the study, six surgeons were each given four samples of 3D printed parts, 10mm x 10mm x 50mm each, comprising out of various combinations of powders, binders and infiltrating agents (Table 6).

The surgeons were asked to give a yes or no answer as to whether the material could be drilled and screws could be placed without fracture.

The surgeons were also given a visual to analogue scale on which they had to rate the different samples from 0 to 10 according to personal preference to work with.

Results are summarized in Table 6.

Sample name	Material combinations			Total number of sample fractures during mechanical drilling	Total number of sample fractures during placement of screws	Total averaged rating out of 10
	Powder	Binder	Infiltrating agent			
W0	ZP 130	zb58	Wax	0	1	7.2
E0	ZP 130	zb58	Epoxy	0	0	3.5
W1	ZP 131	zb60	Wax	0	1	7.5
E1	ZP 131	Zb60	Epoxy	0	0	5.5

Table 6: Summary of results

Although the surgeons commented that the epoxy infiltrated parts had a more realistic feel of actual bone, the majority felt that the softer, wax infiltrated parts were easier to work with and placed less strain on surgical equipment.

It was concluded that wax infiltrated parts are the material of choice when it comes to the physical simulation of surgical procedures. However, results also showed that wax infiltrated parts have a higher risk of breaking during handling, and are therefore not recommended for parts with a wall thickness of less than 10mm.

5.3. Sterilization

Sterilization tests were performed on epoxy infiltrated 3D printed samples to test the following:

- Can samples be autoclaved?
- Can samples be gas sterilized?
- Are there any deformities of the samples due to sterilization?
- Are there any bacterial growth after sterilization?

The aim was to determine whether these models could serve as intra-operative tools in a sterile environment.

Samples were sent away to a company specializing in bio-loading testing.

Results returned showing that the samples could be successfully autoclaved as well as gas sterilized without any post-development of bacterial growth.

Multiple autoclave cycles (8 in total) also showed that there was no geometrical deformity of 3D printed parts due to autoclaving.

5.4. Conclusion

Results conclude that models produced through 3D Printing:

- Are anatomically accurate.
- Are mechanically suitable for physical simulation of planned surgical procedures.
- Can be sterilized to serve as intra-operative tools in a sterile environment.

However, due to the material composition it is possible that 3D printed models can give off small granules of powder during handling. Thus it is not recommended that these models are handled directly by the surgeon during surgery, or that they come in direct contact with surgical tools or implants whilst the surgery is taking place. If for example they are to come into direct contact with surgical tools, or to be used for the pre-bending of reconstruction plates, or fitment and positioning of implants, it is recommended that this is done prior to surgery. These tools, plates, or implants should then be thoroughly washed before being used in theatre.

6. *Application areas: A selection of case studies*

Reconstructive surgery refers to all the disciplines of surgery involving the treatment and or reconstruction of an injured, mutilated, or deformed part of the body by means of surgical intervention.

Due to the wide scope of complications, there are groups of focused specialities responsible for specific disciplines of surgical procedures. Many of these overlap with one another, but for the purpose of this study they have been broadly divided into the following categories:

- Orthopaedic surgery
- Neurosurgery
- Oral & Maxillofacial surgery
- Plastic & Reconstructive surgery
- Periodontics

See Appendix B for an example of a form used to gather case study information.

6.1. *Orthopaedic surgery*

Orthopaedic surgery is a field of surgery that focuses on the treatment of conditions which involve the musculoskeletal system. These conditions involve musculoskeletal trauma, sports injuries, degenerative diseases, infections, tumours, and congenital disorders.

A few examples are:

- Hand surgery
- Shoulder and elbow surgery
- Joint replacement surgery
- Foot and ankle surgery
- Spine surgery
- Orthopaedic trauma

6.1.1. **Acetabulum pelvic fracture**

Condition

The patient was a young lady who had been involved in a car accident which resulted in a pelvic fracture (Figure 25).

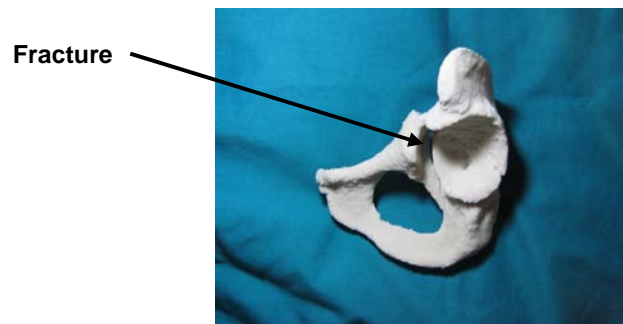


Figure 25: 3D Printed model of fractured pelvis

The main concern was that there could be multiple fractures which were not clearly visible on the pre-operative X-rays.

Aim of surgery

The aim of the surgery was to correctly reposition and fixate the fractured pelvis in its natural position to ensure that it grew back to its normal state.

Use of model

Pre-operatively the model was used to:

- Visualize the defect and plan the surgical procedure (Figure 26).

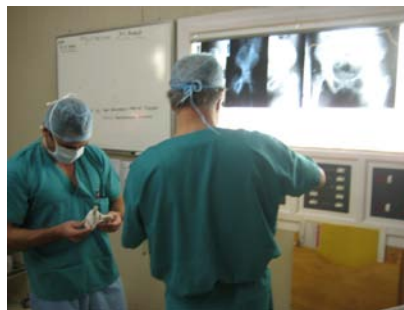

Figure 26: Surgeons planning the surgical procedure

- Determine whether the pelvis had a singular or multiple fractures.
- Determine the point of surgical entry.
- Determine whether only an anterior or both posterior and anterior surgical entries would be required.

During surgery the model was used to:

- Serve as means of communication between the surgical team members (Figure 27).

- Orientate the surgeons in their surgical proceedings relative to the patient's anatomy (Figure 27).

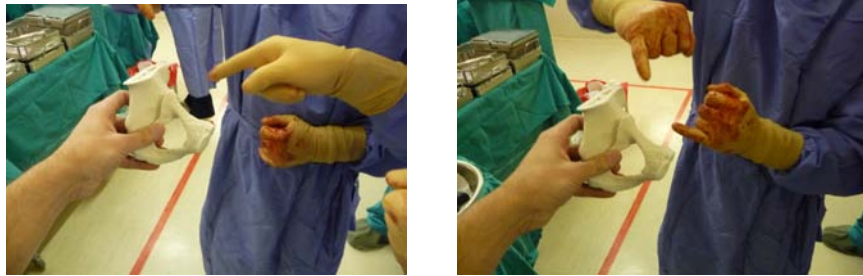


Figure 27: Model being used as an aid of communication and orientation

- Assist in bending the reconstruction plates holding the pelvic bones in their natural position.

Results

The surgical procedure turned out to be a fairly simple and relatively short. It required only an anterior point of entry. The fracture was easily aligned and restored to its correct anatomical position. The reconstruction plates were securely fixated.

Surgeon's opinion

The surgeons were pleasantly surprised by the smooth flow of the procedure as well as the little amount of fatigue after the procedure. They agreed that the model had been of great assistance during the surgery as means of communication between each other as well as an orienting aid for their proceedings relative to the patient's anatomy.

They said that the model helped them to re-align and restore the fracture with a simple "jerk" of the patient's leg, instead of a difficult and slow repositioning procedure.

Also, the model indicated to them, pre-operatively, that only an anterior surgical entry would be required. They said that without the help of the model they would also have done a posterior entry to determine whether there were multiple fractures. This would have resulted in much longer surgery time and additional loss of blood. The surgeons estimated that apart from reduced theatre time, at least two units of blood, priced at roughly R800 per unit, were saved as a direct result of the use of the model.

Conclusion

Physical 3D models produced through 3D Printing can be successfully applied pre-operatively to:

- Determine the amount, position and extent of fractures. The doctors would be unable to do so with only contemporary 2D images.
- Plan the surgical procedure and surgical point of entry.

- Estimate the amount of reserve blood required to compensate for blood loss.

These models can also be successfully applied during the surgical procedure to:

- Serve as an aid of communication between surgical team members.
- Serve as an aid of orientation relative to patient anatomy.
- Assist in bending reconstruction plates.

The application of the 3DP model resulted in a definite reduction of surgery time, reduced fatigue of the surgeons, and reduced blood loss.

6.1.2. Hip revision of complex acetabulum fracture

Condition

The patient was a late aged man who had an accident which resulted in a severely fractured pelvis. The patient already underwent two surgeries which aimed to stabilize the bone of the acetabulum cup. However, the acetabulum was still completely deformed (Figure 28), with the femur dislocated.




Figure 28: 3D Printed model of fractured acetabulum

Aim of surgery

The aim of the surgery was to replace the joint locating surfaces of the acetabulum and the femur, and to reposition the femur so as to restore the joint's range of motion. The main concern was that not enough stable bone was available for performing a complete hip replacement procedure.

Due to the complicated fracture of the acetabulum and the uncertainty as to how much bone was available in the acetabulum cup for placing an acetabular implant component, it was posing to be a long and challenging surgical procedure. The estimate time of surgery was three and a half hours.

Use of model

Pre-operatively the model was used to:

- Determine the amount of bone available for a hip replacement procedure.
- Estimate the maximum depth at which the implant could be placed to ensure a secure placement without penetrating through the acetabulum wall.
- Plan and discussing the surgical procedure among the surgical team members.

During surgery the model was used to:

- Serve as a communication device between the surgical team members during the surgical procedure (Figure 29).

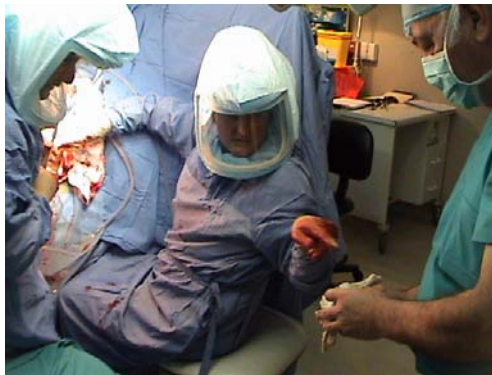

Figure 29: Three surgeons using the 3D printed model to discuss the surgical procedure

- Orientate the surgeons with regards to their surgical proceedings relative to the patient's anatomy (Figure 30).

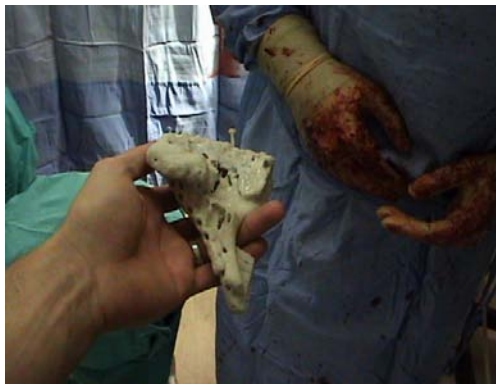

Figure 30: 3D Printed model used for orienting one of the surgeons relative to the patient's anatomy

- Estimate the angle at which the implant had to be placed (Figure 31).

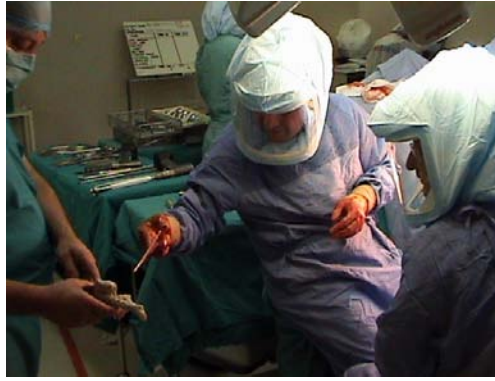

Figure 31: Using the 3D printed model to discuss implant placement

- Select the correct size of implant required for resurfacing the acetabulum.

Results

What posed to be a long, challenging, and tiring surgical procedure turned out to be a fairly simple and relatively short procedure. The surgery was completed within two and a half hours. The implants were securely fixated to the joint surfaces and the new femur head was positioned into the resurfaced acetabulum cup.

Surgeon's opinion

Three surgeons were assisting in the procedure. They remarked that they were pleasantly surprised by the smooth flow of the procedure as well as the little amount of fatigue after the procedure. They all agreed that the model served as a very helpful tool of communication between each other and helped them to orientate themselves during their proceedings relative to the patient's anatomy.

Conclusion

Physical 3D models produced through 3D Printing can be successfully applied pre-operatively to:

- Plan surgical procedures.
- Plan implant placement.
- Determine the amount of bone available for joint replacement.

They can also be successfully applied during the surgical procedure to:

- Select the correct size of implant required for resurfacing the acetabulum cup.
- Help decide on the positioning and placement of implants.
- Serve as a means of communication between surgical team members.
- Serve as an aid for orienting surgical personnel relative to patient anatomy.

It was proved that the 3DP model result in a definite reduction of surgery time, roughly 1 hour (30% of total surgery time) in this particular case. Also it helped reduce mental strain and fatigue of the surgeons performing the surgical procedure.

6.1.3. Elbow arthritis due to an old injury

Condition

The patient was a young man who had an elbow fracture as a young boy. He'd already undergone surgery as a youngster to restore the fracture, but over the years developed arthritis (rough irregularities) on the joint surfaces of the ulna and radius (Figure 32) which started causing him severe pain and restricted range of motion.

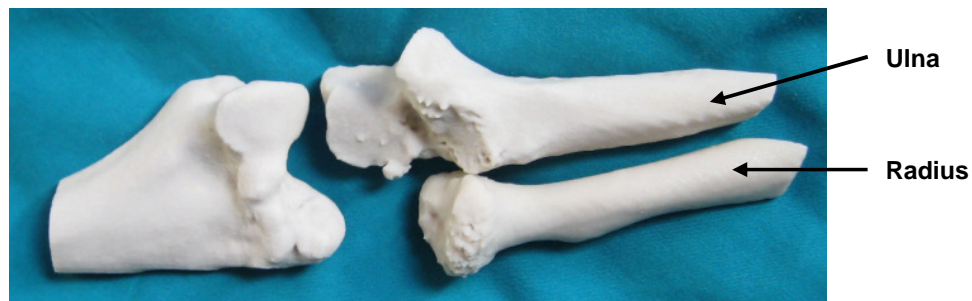

Figure 32: 3D Printed model of elbow joint

Aim of surgery

The aim of the surgery was to cut away the arthritis bone obstructing his range of motion and causing him the pain. The challenge was to decide how much bone at exactly which areas to cut away to ensure that the procedure leads to improvement rather than worsening of the condition.

Use of model

Pre-operatively the model was used to:

- Visualize the defect.
- Simulate the motion of the elbow to determine the problem areas (Figure 33).

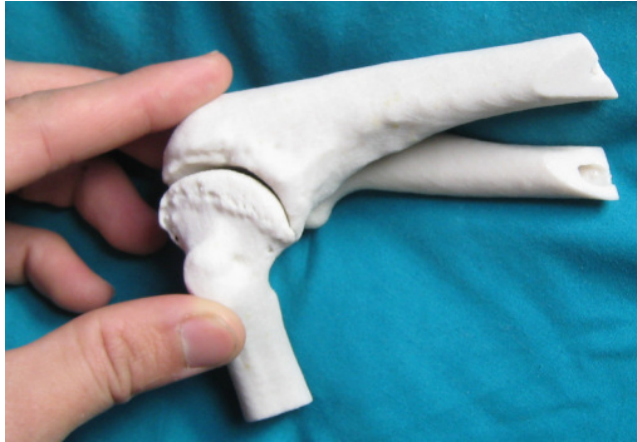

Figure 33: Simulating elbow motion

- Plan the areas of resection.
- Explain the surgical procedure to the patient and obtain patient consent.

During surgery the model was used to:

- Compare and confirm the planned area of resection on the model and that of the patient's anatomy.

Results

The surgery was executed smoothly without any problems.

Surgeon's opinion

The surgeon was able to perform the excision with more confidence and better accuracy thanks to the 3DP model.

Conclusion

Physical 3D models produced through 3D Printing can be successfully applied pre-operatively to:

- Analyze defects.
- Simulate range of motion and determine obstructions.
- Plan the areas of resection.
- Explain the surgical procedure to the patient and obtain patient consent.

They can also be successfully applied during the surgical procedure to:

- Verify the resections made.

The 3DP resulted in higher levels of confidence of the surgeon before and during execution of surgery. As a result, it enabled the surgery to be performed faster and more accurately.

6.1.4. Echinococcosis cyst spine (Appendix B)

Condition

The patient was a middle aged man who was suffering from a rare condition caused by what is termed an “Echinococcosis Cyst”. The cyst in this particular case was situated in the spine of the patient and caused severe bone deterioration. The patient had already undergone a prior surgery which aimed to remove the cyst and reinforce the spinal cord, but had been unsuccessful.

Aim of surgery

The aim of the surgery was to remove as much as possible of the cyst and to reinforce the spine with a “cage” implant.

The surgery was performed at an academic institution, so the secondary aim of the surgery was to educate upcoming orthopaedic surgeons on spinal surgery.

Use of model

Pre-operatively the model was used to:

- Visualize the defect and determine how deep the cyst had penetrated into the spine (Figure 34).

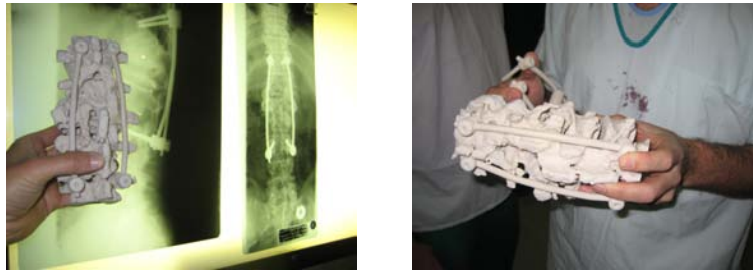

Figure 34: 3D Printed model being used for pre-operative visualization and planning

- Determine the correct point of surgical entry.

During surgery the model was used for:

- Orientate the surgical personnel relative to patient anatomy (Figure 35).

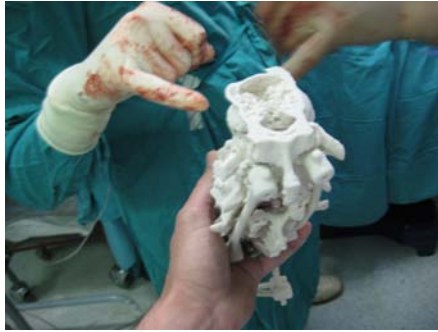

Figure 35: Model being used as an orienting aid and means of communication

- Explain the surgical proceedings to the surgeons in training.
- Select the correct size “cage” implant for reinforcing the spine (Figure 36).

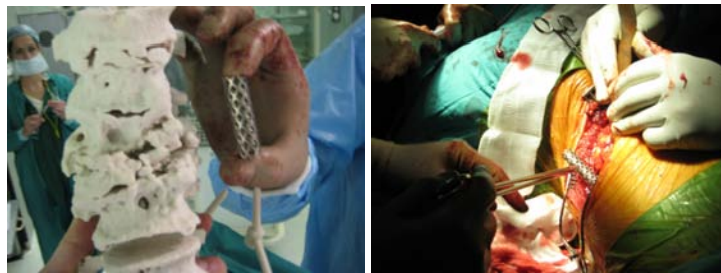

Figure 36: Selecting the implant and inserting it into the patient's spine

Results

The cyst was successfully removed and the cage was securely fixated in the spine.

Surgeon's opinion (Appendix B)

The surgeons all agreed that the physical 3D model served as an accurate means for selecting the correct size of “cage” implant required. This helped save a lot of surgery time since they did not have to place and remove various sizes of “cage” implants in order to obtain the best fit. The head surgeon estimated a total save in surgery time of one hour. The head surgeon also said that the physical 3D model served as a very helpful means of explaining the surgical procedure to the younger surgeons in training. One of the anaesthetic personnel remarked that it was the first time in her career that she actually knew and understood what was going on during the surgical proceedings due to the help of the 3D model and the ease with which it helped explain the surgical procedure.

Conclusion

Physical 3D models produced through 3D Printing can be successfully applied pre-operatively to:

- Determine the extent of bone penetration of cysts.
- Plan the point of entry of the surgical procedure.

They can also be successfully applied during the surgical procedure to:

- Select the correct size of implant required.
- Improve surgical accuracy.
- Serve as a means of communication between surgical team members.
- Serve as means of education to young surgical personnel.
- Serve as a means of orientation relative to patient anatomy.

An estimate of one hour of surgery time was saved implying a total reduction of roughly 30% of total skin to skin surgery time ("skin to skin" refers to the start of incision to closure of the incision).

6.1.5. Patient specific implant design

6.1.5.1. *Custom hip replacement after excision of pelvic tumour*

Condition

The patient was a late aged women suffering from a pelvic tumour causing the degeneration of bone in and around the area of her right acetabulum (Figure 37).

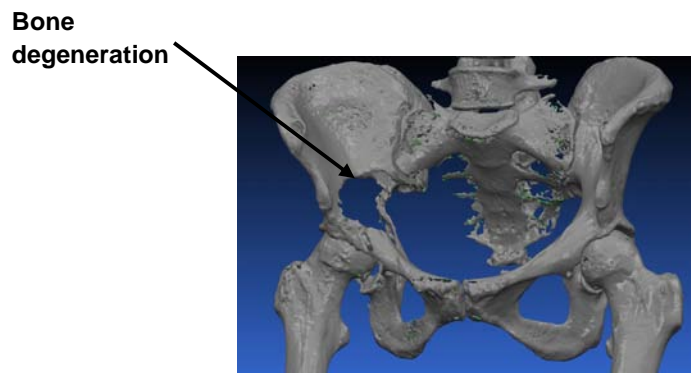


Figure 37: Virtual 3D of pelvis

Aim of surgery

The aim of the surgery was to remove the tumour by means of surgery, and to replace the missing bone with patient specific implants in order to prevent amputation of her right leg.

Use of model

The model was used to:

- Demonstrate the extent of the bone loss due to tumour (Figure 38).

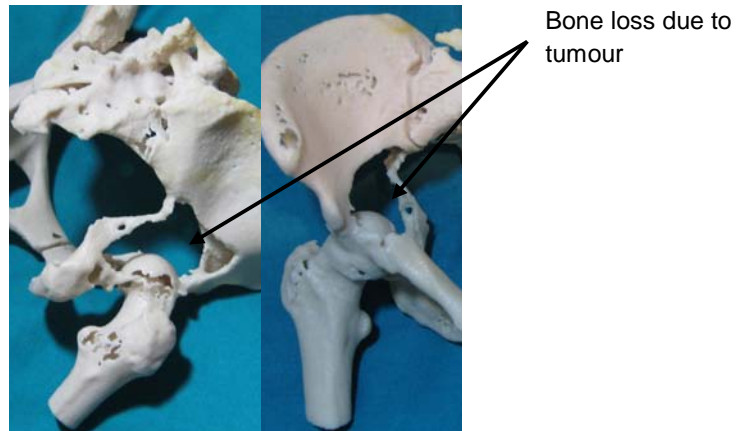


Figure 38: Close-up view of defect

- Determine the full scope of tumour infected bone that needed to be resected.
- Affirm the design of the patient specific-made implant (Figures 39 and 40).

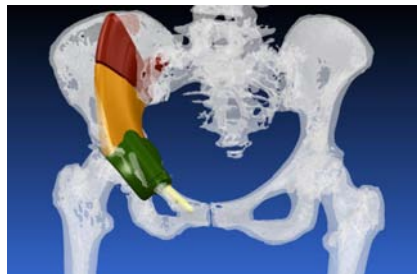

Figure 39: Implant design



Figure 40: Patient specific implants

Results

The implant was successfully placed (Figure 41), but unfortunately the cancer had also spread to various other parts of the body and the patient passed away a few weeks later.

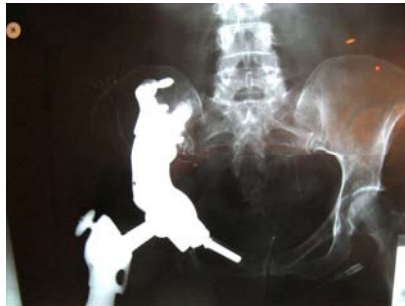

Figure 41: Post-operative X-rays showing the final implant placement

Surgeon's opinion

The surgeon and his team of engineers were very impressed with the texture and the amount of detail of the 3D model, and have started using them on a regular basis.

6.1.5.2. Custom hip replacement after excision of infected bone

The patient had an infection of the proximal femur that had spread into his acetabulum.

Aim of surgery

The aim of the surgery was to reconstruct his acetabulum and proximal femur with the help of a patient specific acetabulum implant (Figure 42).

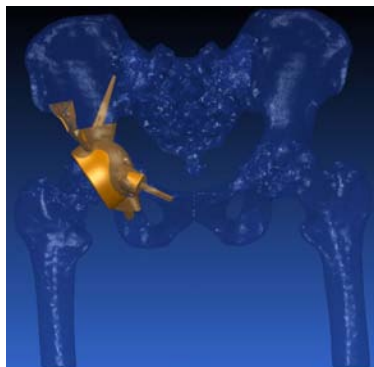


Figure 42: Virtual model of pelvis with patient specific implant

Use of model

- Demonstrate the defect and the extent of the bone loss.

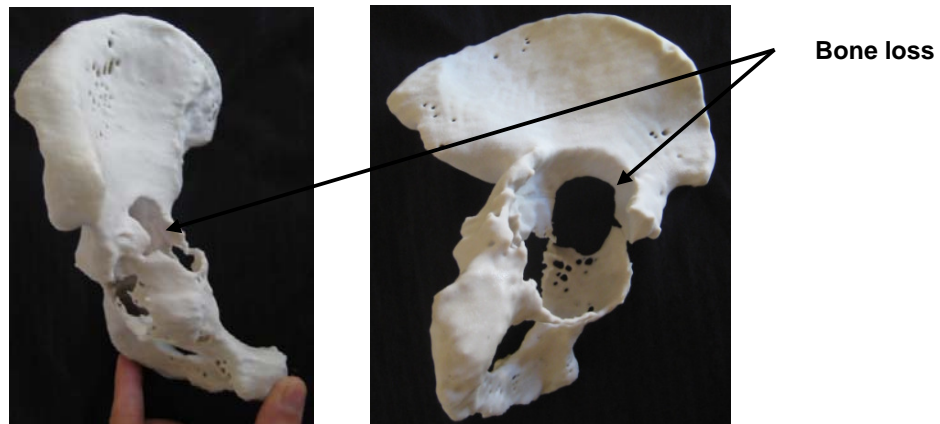


Figure 43: Anterior and side views of 3D printed model

- Plan the surgical procedure.
- Affirm the design (Figure 44) and fitment of the patient specific implant.




Figure 44: Virtual design and positioning of patient specific implant

Results

The surgery was a success. Post-operative X-rays indicated a secure placement of the implants (Figure 45).

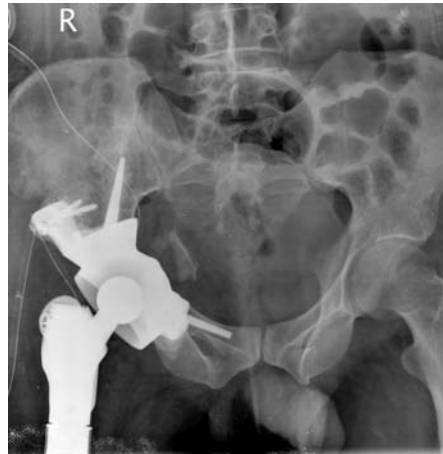

Figure 45: Post-operative X-ray showing implant placement

6.1.5.3. **Conclusion: Case Studies 1 and 2**

Physical 3D models produced through 3D Printing can be successfully applied pre-operatively to:

- Assess the extent of bone loss due to tumour or infection.
- Assist in the design and fitment of patient specific implants.

They can also be successfully applied during the surgical procedure to:

- Guide and orientate the surgical team during removal of infected tissue and or placement of patient specific implants.

As the use of patient specific solutions continue to increase, so will the use of physical 3D models such as those produced by 3D Printing.

6.2. Neurosurgery

Neurosurgery is a field of surgery that focus on the treatment and surgical intervention of conditions which involve the central and peripheral nervous systems (Figure 46) and spinal diseases.

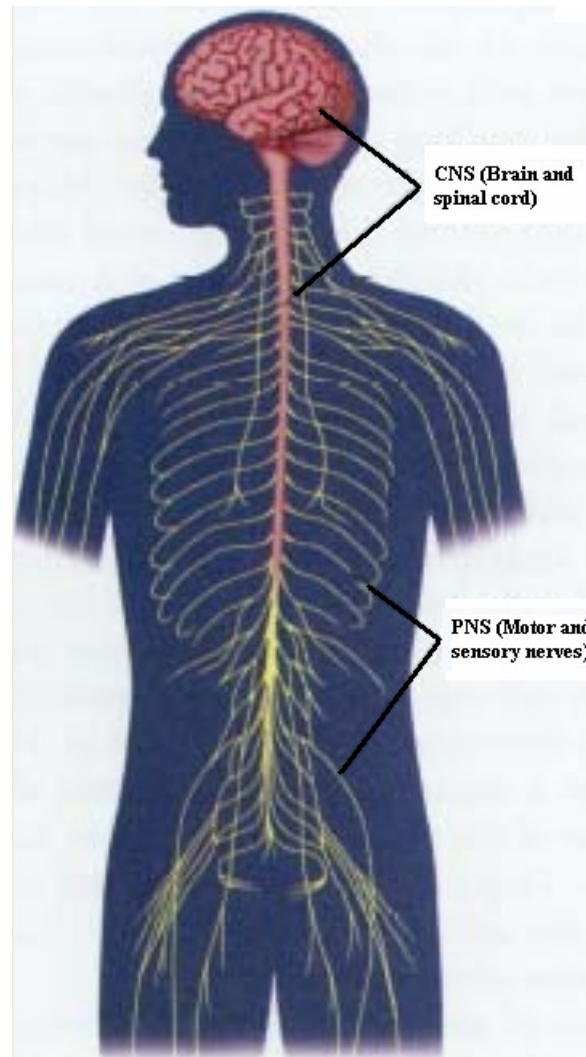


Figure 46: Central and peripheral nervous system [17]

These conditions include primarily brain, spinal cord, vertebral column and peripheral nerve disorders.

A few examples are:

- Head trauma (brain hemorrhages, skull fractures, etc.)
- Spinal cord trauma
- Traumatic injuries of peripheral nerves
- Brain tumours

- Infections and infestations
- Tumours of the spine, spinal cord and peripheral nerves
- Cerebral aneurysms
- Strokes
- Etc.

6.2.1. Cranioplasty after trauma

6.2.1.1. Cranioplasty of a small cranial defect

Condition

The patient was a boy who had been involved in an accident as a young child. The event resulted in a small cranial defect, about 35mm in diameter, which resulted in a concave shaped area on his forehead (Figure 47). Having been mocked at school, the boy was eager to undergo cranioplasty surgery to reconstruct the defect and restore the aesthetical appearance of his forehead.

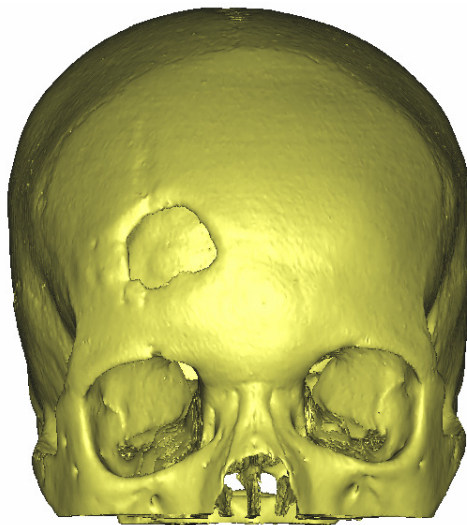


Figure 47: 3D Images of cranium with defect

Aim of surgery

The aim of the surgery was to insert a patient specific implant to close the defect and restore the forehead's aesthetical appearance.

Use of model

The model was used pre-operatively to:

- Determine the exact size and shape of the defect.
- Assist in the design and fitment of a patient specific implant.

During surgery the model was used to:

- Orientate the surgeon to position the implant (Figure 48 and 49).

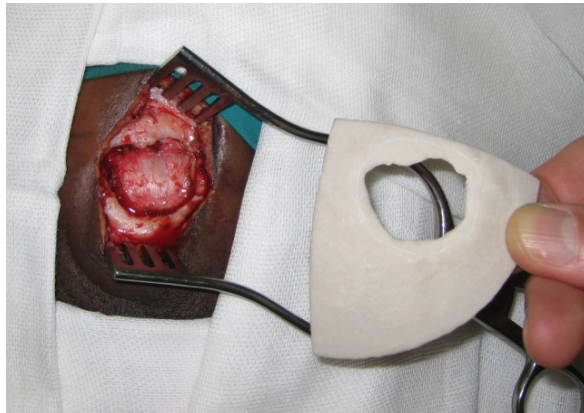


Figure 48: Orientating the 3DP relative to the defect of the patient

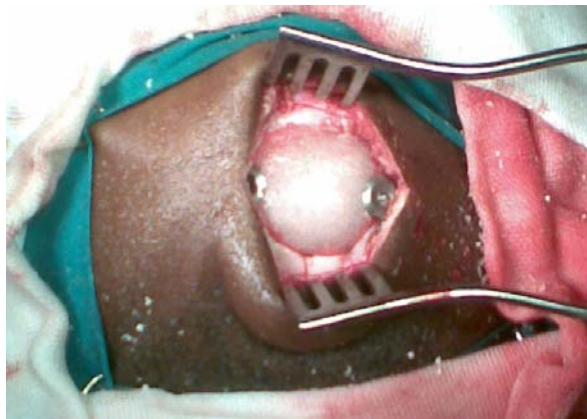


Figure 49: Patient specific implant fixated into defect

Results

Surgery was short and successful. The implant had a perfect fit.

Surgeon's opinion

The surgeon remarked that the boy came for a post-operative check-up with a smile on his face.

6.2.1.2. Cranioplasty of a large cranial defect

Condition

The patient was a middle aged man with a very large cranial defect on the left half of his skull (Figure 50).

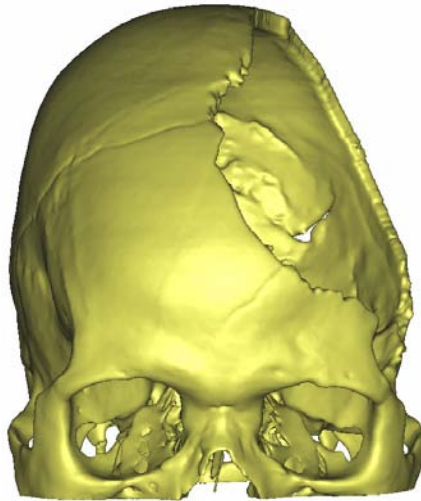


Figure 50: Cranium with trauma defect

The defect was due to a severe assault which fractured the bone of his skull to such an extent that it could not be reconstructed. This left his brain very vulnerable to a knock on the head.

Aim of surgery

The aim of the surgery was to close the defect in order to protect the brain, and to restore the natural geometry of the cranium.

Use of model

Manufacturing costs were reduced by about R 5 000 by making only the rim of the defect (Figure 51) in stead of the full cranium model.

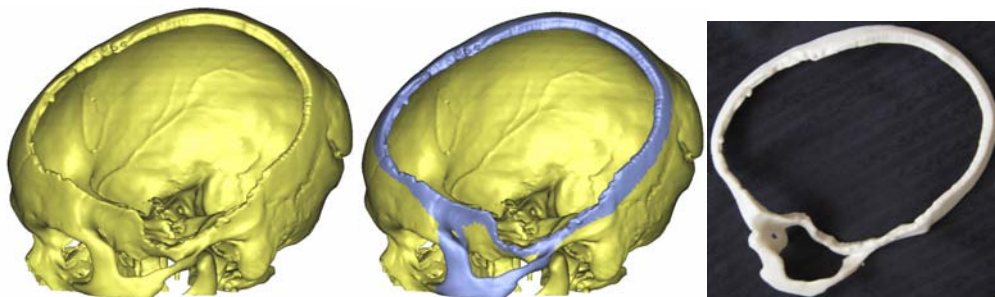


Figure 51: Virtual and physical 3D models of defect

The model was used pre-operatively to:

- Determine the exact size and shape of the defect.
- Assist in the design and fitment of the patient specific implant (Figure 52).

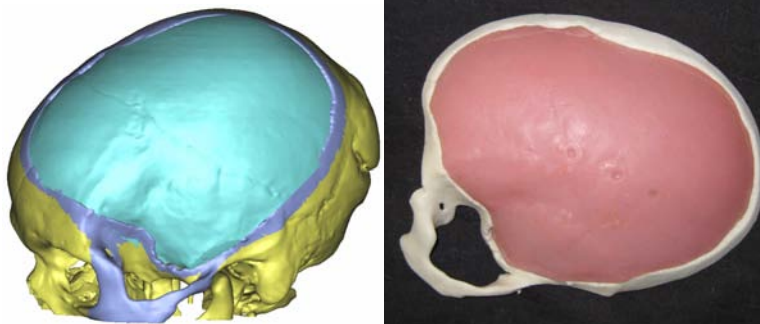


Figure 52: Implant design and fitment

During surgery the model was used to:

- Orientate the surgeon in placement of the implant (Figure 53).

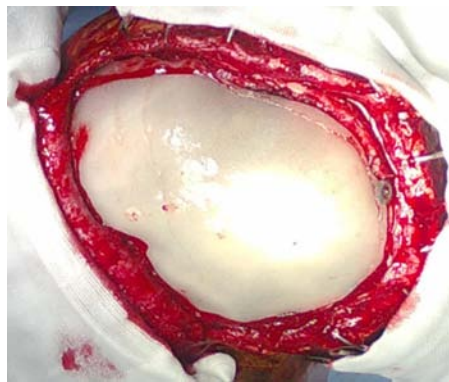


Figure 53: Implant placed in defect with a perfect fit

Results

The implant was a perfect fit and surgery was a huge success.

6.2.1.3. Conclusion: Case Studies 1 and 2

Physical 3D models produced through 3D Printing can be successfully applied pre-operatively to:

- Determine the size and shape of cranial defects.
- Assist in the design and fitment of patient specific implants.

They can also be successfully applied during the surgical procedure to:

- Guide and orientate the surgical team during placement of patient specific implants.

The case studies have shown that 3D printed models help to remarkably simplify cranioplasty procedures and improve their aesthetical outcomes.

6.2.2. Revision surgery cranioplasty

Condition

The patient was a young man who had been involved in a motorcycle accident. The event resulted in a very large cranial defect of his skull which had been closed during a previous surgery using Titanium mesh along with a porous polyethylene material (Figure 54).

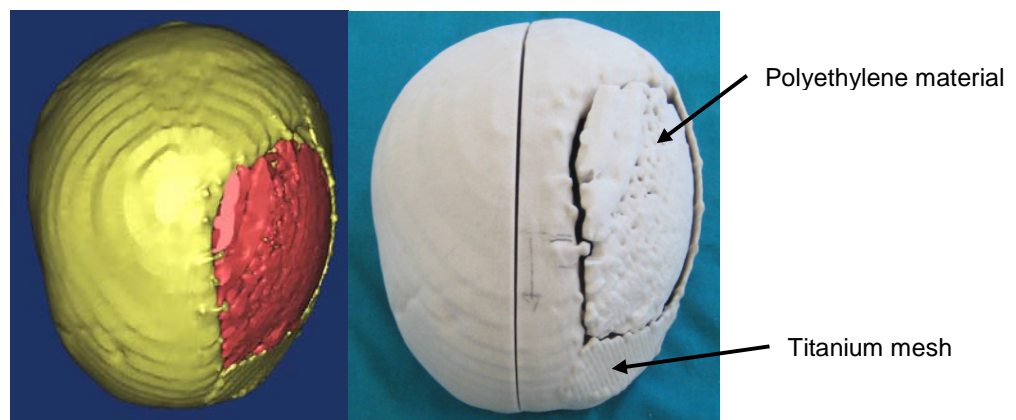


Figure 54: Virtual and 3DP models of defect and porous material

The patient however was not satisfied with the aesthetical results of the first surgery and wanted to undergo a cosmetic cranioplasty to restore the natural geometrical shape of his skull.

Aim of surgery

The aim of the surgery was to insert a patient specific implant on top of the already present Titanium mesh and porous polyethylene implants (Figure 55). The reason for not first removing the already present implants was because the patient suffered from diabetes, and the surgeon wanted to keep the time and extent of surgery to a minimum to avoid possible infection.

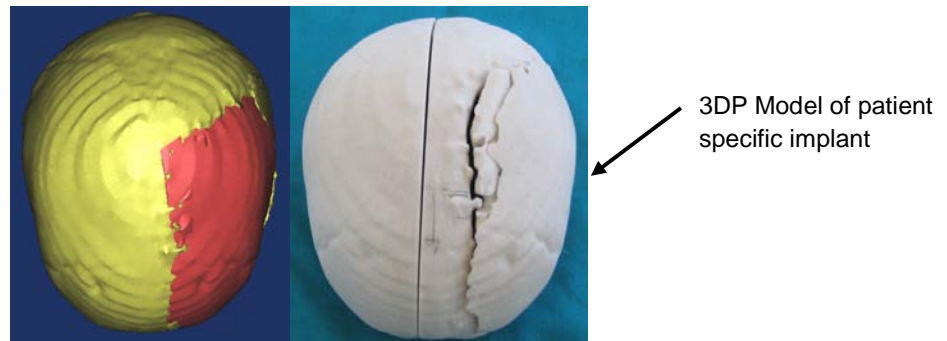


Figure 55: Virtual and physical 3D models of defect and patient specific implant prototype

Use of model

The 3DP cranium model was grown in two halves which reduced the model costs by about R 2 000.

The model was used pre-operatively to:

- Determine the exact size and shape of the defect.
- Decide whether or not the already placed implants would first be removed or be left in tact.
- Explain the surgical procedure to the patient and obtain patient consent.
- Assist in the design and fitment of the patient specific implant.

During surgery the model was used to:

- Orientate the surgical team during the surgical procedure and placement of the patient specific implant.

Results

Surgery was a huge success. The already present implants were left in place. The patient specific implant was placed on top of the already present implants and had a perfect fit (Figure 56).

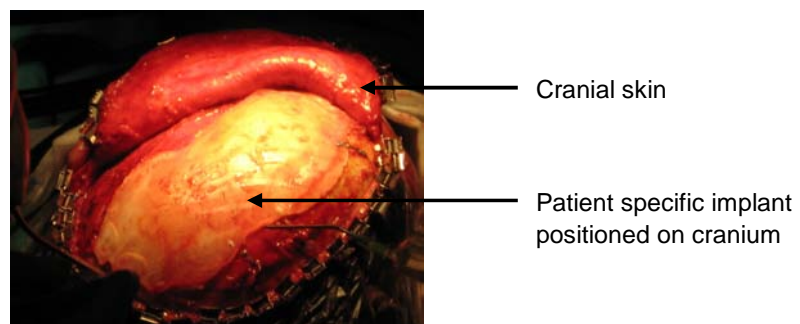


Figure 56: Patient specific implant positioned on cranium

After the surgery, the patient was very happy with the new aesthetical appearance of his head.

Surgeon's opinion

The surgeons were very impressed with the accuracy of the model, the implant, and the aesthetical outcome that resulted from it. Being one of the heads of a medical academic institution, the head surgeon has kept the model and is using it to educate upcoming neurosurgeons on the use of 3D printed models and patient specific technology during cranioplasty surgery.

Conclusion

Physical 3D models produced through 3D Printing can be successfully applied pre-operatively to:

- Determine the size and shape of cranial defects.
- Visualize implants placed during previous surgeries.
- Explain the surgical procedure to the patient and obtain patient consent.
- Assist in the design and fitment of patient specific implants.

They can also be successfully applied during the surgical procedure to:

- Guide and orientate the surgical team during placement of patient specific implants.

Post-operatively:

- 3D printed models can serve as very helpful tools for educating surgical personnel in training.

The case studies have shown that 3D printed models can be used during revision cranioplasty surgeries to improve aesthetical appearance. They can help to simplify surgical procedures and increase the level of accuracy. As a result, they can help to increase levels of self esteem and quality of life of patients by reducing psychological complications caused by aesthetical defects.

6.2.3. Tumour excision and cranioplasty

6.2.3.1. Excision of a meningioma followed by cranioplasty

Condition

The patient was a young lady with a cranial meningioma in the top left part of her forehead (Figure 57). A meningioma is a non-aggressive slow growing tumour, causing uncontrolled growth of the cranial bone.

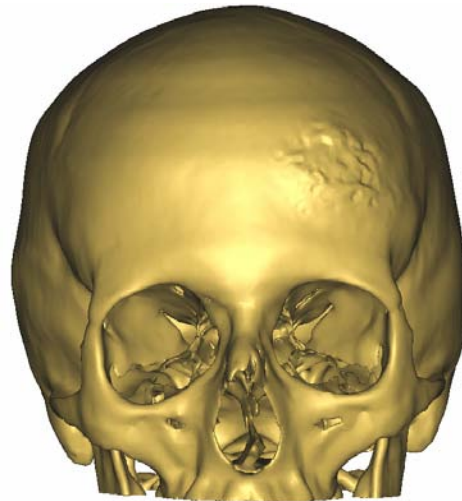

Figure 57: Virtual 3D of cranium with meningioma

Aim of surgery

The aim of the surgery was to remove the tumour infected bone by means of surgery, and to replace the missing bone with a patient specific implant.

Use of model

The model was used pre-operatively to:

- Plan the area of resection (Figure 58).

Planned area of resection



Figure 58: 3D printed model with planned area of resection

- Assist in the design of a patient specific cutting guide (Figure 59).

**Cutting guide used
to mark off the area
of resection**

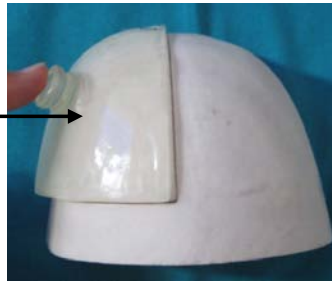


Figure 59: Fitting the patient specific cutting guide

- Assist in the design of a patient specific implant.
- Explain the surgical procedure to the patient and obtain patient consent.

During surgery the model was used to:

- Orientate surgical team during positioning of the cutting guide and excision of the tumour (Figure 60).

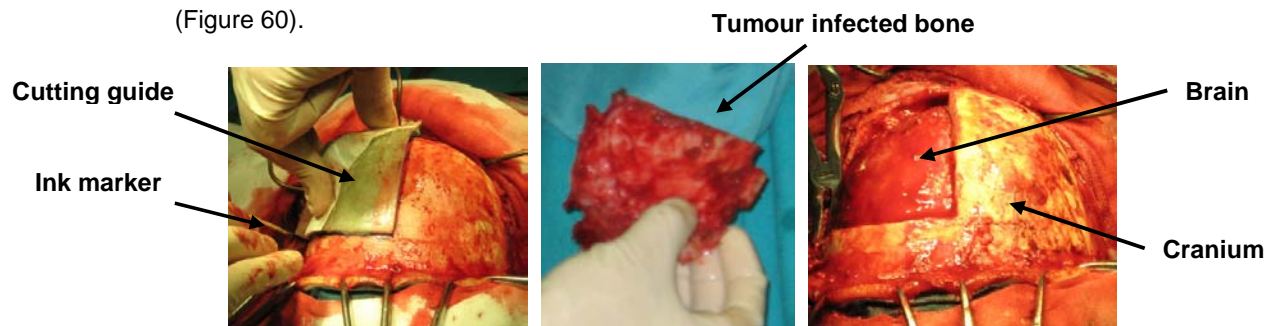


Figure 60: Using cutting guide to mark off and resect the tumour infected bone

Results

Surgery was a huge success. Both the patient specific cutting guide and the patient specific implant (Figure 61) were perfect fits.

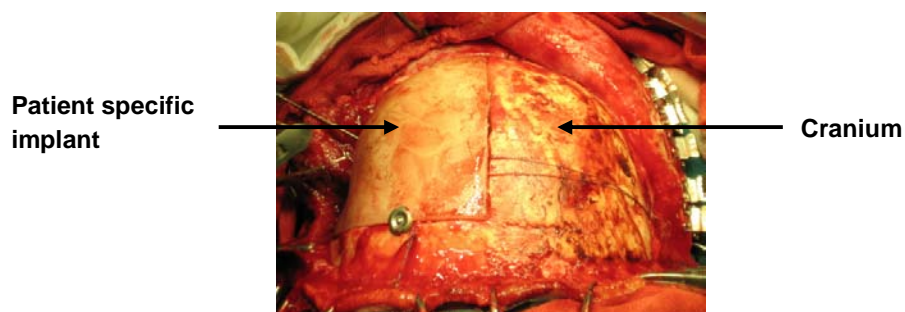


Figure 61: Patient specific implant positioned in defect with a perfect fit

The patient recovered quickly and was very happy with the aesthetical outcome of the surgery.

Surgeon's opinion

The surgeon and his team remarked that the model, along with the patient specific tooling, enabled them to achieve a much higher level of surgical accuracy and, although they did not quantify, that it lead to a remarkable reduction in surgical time. After having a follow-up with the patient, they also said that it resulted in a very satisfied patient with no psychological trauma, the opposite of what it would be if they used conventional procedures.

6.2.3.2. Debulking of a large meningioma followed by cranioplasty

Condition

The patient was a middle aged lady suffering from a very advanced stage of cranial meningioma (Figures 62 and 63).

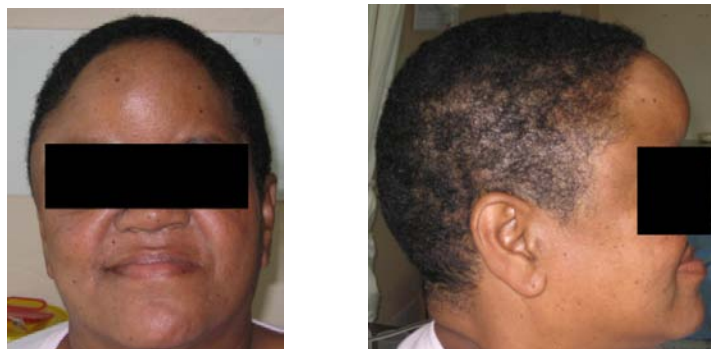

Figure 62: Pre-operative photos of the patient

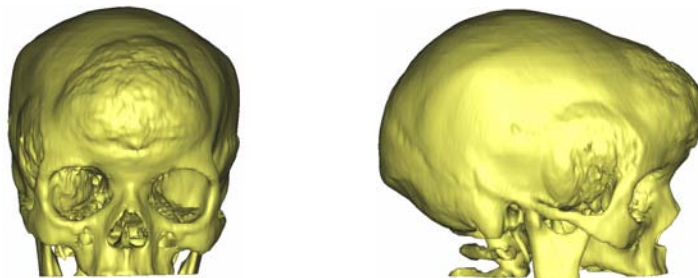


Figure 63: Virtual 3D views of cranium with meningioma

The patient neglected earlier treatment. As a result, the tumour had advanced greatly in size and had started to spread to various other parts of the cranium. It also started infiltrating part of the brain.

Aim of surgery

Due to the extensive penetration of the tumour, it would not be possible to remove the whole tumour without exposing the patient to life-threatening surgery. The aim of the surgery was thus only to debulk the massive amount of tumour infected bone and to replace the missing bone with a patient specific implant.

Use of model

The model was used pre-operatively to:

- Plan the area of resection and assist in the design of a patient specific cutting guide (Figure 64).

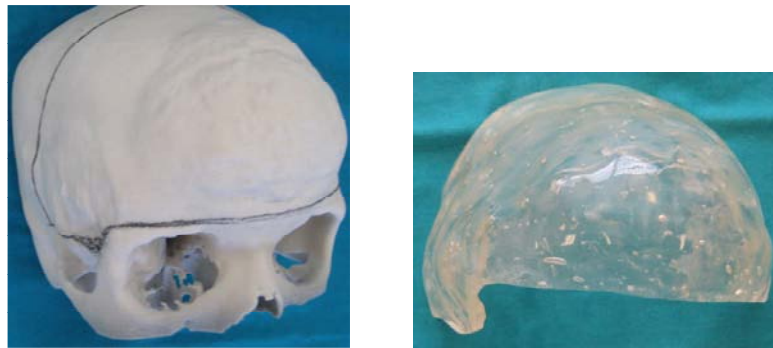


Figure 64: 3DP Model and patient specific cutting guide

- Assist in the design and fitment of a patient specific implant.
- Explain the surgical procedure to the patient and obtain patient consent.

During surgery the model was used to:

- Orientate the surgeon and the surgical team in positioning of the cutting guide, excision of the tumour, and placing of the patient specific implant (Figures 65 and 66)

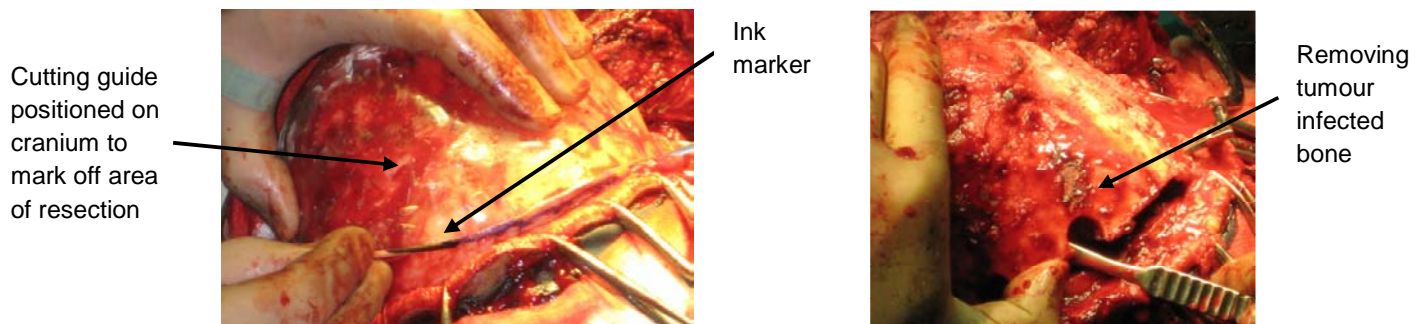


Figure 65: Marking off the planned area of resection and removing the tumour infected bone

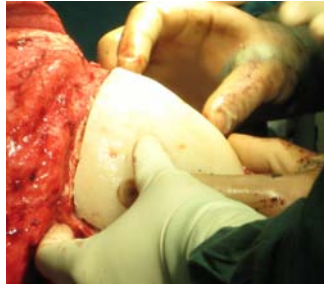

Figure 66: Positioning the patient specific implant

Results

Surgery took about 13 hours, but turned out to be a huge success. The patient recovered quickly and the surgical team were very happy with the immediate post-operative aesthetical results. A few months post operative the implant had shifted from its original position, leaving the patient with a slight deformity of her forehead. The surgeon claimed responsibility and said that it was due to improper fixation from his side. He said that the mistake could easily be corrected with minor surgery.

Surgeon's opinion

The surgeon said that the model was a very helpful tool in guiding them to remove the complexly situated tumour. The surgeon also said that they were previously not capable of achieving the same levels of reconstructive accuracy as they were with the help of the model and the patient specific solutions.

6.2.3.3. Conclusion: Case Studies 1 and 2

Physical 3D models produced through 3D Printing can be successfully applied pre-operatively to:

- Plan the area of resection of bone of cranial bone tumours.
- Assist in the design and fitment of patient specific cutting guides.
- Assist in the design and fitment of patient specific cranial implants.
- Explain the surgical procedure to the patient and obtain patient consent.

They can also be successfully applied during the surgical procedure to:

- Guide and orientate the surgical team during the resection of bone tumours and placement of patient specific cranial implants.

Ultimately 3D printed models help surgeons achieve higher levels of surgical accuracy, reduce surgical time, improve aesthetical results and reduce psychological trauma of the patient.

6.3. Oral & Maxillofacial surgery

Oral and maxillofacial surgery is a field of surgery that focus on the treatment of a wide spectrum of conditions which involve diseases, injuries and defects in the head, neck, face, jaws and the hard and soft tissues of the oral and maxillofacial region.

A few examples are:

- Dentoalveolar surgery: Surgery involving the removal if impacted teeth, difficult tooth extractions, extractions on medically compromised patients, bone grafting or preprosthetic surgery to provide better anatomy for the placement of implants, dentures, or other dental prostheses.
- Diagnosis and treatment of cysts and tumours.
- Diagnosis and treatment of congenital malformations of the craniofacial area .
- Diagnosis and treatment of temporomandibular joint (TMJ) disorders.
- Diagnosis and treatment of incorrect bite.
- Surgical correction of facial asymmetry.
- Diagnosis and treatment of soft and hard tissue trauma of the oral and maxillofacial region (jaw fractures, cheek bone fractures, nasal fractures, LeFort fracture, skull fractures and eye socket fractures.
- Surgery to insert osseointegrated (bone fused) dental implants and Maxillofacial implants for attaching craniofacial prostheses and bone anchored hearing aids.
- Etc.

6.3.1. Overview of fibula free-flap reconstructive surgery of ameloblastoma tumours

Ameloblastomas are slow growing tumours that are generally painless and benign in nature. Ameloblastomas are responsible for approximately 11% of odontogenic tumours with recurrence rates as high as 71% and 90%. They occur in any age group and gender and are characterized by a slow growing, painless swelling, most often in the posteriomandible. Men in the third and fourth decades are generally more often susceptible [18].

These tumours usually extend beyond their radiographic appearance and thus usually require aggressive surgical techniques. Fibula free flap reconstruction is becoming the more popular surgical procedure [18].

In 85% of all cases, these lesions occur in the mandible. In 62% of cases these tumours extend into the ramus, with less frequent occurrences (around 29%) found in the symphyseal region [18].

For reconstruction, the selection of the vascularised bone graft donor site is determined by the required bone length and thickness. For subtotal or total mandibular reconstruction the fibula (Figure 67 B) has the longest bone which can be readily osteotomized (Figure 67 C) as needed. Multiple

osteotomies allow for the entire mandible to be replaced if needed. Soft tissue may have to be obtained from a different source [19].

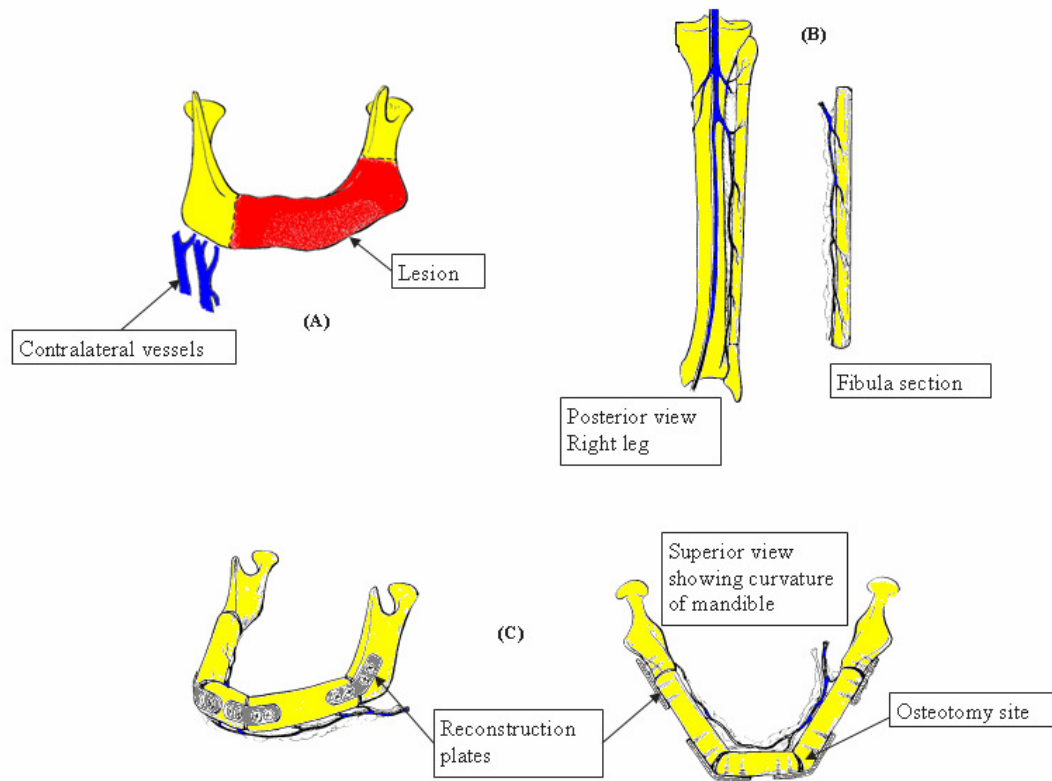


Figure 67: Fibula free flap reconstruction of the mandible [19]

The general pre-operative procedure is that the patient comes in for consultations and is fully inspected (Figure 68). Once the surgeon is strongly convinced that he has been presented with a tumour in the form of an ameloblastoma, the surgeon tries to determine its location, its size, its shape and its consistency. The teeth of the maxilla are evaluated in terms of suitability for full rehabilitation of the occlusion post-operatively.

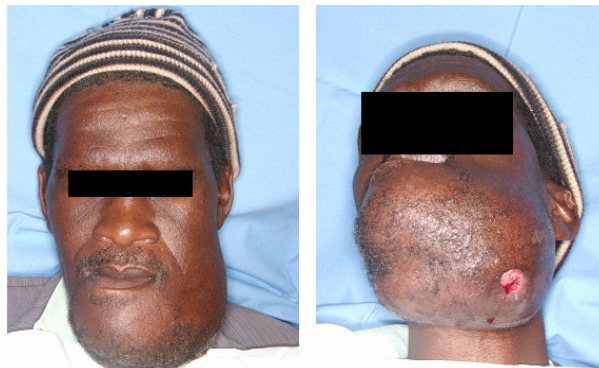

Figure 68: Patient with large Ameloblastoma

The surgeon then takes an incision biopsy from within the boundaries of the resection and the sample is sent for analysis and diagnosis.

The patient is referred for imaging (Figure 69) of the mandible to determine the extent of the tumour.

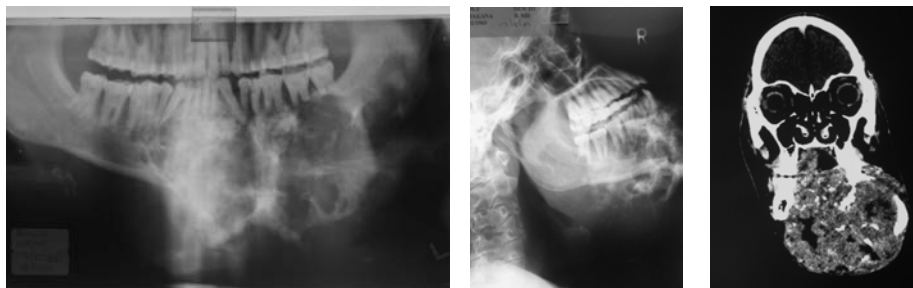


Figure 69: Radiographic images

If all assumptions turn up positive, the treatment procedure involving the free flap reconstruction as well as the next stage of implant insertion is explained to the patient. Being informed of the procedures and possible outcomes, the patient needs to give his or her consent before any further proceedings can take place.

A medical evaluation of the patient is done in terms of smoking habits, alcohol usage, injuries to the body, arthritis, previous strokes, cardiovascular diseases, lung diseases, neurovascular status of the donor area as well as possible conditions of famine [20]. All possible complications are discussed with the patient and the patient is scheduled for surgery.

On the day of surgery, a standard set of routines is performed during which the patient is again clinically evaluated. It includes the following [20]:

- Blood image.
- Blood biochemistry which includes electrolytes, liver functionality and enzymes, glucose, cholesterol and kidney functionality.
- Blood type identification and ordering of three units of blood.
- An EKG and chest plate is arranged due to prolonged anaesthetics with hypotension.
- Dietary consultation to ensure a balanced liquid diet post operatively.
- An Angiogram (Special type of scan used to look at blood vessels) of the donor area.

During surgery, the tumour is resected, followed by the primary procedure of fibula free flap reconstruction.

The tumour is removed by performing a block resection (Figure 70) with a margin of at least 1 cm to 2 cm beyond the visible border of the tumour.

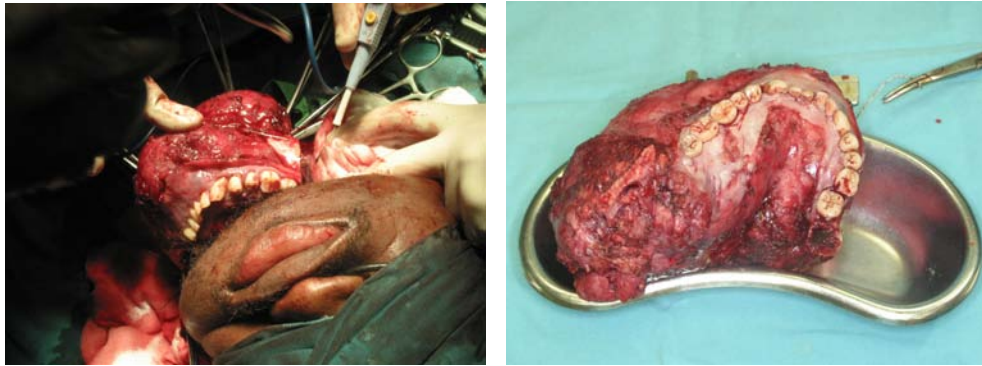


Figure 70: Block resection of Ameloblastoma of the mandible

Once the tumour has been removed, the fibula is removed and contoured by means of osteotomies (Figure 71) to replace the resected part of the mandible.

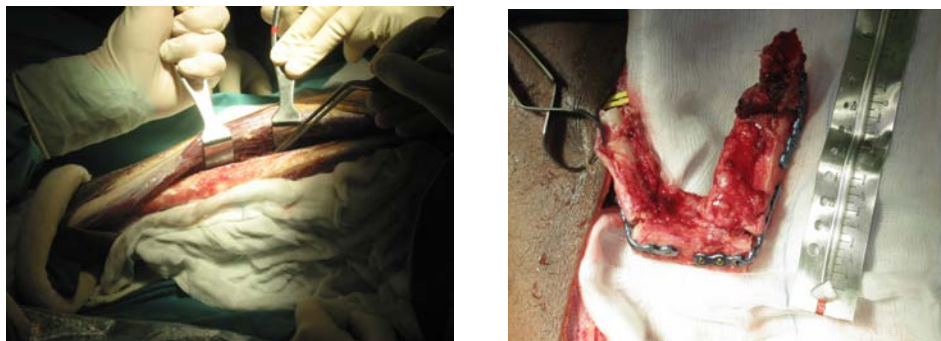


Figure 71: Construction of new mandible from the fibula

The fibula has to remain connected to the blood vessels of the leg to ensure that it receives enough oxygen for the tissue to stay alive whilst being transplanted. This means that contouring the new fibula mandible has to be done by “eyeballing” the remains of the mandible whilst performing the osteotomies on the fibula. Another technique is to use the resected block of tumour infested mandible as reference when performing the osteotomies.

Once the new fibula mandible is ready for transplantation, it is detached from the leg and inserted in its new position.

After surgery is complete, the patient is moved to the intensive care unit (Figure 72).

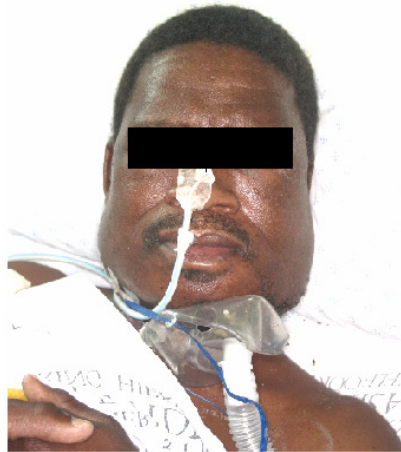

Figure 72: Patient immediately after surgery,

6.3.2. Application of 3D printed models in fibula free-flap reconstructive surgery of ameloblastoma tumours

6.3.2.1. Excision of an ameloblastoma from the right half of the mandible followed by fibula free-flap reconstruction

Condition

The patient was a middle aged man who had an ameloblastoma tumour in the right half of his mandible (Figure 73).

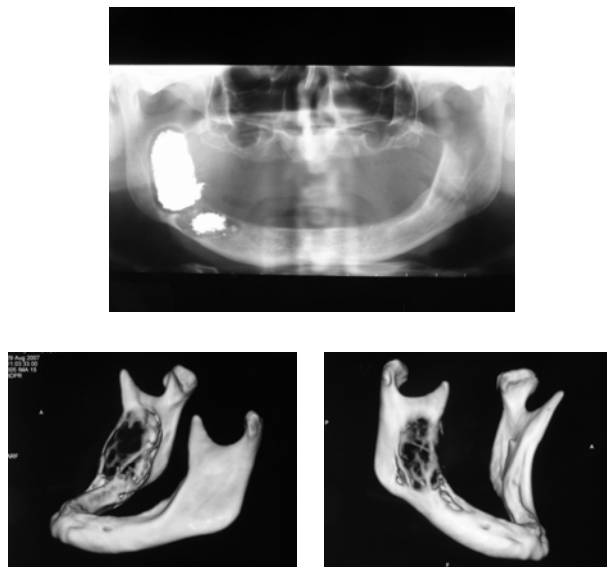

Figure 73: Pantomograph and 3D

Aim of surgery

The aim of the surgery was to resect the tumour from his mandible and to reconstruct the missing piece of mandible using osteotomies of the fibula bone.

Use of model in developing a new surgical planning procedure

Two models were manufactured. The first was a normal view of the tumour infected mandible (Figure 74).

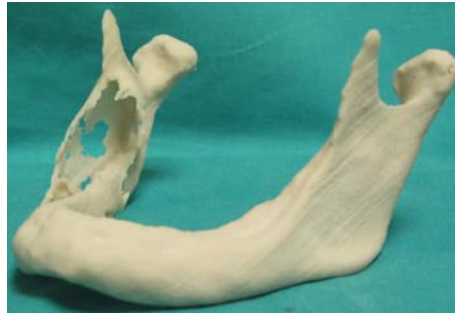

Figure 74: 3D Printed model of normal view

The second was a mirrored view of the healthy left half of the mandible (Figure 75).

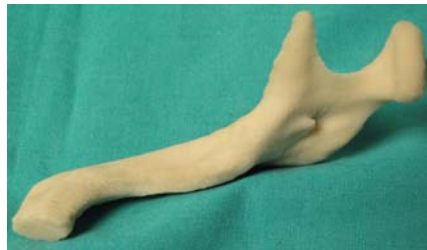

Figure 75: 3D Printed model of mirrored half

The purpose of this mirrored half was to enable the surgeon to determine exactly the length of fibula bone required and angles of the osteotomies that had to be performed to obtain a symmetrically reconstructed mandible.

Pre-operatively the models were used to:

- Visualize the extent of the tumour.
- Plan the size of mandible that needed to be resected.
- Plan the length of fibula bone that had to be resected for reconstruction (Figure 76).

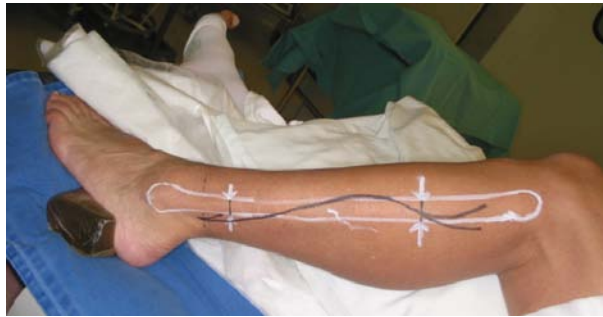

Figure 76: Planned area of partial resection

- Planning and designing the bone graft osteotomies (Figure 77) to achieve a symmetrical reconstructed mandible.

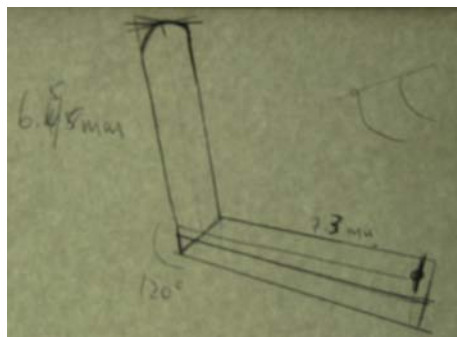


Figure 77: Pre-operative design of bone graft osteotomies

During surgery the models were used to:

- Affirm the planned area of resection on the 3DP model and that of the block resection (Figure 78).

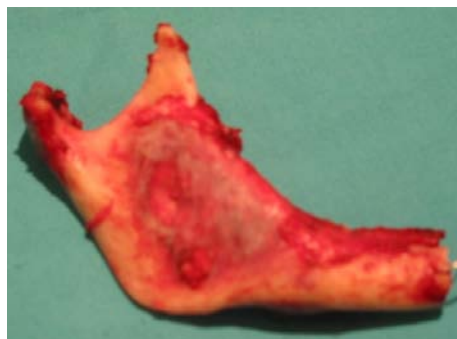

Figure 78: Block resection of tumour infected mandible

The pre-operative design was used to resect the correct length of fibula bone (Figure 79), to perform osteotomies on it at the correct lengths and angles, and to reconstruct a bone graft mandible using reconstruction plates (Figure 80).

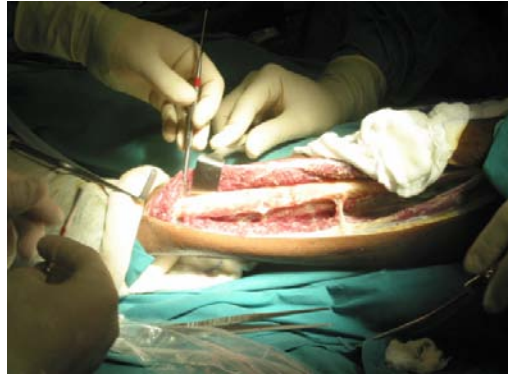


Figure 79: Harvesting bone from the fibula to reconstruct the mandible

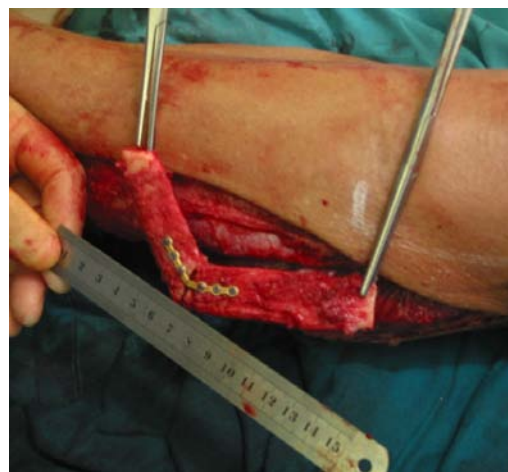

Figure 80: Bone graft mandible reconstructed from fibula (still connected to blood supply of leg)

Results

The surgery had no complications. Post-operative pantomograph show a very good symmetrically reconstructed mandible (Figure 81).

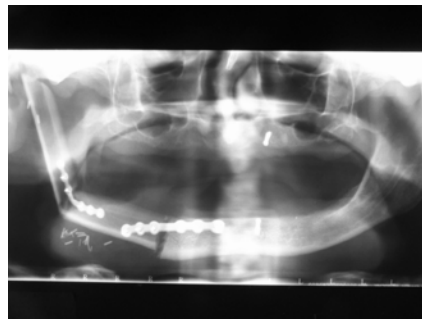


Figure 81: Post-operative pantomograph

6.3.2.2. Excision of a large ameloblastoma followed by fibula free-flap reconstruction

Condition

The patient was a young lady who had an exceptionally large ameloblastoma tumour extending from the anterior toward the posterior regions of both the left and right halves of her mandible (Figure 82 and 83).

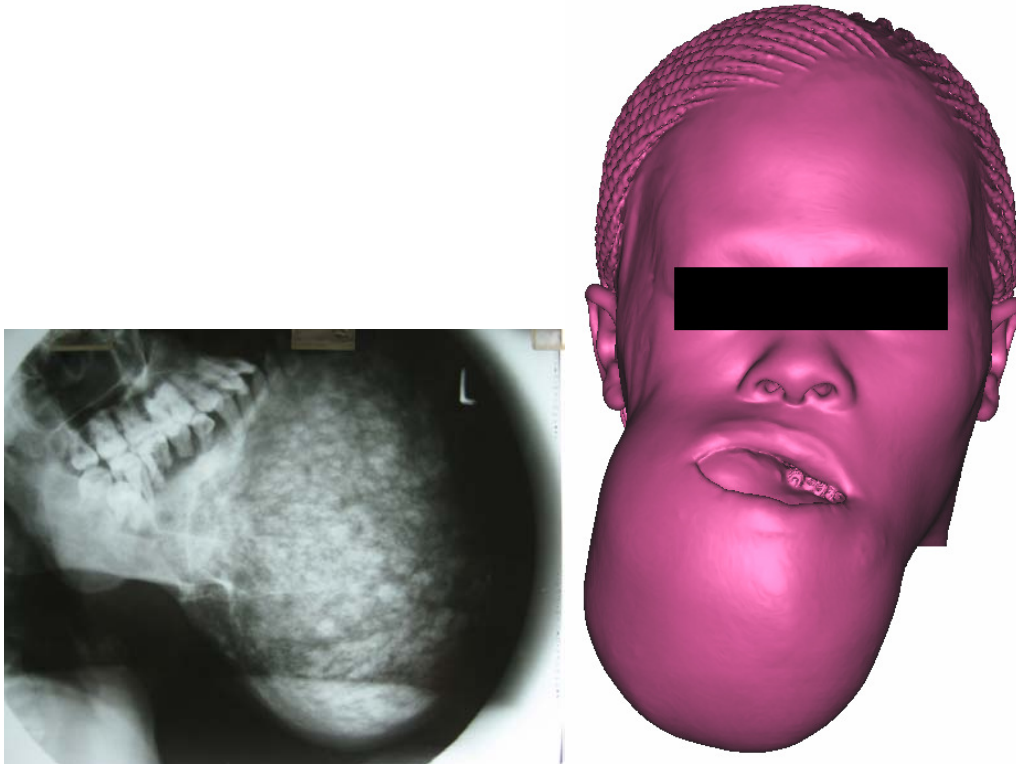

Figure 82: Lateral radiograph of mandible and 3D Image of patient before surgery

Aim of surgery

The aim of the surgery was to resect the tumour from the patient's mandible and to reconstruct the mandible through fibula free flap reconstruction.

Due to the enormous size of the tumour, the surgical procedure would require almost a full mandible to be reconstructed. What further complicated the procedure was that the patient tested HIV positive which meant that the procedure needed to be executed with extreme caution.

Use of model in developing a new surgical planning procedure

Only one model was manufactured showing a normal view of the tumour infected mandible.

Pre-operatively the model was used to:

- Visualize the extent of the tumour (Figure 83) and plan the extent of bone to be resected.

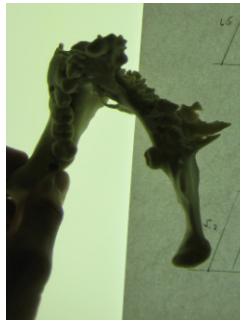

Figure 83: 3DP Model

- Plan the length of fibula bone that had to be resected for reconstruction.
- Planning the osteotomies and designing the planned reconstructed bone graft mandible (Figure 84).

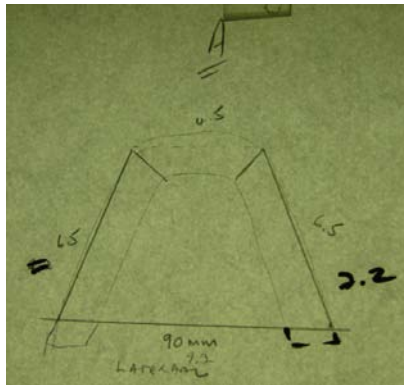


Figure 84: Design of the planned bone graft mandible

During surgery the model was used to:

- Orientate the surgeon during his surgical proceedings (Figure 85).

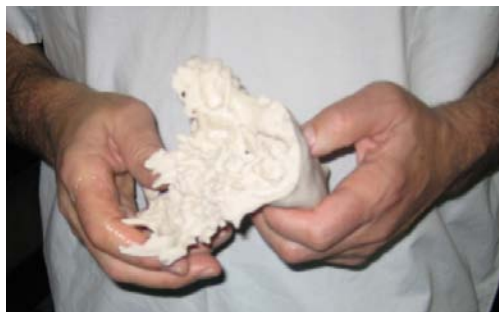

Figure 85: Surgeon studying the model during a time-out period in the surgery

The pre-operative design was used to resect the correct length of fibula bone, perform osteotomies on it at the correct lengths and angles, and to reconstruct a bone graft mandible using reconstruction plates (Figure 86).

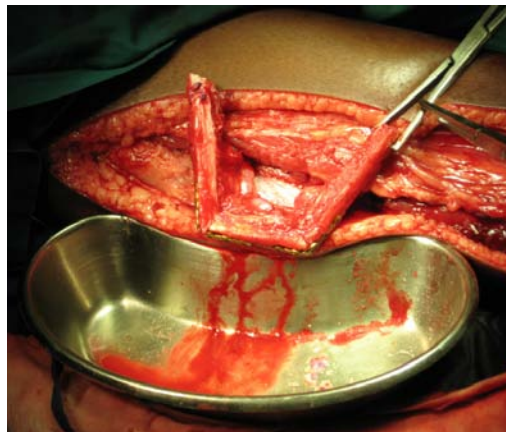

Figure 86: Bone graft mandible reconstructed from fibula (still connected to blood supply of leg)

Results

The surgery took roughly 13 hours, but was executed without any complications. Post operative results were excellent with very good aesthetical results.

6.3.2.3. Surgeon's opinion on Case Studies 1 and 2

The models enabled the surgeon to resect the correct length of fibula and allowed him to plan the exact osteotomies of the fibula before the surgery. This enabled the surgeon to achieve very precise dimensional accuracy, enabling him to reconstruct perfect symmetrical mandibles in both cases.

The surgeon said that the models helped him to achieve amazing results which would otherwise be impossible.

The surgeon estimated a minimum save of critical surgery time of 45 minutes to an hour. This in turn resulted in a major reduction of blood loss and reduction of surgical risk to the patient.

The surgeon suggested that the model could also be used for pre-bending the reconstructive plates holding the fibula reconstructed mandible in place. This could lead to another 20 minutes or 30 minutes reduction of surgery time and further reduce the risk of surgery.

6.3.2.4. Conclusion: Case Studies 1 and 2

Physical 3D models produced through 3D Printing can be successfully applied for Oral & Maxillofacial surgery pre-operatively to:

- Analyse extent of bone penetrating tumours like ameloblastoma.
- Plan the areas of resection.

- Plan and design bone grafts and osteotomies.
- Pre-bend reconstructive plates.

They can also be successfully applied during the surgical procedure to:

- Confirm the resections and osteotomies made.

Ultimately, physical 3D models increase the accuracy of surgical procedures and significantly reduce surgical risk to the patient. Also, apart from indirect costs savings (like eliminating the need for follow-up correctional or revision surgery) the use of 3D printed models directly lead to a large reduction of surgical costs through reduced blood loss, and reduction of theatre time.

6.4. Plastic & Reconstructive surgery

Plastic and reconstructive surgery is a field of surgery that focus on the correction or restoration of form and function. The word "plastic" is derived from the Greek word *plastikos* which means to mould or to shape, and does not have any connection to the synthetic polymer material known as plastic.

Reconstructive plastic surgery is usually performed to improve function, but it may also be done to approximate a normal appearance.

A few examples are:

- Surgical correction of burn impairments
- Surgical correction of traumatic injuries, such as facial bone fractures
- Surgical correction of congenital abnormalities, such as cleft lip, or cleft palate
- Surgical correction of developmental abnormalities
- Surgical treatment of infection or disease
- Surgical removal of cancers or tumours, such as a mastectomy for a breast cancer, a head or neck cancer or an abdominal invasion by a colon cancer

Case study: Soft tissue reconstruction for restoring facial symmetry

Condition

The patient was a lady who suffered from a condition called Parry-Romberg syndrome (Figure 87). It is a rare condition characterized by slowly progressive deterioration (atrophy) of the skin and soft tissues of half of the face (hemifacial atrophy) [21]

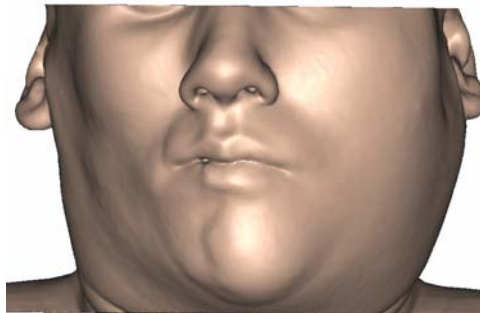

Figure 87: 3D Image of facial deformity

Aim of surgery

The aim of the surgery was to reconstruct the facial soft tissue of the right half of her face (Figure 88) through free flap surgery. This involves harvesting of a soft tissue graft from another part of the patient's body and inserting it underneath the facial skin.

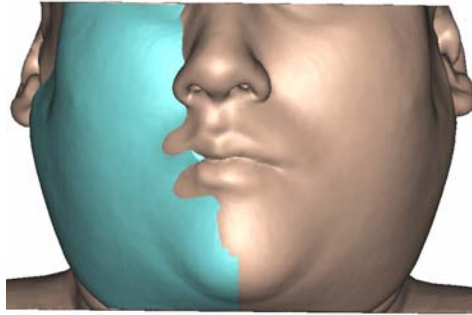


Figure 88: Virtual reconstruction to restore facial symmetry

Use of model

A 3D printed model of the facial bones was manufactured, and covered with silicone representing the soft tissue (Figure 89).

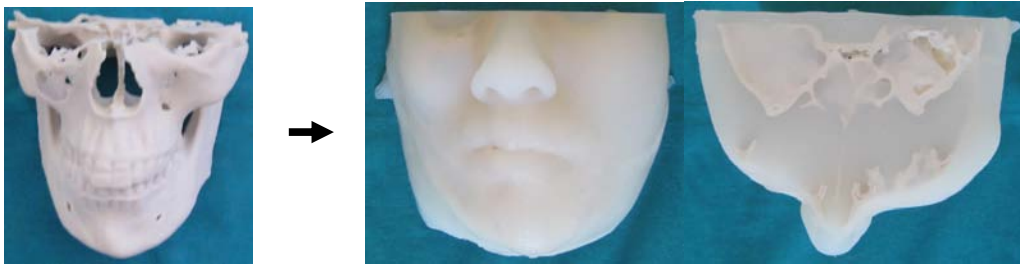

Figure 89: Model showing defect

Also, a prototype was made of the planned soft tissue graft to illustrate the planned facial restoration (Figure 90).

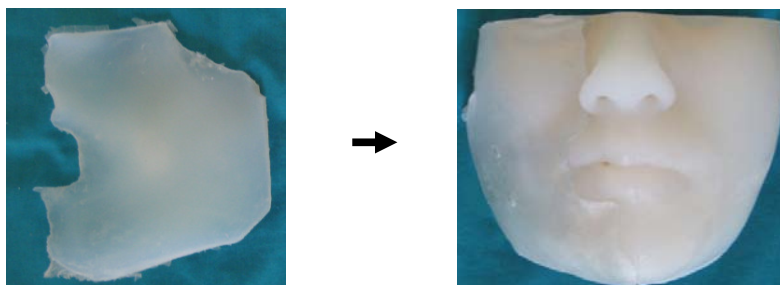


Figure 90: Prototype used to show facial reconstruction

The models were used pre-operatively to:

- Plan the size of the soft tissue harvesting area.
- Plan the shape of the required soft tissue graft.

During surgery the models were used to:

- Guide the surgical team in harvesting the soft tissue graft.

Results

Surgery was a success.

Surgeon's opinion

The surgeon was very impressed with models. He was surprised to see how thin the soft tissue graft needed to be in order to restore facial symmetry. Had it not been for the models, they might have harvested a larger area than needed and perhaps achieved less desirable aesthetical results

Conclusion

Physical 3D models produced through 3D Printing can be successfully applied pre-operatively to:

- Determine the shape of soft tissue defects.
- Determine the size and shape of soft tissue grafts required for reconstruction.

They can also be successfully applied during the surgical procedure to:

- Orientate the surgical team and affirm the harvested soft tissue.

The case study has shown that 3D printed models help to simplify cosmetic procedures and help improve the aesthetical outcomes. They also help prevent the harvesting of unnecessarily large areas of donor tissue.

6.5. Periodontics

Periodontology or Periodontics is a branch of dentistry which studies supporting structures of teeth, along with the diseases and conditions that affect them. A Periodontist is a dentist who specializes in the prevention, diagnosis, and treatment of periodontal diseases, and the surgical placement and long term maintenance of implants. The word periodontics is derived from the Greek word peri meaning around and odons meaning tooth. Literally taken it means the study of that which is “around the tooth”.

Placing of dental implants can sometimes be a very difficult procedure requiring very precise measures to ensure that implants are correctly positioned and that they are not placed too deep or too shallow. If placed too shallow, or in an area where too little bone is available, they might become loose over time or during mastication. If placed too deep, they might damage the mandible nerve canal or penetrate through the maxilla and the floor of the nasal cavity. Ideal placement is therefore critical and requires very accurate planning measures.

Case study: Planning of placement of dental implants

Condition

The patient was a late aged male who had none of his teeth left (Figure 91).

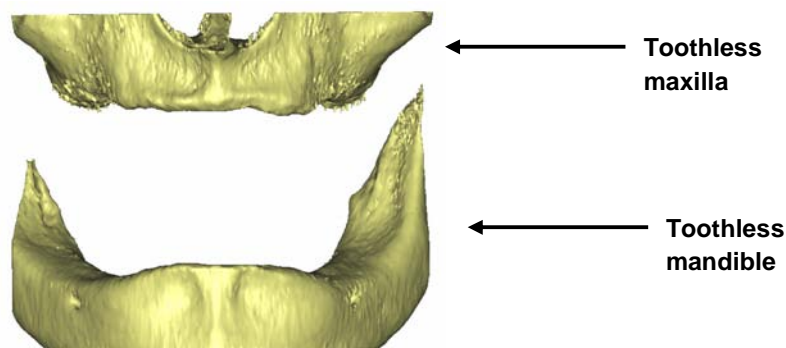


Figure 91: 3D image of toothless mandible and maxilla

Aim of surgery

The aim of the surgical procedure was to securely insert dental implants into the bone of the maxilla of the patient. These implants would then serve as abutments for placing permanent false teeth which would restore aesthetical appearance and mastication.

Use of Model

The model was used pre-operatively to:

- Determine the areas of the maxilla with sufficient bone for placing the implants.
- Plan the most ideal spacing and positioning of the implants and pre-drill the holes to simulate the planned procedure (Figure 92 and 93).

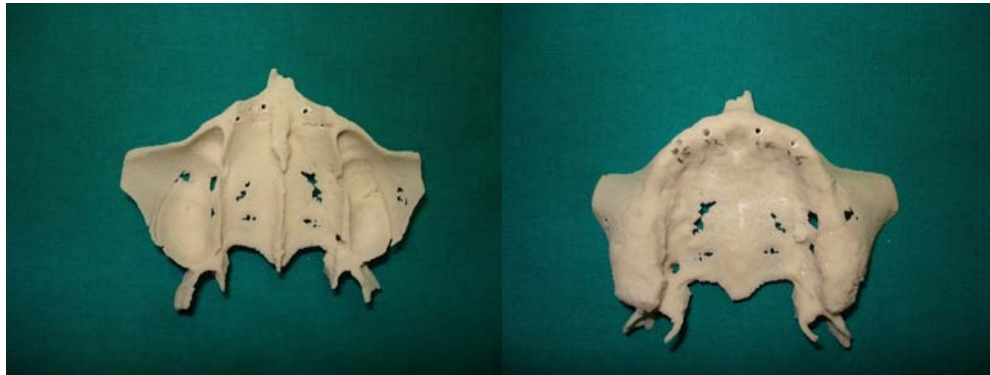


Figure 92: Top and bottom views of 3D printed model on which the surgeon performed his surgical planning

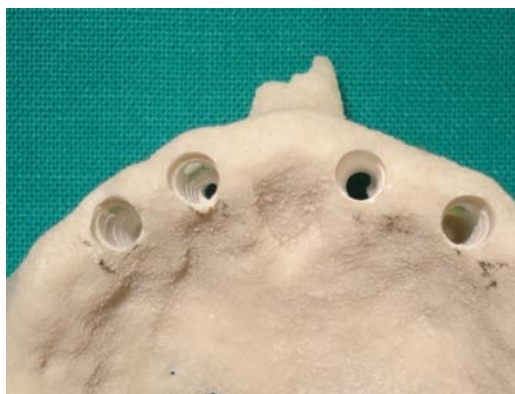

Figure 93: Close-up view of the planned positions for placing the implants

The model was used during surgery to:

- Help identify anatomical landmarks on the patient's maxilla that coincide with that of the model, and which could serve as reference points for positioning the implants.

Below is a few pictures taken during surgery (Figure 94).

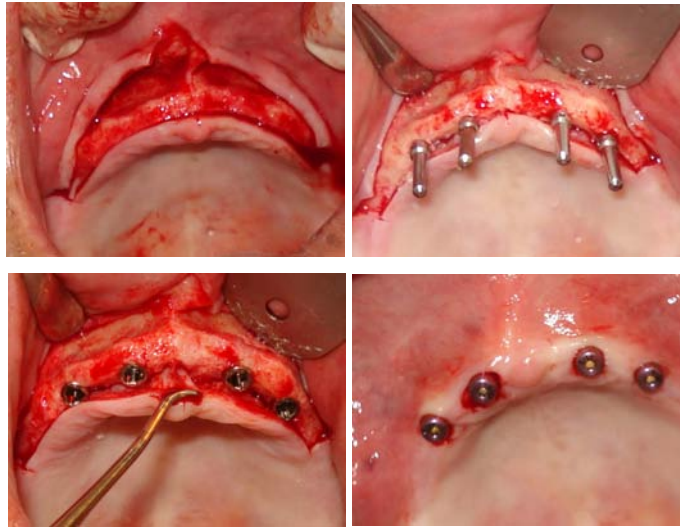


Figure 94: Surgical procedure

Results

Surgery was a success.

Surgeon's opinion

The surgeon said that the model enabled him to perform very accurate placements of the implants. The surgeon believes that the use of these models could become a growing standard. The surgeon said that he personally prefer these models over other patient specific dental solutions such as Simplant and Nobel Bio Guide which are used for placing dental implants. He said that the 3DP model gave him more control over the surgery. He has since started lecturing some of his fellow colleagues on the use of 3D printed models to help improve surgical planning and accuracy during periodontic procedures.

Conclusion

3D Printed models can be successfully used as a tool for guided placement of dental implants. They help increase surgical planning, confidence and accuracy, and offer an alternative solution to more expensive solutions such as Simplant and Nobel Bio Guide.

7. *Summary of results*

Physical 3D models produced through 3D Printing can be successfully applied pre-operatively to:

- Determine the position and extent of fractures which would otherwise be very difficult or even impossible with contemporary 2D radiographic images.
- Plan the surgical procedure and surgical point of entry.
- Estimate the amount of reserve blood required to compensate for blood loss.
- Analyse the extent of bone damage and bone penetration of tumours.
- Analyze defects.
- Simulate range of motion and determine anatomical obstructions.
- Plan the areas of resection.
- Determine the extent of bone degeneration and penetration of cysts.
- Determine the amount of bone available for fixating implants.
- Select the correct size of implants required for spinal procedures.
- Plan the positioning and placement of spinal implants.
- Determine the size and shape of cranial defects.
- Assist in the design and fitment of patient specific implants.
- Plan the area of resection of cranial bone tumours.
- Assist in the design of patient specific cranial cutting guides.
- Visualize implants placed during previous surgeries.
- Plan and design bone grafts and osteotomies.
- Pre-bend reconstruction plates.
- Determine the shape of soft tissue defects.
- Determine the size and shape of soft tissue grafts required for reconstruction.
- Accurately plan the placement of dental implants.

- Explain the surgical procedure to the patient and obtain patient consent.

Physical 3D models produced through 3D Printing can be successfully applied intra-operatively to:

- Serve as a means of communication between surgical team members.
- Serve as a means of orientation relative to patient anatomy.
- Bend reconstruction plates.
- Guide and orientate the surgical team during the removal of tumour and placement of patient specific implants.
- Verify that the correct amount of bone is resected.
- Select the correct size of implants required.
- Improve surgical accuracy.
- Serve as means of education to young surgical personnel.
- Guide and orientate the surgical team during the resection of cranial bone tumours and placement of patient specific cranial implants.
- Assist in the harvesting of soft tissue grafts.
- Assist in guided placement of dental implants.

Physical 3D models produced through 3D Printing can be successfully applied post-operatively to

- Serve as educational tools for surgeons in training.
- Serve as evidence in medical related court trials.

Ultimately, the application of the 3D printed models resulted in

- A reduction of surgery time.
- Shorter time of patient hospitalization.
- Reduced fatigue of surgeons.
- Reduced blood loss of the patients.
- Increased levels of confidence of the surgical team prior and during execution of the surgery.
- Reduced mental strain and fatigue of the surgeons performing the surgical procedure.

- Simplified cranioplasty procedures.
- Improved levels of surgical accuracy.
- Improve aesthetical results.
- Reduced psychological complications and trauma of patients resulting in increased quality of life post-operatively.
- Reduced surgical risk to the patient.
- Simplification of cosmetic procedures.
- Optimal harvesting of hard and soft tissue grafts.
- Reduction of theatre costs.

8. *Conclusions*

It has been shown that the application of 3DP models stretch over a wide range of surgical procedures.

It is difficult to quantify the total impact of 3DP models in terms of overall surgical costs. The reason for this is that there are many variables within each surgical procedure, plus there are other factors like the hospital billing system that also change from one surgery to the next. For example, a government hospital like Tygerberg Hospital has different rates from a private hospital group like Medi-Clinic. Also, a group like the Medi-Clinic Hospital Group has different rates to that of another private group like the Netcare Hospital Group. Apart from this, each private hospital group also has a unique billing system for each of the various medical aid schemes. A larger scheme like Discovery is charged less than a smaller medical aid scheme, simply because they are a larger client and thus receive better rates.

However, together with the case studies presented in this report, a total of almost 50 cases were performed and analyzed to estimate the effect of these models on surgery time and surgical cost. As this database of case studies increase, estimations will become more exact, but the results shown in table 7 already give clear evidence of the direct impact of 3DP models on overall surgical costs.

Surgical field	Most successful areas of application at present day	Application of 3DP model	Average cost of 3DP model	Average lead time from receiving the data to completion of the 3DP model	Reduction of theatre time as estimated by surgeons (minutes)	Direct reduction of theatre costs calculated @ R150 to R200 per minute	Total direct costs savings
Orthopaedic surgery	<p>Pelvic fractures</p> <p>Bone tumours</p> <p>Spinal reconstruction as a result of Echinococcosis cysts or cysts caused by tuberculosis</p> <p>Revision surgeries of hips, knees, and elbows</p> <p>Reconstruction of congenital deformities of hips, knees, and feet</p>	<p>Pre-operative planning</p> <p>Physical simulation of planned surgical procedures</p> <p>Pre-operative adjustment of jigs and fixtures</p> <p>Pre-bending of reconstruction plates</p> <p>Selecting the correct size of implants</p> <p>Design and fitment of patient specific implants</p> <p>Communication between surgical team members and means of orientation relative to patient anatomy</p>	<p>R 2 500 to R 3 500</p>	1 to 3 Days	60	<p>R 9 000 to R 12 000</p>	<p>R 5 500 to R 9 500</p>

Continued on next page

Neurosurgery	<p>Cranioplasty procedures for removal of bone tumour and or reconstruction of cranial defects</p> <p>Revision cranioplasty procedures for restoring aesthetical appearance</p>	<p>Pre-operative planning</p> <p>Physical simulation of planned surgical procedures</p> <p>Communication between surgical team members and means of orientation relative to patient anatomy</p> <p>Design and fitment of patient specific cutting guides</p> <p>Design and fitment of patient specific cranial implants</p>	<p>R 1 500 to R 5 000</p>	1 to 3 Days	60 to 120	<p>R9 000 to R24 000</p>	<p>R4 000 to R22 500</p>
Oral & Maxillofacial surgery	<p>Fibula free flap reconstructions</p> <p>Removal of facial tumours and cysts affecting bone anatomy</p> <p>Reconstruction of temporomandibular joint (TMJ) disorders</p> <p>Reconstruction of facial symmetry as a result of tumours, cysts, trauma, or congenital disease</p>	<p>Pre-bending of reconstruction plates</p> <p>Pre-operative planning</p> <p>Physical simulation of planned surgical procedures</p> <p>Implant design and fitment for temporomandibular joint (TMJ) disorders</p> <p>Communication between surgical team members and means of orientation relative to patient anatomy</p>	<p>R 2 500 to R 4 000</p>	1 to 3 Days	60 to 120	<p>R 9 000 to R 24 000</p>	<p>R 5 000 to R 21 500</p>

Continued on next page

Plastic & Reconstructive surgery	Midface distractions	Planning & positioning of distractors	R 3 500 to R 5 000	1 to 3 Days (2 Days extra for 3DP model with silicone soft tissue)	Data outstanding (Estimated @ 60 minutes minimum)	-	-
	Skull expansions	Planning of soft tissue grafts					
	Soft tissue reconstruction to restore facial symmetry						
Periodontics	Placing of dental implants	Planning the positioning and placement of dental implants	R 1 000 to R 3 000	1 to 3 Days	Data outstanding	-	-

Table 7: Direct cost impact analysis

The table does not include indirect cost effects like reduced blood loss, shorter periods of hospitalisation, reduced follow-up treatment, less need for physiotherapy or other rehabilitating expenses, or reduced risk of revision surgical procedures (which are responsible for 60% of the total surgical cost in the case of hip and knee surgeries).

Also, in some of the neurosurgical cranioplasty procedures, 3DP models resulted in additional cost reductions of between R 35 000 and R 70 000 because it enabled the production of patient specific implants and surgical tooling which would otherwise have to be ordered and imported from overseas at ten times the cost at which it was manufactured locally. Also, had it been imported, it would take a minimum of 3 to 4 weeks, where now it could be manufactured locally within a week.

The project has shown that, as the field of reconstructive surgery heads more and more in the direction of patient specific solutions, cost effective technologies such as 3D Printing can be justified to become part of standard protocol during the planning and execution stages of reconstructive surgery. Not only do they remarkably reduce surgical risk and improve surgical results, but they also directly lead to a large reduction of surgical costs.

9. *Outlook*

What are the next steps?

Ultimately, to become part of standard protocol, surgeons as well as medical aid schemes have to adopt the technology.

Looking at the current modalities used for the purpose of surgical planning, there once was a time where technologies like CT and MRI were also new to the market and needed to be adopted in the medical industry.

Even though X-rays had already been in use, this adoption resulted from a need among surgeons to improve their ability to visualize patient anatomy and improve pre-operative planning. This in turn forced medical aids to start adopting these technologies.

As the need to improve pre-operative planning continues to grow among surgeons, medical schemes will be urged to approve and adopt it.

This project has already started to create a great deal of awareness among surgeons in South Africa. Some of the work has already been presented at four national medical congresses (Appendix C). The project aims to continue engaging surgeons to make them aware of the benefits of using 3DP and other Additive Fabrication technologies.

Over time, the advantages offered by 3DP will become apparent, and it should become a natural process for medical aids to adopt the technology as part of standard protocol.

References

1. Pham, D. T., Dimov S. S., *Rapid manufacturing: the technologies and applications of rapid prototyping and rapid tooling*. London: Springer-Verlag UK, c2001.
2. Wohlers, T, 2009, *Wohlers Report 2009, Rapid Prototyping, Tooling & Manufacturing State of the Industry, Annual Worldwide Progress Report*, Wohlers Associates Inc., Colorado, USA
3. Website: <http://www.xpress3d.com>
4. Website: <http://en.wikipedia.org>
5. Kruth, J.P., Mercelis, P., Van Vaerenbergh, J., Froyen, L., Rombouts, M., 2003, *Advances in Selective Laser Sintering, Proceedings of the 1st International Conference on Advanced Research in Virtual and Rapid Prototyping (VRAP)*, pp 59-70
6. Website: http://www.arcam.com/applications/ps_be.asp
7. Website: <http://www.mtt-group.com/selective-laser-melting.html>
8. Website: http://www.uchospitals.edu/images/cms/uch_008020.jpg
9. Website: <http://www.wpxrays.co.za>
10. Website: <http://www.nhsdirect.nhs.uk/articles/article.aspx?articleId=554§ionId=29>
11. Website: <http://www.materialise.be>
12. Website: <http://home.att.net/~castleisland/3dprint.htm>,
13. Website: <http://www.ptonline.com/articles/200408cu3.html>
14. D. Dimitrov, W. van Wijck, K. Schreve, N. de Beer, 2006, *Investigating the achievable accuracy of three dimensional printing*, Rapid Prototyping Journal, Vol. 12, No. 1
15. D. Dimitrov, K. Schreve, N. de Beer and P.Christiane, 2008, *Three dimensional printing in the South African industrial environment*, South African Journal of Industrial Engineering, pp 208
16. Website: <http://www.zcorp.com>
17. Website: <http://www.biologyreference.com>
18. Van Rensburg L J, 2004, *The application of Magnetic Resonance and Computed Tomography Imaging in the diagnosis and management of maxillofacial tumours*, DSc (Maxillofacial Radiology), Department of Diagnostics, Faculty of Dentistry, University of the Western Cape, pp270-296.
19. Swartz W M, Banis J C, 1992, *Head and Neck Microsurgery*, pp187-224
20. Scheepers P J J, 1995, *Implanto-Ortognatiese rekonstruktiewe chirurgie vir funksionele oromandibulêre rehabilitasie in die fibula vry flap gerekonstrueerde mandibula*
21. Website:http://www.ninds.nih.gov/disorders/parry_romberg/parry_romberg.htm[National Institute of Neurological Disorders and Stroke, National institutes of health]

Other

22. Website: <http://www.emeraldinsight.com>
23. Phidias Network Research Group (Dec 1998, Jun 1999, Dec 1999, Jun 2000, Dec 2000, Jun 2001, Dec 2001, Mar 2002), *Rapid Prototyping in Medicine*, Phidias research papers No. 1-8

24. *Fabrication of maxillo-facial implant*, Rapid Prototyping Journal; Volume12 Number 4; 2006; pp 206-213.

Appendix A: Mechanical tests for medical suitability of 3D printed parts

The objectives of the bar test was to determine how 3D printed parts would respond to surgical simulations like drilling and placing screws. Also, to determine which combination of materials would be more suitable for the purpose of surgical simulation.

The materials used to create the bars were the following:

- The two powder materials used were ZP130 and ZP131.
- The two liquid binder materials used were zb58 and zb60.
- The two infiltrating agents used were wax and Epoxy Resin Prime 20 (slow hardener).

These materials were combined and marked as shown in the table 1:

Material combinations	Marked as
ZP 130 powder, zb58 binder, Wax infiltration	W0
ZP 130 powder, zb58 binder, Epoxy infiltration	E0
ZP 131 powder, zb60 binder, Wax infiltration	W1
ZP 131 powder, zb60 binder, Epoxy infiltration	E1

Table 8: Combination of samples presented to the surgeons

Thus, there were four different types of sample bars (Figure 95).




Figure 95: Test bar samples presented to surgeons

To make the test as accurate and objective as possible, the surgeons were given no information about the characteristics of the different coded materials. Also, all surgeons were given their own set of four sample bars, and they were not allowed to see how the other surgeons rated the bars.

Test 1: Drilling the materials

For this test, the surgeons were each presented with four samples which firstly they had to drill to determine how the material would react, and secondly they had to rate the material according to hardness.

Surgeon 1				
Material	W0	W1	E0	E1
Can it be drilled?	Yes	Yes	Yes	Yes
Does it break or fracture?	No	No	No	No
Hardness rating	Soft	Soft	Very hard	Hard

Surgeon 2				
Material	W0	W1	E0	E1
Can it be drilled	Yes	Yes	Yes	Yes
Does it break or fracture	No	No	No	No
Hardness rating	Soft	Soft	Very hard	Hard

Surgeon 3				
Material	W0	W1	E0	E1
Can it be drilled	Yes	Yes	Yes	Yes
Does it break or fracture	No	No	No	No
Hardness rating	Soft	Soft	Hard	Hard

Surgeon 4

Material	W0	W1	E0	E1
Can it be drilled	Yes	Yes	Yes	Yes
Does it break or fracture	No	No	No	No
Hardness rating	Soft	Soft	Hard	Hard

Surgeon 5				
Material	W0	W1	E0	E1
Can it be drilled	Yes	Yes	Yes	Yes
Does it break or fracture	No	No	No	No
Hardness rating	Soft	Soft	Very hard	Hard

Surgeon 6				
Material	W0	W1	E0	E1
Can it be drilled	Yes	Yes	Yes	Yes
Does it break or fracture	No	No	No	No
Hardness rating	Soft	Soft	Hard	Hard

Test 2: Screw placement

Surgeon 1				
Material	W0	W1	E0	E1
Can screws be placed?	Yes	Yes	Yes	Yes
Does it break or fracture?	No	No	No	No

Surgeon 2				
Material	W0	W1	E0	E1
Can screws be placed?	Yes	Yes	Yes	Yes
Does it break or fracture?	No	No	No	No

Surgeon 3				
Material	W0	W1	E0	E1
Can screws be placed?	Yes	Yes	Yes	Yes
Does it break or fracture?	No	No	No	No

Surgeon 4				
Material	W0	W1	E0	E1
Can screws be placed?	Yes	Yes	Yes	Yes
Does it break or fracture?	No	No	No	No

Surgeon 5				
Material	W0	W1	E0	E1
Can screws be placed?	Yes	Yes	Yes	Yes
Does it break or fracture?	No	No	No	No

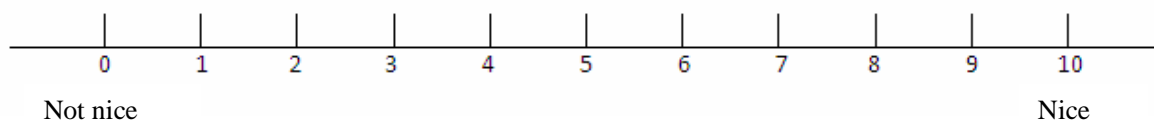
Surgeon 6				
Material	W0	W1	E0	E1
Can screws be placed?	Yes	Yes	Yes	Yes
Does it break or fracture?	Yes	Yes	No	No

Test 3: Rating the materials

For this test, the surgeons rated the different samples on a visual analogue scale (VAS). They had to rate the samples on a scale of 0 to 10 according to their personal preference of the type of material they would prefer to work with.

10 being "Very nice to work with" and

0 being "Not nice to work with"



The ratings were as follows

Surgeon 1				
Material	W0	W1	E0	E1
Rating	6	8	2	9

Surgeon 2				
Material	W0	W1	E0	E1
Rating	9	9	6	6

Surgeon 3				
Material	W0	W1	E0	E1
Rating	9	9	1	2

Surgeon 4				
Material	W0	W1	E0	E1
Rating	9	9	4	4

Surgeon 5				
Material	W0	W1	E0	E1
Rating	8	8	2	3

Surgeon 6				
Material	W0	W1	E0	E1
Rating	2	2	6	9

Appendix B: Sample of form used to gather case study data

Martin Steyn

Surgeon/s: Johan Davis, Prof Vlack Date: 17/07/08

Patient condition: Ant. vertebrae collapse due to osteoporosis

Diagnosis: Ethnic osteoporosis

Time spent in theatre before surgery: _____ Hours 50 Minutes

Duration of surgery (Skin to skin): _____ Hours _____ Minutes I 4:20 - 12:00

Complications: None

Questionnaire:

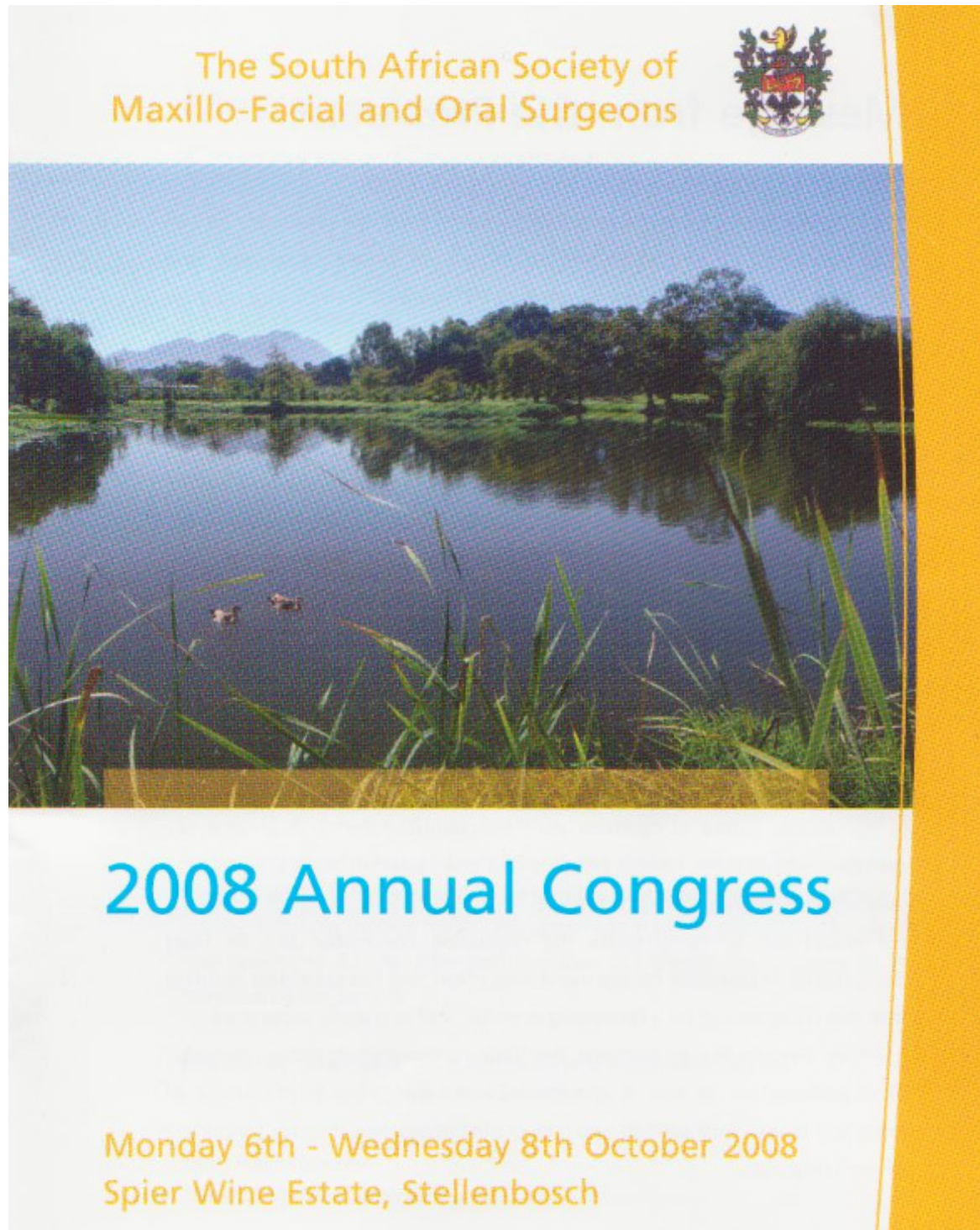
Please read through the questions in the table. Mark yes (Y) or no (N), and give a rating where applicable.

Note: 0 = Bad

10 = Excellent

Application of physical 3D model	Y/N	Rating(0-10)
Planning the surgical approach and the surgical procedures by looking at model	Y	8 /10
Explaining the planned surgical procedure to the surgical team members using the model	Y	7 /10
Explaining the surgical procedures to the patient using the model		/10
Estimating the amount of blood necessary for the surgery with the help of the model		/10
Selecting the correct tools / pins / plates / screws etc by looking at model	Y	8 /10
Positioning of plates / screws / implants relative to model before insertion into the patient	Y	8 /10
Bending and fitting of reconstruction plates / pins relative to model geometry	Y	8 /10
Using the model as a visual orienting device during intervention	Y	10 /10
Estimate of surgery time saved with help of model:	<u>1</u> Hours _____ Minutes	
Did the model change the original surgical plan/diagnosis?	Y/N	
Did the models help to reduce the surgical risk?	Y/N	Rating (0-10) <u>7</u> /10

Appendix C: Example of work presented at a Medical Congress





autologous bone is often an adequate reconstructive option, it carries several disadvantages. The exploitation of the bone induction principle would intuitively be an ideal solution for restoration of missing mandibular bone tissue in human patients. Preclinical trials in calvarial defects of *Papio ursinus* treated with naturally derived bone morphogenetic/osteogenic proteins (BMPs/OPs), hOP-1 and binary applications of hOP-1 and hTGF- β_3 isoforms confirmed the expected theoretical potential to regenerate bone. The translation of these results in human patients has proven to be surprisingly difficult. The generation of small volumes of bone requires mega-doses of recombinant human proteins several fold higher than the predicted doses of recombinant hBMPs/OPs derived from animal models including non-human primates. This suggests that the biological machinery for the induction of bone formation in human patients is incompletely recruited and severely inhibited using single morphogen applications. In addition the concept of osteoinduction can be exploited both orthotopically (bone site) and heterotopically (soft tissue site) in a clinical context. Three cm critical size mandibular defects in 4 baboons were implanted with 375 μ g hTGF- β_3 combined with 3 grams of collagenous matrix as carrier. Significant infection developed in 2 animals resulting in significant reduction of bone regenerate, but nevertheless bone induction. In the other 2 animals marked bone induction was noted. A further 4 mandibular defects in 4 baboon were implanted with binary applications of hOP-1 and hTGF- β_3 . This trial was again complicated by sepsis in 2 animals but nevertheless evidence of osteoinductivity ranging from scant to complete defect repair was seen on day 30. Finally in 2 baboons inductive implants were placed into the rectus abdominis and the induced bone harvested and transplanted into mandibular defects 2 months later. All baboons were euthanized 30 days post implantation and mandibles were subjected to radiographic and histological analysis. These data suggest that the current approach to human bone regeneration by exploiting osteoinduction requires the development of treatment strategies tailored to specific defects and patients. This may require cessation of our reliance on a single morphogen application at a universal dose. Alterations of morphogen dose and morphogen choice including the option of binary application may improve clinical performance and predictability.

Application of South African produced Three-Dimensional Print models in Cranio-Maxillofacial surgery.

JA Morkel¹*, FR Graewe² & AE Zuehlke²

¹Division of Maxillofacial and Oral Surgery, University of the Western Cape

²Division of Plastic Surgery & Reconstructive Surgery, University of Stellenbosch

Introduction: Three-Dimensional Printing (3DP) is a Rapid Prototyping (RP) technique to fabricate prototypes from biomedical images. These models can easily be produced in South Africa (SA) using all standard computed tomographic (CT) data. Literature reflects that 3DP models provide acceptable precision and may be useful aids in most cranio-maxillofacial surgeries.

Materials and Methods: Two pilot studies were performed to evaluate the clinical application of the SA produced models. The first study evaluated the possibility to place titanium plates and directly on the models. Four different compounds were evaluated in a lab based double blind study. The second pilot study evaluated the stability of the chosen compound using repeated autoclave cycles and ethylene oxide gas (EtO) sterilization. The 3DP models were used in surgical planning of 3 free-flap reconstructions of mandibles.

Results: Plates and screws can effectively be used on 1 of 4 tested compounds. Repeated



autoclave cycles and EtO sterilization does not affect the gross 3D stability of the models.

Conclusion: The 3DP models can effectively be used to reduce surgical theatre time in cranio-maxillofacial surgical procedures. The SA produced models can be supplied at a cost compatible to the South African economic climate.

THE USE OF PHYSICAL 3-D MODELS IN ORTHOPEDIC SURGERY

Case 1



Gender: Male (70)
Hospital: Paarl Medi-Clinic Hospital
Pathology: Complex acetabulum fracture
Procedure: Reconstruction, hip replacement

Case 2



Gender: Male (53)
Hospital: Tygerberg Hospital
Pathology: Echinococcus cyst spine
Procedure: Debridement, fusion with cage

Case 3




Gender: Male (28)
Pathology: Bone deformity, elbow fracture
Procedure: Debridement

Case 4



Gender: Female (33)
Hospital: Paarl Medi-Clinic Hospital
Pathology: Acetabulum pelvic fracture
Procedure: Reconstruction


EVALUATION OF PATHOLOGY



SPINAL TUBERCULOSIS



PELVIC FRACTURE



PELVIC TUMOUR

PLANNED PROSTHESIS USAGE



SIZING OF PROSTHESIS



CHOICE OF PROSTHESIS



PLACEMENT OF PROSTHESIS

INTRA-OPERATIVE ORIENTATION



PELVIC FRACTURE



COMPLEX HIP REPLACEMENT

CUSTOM IMPLANT



IMPLANT DESIGN



IMPLANT MANUFACTURING



IMPLANTED PROSTHESIS

PURPOSE OF STUDY

To improve the outcome of reconstructive surgery of complex defects using customized physical 3D models. Improve pre-operative planning and execution of surgery. Reducing cost and risk of complications. Improve communication with staff and patient. Legal protection of surgical team.

METHODS

A custom physical 3D model is produced from CT scan data. Physical 3D Models of pelvis, spine and elbow was used. The models were used for:
Visualization of the defects.
Planning of surgical approach and procedure.
Selecting and orientation of components

RESULTS

Decreased operation time.
Improve confidence and communication in surgical team
Reduced mental and physical effort of surgeon.
Saving costs.
Increased efficiency of team.
Decreased morbidity of patient.
Better longterm outcome anticipated.

CONCLUSION

The use of 3D models improve decision making and the outcome of surgery in complex orthopedic reconstruction. Makes the operation more efficient. Better approach, less blood loss, reduced risk, reduce cost. Higher degree of patient satisfaction

PRE-OPERATIVE PLANNING



PRE-OPERATIVE ORIENTATION



Figure 96: Work presented at SAOA Congress, Cape Town, September 2008