

Acute coronary vasospasm secondary to industrial nitroglycerin withdrawal

A case presentation and review

J. Z. PRZYBOJEWSKI, M. H. HEYNS

Summary

A Black employee exposed to industrial nitroglycerin (NG) in an explosives factory presented with severe precordial pain. The clinical presentation was that of significant transient antero-septal and anterolateral transmural myocardial ischaemia which responded promptly to sublingual isosorbide dinitrate. Despite being removed from exposure to industrial NG and receiving therapy with long-acting oral nitrates and calcium antagonists, the patient continued to experience repeated attacks of severe retrosternal pain, although transient myocardial ischaemia was not demonstrated electrocardiographically during these episodes. Cardiac catheterization revealed a normal myocardial haemodynamic system and selective coronary arteriography delineated coronary arteries free from any obstructive lesions. An ergonovine (ergometrine) maleate provocative test failed to elicit coronary artery spasm, although this was undertaken while the patient was on nitrate and calcium-blocker therapy. Clinical records of previous significant constrictive pericarditis (probably due to tuberculosis) with resultant abnormalities on the ECG complicated the diagnosis. Evaluation was further hindered by the known 'variant pattern' seen on the ECGs of members of the Black population.

We postulate that this patient's clinical features were a direct result of severe vasospasm affecting the left coronary artery; it is also strongly suggested that withdrawal from contact with industrial NG precipitated this potentially lethal coronary vasospasm. The role played by industrial NG in ischaemic heart disease is reviewed, as well as the importance of the 'normal variant pattern' in the assessment of cardiac disease in Black patients.

As far as we are aware this is the first time that the use of the ergonovine maleate provocative test has been documented in the industrial NG withdrawal syndrome.

S Afr Med J 1983; 63: 158-165.

Cardiac Clinic, Department of Internal Medicine, University of Stellenbosch and Tygerberg Hospital, Parowvallei, CP

J. Z. PRZYBOJEWSKI, M.B. CH.B., F.C.P. (S.A.)

Department of Occupational Medicine, PO Dynamite Factory, Somerset West, CP

M. H. HEYNS, M.B. CH.B., DIP. OCC. MED.

Date received: 27 July 1982.

Clinical presentation

The patient, a Black man, was apparently quite healthy until July 1977 when he noted the onset of dyspnoea on moderate exertion and nonspecific chest pain. A chest radiograph then showed 'bilateral basal segment pleuropneumonitis with pleural effusions', cardiomegaly and pulmonary congestion. Therapy for cardiac failure was begun but the patient's clinical condition did not improve significantly and he began experiencing dyspnoea on minimal exertion, orthopnoea, paroxysmal cardiac dyspnoea, swelling of the ankles, and some abdominal distension. At this time he was 41 years old and had been employed at an explosives factory for many years where he came into contact with industrial nitroglycerin (NG).

There was no past history of rheumatic fever or any other cardiac disease; he did not indulge in the consumption of alcohol and his diet was normal. Since his condition was not improving he was referred for admission to another university hospital, where a diagnosis of significant constrictive pericarditis was made. The treatment for cardiac failure was increased with apparent good effect, and he was discharged a week later. Approximately 1 month after discharge he was readmitted because of the recurrence of symptoms of severe right heart failure. Examination revealed gross hepatomegaly, a marked pulsus paradoxus, a soft, apical mid-systolic murmur, a diastolic parasternal lift associated with instantaneous splitting of the second heart sound at the pulmonary area, and a markedly elevated jugular venous pressure exhibiting a positive hepatogastric reflux and Kussmaul's sign. Blood pressure readings were repeatedly normal. A chest radiograph showed a slightly increased cardiothoracic ratio with evidence of hilar blunting, interstitial pulmonary oedema, and bilateral pleural effusions. The ECG displayed sinus rhythm, 'low voltage and some T-wave changes'. Cardiological consultation resulted in a diagnosis of constrictive pericarditis, probably a result of tuberculosis. Antituberculosis therapy was commenced and the possibility of performing a pericardiectomy contemplated, but at follow-up there was a significant decrease in the signs of pericardial constriction. The patient was last seen at that hospital in June 1978 when he was asymptomatic with sinus rhythm, left atrial enlargement and 'diffuse T-wave inversion in keeping with pericarditis' (Fig. 1a). A chest radiograph showed a normal-sized heart with clear lung fields but small bilateral pleural effusions. The final diagnosis of 'healed tuberculous pericarditis' was then made and surgery was considered unnecessary. He was discharged to continue with antituberculosis treatment, digoxin and diuretics for a further 3-month period. An ECG taken in July 1979 demonstrated quite a dramatic change: the T waves were now upright and the only abnormality was increased left ventricular voltage in the absence of systemic hypertension (Fig. 1b).

The patient was admitted to the Intensive Coronary Care Unit (ICCU) of Tygerberg Hospital, Parowvallei, CP, on the morning of Monday 17 December 1979, having been woken up at 04h30 by sudden, severe retrosternal pain such as he had never experienced before. On examination he appeared healthy, was nor-

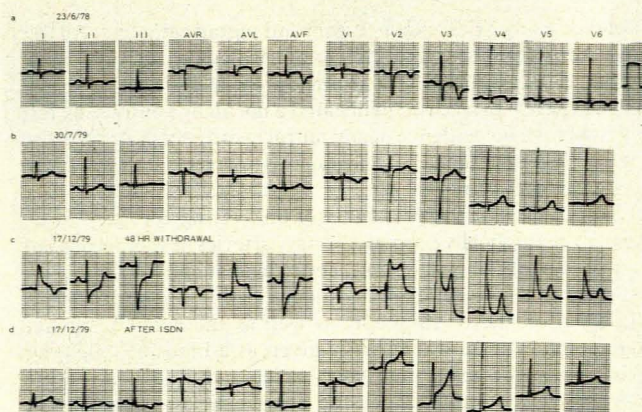


Fig. 1. Twelve-lead resting ECG recorded on full (normal) standardization (10 mm = 1 mV): a — sinus bradycardia 53 beats/min, 1st degree atrioventricular block (PR interval 0.20 second), mean QRS axis + 50°, diffuse upward-coved ST segments and asymmetric T-wave inversion; b — ST segments now normal with upright T waves, increased QRS voltage in all precordial leads; c — recorded during angina: left axis deviation of 30°, marked ST-segment elevation in anteroseptal/anterolateral leads, reciprocal ST-segment depression in inferior leads; d — recorded after administration of sublingual isosorbide dinitrate and relief of angina, mean QRS axis now normal, some early ventricular repolarization in anteroseptal leads.

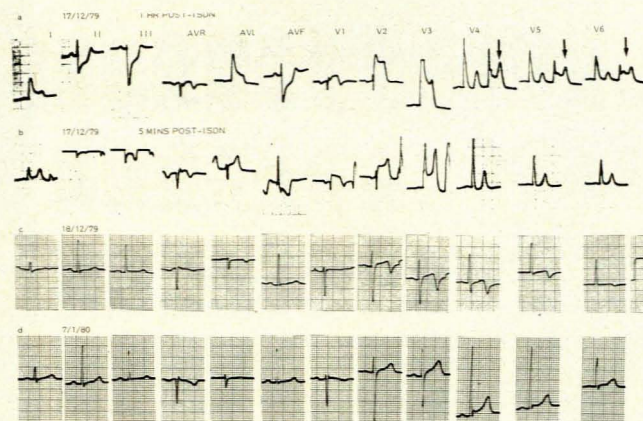


Fig. 2. Twelve-lead resting ECG recorded on full (normal) standardization (10 mm = 1 mV): a — recurrence of ST-segment changes, unifocal ventricular extrasystoles (arrowed) in leads V4-V6 portray significant ST-segment elevation not revealed in sinus complexes; b — after sublingual isosorbide dinitrate and relief of angina. Less severe ST-segment displacement; c — deep asymmetrical T-wave inversion in anteroseptal/anterolateral leads raising possibility of non-transmural myocardial infarction. Possible Grusin pattern 1 variant; d — ST segment and T waves now normal. Early ventricular repolarization and increased QRS voltage in precordial leads.

motensive and not in cardiac failure. A soft, grade 1/6 ejection systolic murmur was heard along the left sternal border with poor radiation to the axilla; a prominent fourth heart sound was present, but no clicks or diastolic murmurs could be heard. An ECG recorded on admission, while the patient was in pain, showed most impressive abnormalities (Fig. 1c). Very marked ST-segment elevation was visualized in the anteroseptal and anterolateral leads, this being as much as 10 mm in leads V2 and V3. In addition, marked reciprocal ST-segment depression was present in standard leads II, III and aVF, but no Q waves could be seen. There was left axis deviation of 30°. The diagnosis of possible hyperacute anteroseptal/anterolateral myocardial infarction or coronary artery spasm with severe transmural myocardial ischaemia was made. He was immediately given sublingual isosorbide dinitrate; within a few minutes the retrosternal pain subsided and a repeat resting ECG demonstrated a remarkable change (Fig. 1d). There was no longer any ST-segment elevation, apart from some early ventricular repolarization in the anteroseptal/anterolateral leads. A diagnosis of transient severe transmural myocardial ischaemia secondary to significant vasospasm of the left coronary artery (LCA) was then made, and was thought to have been provoked by NG withdrawal. Frequent sublingual isosorbide dinitrate, as well as the oral preparation was prescribed, and heparin was also given.

Within about an hour of his chest pain having subsided he again complained of severe retrosternal pain associated with palpitations, sweating and dyspnoea. A further resting ECG demonstrated recurrence of significant ST-segment elevation and depression changes as in the initial episode. However, several unifocal ventricular extrasystoles were also recorded during chest pain, with marked ST-segment elevation in leads V4-V6 not evident in the sinus complexes (Fig. 2a). The patient was given more sublingual isosorbide dinitrate with prompt relief of pain as well as gradual subsidence of the ST-segment changes (Fig. 2b). Treatment with oral nifedipine 10 mg 3 times daily was commenced. On the following day an ECG (Fig. 2c) showed deep asymmetrical T-wave inversion in the anteroseptal and anterolateral leads, raising the possibility of acute non-transmural myocardial infarction. However, daily ECGs remained unchanged and serial enzyme estimations failed to show any elevation to support this diagnosis. Baseline haematological and biochemical investigations were within normal limits.

Serological tests for syphilis were negative, as were investigations for a collagen disorder. A chest radiograph revealed a normal cardiac silhouette and clear lung fields. Ventricular ectopic activity ceased and the patient had no further chest pain. In view of the electrocardiographic findings a ^{99m}Tc pyrophosphate scan ('hot-spot scan') was carried out on the 5th day of hospitalization, but this failed to establish a diagnosis of infarction; a repetition on the 8th day again did not show an increase in isotope uptake. M-mode echocardiography excluded a possible mitral valve prolapse (Barlow's syndrome), as well as hypertrophic obstructive cardiomyopathy. Left ventricular function was also within normal limits. The patient was discharged on 24 December 1979 with a diagnosis of coronary vasospasm due to industrial NG withdrawal, and the remaining T-wave changes seen on the ECGs were attributed to the 'normal variant pattern' encountered in the Black population.

Therapy with isosorbide dinitrate 10 mg 3 times daily and nifedipine at the same dosage was continued, and the patient was withdrawn from exposure to NG. On 7 January 1980 a resting ECG showed that the previously inverted T waves were now upright; the only abnormality was increased voltage over the precordial leads (Fig. 2d). The patient went to his place of employment a few days later (10 January), complaining of constricting left-sided chest pain radiating down his left arm. He was immediately given sublingual isosorbide dinitrate 5 mg, with rapid relief. After this emergency treatment an ECG was taken (Fig. 3a), but proved to be no different from that taken a few days previously. It was then decided to readmit the patient to the ICCU at Tygerberg Hospital on 11 January for observation. The only abnormal finding was a persistent soft ejection systolic murmur at the lower left sternal border. Daily resting ECGs showed no change. A submaximal treadmill effort test demonstrated no myocardial ischaemia, no arrhythmias and no angina. In view of the uncertainty of the underlying pathophysiology it was decided to undertake full cardiac catheterization. The nitrate and nifedipine medication was not discontinued for fear of precipitating further episodes of coronary artery spasm.

Cardiac catheterization

This procedure was undertaken on 17 January 1980. The Seldinger technique via the right femoral artery and vein was

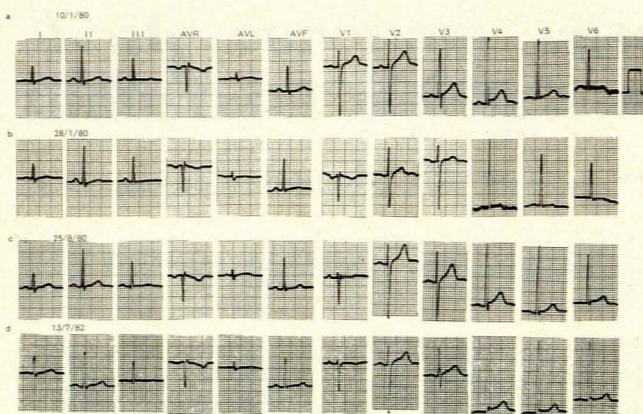


Fig. 3. Twelve-lead resting ECG recorded on full (standard) standardization (10 mm = 1 mV): a — after relief of angina with sublingual isosorbide dinitrate, tracing similar to that seen in Fig. 2d; b — precordial T waves flatter than seen on 10 January, still increased QRS voltage in precordial leads; c — precordial T waves now taller than seen on 28 January; d — most recent tracing showing early repolarization and increased QRS voltage in precordial leads.

employed using 7F Goodale-Lubin and pigtail catheters. All the intracardiac pressures and indices of cardiac contractility were normal. A left ventricular cine angiogram in the right anterior oblique (RAO) projection delineated a normally contracting left ventricle with no evidence of any mitral insufficiency or prolapse (Fig. 4). Selective coronary angiography demonstrated that both the right coronary artery (RCA) (Fig. 5) and the LCA (Fig. 6) were normal. In view of the possibility of underlying coronary vasospasm in anatomically normal coronary arteries, it was decided to carry out an ergonovine (ergometrine) maleate provocation test. A 12-lead ECG was set up and standard lead II and lead V2 were monitored on the oscilloscope, as well as the aortic pressure. Ergonovine maleate was initially given as a bolus of 0,025 mg injected into the main pulmonary artery; 12-lead ECGs were recorded every minute. Since the patient did not complain of angina and there were no features of myocardial ischaemia on the ECGs, a further bolus of ergonovine 0,025 mg was injected 4 minutes after the initial injection. The provocative drug was then administered every 4 minutes at doses of 0,05 mg, 0,05 mg, 0,10 mg and 0,15 mg to a total dose of 0,40 mg. Again, there was no change on the ECG and the patient did not experience angina. Repeat cine angiograms of the LCA (Fig. 7) and RCA (Fig. 8)

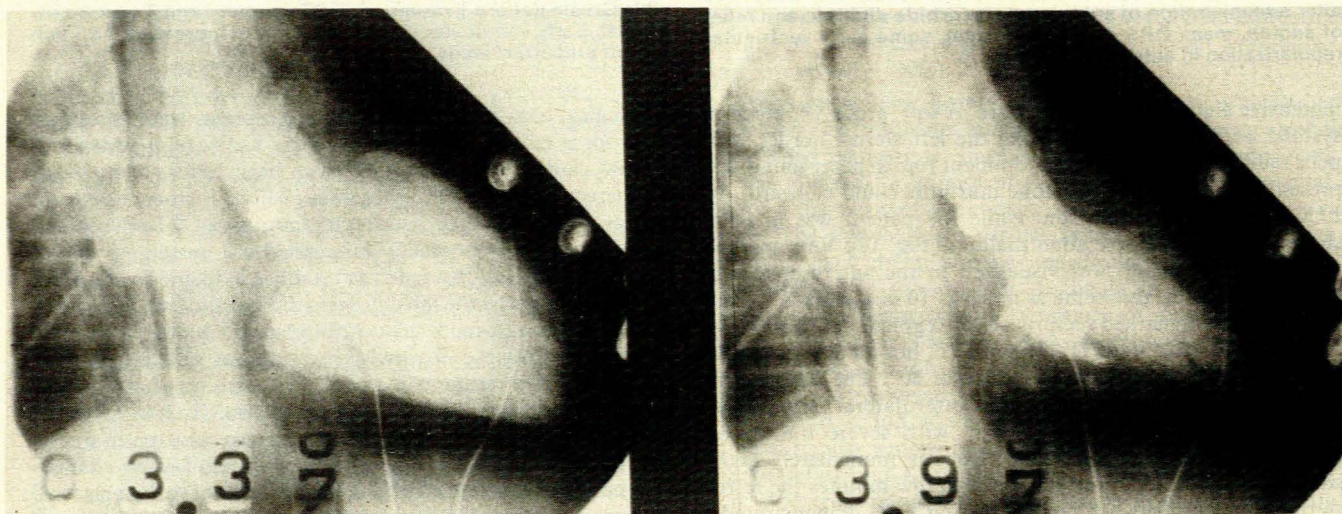


Fig. 4. Left ventricular cine angiograms in RAO projection showing normal contractility and mitral valve: a — left ventricle in end-diastole; b — left ventricle in end-systole.

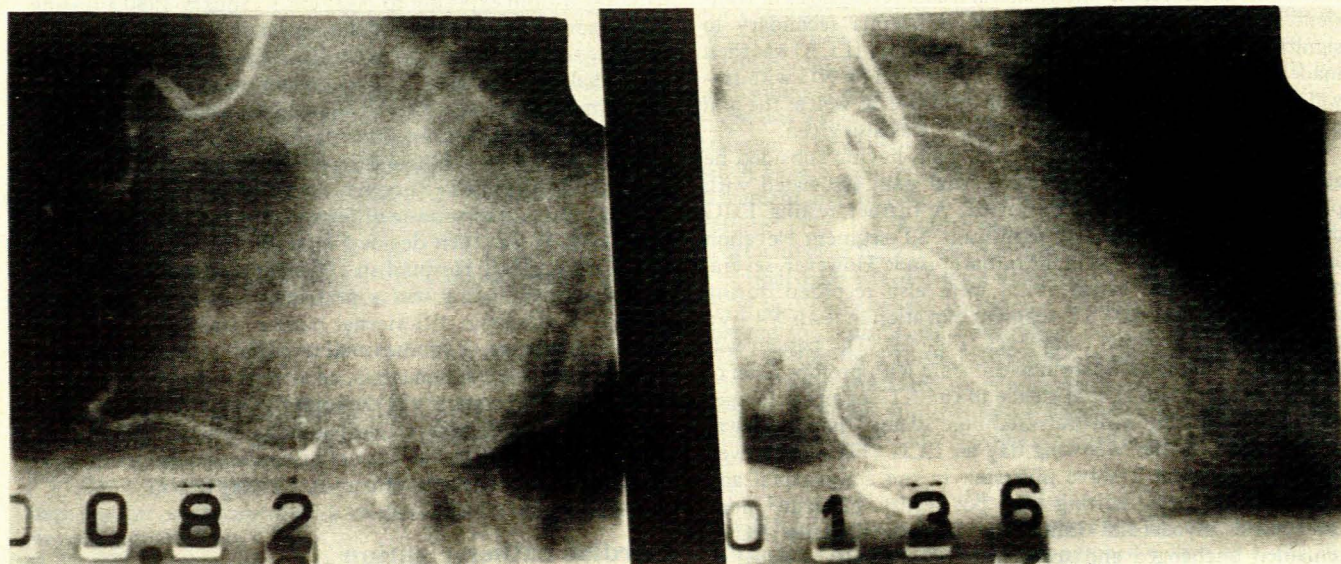


Fig. 5. Before ergonovine (ergometrine) maleate provocation. RCA cine angiograms in the (a) left anterior oblique (LAO) and (b) RAO views. The vessel is dominant and normal.

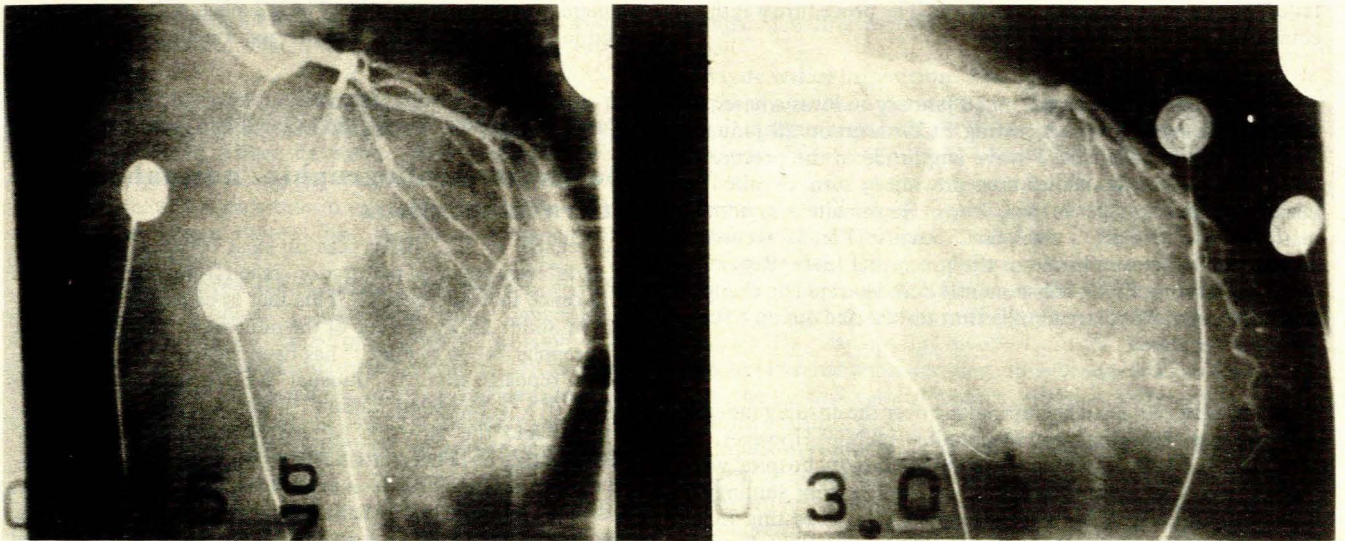


Fig. 6. Before ergonovine (ergometrine) maleate provocation. LCA cine angiograms in the (a) LAO and (b) RAO views. Normal vessels are seen.

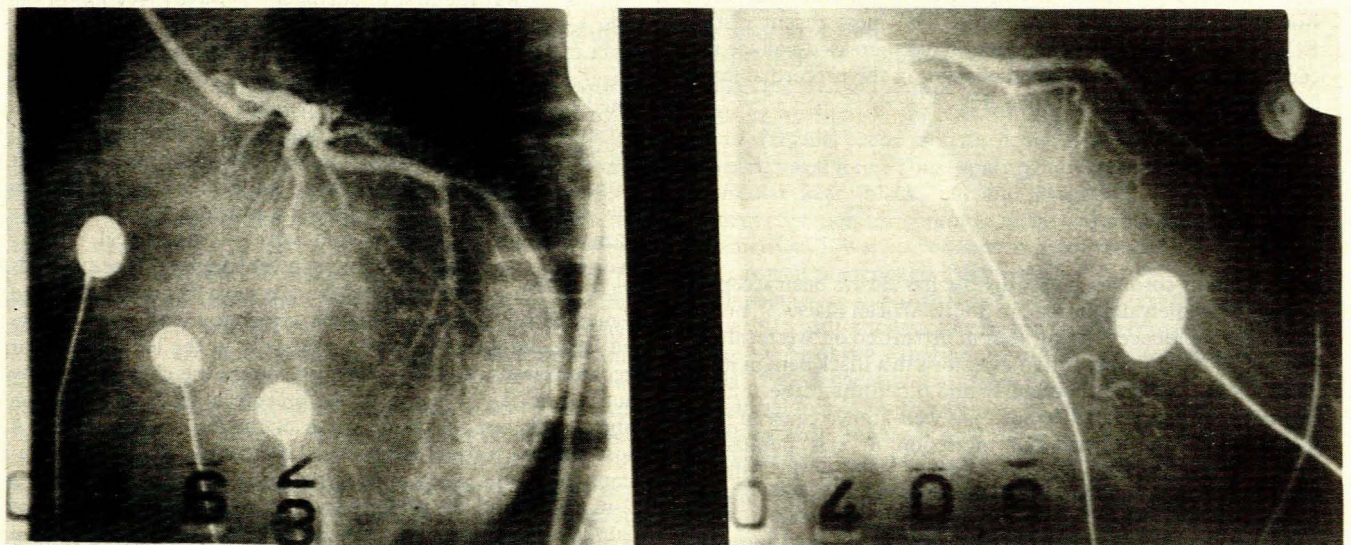


Fig. 7. After ergonovine maleate provocation. LCA cine angiograms in the (a) LAO and (b) RAO views. No coronary vasospasm could be provoked.

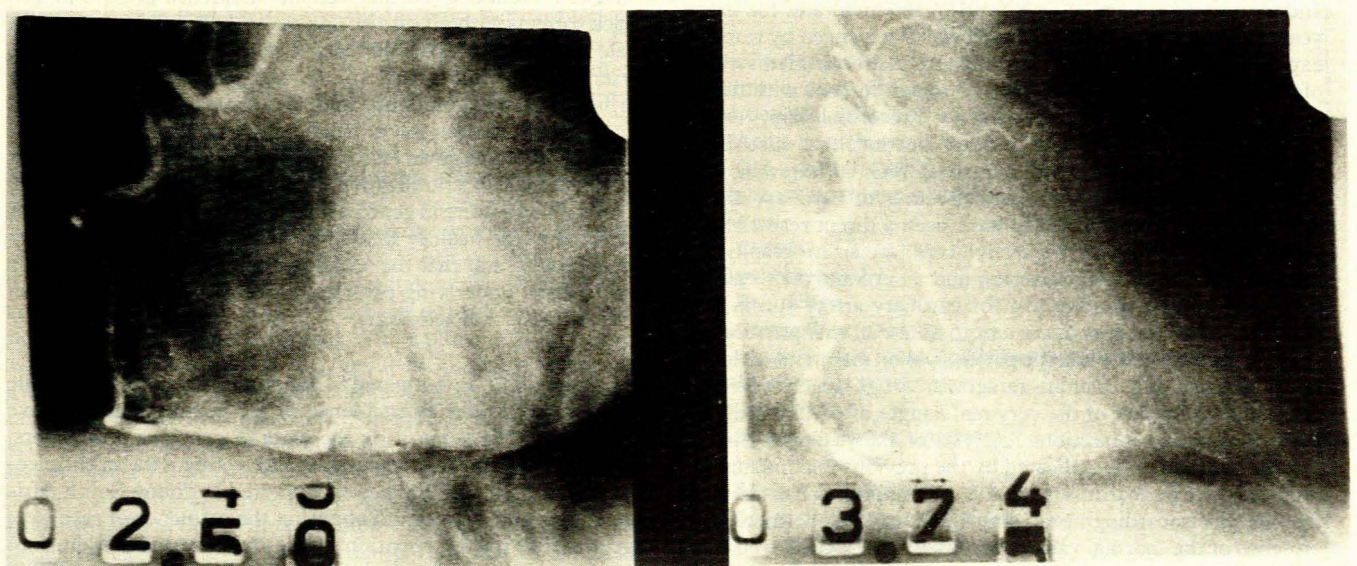


Fig. 8. After ergonovine maleate provocation. RCA cine angiograms in the (a) LAO and (b) RAO views. No coronary vasospasm could be provoked.

failed to document coronary vasospasm. The procedure was then completed without complication.

The patient was discharged on 18 January and was advised to continue his medication. A resting ECG taken on 28 January (Fig. 3b) showed that the T-wave amplitude in the precordial leads was now much smaller than previously seen, despite the increased QRS voltage in these leads. He remained asymptomatic and a routine ECG taken on 25 August (Fig. 3c) recorded T waves of larger amplitude in the precordial leads. Repeated 'checking' resting ECGs subsequently demonstrated no change. A routine submaximal treadmill effort test carried out on 8 June 1981 was negative.

The patient remained asymptomatic over the ensuing months and continued working away from industrial NG. However, on 17 November 1981 he was admitted to the factory hospital with severe precordial pain radiating down the left arm; sublingual isosorbide dinitrate 5 mg gave effective relief. A resting ECG showed no change from that taken on 25 August 1980. Several days of hospitalization ensued with no further chest pain, serial ECGs showing no new features. Since that episode the patient has continued to remain asymptomatic on a combination of isosorbide dinitrate and nifedipine. The most recent resting ECG taken (13 July 1982) demonstrated increased voltage and early ventricular repolarization changes in the precordial leads, but nothing else of significance (Fig. 3d).

Discussion

Atheromatous coronary artery disease has always been accepted as being extremely uncommon in South African Blacks,¹⁻⁵ but an increasing incidence is being seen in urbanized or 'westernized' Blacks.⁶ The symptom of angina pectoris in a Black patient must therefore be considered seriously and a definite cause sought. Syphilitic coronary ostial stenosis is a well-known cause of both angina and acute myocardial infarction in this population group.⁷ Other non-atheromatous causes such as the collagenoses^{8,9} and aortic arteritis (Takayasu's disease¹⁰) must also be considered.

The explosives industry is particularly important in this country, especially since mining is such a dominant economic force. Industrial NG is usually employed in this field and for many years 'withdrawal' symptoms have been experienced by workers exposed to industrial NG.¹¹ The most frequent complaint is that of 'Monday morning headache',^{12,13} which follows withdrawal from NG over the previous weekend. Precordial pain,¹⁴ acute myocardial infarction¹⁵ and sudden death¹⁶ have also been thought to be secondary to industrial NG withdrawal. Our patient presented with the classic features of coronary artery spasm, seriously considered to have been a direct result of the withdrawal syndrome; yet selective coronary arteriography delineated normal coronary arteries, and an ergonovine (ergometrine) maleate provocative test for coronary artery spasm was negative. However, it is important to note that this provocative measure was applied while the patient was on maintenance long-acting nitrates and calcium-antagonist drugs which were not discontinued for fear of the very real danger of precipitating an acute myocardial infarction. Analysis of the patient's clinical picture was further complicated by the previous documentation of constrictive pericarditis (probably tuberculous in nature) with ensuing electrocardiographic abnormalities. Furthermore, the presence of the 'normal variant pattern' on the ECGs, well established in Black South Africans, made unravelling of the clinical

problem even more intriguing. These aspects will now be considered in more detail, as will the therapeutic implications.

The electrocardiographic 'normal variant pattern' in the Black

As regards ECGs, differences do exist between races, sexes and at different stages of maturation (taken from infancy through adolescence to senescence).¹⁷ This fact is of particular importance in South Africa in view of the multiracial population. The 'early repolarization variant'¹⁸ has been variously termed: 'premature repolarization',¹⁹ 'unusual RT-segment deviation',²⁰ 'normal RS-T elevation variant',²¹ 'early repolarization syndrome',²² and the 'juvenile pattern of adult Negro males'.²³ These changes have been attributed to such conditions as excessive vagotonia (such as is seen in athletes, i.e. 'the athletic heart syndrome'), infantile bodily habitus, the electrical position of the heart, some metabolic factors and an increase in myocardial mass.

Brink^{24,25} was the first to document T-wave inversion in the right ventricular (V1 - V3) precordial leads (reporting an incidence of 5% in healthy Black adults), and attributed these repolarization changes to excessive vagotonia. Grusin²⁶ then published his findings in 159 Black patients without heart disease and in 50 healthy Black nurses; some 63% of the former group and 20% of the latter exhibited some form of the 'normal variant pattern'. He recognized three basic 'patterns'. The first pattern (the most common of the three) was characterized by ST-segment depression associated with asymmetrical, deeply inverted T waves, mostly in the right ventricular precordial leads (V1-V3). The second pattern (the next most frequent) consisted of marked ST-segment elevation associated with tall T waves and large-amplitude R waves primarily in the left ventricular precordial leads (V4-V6). The third pattern was characterized by rounded or 'flat' T waves in the precordial leads. Some of his subjects displayed a combination of the first two patterns. A most striking feature documented by Grusin was the spontaneous fluctuation seen to occur in many of his patients over a 12-month period. He preferred to incriminate some influence of malnutrition or a persistence of the 'juvenile pattern' rather than to attribute this to auto-immune nervous system imbalance.

Powell²⁷ found a 'normal variant' incidence of 39% in 100 Black patients without cardiac disease, in 22% of 50 healthy Black male nurses and 37% of 100 Black males suffering from amoebic dysentery. He found that the second pattern previously described by Grusin predominated, and concluded that the cause of the variant pattern was a 'biochemical change in the myocardial cell due to unknown factors'. Woods and Laurie²⁸ were most critical of Grusin's publication, mainly because only about 20% of his subject's 'were in good health'. These workers claimed that the ECG of the healthy Black was similar to that seen in other racial groups, and that the 'Grusin normal variant' was usually due to some underlying cardiac abnormality, apart from those cases of functional aetiology.

Fleishman^{29,30} investigated 573 apparently healthy Black male subjects and found an incidence of ST-segment and T-wave changes of 23%, supporting the work of previous researchers. Walker and Walker¹⁷ documented interesting data on the electrocardiographic differences encountered in young South African Blacks and Whites, highlighting the influence of race, sex, age and the state of nutrition. They confirmed the findings of Grusin and noted a general diminution in the degree of ST-T

segment changes with increasing age. Furthermore, an unduly bad prognosis was not related to the existence of these variant patterns.

Reiley *et al.*³¹ carried out a similar survey in the USA, and found the greatest incidence of the variant among Black males, who were also noted to have the most marked increase in precordial QRS amplitude. A smaller incidence was found in White men, but this was higher than those found in Black or White women. The variant pattern has also been documented in healthy East Africans.³²

Our patient displayed a combination of ST-segment elevation and intermittent biphasic T waves and tented precordial T waves, as well as deep, asymmetrical T-wave inversion in the precordial leads and markedly increased precordial QRS voltage. Thus, a combination of Grusin's pattern 1 and pattern 2 was encountered. The difficulty in interpreting the electrocardiographic changes in this patient in the light of his previous history will be discussed shortly.

ECG tracings mimicked by the 'normal variant pattern' (Table I)

Acute pericarditis. The spectrum of electrocardiographic changes caused by various forms of pericarditis are of particular importance in the differential diagnosis. Acute pericarditis, especially during its very early phase (said to be caused by an epimyocarditis³³⁻³⁵) when seen on ECGs, has proved the most difficult to distinguish from the normal variant pattern, and these two conditions have been claimed to be indistinguishable.^{21,36,37} However, differentiation has been aided by the fact that the changes caused by pericarditis tend to evolve over a period of hours, days or even weeks,^{38,39} whereas those of the normal variant can last many years, albeit with numerous fluctuations. The injury current of the former condition is thought to be secondary to subepicardial inflammation of varying duration. Spodick³³ was the first to demonstrate that the ST-T wave alterations always occurred in the limb leads in acute pericarditis, but that in some 30% of the normal variants these changes were confined to the precordial leads. He also showed that ST-segment elevation in lead V6 and depression in lead V1 were far commoner in acute pericarditis, and that the two conditions could be further differentiated by vector cardiographic analysis. Ginzton and Laks⁴⁰ attempted to distinguish acute pericarditis from the normal variant pattern by quantitative electrocardiographic analysis. These researchers found that an ST/T wave ratio of ≥ 0.25 in lead V6 was specific for acute pericarditis, and that if this lead was not available the same ratio value in leads V4, V5 and I was most suggestive of this condition. Furthermore, a T-wave amplitude of ≤ 0.3 mV in lead V6 was highly suggestive of acute pericarditis.

Chronic constrictive pericarditis. The T-wave deviations in this condition are usually widespread, and consist of either flattened, upright T waves or inverted T waves which are either deep or of small amplitude. These findings would be consistent with those found on the initial ECG of our patient (Fig. 1a). However, that was the only ECG tracing which revealed such extensive changes, and probably indicated that the patient had, most likely, almost passed the constrictive phase of his presumed tuberculous pericarditis. In fact, serial ECGs taken before and after radical pericardiectomy for chronic constrictive pericarditis have demonstrated the persistence of diffuse T-wave inversion despite normal haemodynamic findings.⁴¹ These T-wave changes may be caused by myocardial atrophy, myocardial fibrosis,⁴² cardiac constriction,⁴³ myocardial calcification or a reduction in myocardial blood flow.⁴⁴ Lewis *et al.*⁴⁵ differentiated the electrocardiographic changes of constrictive pericarditis from 'Bantu cardiomyopathy'; the former had a typical ST-T wave pattern

compared with a pseudo-myocardial infarction pattern in the latter.

Myocardial infarction. The hyperactive phase of an antero-septal myocardial infarction may be confused with the ST-T wave changes seen in the Grusin pattern 1 variant. An acute non-transmural antero-septal infarction can likewise be confused with the Grusin pattern 2 variant. Previous non-transmural antero-septal and lateral myocardial infarctions can quite easily mimic the third Grusin pattern of the normal variant.

Myocarditis. This condition, irrespective of the cause, can quite easily be mistaken for a Grusin pattern 3 variant. The picture is further complicated by the frequent existence of an associated pericarditis (i.e. myopericarditis). However, the Black patient often has an underlying sinus bradycardia in association with the normal variant pattern, whereas tachycardia is usual with myocarditis.

Cardiomyopathy. The wide spectrum of restrictive,⁴⁶⁻⁴⁸ congestive (dilated, cryptogenic, idiopathic) and hypertrophic (obstructive⁴⁹ and non-obstructive^{50,51}) cardiomyopathy must be considered in the differential diagnosis of the normal variant pattern, but the clinical characteristics usually allow for quite accurate diagnosis. Left ventricular hypertrophy secondary to systemic hypertension may be especially problematic when 'decapitated' hypertension gives rise to dilated cardiomyopathy or is associated with it.

Athletic heart syndrome. Virtually identical repolarization changes are seen in the athlete.^{52,53} These features are thought to be an expression of the electrophysiological and anatomical effects of regular exercise on the heart, especially that induced by increased vagal tone. Thus, apart from varying degrees of atrio-ventricular heart block, tall and peaked T waves with ST-segment elevation are common in the antero-septal leads. Deep asymmetrical T-wave inversions may be evident in all precordial leads, as well as increased QRS voltage.

Miscellaneous conditions. The hyperventilation syndrome⁵⁴ is a well-known cause of ventricular repolarization alterations, as has been experienced in the interpretation of stress ECGs. Hyperkalaemia, apart from mimicking acute antero-septal myocardial infarction,⁵⁵ may well be confused with the normal variant pattern. Acute cor pulmonale could present difficulty in differentiation from the Grusin pattern 1 normal variant. Likewise, the electrocardiographic manifestations of acute pulmonary embolism and primary pulmonary hypertension⁵⁶ could be mimicked, apart from the obvious changes in P-wave morphology.

TABLE I. ECG TRACINGS MIMICKED BY THE 'NORMAL VARIANT PATTERN'

1. Acute pericarditis
2. Chronic constrictive pericarditis
3. Myocardial infarction
 - Acute non-transmural
 - Old non-transmural
4. Myocarditis (myopericarditis)
 - Acute
 - Chronic
5. Cardiomyopathy
 - Restrictive
 - Congestive (dilated)
 - Hypertrophic (obstructive and non-obstructive)
6. Athletic heart syndrome
7. Miscellaneous
 - Hyperventilation syndrome
 - Hyperkalaemia
 - Acute cor pulmonale
 - Acute pulmonary embolism
 - Primary pulmonary hypertension

Pathophysiology of coronary vasospasm in industrial NG withdrawal syndrome

The pathophysiological concept of coronary artery spasm was revived during the 1970s,^{57,58} and its importance in atherosclerotic coronary artery disease has been emphasized by several researchers.⁵⁹⁻⁶¹ More frequent use of selective coronary arteriography in patients presenting with chest pain, as well as the fairly recent introduction of the ergonovine (ergometrine) maleate provocation test to detect possible underlying coronary vasospasm, has increased the frequency of its documentation as well as its firm acceptance. It is therefore not surprising that this mechanism has been postulated as being of vital importance in the spectrum of non-atheromatous coronary artery disease reported in employees working with explosives.

NG alone, or in combination with ethylene glycol dinitrate (nitroglycol), has been utilized in the manufacturing of dynamite for several decades. This usually involves open techniques, and a substantial level of nitrates is therefore detected in the surrounding atmosphere. Nitrates are particularly volatile and thus easily absorbed via the skin and lungs, especially if adequate protective clothing is not worn. An 'acute toxic response' is therefore most common, and is characterized by such symptoms as headache,^{12,13} orthostatic hypotension, palpitations, gastro-intestinal disturbance, a fall in diastolic blood pressure and rise in systolic pressure. This clinical picture is usually present for approximately a week. Once the subject has been exposed to NG for a period of longer than 12 months a different 'adaptation' response, consisting of a rise in diastolic and a fall in systolic blood pressure with resultant smaller pulse pressure and accompanying bradycardia, occurs. This is the period in the employee's life when a 'withdrawal response' may occur.¹¹

Some 30 years ago the effects of withdrawal from industrial NG was first documented in the German, Swedish and Italian literature. Symptoms of severe angina not related to exertion or emotion were commonly encountered within 1 - 3 days of non-exposure, and relief was subsequently experienced upon re-exposure. Sudden death was far less common.¹⁶ Another typical clinical presentation was that of acute myocardial infarction, autopsy revealing no evidence of significant obstructive coronary atherosclerosis. In an attempt to explain the withdrawal reaction various theories have been proposed. The suggestion of alternating coronary vasodilation (occurring during periods of exposure) and vasoconstriction (during periods of withdrawal), involving the nutrient arterioles and resulting in deposition of hyaline material in the arterial wall was put forward. Another theory was that of severe peripheral vasodilation giving rise to cardiovascular collapse due to inadequate venous return. However, the most attractive postulate, first proposed by Carmichael and Lieben,¹⁶ would appear to be that of acute coronary artery spasm. Lange *et al.*¹⁵ were the first to document spontaneous coronary vasospasm by coronary arteriography during a period of withdrawal. Their patient also responded quite dramatically to the sublingual administration of nitrates, although no electrocardiographic features of vasospasm were noted. A further 8 patients had symptoms of non-atheromatous ischaemic heart disease, 1 dying suddenly; a further 4 underwent selective coronary angiography. One of the subjects who underwent coronary angiography developed complete left bundle-branch block and had a late sudden death.

Klock¹⁴ was the second to demonstrate spontaneous vasospasm of the RCA at the time of coronary arteriography in a patient who developed frequent episodes of non-exertional angina during the withdrawal period. This vasospasm was rapidly relieved by sublingual nitrates, but again no electrocardiographic features of myocardial ischaemia could be detected. The patient had several more episodes of angina after cardiac catheterization, but his condition stabilized on high doses of isosorbide dinitrate. In common with all the previous affected

employees, his angina decreased in frequency with removal from the explosives environment.

Hogstedt *et al.*⁶² first utilized 48-hour ambulatory ECGs (Holter monitoring) on explosives workers, attempting to demonstrate an increasing incidence of dangerous ventricular arrhythmias during the withdrawal period; this would explain the symptoms as due to acute myocardial ischaemia on the basis of coronary vasospasm. They were only able to detect ventricular tachycardia on a Monday morning in a single worker, and some ventricular ectopic beats in both control workers and exposed workers. In addition, they postulated that increased sympathetic activity was more pronounced during the withdrawal period, and that the myocardium was more vulnerable to ventricular fibrillation secondary to coronary vasospasm. Thus, a hypothesis of the cause of sudden death in explosives workers was made more attractive. Nevertheless, it has been shown that sudden cardiac death in men not known to have underlying cardiac disease is statistically more frequent on a Monday morning.⁶³

Our patient almost certainly suffered from the NG withdrawal syndrome as evidenced by severe intermittent non-exertional angina associated with electrocardiographic features of transient myocardial ischaemia, relieved by nitrate therapy. Coronary angiography gave the usual negative results. The fact that the patient was taking oral nitrates and nifedipine while undergoing coronary angiography and the ergonovine maleate provocative test may well have accounted for the fact that spontaneous or induced coronary vasospasm was not documented.⁶⁴ As far as we are aware, this is the first time that the ergonovine maleate provocative test has been employed in the industrial NG withdrawal syndrome.

A further interesting finding was the occurrence of ST-segment elevation in ventricular ectopic beats (Fig. 2a) but not in sinus beats. A similar finding has been documented by Schamroth⁶⁵ in a patient experiencing episodes of variant (Prinzmetal's) angina. Several authors have previously reported on this characteristic in the diagnosis of acute myocardial infarction.⁶⁶

Therapeutic implications

It would seem clear that any subject who has underlying ischaemic heart disease should not be exposed to industrial NG. The intriguing possibility of the use of prophylactic oral isosorbide dinitrate administration during the withdrawal period cannot be ignored entirely, much as this drug is used in the prophylaxis of angina pectoris due to atherosclerotic coronary artery disease. Furthermore, if coronary vasospasm is the mechanism of this withdrawal syndrome, administration of long-term prophylactic calcium-blocking drugs may entirely prevent angina at rest, acute myocardial infarction and sudden death in this specific working population.

A further important implication of the experience derived from the industrial NG withdrawal syndrome concerns the treatment of ischaemic heart disease. Much has been written about the dangers of abrupt withdrawal of propranolol in patients given this drug for angina pectoris. Perhaps sudden cessation of the commonly prescribed oral long-acting nitrates may be just as potentially lethal; prescribing doctors should probably warn their patients of this danger. Sudden death is almost certainly the most common and frustrating single presentation in the spectrum of symptomatic atherosclerotic ischaemic heart disease, and its incidence might well be dramatically reduced by applying such basic clinical principles in the management.

We wish to sincerely thank Miss H. Weymar of the Cardiology Unit, Tygerberg Hospital, for preparing the manuscript and electrocardiographic illustrations. Sister P. Goldsmith of the Department of Occupational Medicine, AECL Ltd, Somerset West, is thanked

for her invaluable technical assistance. Appreciation is also shown towards Mrs I. Bickle of the Department of Photography, University of Stellenbosch Medical School, for her painstaking preparation of the photographs. Finally, due appreciation is shown towards Dr C. Vivier, Chief Medical Superintendent of Tygerberg Hospital, for permission to publish.

REFERENCES

- Seftel HC. The rarity of coronary heart disease in South African Blacks. *S Afr Med J* 1978; **54**: 99-105.
- Chesler E, Mitha AS, Weir EK, Matisson RE, Hitchcock PJ. Myocardial infarction in the Black population of South Africa: coronary arteriographic findings. *Am Heart J* 1978; **95**: 691-696.
- Schire V, Uys CJ. Cardiac infarction in the Bantu. *Am J Cardiol* 1958; **2**: 453-463.
- Lowenthal MN. Coronary heart disease diagnosed as cardiomyopathy in Blacks: a report of four cases. *S Afr Med J* 1978; **53**: 948-949.
- Seedat YK, Pillay N. Myocardial infarction in the African hypertensive patient. *Am Heart J* 1977; **94**: 388-390.
- Isaacson C. The changing pattern of heart disease in South African Blacks. *S Afr Med J* 1977; **52**: 793-798.
- Scharfman WB, Wallach JB, Angrist A. Myocardial infarction due to syphilitic coronary ostial stenosis. *Am Heart J* 1950; **40**: 603-613.
- Bonfiglio TA, Botti RE, Hagstrom JWC. Coronary arteritis, occlusion, and myocardial infarction due to lupus erythematosus. *Am Heart J* 1972; **83**: 153-158.
- Przybojewski JZ. Polyarteritis nodosa in the adult: report of a case with repeated myocardial infarction and review of cardiac involvement. *S Afr Med J* 1981; **60**: 512-518.
- Cipriano PR, Silverman JF, Perlroth MG, Griep RB, Wexler L. Coronary arterial narrowing in Takayasu's aortitis. *Am J Cardiol* 1977; **39**: 744-750.
- Lund RP, Häggendal J, Johnsson G. Withdrawal symptoms in workers exposed to nitroglycerine. *Br J Indust Med* 1968; **25**: 136-138.
- Trainor DC, Jones RC. Headaches in explosive magazine workers. *Arch Environ Health* 1966; **12**: 231-234.
- McGuinness BW, Harris EL. 'Monday head': an interesting occupational disorder. *Br Med J* 1961; **2**: 745-747.
- Klock JC. Nonocclusive coronary disease after chronic exposure to nitrates: evidence for physiologic nitrate dependence. *Am Heart J* 1975; **89**: 510-513.
- Lange RL, Reid MS, Tresch DD, Keelan MH, Bernhard VM, Coolidge G. Nonatheromatous ischaemic heart disease following withdrawal from chronic industrial nitroglycerine exposure. *Circulation* 1972; **46**: 666-678.
- Carmichael P, Lieben J. Sudden death in explosive workers. *Arch Environ Health* 1963; **7**: 424-439.
- Walker ARP, Walker BF. The bearing of race, sex, age, and nutritional state on the precordial electrocardiogram of young South African Bantu and Caucasian subjects. *Am Heart J* 1969; **77**: 441-459.
- Alimurung BN, Gilbert CA, Felner JM, Schlant RC. The influence of early repolarization variant on the exercise electrocardiogram: a correlation with coronary arteriograms. *Am Heart J* 1980; **99**: 739-745.
- Gottschalk CW, Craig E. A comparison of the precordial S-T and T waves in the electrocardiogram of 600 healthy young Negro and White adults. *South Med J* 1956; **49**: 453-457.
- Chelton LG, Burchell HB. Unusual RT segment deviation in electrocardiograms of normal persons. *Am J Med Sci* 1955; **230**: 54-60.
- Wasserburger RH, Alt WJ, Lloyd C. The normal RS-T segment elevation variant. *Am J Cardiol* 1961; **8**: 184-192.
- Kambara H, Phillips J. Long-term evaluation of early repolarization syndrome (normal variant RS-T segment elevation). *Am J Cardiol* 1976; **38**: 157-166.
- Wasserburger RH. Observations on the 'juvenile pattern' of adult Negro males. *Am J Med* 1955; **18**: 428-437.
- Brink AJ. An investigation of factors influencing repolarization in the human heart. *S Afr J Clin Sci* 1951; **2**: 288-297.
- Brink AJ. The normal electrocardiogram in the adult South African Bantu. *S Afr J Lab Clin Med* 1956; **2**: 97-123.
- Grusin H. Peculiarities of the African's electrocardiogram and the changes observed in serial studies. *Circulation* 1954; **9**: 860-867.
- Powell SJ. Unexplained electrocardiograms in the African. *Br Heart J* 1959; **21**: 263-268.
- Woods JD, Laurie W. The electrocardiogram of the South African Bantu. *Circulation* 1959; **19**: 251-256.
- Fleishman SJ. Observations of the electrocardiogram of the apparently healthy African (M. D. thesis). Johannesburg: University of the Witwatersrand, 1962.
- Fleishman SJ. The normal electrocardiogram in the African. *S Afr Med J* 1965; **39**: 177-179.
- Reiley MA, Su JJ, Guller B. Racial and sexual differences in the standard electrocardiogram in Black vs White adolescents. *Chest* 1979; **75**: 474-480.
- Somers K, Rankin AM. The electrocardiogram in healthy East African (Bantu and Nilotic) men. *Br Heart J* 1962; **24**: 542-548.
- Spodick DH. Differential characteristics of the electrocardiogram in early repolarization and acute pericarditis. *N Engl J Med* 1976; **295**: 523-526.
- Surawicz B, Lasseter KC. Electrocardiogram in pericarditis. *Am J Cardiol* 1970; **26**: 471-474.
- Spodick DH. Pathogenesis and clinical correlations of electrocardiographic abnormalities of pericardial disease. *Cardiovasc Clin* 1977; **8**: 201-248.
- Parisi AF, Beckmann CH, Lancaster MC. The spectrum of ST-segment elevation in the electrocardiogram of healthy adult men. *J Electrocardiol* 1971; **4**: 137-144.
- Goldman MJ. RS-T segment elevation in mid and left precordial leads as a normal variant. *Am Heart J* 1953; **46**: 817-820.
- Spodick DH. Diagnostic electrocardiographic sequences in acute pericarditis: significance of PR segment and PR vector changes. *Circulation* 1973; **48**: 575-580.
- Spodick DH. Differential diagnosis of acute pericarditis. *Prog Cardiovasc Dis* 1971; **14**: 192-209.
- Ginzton LE, Laks MM. The differential diagnosis of acute pericarditis from the normal variant: new electrocardiographic criteria. *Circulation* 1982; **65**: 1004-1009.
- Avgoustakis D, Lazarides D, Athanasiadis D, Michaelides G. The electrocardiogram in constrictive pericarditis before and after radical pericardiectomy. *Chest* 1970; **57**: 460-467.
- Hull E. The electrocardiogram in pericarditis. *Am J Cardiol* 1961; **7**: 21-32.
- Scheepers GWH. Tuberculous pericarditis. *Am J Cardiol* 1962; **9**: 248-276.
- Burwell CS. Constrictive pericarditis. *Circulation* 1957; **15**: 161-163.
- Lewis BS, Van der Horst RL and Gotsman MS. Diagnostic electrocardiographic patterns in Bantu cardiomyopathy and constrictive pericarditis. *S Afr Med J* 1971; **45**: 1110-1118.
- Benotti JR, Grossman W, Cohn PF. Clinical profile of restrictive cardiomyopathy. *Circulation* 1980; **61**: 1206-1212.
- Przybojewski JZ, Daniels AR, Van der Walt JJ. Primary cardiac amyloidosis: a case presentation. *S Afr Med J* 1980; **57**: 774-780.
- Przybojewski JZ, Daniels AR, Van der Walt JJ. Primary cardiac amyloidosis: a review of the literature. *S Afr Med J* 1980; **57**: 831-837.
- Savage DD, Seides SF, Clark CE et al. Electrocardiographic findings in patients with obstructive and nonobstructive hypertrophic cardiomyopathy. *Circulation* 1978; **58**: 402-408.
- Chen CH, Nobuyoshi M, Kawai C. ECG pattern of left ventricular hypertrophy in nonobstructive hypertrophic cardiomyopathy: the significance of the mid-precordial changes. *Am Heart J* 1979; **97**: 687-695.
- Przybojewski JZ, Hoffman H, de Graaf AS et al. A study of a family with inherited disease of cardiac and skeletal muscle. Part I: Clinical, electrocardiographic, echocardiographic, haemodynamic, electrophysiological and electron microscopic studies. *S Afr Med J* 1981; **59**: 363-373.
- Lichtman J, O'Rourke RA, Klein A, Karliner JS. Electrocardiogram of the athlete: alterations simulating those of organic heart disease. *Arch Intern Med* 1973; **133**: 763-770.
- Roeske WR, O'Rourke RA, Klein A, Leopold G, Karliner JS. Non-invasive evaluation of ventricular hypertrophy in professional athletes. *Circulation* 1976; **53**: 286-292.
- Biberman L, Sarma RN, Surawicz B. T-wave abnormalities during hyperventilation and isoproterenol infusion. *Am Heart J* 1977; **81**: 166-174.
- Chawla KK, Cruz J, Kramer NE, Towne WD. Electrocardiographic changes simulating acute myocardial infarction caused by hyperkalemia: report of a patient with normal coronary arteriograms. *Am Heart J* 1978; **95**: 637-640.
- Factor SM, Reichel J. Primary pulmonary hypertension. *Am Heart J* 1980; **99**: 789-798.
- Maseri A. Pathogenetic mechanisms of angina pectoris: expanding views. *Br Heart J* 1980; **43**: 648-660.
- Conti CR, Curry RC. Coronary artery spasm and myocardial ischaemia. *Mod Concepts Cardiovasc Dis* 1980; **69**: 1-6.
- Brown BG. Coronary vasospasm: observations linking the clinical spectrum of ischaemic heart disease to the dynamic pathology of coronary atherosclerosis. *Arch Intern Med* 1981; **141**: 716-722.
- Maseri A, Chierchia S, L'Abbate A. Pathogenetic mechanisms underlying the clinical events associated with atherosclerotic heart disease. *Circulation* 1980; **62**: suppl V, 3-13.
- Hellstrom HR. Evidence in favor of the vasospastic cause of coronary artery thrombosis. *Am Heart J* 1979; **97**: 449-452.
- Hogstedt C, Söderholm B, Bodin L. 48-hour ambulatory electrocardiography in dynamite workers and controls. *Br J Indust Med* 1980; **37**: 299-306.
- Rabkin SW, Mathewson FAL, Tate RB. Chronobiology of cardiac sudden death in men. *JAMA* 1980; **244**: 1357-1358.
- Waters DD, Szlachet J, Theroux P, Dauwe F, Mizgala HP. Ergonovine testing to detect spontaneous remissions of variant angina during long-term treatment with calcium antagonist drugs. *Am J Cardiol* 1981; **47**: 179-184.
- Schamroth L. *The Electrocardiology of Coronary Artery Disease*. Oxford: Blackwell Scientific Publications, 1981: 288.
- Bisetti A, Medrano GA, Sodi-Pallares D. Ventricular premature beats in the diagnosis of myocardial infarction. *Br Heart J* 1961; **23**: 521-532.