

The outcome of relapsed and residual clubfeet treated with the Taylor Spatial Frame

BY

Dr Adriaan Hendrik Botha

DIVISION OF ORTHOPAEDIC SURGERY
DEPARTMENT OF SURGICAL SCIENCES
FACULTY OF MEDICINE AND HEALTH SCIENCES
STELLENBOSCH UNIVERSITY

Submitted for the fulfilment of the degree of MMed in Orthopaedic Surgery.

Supervisor: Dr. Jacques Du Toit
Co-Supervisor: Prof. Dr. Robert P Lamberts

May 2014
Tygerberg, Western Cape, South Africa

DECLARATION

I, **Adriaan Hendrik Botha** (student number: 13342258), hereby declare that the work on which this dissertation is based on is my original work (except where acknowledgements indicate otherwise) and that neither the whole work nor any part of it has been, is being, or will be submitted for another degree at this or any other university.

I empower the university to reproduce for the purpose of research either the whole or any portion of the contents in any matter whatsoever.

.....

Signature

Date: 1 May 2014

ACKNOWLEDGEMENTS

I would like to thank my supervisor Dr. Jacques Du Toit for his guidance and inspiration in completing this dissertation. I would also like to thank Prof. Dr. Rob Lamberts for his support in the data analyses, statistics, writing up and formatting of the thesis. Last but not least, I would like to thank Dr. Justin Harvey for his assistance with the statistical analyses.

TABLE OF CONTENTS

Declaration.....	3
Acknowledgements.....	5
Purpose of the study.....	9
Problem Definition and Hypothesis:.....	9
Introduction.....	11
Treatment of primary clubfoot.....	12
Treatment of relapsed/residual clubfeet.....	13
Non-surgical management.....	13
Surgical Treatment.....	14
Methodology:.....	19
International Clubfoot Study Group Score.....	19
Child Health Questionnaire.....	20
Treatment protocol.....	20
Statistical Analysis.....	22
Results.....	23
International Clubfoot Study Group Score.....	23
Child Health Questionnaire.....	24
Complications.....	26
Discussion.....	27
References.....	31
Appendix 1 - International Clubfoot Study Score.....	35

PURPOSE OF THE STUDY

To prove that treatment of residual and recurrent clubfoot with the Taylor Spatial Frame is a viable and effective treatment modality for this problematic patient group.

PROBLEM DEFINITION AND HYPOTHESIS:

The conclusion drawn from the literature review is that the Ponseti regime is currently the gold standard of conservative treatment for clubfeet and has a high success rate.

Relapsed or residual clubfeet however continues to provide a real challenge to the orthopaedic surgeon when it comes to correction of this complex deformity. Despite various extensive surgical procedures described for the treatment of residual or relapsed clubfeet, the ultimate goal of a pain free, mobile, plantigrade foot still continues to elude both the surgeon and the patient.

The Taylor Spatial Frame, combined with the power of modern day computer software, has enabled orthopaedic surgeons to correct complex deformities with excellent results. Complications from treatment with the Taylor Spatial Frame are also less severe and can be treated more easily. The most frequent complication encountered is that of superficial pin tract sepsis, which responds to oral antibiotics. This outcome is therefore preferable to the complications encountered with extensive surgery.

Our study hypothesis was that the Taylor Spatial Frame is an effective salvage modality for relapsed or residual clubfoot and that this treatment modality will improve quality of life in patients with minimal morbidity.

INTRODUCTION

Congenital talipes equinus varus, or clubfoot, which was first described by Hippocrates in 400 BC, is still the most common orthopaedic congenital anomaly.¹⁻⁴ This deformity is characterized by ankle equinus, hindfoot varus, forefoot adduction and supination.^{5 2,6-8} (Figure 1)

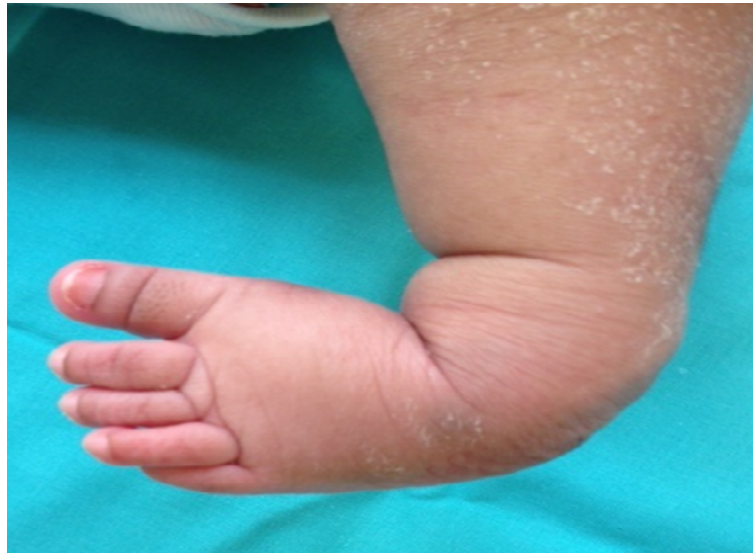

Figure 1. Example of a clubfoot with ankle equinus, hindfoot varus, forefoot adduction and supination

Many treatment modalities have been proposed, but the treatment modality of Ponseti has been the most widely accepted regime for treating primary clubfoot, with an overall success rate of up to 94%.⁹⁻¹¹

Although the Ponseti modality has a high success rate, it remains debatable if this is the best treatment for relapsed and/or residual clubfeet. Conventional surgery associated with extensive soft tissue release such as the posteromedial release has delivered suboptimal results such as a small, stiff and painful foot at long term follow-up.¹²⁻¹⁸

It is well described in the literature, that there is an inverse linear relationship between the amount of surgeries performed on the foot and the function thereof. In other words, the more surgeries performed and the more extensive the dissection of the foot, the worse the long term outcome of the foot. Quality of health studies that have been performed on long term follow-up patients demonstrated a relatively poor quality of life.^{1,19,20}

Distraction osteo/histiogenesis by means of circular external fixation has shown promise and outcomes have included correction of the deformity without the need for extensive soft tissue releases.²¹⁻²⁵ The longest follow up in patients treated with the Ilizarov apparatus revealed a good outcome with correction of the deformities and preservation of foot function.^{21,26-29} The Ilizarov apparatus however requires intricate knowledge to assemble and apply the necessary hinges and distraction devices.³⁰

The Taylor Spatial Frame uses the same principles of distraction osteo/histiogenesis with the aid of a software based correction system. This allows for an anatomically accurate reduction at a preset rate of reduction. Virtual hinges are generated in the software, removing the need for physical, labour intensive hinges as used in the Ilizarov system.

Use of the Taylor Spatial Frame, or TSF as commonly known, have been well described in limb reconstruction and deformity correction. Its use pertaining to the correction of relapsed or recurrent clubfeet has not.

Treatment of primary clubfoot

The first record of clubfoot treatment was made by Hippocrates in 400 BC.¹ Hippocrates recommended gentle manipulation of the foot followed by splinting.¹ In 1836, Guerin introduced the plaster of Paris cast which was a big advance in non-operative treatment of clubfoot.

At the 2002 Annual meeting of the American Academy of Orthopaedic Surgeons, Cummings stated that "There are as many techniques for manipulative treatment of clubfoot as there are authors writing about clubfoot".⁴ Shortly thereafter the International Clubfoot Study Group (ICFSG) decided to approve Kite's, Ponseti and Bensahel's techniques as the standardized conservative regimes for the treatment of clubfoot.³¹⁻³⁴

Currently the most widely accepted non-operative treatment regime is that of Ponseti.^{20,35,36} Ponseti published his first article about his treatment regime in 1963,³⁷ but it was only from 1995 that Ponseti's treatment regime gained popularity after the publication of a 45 year long term follow up study.^{20,38} This study showed that clubfeet treated with the Ponseti method had a good outcome with minimal complications and no need for extensive surgical intervention.^{20,37} These findings are in line with the

finding by Laaveg *et al.*¹¹ who reported that 90% of their patients were satisfied with the appearance and functionality of their feet after being treated with the Ponseti regime.

Herzenberg *et al.*³⁹ compared the treatment of clubfoot patients who were treated with the Ponseti method with those treated with the Kite method. The results showed only one patient within the Ponseti method group needed a posteromedial release, while 94% of the patients treated with the Kite method needed an additional posteromedial release after treatment.³⁹ These findings are in line with Colburn *et al.*⁴⁰ and Segev *et al.*^{40,41} who reported a success rate of 95 and 94%, respectively, in clubfoot patients who were treated with the Ponseti method.

In 2003, an extensive review by Dobbs *et al.*³⁸ concluded that Ponseti technique results in similar functional and performance parameters as the healthy side, although the range of motion of the clubfoot appeared to remain limited. In order to minimize this limited range of motion, Bensahel and Masse developed a stretching and taping technique. Furthermore, the use of a continued passive motion machine has also recently been introduced.⁴² This method, also known as the French method, is extremely expensive and labour intensive even in developed countries, and does not appear to be more successful than the Ponseti regime.^{33,43}

Treatment of relapsed/residual clubfeet

Non-surgical management

Although the treatment of relapsed or residual clubfoot with the Ponseti technique is less responsive than that of the primary idiopathic clubfoot, the current recommendation is to utilize the Ponseti method 2 – 3 times (with or without a tibialis anterior transfer that acts as an internal splint).

There is however little doubt that a small subgroup of relapsed or residual clubfoot is not successfully resolved by the Ponseti method and this subgroup is very problematic to treat. It is however important to initially start with the Ponseti method for residual or relapsed clubfoot before utilizing surgical methods, as the serial casting lessens the deformities that has to be surgically corrected.

Surgical Treatment

Conventional Surgery

The first operative procedure, the posterior release, was described by Phelps in 1891.⁴⁴ Turco introduced the posteromedial release (PMR) in 1980 which was basically a modification of the earlier procedures of Phelps,⁴⁴ Codvilla (1906), Brockman (1937)⁴⁵ and Bost (1960).⁴⁶ Prerequisites for complete correction include releasing all the affected components and maintaining the correction while the tarsal bones remodel. There have been numerous surgical procedures described for the treatment of clubfoot.^{1,13-16,20,28,44,47-50}

Initially it was also advocated that a full posteromedial release should be performed on all patients with clubfoot in whom conservative therapy has failed, or in those who presented with neglected clubfeet.¹⁹

A more recent recommendation, advocated by Bensahel *et al.*¹⁴, is that of an “a la carte” approach. In other words, to do only what is necessary in order to get a well corrected foot. This approach involves a detailed examination of the clubfoot in order to identify which structures are involved and only thereafter the surgical release of the involved structures.. Another debate is when the optimal age for surgical intervention is.⁴⁸

Turco recommended surgery at one year of age, when the affected structures are more easily identified, while Osterman and Merikanto advocated surgery from age 3 to 6 months.⁴⁸ Conducting surgery at a relative young age is proposed due to the remodelling potential of the foot at this age. However other studies reported a higher incidence of failure and recurrence when children are operated at such a young age.^{15,46,48,51}

Incisions used in clubfoot surgery can be divided into 3 categories. The first is the Turco oblique or hockey-stick incision which is a posteromedial incision. Secondly there is the circumferential incision also known as the Cincinnati incision and the third is the two incisions or Carroll approach. Each has its own complications, and frequently there are skin complications since certain skin creases need to be crossed to reach the relevant structures.⁵² Occasionally it is necessary to use two incisions which can potentially create additional complications.

The success rate of posteromedial release is relatively poor, with failure rates of as high as 13% to 50%.^{12,15,51 52}

Up to 47% of patients that had extensive soft tissue release and corrective surgery needed additional surgical interventions. Long term complications of extensive corrective surgery include stiffness of the ankle and sub-talar joint, secondary osteoarthritis, muscle weakness, a small painful foot and residual deformities. The incidence of these complications increases with the amount of subsequent surgeries and the extent of these surgeries.¹²

A 30 year follow-up study by Dobbs *et al.*¹² showed that clubfoot patients who were treated with extensive soft tissue releases still had significantly lower foot function capacity than in their healthy foot. In addition, a lower amount of soft tissue releases and/or less extensive soft tissue releases were associated with less loss of function in the clubfoot.

Residual deformities occur frequently after surgery on the clubfoot and have an incidence of 20 – 25%. These deformities often require further surgical intervention. However, further surgical intervention is associated with a higher complication rate and may even result in a triple arthrodesis of the foot in some cases.¹²

Patients with residual clubfoot also frequently present with dynamic supination of the forefoot due to the weak everting muscles of the foot. Transfer of the tibialis anterior tendon, a strong inverting muscle, to the lateral cuneiform resolves this problem.⁵³

Critchley *et al.*⁵³ reported good results in 82.3% of the patients for whom they did a tibialis anterior tendon transfer. Good results were classified as no limp, absence of pain, a plantigrade foot and active dorsiflexion and eversion.

It can be concluded that soft tissue corrective surgery has a high probability of failure when considering the long term outcome, necessitating additional surgery with even poorer results. We are thus still on the path of identifying the optimal surgical treatment for the relapsed or neglected clubfoot.

Ilizarov Apparatus

In the 1950's Professor Gavril Abramovich Ilizarov from Russia designed the Ilizarov apparatus after having to treat orthopaedic conditions in the Kurgan region of Siberia.³⁰ Originally bicycle parts were used to construct the first frame. Prof Ilizarov achieved great success with his apparatus and continued to develop the Ilizarov technique until he was treating and correcting complex deformities.³⁰

Due to the Cold War, his ground breaking work was kept initially from the West and it was not till the 1980's that Italian surgeons introduced his technique to the West. Today it is a highly effective method of treating deformities of various kinds. It is, however, a highly specialised technique that requires experience and training in the Ilizarov technique in order to get good results.⁵⁴

The Ilizarov technique can be considered a minimally invasive technique in that it does not require large incisions or dissections. However, the technique however is not without complications. Pin tract sepsis and pain are the most common complications. Dysesthesia, anterior talar subluxation and partial subluxation of the distal tibial physis, joint contractures and premature osseous consolidation have also been reported.^{26,28,55}

Various authors have used the Ilizarov apparatus to treat relapsed or residual clubfoot, often with good success. The success of the Ilizarov frame is its ability to correct all aspects of the deformity, often without the need for extensive surgery.^{16,23-29,47,50,55,56}

Bradish and Noor used the Ilizarov technique in 17 relapsed clubfeet in 12 children²⁴ and showed excellent or good outcomes in 13 feet approximately 3 years after surgery. Complications were minor and included superficial pin tract sepsis which responded well to oral antibiotics.²⁴

Nakase *et al.*¹⁶ in their study of the treatment of relapsed clubfoot with the Ilizarov method combined with a complete subtalar release found that all his cases had an improved outcome at 5 years of follow up.

Prem *et al.*²⁸ found that 74% of his patients had a good or excellent outcome after 5 years. He used the Ilizarov frame without any soft tissue or corrective osteotomies. Only one foot had recurrence of the deformity. As with the previously mentioned studies the only complication noted were that of superficial pin tract sepsis which were successfully treated with oral antibiotics.²⁸

Total time that the foot spends in the Ilizarov frame is also important. In Freedman study²⁶, the mean duration of frame application was 27.62 days. This was significantly shorter than the average frame application time of Prem *et al.*²⁸, Nakase *et al.*¹⁶, Bradish and Noor²⁴, who had an average application time of 10 weeks.

The use of the Ilizarov frame has shown promising results with minimal complications compared to extensive soft tissue release and corrective osteotomies.^{16,21,22,24-26,28}

Taylor Spatial Frame

Recently the development of the Taylor Spatial Frame designed by Dr Charles Taylor in 1994 heralded a new era in orthopaedics with regard to deformity correction and certain trauma applications. The Taylor Spatial Frame, or TSF as it is also known, shares certain components and features of the Ilizarov apparatus, but it is also a hexapod device based on the Stewart-Gough platform. (Figure 2)

This enables the Taylor Spatial Frame to correct deformities in three planes namely coronal, sagittal and axial plane. Angular, translational, rotational and length deformities can also be corrected simultaneously.

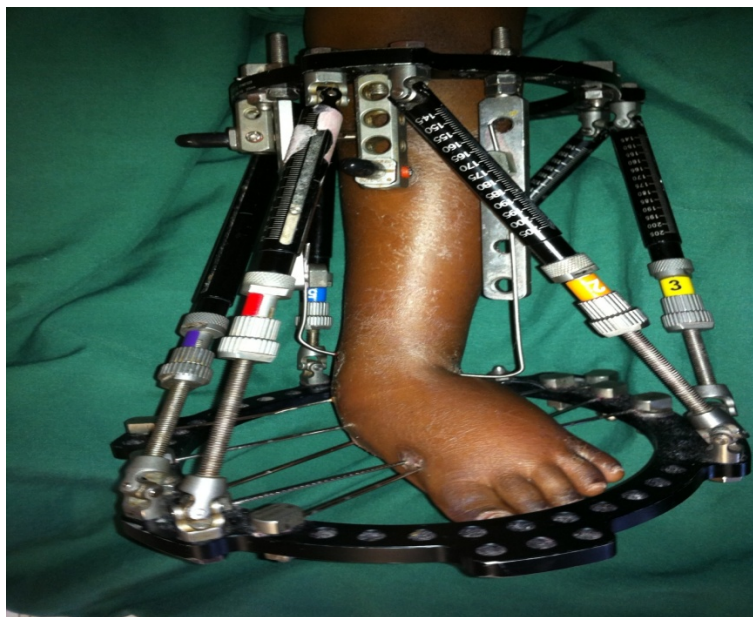

Figure 2: The Taylor Spatial Frame as applied for clubfeet

The technique was developed by Dr. Herzenberg and Lamm *et al.*⁵⁷, and later described in detail by Eidelman *et al.*⁴⁹ The frame is applied in theatre and specific x-ray measurements are taken after the application of the frame in order to characterise the deformity. These are entered into a software program which generates a prescription to correct the deformity. The software enables the surgeon to anatomically correct the deformity.

METHODOLOGY:

A prospective descriptive study was performed at the Lady Michaelis unit at Tygerberg Hospital, South Africa during the period 1 January 2011 to 31 August 2012. All children visiting the clinic with failed clubfoot treatments, residual clubfoot deformities or neglected clubfoot were screened for inclusion to participate into the study. Children had to be over the age of 3 and willing to adhere to the treatment protocol, while the parents had to sign an informed consent, after they were fully informed about the treatment intervention and the associated risks. Ethics approval for the study was obtained through the Health Research Ethics Committee of Stellenbosch University (Ethics file number: N10/10/338).

Inclusion criteria were patients older than 3 years with residual, relapsed, teratogenic or failed post-operative clubfoot. Exclusion criteria were patients under the age of three years, or those that refused surgical intervention.

International Clubfoot Study Group Score

The International Clubfoot Study Group Score is an objective scoring system that assesses three aspects of the foot.³² The first aspect is the morphological appearance of the foot with regards to the hind- and midfoot as well as global alignment. The second is the functional capabilities of the foot. All the important muscles of the foot are tested and scored, as well as the gait pattern. Passive and active range of motion is tested. Finally the radiologic parameters of the foot are assessed in both the lateral and anteroposterior plane. A total score is then calculated and the foot scored as poor, fair, good or excellent with scores showing good intra- and inter-observer reliability.⁶¹ To assess the correction obtained with the above mentioned treatment regimen, we assessed the foot according to the International Clubfoot Study Group Score, pre-operatively as well as one year post-operatively. (Figure 3 & 4)

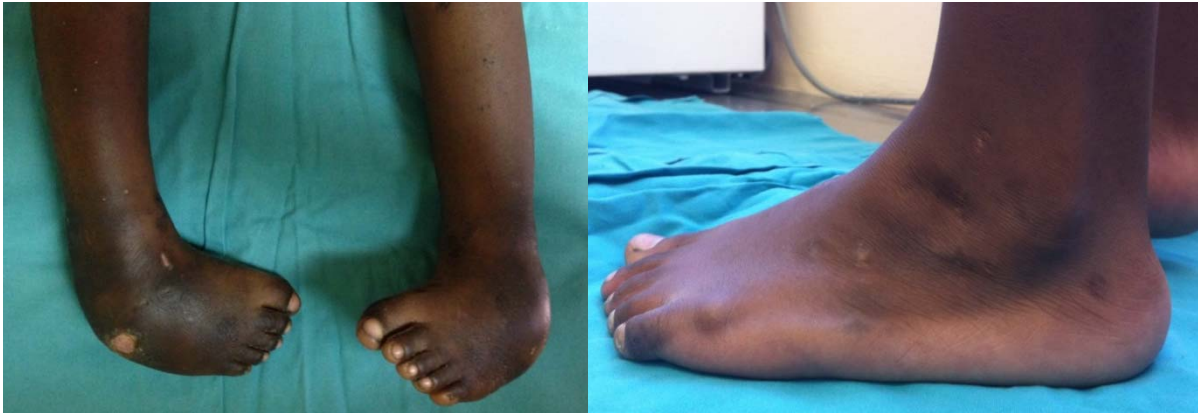

Figure 3: Pre-operative picture of bilateral residual clubfeet

Figure 4: Post-operative result after Taylor Spatial Frame correction

Child Health Questionnaire

For assessment of the quality of life of our study group, we used the Child Health Questionnaire, or CHQ. The CHQ looks at a child's physical and psychosocial health and compares it to a standardized norm.

We used the Child Health Questionnaire 28 which is a parent administered health survey. Questions are asked to test 10 unique physical (PhS) and psychosocial (PsS) aspects, which are then reported in the 10 subsections as well as in a summative Physical and Psychosocial score. The Child Health Questionnaire has been proved to be reliable with a good inter- and intra-observer reliability.⁶²⁻⁶⁴

Both questionnaires were completed by the parents pre-operatively and one year post surgery.

Treatment protocol

After inclusion in the study, patients started the treatment protocol which consisted of 3 interventions. During the first intervention (I) residual adduction of the clubfoot was corrected with the use of the Ponseti method and serial casting performed at the outpatient clinic until adequate correction was obtained.

The patient was then taken to theatre for the second intervention (II) where a Taylor Spatial Frame was applied under general anaesthesia. A full TSF ring is applied to the tibia with hydroxy-apatite coated half pins and fine wires. A foot plate is applied to the foot with fine wires through the calcaneus, as well

as a fine wire through the first and second metatarsal and another wire through the fourth and fifth metatarsal.

This is done with the aim of preventing a splayed foot as found when one wire is used to transfix all the metatarsals. A wire is also passed through the talus and attached to the proximal full ring. This is the first setting for the correction and allows the correction of the subtalar and talonavicular joint.

The patient is then taken back to the ward and seven days are allowed for the soft tissues and pin tracts to settle. Patients are taught how to clean the pin tracts themselves in the ward in this time. During the seven days x-rays are taken and the deformity measured in the 6 planes that need correction. Mounting parameters of the frame are also measured. These parameters are then entered into the software and a prescription is generated to achieve correction.

At day seven the correction is started and continued until the prescription generated by the computer is completed. Correction is performed by adjusting each of the six struts that connects the proximal to the distal frame. The rate of correction can be controlled by means of once-off correction daily or staggered adjustments four times a day. An x-ray is then taken to assess for any possible complications, as well as the correction achieved. The aim of the first correction is to correct the talocalcaneal angle.

During the third and last intervention (III) the patient is taken back to theatre to move the talar wire from the proximal ring to the foot ring to allow for correction of equinus. Correction can be initiated on the following day since no major adjustments are made to the frame. The software generated prescription is then completed and finally the frame is removed in theatre and a below knee circular cast applied to maintain correction and allow for healing of the pin tracts.

The patient is seen at the clinic six weeks later to inspect healing of the soft tissues and to prescribe an ankle-foot-orthosis (AFO) which the patient must wear for six months. If any dynamic supination of the forefoot is present at 6 months follow-up, a tibialis anterior transfer is performed in theatre under general anaesthesia in order to balance the forefoot. The tibialis anterior tendon is transferred to the middle cuneiform to maintain eversion of the foot.

One year post-operatively the foot is assessed according to the ICFSG and CHQ-28 scoring systems.

Statistical Analysis

Statistical analyses were performed with Statistica 10.0 (Statsoft Inc. Tulsa, OK, USA). All data are expressed as mean \pm standard deviation (range). Pre and post sub-category and total scores for morphology, function and radiological score within the ICFSG were analysed with a Wilcoxon test for dependant samples.

Scores for the Child Health Questionnaires were totalled for each of the 10 categories tested. These were then recoded and recalibrated so that a higher score reflects a better outcome. The pre-and post-operative CHQ-28 scores were analysed with a Wilcoxon test for dependant samples and for statistical significance

RESULTS

Nine children were recruited for the study (7 male and 2 female children) with an average age of 6 ± 3 years (range 3 -13 years). Within this group, there were a total of 13 clubfeet with 11 clubfeet of idiopathic of origin and 2 teratogenic clubfeet due to myelomeningocele. Four children had bilateral clubfeet and five had unilateral involvement.

Two children had previous posteromedial release surgery, while all included patients had received an Achilles tenotomy, as part of their initial Ponseti treatment. The average time of frame application was 84 ± 25 days (range: 40 – 126).

The ICFGS and the CHQ were conducted before surgical intervention and again one year post-operatively (53 ± 2.31 weeks).

International Clubfoot Study Group Score

Pre-operative scoring of the clubfeet as described in the methods section according to the International Clubfoot Study Group Score revealed twelve feet with a 'poor' score, and one foot with a 'fair' score.

Post-operatively 2 feet scored 'excellent', 7 'good', 2 'fair' and 2 still 'poor'. The two feet that scored poor was a patient with myelomeningocele who had a complete recurrence of the deformity in both feet.

The total International Clubfoot Study Group score improved from 41 ± 9 (range: 30 - 57) pre-operatively to 16 ± 15 (range: 4 - 49) post-operatively ($p = 0.001474$). In line with this the morphology scores improved from 10 ± 2 (Range 8 – 12) to 3 ± 3 (Range 0 – 10) ($p = 0.00147$), functional scores from 22 ± 7 (Range 15 – 35) to 9 (Range 1 – 32) ($p = 0.001474$) and radiological score 8 ± 2 (Range 6 – 10) to 4 ± 2 (Range 1 – 7) ($p = 0.0015$), from pre to post-operatively respectively (see also Table 1). All the items within the morphological and functional subcategories also improved significantly after the medical intervention, while only the 'lateral parameters' and 'Anteroposterior ankle parameters" within the Radiological section did not change after the medical intervention (see Table 1)

Table 1: International Clubfoot Study Group Score results pre- and post-operative. The data is expressed as mean \pm standard deviation and 95% Confidence intervals (95% CI).

	Pre-operative	95% CI	Post- Operative	95% CI	P value
Morphology					
Hindfoot	3.8 \pm 0.6	3.4 – 4.1	0.8 \pm 0.8	0.8 - 1.3	0.0015 *
Midfoot	3.7 \pm 0.6	3.3 – 4.1	1.2 \pm 1.5	0.34 - 2.1	0.0033 *
Global Rotation	2.7 \pm 1.0	2.1 – 3.3	1.3 \pm 1.3	0.5 - 2.1	0.0058 *
Total	10.2 \pm 1.5	9.2 – 11.1	3.3 \pm 3.3	1.3 - 5.3	0.0015 *
Function					
Passive	4.4 \pm 1.2	3.7 - 5.1	1.7 \pm 1.0	1.1 - 2.3	0.0042 *
Muscle Power	8.2 \pm 5.4	4.9 - 11.4	4.2 \pm 6.8	0.1 - 8.3	0.0051 *
Dynamic Function	9.4 \pm 3.3	7.4 - 11.4	3.0 \pm 4.6	0.3 - 5.9	0.0051 *
Pain	0.4 \pm 0.8	0.07 - 0.85	0.0 \pm 0.0	0.0 – 0.0	0.1088 *
Total	22.3 \pm 7.1	18 - 26.6	9.0 \pm 11.1	2.3 - 15.7	0.0015 *
Radiological					
Anteroposterior parameters	3.9 \pm 0.95	3.3-4.5	2.1 \pm 1.3	0.9-2.4	0.0015 *
Lateral parameters	3.4 \pm 1.3	2.6-4.1	2.1 \pm 1.3	1.3-2.8	0.0107 *
Anteroposterior ankle parameters	0.8 \pm 0.4	0.5-1.03	0.2 \pm 0.4	0.1-0.4	0.0117 *
Total	8.1 \pm 1.6	7.1-9.0	3.9 \pm 1.9	2.8-5.1	0.0015 *
Grand Total:	40.5 \pm 9.2	34.9-46.1	16.2 \pm 15.5	6.8-25.6	0.0015 *

*Significantly different from pre-operative

Child Health Questionnaire

The Child Health Questionnaire™ (CHQ) is a family of generic quality of life instruments that have been designed and normed for children 5 - 18 years of age. The CHQ measures 14 unique physical and psychosocial concepts. The questionnaire is available in different formats such as the CHQ 28, 50 or 87. The number denotes the amount of questions in the survey. ⁶⁵ It has also been translated into various languages enabling patients to complete the questionnaire in their home language.

The youth self-report version is 87 items, and was developed for ages 10 and older.⁶⁵

Scores can be analysed and interpreted separately, ie the CHQ Profile Scores, or combined to derive an overall physical and psychosocial score, the CHQ Summary Scores.⁶⁵

All 9 patient' parents completed the Child Health Questionnaire 28 survey in their home language at the initial pre-operative consultation and at year follow-up. The CHQ 28 questionnaire is a parent completed questionnaire since the majority of our patients are under the age of 10 years. The same parent that completed the initial questionnaire completed the post-operative questionnaire.

The pre-operative survey revealed that all the patients had scored well below the population norm in all categories, as well as in the overall Physical and Psychosocial scores.

Post-operatively there was a statistically significant improvement in all concepts as well as the overall Physical and Psychosocial scores which showed a definite improvement in the patient's quality of life. See Table 2 & Figure 1

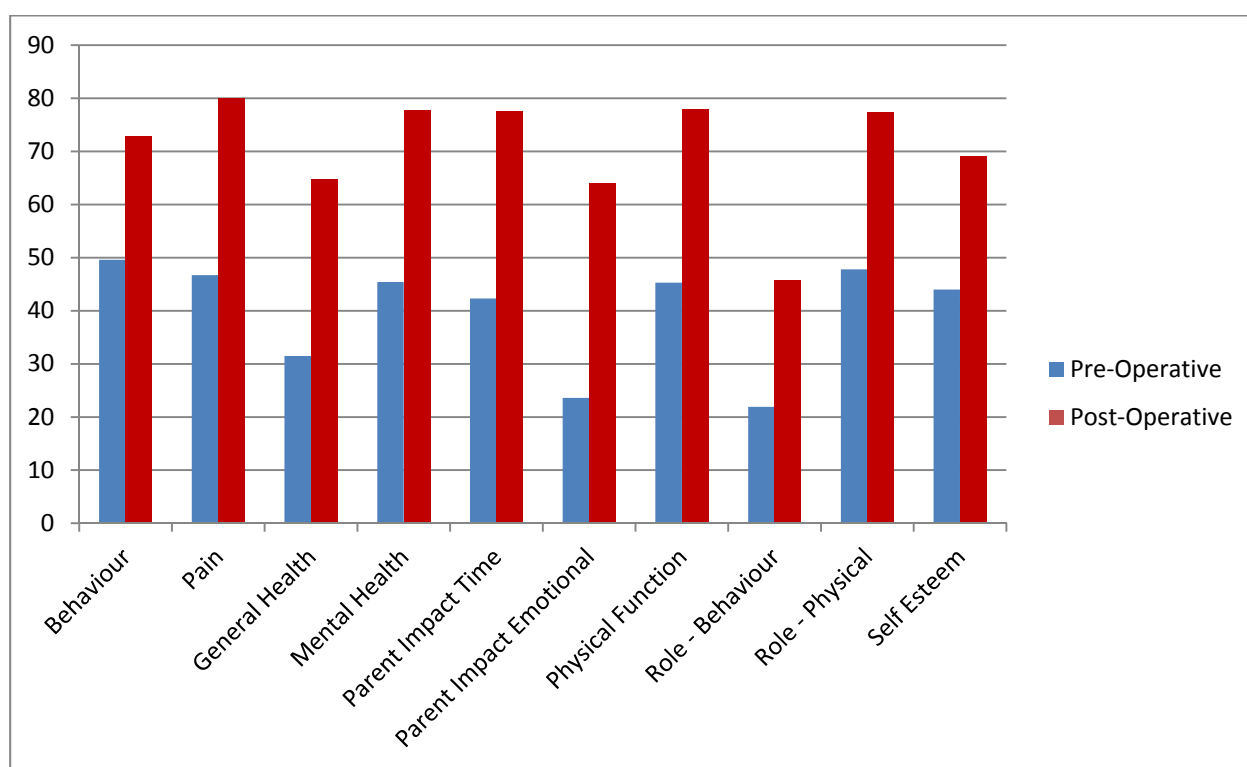


Figure 1: Comparison of pre-operative and post-operative CHQ scores

Table 2: Child Health Questionnaire subsections and Physical, Psychosocial scores. The data is expressed as mean \pm standard deviation and 95% Confidence intervals (95% CI).

	Pre-operative	95% CI	Post-operative	95% CI	P Value
Behaviour	49.6 \pm 23.5	31.5 - 67.6	72.8 \pm 18.4	58.6 - 86.9	0.0117 **
Bodily Pain	46.7 \pm 14.1	35.8 - 57.5	80.0 \pm 20.0	64.6 - 95.4	0.0117 *
General Health	31.5 \pm 6.9	26.1 - 36.8	64.8 \pm 15.5	52.9 - 76.7	0.0077 *
Mental Health	45.4 \pm 17.7	31.7 - 59.0	77.8 \pm 15.6	65.8 - 89.8	0.0078 *
Parent Impact Emotional	23.6 \pm 17.1	10.5 - 36.7	63.9 \pm 24.6	45.0 - 82.8	0.0120 *
Parent Impact Time	42.3 \pm 34.8	15.9 - 68.7	77.6 \pm 27.8	56.2 - 98.9	0.0117 *
Physical Function	45.3 \pm 19.4	45.3 - 75.1	78.0 \pm 13.9	77.9 - 99.3	0.0117 *
Role/Social Emotional – Behaviour	21.9 \pm 28.8	21.9 - 66.3	45.8 \pm 36.5	45.8 - 82.0	0.0280 *
Role/Social – Physical	47.8 \pm 29.3	25.2 - 70.3	77.4 \pm 23.8	59.1 - 95.7	0.0180 *
Self Esteem	44.0 \pm 17.4	44.0 - 70.8	69.0 \pm 15.0	69.0 - 92.1	0.0117 *
Physical	26.5 \pm 9.0	19.5 - 33.4	45.6 \pm 12.5	35.9 - 55.2	0.0077 *
Psychosocial	29.9 \pm 10.4	21.9 - 37.9	48.3 \pm 9.4	41.0 - 55.5	0.0077 *

*Significantly different from pre-operative

Complications

Five patients developed pin tract sepsis which was the most common complication. All were treated effectively with oral antibiotics. One patient had a tibia fracture which was treated conservatively and united without further need for treatment. Two patients needed additional procedures. The first was a midfoot osteotomy for residual forefoot adduction and the other a supramalleolar osteotomy for a pre-existing flat top talus due to the initial Ponsetti regime and not from the treatment in the frame.

We experienced no major complications such as physeal shear or talar subluxation.

DISCUSSION

Although the Ponseti method²⁰ has shown to be an effective way to treat clubfoot, there is a small group of children in which this method and others fail to properly treat the clubfoot. This generally leads to residual clubfoot deformities. Some patients present at an older age with a neglected clubfoot that is unresponsive to Ponseti treatment. Current treatment for the failed clubfoot ranges from a full posteromedial release, a la carte procedures that address specific deformities with varying success, and correction with the Ilizarov frame.

More recently, Eidelman and Hassan began using Taylor Spatial Frames in the treatment of clubfeet, with promising results. Based on these findings, the aim of the current study was determine whether a novel treatment regime consisting of three interventions could successfully treat children with recurrent, residual or neglected clubfeet.

During the initial intervention, the adduction position of the foot is corrected by using the Ponsetti method (I), followed by a talocalcaneal angle correction of the foot with the use of Taylor Spatial Frame (II) and correcting the equinus position of the foot by using the Taylor Spatial Frame (III).

The first finding of this study was that 2 clubfeet scored a 'fair' status based on the International Clubfoot Study Group Score, while the remaining 12 clubfeet scored 'poor' pre-operatively. This finding confirms that children with failed clubfoot treatments, residual clubfoot deformities and/or neglected clubfoot recruited for this study were severely impaired. In line with this, relatively low scores were found in the Child Health Questionnaire (see also Table 2).

All 13 clubfeet were successfully treated with the novel treatment intervention and all patients reported back to the hospital 1 year post operatively (53 ± 2.31 weeks). During this follow up, the function of the clubfoot was again assessed with the International Clubfoot Study Group Score as also done pre-operatively, while the parent was asked to once again complete the Child Health Questionnaire.

The second finding of this study was that International Clubfoot Study Group Scores significantly improved from 40.5 ± 9.2 pre-operative to 48.3 ± 9.4 one year post-operative ($p = 0.0077$). Within the International Clubfoot Study Group Scores, significant improvement were found in all three aspects ranging from morphology (from 10.2 ± 1.5 to 3.3 ± 3.3 ($p = 0.0015$)) to function (from 22.3 ± 7.1 to $9.0 \pm$

11.1 ($p = 0.0015$)) and radiological aspects (from 8.1 ± 1.6 to 3.9 ± 1.9 ($p = 0.0077$)). Although the International Clubfoot Study Group Score has shown to be reliable ⁶¹, it has not yet been commonly used as an assessment tool in scientific research. Although some papers have used the International Clubfoot Study Group Scores to quantify their clubfeet as 'fair', 'poor', 'good' or 'excellent' ⁶⁶⁻⁶⁸, none of these studies used the ICFSG score to assess the feet pre-operative as well as post-operatively. Furthermore, these studies were all performed retrospectively with up to 50% failure with regards to follow-up.⁶⁶⁻⁶⁸

Chu *et al.* ⁶⁷ has used the International Clubfoot Study Group Scores as an assessment tool for calcaneocuboid arthrodesis 17 years after surgery. Although these patients are not comparable to our population, similar morphology (2.5 ± 2.5), function (11.1 ± 4.0), and radiological (4.2 ± 2.9) were reported as our post-operative scores. These improvements resulted in 7 'good', 2 'fair' and 1 'poor' international Clubfoot Study Group Score.

From the 13 feet, 1 improved from 'poor' to 'excellent', 1 from 'fair' to 'good', 7 from 'poor' to 'good', 2 from 'poor' to 'fair' and two stayed 'poor'. In one child a complete recurrence of his clubfoot was observed and his scores stayed "poor".

The latter observation could be explained by the child having myelomeningocele, which was associated with unbalanced muscle tone and poor muscle control of the lower extremities. In this patient, the International Clubfoot Study Group Score remained 'poor'. This case highlights that strict inclusion criteria should be set to assure that the novel treatment approach is effective.

In line with improvement in the International Clubfoot Study Group Scores, the quality of life also improved in treated children. One year post surgery, there were significant improvements in all subsections and summative physical and psychosocial scores of the 28 question quality of life health questionnaire (CHQ-28). However these scores were still slightly less than the established norm values of healthy children in the United States of America. To our knowledge, no study up to date has used the CHQ-28 as quantitative measuring tool, making it difficult to compare our finding to other papers. Roye *et al.* ⁶⁹ and Vitale *et al.* ^{69,70} used the 87 item Child Health Questionnaire (CHQ-87) to assess the treatment of clubfoot treatment in 24 clubfeet that were treated surgically. However, no pre-operative CHQ-87 scoring was done, and no mention made of the type of surgery or severity of the feet pre-operatively.^{69,70}

In contrast to the CHQ-87, which is patient administered questionnaire, the CHQ-28 is a parent based administered questionnaire. As the CHQ-87 has been developed for assessments from the age of 10 years⁶²⁻⁶⁵, we could not use this questionnaire in the current study as the mean age of our patients was 6 ± 3 years. Although the CHQ-28 has shown to be reliable^{62,64} and norm values for healthy children have been established based on American children, future research should also aim to establish norm values based on local populations, while more clubfeet research should use the CHQ-28 to assess the effectiveness of different treatment regimens on the general health implications of these children.

To our knowledge only two other studies have focussed on the treatments of residual clubfeet with a Taylor Spatial Frame. Eidelman *et al.*^{49,59} treated 12 clubfeet of various aetiology with a Taylor Spatial Frame, although midfoot osteotomies were performed in the same sitting. The same method was used by Hassan *et al.*⁵⁹ with distal tibia lengthening, mid and hindfoot osteotomies and soft tissue releases performed in the same sitting as Taylor Spatial Frame application.

Both Eidelman and Hassan reported feet with 'excellent' or 'good' outcomes, although a comprehensive scoring system such as the ICFSG score was not used.

The main complication with the current treatment regime was the pin tract sepsis, which is common in external fixator placement. This complication highlights the importance of good pin tract care and it follows that the ability of the patient/parents to effectively clean and maintain pin tract care should be closely monitored. In addition, we encountered one tibia fracture, while 2 other patients needed additional surgical treatments. This finding suggests that although our treatment regime appears to be largely effective, there is room for further improvement. In addition the lack of improvement in one of the patients highlights the importance of clear inclusion criteria for the method in order to assure a bifacial effect.

Although our sample size in this study was comparable to the study by Eidelman *et al.*^{49,59} (n=12) and Hassan *et al.*⁵⁹ (n = 11), it remains relatively low and future research studies could aim to address this aspect by using a multi-centre research approach. In addition, future research should also aim to determine the long-term effects of this treatment regime.

In conclusion, this study shows that our novel treatment regime was able to successfully treat 11 out of 13 clubfeet and there were significant improvements in ICFSG scores and CHQ-28 scores one year post-operatively. Future research studies should focus on reducing the complication rate, increasing the

sample size and determining the long term effect of this treatment regime as well as determining accurate inclusion and exclusion criteria for the procedure.

REFERENCES

1. Anand A, Sala DA. Clubfoot: etiology and treatment. *Indian J Orthop* 2008;42:22-8.
2. Irani R, Mary S. The pathological anatomy of idiopathic clubfoot. *Clin Orthop Relat Res* 1972;84:14-20.
3. Aronson J, Puskarich CL. Deformity and disability from treated clubfoot. *J Pediatr Orthop* 1990;10:109-19.
4. Cummings J, Davidson R, Armstrong P, Wallace L. Congenital Clubfoot. *J Bone Joint Surg Am* 2002;84:290-293
5. Pirani S, Zeznik L, Hodges D. Magnetic resonance imaging study of the congenital clubfoot treated with the Ponseti method. *J Pediatr Orthop* 2001;21:719-26.
6. Dietz FR, Ponseti IV, Buckwalter JA. Morphometric study of clubfoot tendon sheaths. *J Pediatr Orthop* 1983;3:311-8.
7. Ippolito E, Ponseti IV. Congenital club foot in the human fetus. A histological study. *J Bone Joint Surg Am* 1980;62:8-22.
8. Ippolito E. Update on pathologic anatomy of clubfoot. *J Pediatr Orthop B* 1995;4:17-24.
9. Ippolito E, Farsetti P, Caterini R, Tudisco C. Long-term comparative results in patients with congenital clubfoot treated with two different protocols. *J Bone Joint Surg Am* 2003;85-A:1286-94.
10. Dobbs MB, Rudzki JR, Purcell DB, Walton T, Porter KR, Gurnett CA. Factors predictive of outcome after use of the Ponseti method for the treatment of idiopathic clubfeet. *J Bone Joint Surg Am* 2004;86:22-7.
11. Laaveg SJ, Ponseti IV. Long-term results of treatment of congenital club foot. *J Bone Joint Surg Am* 1980;62:23-31.
12. Dobbs MB, Nunley R, Schoenecker PL. Long-term follow-up of patients with clubfeet treated with extensive soft-tissue release. *J Bone Joint Surg Am* 2006;88:986-96.
13. Atar D, Lehman WB, Grant AD, Strongwater AM. Revision surgery in clubfeet. *Clin Orthop Relat Res* 1992;283:223-30.
14. Bensahel H, Csukonyi Z, Desgrappes Y, Chaumien JP. Surgery in residual clubfoot: one-stage medioposterior release "a la carte". *J Pediatr Orthop* 1987;7:145-8.
15. Hutchins PM, Foster BK, Paterson DC, Cole EA. Long-term results of early surgical release in club feet. *J Bone Joint Surg Br* 1985;67:791-9.
16. Nakase T, Yasui N, Ohzono K, Shimizu N, Yoshikawa H. Treatment of relapsed idiopathic clubfoot by complete subtalar release combined with the Ilizarov method. *J Foot Ankle Surg* 2006;45:337-41.
17. Uglow MG, Clarke NM. Relapse in staged surgery for congenital talipes equinovarus. *J Bone Joint Surg Br* 2000;82:739-43.
18. Uglow MG, Senbaga N, Pickard R, Clarke NM. Relapse rates following staged surgery in the treatment of recalcitrant talipes equinovarus: 9 to 16 year outcome study. *J Child Orthop* 2007;1:115-9.

19. Cummings RJ, Lovell WW. Operative treatment of congenital idiopathic club foot. *J Bone Joint Surg Am* 1988;70:1108-12.
20. Ponseti IV, Ponseti I. *Congenital clubfoot: fundamentals of treatment*: Oxford University Press New York; 1996.
21. Grill F, Franke J. The Ilizarov distractor for the correction of relapsed or neglected clubfoot. *J Bone Joint Surg Br* 1987;69:593-7.
22. Franke J, Grill F, Hein G, Simon M. Correction of clubfoot relapse using Ilizarov's apparatus in children 8–15 years old. *Arch Orthop Trauma Surg* 1990;110:33-7.
23. Wallander H, Hansson G, Tjernstrom B. Correction of persistent clubfoot deformities with the Ilizarov external fixator. Experience in 10 previously operated feet followed for 2-5 years. *Acta Orthop Scand* 1996;67:283-7.
24. Bradish CF, Noor S. The Ilizarov method in the management of relapsed club feet. *J Bone Joint Surg Br* 2000;82:387-91.
25. El Barbary H, Ghani AH, Hegazy M. Correction of relapsed or neglected clubfoot using a simple Ilizarov frame. *Int Orthop* 2004;28:183-6.
26. Freedman J, Watts H, Otsuka N. The Ilizarov Method for the Treatment of Resistant Clubfoot: Is It an Effective Solution? *J Pediatr Orthop* 2006;26:432-7.
27. Hosny GA. Correction of Foot Deformities by the Ilizarov Method without Corrective Osteotomies or Soft Tissue Release. *J Pediatr Orthop B* 2002;11:121-8.
28. Prem H, Zenios M, Farrell R, Day JB. Soft tissue Ilizarov correction of congenital talipes equinovarus: 5 to 10 years post surgery. *J Pediatr Orthop* 2007;27:220-4.
29. Reinker KA, Carpenter CT. Ilizarov applications in the pediatric foot. *J Pediatr Orthop* 1997;17:796-802.
30. Ilizarov GA. The principles of the Ilizarov method. *Bull Hosp J Dis Orthop Inst* 1988;48:1-11.
31. Kite J. The non-operative treatment of congenital clubfoot. *South Med J* 1930;23:337-44.
32. Bensahel H, Kuo K, Duhaime M, International Clubfoot Study Group. Outcome evaluation of the treatment of clubfoot: the international language of clubfoot. *J Pediatr Orthop B* 2003;269-71.
33. Souchet P, Bensahel H, Themar-Noel C, Pennecot G, Csukonyi Z. Functional treatment of clubfoot: a new series of 350 idiopathic clubfeet with long-term follow-up. *J Pediatr Orthop B* 2004;13:189-96.
34. Richards S, Dempsey M. Magnetic resonance imaging of the congenital clubfoot treated with the French functional (physical therapy) method. *J Pediatr Orthop* 2007;214-9.
35. Scher DM. The Ponseti method for treatment of congenital club foot. *Curr Opin Pediatr* 2006;18:22-5.
36. Ponseti IV. Clubfoot management. *J Pediatr Orthop* 2000;20:699-700.
37. Ponseti IV, Smoley EN. Congenital Club Foot: The Results of Treatment. *J Bone Joint Surg Am* 1963;2:261-4.
38. Dobbs MB, Corley CL, Morcuende JA, Ponseti IV. Late recurrence of clubfoot deformity: a 45-year followup. *Clin Orthop Relat Res* 2003;411:188-92.

39. Herzenberg JE, Radler C, Bor N. Ponseti versus traditional methods of casting for idiopathic clubfoot. *J Pediatr Orthop* 2002;22:517-21.
40. Segev E, Keret D, Lokiec F. Early experience with the Ponseti method for the treatment of congenital idiopathic clubfoot. *Isr Medi Ass* 2005;7:307-10.
41. Colburn M, Williams M. Evaluation of the treatment of idiopathic clubfoot by using the Ponseti method. *J Foot Ankle Surg* 2003;42:259-67.
42. Dimeglio, A., Bonnet, F., Mazeau, P. H., & De Rosa, V. Orthopaedic treatment and passive motion machine: consequences for the surgical treatment of clubfoot. *J Pediatr Orthop B*. 1996; 5(3),173-182.
43. Richards BS, Johnson CE, Wilson H. Non-operative clubfoot treatment using the French physical therapy method. *J Pediatr Orthop B* 2005;25:98-102.
44. Phillipson A. The Phelps' Method of Treating Club-Foot. *Ann Surg* 1888;8:459-60.
45. Brockman E. Congenital club-foot: Wright & Sons; 1930, London, England.
46. Turco VJ. Surgical correction of the resistant club foot. One-stage posteromedial release with internal fixation: a preliminary report. *J Bone Joint Surg Am* 1971;53:477-97.
47. Ganger R, Radler C, Handlbauer A, Grill F. External fixation in clubfoot treatment - a review of the literature. *J Pediatr Orthop B* 2012;21:52-8.
48. Osterman K, Merikanto J. Critical aspects of neonatal surgery in clubfoot. *J Pediatr Orthop B* 1996;5:55-6.
49. Eidelman M, Katzman A, Bor N, Lamm B, Herzenberg JE. Treatment of residual clubfoot deformities with the Taylor spatial frame using a Ponseti sequence. *J Bone Joint Surg Br* 2008;90:512-513.
50. Segev E, Ezra E, Yaniv M, Wientroub S, Hemo Y. V osteotomy and Ilizarov technique for residual idiopathic or neurogenic clubfeet. *J Orthop Surg (Hong Kong)* 2008;16:215-9.
51. Hudson I, Catterall A. Posterolateral release for resistant club foot. *J Bone Joint Surg Br* 1994;76:281-4.
52. Crawford HA, Gupta AK. Clubfoot controversies: complications and causes of failure. *Instr Course Lect* 1996;45:339-46.
53. Crithcley JE, Taylor RG. Transfer of Tibialis Anterior tendon for relapsed clubfoot. *J Bone Joint Surg Br* 1952;34:49-52.
54. Hellinger J. Die Behandlung von pseudarthrosen langer röhrenknochen mit simultaner beinverlängerung. *Zbl Chir* 1973;98:1272-6.
55. Velazquez RJ, Bell DF, Armstrong PF, Babyn P, Tibshirani R. Complications of use of the Ilizarov technique in the correction of limb deformities in children. *J Bone Joint Surg Am* 1993;75:1148-56.
56. Watts H, Otsuka N, Freedman J. The Ilizarov method for the treatment of resistant clubfoot: is it an effective solution? *J Pediatr Orthop* 2006;26:432-7.
57. Lamm BM, Standard SC, Galley IJ, Herzenberg JE, Paley D. External fixation for the foot and ankle in children. *Clin Podiatr Med Surg* 2006;23:137-66.

58. Eidelman M, Keren Y, Katzman A. Correction of residual clubfoot deformities in older children using the Taylor spatial butt frame and midfoot Gigli saw osteotomy. *J Pediatr Orthop* 2012;32:527-33.
59. Hassan A, Letts M. The management of the neglected congenital foot deformity in the older child with the Taylor spatial frame. *J Pediatr Orthop* 2012;32:85-92.
60. Eidelman M, Bialik V, Katzman A. Correction of deformities in children using the Taylor spatial frame. *J Pediatr Orthop B* 2006;15:387-95.
61. Celebi L, Muratli HH, Aksahin E, Yagmurlu MF, Bicimoglu A. Bensahel and International Clubfoot Study Group evaluation of treated clubfoot: assessment of interobserver and intraobserver reliability. *J Pediatr Orthop B* 2006;15:34-6.
62. Ruperto N, Ravelli A, Pistorio A, Martini A, Landgraf JM, Singh G. Cross-cultural adaptation and psychometric evaluation of the Childhood Health Assessment Questionnaire (CHAQ) and the Child Health Questionnaire (CHQ) in 32 countries. Review of the general methodology. *Clin Exp Rheumatol* 2000;19:S1-9.
63. Raat H, Landgraf JM, Bonsel GJ, Gemke RJ, Essink-Bot ML. Reliability and validity of the child health questionnaire-child form (CHQ-CF87) in a Dutch adolescent population. *Qual Life Res* 2002;11:575-81.
64. Raat H, Botterweck AM, Landgraf JM, Hoogeveen WC, Essink-Bot ML. Reliability and validity of the short form of the child health questionnaire for parents (CHQ-PF28) in large random school based and general population samples. *J Epidemiol Community Health* 2005;59:75-82.
65. Landgraf JM, Abetz L, Ware JE. *Child Health Questionnaire (CHQ): A user's manual*: Health Institute, New England Medical Center Boston, MA; 1996.
66. Gupta P, Bither N. Ilizarov in relapsed clubfoot: a necessary evil? *J Pediatr Orthop B* 2013;22:589-94.
67. Chu A, Chaudhry S, Sala DA, Atar D, Lehman WB. Calcaneocuboid arthrodesis for recurrent clubfeet: what is the outcome at 17-year follow-up? *J Paediatr Orthop* 2014;8:43-8.
68. Machida J, Kameshita K, Okuzumi S, Nakamura N. Flexibility of idiopathic congenital clubfeet treated by posteromedial release without talocalcaneal joint release. *J Pediatr Orthop B* 2014 23(3) 254-9
69. Roye BD, Vitale MG, Gelijns AC, Roye DP, Jr. Patient-based outcomes after clubfoot surgery. *J Pediatr Orthop* 2001;21:42-9.
70. Vitale MG, Choe JC, Vitale MA, Lee FY, Hyman JE, Roye DP, Jr. Patient-based outcomes following clubfoot surgery: a 16-year follow-up study. *J Pediatr Orthop* 2005;25:533-8.

APENDIX 1 - INTERNATIONAL CLUBFOOT STUDY SCORE

International Clubfoot Study Group Score:

1. Morphology

A. Hindfoot

1. Varus or Valgus	0	1(10°)	2(>10°)
2. Equinus or calcaneus	0	1(10°)	2(>10°)

B. Midfoot

1. Supination or Pronation	0	1(10°)	2(>10°)
2. Adduction or Abduction	0	1(10°)	2(>10°)

C. Global alignment of the foot

1. Rotation: medial or lateral (Thigh-knee foot angle)	0	1(10°)	2(>10°)
2. Pes Cavus or Flatfoot	0	1(10°)	2(>10°)

Maximum (12)

2. Functional Evaluation

A. Passive Motion

1a) Ankle Dorsiflexion	0	1(0°)	2(negative) 2(0° or negative)
2a) Ankle Plantar flexion	0	1(10°)	negative)
2. Subtalar Varus or Valgus	Flexible/Stiff	0	1
3. Midtarsal joint motion	Flexible/Stiff	0	1

B. Muscle Function

	Normal	Moderate	Severe
Jones' Classification	(5,4)	3	(2,1,0)
1. Triceps surae	0	1	2
2. Toe flexors	0	1	2
3. Extensors	0	1	2
4. Anterior tibia tendon	0	1	2
5. Extensor Hallicus Longus	0	1	2
6. Posterior tibia tendon	0	1	2
7. Peroneal tendon	0	1	2
8. Flexor Hallicus Longus	0	1	2

C. Dynamic function

1. Gait	None	Positive	
i. Intoeing (medial rotation)	0	1(10°)	2(>10°)
ii. Calcaneus	0	1(10°)	2(>10°)

iii. Equinus	0	1(10°)	2(>10°)
iv. Dynamic supination	0	1(10°)	2(>10°)
v. Limping	0	1	
vi. Ability to run	0	1	
vii. Ability to jump	0	1	
2. Shoe wear	Normal 0		Abnormal 1
3. Heel walking or toe walking	yes 0		No 1

D. Pain

1. No pain	0
2. Pain with activity	1
3. Pain with sports	2
4. Constant	3

Maximum (36)

3. Radiologic evaluation

A. Standing anteroposterior views (in weight bearing position)	Normal	Abnormal
1. Talo-calcaneal angle	0	1
2. Cuboid-calcaneo alignment	0	1
3. Cubo-M5 axis	0	1
4. Talo-M1 angle	0	1
5. Talo-navicular position	0	1
B. Standing lateral views (foot in weight bearing position)		
1. Talo calcaneal angle	0	1
2. Tibio-calcaneal angle	0	1
3. Talo-navicular position	0	1
4. Talo-M1 axis	0	1
5. Calcaneo-M5 axis	0	1
6. Flat top talus	0	1
C. Ankle AP standing	0	1

Maximum (12)

Result

Excellent	0 - 5
Good	6 to 15
Fair	16 to 30
Poor	>30