


**CORRELATION OF POST MORTEM LODOX DIGITAL RADIOLOGICAL
IMAGES WITH HISTOPATHOLOGICAL FINDINGS AT AUTOPSY. A
PROSPECTIVE AUTOPSY STUDY AT THE TYGERBERG FORENSIC
PATHOLOGY SERVICE FACILITY**

by Dr Karisha Claudia Quarrie

Thesis presented in fulfilment of the requirements for the degree of Master of Medicine
(Forensic Pathology) at the Stellenbosch University



"

"

"

"

"

"

.....

Supervisor: Dr. Elsie Helena Burger

March 2015

Declaration

I, the undersigned, hereby declare that the work contained in this assignment is my original work and that I have not previously submitted it, in its entirety or in part, at any university for a degree.

Signature: Dr Karisha Claudia Quarrie

Date: March 2015

Copyright © 2015 Stellenbosch University

All right reserved

Abstract: English

Background: The LODOX Statscan is a whole-body digital X-ray scanning device which was adapted for medical usage. The LODOX has an established role in the field of Forensic Pathology where it shows high sensitivity and specificity for the detection of skeletal pathology and foreign bodies. The role of the scanner in the detection of soft tissue pathology in the lungs of adults has not been reported and this study aims to review the radio-pathological correlation and the applicability of LODOX as a viable screening tool in the detection of lung pathology in post mortem cases.

Methods: We prospectively reviewed cases which were referred for medico-legal autopsy between November 2012 and March 2013 to the Tygerberg Forensic Pathology Service mortuary, Cape Town, South Africa. All cases meeting the prescribed inclusion criteria underwent LODOX scanning as well as macroscopic and microscopic evaluation of the lungs as permitted by the Inquests Act 58 of 1959. The macroscopic and microscopic variables were considered the “gold standard” when compared with the results of the LODOX. The sensitivity, specificity, positive and negative predictive values were assessed.

Results: One hundred and fifty nine cases (159) were included in the study. The most common radiographic patterns reported were the presence of ground glass opacities and consolidation. Overall, low to moderate sensitivity of these LODOX patterns in the prediction of pneumonic microscopic pathology (oedema, acute and chronic inflammation and features of diffuse alveolar damage) was noted. These values were lower than that reported for pneumonia using conventional X-rays. Additionally, these LODOX patterns have a high probability of representing oedema or autolytic/decomposition change. Pneumothorax was the most common pleural pathology detected on LODOX, but autopsy correlation could not be performed. Poor to no correlation was noted with the variables of cavity, malignant tumour, and bronchiectasis, but the prevalence of these conditions in our cohort was low. In general, LODOX predictions were better at excluding pathology which was not present rather than confirming pathology which was present.

Conclusions: The LODOX offers excellent evidentiary value in the demonstration of a pneumothorax but currently has limited value as a “stand alone” test in the field of Forensic Pathology. However the continued use of the LODOX as an adjunct examination, as well as prospective study of its applicability, is advised.

Key words: LODOX Statscan, forensic, autopsy, macroscopic evaluation, microscopy, correlation

Opsomming: Afrikaans

Agtergrond: Die LODOX Statscan is 'n heel-liggaam digitale X-straal skandeer apparaat wat aangepas is vir mediese gebruik. Die LODOX het 'n gevestigde rol in Geregtelike Patologie, waar dit 'n hoë sensitiwiteit en spesifisiteit het in die opsporing van skeletale patologie en vreemde voorwerpe. Die rol van die skandeerder in die opspoor van sagte weefsel patologie in die longe van volwassenes is nog nie gerapporteer nie, en hierdie studie ondersoek die radio-patologiese korrelasie en toepaslikheid van LODOX as 'n doeltreffende siftingsmeganisme om long patologie op te spoor in post-mortale gevalle.

Metode: Gevalle wat verwys is na die Tygerberg Geregtelike Patologie Diens lykshuis in Kaapstad, Suid-Afrika vir medies-geregtelike outopsies tussen November 2012 en Maart 2013, is prospektief geëvalueer. Alle gevalle wat die voorgeskrewe insluitingskriteria nagekom het, het LODOX skandering asook makroskopiese en mikroskopiese ondersoek van die longe ondergaan, soos toegelaat deur die Wet op Geregtelike Doodsondersoeke Nr 58 van 1959. Die makroskopiese en mikroskopiese veranderlikes is beskou as die “goud standaard” in vergelyking met die resultate van die LODOX. Die sensitiwiteit, spesifisiteit, positiewe en negatiewe voorspellingswaardes is beoordeel.

Resultate: Eenhonderd-nege-en-vyftig gevalle (159) is ingesluit in die studie. Die algemeenste radiografiese patroon wat gerapporteer is, was die teenwoordigheid van gemaalde glas opasiteit en konsolidasie. In geheel is lae to matige sensitiwiteit van hierdie LODOX beelde waargeneem in die voorspelling van pneumoniese mikroskopiese patologie (edeem, akute en chroniese ontsteking, en eienskappe van diffuse alveolêre skade). Hierdie waardes was laer as die wat gerapporteer is vir pneumonie met konvensionele X-strale. Verder het hierdie LODOX beelde 'n hoë waarskynlikheid om edeem en/of outolise/ontbinding uit te beeld. Pneumotoraks was die algemeenste pleurale patologie wat waargeneem is met die LODOX, maar outopsie korrelasie kon nie gedoen word nie. Swak tot geen korrelasie is gemerk vir die veranderlikes kaviteit, maligne tumor en brongi-ektase, maar die prevalensie van hierdie toestande in ons kohort was laag. Oor die algemeen was LODOX voorspellings beter om patologie wat nie teenwoordig is nie, uit te skakel, eerder as om patologie wat teenwoordig is, te bevestig.

Gevolgtrekking: The LODOX is 'n uitstekende bewysstuk in die aantoon van 'n pneumotoraks, maar huidiglik het dit beperkte waarde as onafhanklike toets in die veld van Geregtelike Patologie. Desnieteenstaande word die verdere gebruik van LODOX as bydraende ondersoek, sowel as die prospektiewe studie van sy toepaslikheid aanbeveel.

Sleutel Woorde: LODOX Statscan, forensies, outopsie, makroskopiese ondersoek, mikroskopie, korrelasie

Acknowledgements

I would like to thank my family, supervisor and colleagues for their support and assistance.

Table of Contents

Contents	Page
Title page	
Declaration.....	i
Abstract.....	ii
Opsomming.....	iii
Acknowledgements.....	iv
Table of Contents.....	v-vi
List of Figures.....	vii
List of Tables.....	viii-ix
List of Abbreviations.....	x
Glossary.....	xi-xii
Chapter 1: Introduction.....	1
Chapter 2: Literature Review	
2.1 Introduction.....	2
2.2 Detailed literature review.....	2
2.3 Problem Statement.....	6
2.4 Aim of the study.....	7
Chapter 3: Method	
3.1 Study Design.....	8
3.2 Population.....	8
3.3 Case Selection	8
3.4 Outcome measures.....	9
3.5 Data Collection.....	9
3.6 Continuity measures.....	10
3.7 Statistical analysis.....	11
3.8 Ethics.....	11
3.9 Conclusion.....	12

Chapter 4: Results: General Findings

4.1	Introduction.....	13
4.2	General demographic data evaluation.....	13
4.3	General LODOX/radiological data evaluation.....	15
4.4	General macroscopic data evaluation	19
4.5	General microscopic data evaluation.....	21

Chapter 5: Results: LODOX versus Macroscopic evaluation

5.1	Introduction.....	23
5.2	LODOX ground glass opacities versus macroscopic variables.....	23
5.3	LODOX consolidation versus macroscopic variables.....	26
5.4	LODOX versus other macroscopic variables.....	28

Chapter 6: Results: LODOX versus Microscopic evaluation

6.1	Introduction.....	32
6.2	LODOX ground glass opacities versus microscopic variables.....	32
6.3	LODOX consolidation versus microscopic variables.....	36
6.4	LODOX versus other microscopic variables.....	38

Chapter 7: Discussion

7.1	Introduction.....	41
7.2	Discussion of findings.....	42

Chapter 8: Conclusion

8.1.	Summary of results.....	52
8.2.	Concluding statements.....	52
8.3.	Limitations	53
8.4.	Future research and recommendations.....	53
8.5.	Summary of contributors.....	54

Appendices

Bibliography

List of Figures

	Page
Figure 4.1: LODOX/ Radiological findings for the right upper lobe.	16
Figure 4.2: LODOX/ Radiological findings for the right middle lobe.	17
Figure 4.3: LODOX/ Radiological findings for the right lower lobe.	17
Figure 4.4: LODOX/ Radiological findings for the left upper lobe.	18
Figure 4.5: LODOX/ Radiological findings for the left lower lobe.	18

List of Tables

Chapter 4	Page
Table 4.1 Distribution of pathology where the cause of death was deemed to be due to natural pathology.	14
Table 4.2 Comparison of respiratory cause of death with findings reported on LODOX images for individual cases.	15
Table 4.3 Average lung weights of the individual lungs.	19
Table 4.4 Frequency of positive findings on macroscopic evaluation.	20
Table 4.5 Frequency of positive findings on microscopic evaluation.	22
 Chapter 5	
Table 5.1 LODOX ground glass opacities versus macroscopic oedema.	24
Table 5.2 LODOX ground glass opacities versus macroscopic acute inflammation.	24
Table 5.3 LODOX ground glass opacities versus macroscopic chronic inflammation.	25
Table 5.4 LODOX ground glass opacities versus macroscopic features of Diffuse Alveolar Damage (DAD).	25
Table 5.5 LODOX consolidation versus macroscopic oedema.	26
Table 5.6 LODOX consolidation versus macroscopic acute inflammation.	27
Table 5.7 LODOX consolidation versus macroscopic chronic inflammation.	27
Table 5.8 LODOX consolidation versus macroscopic features of Diffuse Alveolar Damage (DAD).	28
Table 5.9 LODOX bullae versus macroscopic emphysema.	29
Table 5.10 LODOX Pulmonary interstitial emphysema (PIE) versus macroscopic emphysema.	29
Table 5.11 LODOX pleural pathology versus macroscopic pleural pathology.	30

Chapter 6

Table 6.1 LODOX ground glass opacities versus microscopic oedema.	33
Table 6.2 LODOX ground glass opacities versus microscopic acute inflammation.	33
Table 6.3 LODOX ground glass opacities versus microscopic chronic inflammation.	34
Table 6.4 LODOX ground glass opacities versus microscopic features of Diffuse Alveolar Damage (DAD) - fibrin strands.	34
Table 6.5 LODOX ground glass opacities versus microscopic intra alveolar Haemorrhage (IAH).	35
Table 6.6 LODOX consolidation versus microscopic oedema.	36
Table 6.7 LODOX consolidation versus microscopic acute inflammation.	36
Table 6.8 LODOX consolidation versus microscopic chronic inflammation.	37
Table 6.9 LODOX consolidation versus microscopic features of Diffuse Alveolar Damage (DAD) – fibrin strands.	37
Table 6.10 LODOX consolidation versus microscopic intra alveolar haemorrhage (IAH).	38
Table 6.11 LODOX bullae and pulmonary Interstitial Emphysema (PIE) versus microscopic emphysema.	38
Table 6.12 LODOX pleural pathology versus microscopic pleural pathology.	39

List of Abbreviations

BWT	Bronchial wall thickening
CI	Confidence interval
COD	Cause of Death
CT	Computerized tomography
DAD	Diffuse alveolar damage
GGO	Ground glass opacity
IAH	Intra alveolar haemorrhage
LLL	Left lower lobe
LODOX	Low Dose X-ray scan
LUL	Left upper lobe
MRI	Magnetic Resonance Imaging
NPV	Negative Predictive Value
PIE	Pulmonary interstitial emphysema
PPV	Positive Predictive Value
RN	Reticular Nodular Pattern
RLL	Right lower lobe
RML	Right middle lobe
RUL	Right upper lobe
SD	Standard Deviation
SUDA	Sudden unexpected death in an adult
SUDI	Sudden unexpected death in infancy

Glossary

Acute Inflammation: The rapid response of the body to a site of injury or infection by the production and delivery of leukocytes and plasma proteins. For the purpose of this study acute inflammation is further defined as encompassing acute parenchymal infections of the lung (pneumonia). Microscopically characterised by the presence of acute inflammatory cells and associated changes.

Association: The relationship between two variables. For the purpose of this study the term *association* is used interchangeably with *correlation*. (See below)

Autolysis: The initial stage of decomposition which occurs due to the auto enzymatic degeneration of the body tissue.

Bronchiectasis: Microscopically, shows areas of fibrosis and honeycombing interspersed among normal lung parenchyma with the presence of foci of fibroblastic activity noted. Radiologically this pathology will reflect as honeycombing with predominantly a basal and a sub-pleural distribution. [1]

Bullae: Microscopically this represents an airspace which measures more than 1cm in diameter and is demarcated by a thin wall that is no greater than 1mm in thickness. Radiological appearance is a rounded focal lucency which is 1cm or more in diameter. [1]

Cavity: Microscopically refers to an area of expulsion or drainage of necrotic debris with loss of viable parenchyma to accommodate necrotic tissue and may be surrounded by acute or chronic inflammation or fibrosis. Radiologically this refers to a gas filled space which is seen as an area of lucency or low attenuation within an area of consolidation, a mass or a nodule. A fluid level may be noted. [1]

Chronic inflammation: Prolonged period of inflammation (weeks/months) where there is simultaneous and active processes of inflammation, tissue injury and repair. For the purpose of this study chronic inflammation is further defined as any chronic parenchymal infection of the lung (pneumonia). Microscopically represented by the presence of chronic inflammatory cells and features of organization.

Consolidation: Microscopically an exudate or other inflammatory product which replaces alveolar air. Radiological appearance is as a homogenous increase in pulmonary parenchymal attenuation that obscures the margins of the vessels and airways. [1]

Correlation: Any relationship between two measured variables which is measured by strength. No causation is implied.

Diffuse alveolar damage: A progressive inflammatory process which microscopically is initially characterised by oedema and hyaline membrane formation, and later by alveolar and/or interstitial

organization. Radiologically this correlates in the initial phase with ground glass opacities and in the organizing phase with traction bronchiectasis, cysts and reticular pattern of opacities. [1]

Emphysema: Microscopically this is the permanent dilatation/enlargement of the airspaces distal to the terminal bronchioles with destruction of the alveolar walls. The radiological appearance consists of focal areas of low attenuation. [1]

Granulomas: Microscopically evidenced by aggregates of activated macrophages that assumes an epithelioid appearance and may be associated with fibrosis.

Ground glass opacity: Radiological appearance of hazy increased lung opacity which is usually extensive, and within which the pulmonary vessel margins may be indistinct. [1]

Kappa coefficient: a statistical measure of inter-rater agreement and a measure of the strength of relationships between variables compared. A value below 0 indicates no agreement. A value between 0 and 1 indicates some agreement with a value of 1 indicating absolute agreement between variables.

Mass: Radiologically refers to any pleural, pulmonary parenchymal or mediastinal lesion which is greater than 3cm in diameter and may appear as a solid or semi-solid opacity with varying degrees of attenuation. [1]

Parenchyma: Refers to the gas-exchanging part of the lung, consisting of the alveoli and the capillaries. [1]

Predictive value: is the proportion of positive (PPV) or negative (NPV) results in diagnostic tests that are true positives and true negatives respectively.

Pulmonary interstitial emphysema: Microscopically characterized by the air dissecting within the lung interstitium, typically in the peri-bronchovascular sheaths, interlobular septa and the visceral pleura. Radiologically this pathology may appear as perivascular lucent or low attenuating halos and small cysts. [1]

Reticular nodular pattern: Radiologically refers to the summation of points of intersection of innumerable lines, creating the effect of super-imposed nodules. [1]

Reticular pattern: Radiologically refers to a collection of innumerable small linear opacities that by summation produce an appearance resembling a net. Also known as reticulation. [1]

Sensitivity: Also known as true positive rate, measures the proportion of actual positives which are correctly identified as such.

Specificity: Also known as true negative rate, measures the proportion of negatives which are correctly identified as such.

Chapter 1- Introduction

The LODOX Statscan machine is a LOw DOse X-ray (LODOX) device that was developed in South Africa by diamond mining company De Beers, as a screening tool for the prevention of the theft of uncut diamonds by mining staff. [2, 3] The scanner generates high quality digital radiological images of the body which, for a full body scan, can be achieved in approximately thirteen (13) seconds. [4] This efficiency of time and minimal radiation risk, as well as the quality of the digital images and the reproducibility of the data, has allowed for the worldwide approval of the LODOX scanning system for clinical diagnostic purposes. Currently, in South Africa, the technology is well established in the clinical, trauma and forensic settings.

In the field of Forensic Pathology, the utilization of radiological scanning has proved fruitful in the detection of skeletal injuries and foreign bodies, and assists with identification of decomposed remains via skeletal surveying. With the introduction of the LODOX scanning system into forensic mortuaries in the Western Cape in 2007, there has been a shift in favour of the LODOX, as opposed to the conventional X-ray machines. Despite the undisputable advantages of the LODOX in skeletal surveying and foreign body detection, there has been an increasing interest in the ability of the LODOX to accurately detect soft tissue pathology [5, 6].

Traditional X-rays, the Computerized Tomography (CT) and Magnetic Resonance Imaging (MRI) machines have been used in the detection of soft tissue or organ pathology. [7, 8] The “virtopsy” concept is one where extensive radiological investigation allows for CT and MRI 3D reconstruction of the corpse without the need for invasive exposure and evisceration. [7, 8] Admittedly, published data has shown that discrepancies, sometimes significant, exist between the findings of high resolution imaging and the traditional autopsy. [9]

In the resource-limited setting of South Africa, the widespread use of costly CT and MRI technology is outside the scope of most forensic mortuaries, although radiological screening of corpses may result in the detection of significant pathologies which may avert the performance of an autopsy. Hence alternatives to these costly procedures need to be sought. [10]

In our setting, the causes of sudden death are often attributed to pathology within the cardiorespiratory system e.g. myocardial infarction and pneumonia. The significance of soft tissue changes in the appearance of LODOX digital images of the lungs of deceased adults and the correlation of these changes with histopathological findings has not been reported in the current literature. This study aimed to compare digital radiological images obtained via a LODOX Statscan device with histological sections obtained from the lungs of decedents undergoing medico-legal autopsy at Tygerberg Forensic Pathology Service (FPS) facility.

Chapter 2: Literature Review

2.1 Introduction

In November 1895 the first X-ray images were accidentally discovered by a German physicist Wilhelm Conrad Röntgen. Since then the use of X-rays in medicine for both diagnostic and therapeutic purposes has increased exponentially. [11] The images supplied by diagnostic X-ray machines have allowed physicians to non-invasively view the skeletal structures and some soft tissues of living subjects. This has in turn allowed significant advances in the field of orthopaedics and the development of the specialist field of radiology.

However, before the discovery of X-rays and the development of advanced medical imaging devices, the autopsy was the only definitive manner in which the internal structure of the body - anatomy and pathology - could be viewed. Ancient civilizations established the autopsy as a cornerstone to medical teaching and advances in clinical disciplines has been pioneered using cadaveric studies. The word autopsy originated from a Greek word ‘autopsia’ which means to “see with one’s own eyes”. The autopsy has allowed not only for the study of life and biological systems but also for the establishment or formulation of the cause of death. In recent times autopsy examination comprises a review of the clinical history of the deceased, a thorough external examination, evisceration and dissection of internal organs for macroscopic observation of injury or pathology and further histopathological examination if necessary. Modern medical advances, including radiological examinations and laboratory-based diagnostic tests, have become necessary adjuncts to the post mortem examination and the final cause of death determination.

2.2 Detailed literature review

Accurately determining the cause of death may assist the family of the deceased with the bereavement process; provide information regarding genetic conditions and infectious diseases such as Tuberculosis, and assist with death benefit and insurance claims. The determination of the true cause of death is also vital to society as it improves accuracy of death statistics and provides a mechanism whereby health services and interventions can be audited and disease processes can be monitored. In addition, a medico-legal autopsy service is an essential service in any modern society for the purposes of:

- i) determination of cause, manner and mechanism of death;
- ii) determination of time of death,

- iii) collection of evidentiary specimens,
- iv) determination of the relationship of findings to acts of commission or omission and for
- v) recording of findings in a comprehensive report for access to necessary stakeholders, in order to facilitate the administration of justice.

There has been a general decline in autopsy rates worldwide in the past three decades, except for the United Kingdom where autopsy rates have remained surprisingly high at approximately 22% of all deaths. [7, 9]

The most common cause of this decline is the physicians' unwillingness to request permission from the next-of-kin, an increasing fear of medical malpractice litigation and an unawareness of the medico-legal parameters which permit autopsy examination without consent. Other factors include: the cost of the autopsy examination and the subsequent toxicological and histological examinations, the biological and physical risks associated with autopsy examination, religious beliefs and cultural traditions and controversial organ-retention scandals that negatively impacted the hospital autopsy services in some countries, such as the United Kingdom. [7, 9]

In a study conducted by Sieswerda-Hoogendoorn and van Rijn relating to the techniques in paediatric post mortem imaging the authors comment that:

'...perhaps the most important reason for the decline in autopsies is the fact that, with increasing diagnostic and imaging techniques, both doctors and parents/guardians are under the assumption that they already know the cause of death.' [12]

Hence cases are not readily referred for post mortem examination and histopathological correlation of clinical diagnosis is not made.

In contrast, sometimes "unnecessary" post mortem examinations are conducted, as highlighted by Tiemensma and Burger in a study which reviewed the causes of sudden unexpected deaths in an adult population over a 5 year period in a resource-limited environment in Cape Town, South Africa. Here the authors noted that many cases with underlying natural causes of death were subjected to full post mortem examination due to the lack of pre-autopsy information. Most pathologists are confident in making a diagnosis based on the clinical history and the findings at external examination alone when these features are overwhelmingly obvious e.g. a history of persistent cough, night sweats and loss of weight in a decedent who is known to be immune-compromised and who is emaciated with physical signs of chronic illness, can confidently be attributed to Tuberculosis with underlying HIV

infection in the South African setting where these diseases are prevalent. Many authors agree that pre-autopsy radiological screening may help to avoid the performance of unnecessary post mortem examinations as well as to help guide the pathologist in specimen collection in areas which require further examination. [10]

In 2005 Roulsen *et al* published the findings of a large meta-analysis of 18 papers which reviewed the discrepancies between clinical and autopsy diagnosis and the value of post mortem histology. [13] Discrepancy rates ranged from 30-63% in four of the studies which looked specifically at the cause of death. Pulmonary embolism, cardiovascular disease and pneumonia were the conditions that showed the greatest diagnostic discrepancy. The study also showed that diagnostic tests gave misleading results in 3-6% of surgical cases despite these tests being appropriately indicated and administered. Interestingly, the review showed that 0.7% of 541 conventional radiological procedures and 3% of 157 CT scans, ultrasound and other high resolution examinations produced discrepant results. It is therefore noted that plain radiological films are superior in that they have a lower discrepancy rates in comparison to high resolution films in making accurate diagnoses, with CT scans having greater sensitivity yet less specificity.

The majority of advanced forensic pathology facilities which utilize radiographic imaging machines install CT and MRI machines. The limitations of these techniques, specific to the requirements of a forensic pathology service, include the inability to distinguish certain medical conditions, e.g. pneumonia, the difficulty in the use of contrast media in angiographic studies and the need for advanced operators/technicians. Additionally, the images would have to be reported on by a specialist radiologist which has additional cost and resource implications over and above the initial installation costs. In South Africa, health budget constraints inhibit the widespread use of MRI and CT scanning, even in the clinical setting, with these facilities not available for forensic pathology services. The majority of forensic mortuaries/laboratories that have access to imaging modalities have only conventional X-ray machines at the radiology department of the designated regional hospital as an option. Only few central mortuaries/laboratories have in-house X-ray facilities.

The disadvantages of traditional X-ray machines are the need for additional operator staff and the continuous exposure of staff to high doses X-rays which pose a significant additional occupational health hazard. Only few medico-legal facilities in South Africa have installed the LODOX Statscan system with the emphasis on the detection of radio-opaque foreign bodies and the review of skeletal structures for pathology or injury. [5, 6] At the end of

October 2014, four forensic mortuaries in South Africa had LODOX machines, with 10 installed in forensic facilities worldwide [14]

In a review article Whiley *et al* note that the LODOX has many applications in the non-trauma setting. [15] An observation made by Pitcher *et al* during review of the use of the Statscan in the evaluation of poly trauma in the paediatric population in Johannesburg, South Africa, was that the LODOX Statscan displayed: “excellent visualization of the main bronchi” which allows for detection of proximal bronchial abnormalities such as mediastinal lymphadenopathy. [16] This provides one of the first reported advantages of the ability of the Statscan to detect soft tissue abnormalities which may indicate clinically significant pathology.

A study conducted by Douglas *et al* reviewed the utility of full body radiography in cases of sudden unexpected death in infancy (SUDI) at the Salt River Forensic Pathology Laboratory in Cape Town, South Africa during 2008. [6] One hundred and ninety-two (192) cases referred as SUDI were included in the study, all of which had anterior-posterior radiographs taken using the LODOX Statscan radiography system. Of the seventy one cases that did not have autopsy examination 45% were found to have documented evidence of pathology on imaging. Autopsy examination was performed in the remaining 121 cases of which 18% showed correlation between autopsy results and pathology detected on imaging. The image findings described ranged from opacification and consolidation in the lung fields, air bronchograms and obscured heart margins. These findings were described as “correlating” with the autopsy findings of pneumonia and congenital heart disease. In contrast, a similar study conducted by De Lange *et al* [5] showed poor agreement between autopsy findings and pulmonary pathology found in infants referred for radiographic imaging.

A limitation of the study by Douglas was that there was no correlation/confirmation of the radiological diagnosis in the 71 cases that did not have an autopsy. Also, a retrospective review of the radiological findings in a setting where no standard operating procedure exists for the interpretation of those findings by forensic pathologists, may result in erroneous reporting.

Notably, the only study which relates specifically to post mortem radiological imaging using LODOX scanning in the forensic setting has a paediatric population. [6] No studies have yet reviewed findings in the adult autopsy population. This is significant, since the findings of a paediatric population cannot be compared and extrapolated to those of an adult population. Radiological findings in the lung fields of infants are more likely to relate to recent or current pathology, whereas the changes in the lung fields of adults may be related to acute, sub-acute or chronic pathology and disease. Adults are more likely to show evidence of old, fibrotic

lesions on X-ray which may or may not be of forensic significance in the formulation of the cause of death. The anatomical differences between adults and children are obvious, with lung size and chest cavity dimensions significantly different and their varying levels of maturity expose them to a vastly different set of pathologies as well as varying mechanisms of pulmonary injury.

Additionally, the effect of the post mortem interval (the interval from the time of death to the performance of the post mortem) needs to be considered, as many reports have commented on the presence of post mortem artefacts affecting the interpretation of the radiological changes. A significant shortcoming of the afore-mentioned studies is that they have all been retrospective reviews of radiological and autopsy data. De Lange *et al* conceded that a "...prospective study is needed to clarify these correlations further" in respect of radiological and histological reporting." [5]

This sentiment has been echoed by multiple authors and the prospective study is the optimal study design as it allows for the screening of cases prior to investigation so as to facilitate optimal data collection. [5, 6, 17] This is important in our laboratory, as not all cases referred for medico-legal autopsy undergo complete autopsy examination, radiological imaging or histological examination. Therefore, criteria need to be set to standardize the data collection process. Also, except for cases of Non-Accidental Injury (NAI) in children, radiological images are not always independently reviewed by consultant radiologists and the quality and findings of the images are determined by the pathologist. At the time of the study no standardized protocol existed within our laboratory for the interpretation and recording of radiological findings, which would also make a retrospective study difficult, as a complete, continuous data set is not readily available for review.

2.3 Problem statement

The literature highlights the need for further investigation into the ability of the LODOX Statscan to detect soft tissue pathology. There are currently no studies which have addressed this problem by prospective study. Theodore Harcke of the Forensic Radiology Division of the Armed Forces Institute of Pathology stated that:

"It would be a mistake to do post mortem imaging without autopsy correlation until the findings and accuracy of imaging are validated by careful study."[18]

Determining whether correlation exists would enable forensic practitioners to utilize the LODOX as a screening tool. This may assist with either reducing invasive post mortem examination or guiding specimen collection.

2.4 Aim of the study

This study aims to be a preliminary prospective investigation into the correlation of the findings on LODOX imaging with the macroscopic and microscopic variables detected in the lung of decedents presenting for autopsy at the Tygerberg Forensic Pathology Services mortuary.

As there are no other studies to which to compare the findings of this study, the method of statistical evaluation was matched with the conventional method of reporting of traditional X-ray studies. Thus the primary outcome was to determine whether radiological patterns predicted by LODOX imaging correlated with macroscopic and microscopic pathology and to determine the sensitivity and specificity. The secondary outcomes included the determination of the positive and negative predictive values.

Chapter 3: Method

3.1. Study Design

This study is a prospective radiologic-pathologic autopsy correlation study.

3.2. Population

This study aimed to compare digital radiological images obtained via a LODOX Statscan with the macroscopic and histological sections obtained from the lungs of decedents undergoing medico-legal autopsy at Tygerberg FPS during the period of November 2012 to March 2013. Autopsy data for 2010 and 2011 at the Tygerberg facility was reviewed in order to determine the estimated size of proposed study population with an emphasis on the following categories:

- A. Total number of referrals with a history of sudden unexpected death and the number of which proceeded to complete autopsy examination
- B. Total number of referrals with a history of hospital admission and the total number that proceeded to complete autopsy examination.

The total number of cases which fit these criteria amounted to 83 and 92 cases in 2010 and 2011 respectively, with a mean of 86 cases. According to the retrospective study conducted by Tiemensma and Burger at the Tygerberg Medico-Legal Forensic Laboratory, 74.4% of cases referred as sudden unexpected death proceeded to full autopsy examination. In their study this accounted for 601/816 cases, *which meet the inclusion criteria for this study*, undergoing medico-legal autopsy examination over a five year period -, with an average of 120 cases per annum. [10] This study aimed to prospectively review cases for approximately 6 months, which we estimated to amount to approximately 100 cases. This number of cases was deemed appropriate for statistical analysis.

3.3. Case Selection

Cases which met the following criteria were included:

- Cases referred for medico-legal autopsy according to the regulations of section 3(2) of the Inquests Act (Act 58 of 1959), wherein radiology as well as histology was indicated to ascertain the cause of death with more certainty.

Cases were excluded as follows:

- Cases referred for medico-legal autopsy according to the regulations of section 3(2) of the Inquests Act (Act 58 of 1959), where the age of the decedent was less than 12 years.

- Cases of traumatic death (e.g. gunshot wounds, assaults, vehicular accidents) where death occurred immediately.
- Decedents where the post mortem interval was beyond 5 days to exclude the effect of post mortem changes on adequate radiological and histopathological evaluation.

3.4. Outcome measures

The primary outcome was to determine whether radiological patterns predicted by LODOX imaging correlated with macroscopic and microscopic pathology, and to determine the sensitivity and specificity of these predictions.

The secondary outcomes included the determination of the positive and negative predictive values.

Additional outcomes included the determination of the extent of disease and correlation with radiological appearances.

3.5. Data Collection

The data collection period began in November 2012 and was completed in March 2013. Statistical analysis was undertaken after all data was available for evaluation. This allowed for the comparison of variables across the various phases (see description of phases below). All scientific evaluation was performed using standardised reporting templates which were developed during the formulation of the study protocol. (Annexure A, B)

The study comprised three phases of data collection for cases which met the criteria to be included in the study. These phases included:

3.5.1 Post mortem digital radiographic images:

- i. Radiologic scanning utilizing the LODOX Statscan was performed on the day of autopsy prior to the external examination.
- ii. All cases in the study population underwent anterior-posterior (AP) view X-ray imaging. Lateral views were also taken, however cases that did not have lateral views due to technical difficulties, were not excluded from evaluation.
- iii. The personal information of the deceased was not displayed on the LODOX digital image. Instead a unique study number was allocated and digitally annotated before images were submitted to the radiologist.

- iv. The images were digitally transferred to a consultant radiologist who reviewed and reported on the images.
- v. The images were sent in bulk DICOM format to facilitate ease of electronic transfer.
- vi. The radiologist was blinded to both the macroscopic autopsy and histological findings.
- vii. The methodology of reporting included a standardized template developed and modified for the purposes of autopsy reporting.[19]

3.5.2. Macroscopic evaluation and retrieval of histological specimens:

- i. Histological specimens were collected by the principal investigator on each day of the study period (Monday to Friday) at the Tygerberg Medico-legal mortuary.
- ii. Each case received a study number, which correlated with the LODOX study number, before processing.
- iii. The weight of the individual lungs was measured and recorded.
- iv. The histological specimens taken included a section from each individual lung lobe in the region of pathology, where applicable. This resulted in a minimum of 5 tissue cassettes being collected for each case.

3.5.3 Histopathological reports:

- i. Histological review of slides was performed by the principal investigator and the supervisor. Both investigators were blinded to the formal radiologist report and to the macroscopic autopsy findings. In cases of doubt regarding the findings, the assistance of an independent histopathologist was available.
- ii. Tissue sample cassettes were processed at the Division of Forensic Pathology as routine specimens to produce microscopic slides.
- iii. The methodology of reporting included a standardized checklist modified for the purposes of this study. (Appendix B)[20].
- iv. The histopathology reports were recorded according to the study number allocated to the specimen.

3.6 Continuity measures

In the event that the principal investigator was not available to collect specimens, the other medical staff in the division had agreed to continue the collection of specimens. Training and revision of the collection techniques was done before and regularly during the course of the data collection period. There was no instance where this contingency method was employed.

3.7 Statistical analysis

In statistical terminology “correlation” is a measure of association between discrete variables. In this study the term is used as a general term to describe the relationship between the radiological and pathological datasets. As there is no other comparative study utilizing LODOX, it was deemed prudent to report, where possible, on the sensitivity and specificity of this modality. This can then be compared with conventional X-rays and other image modalities.

Despite this study being exploratory, in order to scientifically evaluate the datasets, a proposed null hypothesis was adopted that postulated that: “there is no relationship/correlation between variables predicted by LODOX images and the macroscopic and microscopic variables”.

Two-by-two contingency table statistical analysis was conducted to examine whether there was a relationship between the variables measured by LODOX and the variables observed macroscopically and microscopically. Chi-square and Fisher exact, one-tailed p -values were obtained and the conventional value for statistical significance ($p < 0.05$) was employed. Once statistical significance was present, the determination of the sensitivity, specificity, positive and negative predictive values was determined. Additionally, the strength of relationships between the variables compared was evaluated via the Kappa coefficient. Here a value < 0 indicates no agreement whereas a value > 0 indicates increasing degrees of agreement to a maximum absolute agreement value of 1.

For the interpretation of the contingency table analysis, one of the data sets has to be deemed the “ x ” or unknown variable which is compared with a “ y ”, “known” or “gold standard” variable. In this case the LODOX variables were the always considered the “ x ” variable. For the contingency table analysis of the LODOX versus microscopy, the macroscopic features were considered the “gold standard”. For the contingency table analysis of the LODOX versus microscopy, the microscopic features were considered the “gold standard”. This is in keeping with the international standard that the autopsy and its investigations are the diagnostic gold standard.

For all evaluations the LODOX was the “test” variable.

3.8 Ethics

In accordance with the Inquests Act No 58 of 1959, the protocol in the division of Forensic Medicine at Tygerberg is to collect any and all specimens/perform all tests that may be required to ascertain with more certainty the cause of death. This may include the retention of

tissue and radiologic tests in cases of sudden unexpected death. All tissue taken was marked with the allocated study number. No personal identifiers were available to laboratory personnel. The identity of the deceased was protected by a liaison officer in the division of Forensic Medicine (Mrs. AEJ Riley).

Ethics approval and waiver of family consent for the use of the material in this study was granted by the University of Stellenbosch, Health Research Ethics Committee (HREC). The approval number was **S12/08/225**. The request for waiver of family consent was made as no new testing modality was conducted – the procedure followed in the division was not to be deviated from. The tests already formed part of the divisional protocol and therefore constituted statutory mandate under section 3(a) of the Inquests Act as mentioned *supra*.

Further ethical issues:

- Information used in the study was allocated anonymous study numbers which were continuous for all three of the datasets.
- Data stored on computers were password protected by standard encryption measures.
- All data sheets and files will be destroyed after the study.
- The information obtained in the research and the outcomes of the study will have no impact on the deceased study subjects or their relatives.

3.9 Conclusion:

This study is a prospective radiologic-pathologic autopsy study which aims to evaluate the correlation of the LODOX Statscan with macroscopic and microscopic variables obtained from evaluation of the lungs of decedents during medico-legal post mortem examination.

Chapter 4: Results: General Findings

4.1 Introduction

The study comprised three phases of data collection for cases which met the criteria to be included in the study. Phase one involved the collection of LODOX images and the reporting of results by the radiologist and the second phase involved macroscopic evaluation of the lungs and the retrieval of specimens during the autopsy. Phase three involved the laboratory generation of histological slides stained with Haematoxylin and Eosin (H&E) and the microscopic evaluation thereof.

All dataset evaluations were performed using standardised reporting templates which were developed during the formulation of the study protocol. (Annexure A, B) The data collection period began in November 2012 and was completed in March 2013. Statistical analysis was undertaken after all data was available for evaluation. This allowed for the comparison of variables across the various phases.

The first phase of evaluation relates to the general findings from the data retrieved in each phase of the data collection.

4.2 General demographic data evaluation

One hundred and fifty nine (159) cases were included in the study. The male-to-female ratio was 2:1 (105:54). For males the mean age was 46.2 ± 15.8 years and for females 44.5 ± 19.0 years.

Table 4.1, below, demonstrates the distribution of the underlying cause of death in the cases which were deemed to be “natural”. The majority of deaths were due to cardiovascular pathology, while respiratory disease accounted for 13 (21.7%) of the 60 cases. Pneumonia (lobar, bronchopneumonia, etc.) was the most common lower respiratory pathology recorded as the cause of death in natural cases.

The most commonly recorded cause of death was related to coronary artery atherosclerosis and atherosclerosis of other major vessels. This pathology was found in a third of all cases deemed as “natural”.

In 3 cases the immediate cause of death was not ascribed to any body system or specific pathology but the underlying cause of death was deemed to be “natural”. These cases could not be correctly classified.

Table 4.1: Distribution of pathology in cases where the cause of death was due to natural pathology	
CAUSE OF DEATH	NO. OF CASES (%)
CARDIOVASCULAR PATHOLOGY	30 (50.0%)
Coronary artery disease/IHD	20 (33.3%)
Atherosclerosis and its complications	4 (6.7%)
Cor pulmonale	2 (3.3%)
Myocarditis	2 (3.3%)
Ruptured Abdominal aortic aneurysm	1 (1.7%)
Not specified	1 (1.7%)
REPIRATORY TRACT PATHOLOGY	13 (21.7%)
Pneumonia	5 (8.3%)
Cavitatory lung disease	4 (6.7%)
Asthma	1 (1.7%)
Bullous lung disease	1 (1.7%)
Pulmonary Tuberculosis	1 (1.7%)
Acute epiglottitis	1 (1.7%)
OTHER	14 (23.3%)
Malignancy	3 (5.0%)
Pyelonephritis	2 (3.3%)
Intra-cerebral haemorrhage	2 (3.3%)
Cardiac and respiratory complications of SLE	1 (1.7%)
Generalised viremia	1 (1.7%)
Colloid cyst of the brain	1 (1.7%)
Bowel obstruction	1 (1.7%)
Bacterial meningitis	1 (1.7%)
Epilepsy	1 (1.7%)
Hydrocephalus	1 (1.7%)
UNDETRMINED NATURAL CAUSE	3 (5.0%)
TOTAL NUMBER OF NATURAL CASES	60 (100%)

Table 4.2 tabulates the comparison between the immediate or underlying respiratory causes of death, as stated on the final autopsy report, and the changes reported on LODOX radiological evaluation. Ground glass opacities and consolidation were the 2 most common patterns noted in cases where respiratory conditions were the cause of death.

Table 4.2: Comparison of respiratory cause of death with findings reported on LODOX images for individual cases.		
Case	Cause of death	LODOX features
1	Pneumonia	Ground glass opacification in all lobes
2	Cavitary lung disease	Bullae, consolidation, Bronchial wall thickening
3	Asthma	Ground glass opacification; air in jugular veins, pneumo-pericardium
4	Bullous lung disease	Tension pneumothorax left
5	Pulmonary Tuberculosis	Reticular pattern
6	Cavitary lung disease	Bullae, fibrosis, consolidation; loculated pneumothorax
7	Lobar pneumonia	Ground glass opacification; consolidation
8	Lung abscess	Consolidation; bullae
9	Lower respiratory tract infection	Normal
10	Atypical pneumonia	Consolidation
11	Massive haemoptysis due to cavitary lung disease	Bullae; ground glass opacities
12	Lobar pneumonia	Ground glass opacification in all lobes; pneumo-pericardium
13	Acute epiglottitis	Consolidation and Bronchial wall thickening

4.3 General LODOX/radiological data evaluation

During the study one hundred and fifty nine (159) cases met the aforementioned inclusion criteria and underwent LODOX radiological scanning. All the cases underwent full body scanning in the anterior-posterior (AP) position. One hundred and fifty one (151) cases had LODOX radiological scanning in the right lateral position as well. Eight cases did not have lateral views performed as the rotating C-arm of the LODOX machine was non-functional for two days during the study period and no lateral views could be obtained.

All the cases underwent radiologist review during which only 5 cases of the total 159 cases were deemed inadequate for evaluation. Thus a final total of 154 cases underwent radiologist reporting using the standardized template with reports made for each lobe. Hence, seven

hundred and seventy (770) individual radiological assessments were made. The following Figures 4.1 to 4.5 demonstrate the frequency of radiological findings in each of the lung lobes.

The two most common radiological findings were the presence of a ground glass pattern (mean = 46.6%) and consolidation (mean =22.3%). The ground glass pattern was noted predominantly in the right upper lobe (75/154 cases or 49%) and consolidation in the left lower lobe (48/154 cases or 31%).

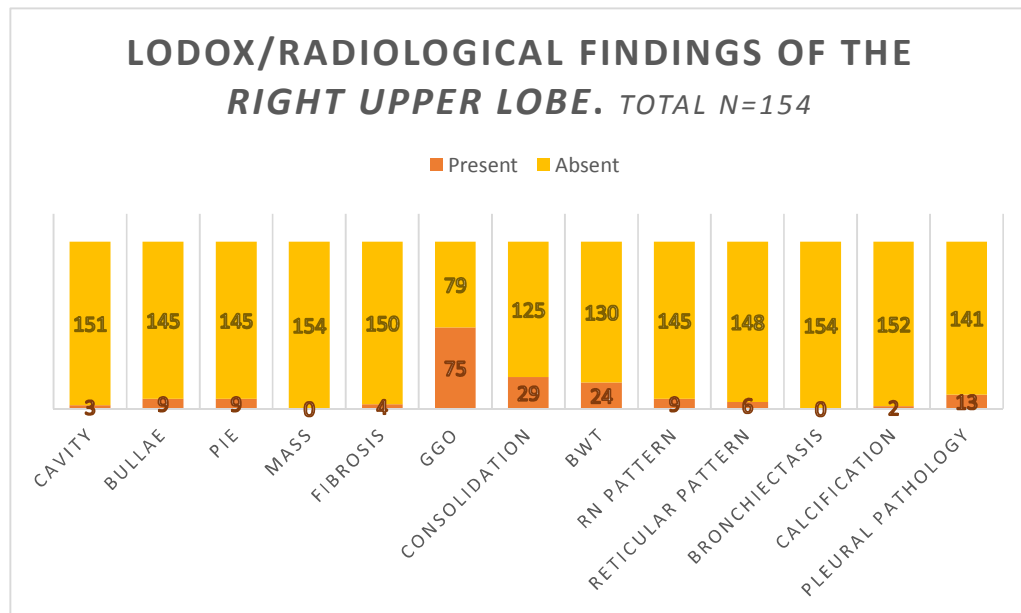


Figure 4.1: LODOX/Radiological findings for the **right upper lobe**. PIE=Pulmonary Interstitial Emphysema; GGO = Ground Glass Opacification; BWT = Bronchial Wall Thickening; RN = Reticular-Nodular pattern

The least common variable reported on radiological evaluation was the presence of a mass, which was only reported in 2 of 154 cases; one lesion in the right lower lobe and the other in the left upper lobe. Only 4 of the 770 evaluations (0.5%) reported the presence of bronchiectasis with both the upper lobes not being affected. Seven of seven hundred and seventy (7/770; 1%) evaluations showed the presence of radiologically detectable cavity formation. The right upper lobe was the most commonly affected with 3 positive reports. There were no reports of thrombosis noted.

Bronchial wall thickening had an average percentage frequency of 15.3%. Pleural pathology was reported in 6-8% (mean =7.1%) of the cases and comprised the findings of pneumothorax, pleural effusions, pleural thickening and pleural plaques. The presence of a pneumothorax was the most commonly reported pleural pathology.

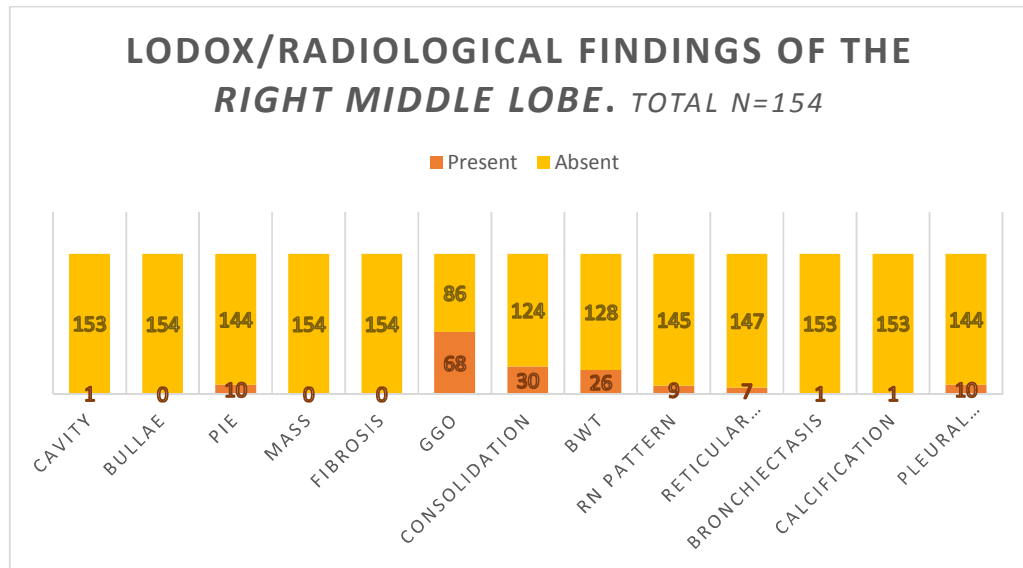


Figure 4.2: LODOX/Radiological finding for the **right middle lobe**. PIE= Pulmonary Interstitial Emphysema; GGO= Ground Glass Opacification; BWT= Bronchial Wall Thickening; RN pattern = Reticular-Nodular pattern.

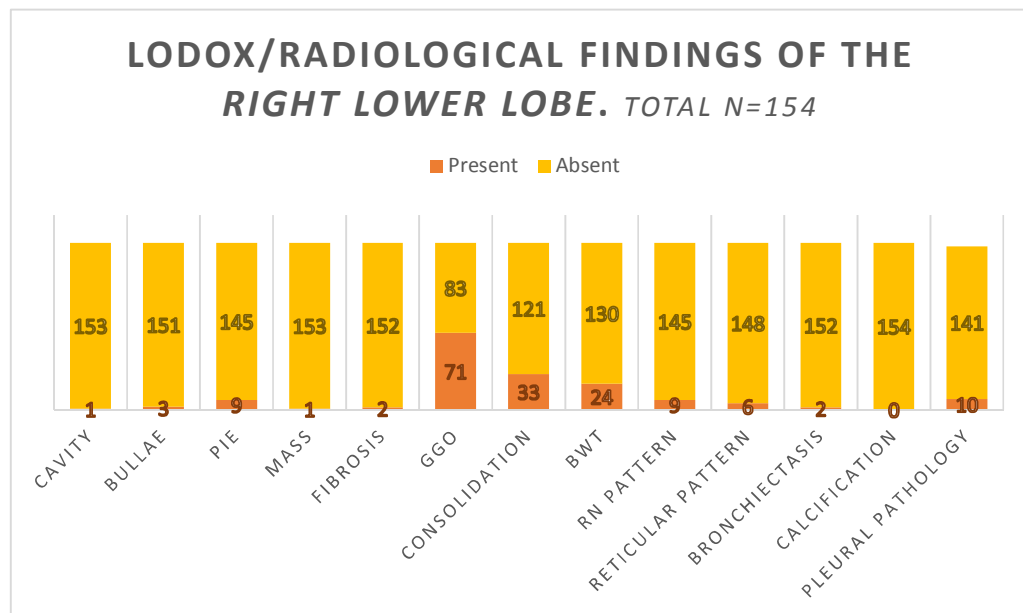


Figure 4.3: LODOX/Radiological findings for the **right lower lobe**. PIE= Pulmonary Interstitial Emphysema; GGO = Ground Glass Opacification; BWT = Bronchial Wall Thickening; RN pattern = Reticular-Nodular Pattern

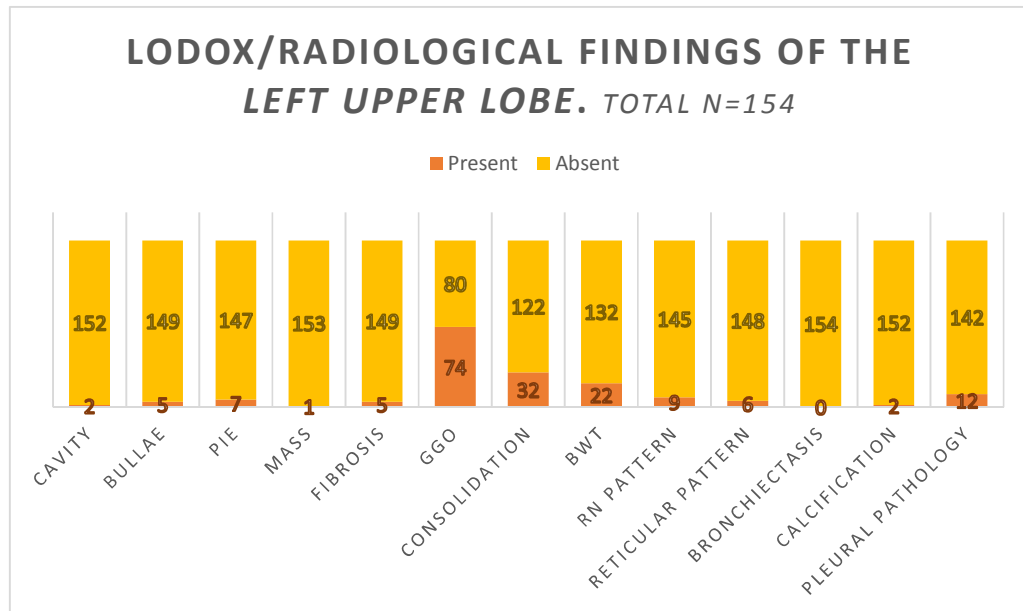


Figure 4.4: LODOX/Radiological findings for the **left upper lobe**. PIE= Pulmonary Interstitial Emphysema; GGO = Ground Glass Opacification; BWT = Bronchial Wall Thickening; RN pattern = Reticular-Nodular Pattern

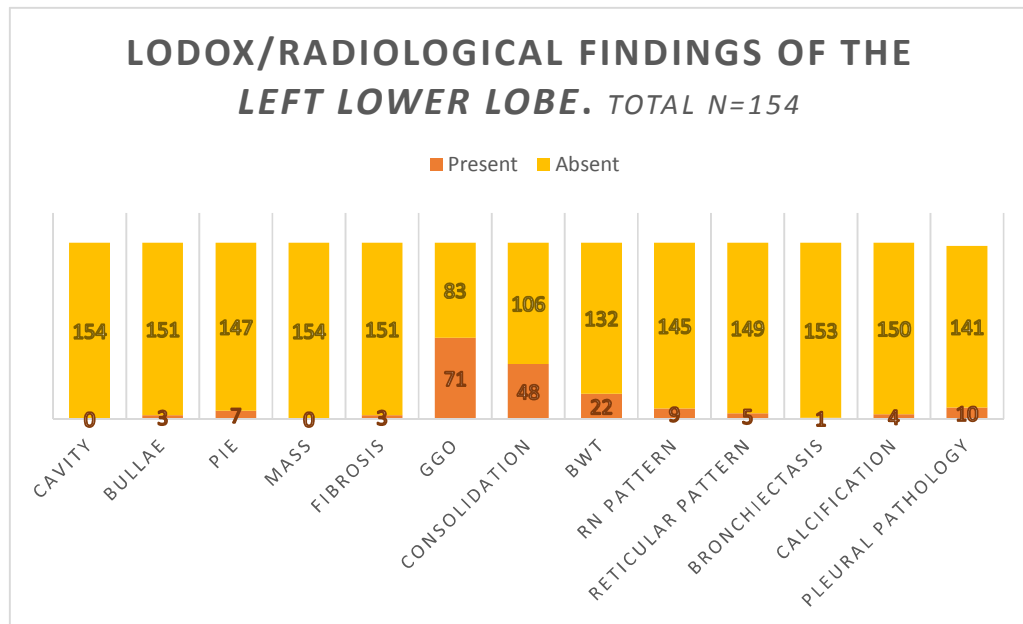


Figure 4.5: LODOLOX/Radiological findings for the **left lower lobe**. PIE= Pulmonary Interstitial Emphysema; GGO = Ground Glass Opacification; BWT = Bronchial Wall Thickening; RN pattern = Reticular-Nodular Pattern

4.4 General macroscopic data evaluation

All cases which met the inclusion criteria during the study period were evaluated macroscopically according to the reporting template. One hundred and fifty nine (159) cases were reported on. There were no cases which were excluded from evaluation. During the autopsy examination the weight of each lung was recorded and the results are depicted in Table 4.2 below:

Table 4.3. Average lung weights of the individual lungs. g=grams		
	Right lung (±SD)	Left Lung (±SD)
Average weight (n=154)	746 ± 220g	584 ± 210g
Molina reference lung weights [24]	445±159g	395±147g

In addition, the following variables were evaluated for their presence or absence macroscopically: cavitation; oedema; emphysema; granulomas; acute inflammatory changes; chronic inflammatory changes; features of diffuse alveolar damage; intra-alveolar haemorrhage and pleural pathology in the category marked as “other”.

For the purposes of this study acute inflammation was the macroscopic finding of serous, fibrinous or purulent inflammatory exudates in the lung parenchyma or the airways, features of acute pneumonic parenchymal changes (soft and friable) with abundant exudate and no features of organization. Chronic inflammation was described as pneumonia with features of grey hepatisation or consolidation where the lung was firm and liver-like with less oedema and more features of organization. Macroscopically, features of Diffuse Alveolar Damage (DAD) were described as heavy, firm, airless lungs which were waterlogged on cut section.

The most common macroscopic feature reported was oedema, which was recorded in 91.9% of cases. [Table 4.4] All the lobes were equally affected (range 91-93%). Acute inflammation was the second most commonly reported finding (27.4%), and was more commonly reported in the left lower lobe. Features of chronic inflammation, DAD and emphysema were also commonly encountered.

Less than 1% of cases showed the presence of autolysis and thrombosis. A tumour mass and bronchiectasis was noted in 0.25% and 0.13% of cases respectively.

Table 4.4. Frequency of positive findings on the macroscopic evaluation.						
Macroscopic variable evaluated	Site of evaluation					
	RUL n=159	RML n=159	RLL n=159	LUL n=159	LLL n=159	Total for all lobes (n= 795)
Oedema	147 (92%)	145 (91%)	148 (93%)	145 (91%)	146 (92%)	731 (91.9%)
Acute inflammation	43 (27%)	46 (29%)	49 (31%)	37 (23%)	43 (27%)	218 (27.4%)
Chronic inflammation	30 (19%)	33 (21%)	27 (17%)	27 (17%)	23 (14%)	140 (17.6%)
*DAD	21 (13%)	22 (14%)	20 (13%)	23 (14%)	23 (15%)	109 (13.7%)
Emphysema	30 (19%)	11 (7%)	12 (8%)	22 (14%)	7 (4%)	79 (9.9%)
Granulomas	18 (11%)	12 (8%)	12 (8%)	18 (11%)	13 (8%)	73 (9.8%)
Pleural pathology	9 (6%)	7 (4%)	5 (3%)	9 (6%)	9 (6%)	39 (4.9%)
** IAH	3 (2%)	2 (1%)	10 (6%)	4 (3%)	6 (4%)	25 (3.1%)
Cavity	7 (4%)	3(2%)	3 (2%)	6 (4%)	3(2%)	22 (2.8%)
Autolysis	2 (1%)	2 (1%)	2 (1%)	2 (1%)	2 (1%)	10 (1.3%)
Thrombus	3 (2%)	0	0	3 (2%)	2 (1%)	8 (1.0 %)
Mass	0	1 (1%)	0	1 (1%)	0	2 (0.25%)
Bronchiectasis	0	0	1 (1%)	0	0	1 (0.13%)
* DAD=Diffuse alveolar damage (features of); ** IAH =Intra alveolar haemorrhage						

4.5 General microscopic data evaluation

The dataset for the microscopic evaluation comprised 1 slide from each of the lung lobes. This resulted in 5 slides per case with a total of 795 slides generated from the 159 cases. Each

slide was stained with Haematoxylin and Eosin (H&E) and evaluated by a senior forensic pathologist and the principal investigator.

In each slide the presence of the following 15 microscopic variables was determined: cavitation, oedema, emphysema, granulomas, acute inflammation, chronic inflammation, fibrin strands, intra-alveolar haemorrhage, tumour mass, other mass, fibrosis, bronchiectasis, pleural pathology, autolysis and thrombosis. (Annexure B)

In the initial microscopic examination the following variables were histologically graded as mild, moderate and severe: oedema, emphysema, acute inflammation, chronic inflammation, fibrin strands, intra-alveolar haemorrhage and fibrosis. This grading was based on the appearance and distribution of the variable in each slide and was made by consensus evaluation by both investigators. The other variables were assessed for their presence or absence.

As depicted in Table 4.5, below, the most commonly encountered variable microscopically was oedema (mean = 79.5%; range 75-88%). Similar to the macroscopic findings, acute and chronic inflammation and emphysema were also prominent findings. Acute inflammation was noted predominantly in the right lower lobe. Intra alveolar haemorrhage was noted in 27.4% of cases with a range of 20-38% between lobes.

Cavity, the presence of a tumour mass and bronchiectasis were the three least commonly encountered variables microscopically, 1.4%, 1.4% and 1.00% respectively.

The tumour masses encountered were all malignant tumours, and were present in 11/795(1.4%) slides evaluated. These tumours involved 7 individual cases. The right middle lobe was the most commonly affected with 4/795 positive slides. The right and left lower lobes each had 2 reports of malignant tumour and the left upper lobe had 3 reports. The following tumours were identified: Squamous cell carcinoma (involving 2 individual cases), bronchoalveolar carcinoma, Carcinoid tumour, malignant lymphoid tumour and an unclassified pleomorphic malignancy (involving 2 individual cases).

The frequency of positive reports for the variable of “other mass” was 4.8%. The lesions that were included in this category included areas of nodular fibrosis, calcified cartilage, schistosoma ova, lymph node inclusions, capillary malformations and focal areas of metaplasia.

Pleural pathology and fibrosis was also reported in 7.2 % and 10.8% of cases, respectively. The respective ranges between lobes were 5-10% and 8-14%. The range of pathology found

in the pleura included: thickening of the pleura, pleural fibrosis and plaque formation, fibrino-purulent exudates, mesothelial dysplasia and a benign pleural tumour (lipoma).

Table 4.5. Frequency of positive findings on the microscopic evaluation.						
Microscopic variable evaluated	Site of evaluation					
	RUL n=159	RML n=159	RLL n=159	LUL n=159	LLL n=159	Total for all lobes (n-795)
Oedema	126 (79%)	122 (77%)	120 (88%)	135 (75%)	129 (81%)	632 (79.5%)
Emphysema	56 (35%)	64 (40%)	44 (28%)	64 (40%)	47 (30%)	275 (34.6%)
* IAH	37 (23%)	31 (20%)	61 (38%)	41 (26%)	48 (30%)	218 (27.4%)
Acute inflammation	24 (15%)	28 (18%)	42 (26%)	25 (16%)	29 (18%)	148 (18.6%)
Chronic inflammation	28 (18%)	29 (18%)	28 (18%)	20 (13%)	24 (15%)	129 (16.2%)
Fibrosis	12 (8%)	23 (14%)	19 (12%)	20 (13%)	12 (8%)	86 (10.8%)
** DAD	8 (5%)	13 (8%)	17 (11%)	11 (7%)	9 (6%)	58 (7.3%)
Pleural pathology	16 (10%)	12 (8%)	11 (7%)	10 (6%)	8 (5%)	57 (7.2%)
Autolysis	8 (5%)	10 (6%)	16 (10%)	10 (6%)	6 (4%)	50 (6.3%)
Granulomas	13 (8%)	8 (5%)	6 (4%)	10 (6%)	8 (5%)	45 (5.7%)
Other masses	12 (8%)	5 (3%)	8 (5%)	7 (4%)	6 (4%)	38 (4.8%)
Thrombus	7 (4%)	9 (6%)	8 (5%)	8 (5%)	3 (2%)	35 (4.4%)
Cavity	4 (3%)	1 (1%)	2 (1%)	3 (2%)	1 (1%)	11 (1.4%)
Mass/tumour	0	4 (3%)	2 (1%)	3 (2%)	2 (1%)	11 (1.4%)
Bronchiectasis	0	1 (1%)	2 (1%)	3 (2%)	2 (1%)	8 (1.00%)
*IAH Intra alveolar haemorrhage; * *DAD=Diffuse alveolar damage (features of)						

Chapter 5: Results: LODOX versus Macroscopic evaluation

5.1 Introduction

The correlation of radiological findings on the LODOX with macroscopic findings in the lungs of decedents was reviewed. The 2 most common LODOX patterns were of ground glass opacities and consolidation. These radiologic variables were compared with the macroscopic variables of oedema, acute inflammation, chronic inflammation, features of diffuse alveolar damage (DAD) and intra-alveolar haemorrhage (IAH).

Statistical analysis in the form of two-by-two contingency table correlation analysis was conducted to examine whether there was a relationship between the variables predicted by LODOX and the variables observed macroscopically. Chi-square and Fisher exact, one-tailed *p* values were obtained and the conventional value for statistical significance ($p < 0.05$) was employed. In the following tables the statistically significant columns are highlighted in yellow. For analysis of sensitivity and specificity the LODOX variables were considered the unknown or “x” variable and the macroscopic data findings were considered the “y”, “known” or “gold standard” for this phase of comparison.

The analysis resulted in true positive, true negative, false positive and false negative values being obtained and tabulated. In order for the analysis to be computed, the contingency tables had to have a minimum value of 10. In some instance, this minimum value was not achieved and the results could thus be not calculated (NC) for individual lung lobes. Where possible a combined statistical result was obtained for “all lobes”.

The diagnostic and clinical significance of the results are to be discussed in a successive chapter.

5.2 LODOX ground glass opacities versus macroscopic variables

Statistical analysis of the most common variables in each lung lobe was undertaken to determine if there was correlation. Ground glass opacities were present in 46.6% of LODOX images evaluated.

The most common macroscopic variable of oedema was noted in 91.9% of cases. Table 5.1 below outlines the findings regarding this comparison in the individual lung lobes. No statistically significant results were noted.

Table 5.1: LODOX ground glass opacities versus macroscopic oedema						
Parameter	Site					
	RUL	RML	RLL	LUL	LLL	All lobes
Chi square	0.26	0.50	0.56	0.88	0.99	0.76
Fischer	0.21	0.35	0.39	0.55	0.61	0.52
Kappa	0.05	0.03	-0.02	-0.01	0.00	0.01
Sensitivity	50.0%	45.0%	45.5%	47.9%	46.1%	55.5%
Specificity	66.7%	64.3%	45.5%	50.0%	53.9%	50.0%
*PPV	94.7%	92.7%	91.6%	90.5%	91.6%	95.3%
**NPV	10.1%	10.5%	6.0%	8.8%	8.4%	5.8%
*PPV= Positive predictive value; ** NPV = Negative predictive value						

Acute inflammation was noted, on average, in 27.4% of macroscopic evaluations. Table 5.2 depicts the comparison of the LODOX variable of ground glass opacities with the macroscopic appearance of acute inflammation.

Table 5.2: LODOX ground glass opacities versus macroscopic acute inflammation.						
Parameter	Site					
	RUL	RML	RLL	LUL	LLL	All lobes
Chi square	0.37	0.83	0.63	0.07	0.83	0.14
Fischer	0.24	NC	0.38	0.05	NC	0.09
Kappa	-0.06	-0.05	0.04	-0.13	-0.05	0.12
Sensitivity	42.9%	40.0%	48.9%	35.1%	41.9%	48.5%
Specificity	49.1%	54.6%	55.2%	47.9%	52.7%	39.5%
*PPV	24.0%	26.9%	33.8%	17.6%	25.7%	38.8%
**NPV	69.6%	68.6%	69.9%	70.0%	69.9%	49.3%
*PPV= Positive predictive value; ** NPV = Negative predictive value						
†NC= Not calculated						

Chronic inflammation was noted, on average in 17.6% of macroscopic evaluations. The comparison of this variable with the LODOX variable of ground glass opacities is depicted in Table 5.3, below. All lobes apart from the right lower lobe showed statistically significant results. ($P < 0.05$).

Table 5.3: LODOX ground glass opacities versus macroscopic chronic inflammation.						
Parameter	Site					
	RUL	RML	RLL	LUL	LLL	All lobes
Chi square	0.003	0.05	0.14	<0.001	0.002	0.01
Fischer	0.003	0.04	0.10	<0.001	0.002	0.01
Kappa	-0.19	-0.13	-0.09	-0.20	-0.18	-0.18
Sensitivity	24.1%	29.0%	33.33%	19.2%	17.4%	38.1%
Specificity	45.6%	52.0%	51.18%	46.1%	48.9%	38.4%
*PPV	9.3%	13.2%	12.68%	6.8%	5.6%	18.8%
**NPV	72.2%	74.4%	78.31%	73.8%	77.1%	62.3%
*PPV= Positive predictive value; ** NPV = Negative predictive value						

Table 5.4, below, summarises the results of the comparison of the LODOX ground glass opacities with features of Diffuse Alveolar Damage (DAD), a variable which was noted in 13.7% of cases. There were no statistically significant results noted in this comparison.

Table 5.4: LODOX ground glass opacities versus macroscopic features of Diffuse Alveolar Damage (DAD).						
Parameter	Site					
	RUL	RML	RLL	LUL	LLL	All lobes
Chi square	0.56	0.89	0.92	0.35	0.99	0.29
Fischer	0.37	0.54	0.56	0.24	†NC	0.20
Kappa	-0.03	0.01	-0.01	-0.05	0.01	-0.06
Sensitivity	42.9%	45.5%	45.0%	39.1%	47.8%	46.7%
Specificity	50.4%	56.1%	53.7%	50.4%	53.9%	42.7%
*PPV	12.0%	14.7%	12.7%	12.2%	15.5%	16.5%
**NPV	84.8%	86.1%	86.8%	82.5%	85.4%	76.8%
*PPV= Positive predictive value; ** NPV = Negative predictive value						
†NC= Not Calculated						

5.3 LODOX consolidation versus macroscopic variables

Consolidation was the second most commonly reported pattern of opacification reported on radiological examination, recorded in 22.3% of all reports.

Table 5.5 depicts the comparison of the LODOX variable of consolidation versus the macroscopic variable of oedema.

Table 5.5: LODOX consolidation versus macroscopic oedema.						
Parameter	Site					
	RUL	RML	RLL	LUL	LLL	All lobes
Chi square	0.84	0.59	0.26	0.51	0.03	0.08
Fischer	0.59	0.46	0.27	0.41	0.04	0.10
Kappa	0.00	0.01	0.02	0.02	0.06	0.05
Sensitivity	40.7%	20.00%	22.4%	21.4%	33.3%	41.8%
Specificity	83.3%	85.7%	90.9%	85.7%	92.3%	87.5%
*PPV	93.1%	93.3%	96.9%	93.8%	97.9%	98.4%
**NPV	8.0%	9.7%	8.3%	9.8%	11.3%	7.6%
*PPV= Positive predictive value; ** NPV = Negative predictive value						

Table 5.6, below, displays the results of the comparison of the LODOX variable of consolidation versus the macroscopic variable of acute inflammation. Statistically significant ($p < 0.05$) results were noted in the left upper lobe and in the combined group.

Table 5.6: LODOX consolidation versus macroscopic acute inflammation.						
Parameter	Site					
	RUL	RML	RLL	LUL	LLL	All lobes
Chi square	0.34	0.63	0.30	0.05	0.23	0.001
Fischer	0.23	†NC	0.20	0.04	†NC	0.001
Kappa	0.08	0.08	0.08	0.16	0.14	0.26
Sensitivity	23.8%	24.4%	26.5%	32.4%	41.9%	54.4%
Specificity	83.0%	82.4%	80.9%	82.9%	72.7%	70.9%
*PPV	34.5%	36.7%	39.4%	37.5%	37.5%	59.7%
**NPV	74.4%	72.4%	70.3%	79.5%	76.2%	66.3%
*PPV= Positive predictive value; ** NPV = Negative predictive value						
†NC= Not calculated						

The results of the comparison of the LODOX variable of consolidation versus the macroscopic appearance of chronic inflammation are demonstrated in Table 5.7. All lobes showed statistically significant results.

Table 5.7: LODOX consolidation versus macroscopic chronic inflammation.						
Parameter	Site					
	RUL	RML	RLL	LUL	LLL	All lobes
Chi square	0.006	0.06	0.04	0.02	0.07	0.003
Fischer	0.006	0.04	0.03	0.02	0.05	0.003
Kappa	0.24	0.16	0.17	0.19	0.14	0.23
Sensitivity	37.9%	32.3%	37.0%	38.5%	47.8%	59.5%
Specificity	85.6%	83.7%	81.9%	82.8%	71.8%	66.9%
*PPV	37.9%	33.3%	30.3%	31.3%	22.9%	40.3%
**NPV	85.6%	83.1%	85.9%	86.9%	88.7%	81.5%
*PPV= Positive predictive value; ** NPV = Negative predictive value						

Statistically significant results were also obtained for the comparison of the LODOX variable of consolidation with the macroscopic features of Diffuse Alveolar Damage (DAD). The results are tabulated below.

Table 5.8: LODOX consolidation versus macroscopic features of Diffuse Alveolar Damage (DAD).						
Parameter	Site					
	RUL	RML	RLL	LUL	LLL	All lobes
Chi square	<0.001	0.002	0.002	<0.001	0.005	<0.001
Fischer	<0.001	0.002	0.002	<0.001	†NC	<0.001
Kappa	0.33	0.26	0.26	0.41	0.25	0.26
Sensitivity	52.4%	45.5%	50.0%	60.9%	60.9%	70.0%
Specificity	86.5%	84.9%	82.8%	86.3%	74.6%	66.9%
*PPV	37.9%	33.3%	30.3%	43.8%	29.8%	33.9%
**NPV	92.0%	90.3%	91.7%	92.6%	91.5%	90.2%
*PPV= Positive predictive value; ** NPV = Negative predictive value]						
†NC= Not calculated						

5.4 LODOX versus other macroscopic variables

5.4.1: LODOX bullae and pulmonary interstitial emphysema (PIE) versus macroscopic emphysema

The comparison of the LODOX variables of bullae and pulmonary interstitial emphysema (PIE) was performed and is demonstrated in Tables 5.9 and 5.10 below. Results could not be calculated in the right middle lobe due to the low number of macroscopically positive cases.

Table 5.9: LODOX Bullous disease versus macroscopic emphysema.						
Parameter	Site					
	RUL	RML	RLL	LUL	LLL	All lobes
Chi square	0.01	NC	0.009	<0.001	0.10	0.008
Fischer	0.01	NC	0.01	0.001	0.13	0.009
Kappa	0.19	NC	0.24	0.27	0.18	0.20
Sensitivity	17.2%	NC	16.7%	19.1%	14.3%	19.4%
Specificity	96.8%	NC	99.3%	99.3%	98.6%	95.9%
*PPV	55.6%	NC	66.7%	80.0%	33.3%	54.6%
**NPV	83.5%	NC	93.4%	88.6%	96.0%	82.5%
*PPV= Positive predictive value; ** NPV = Negative predictive value						
†NC= Not Calculated						

Table 5.10: LODOX Pulmonary Interstitial emphysema versus macroscopic emphysema						
Parameter	Site					
	RUL	RML	RLL	LUL	LLL	All lobes
Chi square	0.001	0.17	0.16	0.05	0.03	0.008
Fischer	0.001	0.15	0.15	0.05	0.03	0.009
Kappa	0.25	0.13	0.13	0.16	0.25	0.20
Sensitivity	20.7%	18.2%	16.7%	14.3%	28.6%	19.4%
Specificity	97.6%	94.4%	95.1%	97.0%	96.6%	95.9%
*PPV	66.7%	20.0%	22.2%	42.9%	28.6%	54.6%
**NPV	84.1%	93.8%	93.1%	87.8%	96.6%	82.5%
*PPV= Positive predictive value; ** NPV = Negative predictive value						
†NC= Not Calculated						

5.4.2 LODOX pleural pathology versus macroscopic pleural pathology

The comparison of the pleural pathology detected on LODOX and macroscopically at autopsy was compared. The results are depicted in Table 5.11 below.

Table 5.11: LODOX pleural pathology versus macroscopic pleural pathology.	
Parameter	Site
	All lobes
Chi square	0.89
Fischer exact	0.62
Kappa	-0.01
Sensitivity	12.5%
Specificity	86.2%
*PPV	9.5%
**NPV	89.5%
*PPV= Positive predictive value; ** NPV = Negative predictive value	

5.4.3 Cavity

There were 7 reports of cavity formation noted on LODOX assessment and 22 cavities were detected on macroscopic examination. The LODOX predicted 3 cavities in the right upper lobe, whereas 7 cavities were detected at macroscopic examination of this lobe. Of these, only one case correlated.

On LODOX evaluation the right middle and lower lobes each had one report of cavity formation. However, on macroscopic examination of the lungs 3 cavities were found in the right middle lobe and 3 cavities in the right lower lobe. However, there was no case correlation.

The left upper lobe had two reports of cavity on LODOX evaluation with 6 reports noted on macroscopic evaluation. Again there was no case correlation noted. Additionally, the LODOX predicted no cavity for the left lower lobe, but 3 cavities were detected on macroscopic examination.

5.4.4: LODOX versus macroscopic findings of a mass

In this study the LODOX predicted 2 mass lesions. These lesions were located in the right lower and left upper lobes of the same study case. However; on macroscopic examination of the lung at autopsy, no tumour or mass lesion was noted in either of these lung lobes. Interestingly,

a cavity, which was not present at autopsy, was also reported in this case on the radiologic report

Additionally, in an unrelated case, a mass measuring 12 x 8mm was discovered in the right middle lobe at autopsy which was not detected on LODOX. Similarly, in one other case, a bronchial tumour measuring 50 x 55mm was noted at autopsy macroscopic examination. However, only “peri-bronchial calcification” was reported on LODOX evaluation.

5.4.5: LODOX versus macroscopic bronchiectasis

In this study there were four reports of bronchiectasis predicted by LODOX evaluation. These involved the right middle and lower lobes and the left lower lobe. Only 2 individual study cases were involved. The macroscopic examination found only 1 case of bronchiectasis, which did not correlate with the 4 cases detected at LODOX evaluation.

5.4.6: LODOX versus macroscopic thrombosis

There were no reports of thrombus on LODOX reporting. In the macroscopic evaluation of the study cases there were 8 reports. Thus there was no correlation for this variable.

Chapter 6: Results: LODOX versus Microscopic evaluation

6.1 Introduction

The correlation of LODOX radiological data with microscopic findings in the lungs of decedents presenting for medico-legal autopsy was reviewed. The two most common radiological variables were ground glass opacities and consolidation. These two variables were compared with microscopic features of oedema, acute inflammation and chronic inflammation, features of DAD-fibrin strands and intra alveolar haemorrhage. Additionally, the microscopic variables of a cavity, bronchiectasis, fibrosis, mass lesions, emphysema and thrombosis were correlated with their radiographic counterparts.

In this study the categorical datasets were the features found at LODOX imaging and the histopathological features identified at microscopy. Two-way contingency table statistical comparison of the LODOX images and the microscopic findings in each individual lobe of the lung was performed. The analysis resulted in true positive, true negative, false positive and false negative values being obtained and tabulated. In order for the analysis to be computed, the contingency tables had to have a minimum value of 10. In some instances, this minimum value was not achieved and the results could thus be not calculated (NC) for individual lung lobes. Where possible the values for each lobe were combined to achieve the minimum value of 10 and the results were thus calculated. Microscopy was, as is convention, considered the “gold standard” for this phase of the study.

Chapter 6.2 pertains to the LODOX pattern of ground glass opacities versus microscopic variables. Chapter 6.3 reviews the findings of the LODOX pattern of consolidation versus the microscopic variables.

6.2 LODOX ground glass opacities versus microscopic variables:

Statistically significant results were noted in the left lower lobe when the LODOX variable of ground glass opacities was compared with the microscopic variable of oedema.

Table 6.1: LODOX ground glass opacities versus microscopic oedema.						
Parameter	Site					
	RUL	RML	RLL	LUL	LLL	All lobes
Chi square	0.66	0.70	0.07	0.70	0.01	0.45
Fischer	0.43	0.44	0.06	0.43	0.01	0.43
Kappa	0.02	0.02	0.09	-0.02	0.11	0.02
Sensitivity	49.6%	45.4%	48.7%	47.3%	50.4%	55.1%
Specificity	56.3%	59.1%	75.0%	46.7%	84.6%	66.7%
*PPV	89.7%	85.7%	93.4%	88.7%	96.9%	98.8%
**NPV	12.7%	16.7%	16.7%	9.2%	15.1%	2.9%
*PPV= Positive predictive value; ** NPV = Negative predictive value						
†NC= Not calculated						

The results of the comparison of the presence of LODOX ground glass and the microscopic variable of acute inflammation is noted in Table 6.2 below. Statistically significant results are noted in the left upper lobe. ($p < 0.05$).

Table 6.2: LODOX ground glass opacities versus microscopic acute inflammation.						
Parameter	Site					
	RUL	RML	RLL	LUL	LLL	All lobes
Chi square	0.05	0.21	0.50	0.04	0.57	0.15
Fischer	0.05	0.15	0.31	0.04	0.36	0.10
Kappa	-0.11	-0.08	-0.05	-0.12	-0.04	0.11
Sensitivity	30.4%	33.3%	41.5%	29.2%	41.4%	47.2%
Specificity	48.1%	53.5%	52.3%	48.5%	52.8%	40.6%
*PPV	9.3%	13.2%	24.3%	9.5%	16.9%	29.4%
**NPV	79.8%	79.1%	70.7%	78.8%	79.5%	59.4%
*PPV= Positive predictive value; ** NPV = Negative predictive value						
†NC= Not calculated						

Table 6.3 demonstrates the results for the comparison of microscopic chronic inflammation and LODOX ground glass opacities. The only lobe which showed statistically significant results was the left upper lobe.

Table 6.3: LODOX ground glass opacities versus microscopic chronic inflammation.						
Parameter	Site					
	RUL	RML	RLL	LUL	LLL	All lobes
Chi square	0.47	0.32	0.54	0.04	0.14	0.13
Fischer	0.31	0.22	0.35	0.04	0.11	0.09
Kappa	-0.04	-0.07	-0.04	-0.11	-0.09	-0.12
Sensitivity	42.3%	35.7%	40.7%	26.3%	31.8%	47.5%
Specificity	50.0%	54.0%	52.8%	48.9%	51.5%	40.0%
*PPV	14.7%	14.7%	15.7%	6.8%	9.9%	32.9%
**NPV	81.0%	79.1%	80.5%	82.5%	81.9%	55.1%
*PPV= Positive predictive value; ** NPV = Negative predictive value]						

Table 6.4 and 6.5 demonstrate the result of the comparison of LODOX ground glass opacities with features of DAD-fibrin strands and intra alveolar haemorrhage.

Table 6.4: LODOX ground glass opacities versus microscopic features of Diffuse Alveolar Damage (DAD)-fibrin strands.						
Parameter	Site					
	RUL	RML	RLL	LUL	LLL	All lobes
Chi square	NC	NC	0.04	NC	NC	0.01
Fischer	NC	NC	0.04	NC	NC	0.01
Kappa	NC	NC	-0.11	NC	NC	-0.15
Sensitivity	NC	NC	23.5%	NC	NC	34.5%
Specificity	NC	NC	51.1%	NC	NC	40.0%
*PPV	NC	NC	5.7%	NC	NC	11.8%
**NPV	NC	NC	84.2%	NC	NC	72.5%
*PPV= Positive predictive value; ** NPV = Negative predictive value]						
†NC= Not calculated						

In Table 6.5 no statistically significant results were obtained for the comparison of the LODOX appearance of ground glass opacities and intra alveolar haemorrhage.

Table 6.5: LODOX ground glass opacities versus microscopic intra alveolar haemorrhage (IAH).						
Parameter	Site					
	RUL	RML	RLL	LUL	LLL	All lobes
Chi square	0.66	0.12	0.31	0.69	0.14	0.35
Fischer	0.40	0.09	0.20	NC	0.10	0.21
Kappa	-0.03	0.11	0.08	-0.06	0.11	-0.08
Sensitivity	45.7%	56.7%	50.9%	42.5%	55.3%	58.4%
Specificity	50.0%	59.0%	57.6%	49.6%	57.6%	49.2%
*PPV	21.6%	25.4%	43.5%	23.0%	36.6%	61.2%
**NPV	75.3%	84.7%	64.6%	70.9%	74.4%	46.4%
*PPV= Positive predictive value; ** NPV = Negative predictive value]						
†NC= Not calculated						

6.3 LODOX consolidation versus microscopic variables

Table 6.6 below demonstrates statistically significant ($p < 0.05$) results in the right lower lobe when the LODOX variable of consolidation is compared with the microscopic variable of oedema.

Table 6.6: LODOX consolidation versus microscopic oedema					
Parameter	Site				
	RUL	RML	RLL	LUL	LLL
Chi square	0.67	0.79	0.04	0.60	0.31
Fischer	0.44	0.49	0.04	0.40	0.23
Kappa	-0.01	-0.01	-0.07	-0.02	-0.04
Sensitivity	20.3%	20.2%	19.7%	20.6%	32.0%
Specificity	75.0%	77.3%	56.3%	73.3%	53.9%
*PPV	86.2%	82.8%	76.7%	87.1%	87.0%
**NPV	10.9%	15.2%	8.7%	9.6%	7.6%
*PPV= Positive predictive value; ** NPV = Negative predictive value					
†NC= Not calculated					

Table 6.7 and 6.8 show the results of the comparison of the LODOX variable of consolidation versus the microscopic variables of acute and chronic inflammation. In both cases statistical significance was observed in selected areas

Table 6.7: LODOX consolidation versus microscopic acute inflammation.						
Parameter	Site					
	RUL	RML	RLL	LUL	LLL	All lobes
Chi square	0.05	0.02	0.18	0.58	0.40	0.05
Fischer	0.04	0.02	0.13	0.41	0.30	0.04
Kappa	0.17	0.20	0.11	-0.04	0.07	0.16
Sensitivity	34.8%	37.0%	29.3%	16.7%	37.9%	50.9%
Specificity	84.0%	84.3%	81.1%	78.5%	70.4%	65.4%
*PPV	27.6%	33.3%	36.4%	12.5%	22.9%	43.5%
**NPV	88.0%	86.3%	75.7%	83.6%	83.0%	71.7%
*PPV= Positive predictive value; ** NPV = Negative predictive value]						

Table 6.8: LODOX consolidation versus microscopic chronic inflammation.						
Parameter	Site					
	RUL	RML	RLL	LUL	LLL	All lobes
Chi square	0.61	0.02	0.32	0.55	0.57	0.27
Fischer	0.43	0.02	0.25	0.41	0.37	0.18
Kappa	-0.04	0.19	-0.08	-0.04	0.04	0.09
Sensitivity	15.4%	35.7%	14.8%	15.8%	36.4%	45.7%
Specificity	80.5%	84.1%	76.8%	78.5%	69.7%	63.2%
*PPV	13.8%	33.3%	12.1%	9.4%	16.7%	43.6%
**NPV	82.4%	85.5%	80.7%	86.9%	86.8%	65.2%
*PPV= Positive predictive value; ** NPV = Negative predictive value						

The statistical analysis of the comparison of the LODOX appearance of consolidation and features of DAD and IAH are tabulated in Table 6.9 and 6.10 below.

Table 6.9: LODOX consolidation versus microscopic features of Diffuse Alveolar Damage (DAD)-fibrin strands.						
Parameter	Site					
	RUL	RML	RLL	LUL	LLL	All lobes
Chi square	NC	NC	<0.001	NC	NC	0.002
Fischer	NC	NC	<0.001	NC	NC	0.002
Kappa	NC	NC	0.30	NC	NC	0.22
Sensitivity	NC	NC	58.8%	NC	NC	65.5%
Specificity	NC	NC	83.0%	NC	NC	65.6%
*PPV	NC	NC	30.3%	NC	NC	30.7%
**NPV	NC	NC	94.1%	NC	NC	89.1%
*PPV= Positive predictive value; ** NPV = Negative predictive value]						
†NC= Not calculated						

Table 6.10: LODOX consolidation versus microscopic intra alveolar haemorrhage (IAH).						
Parameter	Site					
	RUL	RML	RLL	LUL	LLL	All lobes
Chi square	0.39	0.59	0.66	0.99	0.92	0.54
Fischer	0.28	0.37	0.40	†NC	0.53	0.33
Kappa	-0.07	0.04	0.03	0.00	0.01	-0.05
Sensitivity	14.3%	23.3%	23.7%	20.0%	31.9%	38.2%
Specificity	79.3%	78.8%	79.3%	79.6%	68.9%	56.9%
*PPV	17.2%	23.3%	42.4%	25.8%	31.3%	54.8%
**NPV	75.4%	81.2%	61.9%	73.8%	69.5%	40.2%
*PPV= Positive predictive value; ** NPV = Negative predictive value						
†NC= Not calculated						

6.4 LODOX versus other microscopic variables

6.4.1: LODOX bullae and pulmonary interstitial emphysema (PIE) versus microscopic emphysema.

Bullae and PIE were reported, on average, in 2.6% and 5.5% of all radiological reports respectively. The presence of emphysema was reported in 37.8% of all microscopic evaluations. Table 6.11 summarises the statistical evaluation of these results

Table 6.11: LODOX Bullae and Pulmonary Interstitial Emphysema (PIE) versus microscopic emphysema.		
Bullae	Parameter	PIE
0.01	Chi Square	0.08
0.02	Fisher	0.08
0.08	Kappa	0.06
11.5%	Sensitivity %	10.34%
98.4%	Specificity %	96.8%
90.9%	PPV %	81.8%
44.6%	NPV %	43.9%
*PPV= Positive predictive value; ** NPV = Negative predictive value		

6.4.2: LODOX pleural pathology versus microscopic pleural pathology

Table 6.12: LODOX pleural pathology versus microscopic pleural pathology.	
Parameter	Site
	All lobes
Chi square	0.92
Fischer exact	0.58
Kappa	-0.01
Sensitivity	13.2%
Specificity	86.2%
*PPV	23.8%
**NPV	75.2%
*PPV= Positive predictive value; ** NPV = Negative predictive value	

6.4.3 LODOX cavity versus microscopic cavity.

The number of positive variables was too small for contingency table analysis. The LODOX reports predicted 7 cavity lesions and the microscopic evaluation detected 11 cavity lesions. Of these 11 cavities detected microscopically, four lesions were an artefact of laboratory tissue processing. However, the remaining seven microscopic cavities showed no correlation with the LODOX predictions, i.e. the 7 cases reported as having a cavity on LODOX did not have cavity reported microscopically, and vice versa.

6.4.4: LODOX mass versus microscopic mass

Only 2 predictions of a mass on LODOX radiological scanning were made, but both lesions were not detected on microscopic examination and in one instance a cavity was reported radiologically instead.

On microscopic evaluation malignant tumour was present in 11/795 slides (1.4%) and involved 7 individual cases. These malignancies were not picked up by the X-rays.

Additionally, there was no correlation between the LODOX report of a mass and the microscopic reports of “other mass”.

6.4.5: LODOX bronchiectasis versus microscopic bronchiectasis.

The LODOX evaluation of the study cases reported 4 cases of bronchiectasis whilst the microscopy showed 8 positive reports. The discrepancies arose in the left upper lung lobe where the LODOX did not predict any positive findings but where 3 cases were discovered on microscopy. Similarly only 1 case was reported in the left lower lobe on LODOX but 2 cases were discovered on microscopy.

6.4.6: LODOX fibrosis versus microscopic fibrosis.

A total of 14 reports of fibrosis were made on LODOX image evaluation. The microscopic evaluation yielded a much larger number of positive reports i.e. 86 positive reports. The number of “true positive” cases was too small for statistically significant contingency table analysis of the individual lung lobes.

6.4.7: LODOX versus microscopic thrombosis

There were no reports of features compatible with thrombus on LODOX reporting. In the microscopic evaluation there was a mean frequency of 4.4% for positive detection of thrombosis, thus there is no correlation.

6.4.8: LODOX versus microscopic autolysis

Microscopically, 6.3% of slides evaluated displayed autolysis. Contingency table analysis was not possible in all lobes in this study due to the low number of true positives and negatives. When the statistical analysis was performed on the total sample, the presence of ground glass opacities on LODOX had a sensitivity of 66.6% and a specificity of 56.1% for the microscopic finding of autolysis. In comparison, the LODOX variable of consolidation had a sensitivity of 20% and a specificity of 78.4%. However statistical significance was not observed for the association in either case. The evaluation of the presence and extent of emphysema and oedema was obscured in 9.1% and 8.4% of all microscopic slides evaluated due to the presence of autolysis.

Chapter 7: Discussion

7.1 Introduction

The correlation of the LODOX features with macroscopically and microscopically identifiable pathology is necessary for the application of the LODOX Statscan system as a screening tool for soft tissue pathology diagnosis. This study was a preliminary prospective autopsy study which aimed to determine if there is correlation between LODOX digital images and the pathologic changes in the lungs of adult decedents at autopsy. Autopsy correlation studies, such as the current study, have an advantage in that radiological exposure dosage and time are negligible factors when scanning the study cases. An additional advantage is that extensive sampling of the target tissues can be undertaken and comparisons between the radiological interpretation and the histopathological findings can be made. Such intense correlation cannot be performed in the living due to the obvious ethical considerations. The prospective design of this study is also supported by many authors who have previously published data pertaining to the LODOX Statscan. These authors have acknowledged that a standardized prospective autopsy study, such as the current study, would yield the most reliable results. [5, 6, 17]

The prospective design is favourable as it allowed for the development of a standardised method of data collection, reporting and analysis. A prospective autopsy study may also have many challenges and limitations. This study had a limited study period and hence a limited number of inclusion cases. This reduced the number of cases with possible diagnostically important pathology, which, in some instances, may have affected the statistical significance of the results obtained.

The importance of determining the correlation or association of the LODOX digital images and the macroscopic and microscopic pathology cannot be overemphasised. Overconfidence in the diagnostic ability of recent radiological advances can result in major discrepancies. Indeed, many studies have shown that the discrepancy rates ranged from 30% to 63% when the clinical diagnosis (which is often based, at least in part, on radiological findings) is compared with the autopsy findings. [13, 21] It is therefore imperative that the degree of reliance that can be placed on such technology be scientifically evaluated. More so in the arena of medico-legal autopsy practice, where the formulation of the cause of death (COD) can have far reaching consequences. Indeed, authors have questioned the quality of radiographic reports as admissible legal evidence, especially where autopsy was an option. [7, 22]

This study adopted the following null hypothesis: “there is no relationship/correlation between variables predicted by LODOX images and the macroscopic and microscopic

variables pertaining to pathological changes in the lungs of decedents". In order to test this hypothesis, two-by-two contingency table statistical correlation analysis was conducted.

By definition statistical association/correlation does not imply causation. The aim of this study was to determine the presence of a *relationship* between variables rather than causation i.e. to determine to what degree underlying pathology correlates with a certain radiographic picture rather than to determine if one variable is the cause of a specific LODOX/radiological picture or not.

The findings of studies on conventional X-rays are often reported as the sensitivity, specificity and positive and negative predictive values in reference to the ability of the X-ray to detect certain pathology. The sensitivity and specificity reflects the ability of a diagnostic test to correctly identify cases which are truly positive and negative. (E.g. of all the cases that were positive for oedema by the gold standard, how many were correctly identified as such by the diagnostic test i.e. LODOX)

The positive and negative predictive values (PPV and NPV) are a measure of the accuracy of a diagnostic test in predicting a positive or negative outcome. (E.g. of all the tests that were predicted as positive by the LODOX for consolidation, how many were also positive for oedema by the gold standard) A high PPV or NPV is indicative of a high degree of accuracy, or precision, of the test. Of note is that the PPV and NPV are not inherent to the diagnostic test, as prevalence is also a determining factor. PPV is directly proportional to prevalence of the pathology being investigated and is more accurately assessed when the study population reflects the general population. In our study, the prevalence of pathological conditions was reflected by the percentage of cases diagnosed on microscopy (the gold standard). Therefore, the prevalence of certain conditions, like malignant tumour, was low, and resultantly the PPV would also be low.

7.2 Discussion of findings:

In our study and other studies relating to the LODOX Statscan, standard projection in the anterior-posterior (AP) and lateral position were taken [4; 17]. In our study, where possible, the arms were raised above the level of the head, to remove the scapulae from the visual field. These projections allow for the correct evaluation of position and depth of a focal pathologic lesion e.g. cavity. Challenges arose when attempting to scan the bodies of decedents in the presence of rigor mortis, where the rotation of the corpse may have had an effect on the evaluation of the image. Similarly, autolysis and decomposition change, as discussed below, were factors which may have affected the quality of the images. The effect of body mass index (BMI) may have impacted the penetrance of the X-rays and hence the overall quality of

the digital images. However, the LODOX Statscan does have settings which allow for the manipulation of penetration for subjects with higher BMI. Radiation parameters can be widened to obtain the ideal image as the effect of radiation on the corpse is not an issue, as previously noted. This can allow for more adequate imaging in cases with an increased BMI. This was highlighted by Flasch *et al* in the development of a protocol for post mortem radiology. [22] They also noted that motion artefacts, such as inspiration artefacts, are not present in the deceased, which has a positive effect on the overall quality of the image. On the other hand, a lack of circulatory motion may obscure certain pathology e.g. the presence of post mortem lividity/hypostasis may obscure a pulmonary thromboembolism (discussed below).

As mentioned previously, there are no studies which review the correlation of the LODOX images with histopathological findings and hence the results of this study can only be prudently compared with the findings of studies on conventional X-rays, the majority of which pertain to the ante-mortem correlation. Therefore the aforementioned factors must be considered when comparing ante-mortem and post-mortem radiographic imaging modalities.

The general findings of our study were presented in Chapter 4. Of the 60 cases which were finally deemed to be due to “natural” disease, in 13 cases (21.7%) the cause of death was attributed to pathology within the respiratory tract. Apart from a cause of death attributed to “acute epiglottitis”, the remaining 12 cases had pathology which may have been identifiable on LODOX scanning. As suggested by Tiemensma *et al*, the screening of cases prior to evisceration may assist with the detection of natural fatal pathology, which may result in a reduced load of cases which proceed to full autopsy examination. [10]

The analysis of the general dataset revealed that the most common LODOX radiological findings in this study were the appearance of ground glass opacities and consolidation. (Figure 4.1 to 4.5) These were also the two patterns that were most commonly seen in cases where the cause of death was attributable to respiratory pathology (Table 4.2), especially in cases of fatal pneumonia and cavitary lung disease.

Despite the high prevalence of Tuberculosis in South Africa, only one death was deemed to be as a result of pulmonary Tuberculosis and in this one case the radiographic images displayed a reticular pattern. However, the deaths in our study that were attributed to pneumonia or cavitary lung disease may also have had Tuberculosis as the underlying condition.

Radiologically, ground glass opacity is the appearance of hazy increased lung opacity, while consolidation is the appearance of a homogenous increase in pulmonary parenchymal attenuation. [1] These radiologic pictures may therefore overlap with various aetiologies and

in our study these patterns were not strongly associated with any specific pathology. The correlation of radiological findings on the LODOX with macroscopic findings in the lungs of decedents was reviewed and the results were presented in Chapter 5. The 2 most common LODOX variables of ground glass opacities and consolidation were compared with the macroscopic features of oedema, acute inflammation, chronic inflammation and features of diffuse alveolar damage (DAD) to determine if there was association/correlation.

In a review article by Whiley *et al* [15], the authors recognised that many studies reported similar or improved image quality of LODOX in comparison to conventional radiographs. A study by Boffard *et al* aimed to determine if the LODOX had comparable image quality when compared with conventional radiography and deduced that the LODOX and conventional X-rays were the same in the information obtained. The authors showed quantitatively, that initially for 85% of trauma surgeons and 75% of radiologists the LODOX images of the chest were the same as conventional X-rays. In the second phase of assessment 100% of trauma surgeons and 88% of radiologists agreed that the images were the same. [23] In their study, the authors did not discuss whether only skeletal/bony pathology was evaluated or whether parenchymal injury was also noted. Deyle *et al* reported an overall sensitivity of 62% and specificity of 99% with the use of the LODOX Statscan as a screening tool in the trauma setting. These values are reportedly superior to conventional X-rays. [17]. However, this was in relation to the detection of skeletal injury and traumatic parenchymal lung injury and hence no direct comparisons can be made to our study, which evaluated non-traumatic parenchymal lung pathology. Overall, the results of our statistical analysis showed a low to moderate sensitivity (26.3% to 50.4%) of the LODOX feature of ground glass opacity in the prediction of microscopic pathology (oedema, acute inflammation, chronic inflammation and features of diffuse alveolar damage). Similarly, low to moderate sensitivity (19.7% to 65.5%) was noted for the LODOX feature of consolidation ($p < 0.05$). In a review series conducted by Wunderick *et al*, 3 consecutive autopsy series (2 retrospective and 1 prospective) used autopsy histology as the reference/gold standard in the detection of pneumonia (which may be the single underlying pathology in the aforementioned macro/microscopic variables) [24]. In these studies the sensitivity ranged from 57.1% to 87.5% and the specificity ranged from 25.6% to 70%. [28]. In another study comparing ultrasound and chest X-ray in the diagnosis of pneumonia, Bourcier *et al* reported sensitivity of the chest X-ray as 60% ($p < 0.01$) and specificity as 76%. [25]

In the studies conducted by Douglas *et al* [6] and Bolursaz *et al* [26] opacities and consolidation were also the two most commonly reported LODOX radiographic findings in the lungs of their paediatric autopsy populations. In the Douglas study, these radiographic findings translated to pneumonia, aspiration, lower respiratory tract infections and

bronchopneumonia where autopsy and/or histopathological examination were performed. The authors indicated that imaging of cases prior to autopsy may have assisted with the determination of the cause of death, as a large percentage of cases which had pathology on imaging did not proceed to full autopsy examination. However the results of our study show that in adults the presence of ground glass opacities and consolidation were not specific for any one pathology. Additionally no statistical analysis was undertaken in the study by Douglas *et al*, pertaining to the sensitivity and specificity of the LODOX. Hence we cannot compare the results of their study with ours. Our study results show that the presence of ground glass opacities and consolidation had a higher positive predictive value for the appearance of oedema, a non-specific inflammatory marker which may have many underlying aetiologies, than for the other variables measured. This indicates that these LODOX patterns have a higher probability of being oedema than any other pathology. (Table 6.1 and 6.6) Overall, except for oedema, the low to moderate sensitivities and PPV coupled with moderately high to high specificities and NPV indicates that the LODOX predictions were better at excluding pathology which was not present rather than confirming pathology which was present. However, this type of correlation has limited clinical significance, since the negative prediction does not necessarily contribute to the formulation of the cause of death.

Autolysis, which is the early auto-enzymatic decomposition process, was also a microscopic variable of interest in this study. As post mortem interval increases and autolysis progresses, the putrefactive processes of decomposition become prominent and the true pathological findings in these lungs become radio-pathologically indistinct. Therefore, it is possible that radiographic changes such as ground glass opacities may actually be a result of autolytic processes rather than true pathological processes. It is therefore an important process to observe and compare as it results in changes in the lung parenchyma which may cause discrepant reporting. Indeed, de Lange *et al* [5] highlighted this possibility in their study. They noted poor agreement between conventional X-ray findings and pathology detected at autopsy in the paediatric study population, some of which was the result of post mortem artefact. This was in contrast to the study by Douglas, which noted consistency between LODOX digital image findings and autopsy findings in the absence of a report of the post mortem interval. However, in the Douglas study, many cases did not proceed to autopsy, and therefore it was impossible to evaluate whether the cases which had “pathologic changes” on LODOX really had pathology or possibly only decomposition changes. In our study the variable of autolysis had a low frequency and an even distribution in the lung lobes macroscopically, while 6.3% of histopathological slides displayed autolysis microscopically. The LODOX prediction of ground glass opacities had a sensitivity of 66.6% and a specificity of 56.1% ($p > 0.05$) for the microscopic finding of autolysis. This is slightly higher than the

sensitivity and specificity for the other microscopic variables measured in our study (acute inflammation, chronic inflammation, DAD and IAH).

Despite the lack of statistical significance of this result, the fact that the LODOX variable of ground glass opacities, which may represent variable parenchymal pathology, may also represent decomposition change is clinically significant. Radiologists and forensic practitioners utilising the LODOX would have to be cognizant of the post mortem interval when performing imaging and also be aware of other signs of autolytic change which may be present, to be able to correctly make distinctions between true pathology and decomposition artefact. Future study should limit the post mortem interval to a narrower interval (e.g. less than 24 hours) in order to reduce the effects of this variable on the evaluation of radiological and microscopic features.

Emphysema was the second most commonly encountered microscopic finding, with an autopsy frequency of 34.6%. This value was higher than for the macroscopic incidence of emphysema (mean = 9.9%). The comparison of LODOX reports of bullae and pulmonary interstitial emphysema (PIE) compared with macroscopic and microscopic emphysema yielded the same overall result [Table 5.9 and 5.10]: low sensitivity, moderate PPV and high specificity and NPV; ($p < 0.05$ for macroscopic findings). The PPV was higher in the microscopic evaluation owing to a very low false positive rate where even mild grades of emphysema were considered positive microscopically. The conventional X-ray evaluation of emphysema yields variable results (poor- to excellent agreement) in clinico-pathological studies, dependent on the criteria used for evaluation. [27] This was highlighted by Miniati *et al* who conducted a study which attempted to review the use of chest radiography in the diagnosis and exclusion of emphysema. In their study they found the prevalence of emphysema to be 56%. The chest X-ray had a reported sensitivity of 90%; a specificity of 98%, a PPV of 98% and an NPV of 88%. This was reported when multiple radiological criteria were employed. Miniati observed that when only 1 criterion was used to determine the presence of emphysema, the results showed that only 16% of patients with mild-to-moderate and 42% of patients with moderate-to-severe emphysema were correctly diagnosed. Overall, in our study, the absence of bullae and PIE on LODOX was more useful at negating the presence of emphysema than confirming it. In our study no defined criteria for the definition of emphysema were prospectively set out. This may not have been the ideal circumstances and in future studies a defined set of criteria for the diagnosis of emphysema on LODOX may be more useful.

Intra-alveolar haemorrhage (IAH) was the third most commonly encountered microscopic finding with an autopsy frequency of 27.4%. However, there was no radiological equivalent

to correlate this with, as the radiologic appearance of alveolar haemorrhage is variable. The presence of intra-alveolar haemorrhage may have significant diagnostic importance in forensic autopsy practice, in cases of death due to massive haemoptysis as a consequence of cavitary lung disease, which is often due to Tuberculosis and therefore notifiable. (Table 4.2). Since there is no radiological equivalent to detect this pathology, missed diagnoses are inevitable if LODOX alone is employed.

The macroscopic incidence of IAH was 3.1%. The increased frequency of emphysema and IAH noted on microscopic examination compared to macroscopic evaluation can be attributed to the histopathological reporting method utilised in which emphysema and IAH, as well as other variables, were graded as mild, moderate and severe. The cases of macroscopically visible IAH most likely represent the “severe” grade, whereas the mild and moderate grades are likely to only be microscopically identifiable.

The comparison of LODOX detection of pleural pathology and the macroscopic and microscopic findings were tabulated in Table 5.11 and Table 6.12 respectively. The sensitivity and PPV were low and the specificity and NPV were moderately high. Besides these results not being statistically significant, the results are deemed unreliable as a major component of macroscopic assessment was often not performed. The most commonly reported finding relating to pleural pathology on LODOX radiological assessments was a pneumothorax. One of the shortfalls of this study was that the result of the test for pneumothorax was not recorded for every autopsy, and indeed the test may not have been done. In one case, where the cause of death was attributed to respiratory pathology in the form of bullous lung disease, the radiological findings included a report of “tension pneumothorax” which may have been detected at autopsy, had the pneumothorax test been done. [Table 4.2] Deyle *et al* reported that the LODOX had a sensitivity of 54% in the detection of pneumothorax versus sensitivities of 10% to 45% in other studies which utilized conventional X-rays. [17] Another study by Chen reported that the sensitivity and specificity of the LODOX in detecting a pneumothorax was 79.2% and 100% respectively. [28] A more stringent adherence to gold standard principles (in this case performing a pneumothorax test in every autopsy case) may have resulted in better correlation. A review of six SCUBA diving-related deaths by When and Williams showed that in 2 cases pneumothoraxes were evident in pre-autopsy radiology but were not convincingly demonstrated at autopsy. [29] Therefore, the confirmation of a pneumothorax radiologically, not only provides excellent digital evidence, but may also contribute to the cause of death formulation and may be a useful adjunct to the autopsy examination.

The low numbers of “true positive” findings of other macroscopic variables inhibited contingency table analysis. This was an anticipated finding. No statistical significance can therefore be placed on these results and a larger sample size is recommended for future study. Clinical relevance can however, be observed in some instances as discussed below.

No correlation between LODOX prediction of cavity and the microscopic detection of cavities was noted in our study. Macroscopically, there were 23 reports of cavity and microscopically there were 11 reports. Only one case correlated macroscopically and no microscopic correlation was noted. The clinical significance in this is demonstrated in Table 4.2. Here, of the 13 cases where respiratory pathology was the natural COD, 4 cases (30.8%) were deemed to be due to cavitary lung disease/lung abscess. In these 4 fatal cases the LODOX image result showed no correlation for the variable of cavity. However bullae were reported in all 4 cases and consolidation and ground glass opacities were also noted. It is possible that in these cases bullae obstructed the view of cavities, or were erroneously described as cavities. Cavitary lung disease may have multiple underlying aetiologies and the prevalence ranges from between 30% to 50% in patients with Pulmonary Tuberculosis [30]. Authors Gadkowski and Stout reported that cavities often occur in areas of consolidation and that chest radiographs have a sensitivity of 57% in the detection of this pulmonary infection. We cannot compare our findings with the findings of Gadkowski as statistical analysis could not be undertaken. Additionally, our study findings are in contrast to the findings of a recent study undertaken by Bolursaz *et al* which made a comparison of digital chest X-ray with thoracic CT scan in children with Tuberculosis [26]. The authors reported that the sensitivity of the digital X-ray was not considerably different from that of CT in the detection of a cavity/abscess, which they attributed to the large size of cavities in their study population. In our study the subjects were adults, who are more likely than the paediatric population to have other pathologic and age-related changes which may obscure the detection of pathology, even macroscopically visible cavities.

Conventional X-rays have a low sensitivity and positive predictive value for the detection of pulmonary thrombo-embolism in the living and this evaluation is dependent on the interpretation of various radiologic signs (Fleischner; Hampton’s, etc.) which suggest the diagnosis. Additionally, studies which review the findings of autopsy with high resolution radiography, such as CT and MRI scans, have shown high rates of discrepancy in relation to the detection of pulmonary embolism [9, 22] as the distinction between ante-mortem and post-mortem clot cannot be made. Therefore, as anticipated, there was no correlation of these LODOX reports and the macroscopic and microscopic findings.

In this study, tumour was defined as any malignant tumour whether primary or secondary. A study conducted in Australia by Manser *et al* showed that 167/13 834 (1.2%) of natural deaths which underwent coronial autopsy had lung cancer, of which 47/13 834 (0.24%) were incidental. [31] The findings of our study are similar to the findings of Manser, with our study population demonstrating a rate of lung cancer at autopsy of approximately 1.4%. A tumour mass, which may be benign or malignant, may have important direct (mass effect) and indirect effects (para-neoplastic syndromes) which may result in, or significantly contribute to death. Hence the detection thereof and the histological classification are of clinical significance despite the lack of statistical significance. In this study there was no correlation between the radiographic detection of a mass and the microscopic discovery of malignancy. It is likely that all tumours microscopically detected were too small for radiographic detection. Also, since most tumours that were identified, were only noted microscopically, they could be regarded as incidental findings. Additionally, there was a large hilar tumour detected at macroscopic examination but which was missed on radiographic evaluation. This may have been because the tumour was obscured by other pathology or may have been difficult to detect due to its site or artefacts of imaging (rotation of the chest) or a combination of these factors.

The microscopic findings of “other mass” include pathology such as schistosoma eggs, small foci of calcification, venous malformations, etc., which were only microscopically visible and hence not expected to be detected radiologically. Additionally these findings had limited clinical value as none of the lesions detected in our study had any potential to result in a fatal outcome.

A total of 14 reports of fibrosis were made on LODOX image evaluation. The microscopic evaluation yielded a much larger number of positive reports i.e. 86 positive reports. The number of “true positive” cases was too small for statistically significant contingency table analysis; thus correlation could not be assessed. As mentioned for other variables, it is likely that the microscopic grades of fibrosis were not severe enough to be radiologically visible. Most importantly, there is very limited clinical significance that can be placed on the prediction of fibrosis by a screening test, as the relevance of such a result in the formulation of the cause of death is dependent on other factors e.g. background history, other visceral/organ pathology, etc.

Bronchiectasis is a chronic condition characterised by the permanent dilation of the airways and can occur as a result of necrotizing infections. In the South African population there is a high prevalence of chronic respiratory conditions e.g. Tuberculosis, which may be a precursor to the development of bronchiectasis. One would therefore have anticipated a higher number

of macroscopic reports, however this was not the case and this is likely due to the small sample size. It is also conceivable that people who die with severe bronchiectasis may not be classified as “sudden and unexpected” deaths, and therefore not be referred to the medico-legal mortuary. The presence of bronchiectasis is a significant finding as it may directly or indirectly (as a result of its complications) result in death or be an indication of longstanding pathology. The results appear to lack confidence in the specificity or sensitivity of the LODOX in predicting bronchiectasis. Conventional X-ray has a reported sensitivity of 87.8% and a specificity of 74.4% for the detection of bronchiectasis. [31] In our study bronchiectasis was correctly identified in one lung lobe. However in the left lung 4 cases of microscopically visible bronchiectasis were not predicted by the radiologic evaluation. The reasons for this may be that the foci of bronchiectasis were only microscopic and hence not sufficiently large enough to be radiologically detected. Bolursaz *et al* reported that in the paediatric population with pulmonary Tuberculosis, the sensitivity of the spiral CT scan and digital X-rays for co-existing bronchiectasis did not vary much. [26] However, their study had a small study population and the authors recommend further study on a larger scale to compare digital X-rays with CT scan. We agree with this suggestion to compare digital X-rays, including the LODOX, with CT scan and autopsy findings especially as the majority of clinical studies reporting the sensitivity and specificity of X-ray use the CT as the Gold standard.

Interestingly, the average lung weight in this study was higher than previously reported in the literature. Modern textbooks on autopsy practice utilise a reference range for the right lung of 450g (range 360g-570g; mean: males: 455g; mean: females: 402g) and for the left lung of 375g (range 325g-480g; mean: males: 402g; mean: females:345g).[33] According to a recent publication by Molina *et al* the proposed reference range for the male gender is between 155-720g for the right lung and between 112-675g for the left. [34] The cases in our study were from both male and female decedents, however, the mean weight was higher than that reported by Molina: right lung: 746±220g (versus 445±159g) and left lung: 584±210g (versus 395±147g). The likely explanation is that the diseased or pathological lungs in the study group, unless markedly emphysematous, are expected to have a higher weight than normal due to factors such as the effects of inflammation, (e.g. oedema) and other intra alveolar exudates, fibrosis, etc.

A consideration of the autopsy phase of the study was inter-observer variability with regards to the assessment of the macroscopic features. In this study the macroscopic features were reported independently of the radiographic findings by different pathologists with varying degrees of skill and experience. This is a major consideration as the macroscopic features were considered the “gold standard” for the purpose of correlation, with the LODOX variable being the “test” variable. If the reporting pathologist was incorrect, then the “gold standard”

variable would be incorrect, which may result in discrepant findings. A consideration for future studies would be that the macroscopic variables be agreed upon by at least 2 pathologists, to limit discrepancies.

Another consideration is that all the LODOX images were reported on by a consultant radiologist with vast experience and publications on the utilization of the Statscan in the clinical setting. In the general medico-legal setting, the LODOX digital images would be reported on by forensic medical officers and forensic pathologists with varying degrees of skill and experience in radiology interpretation. Our study shows that the LODOX has sensitivity and specificity lower than that of conventional X-ray in the detection of pneumonic changes in the presence of moderate sensitivity and specificity for autolysis. Also a low rate of correlation with other focal pathology, some of which was directly related to the COD, was noted. Hence the same amount of consideration has to be employed to acknowledge the limitations of LODOX, as for conventional X-ray, in the distinction of soft tissue pathology in the lungs.

Chapter 8: Conclusions

8.1 Summary of results

The LODOX Statscan is a relatively new type of full-body radiographic scanning device which offers high quality digital images, high-speed scanning and low radiation dose. The LODOX has an established role in both the trauma and forensic pathology settings, especially in the detection of skeletal/bony pathology and the detection of foreign bodies.

The significance of soft tissue changes in the appearance of LODOX digital images of the lungs of deceased adults and the correlation of these changes with histopathological findings has not been reported in the current literature. Our study aimed to compare digital radiological images obtained via a LODOX Statscan device with histological sections obtained from the lungs of decedents undergoing medico-legal autopsy at Tygerberg Forensic Pathology Service (FPS) facility. The results showed that the most common radiographic patterns noted in the lungs of adults were the presence of ground glass opacities and consolidation. This is comparable with other studies which had paediatric populations. [6, 26]

Overall, the results of our statistical analysis showed a low to moderate sensitivity (26.3% to 50.4%) of the LODOX feature of ground glass opacity in the prediction of microscopic pathology (oedema, acute inflammation, chronic inflammation and features of diffuse alveolar damage). Similarly, low to moderate sensitivity (19.7% to 65.5%) was noted for the LODOX feature of consolidation ($p < 0.05$). This value was slightly lower than that reported for pneumonia using conventional X-rays. [24, 25] Additionally, these LODOX patterns have a higher probability of being oedema than any other pathology, but they also had a high sensitivity and specificity for the detection of autolytic change.

Poor to no correlation was noted with the variables of cavity, malignant tumour, and bronchiectasis, in contrast to a recent study by Bolursaz, [26] although the low number of positive cases in both studies does warrant further large-scale study.

8.2 Concluding statements

Although the LODOX has reported high specificity and sensitivity for the detection of radio-dense foreign bodies e.g. bullets, etc., this study shows that it does not demonstrate the same degree of specificity and sensitivity for soft tissue pathology in the lungs of adults when compared with macroscopic and microscopic autopsy findings.

Hence, despite the advantages of high quality digital images which can be rapidly obtained and easily stored, the use of the LODOX in the detection of pathology in the lungs of decedents at autopsy has limited value as a “stand alone test”. However, it may offer excellent evidentiary value in the demonstration of a pneumothorax, and this finding should prompt a directed search for pneumothorax at autopsy. Overall, LODOX predictions were better at excluding pathology which was not present rather than confirming pathology which was present. Further prospective study is advised to better define the role of the LODOX in the detection of soft tissue pathology and its applicability of use in the setting of Forensic Pathology.

8.3 Limitations

The prospective study design allowed for a standardized approach to be developed in terms of data acquisition, analysis and reporting. However, a limited study period was observed and hence a limited number of cases were included. This reduced the number of cases with possible diagnostically important pathology, which may have affected the statistical significance of the results obtained.

Practical challenges arose when attempting to scan the bodies of decedents in the presence of rigor mortis, where for example the arms could not be lifted for the lateral scans, due to the stiff rigor. Accelerated decomposition change complicated radiological and microscopic evaluation.

The fact that pneumothorax tests were not done consistently by pathologists, led to this variable (which was a significant radiological finding) not being adequately compared in this study.

8.4 Future Research and recommendations

The author will continue with the evaluation and publication of the results of the current data set. This will include evaluations pertaining to the correlation of histological grades of pathology versus the radiographic detection rates. Also further research into the detection of focal pathology in the lungs of decedents is likely to be undertaken.

Our recommendations for a follow-up study include the following:

1. Continuation of use of standardized templates for reporting to allow for bi-directional (retrospective and prospective) study.

2. Utilization of a similar standardized methodology with a larger study population.
3. To limit the inclusion cases to those which have known or markedly obvious radiologically evident pathology.
4. To perform tests for pneumothorax in every case at autopsy to correlate with LODOX findings.
5. To focus future study on a single variable in both the LODOX and the macroscopic and microscopic examinations.
6. Macroscopic variables should be agreed upon by at least 2 pathologists, to limit discrepancies.
7. To evaluate radiologist versus non-radiologist interpretation of LODOX digital images and the correlation with macroscopic and microscopic findings.

8.5 Summary of contributors

I hereby confirm that the author and supervisor significantly contributed to the study design, data acquisition, interpretation and the writing of the final manuscript.

This study has in no way been sponsored by the manufacturers of LODOX or its affiliates.

Reference List:

1. Hansell DM, Bankier AA, MacMahon H, McLoud TC, *et al.* Fleischner Society: Glossary of terms for thoracic imaging. *Radiology*. 2008; 246(3): 697-722.
2. Beningfield SJ, Potgeiter JH, Bautz P *et al.* Evaluation of a new type of direct digital radiography machine. *S Afr Med J*. 1999;89:1182-1188
3. Bateman C. New local scanners transform forensic pathology. *S Afr Med J*. 2008; 98(2):75-76.
4. Exadaktylos AK, Benneker LM, Jeger V, *et al.* Total body digital X-ray in trauma. An experience report on the first operational full body scanner in Europe and its possible role in ATLS. *Injury*. 2008; 39:525-529.
5. Lange C de, Vege A, Stake G. Radiography after unexpected death in the infants and children compared to autopsy. *Pediatr Radiology*.2007; 37(2):159-165.
6. Douglas TS, Fenton-Muir N, Kewana K. Radiological findings at a South African forensic pathology laboratory in cases of sudden unexpected death in infants. *S Afr J Radiol*. 2012; 16(1): 4-6
7. Stawicki SP, Aggrawal A, Dean AJ, *et al.* Postmortem use of advanced techniques: Is autopsy going digital. *OPUS 12 Scientist*. 2008; 2(4): 17-26.
8. Kahana T, Hiss J. Forensic Radiology. *Br J Radiol*.1999; 72:129-133.
9. Roberts ISD, Benamore RE, Benbow EW, *et al.* Post-mortem imaging as an alternative top autopsy in the diagnosis of adult deaths: a validation study. *Lancet*.2012; 379:136-142.
10. Tiemensma M, Burger EH. Sudden and unexpected deaths in an adult population, Cape Town, South Africa, 2001-2005. *S Afr Med J*.2012; 102(2): 90-94.
11. Baglivo M, Winklhofer S, Hatch GM, *et al.* The rise of forensic and post mortem radiology- Analysis of the literature between the year 2000 and 2011. *J For Rad and Imaging*. 2013; 1:3-9.
12. Sieswerda-Hoogendoorn T, Rijn R van. Current techniques in post mortem imaging with specific attention to paediatric applications. *J of Ped Radiol*. 2010; 40:141-152
13. Roulson J, Benbow EW, Hasleton PS, *et al.* Discrepancies between clinical and autopsy diagnosis and the value of post mortem histology; a meta- analysis and review. *Histopathology*. 2005; 47(6): 551-9.
14. Personal communication: Mr Stef Steiner, Lodox Systems.
15. Whiley SP, Mantokoudis G, Ott D, *et al.* A review of full body radiography in non-traumatic emergency medicine. *Emerg Med Int*. 2012 (Article ID108129, 8 pages)
16. Pitcher, RD, *et al.* The use of the Statscan digital X-ray unit in paediatric polytrauma. *J Pead Rad*. 2009; 39:433-437
17. Deyle S, Wagner A, Benneker LM. Could full-body digital X-ray (LODOX-Statscan) screening in trauma challenge conventional radiography? *J Trauma*. 2009; 66:418-422.

18. Harcke HT. The case for post mortem imaging. *J Pediatr Radiol.* 2010; 40(2):138-40.
19. Pitcher RD, Lombard C, Cotton MF, Beningfield SJ, Zar HJ. Clinical and immunological correlates of chest X-ray abnormalities in HIV-infected South African children with limited access to anti-retroviral therapy. *Pediatr Pulmonol.* 2014 Jun; 49(6):581-8.
20. Geldenhuys E. A Morphological assessment of the health status of a cadaver population at the Faculty of Health Sciences, Stellenbosch University, with special reference to tuberculosis (TB) lesion distribution [unpublished thesis]. Cape Town (South Africa): Stellenbosch University; 2014.
21. Kuijpers CCHJ, Fronczek J, Goot FRW (van der), *et al.* The value of autopsies in the era of high tech medicine: discrepant findings persist. *J Clin Pathol.* 2014; 67(6):512-519
22. Flach PM, Gascho D, Schweitzer W, *et al.* Imaging in forensic radiology: an illustrated guide for post mortem computed tomography technique and protocols. *Forensic Sci Med Pathol* (2014) March : DOI 10.1007/s12024-014-9555-6
23. Boffard KD, Goosen J, Plani F, *et al.* The use of the Low Dose X-ray (LODOX/ Statscan) in major trauma: comparison between low dose X-ray and conventional X-ray. *J Trauma-Injury, Infection and Critical Care.* 2006; 60 (6): 1175-1183
24. Wunderick RG, Radiologic Diagnosis of ventilator-associated pneumonia; *Chest.* 2000; 117; 188-190
25. Bourcier J, Paquet J, Seiger M, *et al.* Performance comparison of lung ultrasound and chest X-ray for the diagnosis of pneumonia in the ED. *Am J Emerg Med.* 2014; 32: 115-118
26. Bolursaz MR, Payam M, Aghahosseini F. Comparison of digital X-ray and thoracic CT scan in the childhood Tuberculosis. *Zehedan J Resp Med Sci.* 2015 (online version-published ahead of print).
27. Miniati M, Monti S, Stolk J, Value of chest radiography in phenotyping chronic obstructive pulmonary disease. *Eur Resp J.* 2008; 31: 509-514
28. Chen R, Fu, Wu S. Diagnostic accuracy, Biohazard safety, and cost effectiveness- The LODOX Statscan provides a beneficial alternative for the primary evaluation of patients with multiple injuries. *J Trauma, Injury, Infection and Critical Care.* October 2010; 69 (4) 826-830.
29. Wheen LC, Williams MP. Post-mortems in recreational scuba diver deaths: the utility of radiology. *J Forensic Legal Medicine.* 2009; 16: 273-276
30. Gadkowski LB, Stout JE. Cavitatory Lung Disease. *Clin Microbiol Rev.* April 2008; 21 (2): 305-333
31. Manser RL, Dodd M, Byrnes G, *et al.* Incidental lung cancers identified at coronial autopsy: implications for over diagnosis of lung cancer by screening. *Respir Med.* 2005 April 99(4): 501-507.
32. Bruggen-Bogaarts (van der) BAHA; Bruggen (van der) HMJG; Waes (van) PFGM, *et al.* Screening for Bronchiectasis. *Chest.* March 1996: 109 (3)

33. Sunderman WF, Boerner F: Normal values in clinical medicine. Philadelphia, WB Saunders, 1949.
34. Molina DK, DiMaio VJM. Normal organ weights in men. *Am J Forensic Med Pathol* 2012; 33: 368-372

Appendices

Appendix A:

Respiratory check list macroscopic:

	Right upper lobe	Right middle lobe	Right lower lobe	Left upper lobe	Left lower lobe	Other
Cavitation						
Oedema						
Emphysema						
Granulomas						
Acute inflammation						
Chronic inflammation						
Diffuse alveolar damage						
Intra-alveolar haemorrhage						
Other						

Appendix B

Respiratory check list microscopic:

	Right upper lobe	Right middle lobe	Right lower lobe	Left upper lobe	Left lower lobe	Other
Cavitations						
Oedema						
Emphysema						
Granulomas						
Acute inflammation						
Chronic inflammation						
Diffuse alveolar damage						
Intra-alveolar haemorrhage						
Other						