

in terrazzo — 'n permanente pleister — en die vensters is gemaak van geanodiseerde aluminium wat ook geen onderhoud verg nie. Aan die binnekant is daar gepoog om vloer-, muur- en plafonafwerking dwarsdeur die gebouegroep so eenvoudig en ekonomies moontlik te hou. Dit help om die student te oriënteer en om verwarring te voorkom. Die hele beplanning is konserwatief, met 'n mate van afwyking in buitevertoon om die maksimum geriewe op ekonomiese wyse aan die grootste aantal studente te gee

en om toe te laat dat aangepas kan word by toekomstige ontwikkelinge.

Die Departement van Hospitaaldienste, Kaapse Provinsiale Administrasie en die Universiteit van Stellenbosch word bedank vir toestemming om die inligting te publiseer. Dank en waardering word ook uitgespreek teenoor die argitekte en bou-aannemers van die gebouekompleks en teenoor almal op die gesamentlike diensstaat van die Universiteit en die Kaapse Provinsiale Administrasie vir hulle aktiewe deelname aan die beplanning en oprigting van dié besondere inrigting.

# Penetrating Wounds of the Heart and Great Vessels

## EXPERIENCE WITH 24 CASES INCLUDING 3 WITH INTRACARDIAC DEFECTS

J. J. DE WET LUBBE, P. M. C. JANSÖN, P. M. BARNARD

### SUMMARY

Twenty-four cases of penetrating cardiac injuries due to stab wounds, which were seen over a 3-year period, are reviewed. Ten patients were treated by aspiration alone because tamponade was mild, or because they were seen more than 12 hours after injury. One patient with multiple stab wounds in the ventricles and left atrium died during emergency thoracotomy in the admission room. The mortality rate of 4,2% is considerably lower than rates reported in other series.

Two cases of traumatic ventricular septal defects, one case of traumatic aortic incompetence and sinus of Valsalva fistulae with rupture into the right ventricle and right atrium, and one case of ascending aorta-innominate vein fistula are discussed. Our present plan of management is outlined.

*S. Afr. Med. J.*, 49, 512 (1975).

Department of Cardiothoracic Surgery, Tygerberg Hospital and University of Stellenbosch, Parowvallei, CP

J. J. DE WET LUBBE, M.B. CH.B., M.MED. (THOR.), Senior Specialist

P. M. C. JANSÖN, M.B. CH.B., Registrar

P. M. BARNARD, M.B. CH.B., M.D., Professor

Date received: 21 August 1974.

Reprint requests to: Professor P. M. Barnard, Department of Cardiothoracic Surgery, PO Box 63, Parowvallei 7503.

Penetrating knife wounds of the chest are frequently seen at the provincial hospitals of Cape Town. At the Karl Bremer and Tygerberg Hospitals, which serve an urban population of about 500 000 people, and which are also reference centres for many smaller country hospitals, approximately 25 such cases are admitted every month because of haemopneumothorax or cardiac wounds. Gun-shot wounds of the chest are very infrequent in this area, and this may account for the very low mortality reported in our series of 24 consecutive cases of penetrating cardiac trauma. Only patients who were alive upon arrival at hospital are included in this report. The only patient who died had a cardiac arrest upon arrival, and an emergency thoracotomy had to be done in the admission room.

### CLINICAL MATERIAL

Twenty-four patients with penetrating cardiac trauma were treated at the Karl Bremer Hospital during a 3-year period from June 1971 to May 1974. All the injuries were knife-inflicted, and they are divided into three groups according to therapy.

#### Group I — Non-operative Treatment (Table I)

These 10 patients did not undergo operation for various reasons. Three patients were seen 1 day after injury,

and cardiac tamponade was relieved immediately by a single aspiration. Two patients who initially suffered only from pneumopericardium developed signs of tamponade while under observation, and were treated by pericardiocentesis only.

TABLE I. GROUP I — CONSERVATIVE TREATMENT

Patient No.	Age	Sex	Number of aspirations	Result
1	18	M	1	Recovered
2	26	M	2	Recovered
3	30	M	1	Recovered
4	21	M	1	Recovered
5	18	M	1	Empyema
6	23	F	2	Recovered
7	36	M	1	Pericarditis
8	19	M	3	Recovered
9	15	M	1	Recovered
10	19	M	1	Pericarditis

Five patients with tamponade were seen within hours of injury, but they were not in severe shock, and responded promptly to pericardiocentesis.

All patients were admitted to the intensive care room, and were strictly observed for at least 2 days. One patient needed 3 aspirations, but according to our present plan of management would have undergone surgery after the second aspiration.

One patient developed empyema which was treated by intercostal drainage only. Two patients developed pericarditis with fever and a friction rub but purulent pericarditis did not develop. All 10 patients recovered completely and no recurrences were seen.

### Group II — Immediate Operation (Table II)

Of the 8 cases listed in Table II, 4 had severe tamponade due to wounds in the right ventricle, varying from 8 to 10 mm in length. One midline sternotomy and 3 left anterolateral thoracotomies were performed. In 2 cases where cardiac arrest occurred prior to induction of anaesthesia, the chest and pericardium were rapidly opened and cardiac massage was performed. Both patients recovered completely. Bleeding from the ventricle could in all cases easily be controlled by direct suturing. All 4 patients

TABLE II. GROUP II — IMMEDIATE OPERATION

Patient No.	Age	Sex	Injury	Outcome
1	22	M	Right ventricle 8 mm	Recovered
2	18	M	Pericardium stab only	Recovered
3	23	M	Right ventricle 10 mm	Recovered
4	27	M	Right ventricle 8 mm	Recovered
5	21	M	SVC innominate vein	Recovered
6	25	F	LV, RV, LA	Died
7	19	M	Pericardium stab only	Recovered
8	24	M	Right ventricle 10 mm	Recovered

survived without any significant complications. One patient developed a right upper lobe atelectasis, which cleared with bronchoscopy and physiotherapy.

One young woman underwent emergency thoracotomy for tamponade and cardiac arrest in the emergency room. She had multiple stab wounds through both ventricles and the left atrium, and could not be resuscitated. This patient was the only fatality in this series.

One patient had partial severance of the superior vena cava at the entrance into the pericardium with complete severance of the phrenic nerve. A massively clotted right haemothorax controlled the bleeding until after the chest was opened. The entrance wound was through the right supraclavicular fossa where the right innominate vein was also injured. The patient required 15 units of blood, but made a complete recovery.

Two patients underwent exploratory surgery because of shock and pericardial wounds, but no cardiac injury was found at operation.

### Group III — Delayed Operation (Table III)

Two cases of severe tamponade were seen after being treated elsewhere. In each case the constriction was caused by a mass of clot, fibrin and fluid, and pericardiectomy was done with uneventful recovery.

Cardiopulmonary bypass had to be employed in 4 patients, and will be described more fully.

TABLE III. GROUP III — DELAYED OPERATION

Patient No.	Age	Sex	Injury	Outcome
1	18	M	VSD	Recovered
2	23	M	VSD	Recovered
3	16	M	Aortic incompetence, sinus of Valsalva fistulae	Recovered
4	42	M	Aorta-innominate vein fistula	Recovered
5	23	M	Pericardial tamponade	Recovered
6	18	M	Pericardial tamponade	Recovered

Cases 1 and 2 were young men, stabbed between 6 and 12 months previously. Both were sent to hospital because of a harsh pansystolic murmur, moderate cardiac enlargement and increased pulmonary vascular marking on chest X-ray. Both denied any cardiac illness prior to having been stabbed in the chest. Cardiac catheterisation demonstrated moderate pulmonary hypertension with normal pulmonary vascular resistance and a high ventricular septal defect, with shunts calculated at 36% and 15% of pulmonary blood flow respectively.

Through a median sternotomy dense pericardial adhesions were found in both cases and the septal defects were easily repaired with interrupted sutures through the fibrotic edges. No complications occurred.

Case 3, a 16-year-old male with a stab wound through the third left intercostal space, was operated on for pericardial tamponade 1 day after having been stabbed. No actively bleeding wound could be found through a

left anterolateral thoracotomy. Postoperatively, a decrescendo diastolic murmur was heard, and a wide pulse pressure was noticed. Severe aortic incompetence with a ventricular septal defect (VSD) was diagnosed at cardiac catheterisation.

Through a median sternotomy approach the tissues were found to be oedematous. On opening the right ventricle a sinus of Valsalva fistula between the right coronary cusp and the right ventricle was found, and was repaired by suturing. As no VSD was found, the aorta was cross-clamped and opened. It was found that the previous stab wound had penetrated both the right coronary and the non-coronary cusps of the aortic valve (Fig. 1).

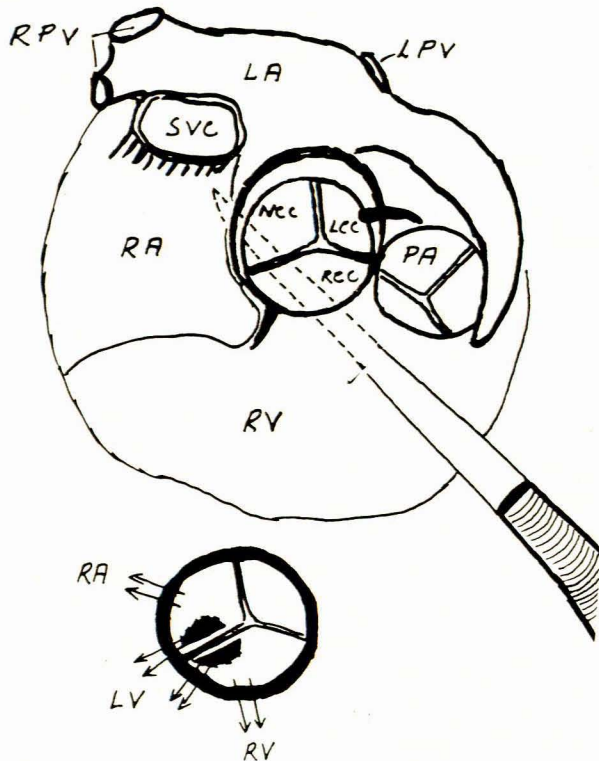


Fig. 1. Pathway of the knife through the right ventricle, root of the aorta and the right atrium. The inset shows the defects in the right coronary and non-coronary sinuses of Valsalva and their corresponding leaflets. The arrows point in the directions of the blood flow (RA = right atrium, RV = right ventricle, LA = left atrium, PA = pulmonary artery, SVC = superior vena cava, RPV = right pulmonary veins, LPV = left pulmonary vein, RCC = right coronary cusp, LCC = left coronary cusp, NCC = non-coronary cusp).

The aortic cusps were repaired by direct suturing but an urgent re-operation was necessary within hours because aortic incompetence recurred when the sutures cut through the friable leaflet tissue. The aortic valve was excised and replaced with a Starr-Edwards prosthesis in a narrow aortic root. In retrospect, the sinus of Valsalva right atrial fistula had thus been missed both at cardiac catheterisation and at surgery.

Because of severe pulmonary complications, the patient had to have a tracheostomy and prolonged ventilatory assistance. He subsequently developed tracheal stenosis which was successfully treated by bronchoscopic excision of scar tissue and tracheal dilatation.

During outpatient follow-up a continuous murmur of increasing severity accompanied by progressive cardiac enlargement and dyspnoea was heard. At re-catheterisation one year after surgery, a sinus of Valsalva fistula was diagnosed with a left-to-right shunt of 7.74 l/min. At re-operation, two fistulae between the sinuses of Valsalva and the right atrium and right ventricle were found. The previous repair of the fistula between the sinus of Valsalva and the right ventricle had broken down. The fistulae were repaired through a right ventriculotomy which offered good exposure to closure of the right atrial fistula through the tricuspid valve as well. The patient remains well more than one year following surgery.

**Case 4**, a middle-aged male, stabbed through the sternum 2 weeks prior to admission was initially treated elsewhere. A loud continuous murmur and a thrill were present over the base of the heart. At cardiac catheterisation, a diagnosis of aortic-right atrial fistula with a left-to-right shunt of 8.24 l/min (44% of pulmonary blood flow) was made.

On exploration through a median sternotomy a large false aneurysm overlying the ascending aorta was found. The patient was cooled to 26°C with cardiopulmonary

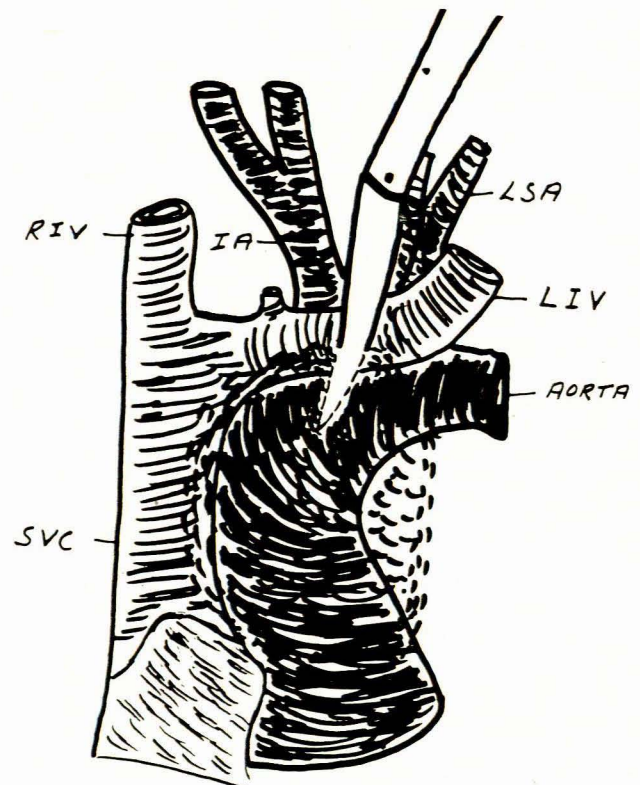


Fig. 2. Pathway of the knife through the side of the left innominate vein and anterior wall of the aorta (LIV = left innominate vein, SVC = superior vena cava, RIV = right innominate vein, LSA = left subclavicular artery, IA = innominate artery).

bypass, the circulation was arrested and the aneurysm opened. The knife had gone through the side of the left innominate vein and had penetrated the anterior wall of the ascending aorta, creating a 1-cm wide A-V shunt (Fig. 2).

A Fogarty catheter was placed through the fistula into the aorta, and the balloon was inflated and withdrawn, thus closing the aortic part of the fistula. The circulation was restarted, and the vascular wounds were closed at leisure. The total time of circulatory arrest was 4 minutes, and no postoperative complications occurred.

## DISCUSSION

An acute pericardial tamponade with a pressure of 12-22 cm of water causes death in the dog.<sup>1</sup> The animal can be saved by removal of only a fraction of the fluid in the pericardium, or by the raising of the central venous pressure. Both these methods have been used as standard treatment for cardiac tamponade for many years, and are still of great value today. Cardiac arrest is not caused by inhibition of venous return, but rather by the lack of diastolic filling of the ventricles.

Rehn<sup>2</sup> is credited with the first successful suture of an actively bleeding 1.5-cm wound of the right ventricle. Although approximately 1 500 cases of penetrating cardiac injuries have appeared in the literature up to 1968,<sup>3</sup> only a few cases of intracardiac shunts after penetrating wounds have been recorded.<sup>4</sup>

Since the reports of Blalock and Ravitch<sup>5,6</sup> concerning the non-operative treatment of cardiac tamponade appeared, there has been a gradual shift, in recent years, towards a more aggressive surgical approach in cases with severe tamponade, leading to an increased salvage rate. During the period 1966-1971, the mortality for stab wounds in Houston<sup>7</sup> was reduced from 22% to 13%, and for gunshot wounds from 40% to 31%. More than half these deaths occurred in the emergency room, where a desperate attempt at resuscitation was made. In all but 3 of their last 72 cases of penetrating heart wounds, most of which were gunshot wounds, thoracotomy and cardiorrhaphy were done.

Most patients with penetrating cardiac trauma do not reach the hospital alive. The prehospital mortality rate varies from 60% to 81%<sup>3</sup> in most large American centres. The instrument used to inflict the injury plays a major role in determining survival — 80% in a series of 373 deaths were due to gunshot wounds, and 20% of the deaths followed stab wounds.<sup>3</sup>

Wounds of the ventricles comprise the majority of heart injuries. Since the right ventricle forms the anterior surface of the heart, it is most often injured (Fig. 3). Bleeding from the ventricle is easily controlled by placing the left index finger on the wound, and inserting mattress sutures through the wound edges underneath the finger (Fig. 4).

Complicated intracardiac defects can only be repaired with the aid of cardiopulmonary bypass and careful pre-operative delineation of the lesions with cardiac catheterisation.

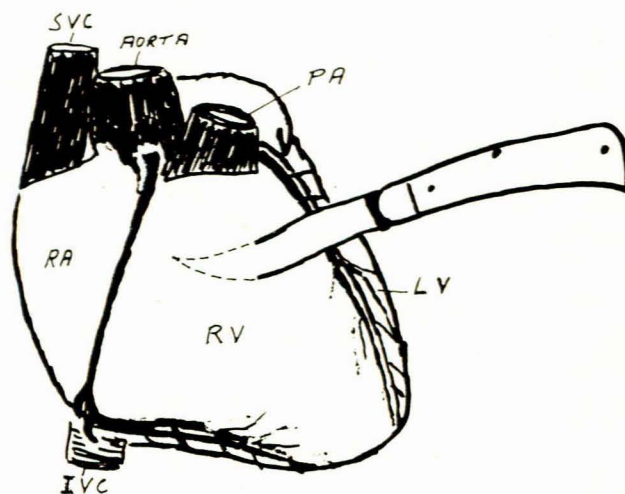


Fig. 3. The right ventricle (RV) is most commonly injured by knife wounds.

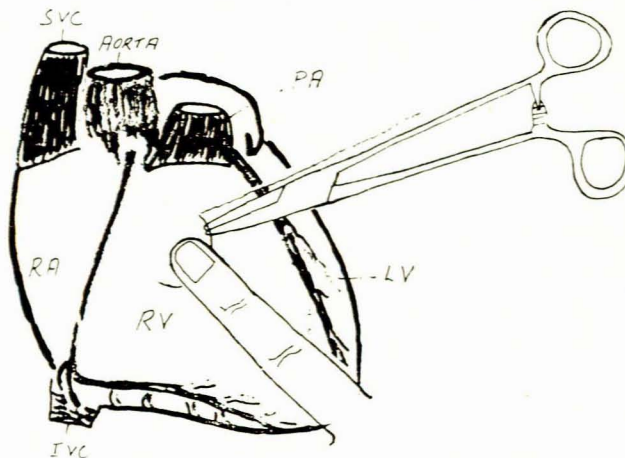


Fig. 4. The index finger on the wound controls bleeding and mattress sutures are inserted underneath the finger.

## Intracardiac Shunts

An unusual variety of fistulae between neighbouring structures is possible after penetrating cardiac wounds. The right ventricular outflow tract, aortic root and right atrium are most commonly involved if a fistula develops. Traumatic defects in the ventricular septum have more commonly been reported after blunt trauma, than after penetrating injuries. Only isolated reports of such injury following penetrating injuries have appeared in the literature.<sup>8-10</sup>

Spontaneous closure of a traumatic ventricular septal defect has been reported.<sup>11</sup> Most cases do not require immediate corrective surgery, as in our 2 cases. A conservative approach to the patient with a haemodynamically small lesion is probably indicated.

Traumatic sinus of Valsalva fistulae are very rare. Only 2 cases of traumatic VSD, sinus of Valsalva fistula

and aortic incompetence have been documented.<sup>12,13</sup> There have been isolated reports of aorta-right atrium fistula<sup>11</sup> and aorta-right ventricular fistula<sup>15,16</sup> after trauma. Our single case is probably unique, in so far as rupture occurred into the right ventricle and the right atrium with concomitant damage to two aortic leaflets. In view of our experience and that of others,<sup>12</sup> a badly damaged aortic valve is best dealt with by prosthetic valve replacement.

Coronary artery lesions did not occur in our series, and this is probably an indication of the lethal nature of this injury. Coronary wounds carry a 20% higher mortality after admission than other penetrating cardiac injuries,<sup>17</sup> owing to the high incidence of arrhythmia and cardiogenic shock. With the ever increasing sophistication in coronary artery surgery with saphenous vein interposition or bypass, a better salvage rate of this type of injury could possibly be expected in future.

### Present Plan of Management

Our present policy concerning the management of penetrating cardiac trauma is as follows: a non-operative approach is used only when the patient is seen late after injury, and exhibits only mild signs of tamponade. These patients have a pericardiocentesis, and are observed in the intensive care unit. All other cases of penetrating

cardiac trauma are explored. Pericardial aspiration may be a life-saving procedure prior to thoracotomy, and should be done in all cases of tamponade. When intra-cardiac defects are suspected, operation should still be carried out to relieve tamponade, and to suture the external cardiac wound. Cardiac catheterisation studies can be carried out afterwards, and the intracardiac defects can be repaired at a later stage.

### REFERENCES

1. Kuno, U. (1917): *J. Physiol.*, **51**, 221.
2. Rehn, L. (1897): *Arch. Klin. Chir.*, **55**, 315.
3. Sugg, W. L., Rea, W. J., Ecker, R. R., Webb, W. R., Rose, E. F. and Shaw, R. R. (1968): *J. Thorac. Cardiovasc. Surg.*, **56**, 531.
4. Summerall, C. P., Lee, W. H. and Boone, J. A. (1965): *New Engl. J. Med.*, **272**, 240.
5. Blalock, A. and Ravitch, M. M. (1943): *Surgery*, **14**, 157.
6. Ravitch, M. M. and Blalock, A. (1949): *Arch. Surg.*, **58**, 463.
7. Beall, A. C., Patrick, T. A., Okies, J. E., Bricker, D. L. and De Bakey, M. E. (1972): *J. Trauma*, **12**, 468.
8. Lui, A. H. F., Glas, W. W. and Bercu, B. A. (1965): *J. Thorac. Cardiovasc. Surg.*, **49**, 517.
9. Williams, G. D., Hara, M. and Bullock, R. (1966): *Amer. J. Cardiol.*, **18**, 907.
10. Leaver, D. G., Sharma, R. N. and Glennie, J. S. (1970): *Brit. Heart J.*, **32**, 561.
11. Walker, W. J. (1965): *Amer. J. Cardiol.*, **15**, 263.
12. Berger, R. L., Gibson, H. jun., Riemer, R. W. and Ramaswamy, K. (1969): *N. Engl. J. Med.*, **281**, 887.
13. Desser, K. B., Benchimol, A., Cornell, W. P. and Nelson, A. R. (1971): *J. Thorac. Cardiovasc. Surg.*, **62**, 830.
14. Swanepoel, A., Schrire, V., Nellen, M., Vogelpoel, L. and Barnard, C. N. (1961): *Amer. Heart J.*, **61**, 121.
15. Smyth, N. P. D., Adkins, P. D., Kelsner, G. A. and Catalayud, J. (1959): *Surg. Gynec. Obstet.*, **109**, 566.
16. King, H. and Shumaker, H. B. (1958): *J. Thorac. Surg.*, **35**, 734.
17. Rea, W. J., Sugg, W. L., Wilson, L. C., Webb, W. R. and Ecker, R. R. (1969): *Ann. Thorac. Surg.*, **7**, 518.