

Conclusion

Some people do not want high-powered medicine to preserve the length of their life at whatever the cost in quality. This the medical profession must learn to accept. We were powerless to stop the patient from refusing hospital treatment unless we used sedation. She had decided to die outside the hospital, but we were against this on the grounds of the schizophrenia. If she had had epilepsy or diabetes would our actions against her leaving the hospital have been the same? What direction should the hospice movement be taking so as to accommodate a case like this within their walls? While all definitions of the hospice concept do state theoretically that *all* terminally ill patients can seek their help,

the question arises as to what extent this is true? This case demonstrates that in practice the criteria for admission to a hospice unit are severely limited as regards certain types of patients.

REFERENCES

1. Kubler-Ross E. *On Death and Dying*. 1st ed. London: Tavistock Publications, 1977.
2. Levin SM, Berman C, Bernstein G, Barnes B. The dying patient — attitudes and responses. *S Afr Med J* 1981; **59**: 21-24.
3. Kutscher AN, Kutscher LO. *Arch Foundation Thanatol* 1979; **7**: 2.
4. Levin SM. An overview of thanatology and defects in the medical curriculum. *Leech* 1981; **51**: 13-15.
5. Saunders C. Control of pain in terminal cancer. *Nurs Times* 1976; **72**: 1133-1135.

Gastric ulcer diagnosed on a plain abdominal radiograph

H. C. PARADISGARTEN

Summary

On occasion gastric ulcers may be recognized on plain abdominal radiographs. A case in which a gastric ulcer was diagnosed on the plain abdominal radiograph, illustrating the importance of careful scrutiny of the plain film in all cases of acute abdomen, is presented. The existence of the lesser curvature ulcer was confirmed on barium contrast studies.

S Afr Med J 1983; **63**: 494-495.

Gastric ulcers are diagnosed radiographically by barium contrast studies. The majority (95%) of gastric ulcers are benign,¹ and are located on the lesser curvature of the stomach where they typically present as a single ulcer crater.^{1,2} Patients with gastric ulcers may present in acute abdominal distress at a time when routine barium studies are not immediately available. A case is presented to illustrate that gastric ulcers may occasionally be recognized on the plain abdominal radiograph.

Case report

A 62-year-old Black woman presented at the Casualty Depart-

ment of Tygerberg Hospital on the evening of 25 February 1981 complaining of severe epigastric pain, marked vomiting and fatigue. She had been anorexic for about 3 weeks, with onset of nausea and vomiting (particularly after meals) 5 days before admission. Other symptoms included persistent heartburn and weight loss. There was no history of dysphagia, haematemesis or melaena. She admitted having regularly taken large quantities of aspirin during the previous 6 months. Relevant findings on physical examination included moderate abdominal tenderness with no evidence of frank guarding or rigidity, and slight enlargement of the liver. The haemoglobin concentration was 10,5 g/dl, and there was 1+ proteinuria. The differential diagnosis at presentation included acute gastritis, gastric ulcer and pyloric obstruction.

A plain radiograph of the abdomen taken in the Casualty Department that evening revealed a 2 cm wide by 1 cm deep ulcer crater situated on the lesser curvature, on the pars media of the stomach (Fig. 1). The existence, size and location of the gastric ulcer was confirmed on standard barium meal examination (Fig. 2) performed 1 day after the acute condition of the patient had subsided. Her symptoms continued to improve with conservative medical management, and she was discharged to follow-up 1 month later.

Discussion

The classic radiological signs of a chronic gastric ulcer (Figs 1 and 2) as seen on single- or double-contrast barium meal examination are well known. By definition a chronic gastric ulcer implies extension and penetration of the original disease process through the gastric mucosa to involve the submucosal and deeper layers of the stomach wall. This in turn results in stomach wall distortions that give rise to the characteristic radiological signs of a (chronic) gastric ulcer.²

Department of Radiology, Tygerberg Hospital, Parowvallei, CP

H. C. PARADISGARTEN, M.B. CH.B., D.M.R., Senior Radiologist

Date received: 27 May 1982.
Reprint requests to: Dr H. C. Paradisgarten, Dept of Radiology, Tygerberg Hospital, Tygerberg, 7505 RSA.

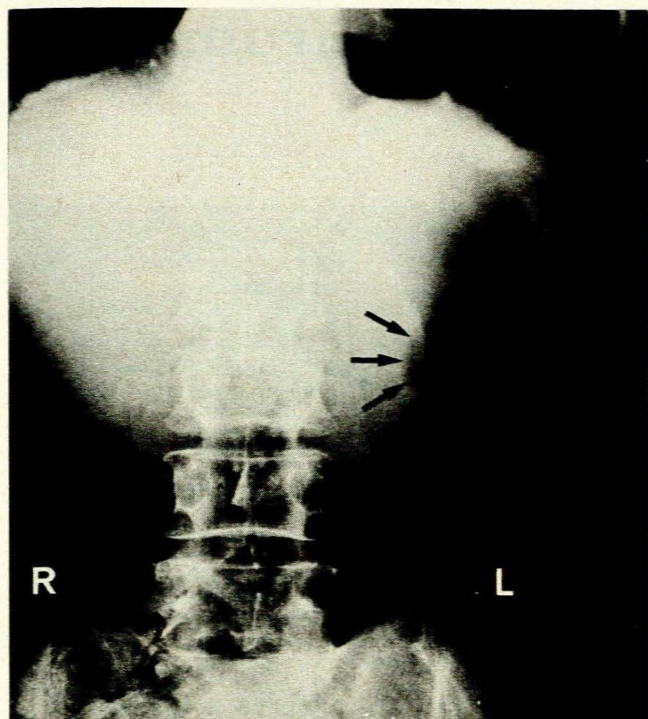


Fig. 1. Plain abdominal radiograph taken in the anteroposterior position. The stomach is dilated with air and the ulcer is seen as an outpouching in the middle third of the lesser curvature of the stomach. The arrows are outside the stomach and delineate the peritoneal surface of the ulcer crater.

Chronic gastric ulceration is estimated as affecting 0,4% of the general population, although this figure varies considerably in different countries.³ The ratio of the occurrence of gastric and duodenal peptic ulceration ranges from 1:4 to 1:17, with coexistence rates (i.e. an ulcer in both locations simultaneously in the same patient) of up to 50%. Gastric ulcers are most commonly diagnosed in elderly males with poor socio-economic backgrounds.³

The rarity of diagnosing a gastric ulcer on a plain abdominal radiograph is perhaps partly a result of the lack of awareness that this entity may indeed be visible on plain films, particularly when the stomach is distended with air ('air contrast'). Rarely, a careful inspection of the gastric contours may reveal the presence of an ulcer crater in patients with suggestive symptoms such as those described in this article. The question of malignancy, however, cannot be settled on the basis of the plain radiograph.

Barium studies are indicated for the confirmation of the presence of the gastric ulcer, and in order to provide additional information on such factors as mobility and motility of the stomach and the presence or absence of pyloric obstruction. The double-contrast technique increases the diagnostic accuracy,⁴ and is rapidly gaining favour as the accepted technique, particularly for the detection of small ulcers or multiple and unusual ulceration (as seen in the Zollinger-Ellison syndrome, for example).

Causes of difficulty or error in distinguishing between benign and malignant lesions of the stomach by radiological⁵ or endo-

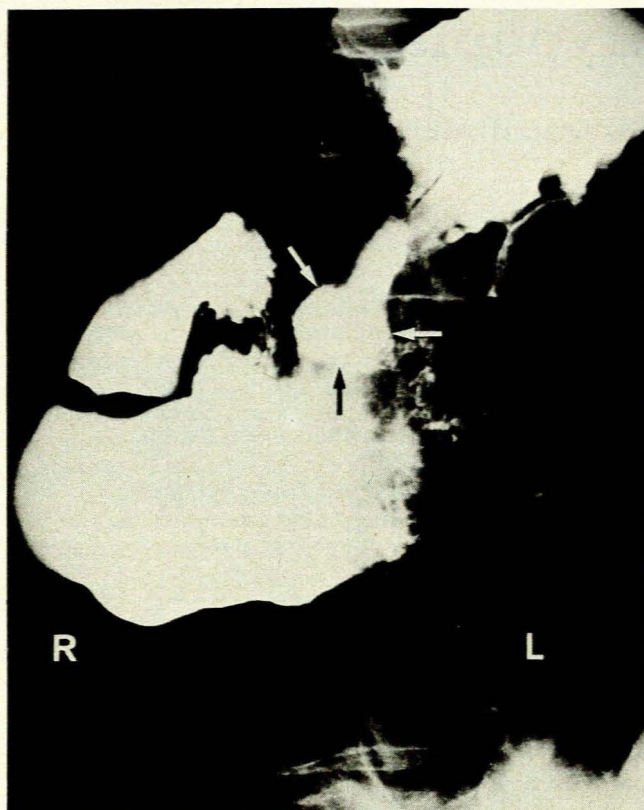


Fig. 2. A selected view (slightly oblique supine) from a barium meal series taken 1 day after the radiograph in Fig. 1. The gastric ulcer in Fig. 1 is now clearly demonstrated as a contrast-filled crater viewed end-on. The 3 arrows delineate the outer contours of the ulcer.

scopic⁶ techniques have been well documented. The size, location or shape of a gastric ulcer alone are not of pathognomonic significance in differentiating benign from malignant lesions.

I wish to thank Professor J. A. Beyers, Head of the Department of Radiology, Tygerberg Hospital, for his constant encouragement and interest. My grateful thanks also to Dr A. R. Eden of the Mount Sinai Medical Center, New York, USA, for his interest and assistance in the preparation of this paper, and to the Medical Superintendent of Tygerberg Hospital for permission to publish.

REFERENCES

1. Nelson SW. The discovery of gastric ulcers and the differential diagnosis between benignancy and malignancy. *Radiol Clin North Am* 1969; 8: 5-25.
2. Samuel E, Laws JW. The stomach and duodenum. In: Sutton D, ed. *A Textbook of Radiology and Imaging*. 3rd ed. Edinburgh: Churchill Livingstone, 1980: 681-712.
3. Rudick J. Gastric ulcer. In: Nyhus LM, Wastell C, eds. *Surgery of the Stomach and Duodenum*. 3rd ed. Boston: Little, Brown, 1977: 191-210.
4. Editorial. Sense and sensitivity about the barium meal. *Lancet* 1980; i: 1171-1172.
5. Gelfand DW, Ott DJ, Tritico R. Causes of error in gastrointestinal radiology. *Gastrointest Radiol* 1980; 5: 91-97.
6. Wright JP, Kahanovitz C, Marks IN. Gastric ulceration — a follow-up study. *S Afr Med J* 1981; 60: 611-612.