

Anaesthesia for congenital lobar emphysema resection

A case report

K. PAYNE, W. VAN ZYL, M. RICHARDSON

Summary

A case of congenital lobar emphysema and a discussion on the anaesthetic management is presented.

S Afr Med J 1984; **66**: 421 - 422.

Congenital lobar emphysema is a rare condition usually presenting in the first month of life.¹ The cause is unknown in half the cases; in a quarter there is localized bronchial cartilaginous dysplasia and the remaining quarter are due to miscellaneous causes of bronchial obstruction.² This results in over-inflation of alveoli, leading to disruption of the anatomy and loss of elasticity. The distended side ceases ventilatory exchange, and the opposite side is compressed. Lung function is grossly impaired.

Case report

A 2-week-old child presented to a general practitioner with a history of cough and tachypnoea present from birth. Examination was non-contributory and the child was treated for a respiratory infection. Two weeks later the child returned. On examination, tachypnoea was still present plus right-sided intercostal recession and the right chest was flatter than the left. The right side was also duller on percussion than the left, and the chest radiograph was thought to show severe right lung collapse; the child was transferred to Tygerberg Hospital.

On admission the 2,4 kg child was apyrexial and cyanosed with a respiration rate of 60/min and a distended left chest. The pulse was 160/min and on room air the partial arterial oxygen pressure (P_{aO_2}) was 3,7 kPa and the partial arterial carbon dioxide pressure (P_{aCO_2}) 8,7 kPa. These values improved on 85% oxygen to P_{aO_2} 13 kPa and P_{aCO_2} 6,6 kPa. A chest radiograph revealed gross distension of the left lung, displacing the mediastinum and compressing the right lung (Fig. 1). Congenital left lobar emphysema was diagnosed and the child, now in a stable condition, was prepared for surgery the next morning.

In theatre the intravenous butterfly line was replaced by a 22-gauge Teflon cannula. Atropine 0,06 mg was given intravenously and ECG leads were connected; awake intubation was performed using an oral uncuffed 3 mm RAE tube. Anaesthesia was maintained with oxygen and halothane 1,5% via an Ayres T-piece and gentle assisted hand ventilation. A blood pressure

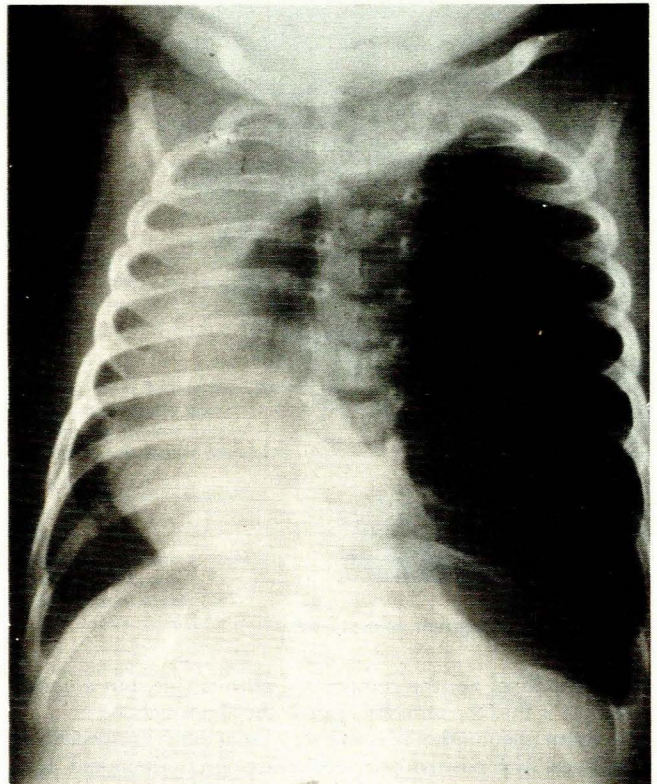


Fig. 1. Chest radiograph, anteroposterior view.

cuff and dopplometer were connected, as was a temperature probe. Surgery commenced with the child in the right lateral position. On opening the chest, the emphysematous left upper and middle lobes ballooned out, the left lower lobe being completely collapsed. The affected lobes were excised, the left lower lobe was gently inflated, and the chest closed with an underwater drain. Blood pressure remained stable at 60 mmHg throughout.

Postoperatively the baby was extubated and breathed well. In intensive care he was given 25% oxygen via a head hood overnight and made an uneventful recovery. Postoperative blood gas values on 25% oxygen were P_{aO_2} 12,5 kPa and P_{aCO_2} 6,1 kPa.

Discussion

Congenital lobar emphysema presents specific anaesthetic problems apart from the usual ones which apply in a small baby. The diagnosis is often difficult to make and must be differentiated from the sudden-onset dyspnoea which may result from foreign-body aspiration. There is usually a subacute history of respiratory problems but a sudden ball-valve effect may precipitate the clinical picture.² Frequently attention is diverted to the so-called

Anaesthetics Department, Tygerberg Hospital, Parowvallei, CP

K. PAYNE, F.F.A. R.A.C.S., *Principal Specialist*

W. VAN ZYL, M.B. CH.B., *Clinical Assistant*

M. RICHARDSON, M.B. CH.B., *Clinical Assistant*

Reprint requests to: Dr K. Payne, 36 Elizabeth Ave, Pinelands, 7405 RSA.

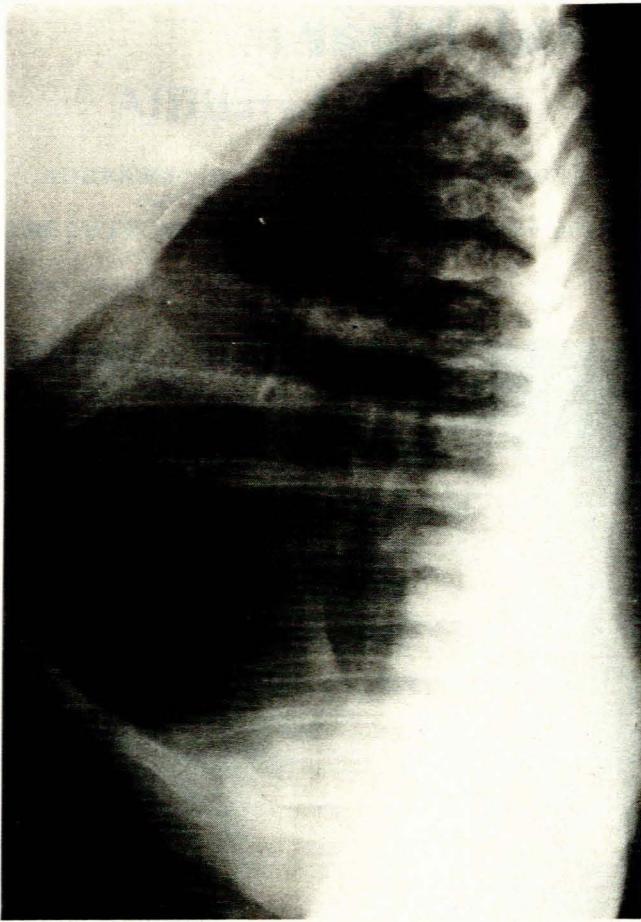


Fig. 2. Chest radiograph, lateral view.

atelectatic lung, i.e. the compressed normal side, but a useful principle is that the immobile side is the abnormal one.

Tension pneumothorax is an everpresent danger, especially if intubation with positive pressure ventilation is attempted. It is better to allow spontaneous respiration with a high inspired oxygen concentration whenever possible.³ Even if a true tension pneumothorax is not present, the clinical picture may be the same. Underwater drainage has been suggested for this situation⁴ and would be helpful if a congenital cyst was present but is unlikely to be of benefit in congenital lobar emphysema.

Should air transport be needed, account must be taken of the low pressure of commercial airline cabins, i.e. equivalent to an

altitude of 2 440 m. According to Boyle's law this would lead to a 30% expansion of any trapped air during the flight.⁵ Transport should be in an oxygen-enriched humidified environment.

Before induction, an intravenous anticholinergic agent is needed to prevent bradycardia and further cardiovascular decompensation. Spontaneous respiration is preferred until the chest is open. Halothane in oxygen is a useful anaesthetic agent, both opiates and muscle relaxants being contraindicated until obligatory positive-pressure ventilation is needed because of the thoracotomy. Gentle hand-assisted ventilation early on is acceptable, provided a close watch is kept on pulmonary and cardiovascular stability. Nitrous oxide should be avoided as its solubility is much higher than that of nitrogen and the volume of trapped air will increase.⁶ An air-oxygen mixture would be beneficial but the means of administering this is not generally available.⁷ The surgeon should be in theatre for the induction as immediate surgical decompression may become necessary if positive-pressure ventilation is needed.

Endobronchial intubation has been advised⁸ but is very likely to obstruct the right upper lobe bronchus. Murray³ has used the unaltered Murphy eye of a RAE tube to permit right upper lobe ventilation. Generally, however, endotracheal intubation is satisfactory. As development of the lung continues after birth,⁹ the compressed lobe on the affected side will be mildly hypoplastic. Over-enthusiastic ventilation will predispose to rupture of alveoli.

Postoperatively, extubation is preferred with spontaneous respiration in an oxygen-enriched humidified atmosphere. Positive-pressure ventilation is usually unnecessary and carries the danger of stump rupture. An underwater chest drain is essential, as is close postoperative monitoring in an intensive care unit.

Similar problems are seen with congenital lung cysts or sequestered areas of lung.

REFERENCES

1. Steward DJ. *Manual of Pediatric Anesthesia*. New York: Churchill Livingstone, 1979: 134.
2. Brown TCK, Fisk GC. *Anaesthesia for Children*. Oxford: Blackwell Scientific Publications, 1979: 360.
3. Murray JF. Anaesthesia for congenital bronchogenic lung cyst resection. *Anaesth Intensive Care* 1983; **11**: 172-173.
4. Brown TCK, Fisk GC. *Anaesthesia for Children* Oxford: Blackwell Scientific Publications, 1979: 158.
5. Oxen HF. Carriage by air of the seriously ill. *Med J Aust* 1977; **1**: 537-540.
6. Tinker J, Vandam L, Cohn H. Tension lung cyst as a complication of postoperative positive pressure ventilation therapy. *Chest* 1973; **64**: 518-520.
7. Teeple E, Pavlov I. The use of compressed air made easy. *Anesthesiology* 1981; **55**: 696-697.
8. Gothard JWW, Branthwaite MA. *Anaesthesia for Thoracic Surgery*. Oxford: Blackwell Scientific Publications, 1982: 87.
9. Brown TCK, Fisk GC. *Anaesthesia for Children*. Oxford: Blackwell Scientific Publications, 1979: 4.