

Duodenal erosion with bleeding from a non-functioning islet cell tumour

A case report

R. D. SHUTTLEWORTH

Summary

A patient with a clinically non-functioning pancreatic islet cell tumour in the medial wall of the duodenum with erosion of the overlying mucosa presented with gastro-intestinal bleeding. At gastroduodenoscopy, the tumour with its apical ulcer was thought to be a leiomyoma. The lesion was excised locally and two other non-functioning APUDomas were shelled out of the body and tail of the pancreas.

S Afr Med J 1988; 73: 546-547.

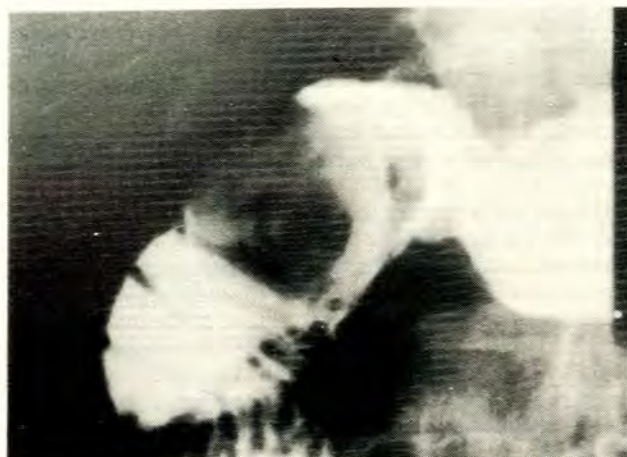

Fig. 1. Barium meal study showing the duodenal tumour.

Islet cell tumours of the pancreas usually draw attention to themselves because of the hormones they secrete. A minority have no clear-cut hormonal symptoms (somatostatinoma, pancreatic polypeptide-secreting APUDoma) or are hormonally inactive, and these present with symptoms related to mass or infiltration of adjacent structures. Gastro-intestinal haemorrhage is an unusual presentation.

Case report

A 71-year-old man, previously well except for several nodules in both lung fields which had remained static for 5 years and were thought to be granulomas, presented with melaena. A barium meal examination showed a mass in the second part of the duodenum with no central umbilication (Fig. 1). Gastroduodenoscopy revealed a smooth sessile polyp with a central ulcer, which was bleeding, on the medial wall at the junction of the first and second parts of the duodenum, thought to be a leiomyoma.

At laparotomy, the 3 cm tumour was locally excised from the medial wall of the duodenum above and anterior to the ampulla of Vater. Two further vascular tumours, 1.5 cm in diameter, were shelled out of their superficial position on the ventral surface of the body and tail of the pancreas. Mobilisation and careful palpation of the pancreas yielded no further tumours, and no other tumours were found in the abdomen or were palpable in the liver. The postoperative course was uneventful.

Histological examination and immunohistochemical investigation were compatible with 3 islet cell tumours. The cells were strongly argyrophilic, stained positively for neuron-specific enolase and a few cells also stained positively for insulin. The patient's fasting blood sugar and insulin levels before excision of the tumours showed no inappropriate insulin secretion. Immunohistochemical tests were negative for glucagon, gastrin, somatostatin, ACTH,

calcitonin and pancreatic polypeptide. These hormones were not assayed in the serum.

Discussion

The vascular tumours on the surface of the body and tail of the pancreas shelled out easily — had they been in the substance of the gland a distal pancreatectomy would have been more appropriate to avoid unrecognised damage to the pancreatic duct with consequent morbidity.¹ Had the patient not bled, it could be expected that the tumour in the duodenal wall would have enlarged until it caused duodenal obstruction, pain, mass or obstructive jaundice.^{2,3}

The obvious association between islet cell tumours and upper gastro-intestinal bleeding is the Zollinger-Ellison syndrome. Islet cell tumours have also presented with gastro-intestinal haemorrhage from oesophageal varices secondary to an arteriovenous fistula or occlusion of the splenic or portal vein.^{4,5}

Ectopic pancreatic tissue is more likely to produce symptoms if large and submucosal, and ulceration of the overlying mucosa has been described.^{6,7} In this patient, histological examination of the ulcer showed that the mucosa overlying the tumour underwent pressure necrosis — there were no features of chronic peptic ulceration and no central necrosis in the tumour.

The patient was referred by Dr P. E. S. Loubser, and the histology and immunohistochemistry was done by Dr U. von der Heyden, Department of Anatomical Pathology, Tygerberg Hospital.

Department of Surgery, University of Stellenbosch and Tygerberg Hospital, Parowvallei, CP
R. D. SHUTTLEWORTH, F.C.S. (S.A.), F.R.C.S.

REFERENCES

1. Broughan TA, Leslie JD, Soto JM, Hermann RE. Pancreatic islet cell tumors. *Surgery* 1986; 99: 671-678.

2. Brown CH, Neville WE, Hazard JB. Islet cell adenoma without hypoglycemia, causing duodenal obstruction. *Surgery* 1950; **27**: 616-620.
3. Kent RB, Van Heerden JA, Weiland LH. Non-functioning islet cell tumours. *Ann Surg* 1981; **193**: 185-190.
4. Ponsky RB, Homan M, Rhodes RS. Arteriovenous fistula and portal hypertension secondary to islet cell tumor of the pancreas. *Surgery* 1979; **85**: 408-411.
5. Maclean N, Falconer CWA, Gilmour IEW, Webb JN. Islet cell tumours of the pancreas with portal varices and gastro-intestinal haemorrhage. *J R Coll Surg Edinb* 1970; **15**: 206-212.
6. Armstrong CP, King PM, Dixon JM, MacLeod IB. The clinical significance of heterotopic pancreas in the gastro-intestinal tract. *Br J Surg* 1981; **68**: 384-387.
7. Barbosa J, Dockerty MB, Waugh JM. Pancreatic heterotopia. *Surg Gynecol Obstet* 1946; **82**: 527-542.

Embolisation of arteriovenous malformation of the spinal cord

A case report

P. A. FOURIE, M. J. VAN RENSBURG, P. R. BARTEL

Summary

An arteriovenous malformation of the spinal cord in a 41-year-old man treated by intra-arterial embolisation is reported. The progressive spastic weakness and severe burning pain responded well to treatment. The carefully calculated use of Ivalon particles is essential and is described. Evoked potentials were used to monitor the status of the spinal cord during the procedure. It is essential that a team of clinicians and radiologists be established at major centres to handle such cases.

S Afr Med J 1988; **73**: 547-550.

Arteriovenous (AV) malformations of the spinal cord can be classified into two types:¹ (i) extramedullary; and (ii) intramedullary. The extramedullary type can be either anterior or posterior to the spinal cord.

Treatment of these AV anomalies can be either by surgery or embolisation via the arterial feeders to the anterior spinal artery. Because of the problem of gaining access, surgery anterior to the cord is extremely difficult.

Embolisation must be performed with strict safety precautions to minimise the risk of cord ischaemia. Temporary occlusion by balloon catheter¹ and the use of evoked potentials² during the procedure are necessary. Particles used should be smaller than the anterior spinal artery lumen and larger than the intramedullary vessels.

Departments of Radiology, Neurosurgery and Neurophysiology, University of Pretoria and H. F. Verwoerd Hospital, Pretoria

P. A. FOURIE, M.B. CH.B., M.MED. (RAD.D.)

M. J. VAN RENSBURG, M.B. B.CH., F.C.S. (S.A.), F.R.C.S.

P. R. BARTEL, PH.D.

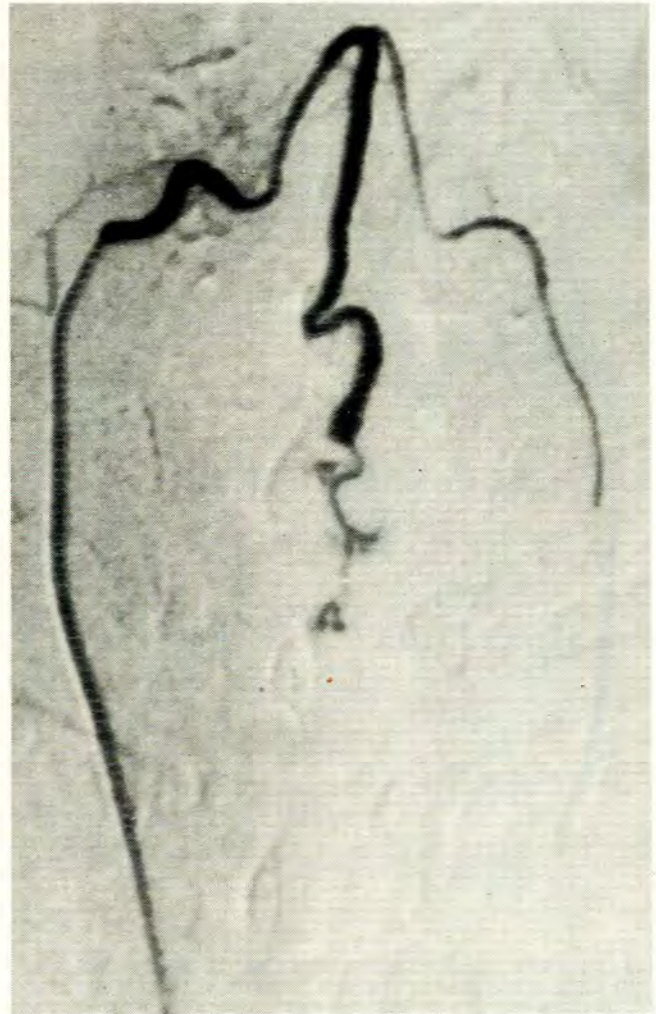


Fig. 1. Anterior spinal artery (middle) with catheter in branch of right thyrocervical artery. Overflow of contrast medium in left branch of left thyrocervical trunk.