



CLINICAL IMAGES

Disseminated tuberculous osteitis

D A Whitelaw, G Currie, N Littleton

A 25-year-old woman presented with a 6-month history of chronic non-productive cough, an increasingly 'lazy' tongue, a pussy discharge from the right ear with increasing deafness, and right-sided headaches. There was no history of previous tuberculosis (TB), weight loss, promiscuity, intravenous drug abuse or excessive ethanol use.

On examination the patient was not distressed, mildly pyrexial, normotensive and her respiratory system was normal. There were lower motor neuron lesions of the IX, X and XII nerves on the right, with conduction deafness of the right ear. The right eardrum was perforated, with a pussy discharge.

A chest radiograph revealed two eroded ribs. A high-resolution computerised tomography (CT) scan of the chest was normal. CT of the skull revealed a retropharyngeal mass. Biopsy yielded granulomas suggestive of chronic infection. Ziehl-Neelsen, Gram stains and cultures were negative. A technetium bone scan revealed multiple areas of increased uptake throughout the skeleton including the two eroded ribs (Fig. 1).

Biopsy of a rib revealed caseating granulomas and acid-fast bacilli. *Mycobacterium tuberculosis* was cultured.

The patient was commenced on a four-drug regimen (rifampicin, isoniazid, pyrazinamide and ethambutol) for 9 months. She rapidly regained her health and a repeat bone scan revealed that the bony lesions had cleared.

Discussion

Bone TB is a well-described but infrequent complication of *M. tuberculosis* infection. Nicholson¹ described 176 patients over a 20-year period and demonstrated a steady decline in incidence. Skeletal TB represented 0.05% of all tuberculous infections in

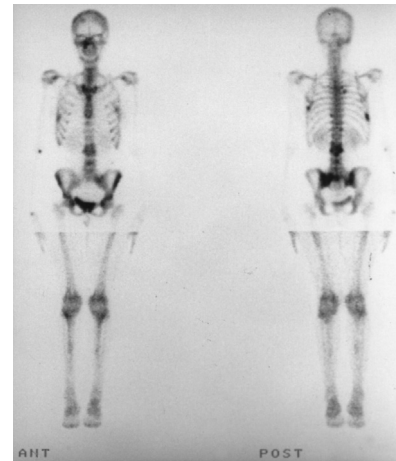


Fig. 1. Anteroposterior technetium isotope bone scan showing multiple areas of increased uptake.

the UK in 1992,² and 0.81% in Boston between 1968 and 1977.³ A 5.2% incidence was reported in the USA between 1928 and 1946.⁴ Bone TB is uncommon in patients with HIV infection.⁵

In this case the portal of entry remains unresolved. It is unlikely that the patient had pulmonary TB — 50% of patients with bone TB have a normal chest radiograph.³ No organisms were cultured from the discharging ear, which may have been the portal of entry, or from the resultant retropharyngeal tuberculoma. She did not develop lymphadenopathy, a common finding in patients with head and neck TB.⁶

Tuberculous osteitis is uncommon, even in patients with HIV infection.^{5,7,8} Multiple sites of osteitis are uncommon. Only Nicholson² mentions this — approximately 3% of his series had multiple sites involved. Definitive diagnosis depends on histological examination and culture.³ This case illustrates the multifaceted presentations of *M. tuberculosis* infection and the need to have a high index of suspicion, particularly in areas with a high incidence of the disease.

Dave Whitelaw is a senior consultant and lecturer in the Department of Medicine and Head of Rheumatology at Tygerberg Hospital. He has a special interest in connective tissue diseases.

Neil Littleton has an MMed in internal medicine and is now a senior registrar in the Department of Haematology and is completing his time in laboratory work.

Graham Curry was a senior student when this patient presented to the department. He has subsequently graduated and we unfortunately lost contact with him after he departed to complete his internship in KwaZulu-Natal. He was aware of the fact that we intended publishing this case and verbally agreed to be one of the co-authors.

1. Nicholson RA. Twenty years of bone and joint tuberculosis in Bradford. *J Bone Joint Surg Br* 1974; **56B**: 760-765.
2. Meredith SK, Aber VR, Nunn AJ, et al. National survey of notifications of tuberculosis in England and Wales in; 1988. *Thorax* 1992; **47**: 770-775.
3. Alvarez S, McCabe WR. Extrapulmonary tuberculosis revisited: A review of experience at the Boston City and other hospitals. *Medicine* 1984; **63**: 25-55.
4. LaFond EM. An analysis of adult skeletal tuberculosis. *J Bone Joint Surg Am* 1958; **49A**: 346-364.
5. Sunderam G, McDondald RJ, Mantias T, et al. Tuberculosis as a manifestation of the Acquired Immune Deficiency Syndrome. *JAMA* 1986; **256**: 362-366.
6. Penfold CN, Revington PJ. A review of 23 patients with tuberculosis of the head and neck. *Br J Oral Maxillofac Surg* 1996; **34**: 508-510.
7. Sathe SS, Reichman LB. Mycobacterial disease in patients infected with the human immunodeficiency virus. *Clin Chest Med* 1989; **10**: 445-463.
8. Chaison RE, Schechter GF, Theuer CP, et al. Tuberculosis in patients with the Acquired Immunodeficiency Syndrome. *American Review of Respiratory Disease* 1987; **136**: 570-574.