

given to the use of suxamethonium in minor procedures. If it is deemed mandatory, then some method which will prevent the occurrence of these pains must be used.

## REFERENCES

1. Bourne, J., Collier, H. O. J. and Somers, G. F. (1952): *Lancet*, **1**, 1225.
2. Churchill-Davidson, H. C. (1954): *Brit. Med. J.*, **1**, 74.
3. Foster, C. A. (1960): *Ibid.*, **2**, 24.
4. Gupte, S. R. and Savant, N. S. (1971): *Anaesthesia*, **26**, 436.
5. Usubiaga, J. E., Wikinski, J. A., Usubiaga, L. E. and Molina, F. (1967): *Anesth. Analg. (Cleveland)*, **46**, 225.
6. Haldia, K. N., Chatterji, S. and Kackar, S. N. (1973): *Ibid.*, **52**, 849.
7. Paton, W. D. M. (1959): *Anesthesiology*, **20**, 453.
8. Von König, W. (1956): *Anaesthetist*, **5**, 50.
9. Mayrhofer, O. (1959): *Ibid.*, **8**, 313.
10. Waters, D. J. and Mapleson, W. W. (1971): *Anaesthesia*, **26**, 127.
11. Barrow, M. E. H. and Smethurst, J. R. (1963): *Brit. J. Anaesth.*, **35**, 465.
12. Fuller, W. R., Davies, D. M. and Stradling, P. (1972): *Anaesthesia*, **27**, 292.
13. White, D. C. (1962): *Brit. J. Anaesth.*, **34**, 332.
14. Lamoreaux, L. F. and Urbach, K. F. (1960): *Anesthesiology*, **21**, 395.
15. Foldes, F. F., Monte, A. P., Brunn, H. M. and Wolfson, B. (1961): *Ibid.*, **22**, 230.

# Mesothelial Reaction to Asbestos and Other Irritants after Intraperitoneal Injection

F. M. ENGELBRECHT, B. F. BURGER

## SUMMARY

Ten groups of rats were injected intraperitoneally with one of the following suspensions; (i) standard reference crocidolite; (ii) acid-treated crocidolite (iii) crocidolite + iron oxide; (iv) crocidolite + silica; (v) iron oxide; (vi) silica; (vii) long fibre crocidolite; (viii) short fibre crocidolite; (ix) long fibre glass and (x) short fibre glass.

Two rats from each group were killed at 45, 90, 150, 240 and 330 days respectively, and the pathology induced by the different suspensions was studied histologically at each time interval. No evidence in support of the chemical induction theory or mechanical irritation theory in the pathogenesis of peritoneal mesotheliomas could be found, although all the suspensions except iron oxide caused a reactive mesothelium.

*S. Afr. Med. J.*, **49**, 87 (1975).

Clinical, epidemiological and experimental evidence indicates that asbestos, and especially the crocidolite variety, is extremely carcinogenic. However, the mode of action of asbestos as a carcinogen remains a matter of speculation.<sup>1</sup>

In a previous experimental study,<sup>2</sup> peritoneal mesotheliomas were induced in rats by asbestos suspensions after intraperitoneal injection. Histopathologically the asbestos fibres were first encapsulated by fibrous tissue and the latter covered by a layer of mesothelial cells. These meso-

thelial cells eventually underwent metaplasia, due either to soluble carcinogens slowly diffusing from the entrapped asbestos particles, or to the continuous mechanical irritation of the cells by the long needle-like fibres. It was also suggested that iron and silica compounds or other metal inclusions in the asbestos lattice were probably carcinogenic agents.

In following up these suggestions, the present experiments were planned to investigate, on a comparative basis, (i) the carcinogenicity of natural and acid-treated (metal-free) asbestos; (ii) the effects of iron and silica in association with acid-treated and natural asbestos, and (iii) the possible contribution of mechanical irritation in the pathogenesis of mesotheliomas.

## MATERIALS AND METHODS

### Samples

**Asbestos.** (a) UICC standard reference crocidolite, supplied by the Pneumoconiosis Research Unit, Johannesburg.

(b) Long fibre crocidolite, prepared from the standard reference sample by sedimentation of the long fibres in de-ionised water.

(c) Short fibre crocidolite, prepared by centrifuging the supernatant of (b) after allowing 30 minutes for the long fibres to sediment.

(d) Acid-treated crocidolite, prepared by successively boiling samples for 30 minutes with concentrated hydrochloric and nitric acid to remove soluble organic and inorganic components. After each treatment the samples were washed with de-ionised water until neutral, pH = 7.0.

**Glass:** After milling, commercial fibre glass was separated into long and short fibres by sedimentation and

MRC Tissue Damage and Cell Metabolism Research Group,  
Department of Physiology, University of Stellenbosch, Stellenbosch, CP

F. M. ENGELBRECHT, D.S.C.  
B. F. BURGER, M.S.C.

Date received: 25 September 1974.

centrifuging procedures.

**Silica.** Quartz dust (Dowson and Dobson) finely powdered and specially treated to remove impurities.

**Iron oxide.** Iron oxide — 97% pure (British Drug Houses).

All the samples were suspended in 0,9% saline and autoclaved before injection. The mean size and sized distribution of the particles in the suspensions are given in Table I.

TABLE I. MEAN SIZE AND SIZE DISTRIBUTION OF THE PARTICLES IN THE DIFFERENT SUSPENSIONS

	Percentage				Mean
	< 5 $\mu\text{m}$	6 - 9 $\mu\text{m}$	10 - 25 $\mu\text{m}$	> 25 $\mu\text{m}$	
<b>Crocidolite asbestos</b>					
UICC standard reference	7	41	30	22	11,5
Long fibre	4	18	50	28	22,2
Short fibre	65	30	5	0	4,7
Acid-treated	22	40	22	16	13,9
<b>Glass</b>					
Long fibre	54	21	12	13	12,9
Short fibre	98	2	0	0	2,4
Silica	92	8	0	0	2,5
Iron oxide	100	0	0	0	$\pm$ 1,0

## Animals

Female albino rats (*Rattus norvegicus*, Wistar Institute) of the same age and weight ( $140 \pm 10$  g) were used. The animals were divided at random into 10 groups of 10 each.

## General Procedure

The animals in a particular group were each injected intraperitoneally as previously described,<sup>2</sup> with the following suspensions:

- Group 1 — UICC standard reference crocidolite (50 mg/rat)
- Group 2 — acid-treated crocidolite (50 mg/rat)
- Group 3 — UICC standard reference crocidolite (50 mg/rat) + iron oxide (20 mg/rat)
- Group 4 — iron oxide (20 mg/rat)
- Group 5 — UICC standard reference crocidolite (50 mg/rat) + silica (20 mg/rat)
- Group 6 — silica (20 mg/rat)
- Group 7 — long fibre crocidolite (50 mg/rat)
- Group 8 — short fibre crocidolite (50 mg/rat)
- Group 9 — long fibre glass (50 mg/rat)
- Group 10 — short fibre glass (50 mg/rat).

## Duration of Experiment

Two animals from each group were killed at 45, 90, 150, 240 and 330 days after injection of the suspensions, re-

spectively. During the run of the experiment the animals were inspected daily for signs of abdominal distension. These animals were sacrificed even if this took place ahead of schedule. After macroscopic examination, blocks of tissue were selected from the abdominal organs for histological processing.

## RESULTS

Over the first 45 days crocidolite asbestos (standard reference, acid-treated, long and short fibre samples) induced proliferation of spherical and cyst-like nodules scattered all over the serosal surface of the abdominal viscera. The cysts consisted of a fibrous capsule containing fluid, and sometimes a few asbestos fibres. The spherical nodules were firm and more numerous than the cysts. Histologically these nodules revealed a typical foreign body reaction consisting of fibroblasts, macrophages, giant cells and other inflammatory cells.

The fibrous nodules from animals killed at 90 and 150 days were larger than the nodules of the initial stage, and consisted of a firm fibrous mass covered by a layer of mesothelial cells. Numerous plaque-like fibrous growths involving the peritoneum were usually found in the vicinity of the stomach, spleen, pancreas and liver. In most cases these pathological changes were accompanied by an accumulation of ascitic fluid on the abdomen. Where plaque-like structures adhered to the spleen and liver, the capsules of these organs were involved. In these areas the mesothelial cells reacted by proliferating into polyhedral or elongated, spindle-shaped cells (Fig. 1).

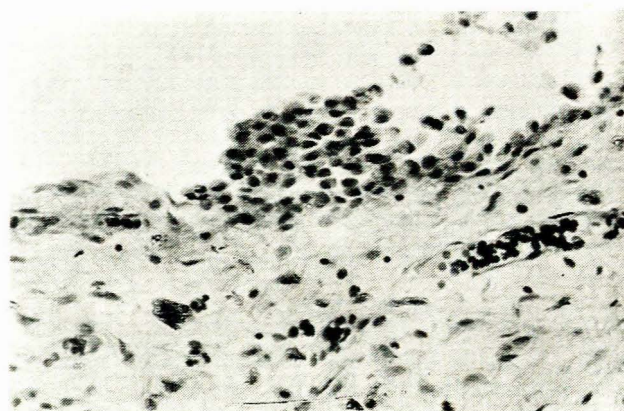


Fig. 1. Proliferating cells from the serosal surface of an asbestos granuloma 90 days after injection of crocidolite (H. and E.  $\times$  200).

At this stage it was, however, impossible to decide whether the proliferating, reactive mesothelial cells were benign or malignant.

Malignant mesotheliomas were found in the rats from the crocidolite groups killed at 240 and 330 days (Table II). These tumours consisted of nodular and plaque-like growths which infiltrated the organs and joined the viscera into a tight mass. Microscopically, malignant cells were usually located on the periphery of these fibrous

TABLE II. NUMBER AND TYPE OF MALIGNANT MESOTHELIOMAS IN THE DIFFERENT GROUPS 240 TO 330 DAYS AFTER INJECTION OF THE SUSPENSIONS

Group	No.	Type		
		Epithelioid	Sarcomatous	Mixed
UICC standard reference crocidolite	2	2	—	—
Acid-treated crocidolite	3	—	—	3
UICC standard reference crocidolite + iron oxide	2	1	1	—
Iron oxide	—	—	—	—
UICC standard reference crocidolite + silica	2	—	2	—
Silica	—	—	—	—
Long fibre crocidolite	3	—	2	1
Short fibre crocidolite	3	—	2	1
Long fibre glass	—	—	—	—
Short fibre glass	—	—	—	—

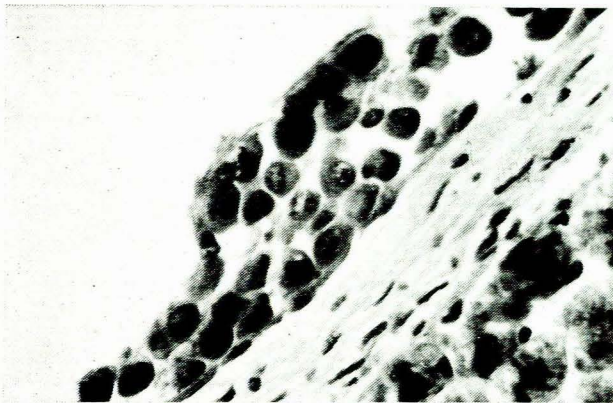

Fig. 2. Proliferation of malignant cells on the liver capsule, 330 days after injection of crocidolite (H. and E.  $\times$  400).

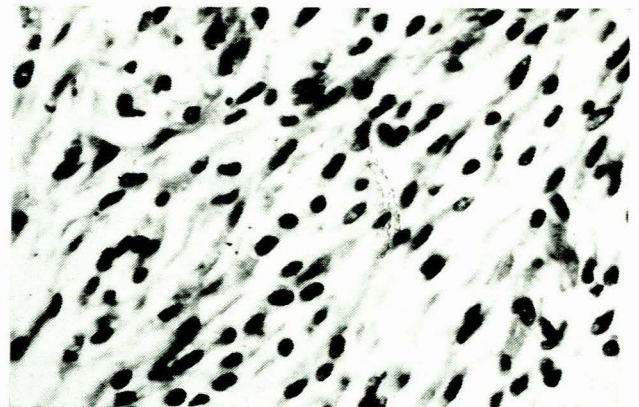


Fig. 4. Spindle-shaped cells in a sarcoma-like mesothelioma 240 days after injection of acid-treated crocidolite (H. and E.  $\times$  400).

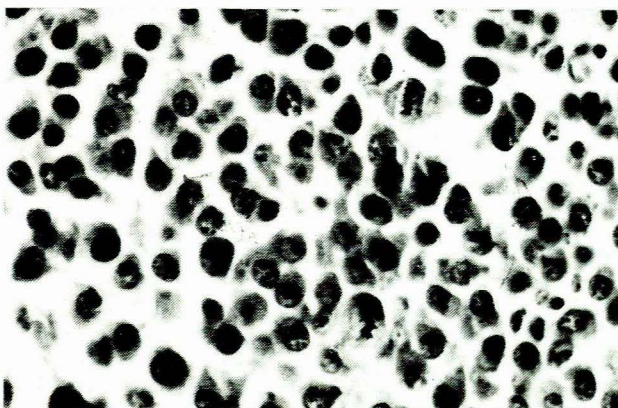


Fig. 3. Loosely arranged polyhedral cells with little intercellular substance in an epithelioid type mesothelioma, 330 days after injection of crocidolite (H. and E.  $\times$  400).

granulomas and the plaque-like growths. Areas quite free of asbestos fibres were often involved in malignant transformation (Fig. 2). The mono- and biphasic mesotheliomas consisted of loosely arranged polyhedral cells (epithelioid type, Fig. 3) or of spindle-shaped cells (sarcomatous type, Fig. 4).

The tubular, papillar or acinar cyto-architectural patterns found in the terminal stages of previous experiments<sup>2</sup> were absent at this stage. Histologically the crocidolite samples, e.g. standard reference, acid-treated, long and short fibres, provoked similar reactions.

Silica and asbestos, administered simultaneously, caused a marked initial macrophage mobilisation and a prominent fibrous reaction in the later stages.

### Glass

Both long and short glass fibres caused a similar tissue reaction consisting of small nodules scattered over the peritoneum at 45 days. Histologically these nodules revealed a peripheral zone of inflammatory cells, surrounding a central area of macrophages containing large numbers of

glass particles. Small fibrous growths replaced these nodules in the later stages. Initially a few areas of reactive mesothelium, consisting of well-differentiated cells, were observed, although no malignant transformation occurred in the terminal stages.

### Iron Oxide

The tissue response to iron oxide was a slight foreign body reaction, which disappeared completely 150 days after administration.

### Silica

Silica induced an initial inflammatory reaction followed by a subsequent infiltration by fibroblasts and the formation of fibrous tissue, which developed eventually into large, acellular, fibrous nodules. Although a reactive mesothelium was encountered during the early stages, transformation into mesotheliomas did not occur.

## DISCUSSION

All the suspensions except iron oxide caused an initial foreign body reaction followed by fibroblast infiltration, fibrosis and a reactive mesothelium. The fibrogenic reaction was more pronounced in the group injected with silica. The initial reactions evoked by all the suspensions appeared to be part of the inflammatory response.

Malignant mesotheliomas developed only in the crocidolite groups, and the carcinogenicity of long and short fibre asbestos was similar. From this observation, as well as the tissue response to long and short glass fibres, it may be concluded that mechanical irritation does not contribute to the induction of mesotheliomas. This finding is supported by the results of Harington and Roe.<sup>3</sup>

Although our findings indicate that iron oxide was inert, this does not exclude the possible carcinogenic effects of other iron complexes. Silica administration caused a fibroblast infiltration and excessive fibrosis, but induced no malignancies in contrast to the mesotheliomas found by Wagner<sup>4</sup> and Schepers.<sup>5</sup> Although silica had a significant effect on fibrogenesis, it did not alter the carcinogenic property of asbestos, when injected simultaneously.

Warburg<sup>6</sup> postulated that carcinogenic agents act by interference in cellular respiration. Smith *et al.*<sup>7</sup> supported this theory by suggesting that transformation of the mesothelial layer to malignant cells was caused by their entrapment in dense fibrous tissue. Applying these theories to asbestos, silica should be expected to be highly carcinogenic, a finding which is not substantiated by the present results. The malignant cells found after asbestos administration were either covering the surface of fibrous granulomas containing asbestos particles or appeared in areas deficient in asbestos. This suggests that malignant transformation involves only the cells of the mesothelial layer.

The carcinogenic property of crocidolite was not altered by treatment with strong acids to remove soluble metal complexes and organic compounds. Previous postulations by the authors<sup>2</sup> that some soluble agent might slowly diffuse from the asbestos fibres are not substantiated by the present results.

It is thus concluded that asbestos must have some other properties, not yet disclosed, which are involved in carcinogenesis.

## REFERENCES

1. Harington, J. S., Roe, F. J. C. and Walters, M. (1967): *S. Afr. Med. J.*, **41**, 800.
2. Engelbrecht, F. M. and Burger, B. F. (1973): *Ibid.*, **47**, 1746.
3. Harington, J. S. and Roe, F. J. C. (1965): *N.Y. Acad. Sci.*, **132**, 439.
4. Wagner, J. C. (1962): *Nature (Lond.)*, **196**, 180.
5. Schepers, G. W. H. (1965): *N. Y. Acad. Sci.*, **132**, 504.
6. Warburg, O. (1956): *Science*, **123**, 309.
7. Smith, W. E., Miller, L., Elsasser, R. E. and Hubert, D. D. (1965): *N.Y. Acad. Sci.*, **132**, 456.