

# Oesophago-antrostomy with and without pyloroplasty — radiological and manometric findings in the chacma baboon

L. C. J. VAN RENSBURG, A. D. KEET

## Summary

Oesophago-antrostomy with and without pyloroplasty, and with preservation of Latarjet's anterior nerve with an intact pylorus, was studied in chacma baboons. Radiological and manometric studies showed that pyloroplasty is unnecessary after oesophago-antrostomy with an incidental vagotomy and that pyloroplasty in fact interferes with the muscular rhythm of the pyloric sphincteric cylinder.

*S Afr Med J* 1983; **63**: 816-819.

The addition of a pyloroplasty to the operation of oesophago-antrostomy seems to be a logical concept because of the incidental vagotomy. Although this is still recommended by surgeons there is enough documented evidence to prove it an unnecessary step.<sup>1</sup> We studied the radiological and manometric findings in a group of chacma baboons over a period of 6 months.

## Materials and methods

The experimental animal was the adult baboon (*Papio ursinus ursinus*) and subjects were divided into three groups: group A — oesophago-antrostomy without pyloroplasty (4 animals) (Fig. 1); group B — oesophago-antrostomy with pyloroplasty (4 animals) (Fig. 2); and group C — oesophago-antrostomy without pyloroplasty and with preservation of Latarjet's anterior nerve (3 animals) (Fig. 3).

The baboons, of either sex and weighing  $\pm 17$  kg, underwent the operation after a period of conditioning. The operative procedure was performed under general anaesthesia. Ketamine hydrochloride 100 mg was injected intramuscularly to subdue the animal so that anaesthesia could be induced by an intravenous injection of pentobarbitone sodium 20 mg/kg body weight. Thereafter pentobarbitone 4 mg/kg was given intravenously every hour during the operation.

An upper midline incision was used to open the abdomen. The oesophagus was mobilized to obtain an adequate length for anastomosis. The upper part of the stomach and distal oesophagus was resected, leaving a distal gastric segment 7 cm long on the greater curvature side and 5 cm long on the lesser curvature side. The spleen was not removed. The upper part of the gastric

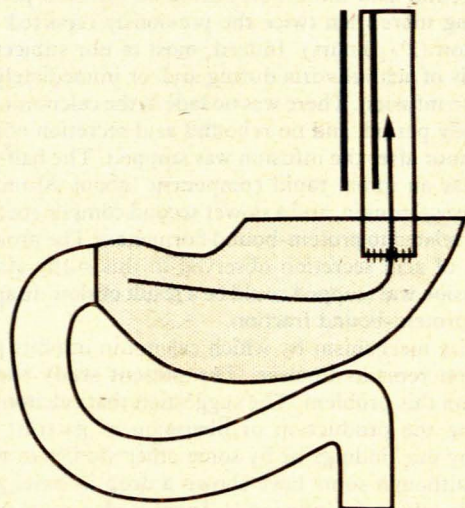


Fig. 1. Group A. Oesophago-antrostomy without pyloroplasty.

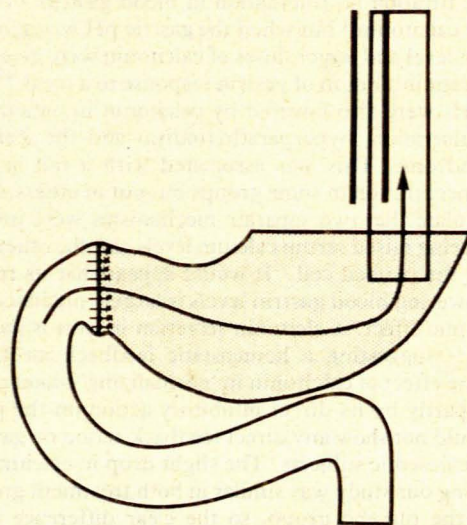


Fig. 2. Group B. Oesophago-antrostomy with pyloroplasty.

remnant was closed with a continuous 3/0 chromic catgut suture. The oesophagus was anastomosed to the anterior wall of the stomach just below the gastric closure in two layers. An interrupted posterior layer of 3/0 black silk was inserted in such a manner that the oesophageal muscle was anastomosed to the seromuscular part of the stomach before the gastrotomy was performed. On completion of this layer the stomach was opened to insert a layer of a continuous 3/0 chromic catgut suture between the oesophageal mucosa and the gastric mucosa. The anterior suture line was then completed with interrupted 3/0

Departments of Surgery and Radiology, University of Stellenbosch, Parowvallei, CP

L. C. J. VAN RENSBURG, M.MED. (SURG.), F.C.S. (S.A.), F.R.C.S.  
A. D. KEET, M.D., PH.D. (RAD.)



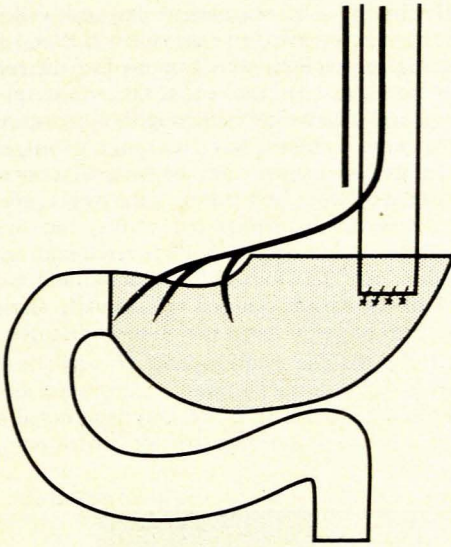


Fig. 3. Group C. Oesophago-antrostomy without pyloroplasty and with preservation of Latarjet's anterior nerve.

black sutures between the oesophageal musculature and the seromuscular part of the stomach. The pyloroplasty was of the Heineke-Mikulicz type employing a single interrupted layer of 3/0 chromic catgut sutures. Complete truncal vagotomy was established in all animals in groups A and B. In group C the proximal gastrectomy was performed as described, carefully preserving Latarjet's anterior nerve and severing the posterior vagus nerve. For the first 48 hours after the operation the animals received intravenous feeding and then small sips of water, and within 5 days they were eating their normal pellet diet.

Three months after the procedure cine fluoroscopy was performed. Each animal received a dose of ketamine 10 mg/kg, which was enough to produce sedation but not interfere with the swallowing reflex. A mixture of thick barium paste and the usual solid pellet diet, having the consistency of thick porridge, was administered with a spoon and swallowed without difficulty.

## Results

It is proposed to interpret the results according to the descriptions of the anatomy of the distal part of the stomach by Cunningham<sup>2</sup> (in man and the anthropoid ape), Forssell<sup>3</sup> and Torgersen<sup>4</sup> (in comparative anatomical studies) and others.<sup>5,6</sup> According to these authors the circular muscularis externa forms a tube-like thickening, 3 - 4 cm in length, in the distal stomach, called the pyloric sphincteric cylinder ('canalis egestorius'). The pyloric ring (sphincteric ring or 'right canalis loop') is not a separate structure, but merely a localized, annular thickening of the aboral part of the cylinder. While the circular fibres of the ring are sharply demarcated from those of the duodenum by a fibrous septum, no such division exists on the gastric side where the fibres of the ring merge imperceptibly into those of the cylinder. Anatomically and functionally the ring forms an inherent part of the cylinder.<sup>1-5</sup> The various parts of the cylinder do not function separately, but act as a unit. The movements of the cylinder in the living human stomach as seen radiographically have been fully documented.<sup>7</sup> Our previous cine radiographic experience showed that the movements in *P. ursinus ursinus* were identical to those in humans. (The abovementioned authors indicated that the concept 'antrum' could not be defined anatomically, and advocated the abolition of this term.)

**Group A** (Fig. 4). The usual finding was that the barium-filled oesophagus emptied rapidly into the remaining stomach,

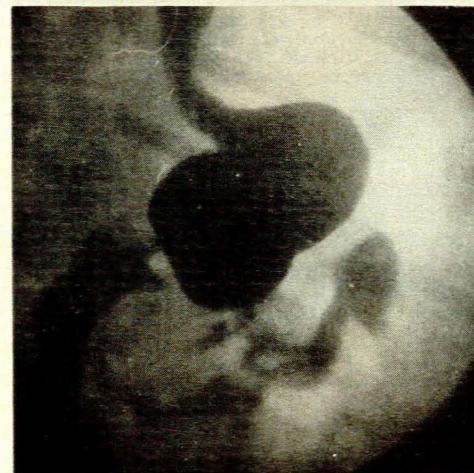
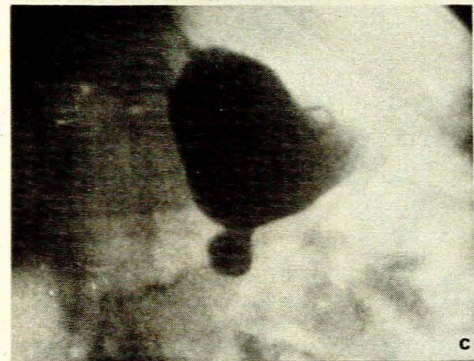
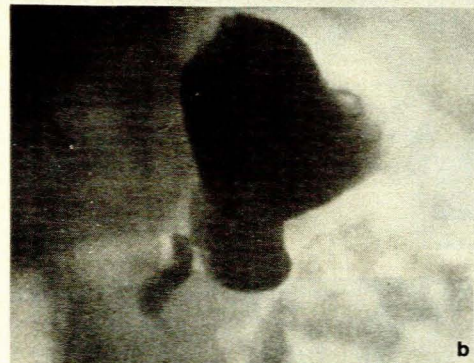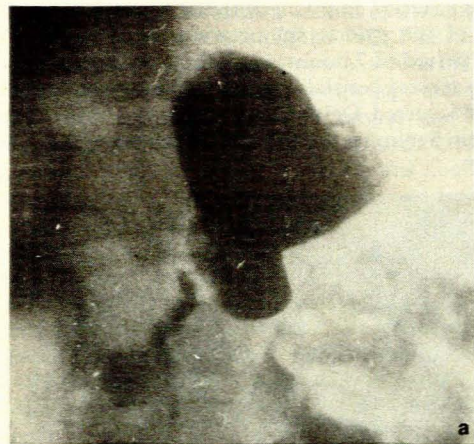


Fig. 4. Group A. Radiographs a, b and c show a sequence of active contractions of the pyloric sphincteric cylinder. Radiograph d shows some degree of oesophageal reflux and the radiographic appearance of an intact pyloric sphincteric ring.



the stomach started emptying within 2 minutes, and active contractions of the pyloric sphincteric cylinder were observed. Within a period of 7 minutes half the barium had left the stomach. No reverse peristalsis was observed and no duodenogastric reflux occurred. Oesophageal reflux was observed occasionally. Within 5 minutes the proximal small bowel was filled with barium.

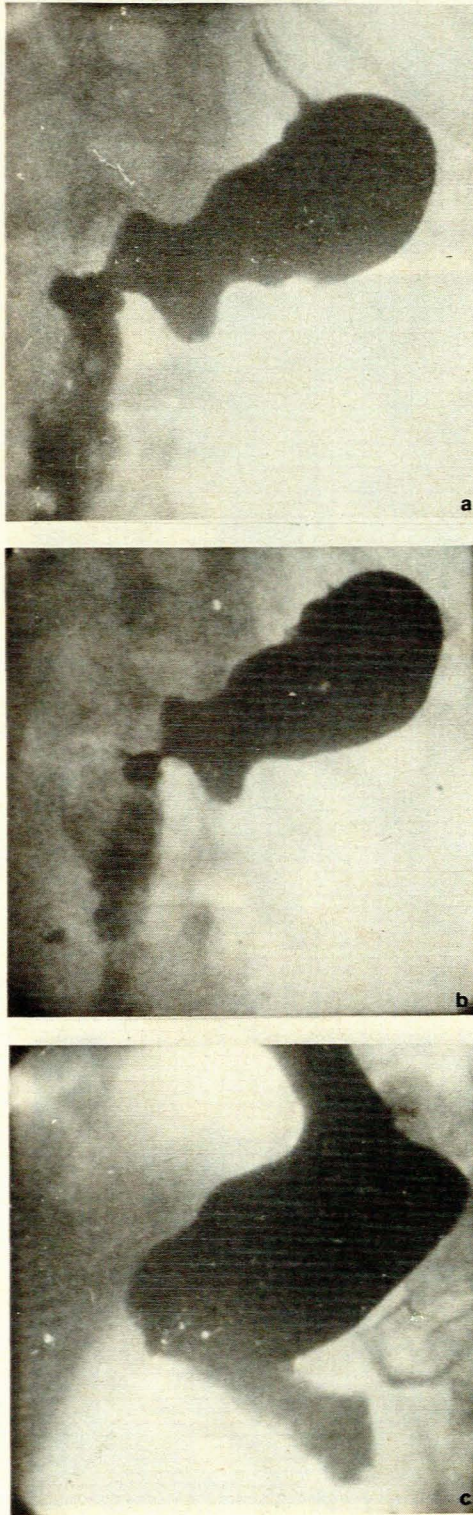


Fig. 5. Group B. Weak, irregular contractions and the typical radiographic picture of a pyloroplasty are seen in a and b. Radiograph c reveals poor contractions of the pyloric sphincteric cylinder with the impression that the stomach is emptying by gravity.

**Group B** (Fig. 5). The oesophagus emptied well into the stomach and barium began to leave the stomach after 3 minutes. Weak, irregular contractions were observed in the remaining stomach, but no normal contractions of the pyloric sphincteric cylinder were seen. The typical radiographic appearances of the pyloroplasty were evident, viz. temporary bulges (out-pouchings?) of the lesser and greater curvatures, lack of maximal contraction of the cylinder, and failure of the pyloric aperture to close. There was no duodenogastric reflux, but occasional gastro-oesophageal reflux occurred. The overall impression was that the barium left the stomach by gravity, and within 10 minutes 50% of the barium had left the stomach. Barium was noted in the small bowel within a period of 10 minutes.

**Group C** (Fig. 6). The pyloric sphincteric cylinder showed fairly normal-looking contraction waves, the barium leaving the stomach within 1 minute with a 50% emptying noted at 5 minutes. There was no duodenogastric or gastro-oesophageal reflux.

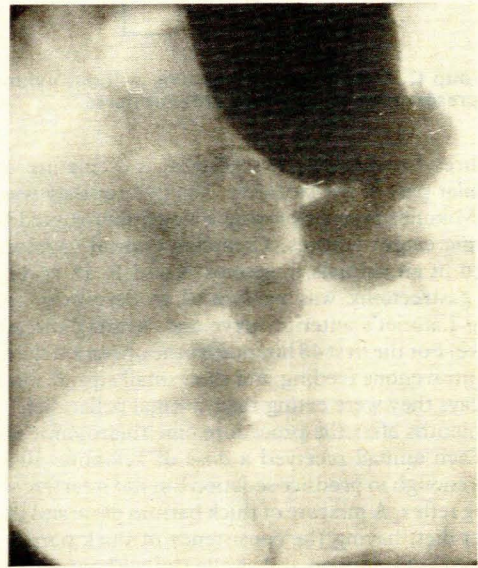


Fig. 6. Group C. The pyloric sphincteric cylinder shows fairly normal-looking contractions with good emptying of the remaining distal stomach segment.

### Manometric studies

A water-filled gastric balloon was inserted during the original operative procedure to test its size and accuracy for later manometric studies. Three months after the original procedure manometric studies were performed under the influence of ketamine 10 mg/kg. The baboon tolerated the insertion of the gastric tube and balloon and was fed the usual barium and pellet mixture. A transducer connected to a Hewlett Model W788A monitoring machine was used for recording contractions in millimetres of mercury. Fig. 7 demonstrates fairly normal-looking

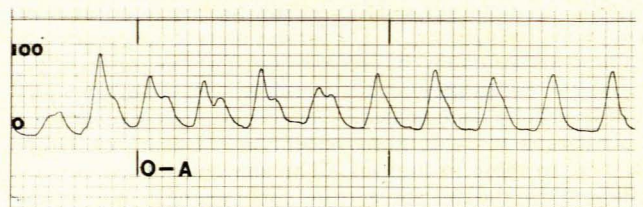


Fig. 7. Group A. Regular, fairly normal-looking contractions of the pyloric sphincteric cylinder (measured in mmHg).



contractions of the pyloric sphincteric cylinder in the group A model. In contrast the manometric findings in group B (Fig. 8) show irregular disorganized contractions varying in intensity. Fig. 9 demonstrates the manometric findings in group C. This model was developed to compare the radiological and manometric findings with those in the two previous models. It should be noted that the contraction waves were smooth, of high amplitude and fairly regular.

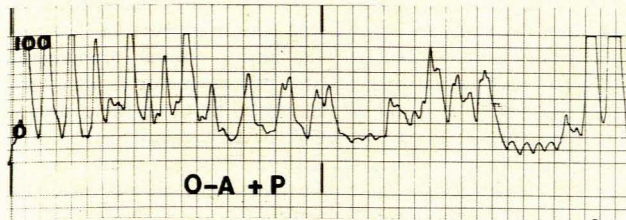


Fig. 8. Group B. The contractions are irregular and disorganised, varying in intensity (measured in mmHg).

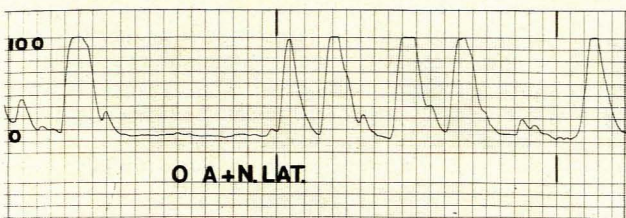


Fig. 9. Group C. The contractions are smooth and fairly regular with a high amplitude (measured in mmHg).

## Discussion

There are advocates for and against pyloroplasty or pyloromyotomy in patients who undergo oesophago-antrotomy. From these experimental findings it became obvious that a pyloroplasty was not necessary after oesophago-antrotomy. In fact a pyloroplasty seems to cause a disturbance of the muscular rhythm of the pyloric sphincteric cylinder as evidenced by our radiological and manometric findings. The emptying of the stomach depends upon the pressure grading between the stomach and duodenum, the amplitude of contraction of 'antrum' and the physiological properties of the gastric content.<sup>8</sup> According to Laplace's law the pressure within a cylinder is directly related to the circumferential tension in its wall but inversely proportional to its radius. If one considers the unresected vagotomized stomach without drainage, delayed emptying certainly does occur and many of Dragstedt and Camp's<sup>9</sup> patients had to have some sort of a drainage procedure. If Laplace's law is applied this particular type of stomach is seen to have a poor circumferential tension with a large radius. If the proximal half of the stomach is removed the circumferential radius is reduced and the muscular distal stomach (pyloric sphincteric cylinder) probably generates a greater degree of tension with better emptying. A pyloroplasty is an unnatural procedure, with interruption

of the anteriorly situated circular muscularis externa fibres, and must disturb the muscular tension of the wall. This may be the reason why such a stomach does not empty as well as the stomach with an intact pylorus. In an experiment on dogs in which they studied the effect of pyloroplasty on the 'antral' and duodenal activity, Ludwick *et al.*<sup>10</sup> found that the co-ordinated 'antral' contraction and duodenal inhibition reflex was abolished by pyloroplasty, with the 'antrum' and duodenum contracting simultaneously, in contrast to the animal with intact pylorus in which there was a reflex inhibition of the duodenum during periods of large antral contractions. The addition of vagotomy did not affect this. Our experimental model seems to demonstrate similar findings. In the baboon with an intact pylorus after oesophago-antrotomy the pyloric sphincteric cylinder contracted well in spite of the incidental vagotomy. The explanation for this is not easy unless one accepts the work by Jefferson *et al.*<sup>11</sup> on dogs in which they suggest that extravagal motor fibres to the stomach issue from anterior and posterior spinal roots and from sympathetic trunks and descend to the stomach in the splanchnic nerves and by other roots presently unknown.

For the last 5 years we have not performed a pyloroplasty or pyloromyotomy on patients undergoing oesophago-antrotomy for carcinoma of the stomach. In none of these patients did we find any problems with gastric emptying or oesophageal reflux.

## Conclusion

We feel that these experiments adequately prove that pyloroplasty is not necessary after oesophago-antrotomy; in fact, pyloroplasty may be undesirable because of the unusual irregular contractions of the pyloric sphincteric cylinder.

We wish to thank Messrs G. Louw, J. J. Geldenhuis and L. Nieuwenhuizen of our Surgical Research Laboratory for their assistance. We also thank the staff of our Medical Illustration and Photographic Department for their contribution. We are indebted to the Harry Crossley Research Fund for financial assistance.

## REFERENCES

1. Angorn IB. Oesophagostomy without a drainage procedure in oesophageal carcinoma. *Br J Surg* 1975; **62**: 601-604.
2. Cunningham DJ. The varying form of the stomach in man and the anthropoid ape. *Trans R Soc Edinb* 1906; **45**: 9-47.
3. Forsell G. Über die Beziehung des menschlichen Magens zu seinem anatomischen Bau. *Fortschr Röntgenstr* 1913; suppl 30.
4. Torgersen J. The muscular build and movements of the stomach and duodenal bulb. *Acta Radiol (Suppl) (Stockh)* 1942; No. 45.
5. Cole LG. The living stomach and its motor phenomenon. *Acta Radiol (Diagn) (Stockh)* 1928; **9**: 533-545.
6. McNaught GHD. Simple pyloric hypertrophy in the adult. *J R Coll Surg Edinb* 1957; **3**: 35.
7. Keet AD. The prepyloric contractions in the normal stomach. *Acta Radiol (Diagn) (Stockh)* 1957; **48**: 413-424.
8. Hunt JN. Gastric emptying and secretion in man. *Physiol Rev* 1959; **39**: 491-533.
9. Dragstedt LR, Camp EH. Follow-up of gastric vagotomy alone in the treatment of peptic ulcer. *Gastroenterology* 1948; **11**: 460-465.
10. Ludwick JR, Wiley JN, Bass P. Pyloroplasty and vagotomy. Early effects on antral and duodenal contractile activity. *Arch Surg* 1969; **99**: 553-559.
11. Jefferson NC, Kuroyanagi Y, Arai T, Giesel T, Necheles H. Extravagal gastric motor innervation. *Surgery* 1965; **58**: 420-423.