

Gastric haemorrhage in a patient with neurofibromatosis

A case report

D. F. DU TOIT

Summary

A 54-year-old woman with upper gastro-intestinal haemorrhage, neurofibromatosis and an underlying schwannoma of the stomach is presented. Gastroscopy and barium meal examination revealed the presence of a submucosal gastric tumour with overlying ulceration. A Billroth II gastrectomy was performed with complete excision of the tumour; histologically this was revealed as a schwannoma of undetermined biological activity.

S Afr Med J 1987; 71: 730-731.

In clinical practice about 85% of upper gastro-intestinal bleeding is caused by peptic ulcer disease, gastritis or oesophageal varices. Gross haematemesis is rare in patients with gastric cancer, who usually present with vague abdominal and dyspeptic complaints, anorexia, weight loss, and anaemia with or without signs of gastric outlet obstruction. In contrast to patients with gastric cancer, those with benign gastric tumours often present with haemorrhage resulting from ulceration of the overlying mucosa.

A patient with underlying neurofibromatosis and haemorrhage from a gastric schwannoma is presented.

Case report

A 54-year-old coloured woman was referred from a peripheral hospital with a recent history of haematemesis and mealaena. She had associated vague dyspeptic complaints and needed 4 U of blood to correct the anaemia resulting from the acute gastric haemorrhage. Barium meal examination (Fig. 1) revealed the presence of a submucosal circumscribed tumour adjacent to the gastro-oesophageal junction. Gastroscopy confirmed the presence of a localised tumour with overlying mucosal ulceration but endoscopic biopsies revealed nonspecific gastritis. A gastric leiomyoma was considered in the differential diagnosis.

At laparotomy there was no signs of localised spread or metastases. A 90% subtotal gastrectomy with a Billroth II anastomosis was performed because of the position of the tumour and its unknown type.

The resected specimen was a circumscribed tumour with overlying mucosal ulceration and signs of recent haemorrhage. Histological examination proved it to be a schwannoma of undetermined biological activity.

The postoperative course was uncomplicated but on closer physical examination of the patient the presence of *café au lait* pigmentation strongly suggested underlying neurofibromatosis.

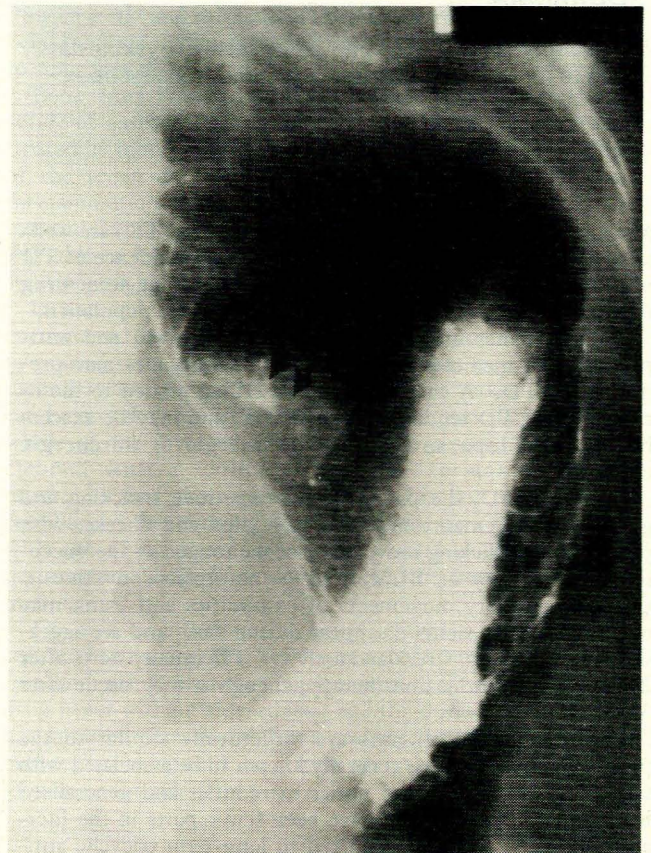


Fig. 1. Histologically proven schwannoma (arrows) situated on the posterolateral aspect of the lesser curvature of the stomach adjacent to the oesophagogastric junction. The smooth surface is highly suggestive of a mural tumour.

Discussion

In the experience of surgeons and pathologists about 90-95% of malignant tumours of the stomach are adenocarcinomas. Less common malignant gastric tumours encountered include lymphomas, leiomyosarcomas and argentaffinomas.¹ Benign gastric neoplasms are rare and constitute approximately 2% of all gastric neoplasms. By far the commonest benign gastric tumours are adenomatous polyps and leiomyomas, the reported incidence of neurogenic tumours being 2%.^{1,2}

Benign gastric tumours may present with pain and bleeding from mucosal ulceration as in our patient, and occasionally with gastric outlet obstruction as a result of prolapse of the tumour through the pylorus. Most are discovered incidentally by barium meal examination or gastroscopy performed on patients with ill-defined abdominal pain.^{2,3} Undoubtedly, the liberal use of gastroscopy in recent years has led to the detection of many asymptomatic benign gastric tumours.

Department of Surgery, University of Stellenbosch and Tygerberg Hospital, Parowvallei, CP

D. F. DU TOIT, PH.D., F.R.C.S

Schwannomas (neurilemmomas) usually occur in the 5th decade of life and may be associated with von Recklinghausen's neurofibromatosis. Although malignant transformation of schwannomas has been reported, some authors indicate that this diagnosis should be made with caution.¹ However, areas of markedly increased hypercellularity with many mitoses on histological evaluation suggest malignant transformation.¹ In the event of malignant transformation metastases are uncommon and the tumours tend to infiltrate locally and recur; 50% of patients with malignant schwannomas have von Recklinghausen's disease.¹

In all cases, benign mesenchymal tumours of the stomach should be excised to rule out the presence of malignant disease. An annual barium meal examination or gastroscopy is

advisable to detect new tumours and recurrence after resection.²

The author thanks the Medical Superintendent of Tygerberg Hospital for permission to publish.

REFERENCES

1. Robbins SL, Cotran RS. *Pathologic Basis of Disease*. 2nd ed. Philadelphia: WB Saunders, 1979: 918-1003.
2. Edis AJ. Benign tumors of the stomach. In: Schwartz SI, Ellis H, eds. *Maingot's Abdominal Operations*. 8th ed. Norwalk, Conn.: Appleton-Century-Crofts, 1985: 943-956.
3. Berk RN. The stomach. In: Teplick JG, Haskin ME, eds. *Surgical Radiology*. 1st ed. Philadelphia: WB Saunders, 1981: 448-501.

Triple non-contiguous injuries of the spine

A report of 2 cases

J. A. LOUW, C. R. OOSTHUIZEN, M. SCHWAB

Summary

Two cases of triple non-contiguous injuries of the spine are presented. Both patients had obvious single level injuries which obscured the associated double lesions. The importance of meticulous clinical and radiological examination of the entire spine is emphasised.

S Afr Med J 1987; 71: 731-732.

Multiple non-contiguous injuries should always be suspected in patients with trauma to the vertebral column. The incidence of double injuries to the spine has ranged from 4,2% to 7,9% in previous reports,^{1,2} but triple injuries are rare. Only 8 cases have been reported in the English-language literature.^{1,3,4}

The term 'non-contiguous multiple level injuries' of the spine refers to injuries at more than one site where these sites are separated by an area of normal spine; this must consist of at least two intact vertebral bodies and posterior elements with intact intervening disc and paravertebral joints.

Department of Orthopaedic Surgery, University of Pretoria and Spinal Injuries Unit, Kalafong Hospital, Pretoria

J. A. LOUW, M.B. CH.B., M.MED. (ORTH.)

C. R. OOSTHUIZEN, M.B. CH.B.

M. SCHWAB, M.B. CH.B.

Two cases of triple non-contiguous injuries of the spine are described.

Case reports

Case 1

A 45-year-old black man complained of thoracic back pain and complete loss of function of his lower extremities after a motor vehicle accident 10 hours before admission to hospital.

Examination revealed complete paraplegia below the 8th thoracic segment. Severe pressure tenderness could be elicited posteriorly at T7 and T8, with anteroposterior and lateral translation in the alignment of the spinous processes at this level.

Radiographs of the thoracic spine demonstrated an obvious fracture dislocation at T7/T8 level. Routine radiographs of the entire vertebral column revealed a 5 mm anterior subluxation between C7 and T1 as well as a burst fracture of L1 (Fig. 1).

The patient was admitted to the Spinal Injuries Unit of Kalafong Hospital where routine management was carried out.

Case 2

A 19-year-old black woman complained of neck pain after a motor vehicle accident the previous day.

Examination revealed that the patient was neurologically intact but had pressure tenderness in the lower cervical region anteriorly. Spasm of the neck muscles prevented accurate localisation of the lesion.

Radiographs of the entire spine demonstrated bilateral laminae fractures of C2, burst fractures of both C6 and C7, and a compression fracture of T3.

The patient was managed conservatively and the outcome was gratifying.