

# **The management of clavicle shaft fractures**

**Evaluating the ability of a novel locked intramedullary device to  
achieve union and restore function of the shoulder**

BY

**PAUL REGINALD KING**

**Thesis presented for the degree of**

**Doctor of philosophy**

**in**

**ORTHOPAEDIC SURGERY**

**at the**

Per bona studiorum cultus recti

**STELLENBOSCH UNIVERSITY  
DIVISION OF ORTHOPAEDIC SURGERY  
DEPARTMENT OF SURGICAL SCIENCES  
FACULTY OF MEDICINE AND HEALTH SCIENCES**

**Supervisor**

Professor Robert P. Lamberts MSc, PhD, FECSS

**Examiners**

Professor Michael McKee, University of Arizona, USA

Dr Jeroen Swart, University of Cape Town, South Africa

Dr Anne Vochteloo, Centre for Orthopaedic Surgery, Netherlands



## DECLARATION

By submitting this dissertation electronically, I, Paul Reginald King (13091603), declare that the entirety of the work contained therein is my own, original work, that I am the sole author thereof (save to the extent explicitly otherwise stated), that reproduction and publication thereof by Stellenbosch University will not infringe any third party rights and that I have not previously in its entirety or in part submitted it for obtaining any qualification.

The research presented in this thesis is based on 3 published articles (Chapter 3,4 and 5), one submitted articles which is under review (Chapter 1) and one article which is submission ready to a peer reviewed international journal (Chapter 2)

Small stylistic language changes and using the same references style, were made to the published articles in this thesis.

The role, which I and my co-authors fulfilled within each of the publications (chapters) is outlined below.

### Chapter 1

P.R. King, R.P. Lamberts. Management of clavicle shaft fractures with intramedullary devices: a review of current concepts. *Expert Review of Medical Devices* 2019; *Under review*.

I reviewed the relevant literature and drafted the manuscript submitted for publication. Prof Lamberts assisted in his role as main supervisor and assisted with drafting the submitted manuscript.

*Drafting manuscript contributions: P.R. King 75%, R.P. Lamberts 25%*

### Chapter 2

P.R. King, M.M Eken, R.P. Lamberts. Fractures of the clavicle shaft – epidemiology study of patients treated in a tertiary hospital in South Africa. *Injury* 2019; *Submission ready*

## Declaration

---

I drafted the research proposal and successfully applied for ethical clearance. The data was collected and captured with assistance from Dr Eken. The data was analysed with the assistance of Prof Lamberts. I drafted the manuscript with the assistance of my supervisor, Prof Lamberts.

*Drafting manuscript contributions: P.R. King 70%, M.M. Eken 10% R.P. Lamberts 20%*

**Chapter 3**

P.R. King, A. Ikram, R.P. Lamberts. The treatment of clavical shaft fractures with an innovative locked intramedullary device. *Journal of Shoulder and Elbow* 2015; 24(1): e1-6

I drafted the research proposal and successfully applied for ethical clearance. The data was collected and captured by myself. The data was analysed with the help of R.P. Lamberts. I drafted the published manuscript. A. Ikram provided clinical guidance regarding surgical technique and structuring the research. Apart from the normal guidance from my supervisor, R.P., Lamberts, I did not receive any other assistance.

*Drafting manuscript contributions: P.R. King 70%, A. Ikram 10%, R.P. Lamberts 20%*

**Chapter 4**

P.R. King, C.J. Basamania, R.P. Lamberts. Implantation of an innovative intramedullary locked fixation device for the treatment of clavicle shaft fractures. *Journal of Bone and Joint Surgery Am – Essential Surgical Techniques* 2016; 6(1)-e8: 1-11

I drafted the published manuscript with assistance from Dr Basamania and Prof Lamberts. Dr Basamania provided clinical guidance regarding surgical technique, while Prof Lamberts assisted in making the supporting video material. Apart from the normal guidance from my supervisor, I did not receive any other assistance.

*Percentages of contribution: P.R. King 70%, C.J. Basamania 5% R.P. Lamberts 25%*

Declaration

---

## Chapter 5

P.R. King, A. Ikram, M.M. Eken R.P. Lamberts. The effectiveness of a flexible locked intramedullary nail and an anatomical contoured locked plate to treat clavical shaft fractures. *Journal of Bone and Joint Surgery Am.* 2019;101(7):628-634

I drafted the research proposal and successfully applied for ethical clearance. The data was collected and captured by myself. The data was analysed with the help of Prof Lamberts and Dr Eken. Dr Ikram provided clinical guidance regarding surgical technique. I drafted the thee manuscript with support of Dr Eken and Prof Lamberts. Apart from the normal supervisory guidance, I did not receive any other assistance.

*Percentages of contributions: P.R. King 70%, A. Ikram 7.5%, M.M. Eken 7.5%, R.P. Lamberts 15%*

All co-authors have granted their permission to Paul Reginald King to use the above-mentioned work for his degree of Doctor of Philosophy in Orthopaedic Surgery at Stellenbosch University, Division of Orthopaedic Surgery, Department of Surgical Sciences, Faculty of Medicine and Health Sciences.

I hereby grant Stellenbosch University free license to reproduce the above thesis in whole or in part, for the purpose of research.

This thesis is presented for examination in fulfillment of the requirements for the degree of Doctor of Philosophy in Orthopaedic Surgery

Dr Paul Reginald King

December 2019

Copyright © 2019 Stellenbosch University  
All rights reserved

## Declaration

---

## **ACKNOWLEDGEMENTS**

This thesis is dedicated to Dr Cornelius (Neels) van der Westhuizen, a talented and dedicated orthopaedic surgeon. Had it not been for his inspirational influence, I would likely not have become an orthopaedic surgeon. You have been a mentor to not only me, but to numerous other junior surgeons. Your work ethic and high standards have helped to shape our careers. You have also been a father figure and a friend to me. I am very grateful that our paths could cross.

Thank you to my wife, Jeanmari, and children, Leah and Jeannie, for the sacrifices you have made in allowing me time to work on my research. Jeanmari, thank you for providing our children and myself with a loving home environment. You have supported me through many challenging times. You have always been the solid base I can rely on. I love you!

Thank you to my mother, Dr Lizette King, for installing in me a love for academia. Your example has been an inspiration to me and, I am sure, to your numerous PhD students as well. Thank you for raising me well and for all the sacrifices you have made for my siblings and me. We are lucky to have a strong woman as a mother.

I am eternally grateful to Prof. Robert Lamberts. Your help and guidance in preparing this thesis and the publications, which make up this dissertation, has been monumental. Without your help, this project would not have materialized. You are the reason for the dramatic increase in academic output from our department. An academic career is a difficult and selfless road – one that is not always appreciated by those who do not understand the sacrifices it asks. Thank you for the time you have dedicated to me and for the friend that you have become.

Thank you to my Head of Department, Prof Jacques du Toit, and the other members of staff at the Division of Orthopaedic Surgery, Stellenbosch University. You provided excellent clinically training as well as an enabling academic environment. You also became my second family during my training.

To all my co-authors: Dr Ajmal Ikram, Dr Carl Basamania, Dr Maaïke Eken, thank you for all your input and help. Drs. Ikram and Basamania provided invaluable clinical guidance. Their vast experience in managing upper limb trauma allowed me to

## Acknowledgments

---

develop my own techniques and ideas. Thank you for sharing your vast experience and teaching me with patience.

My sincere gratitude to Dr Justin Harvey for his assistance with the statistical analysis of data for a number of years. Thank you for patiently enduring my lacking understanding of statistics!

Dr Jack Eksteen has been a mentor to me in private practice. Thank you for teaching me a vast number of skills. You are a visionary in your field, and I am grateful for the opportunity you afforded me. Your approach to private practice and the transfer of skills from one generation to the next is unique and it should be the norm.



## Table of contents

**TABLE OF CONTENTS**

<b>DECLARATION</b>	<b>III</b>
<b>ACKNOWLEDGEMENTS</b>	<b>VII</b>
<b>TABLE OF CONTENTS</b>	<b>IX</b>
<b>PUBLICATIONS AND PRESENTATIONS</b>	<b>XIII</b>
Articles in review .....	xiii
Published conference proceedings .....	xiii
Conference presentations .....	xiv
<b>LIST OF ABBREVIATIONS</b>	<b>XIX</b>
<b>OUTLINE OF THE THESIS</b>	<b>XXI</b>
Introduction .....	xxii
Research questions and aims.....	xxiii
Main research question .....	xxiii
Sub-research questions.....	xxiii
Chapter layout.....	xxvi
<b>CHAPTER 1</b>	
<b>Management of clavicle shaft fractures with intramedullary devices: a review of current concepts</b>	<b>1</b>
Abstract.....	3
Epidemiology of clavicle fractures.....	5
Anatomy of the clavicle .....	6
Anatomical variations of the clavicle .....	6
Clavicle anatomy and intramedullary fixation of clavicle shaft fractures .....	7
Classification of clavicle fractures .....	8
Treatment of clavicle shaft fractures .....	9
Indications for operative treatment.....	11
Treatment options .....	11
External fixation .....	11
Plate fixation.....	12
Intramedullary fixation .....	12

## Table of contents

Intramedullary versus extramedullary fixation of clavicle fractures .....	17
Conclusion .....	18
 <b>CHAPTER 2</b>	
<b>Fractures of the clavicle shaft epidemiological study of patients treated at a tertiary hospital in South Africa</b>	<b>25</b>
Abstract.....	25
Introduction .....	29
Methods .....	29
Patients.....	29
Study Variables .....	29
Statistical methods .....	31
Results.....	31
Demographics .....	31
Mechanisms of injury.....	32
Type of fractures, skin and neurovascular condition.....	34
Additional injuries .....	35
Treatment .....	37
Discussion .....	39
Conclusion.....	42
References .....	43
 <b>CHAPTER 3</b>	
<b>The treatment of clavicle shaft fractures with an innovative locked intramedullary device</b>	<b>45</b>
Abstract.....	47
Introduction .....	49
Methods .....	51
Recruitment .....	51
Study Design .....	51
Device description .....	52

## Table of contents

Surgical technique .....	53
Statistical analysis .....	56
Results .....	57
Discussion .....	59
Conclusion.....	60
References .....	63

**CHAPTER 4****A novel intramedullary locked fixation device for treatment of clavicle shaft fractures 65**

Introduction .....	67
Surgical technique .....	68
Indications and contraindications.....	68
Step 1: Positioning.....	69
Step 2: Skin Incision .....	70
Step 3: Preparing the Medial Fragment.....	71
Step 4: Preparing the Lateral Fragment .....	72
Step 5: Placement of the Intramedullary Nail.....	78
Step 6: Activation of the Locking Device .....	78
Step 7: Management of Comminuted Fracture Fragments.....	79
Step 8: Postoperative Management .....	80
Results.....	81
Pitfalls & Challenges .....	83
Clinical Comments .....	83
References .....	85

**CHAPTER 5****The effectiveness of a flexible locked intramedullary nail and an anatomical contoured lock plate to treat clavicle shaft fractures 87**

Abstract.....	89
Introduction .....	91
Methods .....	93

## Table of contents

Study design.....	93
Ethical Considerations.....	94
Operative Treatment.....	95
Anatomically Contoured Locked Plate.....	95
Flexible Locked Intramedullary Nail.....	95
Rehabilitation and Data Capturing.....	96
Shoulder Function Assessments .....	96
Sample Size .....	96
Data Analysis.....	96
Trial Registry .....	97
Results.....	99
Complications.....	102
Discussion .....	103
References .....	107
<b>CHAPTER 6</b>	
<b>Summary and conclusions</b>	<b>109</b>
Chapter summaries.....	111
Chapter 1.....	111
Chapter 2.....	112
Chapter 3.....	113
Chapter 4.....	115
Chapter 5.....	116
Thesis research question and conclusion .....	119
Recommendations and future research.....	120
Practical implications .....	122

## Publications and presentations

### PUBLICATIONS AND PRESENTATIONS

- 2019 **King PR**, Eken MM, Ikram A, Lamberts RP. The effectiveness of a flexible locked intramedullary nail and an anatomically contoured locked plate to treat clavicle shaft fractures – a one year randomized control trial. *Journal of Bone and Joint Surgery – American Volume* 2019;101(7):628-634.
- 2016 **King, PR**, Basamania, CJ, Lamberts RP. A novel intramedullary device for treatment of clavicle shaft fractures. *Journal of Bone and Joint Surgery Essential Surgical Techniques* 2016;6(1):e8(1-11).
- 2015 **King PR**, Ikram A, Lamberts RP. The treatment of clavicle shaft fractures with an innovative locked intramedullary device. *Journal of Shoulder and Elbow Surgery* 2015;42(1):e1-6.
- 2014 **King PR**, Scheepers S, Ikram A. Anatomy of the clavicle and its medullary canal – a computer tomography study. *European Journal of Orthopaedic Surgery and Traumatology*. 2014;24(1):37-42
- 2011 **King PR**, Ikram A. Intramedullary locked fixation of clavicle shaft fractures – review of early results. *South African Orthopaedic Journal* 2011;4: 67-74.

### ARTICLES IN REVIEW

- 2019 **King PR**, Lamberts RP. Management of clavicle shaft fractures with intramedullary devices: a review of current concepts. *Expert Review of Medical Devices – In review*

### PUBLISHED CONFERENCE PROCEEDINGS

- 2014 **King PR**, Ikram A, Lamberts RP. Intramedullary fixation versus anatomically contoured plating of clavicle shaft fractures: a one-year follow-up study. *Bone Joint Journal – American Volume* 2014;96-B(S19): 54.
- 2013 **King PR**, Ikram A. Intramedullary Locked Fixation of Clavicle Shaft Fractures – Review of Early Results. *Bone and Joint Journal – American Volume* 2013;95-B(SUPP 29):71.
- King PR**, Ikram A. Intramedullary locked fixation of clavicle shaft fractures – continued review of results. *Bone and Joint Journal – American Volume* 2013;95-B(SUPP 14):5.

## Publications and presentations

**King PR**, Scheepers S, Ikram A. Anatomy of the clavicle and its medullary canal. *Bone and Joint Journal – American Volume* 2013;95-B(SUPP 14):4.

**King PR**, Ikram A. Fractures of the middle third of the clavicle – epidemiological study of patients treated at a tertiary hospital and a classification system. *Bone and Joint Journal – American Volume* 2013;95-B(SUPP 14):6.

**King PR**, Ikram A. Lamberts RP. Locked Intramedullary Fixation vs. Anatomically Contoured Locked Plating of Clavicle Shaft Fractures – A Prospective Randomized Controlled Trial. *Orthopedic Journal of Sports Medicine* 2013;1(SUPP 4):2325967113S00037.

## CONFERENCE PRESENTATIONS

2016 **13<sup>th</sup> Meeting of the combined Orthopaedic Associations (COMOC), 11-15 April 2016, Cape Town, South Africa,**

*Oral presentation: PR King 'Effectiveness of a novel intramedullary fixation device compared to plating for the treatment of displaced clavicle shaft fractures'*

2015 **American Academy of Orthopaedic Surgeons (AAOS) Annual Meeting - 24-28 March 2015, Las Vegas, USA**

*Oral presentation: PR King 'Intramedullary fixation versus anatomically contoured locked plating of clavicle shaft fractures: a 1 year follow-up study'*

2014 **Gerhard Kuntsher Society Annual Meeting – 11-13 September 2014, Krems, Austria**

*Oral presentation: PR King 'Intramedullary fixation versus anatomically contoured locked plating of clavicle shaft fractures: a one year follow-up study'*

**South African Orthopaedic Association Annual Congress – September 2014, Cape Town, South Africa**

*Oral presentation: PR King 'Intramedullary fixation versus anatomically contoured locked plating of clavicle shaft fractures: a one-year follow-up study'*

**Stellenbosch University Annual Academic Year Day – August 2014, Cape Town, South Africa**

*Oral presentation: PR King 'Locked intramedullary fixation vs. anatomically contoured locked plating of clavicle shaft fractures – a one-year follow-up study'*

## Publications and presentations

2013 **South African Society for Surgery of the Hand Annual Congress – 30 August to 1 September 2013, Sun City, South Africa**

Oral presentation: **PR King** 'Locked intramedullary fixation vs. anatomically contoured locked plating of clavicle shaft fractures – a randomized controlled trial'

**South African Orthopaedic Association Annual Congress – 30 August to 1 September 2013, Sun City, South Africa**

Oral presentation: **PR King** 'Locked intramedullary fixation vs. anatomically contoured locked plating of clavicle shaft fractures – a randomised controlled trial'

**Stellenbosch University Faculty of Health Academic Year Day – August 2013, Sun City, South Africa**

Oral presentation: **PR King** 'Locked intramedullary fixation vs. anatomically contoured locked plating of clavicle shaft fractures – a randomized controlled trial'

**Edinburgh International Trauma Symposium – 21-23 August 2013, Edinburgh, Scotland**

Oral presentation **PR King:** 'Locked intramedullary fixation vs. anatomically contoured locked plating of clavicle shaft fractures – a randomised controlled trial'

**Prize for best oral presentation of a scientific paper**

**American Orthopaedic Society for Sports Medicine Annual Meeting – July 2013, Chicago, USA**

Oral presentation: **PR King** 'Locked intramedullary fixation vs. anatomically contoured locked plating of clavicle shaft fractures – a randomized controlled trial'

2012 **South African Society for Surgery of the Hand Annual Congress – 31-August – 2 September 2012, Durban, South Africa**

Oral presentation: **PR King** 'Anatomy of the clavicle and its medullary canal – a computer tomography study'

**South African Society for Surgery of the Hand Annual Congress – 31-August – 2 September 2012, Durban, South Africa**

Oral presentation: **PR King** 'Fractures of the middle third of the clavicle – epidemiological study of patients treated at Tygerberg Academic Hospital and a classification system'

## Publications and presentations

### **South African Society for Surgery of the Hand Annual Congress – 31-August to 2 September 2012, Durban, South Africa**

Oral presentation: **PR King** 'Intramedullary locked fixation of clavicle shaft fractures – continued review'

### **South African Othopaedic Association Annual Congress – 31-August to 2 September 2012, Durban, South Africa**

Oral presentation: **PR King** 'Anatomy of the clavicle and its medullary canal – a computer tomography study'

**GT du Toit Registrar Prize for best original research and presentation**

### **South African Othopaedic Association Annual Congress – 31-August to 2 September 2012, Durban, South Africa**

Oral presentation: **PR King** 'Fractures of the middle third of the clavicle – epidemiological study of patients treated at Tygerberg Academic Hospital and a classification system'

### **South African Othopaedic Association Annual Congress – 31-August to 2 September 2012, Durban, South Africa**

Oral presentation: **PR King** 'Intramedullary locked fixation of clavicle shaft fractures – continued review'

### **Stellenbosch University Faculty of Health Academic Year Day – August 2012, Tygerberg, South Africa**

Oral presentation: **PR King** 'Fractures of the middle third of the clavicle – epidemiological study of patients treated at Tygerberg Academic Hospital and a classification system'

### **Stellenbosch University Faculty of Health Academic Year Day – August 2012, Tygerberg, South Africa**

Oral presentation: **PR King** 'Intramedullary locked fixation of clavicle shaft fractures – continued review'

**Prize for best surgical discipline presentation**

### **South African Orthopaedic Association Annual Registrars' Congress – February 2012, Cape Town, South Africa**

Oral presentation: **PR King** 'Clavicle fractures'



Publications and presentations

**2011 Edinburgh Trauma Symposium and Instructional Course – 17-19 August 2011, Edinburgh, Scotland**

Oral presentation: **PR King** 'Clavicle fractures'

**Edinburgh Trauma Symposium and Instructional Course – 17-19 August 2011, Edinburgh, Scotland**

Oral presentation: **PR King** 'Intramedullary locked fixation of clavicle shaft fractures'

**South African Society for Surgery of the Hand Annual Congress – 2-4 September 2011, Sun City, South Africa**

Oral presentation: **PR King** 'Intramedullary locked fixation of clavicle shaft fractures – review of early results'

**SASSH registrar Prize for best oral presentation by a registrar**

**South African Orthopaedic Association Annual Congress – 2-4 September 2011, Sun City, South Africa**

Oral presentation: **PR King** 'Intramedullary locked fixation of clavicle shaft fractures – review of early results'

## Publications and presentations

## List of abbreviations

### **LIST OF ABBREVIATIONS**

ANOVA:	Analysis of Variance
AO:	Arbeitsgemeinschaft für Osteosynthesefragen Association for the study of Internal Fixation
C-arm:	C-shaped image intensifier used for intra-operative imaging
cm:	centimeter
CS:	Constant Shoulder score
CT:	Computer Tomography
DASH:	Disabilities of the Arm, Shoulder and Hand score
Fig:	Figure
g:	gram
IM:	Intramedullary
K-wire:	Kirschner wire
MCID:	Minimal clinically important difference
min:	minute
ml:	milliliter
mm:	millimeter
n:	number
OTA:	Orthopaedic Trauma Association
PACS:	Picture Archiving and Communication System
TBH:	Tygerberg Hospital
TEN:	Titanium Elastic Nail
SD:	Standard Deviation
3D:	three dimensional

## List of abbreviations

## **OUTLINE OF THE THESIS**

## Outline of the thesis

### **INTRODUCTION**

Clavicle fractures are common and generally occur in young, physically active individuals. Traditionally clavicle fractures were classified and described according to the location of the fracture; fractures to the clavicle shaft and fractures to either in the medial or lateral end of the clavicle. This thesis will focus on the management of clavicle shaft fractures. The management of clavicle shaft fractures has been a controversial topic. Historically these fractures were viewed as benign and treated conservatively with good outcomes described. More recent studies suggested that, particularly in the case of displaced and shortened fractures, surgical management is likely to result in better outcomes. The best method of treatment for these more complex fractures has been a topic of debate with various positive and negative aspects attached to each treatment modality. These treatment options can be classified into two groups – intramedullary and extramedullary fixation. Extramedullary fixation is the most commonly used modality of treatment, but high complication rates and high rates of secondary operative procedures to remove the hardware has made this modality less than ideal. Intramedullary fixation holds the advantage of less invasive surgical techniques, less soft tissue dissection and periosteal stripping with potentially higher union rates, but its use has been limited by the risk of hardware migration.

In the last decade an intramedullary nail was designed that has a medial flexible part to better adapt to the anatomical shape of the clavicle. This allows wider bridging of the fracture site providing better fixation. The device is also locked into place by a gripper system at its medial end and a lateral locking screw. This potentially negates the risk of hardware migration. Limited clinical data proving the efficacy of this device is available and clear indications to use the device have not been established. It is postulated that this device will give comparable union rates and functional outcomes to patients treated by traditional extramedullary fixation, but with superior cosmetic result and a shorter surgical time.

Outline of the thesis

## **RESEARCH QUESTIONS AND AIMS**

The aim of this PhD study is to determine whether a novel locked intramedullary device, which is used in the treatment of clavicle shaft fractures, can restore the anatomy and function of the shoulder as effectively as anatomical contoured locked plating.

### **Main research question**

Is the Sonoma CRx intramedullary nail able to achieve union and restore function of the affected shoulders in patients sustaining displaced and shortened clavicle shaft fractures and is it as effective as treating these fractures with anatomical contoured locked plating?

We hypothesized that the intramedullary nail would be as effective as an anatomical contoured locking plate to achieve union and restore shoulder function in patients with displaced and clavicle shaft fractures.

To answer this question, a series of studies were done and is consequently presented in six research chapters and one summary and conclusion chapter. Each of the six research chapters presents a response to unique aims and research questions, while chapter 7 provides an overview of the scientific findings of the thesis chapters and answers the overall main question of this thesis.

### **Sub-research questions**

**Chapter 1** aims to present a thorough overview of the literature with special emphasis on the intramedullary fixation of clavicle shaft fractures.

The research question is: Can the available literature indicate whether intramedullary *or* extramedullary fixation of clavicle shaft fractures is superior?

The hypothesis is that the literature would not be able to provide a clear answer to this research question.

## Outline of the thesis

**Chapter 2** aims to describe the epidemiological profile of patients presenting with clavicle shaft fractures in a developing country.

The research question is: How common are clavicle shaft fractures in a tertiary hospital in South Africa and what is the epidemiological profile of these patients?

The hypothesis is that the epidemiological profile of patients presenting with clavicle shaft fractures in a developing country will differ from the epidemiological profile of patients presenting in the developed world.

**Chapter 3** aims to report on the use of the novel intramedullary device in consecutive patients presenting with displaced and shortened clavicle shaft fractures to determine whether this device is effective.

The research question is: Can the Sonoma CRx intramedullary nail successfully treat displaced and shortened clavicle shaft fractures presenting to a tertiary hospital in South Africa?

The hypothesis is that the device can be used effectively to treat displaced and shortened clavicle shaft fractures.

Based on the experience gained and presented in Chapter 3, **Chapter 4** aims to provide a detailed description of the surgical technique used when implanting the novel Sonoma CRx device.

The research question is: Can a reproducible and safe surgical technique be described to guide other surgeons in the effective use of a novel intramedullary device?

The hypothesis is that such a technique can indeed be described, effectively communicated and distributed.

Based on the findings presented in earlier chapters, the aim of **Chapter 5** is to compare the treatment outcomes of patients with clavicle shaft fractures who were randomly treated using either traditional anatomically contoured locked plating (extramedullary fixation) or the novel locked intramedullary device.



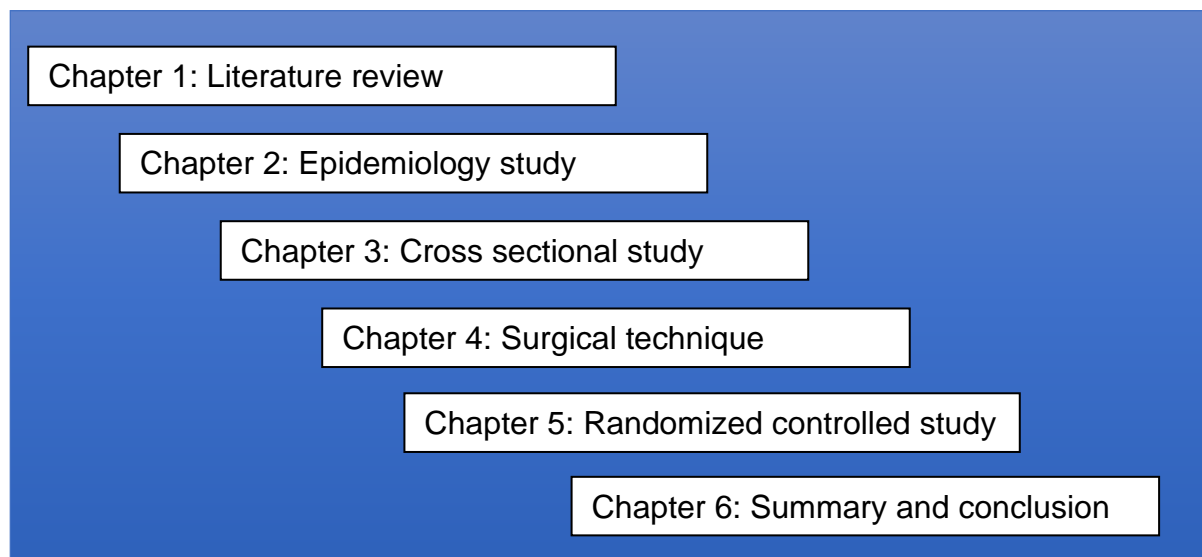
## Outline of the thesis

The research question is: How effective is the Sonoma CRx intramedullary nail compared to traditional anatomically contoured locked plating of shortened and displaced clavicle shaft fractures in achieving union and restoring functional capacity of the shoulder?

The hypothesis is that the intramedullary device, due to its unique properties, will provide superior functional and anatomical results when compared to traditional extramedullary fixation.

**Chapter 6** summarises and discusses the results presented in the preceding six chapters. Relevant additions to existing knowledge on the subject are highlighted and areas for further study are identified.

## Outline of the thesis

**CHAPTER LAYOUT**

**Figure 1.** Overview of the chapter layout of the thesis.

**Chapter 1** of the thesis presents a review of current literature on clavicle shaft fractures. Emphasis is placed on the management of displaced and shortened fractures treated by intramedullary fixation.

In **Chapter 2** the epidemiological profile of patients presenting with clavicle shaft fractures in a developing country is described to thus illustrate the extent of the pathology.

**Chapter 3** describes the outcomes of consecutive patients with displaced and shortened clavicle shaft fractures treated with the novel device as a pilot study.

The surgical technique used to implant this novel intramedullary device, as based on experiences gained during the pilot study, is described in detail in **Chapter 4**.

In **Chapter 5** this device is compared to the gold standard of treatment in a randomised controlled trial to determine whether it is more effective.

In **Chapter 6**, the findings of chapters 1 to 6 are summarized and discussed to answer the main research question of this thesis.

## MANAGEMENT OF CLAVICLE SHAFT FRACTURES WITH INTRAMEDULLARY DEVICES: A REVIEW OF CURRENT CONCEPTS

The article has been submitted for publication as:

**P.R. King**, R.P. Lamberts. Management of clavicle shaft fractures with intramedullary devices: a review of current concepts. *Expert Review of Medical Devices* 2019 – *In review*.

**Impact factor:** 2.2

**Ranking:** #42 of 80 in Engineering and Biomedical Science (ISI Web of Science)

## Chapter 1

---

**ABSTRACT**

The clavicle is a bone frequently fractured through a number of mechanisms. These fractures commonly affect young individuals who are economically and physically active. The management of clavicle shaft fractures has, in recent times, evolved from being purely supportive to more aggressive and invasive approaches in a significant percentage of fractures. Minimally displaced fractures are benign, heal with excellent results and generally exact little attention. However, it has been shown that displaced and shortened fractures have high non-union and malunion rates. These mal- and non-united fractures are symptomatic in the majority of patients and may result in significant morbidity. An operative approach is generally considered the procedure of choice when dealing with these complicated fractures. However, the question as to what constitutes the best course of action when dealing with these more complex fractures has been widely debated and various positive and negative aspects have been attributed to each treatment modality. The treatment options can be broadly classified in two groups – intramedullary and extramedullary fixation. Extramedullary fixation has, over time, become the most commonly used modality of treatment. However, high incidence of complications together with high rates of secondary operative procedures to remove the plate have shown this modality to be less than ideal. Intramedullary fixation holds the advantage of employing less invasive surgical techniques resulting in less soft tissue dissection and periosteal stripping, thus yielding potentially higher union rates. Its use, however, has been limited due to the risk of hardware migration and high rates of secondary operations to remove said hardware.

**Level of evidence:** 2

**Keywords:** clavicle fractures, intramedullary nail, orthopaedic surgery, review

## Chapter 1

---

## EPIDEMIOLOGY OF CLAVICLE FRACTURES

Clavicle fractures are common fractures comprising 2, 6 to 4% of all adult fractures and accounting for 35% of injuries to the shoulder girdle.<sup>1</sup> The annual incidence of clavicle fractures varies between 29 and 64 per 100 000 population per year.<sup>1</sup> Nowak *et al.* ascertained the incidence of clavicle fractures to be 70 per 100 000 in males and 30 per 100 000 in females.<sup>2</sup> Postacchini *et al.* noted, in their series of 535 isolated clavicle fractures, that 68% of these occur in men with the left clavicle being affected in 61% of patients.<sup>3</sup> In addition, they ascertained that middle third clavicle fractures account for 81% of clavicle fractures and are displaced in 48% and comminuted in 19% of cases. Robinson *et al.* reported that middle third fractures comprise 69% and medial third fractures 2% of fractures whilst lateral third fractures account for the balance.<sup>4</sup> The mean age at time of injury is 33 years with a male to female ratio of 2.6 to 1 and the ratio of left to right clavicle fractures 1.28 to 1. They further identified the highest incidence of fractures to be in males, 13 to 20 years of age.<sup>4</sup>

Stanley *et al.* noted the first, and highest, peak of clavicle fractures to be in males younger than 30 years with the second peak occurring in females aged 80 years and older.<sup>5</sup> These latter fractures are thought to be related to osteoporosis.

The mechanisms of injury which results in middle third clavicle fractures can be divided into direct and indirect trauma. Indirect trauma to the clavicle occurs with falls onto an outstretched hand or, more commonly, falls onto the point of the shoulder. These fractures commonly occur during sporting activities including mountain biking or horse riding. Direct trauma inflicted by a blunt or penetrating mechanism can result in a clavicle fracture. Postacchini *et al.* identified motor vehicle accidents to be the main mechanism of injury.<sup>6</sup> Stanley *et al.* noted that fractures which occur in the elderly generally happen secondary to low energy falls from standing.<sup>5</sup> Nowak *et al.* identified bicycle accidents as the most common mechanism of injury with sporting injuries resulting in most clavicle fractures in males.<sup>2</sup> Zhu *et al.* reported that the vast majority of fractures in an urban Chinese population were as a result of road traffic accidents.<sup>7</sup> Nordqvist *et al.* noted, in a series of 2035 fractures, a significant increase in the incidence of clavicle fractures during the 35 year period of his review.<sup>8</sup>

An interesting study in China identified alcohol abuse, increased age, smoking, lack of sleep and a history of previous fracture/s to be risk factors which increase the

possibility of sustaining a clavicle fracture in the future.<sup>9</sup> High energy injury mechanisms are associated with an increase in fracture comminution, associated injuries and the incidence of open fractures.<sup>10,11</sup>

Although these fractures are commonly encountered, little is known about the epidemiology of fractures seen in an African population. No epidemiological studies of patients presenting with clavicle fractures in an African setting have been done. The epidemiology has been widely studied in first world populations, but it is unknown whether this data is applicable to the third world.

## **ANATOMY OF THE CLAVICLE**

The clavicle consists of cancellous bone, enveloped by cortical bone, which is much thicker in its middle 3/5th than in the lateral and medial fifths.<sup>12</sup> The configuration of the clavicle presents a double curvature – a convex anterior curve in the medial half and a concave anterior curve in the lateral half. It has an apex superior curvature located in the medial half of the clavicle.<sup>13</sup> The cross-sectional anatomy of the clavicle differs in shape along its length. Distally the outer third is virtually flat, the medial third is prismatic and the middle third is circular in shape.<sup>12</sup>

The clavicle is the first bone in the body to ossify (5th week of fetal life) as well as the only long bone to ossify by intramembranous ossification without going through the cartilaginous stage.<sup>12</sup> The medial growth plate of the clavicle is the last growth plate in the body to close, usually between 22 and 25 years of age.<sup>12</sup> The clavicle articulates medially with the sternum at the sterno-clavicular joint and laterally with the acromion at the acromio-clavicular joint.

### **Anatomical variations of the clavicle**

Based on gender and age, the clavicle can vary substantially in size and shape.<sup>12</sup> Andermahr *et al.* reported that clavicles in females are generally shorter, less curved and that they contain a lower calcium concentration.<sup>14</sup> In line with this, Daruwalla *et al.* reported, based on 3D computer tomography reconstructions, that the clavicle bones of males are generally longer, wider and thicker than those of females.<sup>13</sup>



Bortier *et al.* evaluated 90 clavicles in males and females through the use of computer tomography and reported an average length of  $163 \pm 11\text{mm}$ .<sup>15</sup> In addition, they reported that the clavicle length between the right and the left side tends to differ by 1.2% whilst, on average, clavicles were 9% longer in males. In line with this, Bortier *et al.* further noted that the sternal (18%) and acromial curvature (4%) were substantially less pronounced in females than in males.<sup>15</sup> In line with the previous studies, King *et al.* also reported differences in length between the right and left clavicle. In this study, however, no curvature differences were noted between the right and left clavicle.<sup>16</sup>

### **Clavicle anatomy and intramedullary fixation of clavicle shaft fractures**

Andermahr *et al.* analysed 196 cadaver clavicles to determine the anatomical variations in the medullary canal and its suitability to intramedullary fixation.<sup>14</sup> They ascertained the narrowest portion of the canal to be at the midpoint of the clavicle  $-6.7 \pm 2.6\text{mm}$  in diameter. They also discovered the cortex to be at its thinnest at the dorsal aspect of the lateral clavicle and the ventral aspect of the medial clavicle. This represents the insertion points for commonly used intramedullary devices, but also areas at risk for cortical perforation.

In a computer tomography study of clavicle anatomy, King *et al.* reported the size of the medullary canal adequate to accommodate most intramedullary devices.<sup>16</sup> This study describes, in some detail, the height and width of the intramedullary canal on the lateral, middle and medial end of the clavicle in relation to the clavicle curvatures. The study shows that the medullary canal is sufficiently wide and extends deep enough into the lateral and medial components of the clavicle and therefore is able to accommodate an intramedullary device in most cases.<sup>16</sup> Only 1.4% of the male clavicles had a medullary canal which was too small to accommodate an intramedullary nail whilst 31% of the female clavicles had a too narrow medullary canal.

The curvature of the clavicle varies and that can affect the length of the implant to be inserted, particularly if the implant is rigid and does not allow for accommodation of the curvature. To determine whether rigid fixation devices can be effective in treating this complex 3-dimensional anatomy, Bachoura *et al.* scanned 22 clavicles and used a CT model to evaluate the length and cross-sectional area of the clavicle.<sup>17</sup> They

simulated IM fixation by superimposing a straight cylindrical corridor in a lateral-to-medial direction. The authors considered stable fixation as the ability to bypass the midpoint of the clavicle (assumed fracture site) by two cortical diameters with the straight corridor. They also found the midpoint of the clavicle to have the smallest cross-sectional area and were able to simulate rigid IM fixation successfully in 15 of the 22 clavicles.<sup>17</sup> This seems to suggest limitations in the use of rigid devices, particularly in addressing complex fractures or fractures which are not located at the midpoint of the clavicle. The ability to achieve two cortical diameters was related to the size of the clavicle, although no demographic information was available.

## **CLASSIFICATION OF CLAVICLE FRACTURES**

Various classification systems for fractures of the clavicle have been described and these include the Allman classification, the Neer classification and the Craig classification.<sup>1</sup> Allman classified clavicle fractures based solely on the anatomical location of the fracture. He thus classified fractures as occurring in the medial third, the middle third and the lateral third.<sup>18</sup> Neer subclassified fractures occurring in the lateral third of the clavicle with Craig further subclassifying fractures of the lateral and medial third.<sup>1</sup> The lateral third fractures were subclassified according to displacement, ligamentous integrity and amount of comminution. Lateral third fractures are subclassified as one of 5 types<sup>1</sup>. Medial third fractures are classified according to displacement, comminution and whether the fracture extends into the sternoclavicular joint<sup>1</sup>. The Edinburgh (Robinson) classification system describes middle third clavicle fractures according to their displacement and degree of comminution.<sup>4</sup> Type IIA fractures were classified as undisplaced or angulated only. Type II B fractures were described as displaced with subclassifications for the fracture configuration and amount of comminution<sup>4</sup>. O'Niell *et al.* has shown that the Robinson classification has the greatest prognostic value for clavicle shaft fractures whilst Craig's classification holds the greatest prognostic value for distal third fractures.<sup>19</sup> The AO/OTA classification scheme has been expanded to include the clavicle. The clavicle is segment 15 and is divided in metaphyseal, diaphyseal and lateral metaphyseal fractures.

## TREATMENT OF CLAVICLE SHAFT FRACTURES

Various treatment modalities exist for dealing with clavicle shaft fractures. Treatment options include both operative and non-operative options. However, the optimal treatment for displaced clavicle shaft fractures remains a controversial and widely debated topic.<sup>1</sup> Historically, clavicle shaft fractures were thought to be benign fractures and were treated non-surgically.<sup>20,21</sup> However, a landmark study by McKee *et al.*<sup>22</sup> challenged this belief.

More recent studies have indicated significantly higher complication rates in certain fracture types when these are treated conservatively.<sup>22-23</sup> Non-randomised, non-comparative, pooled data across all studies comparing conservative treatment with plating of clavicle shaft fractures have shown a non-union rate of 2.5% in the operatively treated fractures compared to a non-union rate of 5.9% in the conservatively treated group.<sup>24</sup> When the displaced group of fractures is looked at separately, the non-union rate increases to 15.1%.<sup>24</sup> In 1997, Hill *et al.* demonstrated in a retrospective study of 52 non-operatively treated clavicle shaft fractures that displaced fractures with initial shortening of >20mm were associated with a higher risk of non-union and a poor clinical outcome.<sup>23</sup> The landmark study by McKee, which first indicated inferior outcomes in non-operatively treated fractures, compared non-operative treatment with primary plate fixation in 132 displaced middle third clavicle fractures.<sup>22</sup> McKee *et al.* showed superior functional outcomes, lower rates of malunion and nonunion and a shorter time to union in the operative group.<sup>22</sup>

Escola *et al.* demonstrated that malunion of a middle third clavicle fracture with shortening of the clavicle may alter the position of the glenoid fossa which in turn, may affect glenohumeral mobility and scapular rotation leading to unsatisfactory results and loss of function.<sup>25</sup> Lazarides and Zafiropoulos. investigated 132 patients with united fractures of the middle third of the clavicle after conservative treatment.<sup>26</sup> In their study 25.8% of the patients were dissatisfied with their treatment result. Final clavicle shortening of more than 18mm in males and 14mm in females was associated with these unsatisfactory results.

Operative treatment of displaced middle third clavicle fractures is associated with significantly improved Constant Shoulder and DASH scores when compared to fractures in patients treated conservatively.<sup>22</sup>

It is widely accepted in literature that un-displaced or minimally displaced middle third clavicle fractures can, and should be treated conservatively, either in a sling or figure-of-eight bandage.<sup>1,27,28</sup> No difference was noted in the outcomes of patients treated with either a sling or a figure-of-eight bandage, but the figure-of-eight bandage is difficult to apply and causes early discomfort.<sup>29,30</sup>

To further complicate matters, recent reviews are once again questioning whether the operative treatment of displaced clavicle shaft fractures leads to better results. A 2018 Cochrane review<sup>31</sup> concluded that there is only low-quality evidence to prove that surgical treatment holds additional benefits in terms of function, pain and quality of life when compared to conservative treatment. In terms of adverse outcomes, they could not ascertain any differences between the two treatment options. The reviewers suggest that treatment should be individualised and patient specific to thus better balance the risks of non-operative treatment (symptomatic malunion and shoulder stiffness) with the risks of operative treatment (wound infection, wound dehiscence and hardware irritation).<sup>31</sup> In a retrospective study, Napora *et al.* found complications and/or poor outcomes between conservatively and operatively treated displaced fractures to be similar.<sup>32</sup> In a meta-analysis, Woltz *et al.* found that plate fixation does reduce the risk of non-union but does not, however, provide clinically relevant better outcomes when compared to conservative treatments.<sup>33</sup> Additionally, secondary operations were found to be common in both groups. They concluded that literature does not support routine operative treatment for all patients with displaced clavicle shaft fractures.<sup>33</sup> In a prospective randomised controlled trial of 160 patients, the same authors<sup>33</sup> discovered that operative treatment significantly reduced non-union rates, but that secondary operations were common in both groups. They found no difference in the functional outcomes between the two groups. Robinson *et al.* noted a reduced rate of non-union in operatively treated fractures in addition to better functional results.<sup>4</sup> They, however, posited that operative treatment is more expensive and yields a higher rate of implant related complications. They concluded that the routine operative treatment of displaced clavicle shaft fractures is not supported.<sup>4</sup>

This remains a controversial issue.<sup>34</sup> A recent, high quality prospective randomised trial found that surgical treatment yields better functional and radiological outcomes, with minimal complications, when compared to conservative management.<sup>35</sup> Patel *et*

*al.* also concluded that surgical treatment yields superior results.<sup>36</sup> In a very recent current concepts review Hoogervorst *et al.* concluded that the choice of optimal treatment strategy remains debateable.<sup>37</sup> They found that operative treatment leads to improved short-term functional results, increased patient satisfaction, earlier return to sport activities and lower rates of nonunion. They also concluded surgical treatment to be more cost effective. However, they noted that operative treatment has more complications and higher re-operation rates. They found long-term shoulder function to be similar between the two groups. Their final conclusion was that a shared decision-making model should be used to tailor-make an optimal treatment strategy in accordance with the patient's specific needs and expectations.<sup>37</sup> This seems to be the thread common to most of the recent literature.

## **INDICATIONS FOR OPERATIVE TREATMENT**

Indications for surgical treatment of clavicle shaft fractures can be divided into absolute and relative indications.<sup>38</sup> Absolute indications include open fractures, overlying skin compromise, neurological deficit or associated vascular injury.<sup>27,38</sup> Relative indications include multisystem traumatised patients, painful malunions and nonunions and a floating shoulder. Relative indications have also been expanded to include fractures with 15 - 20mm of shortening, complete displacement and comminution.<sup>38</sup> As suggested by Zenni *et al.* these indications have been expanded to include patients who cannot tolerate prolonged immobilisation of the upper limb, for example patients suffering from Parkinson's disease and neuromuscular disorders.<sup>27</sup>

## **TREATMENT OPTIONS**

Operative treatment options consist of external fixation, open reduction and internal fixation using locked or non-locked plates or open or closed reduction with internal fixation using intramedullary rods, wires or nails. <sup>1,24</sup>

### **External fixation**

There are numerous studies available which describe the external fixation of displaced clavicle fractures.<sup>39-40</sup> Each of them have shown fairly good results comparable to plate

fixation and superior to non-operative treatment. In cases of soft tissue compromise, this technique has yielded good results.<sup>41</sup> However, the technique is rarely used as it presents significant limitations including prominent bulky hardware and pin tract problems.

### **Plate fixation**

Plate fixation has predictable union and low complication rates and allows for early mobilisation of the shoulder.<sup>1,38</sup> Anatomically contoured locked plates are currently the most widely used mode of treatment. The superior approach, in which the plate is placed superiorly, is most commonly adopted. This plate position has been shown to be superior biomechanically. Neurovascular structures, however, are at greater risk during drilling and the plate is more prominent under the skin.<sup>42</sup> An alternative to this treatment is the anterior-inferior approach which makes use of appropriately shaped plates. Biomechanical studies have shown that there is no difference between the load to failure of locked and non-locked plates when mono-cortical screw fixation is used.<sup>43,44</sup> Locking plates constructs comprise a plate and screw combination where the screw itself screws into thread created in the plate. This creates a fixed angle screw and plate construct. When bicortical screws are used both constructs have significantly improved loads to failure.<sup>43</sup> A percutaneous plating technique, as described by Lee *et al.*, has shown good results.<sup>45</sup> Theoretical advantages include less surgical dissection, smaller scars and quicker recovery following surgery.<sup>45</sup>

### **Intramedullary fixation**

Intramedullary (IM) fixation presents an alternative to plate fixation for midshaft clavicle fractures and includes the potential advantages of a smaller incision, less soft-tissue disruption and less prominent implants. Numerous intramedullary fixation devices for the treatment of middle third clavicle fractures are available on the market and commonly used.<sup>1,46</sup> These devices include Knowles pins, Hagie pins, Rockwood pins and minimally invasive titanium nails.<sup>38,47</sup> Techniques include antegrade insertion through an entry point on the antero-medial surface of the clavicle. The nail is thus passed over the fracture from an entry point on the sternal side of the clavicle. Alternatively, a postero-lateral entry point in the lateral fragment is created and the nail

is passed over the fracture from laterally into the medial fragment. Both these techniques necessitate the opening of the fracture site to reduce the fracture. Intramedullary fixation of displaced middle third clavicle fractures is associated with a significantly reduced non-union rate when compared to conservative treatment.<sup>24</sup> Thyagarajan recommended intra-medullary fixation of displaced middle third clavicle fractures over plating and conservative treatment.<sup>33</sup> He reported no non-unions, scar related neither complications nor prominent hardware in the nailing group.

Previously intramedullary fixation devices could not be reliably locked and thus axial rotation and length were difficult to control when these devices were used.<sup>48-49</sup>

Smaller incision sizes and less periosteal stripping are potential positive outcomes in fixating clavicle fractures as the clavicle has a periosteal blood supply. Less soft tissue dissection would potentially preserve blood supply and enhance healing whilst smaller incision sizes would potentially preserve the supraclavicular nerves thus avoiding anaesthesia of the anterior chest wall. Logic would dictate that since the device is positioned in the medullary canal there would be no problematic superior subcutaneous hardware as often observed with plate fixation.<sup>46</sup> However, some implants have prominent hardware protruding from the lateral entry point (Hagie pin and TEN nails).<sup>46</sup>

Biomechanical studies have shown that the risk of refracture following removal of the intramedullary device is smaller than after plate fixation. The plate fixated clavicles were predictably vulnerable to fracture through the vacant screw hole after removal of the plate and screws.<sup>50</sup> Removal of the plate following successful union is an invasive procedure with known complications.<sup>51</sup>

### ***Kirschner wire fixation***

K-wire fixation of clavicle shaft fractures was first described in 1940. Recent studies still report good outcomes with the use of this technique. Bokata described good results using a two wire technique and found this technique to be safe.<sup>52</sup> Coppa *et al.* reported that intramedullary fixation using K-wires had superior outcomes when compared to conservative management and found the procedure to be safe.<sup>53</sup> A recent meta-analysis found less revision and hardware related complications following K-wire fixation than in the case of plate fixation. However, inferior functional post-operative

results after K-wire fixation were noted.<sup>54</sup> Major concerns regarding the migration of the wires exist and numerous case reports describing the intrathoracic, aortic, neck and even spinal cord migration of wires have been published.<sup>55-56</sup> These catastrophic complications have resulted in this technique falling out of favour.<sup>56</sup>

### ***Clavicle pins (Hagie and Rockwood pins)***

Hagie and Rockwood pins are nearly identical devices and, as such, are commonly confused. Both devices are made from solid stainless-steel with a terminal threaded end to obtain bone purchase. Both devices have two locking nuts – one to provide compression over the fracture and the other to keep the compression nut in place. They also differ as to the position of the trochar point. The Rockwood pin can be placed from either the medial or the lateral end of the fracture whilst the Hagie pin can only be placed from the lateral end. To place the device the fracture site is opened and the medial and lateral medullary canals prepared. The device can then be inserted via an anteromedial approach, close to the sternoclavicular joint, or via a lateral approach, close to the acromioclavicular joint. The fracture is held in the reduced position while the pin is advanced over the fracture. The lateral end of the pin is then cut under the skin. Both these devices need to be removed after fracture union.

Good results have been obtained using both these devices, but complications are relatively common. Payne *et al.*<sup>57</sup> reported a union rate of 97%, but a complication rate of more than 80%. The main complication noted was painful hardware at the lateral end, but loss of shoulder range of movement, infections and hardware failure were also reported.<sup>57</sup> Millett *et al.* reported a union rate of over 90% using Hagie pins and a lower complication rate of 25%.<sup>58</sup> However, painful lateral hardware was once again noted as the most common complication. Judd *et al.* reported a high union rate using the Hagie pin in a study which compared Hagie pin fixation to non-operative treatment.<sup>59</sup> The complication rate was, however, higher and no difference in functional outcome was noted between the two groups at 12 months follow-up. In smaller studies using these devices Mudd and Strauss found unacceptably high complication rates and warned against the use of these devices.<sup>60,61</sup> In a recent literature review Eichenger *et al.* concluded that the complication rate when using



these devices is unacceptably high and that alternative fixation devices should be used.<sup>46</sup>

### ***Titanium elastic nail (TEN) fixation***

Titanium elastic nail fixation was first described in 2003 by Jubel.<sup>47</sup> The technique is fairly simple and the device can be passed over the fracture in an open or closed technique. An anterograde or retrograde technique can be used. The device is removed after fracture union to mitigate the risk of hardware migration and prominent subcutaneous hardware at the entry point. Jubel reported a very high union rate and a relatively low complication rate.<sup>47</sup> In two randomised controlled trials the complication rate was noted as much higher<sup>62,63</sup> although excellent union rates were achieved. Similar results were recorded in the van der Meijden study with patients treated by TEN and plating. In the van der Meijden study the complication rate was inflated as the second surgery to remove the implant was noted as a complication – a procedure generally regarded as routine when using a titanium elastic *nail*.<sup>63</sup>

### ***Intramedullary screw fixation***

Solid or cannulated intramedullary screws have been described in a few studies detailing the treatment of clavicle shaft fractures. Good results were reported in these studies with high union and relatively low complication rates. The screws can be placed from medial or lateral. In the case of a medial approach the screw head is prominent medially under the skin and the device needs to be removed following union. Khalil *et al.* showed a union rate of 100% and found the technique to be both simple and affordable.<sup>64</sup> In another study, where a lateral to medial screw trajectory was used, the problem of prominent subcutaneous hardware was avoided. No hardware had to be removed and excellent union rates were recorded.<sup>65</sup> The same anatomical problems associated with the use of Hagie or Rockwood pins would presumably apply to intramedullary screws. A rigid straight implant is placed over the fracture in a bone with a s-shaped curve in the axial plane as well as a curvature in the coronal plane. As described previously,<sup>17</sup> in certain cases the accurate placing of the device, with solid fixation over the fracture site, proves to be problematic. Good

results using this device have been described, but the available literature is of fairly low quality. These results have not been clinically replicated and the technique has largely fallen out of favor<sup>1</sup>.

### ***Flexible locked nail***

More recently an alternative device has become available which attempts to address the biomechanical challenges presented by traditional devices – lack of rotational and length stability. The Sonoma CRx device consists of a solid straight hub, a flexible tubular medial section and an internal fixation system. The device is inserted into the medullary canal following reduction of the fracture. The medial flexible portion of the device follows the axial and coronal curvature of the clavicle. Once properly seated in the medullary canal and accurate fracture reduction has been achieved, the internal assembly is activated. Upon activation, the flexible section is then transformed into a rigid nail and grippers at the medial end are deployed. The grippers lock the medial end of the device providing rotational and axial stability. Laterally the device is locked with an interlocking screw.<sup>66</sup> One prospective study has been done in which the device is compared to minimally invasive plating. Similar functional outcomes were noted between the two groups but a shorter time to union in the nailing group was perceived. King *et al.* conducted a retrospective study in which the effectiveness of this device was evaluated.<sup>67</sup> The study yielded a 100% union rate but 3 hardware failures occurred. Two further case reviews also reported hardware failure.<sup>68,69</sup> King *et al.* ascribed the hardware failure witnessed in their study to technically inferior surgical techniques – the device was not inserted far enough medially across the fracture site making the construct unstable.<sup>67</sup> In the other two case reports the authors questioned the implant itself. The authors perceived the hardware failures were due to weakness of the device itself causing the hardware failures. Calbiyik *et al.* made no reference to hardware failures in a paper describing their initial experience with the device.<sup>70</sup> King *et al.* described the surgical technique which should be used to insert this device in order to avoid hardware failure.<sup>66</sup>

---

## INTRAMEDULLARY VERSUS EXTRAMEDULLARY FIXATION OF CLAVICLE FRACTURES

Numerous meta-analyses and review articles comparing intramedullary and extramedullary fixation found no statistically significant difference between the two treatment modalities regarding union rate and functional outcome.<sup>71,72</sup> Retrospective and prospective studies comparing intra- and extramedullary fixation have presented similar outcomes when union rates and functional outcomes are compared.<sup>73-74</sup> Ferran *et al.* compared plating of displaced middle third clavicle fractures to intramedullary fixation using a Rockwood pin and found no significant difference between the union rate, Constant Shoulder score or the Oxford Shoulder score of the two groups.<sup>75</sup> However, in this study all the Rockwood pins and 53% of the plates had to be removed due to infection or soft tissue irritation.<sup>75</sup> In a meta-analysis and systematic review, prominent hardware in the plating group resulted in complications in most cases.<sup>71,72</sup> A recent meta-analysis noted increased reoperation and refracture rates after the removal of plates, post extramedullary fixation, but no difference in union rate or functional outcome was evident.<sup>71</sup> Two very recent meta-analyses ascertained that intramedullary fixation might be the treatment modality of choice, citing the high reoperation rate due to prominent subcutaneous hardware in the plating group as reason for this conclusion.<sup>76-77</sup> A recent Cochrane review could not recommend one specific fixation technique suitable for midshaft clavicle fractures, citing the inadequacy of available evidence.<sup>78</sup> A very high proportion of fractures treated with plate fixation require a second operation to remove the plate. This procedure has to be done through the original skin incision resulting in further scarring and soft tissue compromise. The second surgery also increases the risk of supraclavicular nerve injury leading to reduced patient satisfaction.<sup>51</sup> It has been shown that when intramedullary devices and plates are removed, following union of the fracture, that these clavicles treated with an intramedullary device has a higher load to failure. This, in turn, decreases the risk of a fracture shortly after removal of the fixation device.<sup>50</sup> Houwert *et al.* also discovered higher refracture rates following hardware removal in plated clavicles compared to intramedullary fixation.<sup>71</sup> Intramedullary nailing of the clavicle employs a percutaneous operative technique which results in minimal periosteal stripping and no bone/plate compression interface, thus the periosteal blood supply is preserved

promoting union.<sup>38,73</sup> Fixation of the fracture can be achieved through a much smaller wound than that which is needed for fixation using a plate and screws.<sup>28,38,73,79,80</sup>

Millett *et al.* noted a major complication rate (non-union, malunion and infection) of 8.6% using intramedullary fixation and further ascertained that superficial skin infections and skin erosions were present in 15% of cases.<sup>58</sup> Multiple case reviews have described migration of non-locked intramedullary fixation devices into the lungs or other structures in the thorax.<sup>56</sup> Wijdicks *et al.* noted that intramedullary fixation yielded a lower post-operative complication rate when compared to patients treated by plating.<sup>81</sup> Early nail failure using the Sonoma CRx intramedullary device has been described.<sup>67,68</sup> Early failure is commonly associated with incorrect placement of the device during initial fixation of the fracture.<sup>67</sup> A recent meta-analysis found a lower complication rate in terms of refracture rate, prominent hardware and reoperation rates in patients treated with intramedullary fixation.<sup>82</sup> Prominent subcutaneous hardware at the lateral entry point remains problematic with traditional implants as this procedure requires the implants to be removed routinely once fracture union has been achieved.<sup>83</sup>

## **CONCLUSION**

Clavicle shaft fractures were traditionally considered benign injuries and treated conservatively with good results. Modern outcome-based studies propose more aggressive treatment of displaced and shortened fractures. This remains a controversial topic with numerous systematic reviews and meta-analyses providing conflicting conclusions. Further high-quality research is needed to provide a definitive answer. Current consensus is that each patient should be individualised in terms of fracture configuration and functional demand. The risks of operative fixation versus the risk of complications secondary to mal- and non-union should be weighed. The best operative treatment modality remains unclear. Recent high-quality research studies maintain that there is no difference in outcomes between intra- and extramedullary fixation. Limited research has investigated the effectiveness of a novel flexible, locked device. Early results are encouraging, but no long-term reviews and studies are available which compare this device to the current gold standard of treatment – extramedullary locked plate fixation.

---

**REFERENCES**

1. Khan L, Bradnock TJ, Scott C, Robinson CM. Fractures of the clavicle. *J Bone Jt Surg Am.* 2009;91(2):447-460.
2. Nowak J, Mallmin H, Larsson S. The aetiology and epidemiology of clavicular fractures. A prospective study during a two-year period in Uppsala, Sweden. *Injury.* 2000;31(5):353-358.
3. Postacchini R, Gumina S, Farsetti P, Postacchini F. Long-term results of conservative management of midshaft clavicle fracture. *Int Orthop.* 2010;34(5):731-736.
4. Robinson CM. Fractures of the clavicle in the adult. Epidemiology and classification. *J Bone Joint Surg Br.* 1998;80(3):476-484.
5. Stanley D, Trowbridge EA, Norris SH. The mechanism of clavicular fracture. A clinical and biomechanical analysis. *J Bone Joint Surg Br.* 1988;70(3):461-464.
6. Postacchini F, Gumina S, De Santis P, Albo F. Epidemiology of clavicle fractures. *J Shoulder Elb Surg.* 2002;11(5):452-456.
7. Zhu X, Li W, Chen Z. Analyses of epidemiology in 363 cases of clavicle fractures. *Zhongguo Xiu Fu Chong Jian Wai Ke Za Zhi.* 2004;18(4):275-276.
8. Nordqvist A, Petersson C. The incidence of fractures of the clavicle. *Clin Orthop Relat Res.* 1994;(300):127-132.
9. Chen W, Zhu Y, Liu S, *et al.* Demographic and socioeconomic factors influencing the incidence of clavicle fractures, a national population-based survey of five hundred and twelve thousand, one hundred and eighty seven individuals. *Int Orthop.* 2018;42(3):651-658.
10. Gottschalk HP, Dumont G, Khanani S, Browne RH, Starr AJ. Open clavicle fractures: patterns of trauma and associated injuries. *J Orthop Trauma.* 2012;26(2):107-109.
11. Taitsman LA, Nork SE, Coles CP, Barei DP, Agel J. Open clavicle fractures and associated injuries. *J Orthop Trauma.* 2006;20(6):396-399.
12. Moseley HF. The clavicle: its anatomy and function. *Clin Orthop Relat Res.* 1964;58:17-27.
13. Daruwalla ZJ, Curtis P, Fitzpatrick C, Fitzpatrick D, Mullett H. Anatomic variation of the clavicle: A novel three-dimensional study. *Clin Anat.* 2010;23(2):199-209.
14. Andermahr J, Jubel A, Elsner A, *et al.* Anatomy of the clavicle and the intramedullary nailing of midclavicular fractures. *Clin Anat.* 2007;20(1):48-56.
15. Bortier HE, Amit B, Huysmans T, *et al.* Osteologic exploration of the clavicle: a new approach. *FASEB J* 2009;23:Meeting Abstract Supplement, LB9-1039.5
16. King PR, Scheepers S, Ikram A. Anatomy of the clavicle and its medullary canal: a computed tomography study. *Eur J Orthop Surg Traumatol.* 2014;24(1):37-42.
17. Bachoura A, Deane AS, Wise JN, Kamineni S. Clavicle morphometry revisited: a 3-dimensional study with relevance to operative fixation. *J Shoulder Elb Surg.* 2013;22(1):e15-e21.
18. Allman FL. Fractures and ligamentous injuries of the clavicle and its articulation. *J Bone Joint Surg Am.* 1967;49(4):774-784.
19. O'Neill BJ, Hirpara KM, O'Briain D, McGarr C, Kaar TK. Clavicle fractures: a comparison of five classification systems and their relationship to treatment outcomes. *Int Orthop.* 2011;35(6):909-914.

20. Neer CS. Nonunion of the clavicle. *J Am Med Assoc.* 1960;172:1006-1011.
21. Rowe CR. An atlas of anatomy and treatment of midclavicular fractures. *Clin Orthop Relat Res.* 1968;58:29-42.
22. Canadian Orthopaedic Trauma Society. Nonoperative treatment compared with plate fixation of displaced midshaft clavicular fractures. A multicenter, randomized clinical trial. *J Bone Joint Surg Am.* 2007;89(1):1-10.
23. Hill JM, McGuire MH, Crosby LA. Closed treatment of displaced middle-third fractures of the clavicle gives poor results. *J Bone Joint Surg Br.* 1997;79(4):537-539.
24. Zlowodzki M, Zelle BA, Cole PA, Jeray K, McKee MD. Treatment of acute midshaft clavicle fractures: systematic review of 2144 fractures: on behalf of the Evidence-Based Orthopaedic Trauma Working Group. *J Orthop Trauma.* 2005;19(7):504-507.
25. Eskola A, Vainionpää S, Myllynen P, Pätäälä H, Rokkanen P. Outcome of clavicular fracture in 89 patients. *Arch Orthop Trauma Surg.* 1986;105(6):337-338.
26. Lazarides S, Zafiroopoulos G. Conservative treatment of fractures at the middle third of the clavicle: the relevance of shortening and clinical outcome. *J Shoulder Elbow Surg.* 2006;15(2):191-194.
27. Zenni Jr. EJ, Krieg JK, Rosen MJ. Open reduction and internal fixation of clavicular fractures. *J Bone Joint Surg Am.* 1981;63:147-151.
28. Boehme D, Curtis RJ, DeHaan JT, Kay SP, Young DC, Rockwood CA. Non-union of fractures of the mid-shaft of the clavicle. Treatment with a modified Hagie intramedullary pin and autogenous bone-grafting. *J Bone Joint Surg Am.* 1991;73(8):1219-1226.
29. Ersen A, Atalar AC, Birisik F, Saglam Y, Demirhan M. Comparison of simple arm sling and figure of eight clavicular bandage for midshaft clavicular fractures. *Bone Joint J.* 2015;97-B(11):1562-1565.
30. Stanley D, Norris SH. Recovery following fractures of the clavicle treated conservatively. *Injury.* 1988;19(3):162-164.
31. Lenza M, Buchbinder R, Johnston R V, Ferrari BA, Faloppa F. Surgical versus conservative interventions for treating fractures of the middle third of the clavicle. *Cochrane Database Syst Rev.* 2019;1:CD009363.
32. Napora JK, Grimberg DC, Childs BR, Vallier HA. Results and Outcomes After Midshaft Clavicle Fracture: Matched Pair Analysis of Operative Versus Nonoperative Management. *Orthopedics.* 2018;41(5):e689-e694.
33. Woltz S, Krijnen P, Schipper IB. Plate Fixation Versus Nonoperative Treatment for Displaced Midshaft Clavicular Fractures. *J Bone Joint Surg Br.* 2017;99(12):1051-1057.
34. Houwert RM, Smeeing DPJ, Ahmed Ali U, Hietbrink F, Kruyt MC, van der Meijden OA. Plate fixation or intramedullary fixation for midshaft clavicle fractures: a systematic review and meta-analysis of randomized controlled trials and observational studies. *J Shoulder Elb Surg.* 2016;25(7):1195-1203.
35. Bhardwaj A, Sharma G, Patil A, Rahate V. Comparison of plate osteosynthesis versus non-operative management for mid-shaft clavicle fractures—A prospective study. *Injury.* 2018;49(6):1104-1107.
36. Patel MM, Patel JJ, Gupta AK, *et al.* Comparative evaluation of operative versus non-operative management of midshaft displaced clavicle fractures: A case series. *Int J Orthop Sci.* 2017;3(32):594-599.
37. Hoogervorst P, van Schie P, van den Bekerom MP. Midshaft clavicle fractures. *EFORT Open Rev.* 2018;3(6):374-380.

38. Van Der Meijden OA, Gaskill TR, Millett PJ. Treatment of clavicle fractures: current concepts review. *J Shoulder Elb Surg.* 2012;21(3):423-429.
39. Ma XZ, Zhang BS, Wang ZD, Wang MY. Comparisons of clinical effects among three kinds of treatments of 1/3 displaced midshaft clavicular fractures in adults. *Zhonghua Yi Xue Za Zhi.* 2016;96(1):25-29.
40. Demiralp B, Atesalp AS, Sehirlioglu A, Yurttas Y, Tasatan E. Preliminary results of the use of Ilizarov fixation in clavicular non-union. *Arch Orthop Trauma Surg.* 2006;126(6):401-405.
41. Schuind F, Pay-Pay E, Andrienne Y, Donkerwolcke M, Rasquin C, Burny F. External fixation of the clavicle for fracture or non-union in adults. *J Bone Joint Surg Am.* 1988;70(5):692-695.
42. Iannotti MR, Crosby LA, Stafford P, Grayson G, Goulet R. Effects of plate location and selection on the stability of midshaft clavicle osteotomies: a biomechanical study. *J Shoulder Elbow Surg.* 11(5):457-462.
43. Little KJ, Riches PE, Fazzi UG. Biomechanical analysis of locked and non-locked plate fixation of the clavicle. *Injury.* 2012;43(6):921-925.
44. Renfree T, Conrad B, Wright T. Biomechanical comparison of contemporary clavicle fixation devices. *J Hand Surg Am.* 2010;35(4):639-644.
45. Lee H-J, Oh C-W, Oh J-K, *et al.* Percutaneous plating for comminuted midshaft fractures of the clavicle: a surgical technique to aid the reduction with nail assistance. *Injury.* 2013;44(4):465-470.
46. Eichinger JK, Balog TP, Grassbaugh JA. Intramedullary Fixation of Clavicle Fractures. *J Am Acad Orthop Surg.* 2016;24(7):455-464.
47. Jubel A, Andermahr J, Schiffer G, Tsironis K, Rehm KE. Elastic stable intramedullary nailing of midclavicular fractures with a titanium nail. *Clin Orthop Relat Res.* 2003;(408):279-285.
48. Wilson DJ, Scully WF, Min KS, Harmon TA, Eichinger JK, Arrington ED. Biomechanical analysis of intramedullary vs. superior plate fixation of transverse midshaft clavicle fractures. *J Shoulder Elb Surg.* 2016;25(6):949-953.
49. Golish SR, Oliviero JA, Francke EI, Miller MD. A biomechanical study of plate versus intramedullary devices for midshaft clavicle fixation. *J Orthop Surg Res.* 2008;3(1):28.
50. Smith SD, Wijdicks CA, Jansson KS, *et al.* Stability of mid-shaft clavicle fractures after plate fixation versus intramedullary repair and after hardware removal. *Knee Surg Sports Traumatol Arthrosc.* 2014;22:448-55
51. Wang K, Dowrick A, Choi J, Rahim R, Edwards E. Post-operative numbness and patient satisfaction following plate fixation of clavicular fractures. *Injury.* 2010;41(10):1002-1005.
52. Bakota B, Chan G, Staresinic M, Rajput V, Phadnis J, Korac Z. Safe intramedullary fixation of displaced midshaft clavicle fractures with 2.5 mm Kirschner wires – technique description and a two-part versus multifragmentary fracture fixation outcome comparison. *Injury.* 2017;48:S27-S33.
53. Coppa V, Dei Giudici L, Cecconi S, Marinelli M, Gigante A. Midshaft clavicle fractures treatment: threaded Kirschner wire versus conservative approach. *Strateg Trauma Limb Reconstr.* 2017;12(3):141-150.

54. Zhang K, Zhao J, Zhao Z, *et al.* Treatment of clavicular fractures using intramedullary nailing or K-wire versus plating fixation: a meta-analysis. *Zhongguo Gu Shang*. 2015;28(5):454-461.
55. Minić L, Lepić M, Novaković N, Mandić-Rajčević S. Symptomatic migration of a Kirschner wire into the spinal canal without spinal cord injury: case report. *J Neurosurg Spine*. 2016;24(2):291-294.
56. Reghine ÉL, Cirino CCI, Neto AA, Varallo FR, Évora PRB, de Nadai TR. Clavicle Kirschner Wire Migration into Left Lung: A Case Report. *Am J Case Rep*. 2018;19:325-328.
57. Payne DES, Wray WH, Ruch DS, Zura RD, Moorman CT. Outcome of intramedullary fixation of clavicular fractures. *Am J Orthop (Belle Mead NJ)*. 2011;40(6):E99-104.
58. Millett PJ, Hurst JM, Horan MP, Hawkins RJ. Complications of clavicle fractures treated with intramedullary fixation. *J Shoulder Elbow Surg*. 2011;20(1):86-91.
59. Judd DB, Pallis MP, Smith E, Bottoni CR. Acute operative stabilization versus nonoperative management of clavicle fractures. *Am J Orthop (Belle Mead NJ)*. 2009;38(7):341-345.
60. Strauss EJ, Egol KA, France MA, Koval KJ, Zuckerman JD. Complications of intramedullary Hagie pin fixation for acute midshaft clavicle fractures. *J Shoulder Elb Surg*. 2007;16(3):280-284.
61. Mudd CD, Quigley KJ, Gross LB. Excessive complications of open intramedullary nailing of midshaft clavicle fractures with the Rockwood Clavicle Pin. *Clin Orthop Relat Res*. 2011;469(12):3364-3370.
62. Smekal V, Irenberger A, Struve P, Wambacher M, Krappinger D, Kralinger FS. Elastic stable intramedullary nailing versus nonoperative treatment of displaced midshaft clavicular fractures-a randomized, controlled, clinical trial. *J Orthop Trauma*. 2009;23(2):106-112.
63. van der Meijden OA, Houwert RM, Hulsmans M, *et al.* Operative Treatment of Dislocated Midshaft Clavicular Fractures: Plate or Intramedullary Nail Fixation? *J Bone Joint Surg. Am*. 2015;97(8):613-619.
64. Khalil A. Intramedullary screw fixation for midshaft fractures of the clavicle. *Int Orthop*. 2009;33(5):1421-1424.
65. Chuang T-Y, Ho W-P, Hsieh P-H, Lee P-C, Chen C-H, Chen Y-J. Closed reduction and internal fixation for acute midshaft clavicular fractures using cannulated screws. *J Trauma*. 2006;60(6):1315-20;1320-1.
66. King PR, Basamania CJ, Lamberts RP. A novel intramedullary locked fixation device for treatment of clavicle shaft fractures. *JBSJ Essent Surg Tech*. 2016;6(1):e8.
67. King, P R IA. Intramedullary locked fixation of clavicle shaft fractures – review of early results. *South African Orthop J*. 2011;10(4):67-74.
68. Palmer DK, Husain A, Phipatanakul WP, Wongworawat MD. Failure of a new intramedullary device in fixation of clavicle fractures: a report of two cases and review of the literature. *J Shoulder Elbow Surg*. 2011;20(4):e1-4.
69. Wilson DJ, Weaver DL, Balog TP, Arrington ED. Early Postoperative Failure of a New Intramedullary Fixation Device for Midshaft Clavicle Fractures. *Orthopedics*. 2013;36(11):e1450-1453.



70. Calbiyik M, Zehir S, Ipek D. Minimally invasive implantation of a novel flexible intramedullary nail in patients with displaced midshaft clavicle fractures. *Eur J Trauma Emerg Surg.* 2016;42(6):711-717.
71. Houwert RM, Wijdicks F-J, Steins Bisschop C, Verleisdonk E-J, Kruyt M. Plate fixation versus intramedullary fixation for displaced mid-shaft clavicle fractures: a systematic review. *Int Orthop.* 2012;36(3):579-585.
72. Duan X, Zhong G, Cen S, Huang F, Xiang Z. Plating versus intramedullary pin or conservative treatment for midshaft fracture of clavicle: a meta-analysis of randomized controlled trials. *J Shoulder Elbow Surg.* 2011;20(6):1008-1015.
73. Liu H-H, Chang C-H, Chia W-T, Chen C-H, Tarng Y-W, Wong C-Y. Comparison of plates versus intramedullary nails for fixation of displaced midshaft clavicular fractures. *J Trauma.* 2010;69(6):E82-E87.
74. Kleweno CP, Jawa A, Wells JH, *et al.* Midshaft clavicular fractures: comparison of intramedullary pin and plate fixation. *J Shoulder Elbow Surg.* 2011;20(7):1114-1117.
75. Ferran N a, Hodgson P, Vannet N, Williams R, Evans RO. Locked intramedullary fixation vs plating for displaced and shortened mid-shaft clavicle fractures: a randomized clinical trial. *J Shoulder Elbow Surg.* 2010;19(6):783-789.
76. Zhang B, Zhu Y, Zhang F, Chen W, Tian Y, Zhang Y. Meta-analysis of plate fixation versus intramedullary fixation for the treatment of mid-shaft clavicle fractures. *Scand J Trauma Resusc Emerg Med.* 2015;23(1):27.
77. Xu B, Lin Y, Wang Z, *et al.* Is intramedullary fixation of displaced midshaft clavicle fracture superior to plate fixation? Evidence from a systematic review of discordant meta-analyses. *Int J Surg.* 2017;43:155-162.
78. Lenza M, Faloppa F. Surgical interventions for treating acute fractures or non-union of the middle third of the clavicle. *Cochrane Database Syst Rev.* 2015;(5):CD007428.
79. Lee Y-S, Huang H-L, Lo T-Y, Hsieh Y-F, Huang C-R. Surgical treatment of midclavicular fractures: a prospective comparison of Knowles pinning and plate fixation. *Int Orthop.* 2008;32(4):541-545..
80. Liu P-C, Chien S-H, Chen J-C, Hsieh C-H, Chou P-H, Lu C-C. Minimally invasive fixation of displaced midclavicular fractures with titanium elastic nails. *J Orthop Trauma.* 2010;24(4):217-223.
81. Wijdicks F-JG, Houwert RM, Millett PJ, Verleisdonk EJJM, Van der Meijden OAJ. Systematic review of complications after intramedullary fixation for displaced midshaft clavicle fractures. *Can J Surg.* 2013;56(1):58-64.
82. Shackford SR, Connolly JF. Taming of the screw: a case report and literature review of limb-threatening complications after plate osteosynthesis of a clavicular nonunion. *J Trauma.* 2003;55(5):840-3; 843.
83. Millett PJ, Hurst JM, Horan MP, Hawkins RJ. Complications of clavicle fractures treated with intramedullary fixation. *J Shoulder Elb Surg.* 2011.

## Chapter 1

---

**FRACTURES OF THE CLAVICLE SHAFT**  
**EPIDEMIOLOGICAL STUDY OF PATIENTS TREATED AT A TERTIARY**  
**HOSPITAL IN SOUTH AFRICA.**

The article has been prepared for submission:

**P.R. King**, M.M Eken, R.P. Lamberts. Fractures of the clavicle shaft – epidemiology study of patients treated at a tertiary hospital in South Africa. *Injury – Submission ready*

**Impact factor:** 1.8

**Ranking:** #40 of 76 in Orthopedics (ISI Web of Science)

## Chapter 2

---

**ABSTRACT**

**Purpose:** An epidemiological study describing patients with acute clavicle shaft fractures presenting over a period of 10 years to a tertiary hospital located in an African urban setting.

**Methods:** Patients presenting with acute clavicle shaft fractures were identified by systematically reviewing the Picture Archiving and Communication system of Tygerberg Academic Hospital. The clinical notes of each patient were reviewed to determine age, gender, mechanism of injury, soft tissue status, neurovascular status, associated injuries and treatment rendered. Radiographs were examined to describe fracture displacement and morphology.

**Results:** One thousand and three patients were included in the review, 729 males and 274 females. The right clavicle was fractured in 465 cases and the left in 538. The mean age at presentation of the male patients was  $32 \pm 12$  years and  $37 \pm 14$  years for the female patients ( $p < 0.001$ ). Most clavicle shaft fractures were reported in the age group 21-30 years. The most common mechanism of injury was road accidents, followed by falls, interpersonal violence and sports. In addition to the clavicle shaft fracture, 23.4% of patients sustained further injuries. Fractures were mainly treated conservatively (72%), while 17% were treated with a plate and 11% were treated with an intramedullary nail.

**Conclusion:** The epidemiological profile of patients sustaining clavicle shaft fractures in this study differed from the profile described in similar studies done in developed countries. Patients tended to be younger and a higher proportion of fractures were caused by road accidents and interpersonal violence, especially up to the age of 50 years. A high proportion of clavicle shaft fractures caused by road accidents and interpersonal violence were complicated by additional injuries.

**Keywords:** Clavicle, fracture, epidemiology, Western Cape, South Africa

## Chapter 2

---

## INTRODUCTION

Clavicle fractures are common and comprise 2.6 to 4% of all adult fractures and account for 35% of injuries to the shoulder girdle<sup>1</sup>. The annual incidence varies between 29 and 64 per 100 000 population<sup>1</sup>. In a Swedish population based study, Nowak *et al.* found the annual incidence of clavicle fractures to be 70 per 100 000 in males and 30 per 100 000 in females<sup>2</sup>. Most fractures have been reported to occur in the clavicle shaft (69-82%), followed by 12–26% in the lateral part and 2–6% in the medial part<sup>3,2,4,5</sup>.

The epidemiological profile of patients presenting with clavicle fractures in developed countries has been described in numerous studies.<sup>7,2,3,4</sup> A wide range of injury mechanisms has been described,<sup>6,1</sup> such as low energy falls from standing, motor vehicle accidents and sporting injuries. The age groups at highest risk of sustaining clavicle fractures has been reported to be young adults and the elderly<sup>7,8</sup>. However, whether this data is also applicable to developing countries is unknown. No epidemiological data is available describing patients presenting with clavicle fractures in an African country.

Therefore, this study aimed to describe the epidemiological profile of patients presenting to a tertiary hospital, serving a South African urban population, with acute clavicle shaft fractures from 2008 to 2018.

## METHODS

### Patients

The study was designed as a retrospective case review of all patients presenting to a tertiary hospital with acute clavicle shaft fractures. Institutional approval was obtained from the hospital's review board (IRB0005239, N11/07/207) and the Human Research Ethics Committee (HREC S19/02/037) prior to the study commencing.

X-rays in the Picture Archiving and Communication System (PACS) of Tygerberg Academic Hospital (Cape Town, South Africa) were systematically reviewed to identify patients that presented with acute clavicle shaft fractures from September 2008 to December 2018. Patients aged 16 years and older were included in the study. Clinical notes made at presentation and during follow-up of the patients identified were studied

retrospectively. Pathological fractures and patients who had sustained a previous clavicle fracture were excluded from the study.

### **Study Variables**

Data captured as part of the epidemiological study included: age, gender, mechanism of injury, lateralization (fracture of left/right clavicle), fracture morphology, condition of the overlying tissue, neurovascular condition, treatment regime and other associated injuries that the patient sustained.

Mechanism of injury was classified as either road traffic accidents, interpersonal violence, falls and sporting injuries. 'Road accidents' included motor vehicle and motorcycle accidents as well as pedestrian vehicle accidents. 'Interpersonal violence' comprised direct blunt trauma and penetrating trauma, including gunshot wounds. 'Falls' included all low energy fall related fractures. 'Sports injuries' included all sport related fractures – rugby, football, bicycle falls, etc.

The patients' radiographs were assessed to describe the fracture and to determine the displacement of the fracture. Standard 15° cephalad tilt views of the affected clavicle were used in all cases.

Fractures were described as displaced or undisplaced. Undisplaced fractures had at least partial cortical contact. These included angulated and incomplete fractures. Fractures with no cortical contact between the medial and lateral fragments were described as displaced. Displaced fractures were further classified according to the fracture pattern and the amount of comminution at the fracture site. Fractures with a single fracture line in a transvers, oblique or spiral configuration were described as simple fractures. Fractures containing a single butterfly segment at the fracture site were classified as single fragment fractures. Fractures with multiple comminuted fragments at the fracture site with multiple fracture lines were described as 2 or more fragment fractures.

The conditions of the overlying soft tissue were either classified as 'normal', 'bruising', 'visible deformity', 'skin tethering' or 'open fractures'. Neurovascular status of the affected limb was either classified as 'intact', 'vascular injury' or 'neurological injury'.



In addition to the clavicle shaft fracture, any associated injuries that the patient sustained were also captured. Associated injuries were either classified as 'head injuries' (epidural hematomas, subdural hematomas, cerebral hematomas and contusions, skull fractures), 'chest injuries' (pneumothorax, haemothorax, lung contusions) or 'abdominal injury' (solid organ injury, bowel injuries). Additional fractures were described as 'pelvis', 'spine', 'rib', 'scapula', 'humerus', 'forearm', 'hand', 'femur', 'tibia', 'ankle' or 'foot' fractures.

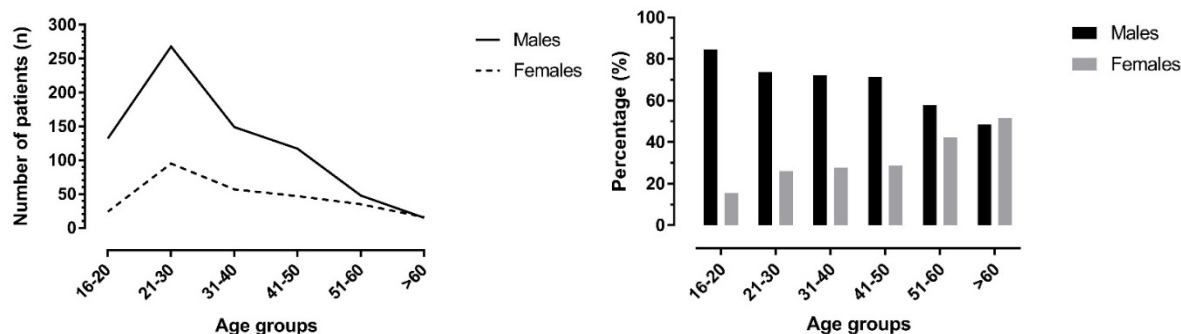
### Statistical methods

Data was analysed with STATISTICA (version 13.3; TIBCO Software). Distribution and homogeneity of variances for the data were examined using a Levene test. Data was expressed as mean  $\pm$  standard deviation as well as percentages of the entire cohort or sub-groups. Differences in age between the males and females were analyzed with a t-test. Significance was set at  $p < 0.05$ .

## RESULTS

### Demographics

In total, 1003 patient were included in our retrospective study, which ranged from 2008 to 2018. The average age of all patients was  $33 \pm 13$  years, with male patients ( $32 \pm 14$  years) being younger than female patients ( $37 \pm 14$  years) ( $p < 0.001$ ). The mean age of the male and female patients within each of the age groups are shown in Table 2.1.



**Figure 2.1** Age and gender distribution in the patients with a clavicle shaft fracture

Almost three-quarters of the patients were male (n=729; 73%), while one-quarter was female (n=274; 27%). This gender distribution was most notably seen in the age groups 16-20, 21-30 and 31-40 years, while a more equal gender distribution was seen in the 51-60 and >60 years age groups (see Figure 2.1).

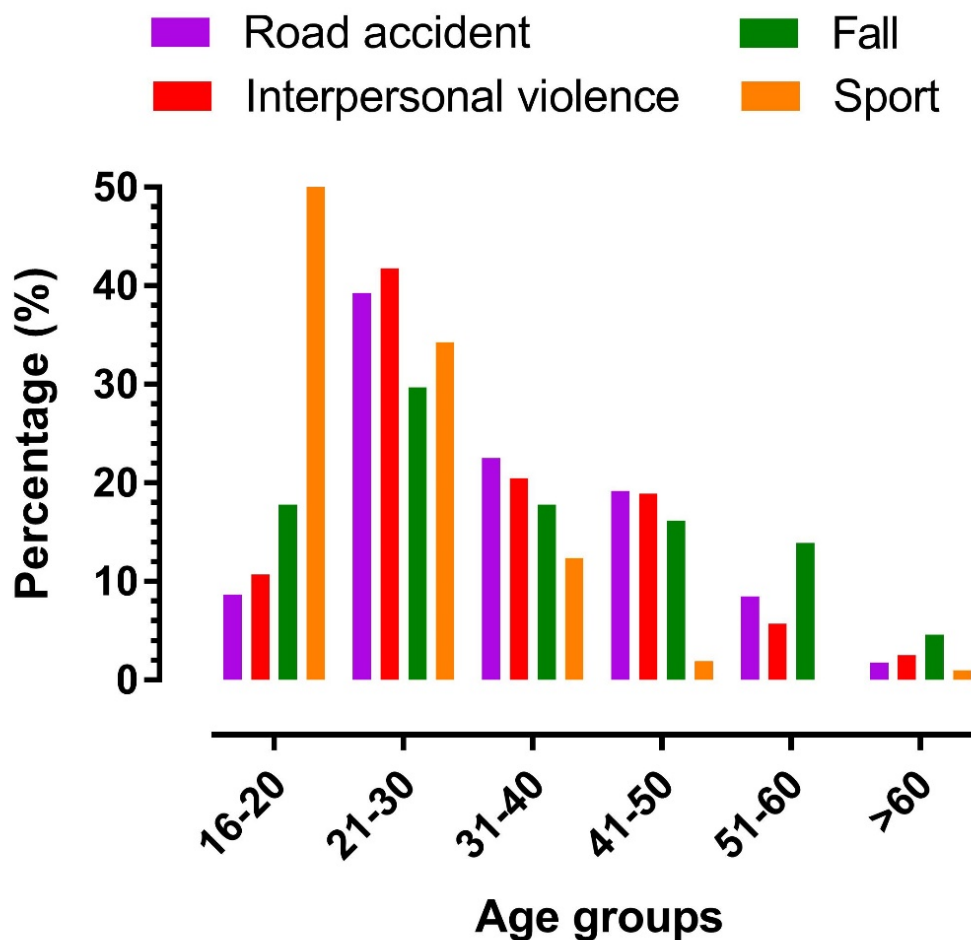
**Table 2.1** Age and percentage male/female distribution in each age group.

	<b>Males</b>	<b>Percentage</b>	<b>Females</b>	<b>Percentage</b>	<b>p - value</b>
<b>16-20 years</b> (n = 156)	17 ± 2 (n = 132)	84.6%	17 ± 2 (n = 24;)	15.4%	0.850
<b>21-30 years</b> (n = 363)	25 ± 4 (n = 267)	73.8%	26 ± 3 (n = 96)	26.2%	0.136
<b>31-40 years</b> (n = 206)	35 ± 3 (n = 149)	72.3%	35 ± 3 (n = 57)	27.7%	0.210
<b>41-50 years</b> (n = 164)	46 ± 3 (n = 117)	71.3%	45 ± 3 (n = 47)	28.7%	0.806
<b>51-60 years</b> (n = 83)	55 ± 3 (n = 48)	57.8%	55 ± 3 (n = 36)	42.2%	0.322
<b>&gt;60 years</b> (n = 31)	66 ± 4 (n = 15)	48.4%	69 ± 9 (n = 16)	51.6%	0.234

The highest percentage of clavicle fractures were observed in the age group 21-30 years (36.2% of all fractures recorded), followed by 31-40 years (20.5%), 16-20 years (15.6%), 51-60 years (8.3%) and >60 years (3.1%).

### Mechanisms of injury

The most common injury mechanism causing clavicle shaft fractures in this study was road accidents (44.7%), followed by falls (25.8%), interpersonal violence (12.2%) and sports (10.5%). The mechanism of injury was unknown in 6.9% of cases. An overview of the injury mechanism per age group is shown in Figure 2.2. An overview of the age and gender distribution within each of the mechanisms of injury categories is shown in Table 2.2.



**Figure 2.2** Overview of the mechanisms of injury in the different age groups.

Significant differences in age between male and female patients were found in the mechanism of injury categories of 'road accident', interpersonal violence' and 'fall' (Table 2.2). Males sustaining fractures secondary to these mechanisms were younger than the females. Differences in age between male and female patients were found in the mechanism of injury categories of 'road accident', interpersonal violence' and 'fall'.

**Table 2.2** Age and male-female distribution in each of the mechanism of injury categories.

	<b>Males</b>	<b>Percentage</b>	<b>Females</b>	<b>Percentage</b>	<b>p - value</b>
Road accidents (n = 448)	33 ± 12 (n= 324)	72.3%	36 ± 13 (n = 124)	27.7%	0.049*
Interpersonal violence (n = 122)	34 ± 11 (n= 93)	76.2%	39 ± 15 (n = 29)	23.8%	0.043*
Fall (n = 259)	33 ± 13 (n = 163)	62.9%	38 ± 16 (n = 96)	37.1%	0.004*
Sport (n = 105)	22 ± 8 (n = 95)	90.5%	24 ± 7 (n = 10)	9.5%	0.359
Other (n = 69)	36 ± 14 (n = 53)	76.8%	37 ± 13 (n = 16)	23.2%	0.899

\* Significant difference between male and female incidence

### Type of fractures, skin and neurovascular condition

Clavicle shaft fractures were observed equally on the right (53.3%) and left side (46.7), while displaced fractures (75.2%) were observed more commonly than un-displaced (24.8%) clavicle shaft fractures (Table 2.3). Within the displaced fractures, 46.8% had a simple fracture, 26.0% had a fracture with one major fragment, while in 27.7% the fracture was associated with two or more fragments.

In 22.1% of all cases the skin condition was described as 'normal', while in 16.2% 'bruising' was observed, in 46.7% a visible deformity was noted, in 0.7% 'skin tethering' was found, 2.7% had 'open fractures', while in 11.7% this data was not captured. A vascular injury was found in 7 patients (0.7%), while in 6 patients (0.6%) an injury to the brachial plexus was sustained.

**Table 2.3.** Overview of the fracture types

	Un-displaced	Displaced	Fracture types within the displaced fractures		
			Simple	One major fragment	Two or more major fragment
<b>Road accident</b>					
Male	90 (27.9%)	233 (72.1%)	90 (38.6%)	62 (26.6%)	81 (34.8%)
Female	37 (30.1%)	86 (69.9%)	42 (48.8%)	19 (22.1%)	25 (29.1%)
All	127 (28.5%)	319 (71.5%)	132 (41.4%)	81 (25.4%)	106 (33.2%)
<b>Interpersonal violence</b>					
Male	29 (30.2%)	67 (69.8%)	43 (64.2%)	8 (11.9%)	16 (23.9%)
Female	8 (29.6%)	19 (70.4%)	8 (42.1%)	6 (31.6%)	5 (26.3%)
All	37 (30.1%)	86 (69.9%)	51 (59.3%)	14 (16.3%)	21 (24.4%)
<b>Fall</b>					
Male	29 (18.4%)	129 (81.6%)	50 (38.8%)	41 (31.8%)	38 (29.5%)
Female	16 (16.8%)	79 (83.2%)	34 (43.0%)	40 (38.0%)	15 (19.0%)
All	45 (17.8%)	208 (82.2%)	84 (40.4%)	71 (34.1%)	53 (25.5%)
<b>Sport</b>					
Male	24 (24.7%)	73 (75.3%)	43 (58.9%)	12 (16.4%)	18 (24.7%)
Female	1 (9.1%)	10 (90.9%)	7 (70.0%)	2 (20.0%)	1 (10.0%)
All	25 (23.1%)	83 (76.9%)	50 (60.2%)	14 (16.9%)	19 (22.9%)
<b>All patients</b>					
Males	181(24.8%)	548 (75.2%)	250 (46.3%)	135 (26.0%)	163 (27.7%)
Female	68 (24.8%)	206 (75.2%)	99 (45.6%)	61 (24.6%)	46 (29.7%)
All	249(24.8%)	754 (75.2%)	349 (46.3%)	196 (26.0%)	209 (22.3%)

### Additional injuries

Two hundred and thirty-five (23.4%) patients presented with additional injuries other than the clavicle shaft fracture. In the male patients 22.4% sustained additional injuries and 26.3% in the female population. An overview of the additional injuries within each of the mechanism of injury categories is shown in Table 2.4.

Most additional injuries were observed in association with 'road accidents' (overall: 36.6%; male patients: 33.5%; female patients: 44.7%), followed by 'interpersonal violence' (overall: 17.2%; male patients: 18.3%; female patients: 13.8%), a 'fall' (overall: 12.7%; male patients: 16.0%; female patients: 7.3%) and 'sports' injuries (overall: 4.8%; male patients: 4.2%; female patients: 10.0%). The relatively high percentage of additional injuries in the female patient 'sport' category was caused by a small sample size in which 1 of 10 female patients also sustained a hand injury.

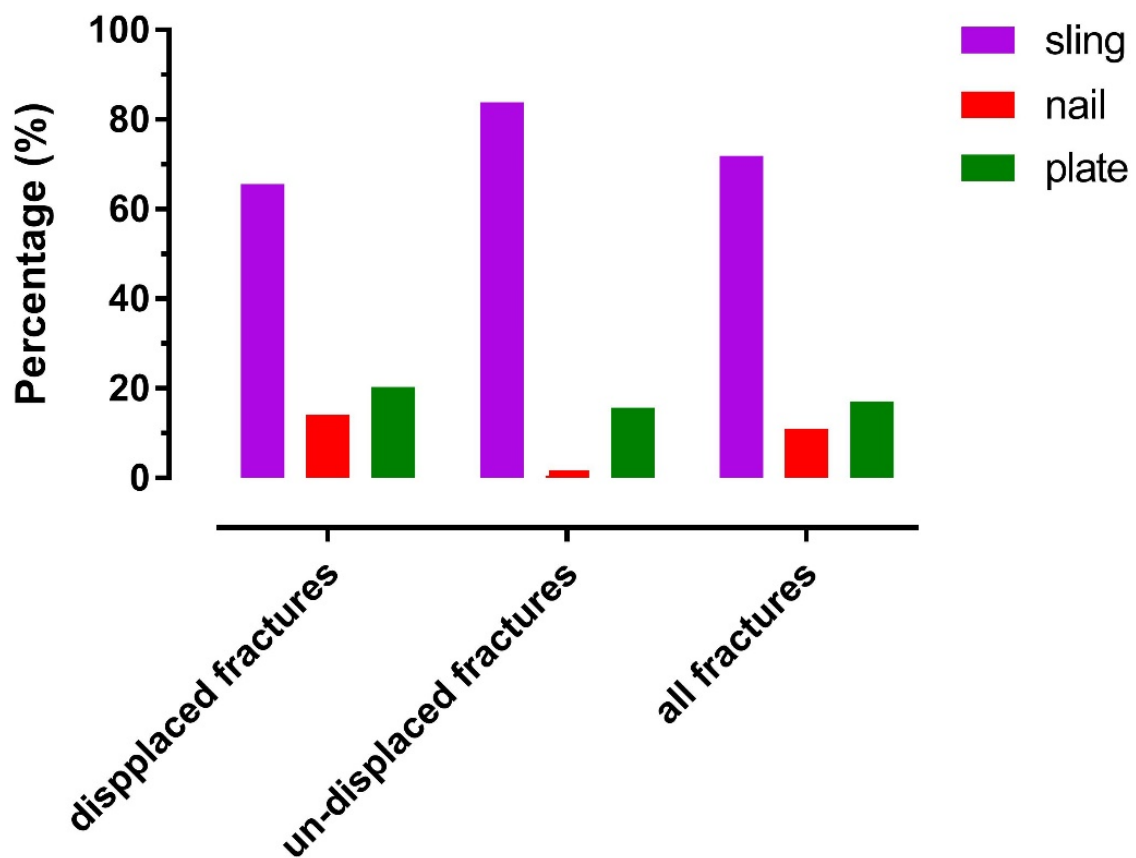
**Table 2.4.** Percentage of additional injuries within each of the mechanism of injuries category and overall.

	Head	Chest	Abdominal	Pelvis	Spine	Rib	Scapula	Humerus	Forearm	Hand	Femur	Tibia	Ankle	Foot
<b>Road accidents</b>														
Male (%)	11.7	11.1	4.6	4.9	5.8	7.4	3.4	2.8	3.4	0.3	4.3	4.3	1.8	0.9
Female (%)	12.2	11.4	8.1	14.6	9.8	10.6	8.1	4.9	1.6	2.4	8.9	7.3		
All (%)	11.8	11.2	5.6	7.6	6.9	8.3	4.7	3.3	2.9	0.9	5.6	5.1	1.3	0.7
<b>Interpersonal violence</b>														
Male (%)	4.3	14.0	1.1	1.1		6.5	2.2		1.1	1.1	1.1	2.2		
Female (%)	6.9		3.4					3.4		6.9		3.4		
All (%)	4.9	10.7	1.6	0.8		4.9	1.6	0.8	0.8	2.5	0.8	2.5		
<b>Fall</b>														
Male (%)	5.5	3.7	1.8	1.2	4.9	4.3	1.8	1.2	1.2	0.6	0.6	1.2	1.2	0.6
Female (%)	5.2	2.1	2.1	1.0	1.0	1.0		1.0	2.1		1.0	1.0		
All (%)	5.4	3.1	1.9	1.2	3.5	3.1	1.2	1.2	1.5	0.4	0.8	1.2	0.8	0.4
<b>Sport</b>														
Male (%)	2.1						1.1							
Female (%)										10.0				
All (%)	1.9						1.0			1.0				
<b>All</b>														
Male (%)	7.5	8.0	2.7	2.9	3.7	5.2	2.3	1.6	2.2	0.4	2.2	2.7	1.1	0.5
Female (%)	8.8	6.9	5.1	7.3	5.1	5.8	4.0	2.9	1.5	2.9	4.4	4.0		
All (%)	7.9	7.7	3.4	4.1	4.1	5.4	2.8	2.0	2.0	1.1	2.8	3.1	0.8	0.4

No color: <1%; Green: 1- 5%; Yellow: >5-10%; Orange: >10 %

## Treatment

The majority of patients were treated conservatively with a sling (overall: 71.9%; male patients: 72.4%; female patients: 70.4%). Only 34.4% of patients with displaced fractures were managed surgically, while 9.2% of the undisplaced clavicle shaft fractures were treated surgically. An overview of the treatment modalities in all patients as well as the male and female patients is shown in Figure 2.3.



**Figure 2.3** Overview of the treatment modalities used to treat displaced, un-displaced fractures

## Chapter 2

---



---

## DISCUSSION

Although numerous epidemiological studies describe clavicle fractures in general<sup>6,13,7,5,2,3</sup>, to our knowledge this is the first study to describe the epidemiology of clavicle shaft fractures in a developing country.

The mean age of patients included in our study was  $33 \pm 13$  years, which is considerably lower, compared to studies done in the developed world. Overall and within the mechanisms of injury: 'road accidents', 'interpersonal violence' and 'falls', male patients were younger than female patients ( $p < 0.05$ ). Up to the age of 50 substantially more males than females sustain clavicle shaft fractures (see also Fig. 2.1). In developed countries, patients with clavicle fractures are generally seen around 2 age peaks, the first and largest peak is seen in male patients around 30 years of age, while a second peak in female patients is generally seen around the age of 80 years<sup>1</sup>. A number of the older patients described in these studies would have sustained lateral third fractures, thus the likely average age for shaft fractures would be slightly lower. It is known that the incidence of shaft fractures decreases with increasing age<sup>7</sup>. However, fractures in the over 60-age group in the population studied is still substantially lower than found in developed countries. Kihlstrom *et al* found 16% of shaft fractures occurred in patients over 65 years. Herteleer *et al.* also found two peaks studying an urban Belgium population, the first in young male athletes and the second in males, 41 to 50 years old. They reported a shift in age from younger patients to more middle aged patients during the period studied<sup>11</sup>. The same was found by Huttenen *et al.* and Kihlstrom *et al.* studying Scandinavian populations<sup>13,6</sup>. Kihlstrom *et al.* reported a mean age at presentation of 48 years<sup>6</sup>.

The current study reflects higher rates of clavicle shaft fractures caused by road accidents and interpersonal violence, (Table 2.2), which is commonly accompanied by additional injuries (Table 2.4). Studies done in developed countries report that the most common mechanisms of injury are related to simple falls, sporting activities and bicycle accidents.<sup>2,4,12,6</sup> Kihlstrom *et al.* reported high-energy mechanisms (road traffic accidents and falls from heights) to cause 35% of shaft fractures<sup>8</sup>, in contrast to 44.7% in our study.

The higher incidence of fractures caused by road accidents and interpersonal violence described in the South African population, compared to those described in developed

countries, ultimately relates to South Africa's high road accident rates and high levels of interpersonal violence<sup>9</sup>. An estimated 1.5 million trauma cases are treated each year in hospitals in South Africa of which half are estimated to relate to violence<sup>9</sup>. Injuries caused 59 935 deaths in the year 2000 (estimated population of 45 million people) of which 46% (27 563) were homicides. Road traffic accidents accounted for 26.7% (16 002) of these injury related deaths<sup>10</sup>. In addition, South Africa has double the global rate of injuries caused by road traffic accidents<sup>10</sup>. Due to these high rates of road accidents and violence, injuries in South Africa are the second leading cause of loss of 'healthy' life, and are accountable for 14.3% of all disabilities<sup>10</sup>. In the year 2000 violence and road traffic accidents combined caused 16.9% of all mortalities<sup>11</sup>.

The gender distribution compares to epidemiological studies done in developed countries. The majority of fractures occur in male patients<sup>3,4,5</sup>. Herteleer *et al.* reported 81% of shaft fractures occurred in males<sup>7</sup>. This correlates to the higher incidence of interpersonal violence and road traffic accidents in the male population<sup>10</sup>. Among military recruits males were found to have double the risk of sustaining a clavicle fracture<sup>14</sup>.

Soft tissue compromise and neurovascular injuries complicate clavicle fractures only on very rare occasions. This is similar to studies done in developed countries. Postacchini showed skin compromise in 0.4% of clavicle fractures and found no neurovascular injuries<sup>3</sup>. Robinson reported no neurovascular injuries in his series<sup>4</sup>. Kilstrom reported an incidence of open fractures of only 0.7%<sup>6</sup>. This is surprising given the subcutaneous location of the clavicle and the anatomical relationship of the clavicle to especially the subclavian artery and vein<sup>15,16</sup>. Skin tethering between fracture ends is rare and no late skin breakdown due to pressure necrosis caused by skin tenting was found. Open clavicle fractures are associated with a higher incidence of neurovascular injury if the fracture is caused by a penetrating mechanism<sup>17</sup>. Open fractures are commonly associated with high energy mechanisms and serious associated injuries<sup>18</sup>.

In line with other studies done, 75% of clavicle shaft fractures in this review were displaced. Kilstrom *et al.* reported midshaft fractures to be displaced in 66% of cases. Herteleer *et al.* found an incidence of displaced fractures of 82% of cases<sup>19</sup>.

The treatment rendered in the displaced fracture group seems to be inadequate if generally accepted indications for surgery are used<sup>1</sup>. A recent meta-analysis has indicated fractures that are completely displaced, shortened and comminuted treated surgically have lower rates of malunion, non-union and higher rates of patient satisfaction<sup>20</sup>. Huttunen *et al.* reported a 705% increase in surgically treated clavicle fractures over a period of 10 years<sup>13</sup>. There has been some concern raised that fractures tend to be over treated in this population.<sup>21</sup> The impact of the apparent under treatment on patient outcome in our population is not known. Patients tend to be discharged early from follow-up following conservative treatment. Few of these patients report back with problems relating to their fracture. During this review only one patient had delayed treatment for a symptomatic nonunion. It is unknown whether these patients have residual non-unions, loss of power or loss of range of movement as a result of the fracture<sup>1, 2, 3</sup>.

It should be taken into account that the institution where the study was done is a referral hospital draining complicated orthopaedic cases from a large area as well as acting as a point of first contact for a smaller demographic area. This leads to a selection bias with higher numbers of displaced fractures seen. Un-displaced fractures are managed on some occasions by the primary health care institution of first contact. A further shortcoming of this study is that data was collected retrospectively and there was reliance on clinical notes made by other clinicians.

An important limitation to this study is that data were collected exclusively in the public health system. South Africa has a parallel health care system providing private health care to between 10 and 20% of South Africans. Patients accessing the private system are generally of a higher socio-economic status than patients presenting for care at Tygerberg Academic Hospital. It is unknown whether these patients have a different epidemiological profile. There are no data available describing patients with clavicle shaft fractures presenting to the private healthcare system. Thus the epidemiological profile described in this study exclusively describes patients presenting to a public, tertiary hospital in an urban setting. It does not describe the epidemiological profile of all patients presenting with clavicle shaft fractures in South Africa.

**Conclusion**

The epidemiological profile of patients with clavicle shaft fractures presenting to a tertiary hospital in South Africa differs from the epidemiology profile described in developed countries. Patients were generally younger than in developed countries. Fractures in middle-aged patients were much less common and patients over 60 years of age rarely presented. In addition, interpersonal violence and road traffic accidents caused a much higher proportion of injuries, with young males most commonly involved. In this study, clavicle fractures were commonly complicated by additional injuries including head injuries, chest injuries and additional fractures.

---

**REFERENCES**

1. Khan L a K, Bradnock TJ, Scott C, Robinson CM. Fractures of the clavicle. *J Bone Joint Surg Am.* 2009;91(2):447-460.
2. Nowak J, Mallmin H, Larsson S. The aetiology and epidemiology of clavicular fractures. A prospective study during a two-year period in Uppsala, Sweden. *Injury.* 2000;31(5):353-358.
3. Postacchini F, Gumina S, De Santis P, Albo F. Epidemiology of clavicle fractures. *J Shoulder Elb Surg.* 2002;11(5):452-456.
4. Robinson CM. Fractures of the clavicle in the adult. Epidemiology and classification. *J Bone Joint Surg Br.* 1998;80(3):476-484.
5. Nordqvist A, Petersson C. The incidence of fractures of the clavicle. *Clin Orthop Relat Res.* 1994;(300):127-132.
6. Kihlström C, Möller M, Lönn K, Wolf O. Clavicle fractures: epidemiology, classification and treatment of 2 422 fractures in the Swedish Fracture Register; an observational study. *BMC Musculoskelet Disord.* 2017;18(1):82.
7. Herteleer M, Winckelmans T, Hoekstra H, Nijs S. Epidemiology of clavicle fractures in a level 1 trauma center in Belgium. *Eur J Trauma Emerg Surg.* 2018;44(5):717-726.
8. Kihlström C, Möller M, Lönn K, Wolf O. Clavicle fractures: epidemiology, classification and treatment of 2 422 fractures in the Swedish Fracture Register; an observational study. *BMC Musculoskelet Disord.* 2017;18(1):82.
9. Matzopoulos RG, Prinsloo M, Butchart A, Peden MM, Lombard CJ. Estimating the South African trauma caseload. *Int J Inj Contr Saf Promot.* 2006;13(1):49-51.
10. Norman R, Matzopoulos R, Groenewald P, Bradshaw D. The high burden of injuries in South Africa. *Bull World Health Organ.* 2007;85(9):695-702. doi:10.2471/blt.06.037184.
11. Bradshaw D, Groenewald P, Laubscher R, *et al.* Initial burden of disease estimates for South Africa, 2000. *S Afr Med J.* 2003;93(9):682-688.
12. Stanley D, Trowbridge EA, Norris SH. The mechanism of clavicular fracture. A clinical and biomechanical analysis. *J Bone Joint Surg Br.* 1988;70(3):461-464.
13. Huttunen TT, Launonen AP, Berg HE, Lepola V, Felländer-Tsai L, Mattila VM. Trends in the Incidence of Clavicle Fractures and Surgical Repair in Sweden: 2001-2012. *J Bone Joint Surg Am.* 2016;98(21):1837-1842.
14. Hsiao MS, Cameron KL, Huh J, *et al.* Clavicle fractures in the United States military: incidence and characteristics. *Mil Med.* 2012;177(8):970-974.
15. Sinha A, Edwin J, Sreeharsha B, Bhalai V, Brownson P. A radiological study to define safe zones for drilling during plating of clavicle fractures. *J Bone Joint Surg Br.* 2011;93(9):1247-1252.
16. Galley IJ, Watts AC, Bain GI. The anatomic relationship of the axillary artery and vein to the clavicle: a cadaveric study. *J Shoulder Elbow Surg.* 18(5):e21-5.
17. Gottschalk HP, Dumont G, Khanani S, Browne RH, Starr AJ. Open clavicle fractures: patterns of trauma and associated injuries. *J Orthop Trauma.* 2012;26(2):107-109.
18. Taitzman LA, Nork SE, Coles CP, Barei DP, Agel J. Open clavicle fractures and associated injuries. *J Orthop Trauma.* 2006;20(6):396-399.
19. Xu C-P, Li X, Cui Z, Diao X-C, Yu B. Should displaced midshaft clavicular fractures be treated surgically? A meta-analysis based on current evidence. *Eur J Orthop Surg*

Chapter 2

---

- Traumatol.* 2013;23(6):621-629.
20. Ban I, Nowak J, Virtanen K, Troelsen A. Overtreatment of displaced midshaft clavicle fractures. *Acta Orthop.* 2016;87(6):541-545.

## THE TREATMENT OF CLAVICLE SHAFT FRACTURES WITH AN INNOVATIVE LOCKED INTRAMEDULLARY DEVICE

The content of this article was published as:

**P.R. King**, A. Ikram, R.P. Lamberts. The treatment of clavicular shaft fractures with an innovative locked intramedullary device. *Journal of Shoulder and Elbow Surgery* 2015;24(1):e1-6

**Impact factor:** 2.9

**Ranking:** #20 of 76 in Orthopedics (ISI Web of Science)

## Chapter 3

---



**ABSTRACT**

**Background:** Displaced and shortened clavicle shaft fractures can be treated by intramedullary fixation; however, hardware migration and soft tissue irritation at the insertion site have complicated its use. The aim of this study was to determine whether this new intramedullary device (Sonoma CRx™) can be used successfully to treat displaced and shortened clavicle shaft fractures and restore the functional capacity of shoulder without the development of secondary complications.

**Methods:** Forty-seven consecutive patients with displaced and shortened clavicle shaft fracture were treated with the CRx™ device. The size of the surgical incision made in order to implant the device as well as the surgical time needed was captured during the surgical procedure. Shoulder function was assessed by Disabilities of the Arm, Shoulder and Hand (DASH) score, the Constant Shoulder score and a Range of Movement score. Patients were assessed either after 3-6 months (Group I), 6-9 months (Group II) or 9-12 months (Group III) post-operatively. Progression to union was determined at the time of follow-up using fracture radiographs assessed by an independent radiologist.

**Results:** All patients had achieved union at the time of review without any incidence of hardware migration. Three patients developed complications post-operatively (infection (1) and hardware failure (2)). No differences between the groups were found for DASH score ( $p=0.33$ ), Constant Shoulder ( $p=0.38$ ) and Range of Movement scores ( $p=0.96$ ). DASH, Constant Shoulder and Range of Movement scores were similar to other successful treatment options, such as plating.

**Conclusion:** The Sonoma CRx™ is a good alternative device to treat displaced and shortened clavicle shaft fractures and restore the functional capacity of the shoulder. Future research should focus on when nailing and plating should be used to treat clavicle shaft fractures most optimally.

**Level of evidence:** Level II, Treatment Study.

**Keywords:** Clavicle; collarbone; fracture; intramedullary nail; fixation; CRx

## Chapter 3

---

## INTRODUCTION

Fracture of the clavicle is a relatively common injury, thought to account for 35% of all shoulder girdle injuries in adults.<sup>13</sup> Shaft fractures comprise 69% of fractures with 48% of these fractures being displaced and 19% comminuted.<sup>18</sup> Treatment options for clavicle fractures include both non-operative and operative approaches, depending on the severity of the injury.<sup>13,19</sup> For example, in the case of any displaced fractures, non-operative treatment in a simple sling has been shown to give excellent results with low complication rates. However, in the case of displaced and shortened fractures, operative treatment results in higher union rates, higher functional outcome scores and fewer complications compared to non-operative treatment.<sup>2,8,23</sup>

Surgical options for these more complicated fractures include extramedullary and intramedullary fixation devices. Extramedullary fixation typically involves a plate and screw construct and may take the form of a fixed angle or a non-fixed angle device. Intramedullary fixation may involve either rigid or flexible devices in the form of rigid screw designs or flexible titanium nails, respectively.<sup>13</sup> Although both extramedullary and intramedullary fixation methods have been demonstrated to be effective treatment modalities,<sup>5,9</sup> each modality is associated with certain concerns. For example, extramedullary fixation can be prominent subcutaneously, which might interfere with certain tasks (e.g. carrying a back-pack).<sup>19,22</sup> Conversely, intramedullary devices have been associated with fixation problems, which can lead to migration of the device and soft tissue irritation due to protruding hardware at the insertion site.<sup>21,22</sup> Hardware failure has been reported in both devices.<sup>17,22</sup> Both extramedullary and intramedullary devices are associated with a relatively high rate of secondary surgical interventions to remove the hardware.<sup>20</sup>

In response to the concerns associated with existing fixation devices, a new intramedullary device for the treatment of displaced and shortened clavicle shaft fractures has recently been introduced.<sup>14</sup> The novelty of this device is that it is flexible at its medial end, which allows it to follow the curvature of the clavicle at its medial end. The device is then activated to become rigid once the desired fracture position is achieved and to deploy grippers at its medial end to lock the device. Laterally, the device is locked with a screw placed through a jig. These design features are intended to prevent the device from migrating and to make the device length and rotationally

stable, thereby reducing the risk of subsequent complications. However, these claims have not yet been confirmed in a controlled research setting. Therefore the main aim of this study was to determine whether this new intramedullary device can be used successfully to treat displaced and shortened clavicle shaft fractures, whilst showing no evidence of migration in the months after surgery. To achieve this research aim, a group of consecutive patients treated with this device in a 12 month period was followed up and assessed for a period ranging from 3 months to 12 months post-operatively.

## **METHODS**

### **Recruitment**

Forty-seven consecutive patients with displaced and shortened clavicle shaft fractures, who were treated with the Sonoma intramedullary device (Sonoma CRx™, Sonoma Orthopedic Products Inc, Santa Rosa, CA, USA), were recruited to participate in this study. All patients were treated by the same surgeon at the same institution (Tygerberg Academic Hospital, Cape Town, South Africa). Before implanting the device and participation in the study, all patients were thoroughly informed about the study and the associated risks, and an informed consent was signed. The study was approved by the Health and Research Ethics committee of the Stellenbosch University (IRB0005239, N11/02/032), and performed in accordance with the principles outlined in the Declaration of Helsinki.

### **Study Design**

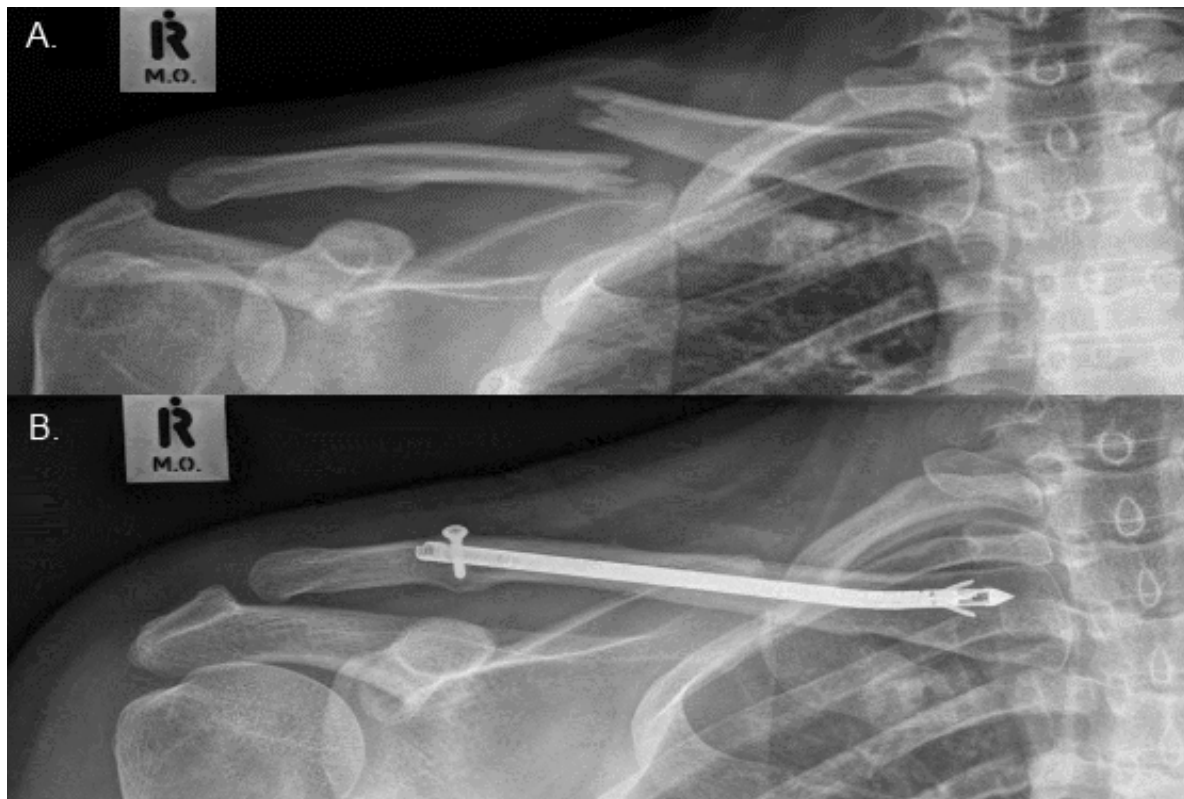
All patients who participated in the study were diagnosed with a displaced and shortened clavicle shaft fracture and were treated surgically using an innovative intramedullary device (Sonoma CRx™, Sonoma Orthopedic Products Inc, 3589 Westwind Boulevard Santa Rosa, CA 95403) over a 12 month period. Patients in both groups were treated within 7 days of the injury after which the shoulder was immobilized for a period of six weeks in a shoulder immobilizer. During this period, patients were asked to remove the immobilizer six times a day and perform anti-gravity pendular exercises of the shoulder and range of movement exercises of the ipsilateral elbow. Six weeks post-surgery, patients were allowed to remove the immobilizer and return to normal activities of the shoulder. No physiotherapy guided exercise program for the shoulder was provided.

For the study patients returned to the hospital on one occasion, which was planned between 3- and 12-months post-surgery. Based on the time period between the surgery and the follow-up assessment, subjects were retrospectively categorized as 3 to 6 months post-operative (Group I), 6-9 months post-operative (Group II) or 9-12 months post-operative (Group III).

The range of follow-up times was used to provide insight into healing capacity (union rate) with the use of the new device and when possible complications with the device may tend to occur. In addition, the range of follow-up periods was intended to provide insight into how quickly functional shoulder capacity tends to be restored. During the assessment visit, standard anterior-posterior and 15° cephalad tilt radiographs were obtained. These were reviewed by an independent radiologist for union, loss of fixation and hardware migration. Furthermore, a physical examination was used to determine whether there was any migrated or protruding hardware causing soft tissue irritation. The functional capacity of the shoulder was assessed using the Disabilities of the Arm, Shoulder and Hand (DASH) score and Constant Shoulder Score.<sup>3,10</sup> Range of movement of the affected shoulder was determined and scored using the range of movement section of the Constant Shoulder Score ranging from 0 to 40.<sup>3</sup> Flexion, abduction, internal and external rotation were each graded out of 10 and scored accordingly. The Constant shoulder score and range of movement were determined by an independent physical therapist, while the DASH score questionnaire was completed during a visit to an independent occupational therapist.

### **Device description**

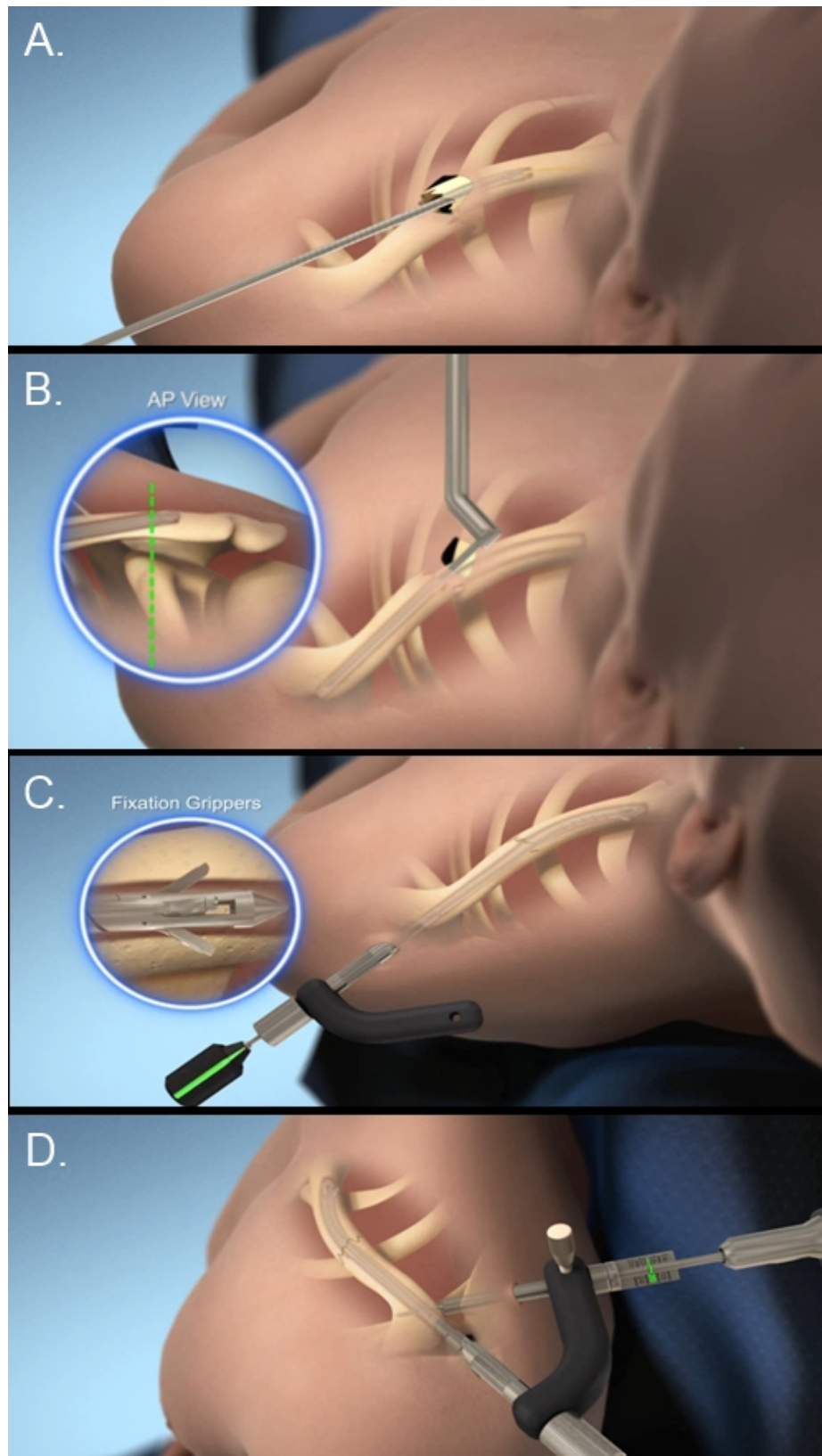
The Sonoma Clavicle fracture repair (CRx) system is an innovative device that transforms from a flexible intramedullary device at insertion into a rigid fixation system after placement inside the clavicle bone. The stainless-steel device consists of a solid straight hub, a flexible tubular medial section, and an internal fixation system (Fig. 3.1). The device is inserted into the medullary canal following reduction of the fracture. The medial flexible portion of the device follows the axial and coronal curvature of the clavicle. Once the device has been properly seated in the medullary canal and accurate fracture reduction has been achieved, the internal WaviBody™ assembly is activated. Upon activation, the flexible section is transformed into a rigid nail and grippers at the medial end are deployed. The grippers lock the medial end of the device providing rotational and axial stability. Laterally, the device is locked with an interlocking screw.



**Figure 3.1.** X-rays of the same patient, pre-operative (A.) and 6 months post-operative (B.).

### **Surgical technique**


Patients were given 2g of intravenous cefazolin pre-operative and a general anaesthetic. The patient was positioned in the beach chair position, prepped and draped. An incision was made over the fracture site and the medial and lateral fragments were identified, while taking care that minimal soft tissue was stripped off the clavicle and comminuted fragments. The medullary canal of the medial fragment was opened with a 3mm awl and then reamed manually with a 4.5mm awl. The surgeon aimed to prepare the canal as far medially as possible in order to allow for implantation of the longest possible implant (Fig. 3.2<sup>A</sup>).



**Figure 3.2** Schematic overview of the surgical procedure. **A.** reaming out the medial part of the clavicle. **B.** Opening the lateral part of the clavicle over the guidewire. **C.** Inserting the Sonoma CRx™ intramedullary nail as far medial as possible and activating the grippers distally. **D.** Locking the Sonoma CRx™ intramedullary nail laterally with the use of an interlocking screw.



Furthermore, the surgeon aimed to pass the medial end of the device as far past the fracture site as possible. It was intended that the medial end of the device should be placed at least 50 mm past the fracture site and the same approach was applied in preparing the lateral fragment. An aiming device was passed into the lateral fragment and a guidewire was passed from medially to exit the clavicle at the apex of the posterior curvature of the clavicle. The guidewire was passed posterior to the acromioclavicular joint to exit the skin laterally. The lateral end of the clavicle was then opened with a cannulated drill over the guidewire (Fig. 3.2<sup>B</sup>). A flexible guidewire was inserted in a retrograde manner through the cannulated drill to exit laterally. The fracture was reduced and held in position while the guidewire was passed over the fracture into the medial fragment. The canal was then reamed under power with a flexible reamer from lateral to medial. The length of implant required was measured by passing a length gauge over the reamer when it was at its most medial position past the fracture. An insertion guide was placed into the lateral end of the clavicle over the guidewire prior to its removal. The intramedullary nail was connected to the locking jig and inserted into the lateral aspect of the clavicle over the insertion guide. The device was passed over the fracture into the medial end of the clavicle. Once the desired position of the device was confirmed, the grippers were activated from distally (Fig. 3.2<sup>C</sup>). Laterally, the device was locked by placing an interlocking screw by means of a jig (Fig. 3.2<sup>D</sup>). Adjuvant fixation of the butterfly segments were performed using circlage sutures while avoiding periosteal stripping.



**Figure 3.2** Sonoma CRx Device

**Statistical analysis**

The data was analyzed with STATISTICA version 12 (Stat-soft Incl., Tulsa, OK USA) with statistical significance accepted at  $p < 0.05$ . All data are expressed as mean  $\pm$  standard deviation ( $X \pm s$ ). A Levene test was used to test the homogeneity of variances for the descriptive data, surgical time and incision size to warrant the use of parametric statistics. A one-way analyses of variance (ANOVA), was also used to determine any differences in general characteristics between groups, I (3-9 months postoperatively), II (6-9 months postoperatively) and III (9-12 months postoperatively). A one-way ANOVA was also used to determine any differences in shortening and displacement of the clavicle, surgical time and incision size between the three groups. Functional capacity of the shoulder measured by the DASH, Range of Motion and Constant Shoulder score, which were analyzed with a Kruskal–Wallis one-way analysis of variance. Significance was accepted at  $p < 0.05$

## RESULTS

Following implantation of the intramedullary device, 3 patients developed post-operative complications. One patient developed a deep infection, which resulted in the removal of the implant, at which time the fracture was partially united and no further surgical treatment was indicated. The infection was successfully treated with intravenous antibiotics. Two other patients were diagnosed with broken hardware. Both these failures occurred at the junction of the flexible and non-flexible portion of the implant. One of these patients had a second trauma incident 1-month post-operative, but did not seek medical attention, as the clavicle bone did not look displaced. The other patient resumed his occupation as a manual construction worker at a building site 1 week post-operatively. Although the behavior of both patients might have contributed to failure of the device, the device in both cases was also not inserted far enough into the medial fragment of the clavicle. However, the clavicle fractures in all three subjects united in a functional and acceptable position.

The descriptive statistics of the forty-seven patients, who had a shortened and displaced clavicle shaft fracture treated with the Sonoma CRx™ intramedullary nail, are shown in Table 3.1. No difference in age, gender and type of clavicle shaft fracture (configuration and amount of comminution) was found between the 3 groups. The mean follow-up time was  $18 \pm 4$  weeks for group I (range: 14-23 weeks),  $29 \pm 4$  weeks for group II (range: 24-36 weeks) and  $44 \pm 4$  weeks for group III (range: 37-52 weeks).

**Table 3.1.** General characteristics of the patients (mean  $\pm$  SD (range))

	3-6 months post-op (n = 17)	6-9 months post op (n = 16)	9-12 months post op. (n = 14)	All patients (n=47)
Age (years)	$29 \pm 14$	$34 \pm 10$	$26 \pm 9$	$30 \pm 11$
Males/females	10 / 7	12 / 4	10 / 4	32 / 15
Fractures types <sup>14</sup>				
Simple	9 (53%)	4 (25%)	4 (28.5%)	17 (36%)
Single fragment	5 (29%)	5 (31%)	4 (28.5%)	14 (30%)
Multiple fragments	3 (18%)	7 (44%)	6 (43%)	16 (34%)
Coronal displacement (mm) *	$19 \pm 10$ (5 - 45)	$22 \pm 9$ (5 - 36)	$18 \pm 9$ (5 - 36)	$19 \pm 9$ (5 - 45)
Shortening (mm) **	$15 \pm 11$ (0 - 35)	$16 \pm 12$ (0 - 33)	$22 \pm 11$ (5 - 44)	$17 \pm 11$ (0 - 44)

\* Average coronal displacement of the lateral portion of the clavicle in relation to the medial portion of the clavicle

\*\* Shortening of the fractured clavicle. Post-op: post operatively.

All fractures were fully united at the time of review, while no radiographic evidence of hardware migration was found. Visual and tactile examination did not reveal any protrusion of the Sonoma CRx™ device into the soft tissue or skin of the lateral shoulder. The functional outcome scores of the affected shoulders are shown in Table 3.2. No differences in Range of Movement Scores ( $p = 0.961$ ), Constant Shoulder Scores ( $p = 0.389$ ) and Dash scores ( $p = 0.332$ ) were found between patients in the 3 different follow-up groups.

**Table 3.2.** Surgical details, follow-up period and functional outcome after implanting a novel intramedullary device for the treatment of clavicle shaft fractures (mean  $\pm$  SD (range)).

	<b>3-6 months post-op. (n = 17)</b>	<b>6-9 months post op. (n = 16)</b>	<b>9-12 months post op. (n = 14)</b>	<b>All patients (n=47)</b>
Surgical time(min)	80 $\pm$ 19 (45 - 110)	71 $\pm$ 14 (50 - 90)	70 $\pm$ 14 (45 - 90)	74 $\pm$ 16 (45 - 110)
Incision size (mm)	47 $\pm$ 12 (30 - 65)	44 $\pm$ 15 (25 - 85)	56 $\pm$ 21 (35 - 100)	49 $\pm$ 17 (25 - 100)
Dash Score	15 $\pm$ 19 (0 - 58)	11 $\pm$ 7 (0 - 63)	8 $\pm$ 18 (0 - 70)	11 $\pm$ 18 (0 - 70)
Range of Movement score	36 $\pm$ 9 (12 - 40)	37 $\pm$ 8 (8 - 40)	38 $\pm$ 3 (28 - 40)	37 $\pm$ 8 (8 - 40)
Constant Shoulder Score	89 $\pm$ 13 (58 - 100)	87 $\pm$ 17 (47 - 100)	93 $\pm$ 10 (70 - 100)	90 $\pm$ 13 (47 - 100)

---

## DISCUSSION

Forty-seven patients with displaced and shortened clavicle shaft fractures were treated with an innovative intramedullary fixation device, also known as the Sonoma CRx™. The mean operation time to implant the device was  $74 \pm 16$  min, with a range from 45 to 110 minutes. The mean incision length was  $49 \pm 17$  mm, which is substantially less than the incision size needed to plate clavicle shaft fractures (80 to 100 mm).<sup>1,7,16</sup> However this difference can be explained by the design of the intramedullary device, which is fixed medially by distally activated grippers and laterally by one screw placed through a jig. This necessitates only opening the fracture site itself. No signs of migration of the new intramedullary device were found at the time of the follow up consult, while visual inspection and a physical examination did not reveal any protrusion of the CRx™ device into the surrounding soft tissue or skin.

Three patients developed complications after implantation of the device, which is comparable to the complication rates reported in studies using other extramedullary and intramedullary clavicle fixation devices.<sup>2,6,15</sup> Two of our patients (4%), who started loading the shoulder excessively directly after surgery, reported to the hospital with hardware failures, while one patient (2%) developed an infection post-operatively. In the latter case, the device was removed while in the other 2 cases follow-up x-rays showed that the CRx™ devices were also not inserted far enough medially into the medial fragment to bridge the fracture site adequately, which might have contributed to the malfunctioning of the device. The hardware was left in situ in these two cases as signs of fracture union were observed at the time of presentation with the complication. The fractures united uneventfully despite the hardware failure with no further interventions required. In line with our findings, Palmer *et al.* also reported hardware failures of the CRx™ device, one a patient who was diving to catch a Frisbee and one in a patient who fell of his motorbike.<sup>17</sup> No hardware failures were found in our remaining 44 patients, who anecdotally also reported to have fallen on several occasions. This suggests that potentially other underlying factors, such as biological factors and technical mistakes, might play a role in the malfunctioning of the device.

All fractures were fully united at the follow-up visit irrespective of whether the patient was seen 3-6, 6-9 or 9-12 months post-operatively. Although we cannot conclude that fractures were fully united within a certain timeframe, the results within group I

suggests that it can be reasonably expected that the fracture will unite within 6 months. However, a longitudinal study with a larger sample size is needed to determine the exact timeframe at which clavicle shaft fractures generally unite when using the CRx™ device.

The functional capacity of the shoulder post-operatively was measured with the range of motion division of the Constant Shoulder Score, the Constant Shoulder Score and the DASH score.<sup>3,10</sup> DASH and Constant Shoulder scores observed 3-6 months post-operatively were similar to the values found in patients 6- 9 months and 9 -12 months and comparable to the norms published by Katolik *et al.*,<sup>12</sup> the work by Jester *et al.*<sup>11</sup> and Wijdicks *et al.*<sup>4</sup> and what has been reported when using other intramedullary and extramedullary devices.<sup>2, 9</sup>

Patients in both groups were immobilized for 6 weeks. This period is slightly longer than the typical immobilization period for plated patients. Despite this prolonged immobilization period the shoulder range of movement recovered to normal at an early stage.

The main limitation of the current study design is that patients were followed up longitudinally, so that effects over time can be made. As the CRx™ device was not compared to a traditional plating technique, no conclusion can be drawn whether nailing or plating of clavicle shaft fractures is more effective. The current study and the literature suggest that both nailing and plating seem to be associated with complications. However, complications in both these devices are frequently caused by underlying biological factors and/or technical implantation mistakes causing the device to malfunction. Future research should aim to conduct a randomized control trial to establish which method can be best used to treat displaced and shortened clavicle shaft fractures.

## **Conclusion**

This study shows that the CRx™ intramedullary device was able to successfully treat displaced and shortened clavicle shaft fractures, resulting in a 100% union rate. Good functional outcome scores and range of movement of the affected shoulders were found. Future research should aim to establish if the CRx™ intramedullary device is

## Chapter 3

---

more effective than traditional plating and when which device can best be used to treat patients with displaced and shortened clavicle shaft fractures.

## Chapter 3

---



---

**REFERENCES**

1. Assobhi JEH. Reconstruction plate versus minimal invasive retrograde titanium elastic nail fixation for displaced midclavicular fractures. *J. Orthop. Traumatol.* 2011;12(4):185–192.
2. Canadian Orthopaedic Trauma Society. Nonoperative treatment compared with plate fixation of displaced midshaft clavicular fractures. A multicenter, randomized clinical trial. *J. Bone Joint Surg. Am.* 2007;89(1):1–10.
3. Constant CR, Murley AH. A clinical method of functional assessment of the shoulder. *Clin. Orthop. Relat. Res.* 1987;214:160–164.
4. De Smet L. The DASH questionnaire and score in the evaluation of hand and wrist disorders. *Acta Orthop. Belg.* 2008;74(5):575–581.
5. Duan X, Zhong G, Cen S, Huang F, Xiang Z. Plating versus intramedullary pin or conservative treatment for midshaft fracture of clavicle: a meta-analysis of randomized controlled trials. *J. Shoulder Elbow Surg.* 2011;20(6):1008–1015.
6. Ferran N a, Hodgson P, Vannet N, Williams R, Evans RO. Locked intramedullary fixation vs plating for displaced and shortened mid-shaft clavicle fractures: a randomized clinical trial. *J. Shoulder Elbow Surg.* 2010 Sep;19(6):783–789.
7. Fu T-H, Tan B-L, Liu H-C, Wang J-W. Anatomical reduction for treatment of displaced midshaft clavicular fractures: Knowles pinning vs. reconstruction plating. *Orthopedics.* 2012;35(1):e23–30.
8. Hill JM, McGuire MH, Crosby LA. Closed treatment of displaced middle-third fractures of the clavicle gives poor results. *J. Bone Joint Surg. Br.* 1997 Jul;79(4):537–539.
9. Houwert RM, Wijdicks F-J, Steins Bisschop C, Verleisdonk E-J, Kruyt M. Plate fixation versus intramedullary fixation for displaced mid-shaft clavicle fractures: a systematic review. *Int. Orthop.* 2012;36(3):579–585.
10. Hudak PL, Amadio PC, Bombardier C. Development of an upper extremity outcome measure: the DASH (disabilities of the arm, shoulder and hand) [corrected]. The Upper Extremity Collaborative Group (UECG). *Am. J. Ind. Med.* 1996;29(6):602–608.
11. Jester A, Harth A, Rauch J, Germann G. DASH data of non-clinical versus clinical groups of persons—a comparative study of T-norms for clinical use. *Handchir Mikrochir Plast Chir* 2010;42:55-64.
12. Katolik LI, Romeo A a, Cole BJ, Verma NN, Hayden JK, Bach BR. Normalization of the Constant score. *J. Shoulder Elbow Surg.* 2005;14(3):279–285.
13. Khan L a K, Bradnock TJ, Scott C, Robinson CM. Fractures of the clavicle. *J. Bone Joint Surg. Am.* 2009;91(2):447–460.
14. King PR. Intramedullary locked fixation of clavicle shaft fractures – review of early results. *South African Orthop. J.* 2011;10(4):67–74.
15. Lee Y-S, Huang H-L, Lo T-Y, Hsieh Y-F, Huang C-R. Surgical treatment of midclavicular fractures: a prospective comparison of Knowles pinning and plate fixation. *Int. Orthop.* 2008;32(4):541–545.
16. Liu H-H, Chang C-H, Chia W-T, Chen C-H, Tarng Y-W, Wong C-Y. Comparison of plates versus intramedullary nails for fixation of displaced midshaft clavicular fractures. *J. Trauma.* 2010;69(6):E82–87.

17. Palmer DK, Husain A, Phipatanakul WP, Wongworawat MD. Failure of a new intramedullary device in fixation of clavicle fractures: a report of two cases and review of the literature. *J. Shoulder Elbow Surg.* 2011;20(4):e1–4.
18. Postacchini F, Gumina S, De Santis P, Albo F. Epidemiology of clavicle fractures. *J. Shoulder Elb. Surg.* 2002;11(5):452–456.
19. Van Der Meijden OA, Gaskill TR, Millett PJ. Treatment of clavicle fractures: current concepts review. *J. Shoulder Elbow Surg.* 2012;21(3):423–429.
20. Wijdicks F-J, Houwert M, Dijkgraaf M, de Lange D, Oosterhuis K, Clevers G, *et al.* Complications after plate fixation and elastic stable intramedullary nailing of dislocated midshaft clavicle fractures: a retrospective comparison. *Int. Orthop.* 2012 ;36(10):2139–2145.
21. Wijdicks F-JG, Houwert RM, Millett PJ, Verleisdonk EJJM, Van der Meijden OAJ. Systematic review of complications after intramedullary fixation for displaced midshaft clavicle fractures. *Can. J. Surg.* 2013;56(1):58–64.
22. Wijdicks F-JG, Van der Meijden OAJ, Millett PJ, Verleisdonk EJMM, Houwert RM. Systematic review of the complications of plate fixation of clavicle fractures. *Arch. Orthop. Trauma Surg.* 2012;132(5):617–625.
23. Zlowodzki M, Zelle BA, Cole PA, Jeray K, McKee MD. Treatment of acute midshaft clavicle fractures: systematic review of 2144 fractures: on behalf of the Evidence-Based Orthopaedic Trauma Working Group. *J. Orthop. Trauma.* 2005;19(7):504–507.

## A NOVEL INTRAMEDULLARY LOCKED FIXATION DEVICE FOR TREATMENT OF CLAVICLE SHAFT FRACTURES

The content of this article was published as:

**P.R. King**, C.J. Basamania, R.P. Lamberts. Implantation of an innovative intramedullary locked fixation device for the treatment of clavicle shaft fractures. *Journal of Bone and Joint Surgery Am – Essential Surgical Techniques* 2016;6(1):e8(1-11)

**Impact factor:** New PubMed cited journal which does not have an impact factor yet, however the journal is a sub-component of *Journal of Bone and Joint Surgery Am* (4.7)

**Ranking:** #4 of 76 in Orthopedics (ISI Web of Science)

## Chapter 4

---

## INTRODUCTION

An intramedullary nail (the Sonoma CRx) with a unique flexible anatomical design and locking system is a viable alternative for treatment of displaced and shortened clavicle shaft fractures. Displaced and shortened clavicle shaft fractures may be considered for surgical fixation to restore the anatomy and functional capacity of the shoulder. This can be achieved by using an anatomically contoured plate (extramedullary fixation) or an intramedullary nail. Recently, an innovative intramedullary nail, with a novel flexible anatomical design and unique locking system, was developed to treat clavicle shaft fractures.

Clavicle fractures are relatively common<sup>1-3</sup> in young, physically active individuals<sup>4</sup>. Minimally displaced fractures are generally treated conservatively, with excellent results. In contrast, conservative treatment of displaced and shortened fractures has been followed by nonunion and malunion rates as high as 15%, with their associated morbidity.<sup>5,6</sup> On the basis of these findings, the management of displaced and shortened clavicle shaft fractures has evolved over the past two decades from purely supportive to a more invasive surgical approach<sup>7,8</sup>. The different treatment options for displaced and shortened clavicle shaft fractures can be categorized as extramedullary and intramedullary. Although both modalities are effective, each is associated with different complications and limitations. Patients treated with the extramedullary technique can have a prominent painful subcutaneous plate and screws,<sup>9,10</sup> whereas intramedullary devices can migrate and there can be soft-tissue irritation at their insertion site<sup>11-13</sup>; device failure has been reported with both techniques.<sup>10,14</sup> Potential advantages of intramedullary nailing are smaller surgical scars and thus potentially better cosmetic results as well as the possibility of preserving the vascularity to the bone.

Recently Sonoma Orthopedic Products, Inc., developed an innovative intramedullary device called the Sonoma CRx. This intramedullary nail is unique because of its flexible anatomical design (of the medial part of the nail) and locking system. The aim is to restore the anatomy of the clavicle bone through a minimally invasive technique, with the goal of preserving the blood supply to the clavicle bone and minimizing scarring. While a study comparing the Sonoma CRx nail with a traditional anatomically contoured plate has yet to be completed,<sup>15</sup> a preliminary study showed the Sonoma

CRx to be a viable alternative for the treatment of displaced and shortened clavicle shaft fractures and restoration of the functional capacity of the shoulder.<sup>16</sup>

A patient who is to be treated with the Sonoma CRx intramedullary nail is positioned in the beach-chair position after administration of a general anesthetic. After the fracture site is opened, the medial and lateral fragments of the clavicle bone are prepared for the insertion of the intramedullary nail. An introduction point in the lateral fragment is created before the nail is inserted from the lateral side and passed as far as possible into the medial side of the clavicle; this is possible because of the flexible design of the device. Although the Sonoma CRx intramedullary nail is currently available in only one diameter (4.2mm), a previous anatomical study by one of us and colleagues<sup>17</sup> showed that the nail can be implanted in the vast majority of patients. After the nail is positioned, the locking system is activated, transforming the flexible part of the device into a rigid one. In addition, a locking screw is placed on the lateral side of the clavicle; this provides length and rotational stability as well as prevents the device from migrating. A detailed description of the steps of the surgical technique is presented below.

## **SURGICAL TECHNIQUE**

### **Indications and contraindications**

#### ***Indications***

Displaced and shortened clavicle shaft fracture requiring surgical intervention to restore the anatomy of the clavicle bone.

Open clavicle shaft fracture.

Clavicle shaft fracture in a polytraumatized patient.

#### ***Contraindications***

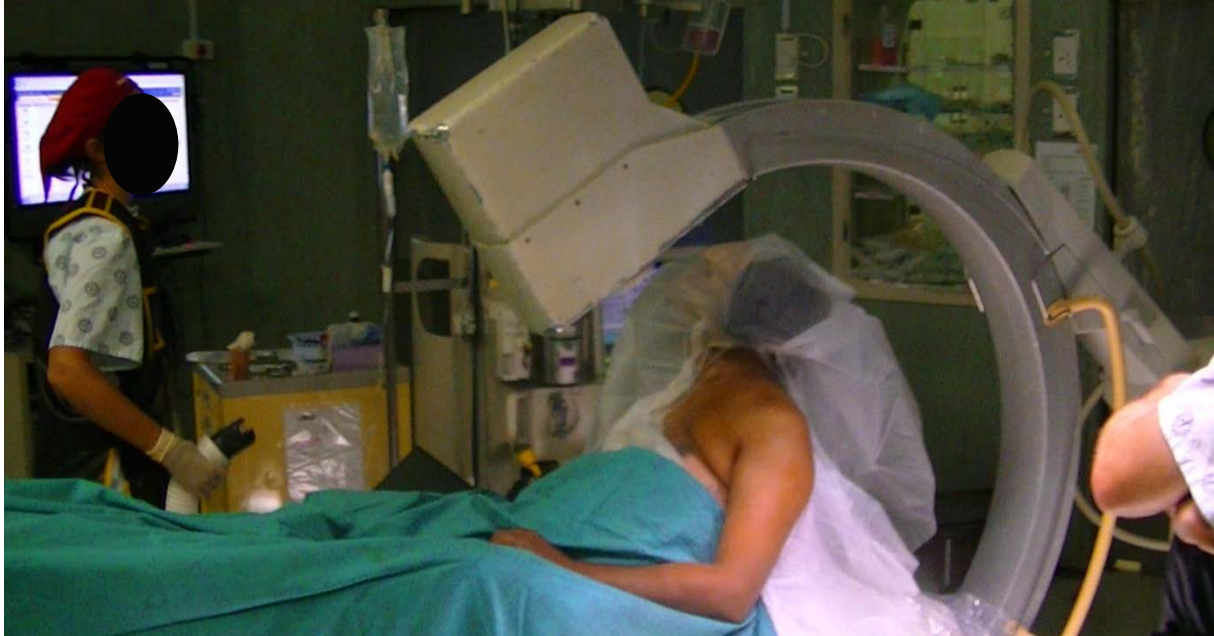Clavicle shaft fracture extending to within 50 mm of the medial end of the clavicle bone.

Clavicle shaft fracture extending lateral to the coracoid process or conoid tubercle.

A medullary canal that is too small to accommodate the 4.2-mm-diameter nail<sup>17</sup>.

### Step 1: Positioning

Place the patient in the beach-chair position (Fig. 4.1) and drape the arm free so that you can obtain an exaggerated anteroposterior and an axial fluoroscopic view of the clavicle by manipulating the position of the arm.



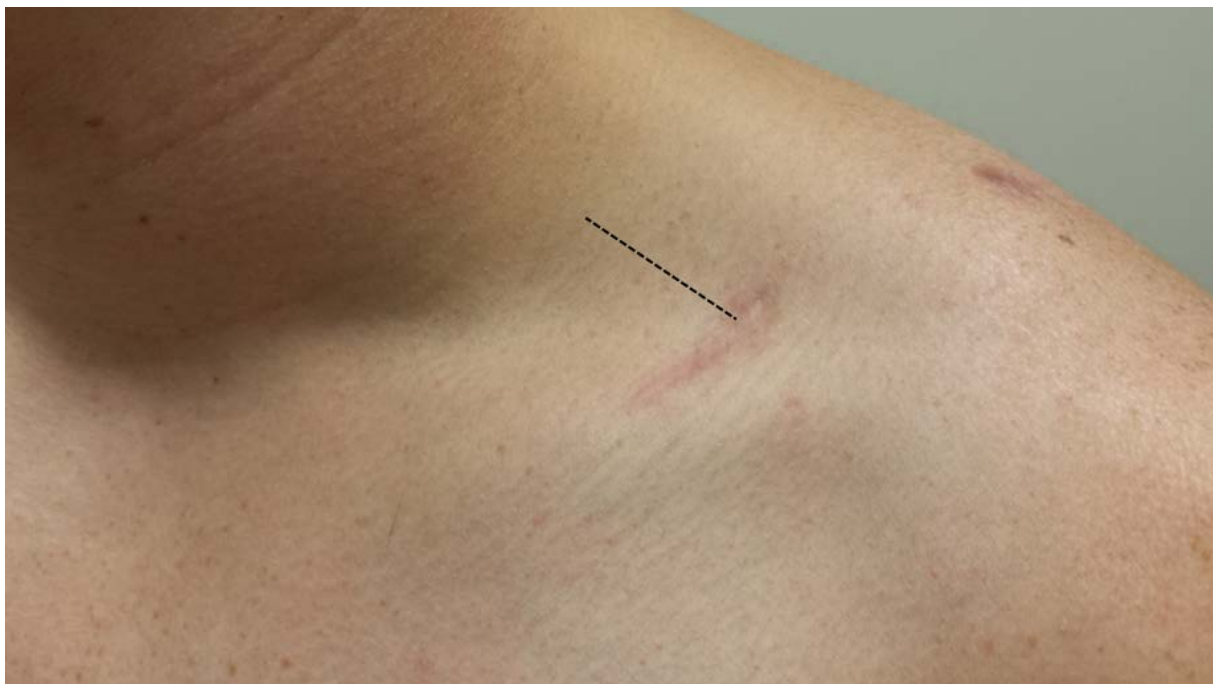**Figure. 4.1.** The patient is placed in the beach-chair position.

- Place the patient in the beach-chair position with the upper body 45° to the horizontal and the head and neck secured in a neutral position.
- Drape the arm on the fractured side free, so that you can flex and extend the shoulder. This will allow you to position the clavicle in such a way that an exaggerated anteroposterior (almost caudal tilt) view and axial view of the clavicle can be captured with fluoroscopy.
- Place the fluoroscopy machine in line with the patient, with the C-arm over the patient's shoulder and fractured clavicle. Because you can flex and extend the patient's shoulder, the position of the C-arm does not have to be changed during the surgical intervention.
- Infiltrate the surgical incision site with a mixture of epinephrine and local anesthetic to reduce bleeding at the incision site. (We used 1 mL of a 0.1 mg/mL solution of epinephrine mixed with 5 mL 0.5% Marcaine [bupivacaine] solution.)
- Drape the arm and fractured clavicle sterilely in such a way that allows access to the surgical area as well as manipulation of the arm.

## Step 2: Skin Incision

The surgical technique necessitates opening the fracture site in order to implant the device.

- Create an incision of about 20 to 30 mm from the tip of the medial fragment and extend it laterally. The length of the incision is dictated by the fracture configuration and amount of comminution at the fracture site, but keep the incision as short as possible.
- Alternatively, an oblique incision can be made along the Langer lines over the distal tip of the medial fragment. If the incision needs to be extended medially or laterally, the incision can be “z’ed” by extending the inferomedial aspect of the incision medially and the superolateral aspect laterally. The primary advantage of the oblique incision is that it tends to heal quite well cosmetically since it does not cross the Langer lines (Fig. 4.2).



**Figure 4.2** Image of a left shoulder and clavicle after treatment with the intramedullary nail. The scar shows the location of the transverse incision over the fracture, while the dotted line indicates the location of an alternative longitudinal incision.

- Identify and preserve the branches of the supraclavicular nerves.
- Try to avoid stripping off the periosteum from the medial and lateral clavicle fragments.



- The incision should allow you access to the less mobile lateral clavicle fragment, which is secured by the coracoclavicular ligaments, and the more mobile medial fragment.

### **Step 3: Preparing the Medial Fragment**

The preparation of the medial fragment is of utmost importance as the intramedullary Sonoma CRx nail should be placed as far as possible into the medial fragment of the clavicle, to provide the highest level of stability and the lowest risk of device failure.

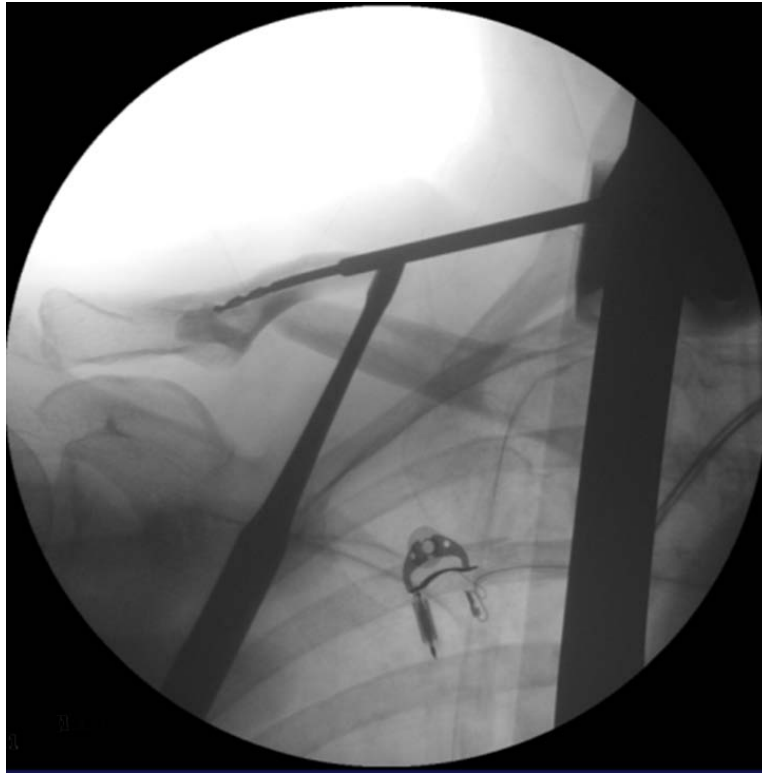
- Locate the medial fragment of the clavicle bone and manoeuvre the fragment to enable easy access to the medullary canal. The lateral end of the medial fragment can be grasped with a towel clip to elevate it into the incision. Placement of a Key elevator under the medial fragment decreases the likelihood of the drill or awl skiving off and going deep to the medial fragment, potentially causing damage to the underlying neurovascular structures.
- Open the medial medullary canal with a 3-mm curved awl. If needed, use a 2-mm drill to open the initial 1 cm of the medial medullary canal ([Video 1 \(https://journals.lww.com/jbjsesst/Fulltext/2016/06010/A\\_Novel\\_Intramedullary\\_Locked\\_Fixation\\_Device\\_for.8.aspx\)](https://journals.lww.com/jbjsesst/Fulltext/2016/06010/A_Novel_Intramedullary_Locked_Fixation_Device_for.8.aspx)). Ensure that the awl penetrates only the medullary canal and does not pass behind the clavicle bone, as this could damage neurovascular structures.
- After opening the medullary canal with the awl, gently enlarge the entry point by sliding the sharp point of the awl against the superior roof of the medullary canal. It is very important that the awl be passed with a slight oscillating movement because turning the awl in too much will cause the path through the canal to be oblong rather than round.
- Ream the medullary canal with a 4.5-mm blunt reaming awl that is curved to follow the curvature of the clavicle bone in the axial plane ([Video 1](#)). Prepare the medial fragment canal as deeply as possible—at least 50 mm past the fracture site.

- Keep fluoroscopy times to the bare minimum during the surgical procedure. (Note that the fluoroscopy times used in [video 1](#) were for the purposes of demonstrating the technique and are longer than would be used normally.)

#### **Step 4: Preparing the Lateral Fragment**

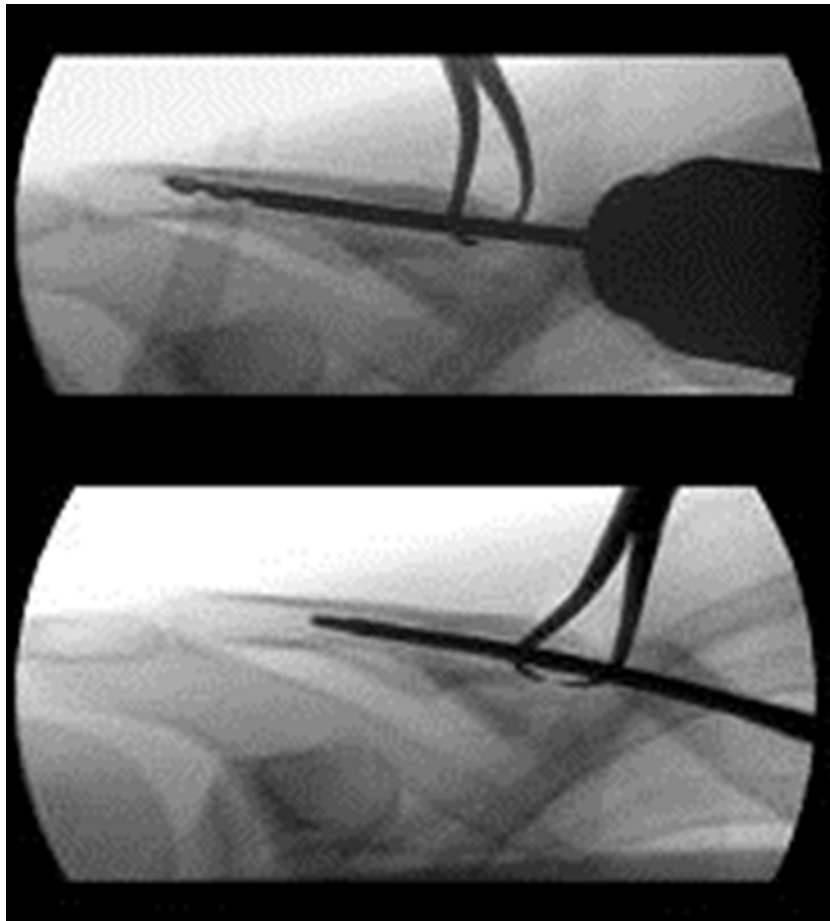
Preparation of the lateral fragment is more challenging than preparation of the medial fragment because of its relative immobility and shorter medullary canal.

- Locate the lateral fragment of the clavicle bone and manoeuvre the fragment to enable access to the medullary canal. Although good exposure is preferred, do not violate the coracoclavicular ligaments on the inferior border of the lateral third of the clavicle during this procedure. If it is too difficult to access the canal because of the patient's head and neck, externally rotate the involved arm to bring the fragment into more of an anterior-posterior orientation rather than a medial-lateral orientation.
- Open the medullary canal again with a straight, sharp 3-mm awl. Alternatively, a 2-mm drill-bit can be passed to check the orientation of the lateral canal (Fig. 4.3, [Video 2](#)). By flexing and extending the shoulder you can obtain an "anteroposterior" and an "axillary" equivalent fluoroscopic image. The trajectory of the drill-bit on the axillary view should be to a midpoint on the posterolateral cortex of the clavicle halfway between the conoid tubercle and the acromioclavicular joint.



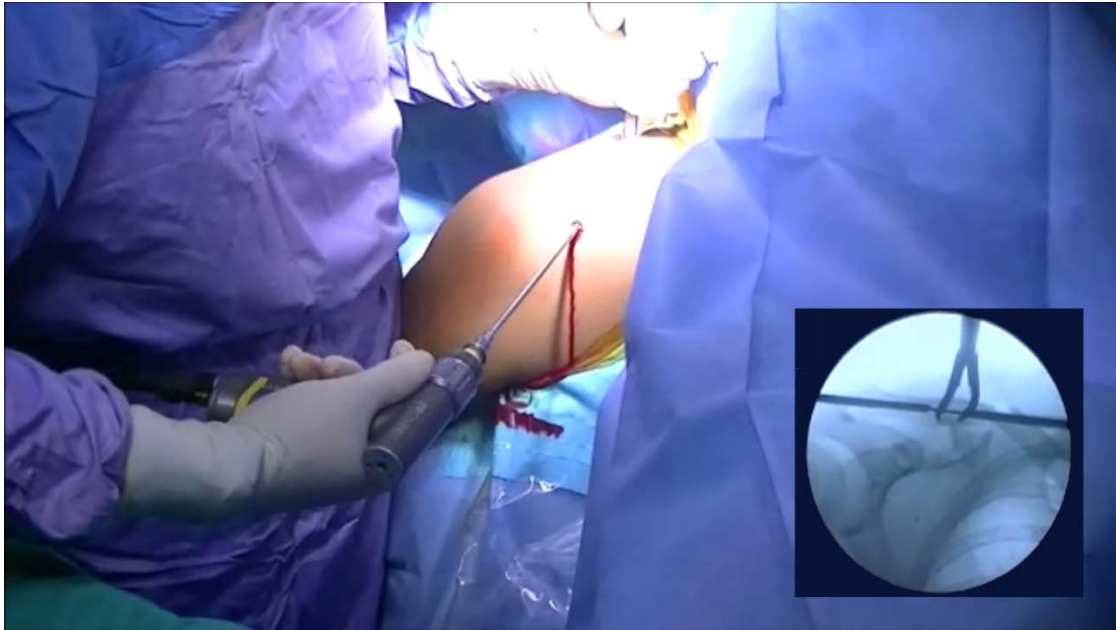
**Figure 4.3.** Opening the lateral entry point using a 2-mm drill-bit.

- On the anteroposterior view, the drill-bit should be at the “equator” of the clavicle. The combination of these two aiming points represents the ideal exit point on the lateral fragment. Exiting too high may result in the fragments being flexed superiorly in relation to each other, and exiting too low can result in an apex inferior angulation. Exiting too far medially can cause an apex posterior angulation of the clavicle, and exiting too far laterally can result in an apex anterior angulation.
- Enlarge the canal with a straight 4.5-mm blunt awl or drill-bit (Fig. 4.4). Note that, in most cases, the blunt awl can be passed only about 20mm beyond the fracture site.



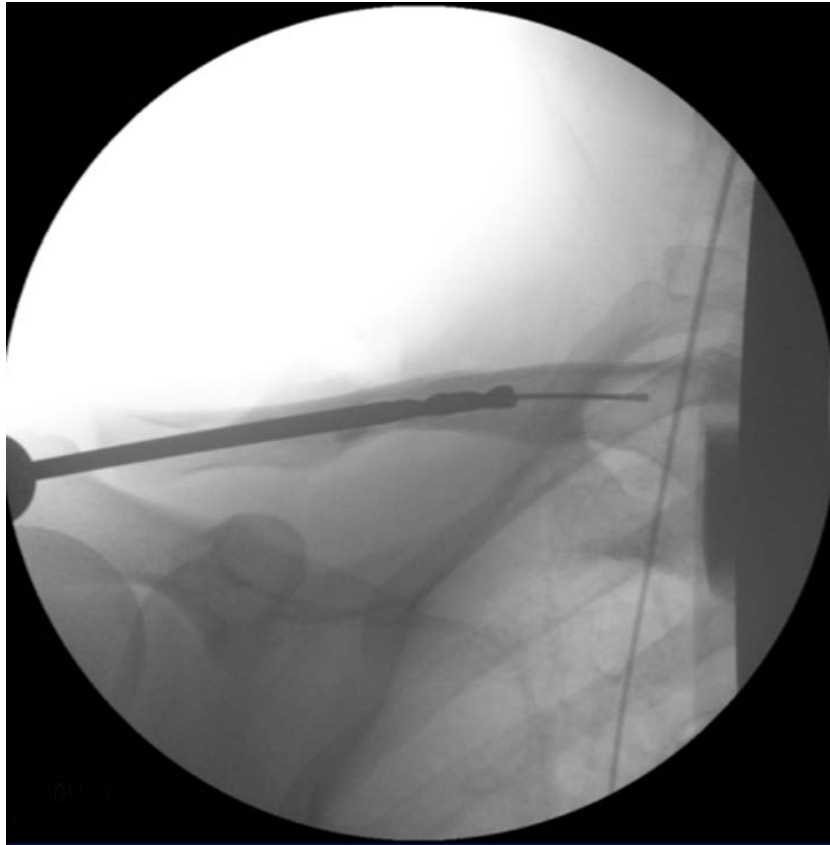
**Figure 4.4.** Enlarging the entry point using a 4.5-mm drill-bit.

- Place an aiming awl in the medullary canal and drill a Kirschner wire through the cannulated aiming device from the medial side to the lateral side of the fragment. The Kirschner wire should exit on the posterior-lateral surface at the equator of the clavicle, halfway between the conoid tubercle and the acromioclavicular joint.
- Once the wire has penetrated the skin, create a 10mm incision that can accommodate the passage of a cannulated drill over the Kirschner wire and, at a later stage, the Sonoma CRx intramedullary nail.
- With a 4.5-mm cannulated drill-bit, open the lateral entry point in the lateral fragment over the Kirschner wire.
- Remove the Kirschner wire and pass a “flutter” flexible guidewire into the cannulated drill with only the flattened tip of the guidewire protruding from the end of the cannulated drill.



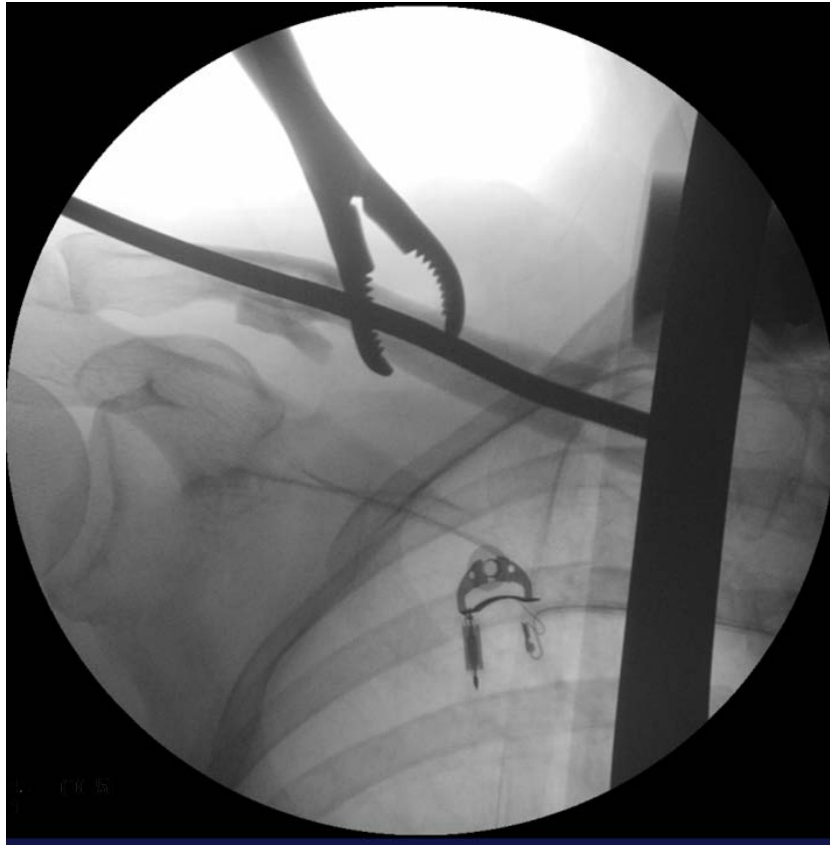**Figure 4.5** Opening the medullary canal of the lateral fragment of the clavicle with a 4.5-mm cannulated drill-bit.

- Then pass the cannulated 4.5-mm drill-bit in a retrograde fashion to ream the lateral canal (Fig. 4.5). Once the tip of the drill-bit is slightly medial to the medial most aspect of the lateral fragment, use the drill-bit to obtain a provisional fracture reduction. This is done by lifting up the patient's elbow to counteract the downward displacement of the lateral fragment due to gravity while at the same time depressing the medial fragment. Then pass the 4.5-mm drill-bit and guidewire a short distance into the medial fragment. Compare the diameters of the two fragments to make sure that they are equal; a difference in their diameters can represent a rotational deformity and must be corrected. Loss of length caused by fracture comminution can also result in a discrepancy in fragment diameter.
- Use the 4.5-mm cannulated drill to place the flutter flexible guidewire into the medial fragment of the clavicle bone (Fig. 4.6 and [Video 3](#)). Generally, this can be achieved most easily by asking an assistant to lift the patient's elbow while the surgeon pushes the medial fragment of the clavicle down.



**Figure 4.6.** Reduction of the fracture, and positioning of the flutter wire using the drill.

- Once you have entered the medullary canal of the medial fragment, pass the flexible guidewire into the most medial end of the medial fragment.
- Ream the entire canal with a 4.5-mm flexible reamer under power, from the lateral side of the lateral fragment to the most medial part of the medial fragment ([Video 3](#)). Once the most medial part of the medial fragment is reached, make sure that at least 50 mm of the medial fragment has been reamed; there is a band on the flexible reamer marking the 50-mm length (Fig. 4.7).



**Figure 4.7.** The fracture is held reduced while the canal is reamed with the flexible reamer.

- Disconnect the drill and place the measuring device over the reamer. Read the required nail length of the measuring device.
- Remove the reamer and measuring device, but not the flexible guidewire.
- Pass the insertion device over the guidewire into the lateral fragment for about 10mm.
- Remove the guidewire and the inner tube of the insertion device, leaving only the guide channel in the medullary canal.
- Keep fluoroscopy times to the bare minimum during the surgical procedure. (Note that the fluoroscopy screening times used in [Video 2](#) were for the purposes of demonstrating the technique and longer than would be used normally.)

**Step 5: Placement of the Intramedullary Nail**

Use the longest possible intramedullary nail that the clavicle can accommodate and insert the nail as far medially as possible into the medullary canal of the clavicle bone.

- Connect the selected Sonoma CRx intramedullary nail to the lateral locking jig. Make sure to use the longest possible intramedullary nail that the clavicle can accommodate.
- Insert the Sonoma CRx intramedullary nail, which is 4.2 mm in diameter, along the guide channel into the medullary canal of the lateral fragment. Once the tip of the intramedullary nail is inside the lateral fragment, remove the guide channel.
- To ensure that the intramedullary nail enters the medial fragment, reduce the fracture site with the use of reduction clamps. While doing so, gently tap on the back of the jig with a light hammer to insert the device fully into the medial side of the clavicle bone. Inserting the nail as deeply as possible into the medial fragment of the clavicle provides the optimal stability for the fracture and minimizes the risk of device failure. Note that the notch of the lateral locking screw should be placed just past the superior cortex and be visible on fluoroscopy, to ensure that the lateral locking screw can be placed.
- Take care not to insert the device so deeply that the lateral end is buried under the cortex of the clavicle as this will make removal of the device considerably more difficult.
- Keep fluoroscopy times to the bare minimum during the surgical procedure. (Note that the fluoroscopy screening times used in [Video 3](#) were for the purposes of demonstrating the technique and longer than would be used normally.)

**Step 6: Activation of the Locking Device**

Lock the device at its medial end with distally deployed grippers and laterally with a locking screw placed through a jig.

- Once the Sonoma CRx intramedullary nail is placed in the desired position, activate its innovative locking device with use of the torque-limiting actuation driver. This activation will cause the flexible part of the nail to become rigid in the desired anatomical shape, while a set of grippers at the medial end of the nail is



deployed. Turn the driver approximately twenty times until the lines on the driver handle line up with the lines on the shaft of the driver.

- Confirm full deployment of the grippers with fluoroscopy.
- Once the device is locked medially, place a drilling sleeve through the locking guide on the lateral side of the nail. This drilling sleeve will indicate the position of the lateral locking hole.
- Make a 1-cm incision at the indicated location of the lateral locking hole.
- Drill a hole using the lateral locking jig to place the lateral locking screw. Do this carefully as the drill-bit is quite thin and can become misaligned. Ensure that the locking guide is flush with the bone with no intervening soft tissue. The locking screw should engage the superior and inferior cortices of the clavicle, as this provides the best rotational stability
- Once the locking screw is placed, replace the actuation driver in the lateral end of the nail ([Video 3](#)). If the driver engages the nail, the locking hole has been missed and should be repositioned.
- Confirm the correct placement of the Sonoma CRx intramedullary nail with fluoroscopy.

### **Step 7: Management of Comminuted Fracture Fragments**

Comminuted fractures are not a contraindication to the use of the intramedullary device as they can be reduced by the nail and secured by using cerclage sutures.

- Hold the comminuted fracture out to length before activating the intramedullary nail and passing the interlocking screw, to ensure that the anatomical length is being restored.
- Use absorbable cerclage sutures to secure all comminuted fracture fragments to the intramedullary nail, while trying to preserve their soft-tissue attachments. While taking care not to strip off soft tissue unnecessarily, pass the suture around the fracture fragment as either a single or a double strand under direct vision. A specially designed Crego elevator in the set facilitates this.
- Suture smaller comminuted fracture fragments back onto the strut provided by the nail, again ensuring that soft-tissue attachments are preserved. Suturing small

fragments back onto the nail provides bone stock at the fracture site, enabling union of even comminuted fractures.

### **Step 8: Postoperative Management**

Protect the affected shoulder in a shoulder immobilizer for six weeks.

- The patient wears a broad arm sling for six weeks, during which time he/she performs pendulum-type exercises of the shoulder and range-of-motion exercises of the elbow six times a day. Heavy lifting and strenuous overhead activities are avoided until bridging callus is seen on follow-up radiographs.
- If bridging callus is seen on six-week postoperative radiographs, the patient is allowed to return to activities as tolerated. Since an intramedullary nail is a load-sharing device, allowing full function will facilitate healing—unlike the case with a plate, which is load-bearing. An important distinction between bone healing after use of an intramedullary device and that after plate fixation is that callus can be seen and followed on radiographs after intramedullary fixation. Because of the direct, noncallus nature of bone healing following plate fixation, healing can only be inferred based on a lack of complications such as screw loosening or plate breakage.
- Most patients have achieved a full range of motion and normal shoulder function by three months.

## RESULTS

In our original study,<sup>16</sup> forty-seven consecutive patients with a displaced and shortened clavicle shaft fracture were treated with open reduction and internal fixation using the Sonoma CRx device. The average duration (and standard deviation) of the operation to implant the Sonoma CRx intramedullary nail was  $74 \pm 16$  minutes, and the mean incision length (the total for the three incisions needed to implant and lock the device) was  $49 \pm 17$  mm. The patients were divided into three groups according to whether the postoperative assessment had been performed at three to six months, six to nine months, or nine to twelve months postoperatively. All forty-seven fractures had fully united at these assessments. Two patients (4%) were diagnosed with device failure, but retrospective analysis suggested that these failures were most likely caused by a second traumatic incident (one patient) and nonadherence to the immobilization protocol (one patient). Although the device failed, both fractures united without additional intervention.

The functional capacity of the shoulder was assessed on the basis of the range of motion; the Disabilities of the Arm, Shoulder and Hand (DASH) score;<sup>18</sup> and the Constant Shoulder (CS) score.<sup>19</sup> The range of motion and DASH and CS scores were good in all three groups and did not differ among the groups. These findings suggest that displaced and shortened clavicle fractures can be treated with the Sonoma CRx intramedullary nail and that full function of the shoulder can be regained as early as three to six months postoperatively.<sup>16</sup> However, as this study was cross-sectional, no conclusions regarding changes over time could be drawn. In addition, because no patients were treated with an anatomically contoured plate, it was also not possible to draw conclusions regarding the effectiveness of the Sonoma CRx intramedullary nail compared with traditional anatomical plate fixation.

We are currently conducting a randomized controlled trial comparing anatomically contoured plate fixation with intramedullary nailing for displaced and shortened clavicle fractures.<sup>15</sup> We randomly assigned patients to treatment with either a traditional anatomically contoured plate or a Sonoma CRx intramedullary nail. Patients were followed at twelve months post-surgery. At the time of writing, forty-seven patients (twenty-five in the anatomical plate group and twenty-two patients in the intramedullary nail group) had completed the study. Preliminary data from this cohort determined that,

on average, the nailing group had a shorter operating time ( $43 \pm 8$  minutes versus  $60 \pm 19$  minutes,  $p = 0.0029$ ) and a shorter incision ( $38 \pm 9$  mm versus  $118 \pm 19$  mm,  $p < 0.0001$ ). No failure of either the anatomical plate or the intramedullary nail was observed. The intramedullary nail group also had a lower mean DASH-score ( $2 \pm 5$  versus  $16 \pm 18$ ,  $p = 0.0071$ ) and a higher mean CS score ( $96 \pm 6$  versus  $90 \pm 18$ ,  $p = 0.0122$ ) twelve months postoperatively. Although the trial has not yet been completed and has not reached sufficient power, the initial findings suggest that the Sonoma CRx intramedullary nail may be an effective alternative for the treatment of displaced and shortened clavicle fractures. However, there will always be a place for both plate fixation and nailing in the treatment of clavicle fractures, and that treatment choice should be based on the patient's personal profile and goals.

## **PITFALLS & CHALLENGES**

- Place and secure the patient in the beach-chair position so that adequate fluoroscopic images of the clavicle bone can be obtained. Before starting the surgery, make sure that you can see the medial and most lateral aspects of the clavicle using the fluoroscopy machine.
- Avoid periosteal stripping of the medial and lateral fragments and preserve the soft-tissue attachments and blood supply of comminuted fracture fragments.
- Prepare the medial fragment canal as deeply as possible—at least 50mm past the fracture site.
- Use the longest possible intramedullary nail to achieve the highest level of stability and lowest risk of device failure.
- Reduce comminuted fracture fragments back onto the implant and secure them with absorbable cerclage sutures.
- A special device is available for removal of the nail, which can be done with relative ease. The lateral locking screw needs to be removed, a small incision over the entry point laterally is made, and the device is deactivated. This allows the medial grippers to retract to allow extraction of the nail.

## **CLINICAL COMMENTS**

- Initial findings suggest that the Sonoma CRx intramedullary nail is a good alternative for the treatment of displaced and shortened clavicle shaft fractures.
- Preliminary data have shown that the Sonoma CRx intramedullary nail yields a good union rate with a very low rate of device migration.
- The aim of future research should be to determine the advantages of plate fixation and nailing of clavicle shaft fractures in different populations.

## Chapter 4

---

---

**REFERENCES**

1. Postacchini F, Gumina S, De Santis P, Albo F. Epidemiology of clavicle fractures. *J Shoulder Elbow Surg.* 2002;11(5):452-456.
2. Nowak J, Mallmin H, Larsson S. The aetiology and epidemiology of clavicular fractures. A prospective study during a two-year period in Uppsala, Sweden. *Injury.* 2000;31(5):353-358.
3. Stanley D, Trowbridge EA, Norris SH. The mechanism of clavicular fracture. A clinical and biomechanical analysis. *J Bone Joint Surg Br.* 1988;70(3):461-464.
4. Khan LA, Bradnock TJ, Scott C, Robinson CM. Fractures of the clavicle. *J Bone Joint Surg Am.* 2009;91(2):447-460.
5. Martetschläger F, Gaskill TR, Millett PJ. Management of clavicle nonunion and malunion. *J Shoulder Elbow Surg.* 2013;22(6):862-868.
6. McKee MD, Pedersen EM, Jones C, Stephen DJ, Kreder HJ, Schemitsch EH, Wild LM, Potter J. Deficits following nonoperative treatment of displaced midshaft clavicular fractures. *J Bone Joint Surg Am.* 2006;88(1):35-40.
7. Neer CS. Nonunion of the clavicle. *J Am Med Assoc.* 1960;172:1006-1011.
8. van der Meijden OA, Gaskill TR, Millett PJ. Treatment of clavicle fractures: current concepts review. *J Shoulder Elbow Surg.* 2012;21(3):423-429.
9. Houwert RM, Wijdicks FJ, Steins Bisschop C, Verleisdonk EJ, Kruijt M. Plate fixation versus intramedullary fixation for displaced mid-shaft clavicle fractures: a systematic review. *Int Orthop.* 2012;36(3):579-585.
10. Wijdicks FJ, Van der Meijden OAJ, Millett PJ, Verleisdonk EJMM, Houwert RM. Systematic review of the complications of plate fixation of clavicle fractures. *Arch Orthop Trauma Surg.* 2012;132(5):617-625.
11. Lee YS, Lin CC, Huang CR, Chen CN, Liao WY. Operative treatment of midclavicular fractures in 62 elderly patients: Knowles pin versus plate. *Orthopedics.* 2007;30(11):959-964.
12. Liu HH, Chang CH, Chia WT, Chen CH, Tarng YW, Wong CY. Comparison of plates versus intramedullary nails for fixation of displaced midshaft clavicular fractures. *J Trauma.* 2010;69(6):E82-7.
13. Wijdicks FJ, Houwert M, Dijkgraaf M, de Lange D, Oosterhuis K, Clevers G, Verleisdonk EJ. Complications after plate fixation and elastic stable intramedullary nailing of dislocated midshaft clavicle fractures: a retrospective comparison. *Int Orthop.* 2012;36(10):2139-2145.
14. Palmer DK, Husain A, Phipatanakul WP, Wongworawat MD. Failure of a new intramedullary device in fixation of clavicle fractures: a report of two cases and review of the literature. *J Shoulder Elbow Surg.* 2011;20(4):e1-4.
15. King PR, Ikram A, Lamberts RP. Intramedullary fixation versus anatomically contoured plating of clavicle shaft fractures: a one-year follow-up study. *Bone Joint J* 2014;96:54.
16. King PR, Ikram A, Lamberts RP. The treatment of clavicular shaft fractures with an innovative locked intramedullary device. *J Shoulder Elbow Surg.* 2015;24(1):e1-6.
17. King PR, Scheepers S, Ikram A. Anatomy of the clavicle and its medullary canal: a computed tomography study. *Eur J Orthop Surg Traumatol.* 2014;24(1):37-42.
18. De Smet L. The DASH questionnaire and score in the evaluation of hand and wrist disorders. *Acta Orthop Belg.* 2008;74(5):575-581.

Chapter 4

---

19. Constant CR, Murley AH. A clinical method of functional assessment of the shoulder. *Clin Orthop Relat Res.* 1987;214:160-164.



## **THE EFFECTIVENESS OF A FLEXIBLE LOCKED INTRAMEDULLARY NAIL AND AN ANATOMICAL CONTOURED LOCK PLATE TO TREAT CLAVICLE SHAFT FRACTURES**

The content of this article was published as:

**P.R. King**, A. Ikram, M.M. Eken R.P. Lamberts. The effectiveness of a flexible locked intramedullary nail and an anatomical contoured locked plate to treat clavicular shaft fractures. *Journal of Bone and Joint Surgery Am.* 2019;101(7):628-634

**Impact factor:** 4.7

**Ranking:** #4 of 76 in Orthopedics (ISI Web of Science)

## Chapter 5

---

**ABSTRACT**

**Background:** Displaced and shortened clavicular shaft fractures can be treated operatively with intramedullary or extra-medullary fixation. The aim of the present study was to compare the union rates and functional outcomes of displaced and/or shortened clavicular shaft fractures treated with a flexible locked intramedullary nail or with an anatomically contoured locked plate.

**Methods:** Seventy-two patients with acute displaced and/or shortened clavicular shaft fractures underwent randomly assigned management with either an intramedullary locked nail or an anatomically contoured locked plate. The same surgeon performed all surgical procedures, and all patients underwent identical postoperative treatment regimens. Incision length, surgical time, and union rate were recorded, and the functional outcome of the shoulder was assessed with use of the Disabilities of the Arm, Shoulder and Hand (DASH) and Constant Shoulder (CS) scores. Data were analyzed with use of traditional statistical methods as well as Cohen effect sizes, which were based on the minimal clinical important differences.

**Results:** Thirty-seven patients were managed with an anatomically contoured locked plate, and 35 patients were managed with a Sonoma CRx intramedullary flexible locked nail. There were no differences in general patient characteristics, fracture type, or displacement between treatment groups. The nailing group had significantly better outcomes ( $p < 0.001$ ) than the locked plating group for surgical time (mean and standard deviation [SD],  $45 \pm 12$  compared with  $65 \pm 21$  minutes, respectively) and incision size (mean and SD,  $37 \pm 9$  compared with  $116 \pm 18$  mm). A union rate of 100% was observed in both groups. DASH scores were similar between groups at 1.5, 3, and 6 months, whereas the nailing group had significantly better DASH scores at 12 months ( $p = 0.022$ ); however, this difference had only a moderate effect size. Overall, individual variation in DASH and CS scores was substantially higher in the plating group compared with the nailing group.

**Conclusions:** Both the pre-contoured locked plate and the flexible locked intramedullary nail effectively treated displaced and/or shortened clavicular shaft fractures. Similar outcomes were achieved at 1.5, 3, and 6 months after surgical intervention, and better DASH scores were observed in the nailing group at 12 months. Cohen effect sizes suggested that slightly better outcomes were potentially achieved

in the nailing group.

**Level of evidence:** Therapeutic Level I, Randomized Controlled Trial.

**Keywords:** Clavicle fracture; intramedullary nail; anatomical plate; union; shoulder function

## INTRODUCTION

Clavicle fractures are common, comprising 2.6 to 4.0% of all adult fractures and accounting for 35% of injuries to the shoulder girdle.<sup>1</sup> Recent studies have indicated higher complication rates in fracture types treated non-operatively.<sup>2-4</sup> In nonoperatively treated clavicular fractures, poorer outcomes have been associated with a higher degree of shortening.<sup>3,5,6</sup> Compared with nonoperative treatment, operative treatment of displaced clavicular shaft fracture is associated with improved shoulder function, as measured with the Disabilities of the Arm, Shoulder and Hand (DASH) and Constant Shoulder (CS) scores<sup>7</sup>. In nonoperatively treated clavicle fractures, poorer outcome results have been associated with a higher degree of shortening.<sup>3,5,6</sup> It is widely accepted that minimally displaced clavicular shaft fractures can and should be treated conservatively, with either a sling or a figure-of-8 bandage.<sup>1,4</sup> Operative treatment consists of open reduction and internal fixation involving locked or non-locked plates or involving intramedullary rods, wires, or nails<sup>2</sup>. Numerous intramedullary fixation devices are available, including Knowles pins (Zimmer), Hagie pins (DePuy), Rockwood pins (DePuy), minimally invasive titanium nails (Synthes), and the Sonoma CRx nail (Sonoma Orthopedic products).<sup>1,6,8,9</sup>

Although several randomized controlled trials and systematic reviews have compared intramedullary nailing to traditional anatomical plating,<sup>10-12</sup> to our knowledge, no study to date has compared traditional plating with the use of the SonomaCRx nail. In contrast with other nails, the Sonoma nail has a flexible medial part that allows the nail to follow the anatomical shape of the clavicle.<sup>9,13</sup> After positioning the nail, the flexible part is made rigid with the use of an activation screw.<sup>13</sup> The lateral aspect of the device is locked with an interlocking screw and the medial aspect deploys grippers, providing rotational and length stability.

The aim of the present study was to compare the union rates and functional outcomes of displaced and/or shortened clavicular shaft fractures treated with a flexible locked intramedullary nail or with an anatomically contoured locked plate.

## Chapter 5

---

## METHODS

### Study design

This randomized controlled study compared the effectiveness of a flexible locked intramedullary nail with that of an anatomically contoured plate to restore union of the clavicle and the functional capacity of the shoulder in patients with a displaced and/or shortened clavicular shaft fracture. Patients who had sustained a displaced and/or shortened clavicular shaft fracture between 2011 and 2013 and who sought treatment at the Division of Orthopaedic Surgery at the Tygerberg Academic Hospital were invited to participate in the study. Before enrollment, all patients signed an informed consent form, after which they were randomly assigned to either of the 2 treatment groups.

Ninety-two patients were identified for inclusion in the study (Fig. 5.1). Patients had to have been admitted to the hospital with a fracture of the shaft of the clavicle, as determined by the Allman classification<sup>14</sup>. In addition, the fracture had to be (1) shortened by  $\geq 15$ mm and/or (2) 100% displaced and/or comminuted. Patients with previous clavicular fractures or a pathological fracture were excluded from the study. A total of 5 patients were excluded from the study: 1 for not meeting inclusion criteria, 2 who declined to participate, and 2 who demanded a specific treatment and thus could not be randomized to a treatment group.

With use of a computerized block randomization program, 42 patients were allocated to the nailing group and 45 patients were allocated to the plating group (Fig. 5.1). One patient in the nailing group did not receive the allocated intervention and was excluded from the study. During the study, 14 patients (6 in the nailing group and 8 in the plating group) were lost to follow-up, of whom 9 opted not to come back for follow-up assessments without providing a reason; these patients are marked as “unknown” in Fig. 5.1. The primary outcomes of the study were the union rate and the functional shoulder capacity, as measured with the use of the DASH<sup>15</sup> and CS<sup>16</sup> scores, at 1.5, 3, 6, and 12 months after the surgical procedure. In addition, surgical time, incision size, and rate of hardware failure were compared.

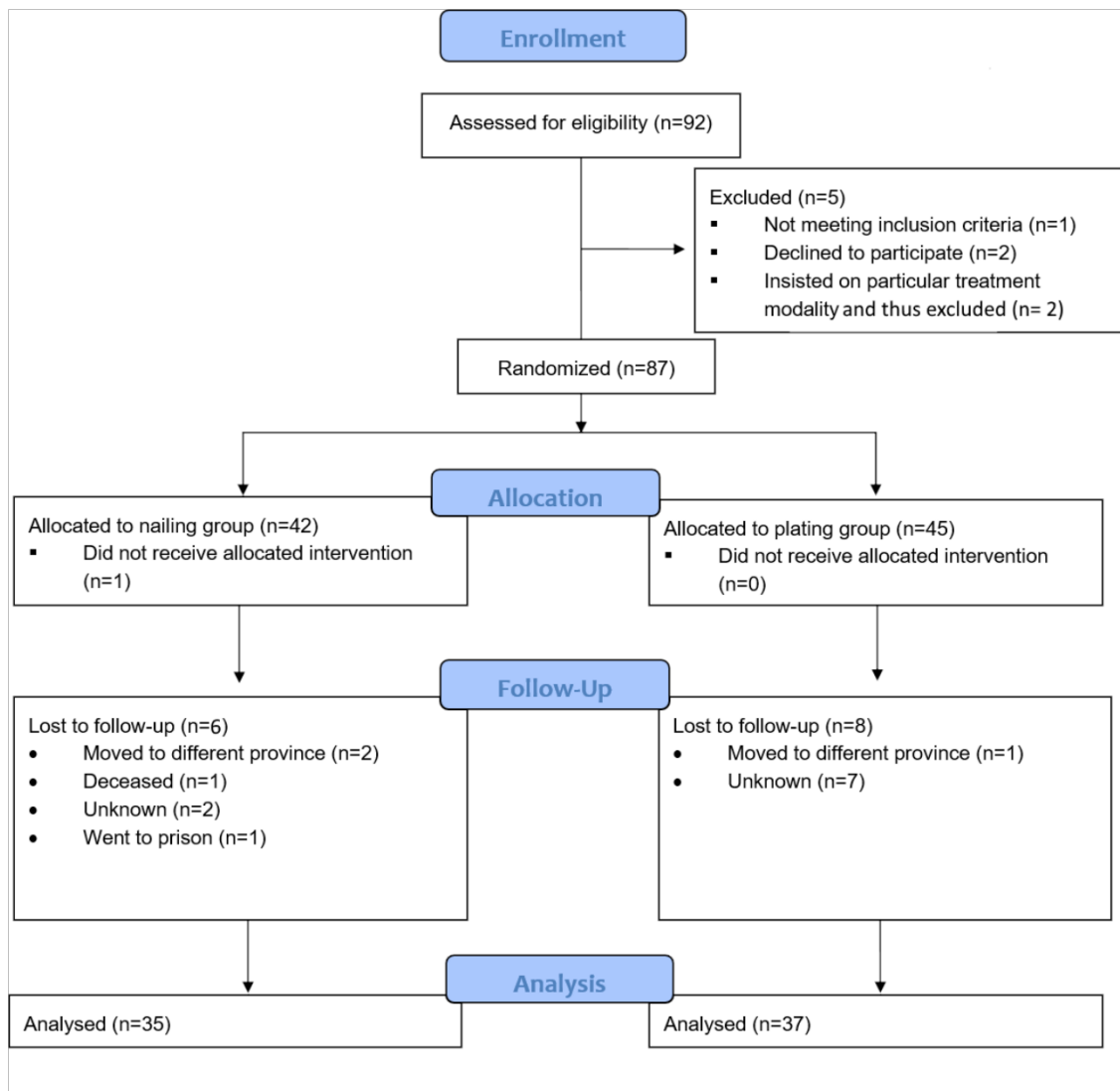


Figure 5.1. CONSORT flow diagram

## Ethical Considerations

Ethical approval for this study was granted by the Health Research Ethics Committee of Stellenbosch University (M11/05/012; IRB0005239), and hospital clearance was given by Tygerberg Hospital. The principles outlined by the Declaration of Helsinki were followed.



## **Operative Treatment**

Patients were assessed on admission and kept in a shoulder immobilizer until they underwent operative treatment.<sup>13</sup> Fifteen degree cephalad tilt radiographs were made at admission and used to classify fractures according to the Allman classification system<sup>14</sup>. The surgical preparation was similar for both groups, with patients being positioned in the beach chair position. Preoperatively, patients were administered 2 g of intravenous cefazolin and a general anesthetic.<sup>13</sup>

### **Anatomically Contoured Locked Plate**

Patients in the anatomically contoured locked plating group were managed with the Acumed Clavicle Plating System. All plates were positioned superiorly, and the branches of the supraclavicular nerve were identified and protected during dissection. Care was taken not to disrupt the nerve branches while positioning the plate. Fractures were reduced, and fragments deemed large enough were fixed with interfragmentary lag screws. Small comminuted fragments were reduced and fixated with cerclage sutures. Closure of the wound was performed in layers, with care taken to approximate the detached muscle insertions over the plate and to approximate the platysma muscle as a separate layer.

### **Flexible Locked Intramedullary Nail**

Patients allocated to the flexible locked intramedullary nailing group were managed with a Sonoma CRx intramedullary nail. This nail features a medial WaviBody assembly (Arthrex), which is a flexible portion that becomes rigid once activated. The nail is inserted into the medullary canal following reduction of the fracture<sup>13</sup> with the flexible medial portion alongside the axial and coronal curvature of the clavicle. Following insertion and alignment along the clavicle, the WaviBody assembly is activated, becoming rigid and deploying grippers at the medial tip of the nail. These grippers, together with a lateral interlocking screw, secure the nail into place and provide length and rotational stability. A visual step-by-step process and description of the surgical technique involving the Sonoma nail has been previously published.<sup>13</sup>

## Rehabilitation and Data Capturing

The affected upper extremity was supported in a shoulder immobilizer for 6 weeks. Patients were advised to perform pendular exercises of the shoulder and flexion/extension exercises of the ipsilateral elbow 6 times a day for the 6-week period. Full range of movement exercises of the shoulder were commenced after 6 weeks. Full return to activity and contact sports were advised after 3 months.<sup>13</sup>

## Shoulder Function Assessments

Shoulder function was measured with use of DASH<sup>15</sup> and CS<sup>16</sup> scores, with each patient being assessed by a single independent and experienced physiotherapist. The DASH system is a 30-item questionnaire quantifying physical function and symptoms of the upper limb,<sup>13</sup> with scores ranging from 0 (no disability) to 100 (completely disabled).<sup>13</sup> CS scores are based on the flexion, abduction, internal and external rotation, and range of motion of the shoulder, with scores ranging from 0 (severe impairment) to 100 (no impairment).<sup>16</sup> Union was determined by an independent radiologist on the basis of anteroposterior radiograph with a 15° cephalad tilt.

## Sample Size

An a priori sample size calculation was performed to determine the minimum sample size for this study. The sample size calculation was based on data from Gummesson *et al.*<sup>17</sup> and the minimal clinically important difference (MCID) for DASH<sup>18</sup> and CS<sup>19</sup> scores, which was set at  $10 \pm 13$  points for both. To achieve a power of 80% with a significance level of 0.05, the sample size analyses indicated that 27 patients had to be allocated to each group. Based on potentially high drop-out rates, we aimed to recruit about 45 patients in each group.

## Data Analysis

The data were analyzed with STATISTICA (version 13.3; TIBCO Software). Distribution and homogeneity of variances for the data were assessed with use of a Levene test. Differences in descriptive parametric parameters were analyzed with use of a t-test, and nonparametric descriptive parameters were analyzed with use of a

Mann-Whitney U test. DASH and CS scores were accepted as parametric data, which was in line with other randomized controlled trials.<sup>12,20,21</sup> Differences over time (at 1.5, 3, 6, and 12 months), between treatment groups, and interaction effects (time x group), were analyzed with a repeated-measure analysis of variance test, with a Tukey post-hoc analysis when significance was found. Cohen effect sizes were calculated and determined as trivial (<0.2), small ( $\geq 0.2$  to <0.5), moderate ( $\geq 0.5$  to <0.8), or large ( $\geq 0.8$ ).<sup>22</sup> Significance was set at  $p < 0.05$ .

### **Trial Registry**

This study was registered in the public Pan African Clinical Trial Registry (PACTR201805003376209).

## Chapter 5

---

## RESULTS

Of the 72 patients with a displaced and/or shortened clavicular shaft fracture who completed the study, 35 (49%) were managed with the pre-contoured locked plate and 37 (51%) with the flexible Sonoma CRx nail (Table 5.1).

**Table 5.1** Characteristics of the patients in the nailing and in the plating group

Characteristic	Plating Group (n=37)	Nailing Group (n=35)	p-value
<i>General</i>			
Age (yrs)	35 ± 12	29 ± 14	0.439
Sex			
Male	20 (54%)	26 (74%)	0.991
Female	17 (46%)	9 (26%)	0.979
<i>Injury details</i>			
Fracture types			
Simple	23 (62%)	23 (66%)	0.985
Single fragment	2 (5%)	3 (8%)	0.773
Multiple fragment	11 (30%)	9 (26%)	0.983
Coronal displacement (mm)	22 ± 9	25 ± 13	0.186
Shortening (mm)	14 ± 9	15 ± 10	0.970
<i>Surgery details</i>			
Cutting time (min)	65 ± 21 <sup>a</sup>	45 ± 12 <sup>a</sup>	< 0.001
Scar length (mm)	116 ± 18 <sup>b</sup>	37 ± 9 <sup>b</sup>	< 0.001

Continuous data is expressed as mean ± standard deviation, while categorical data is expressed as n (percentage).

Although no differences were found in the general characteristics, the nailing group had significantly better outcomes than the locked plating group for surgical time (mean and standard deviation [SD], 45 ± 12 compared with 65 ± 21 minutes) and incision size (mean and SD, 37 ± 9 compared with 116 ± 18 mm;  $p < 0.001$ ) (Table 5.1). At 12 months, a union rate of 100% was observed in both the anatomically contoured locked plating group and the locked intramedullary nailing group.

## Chapter 5

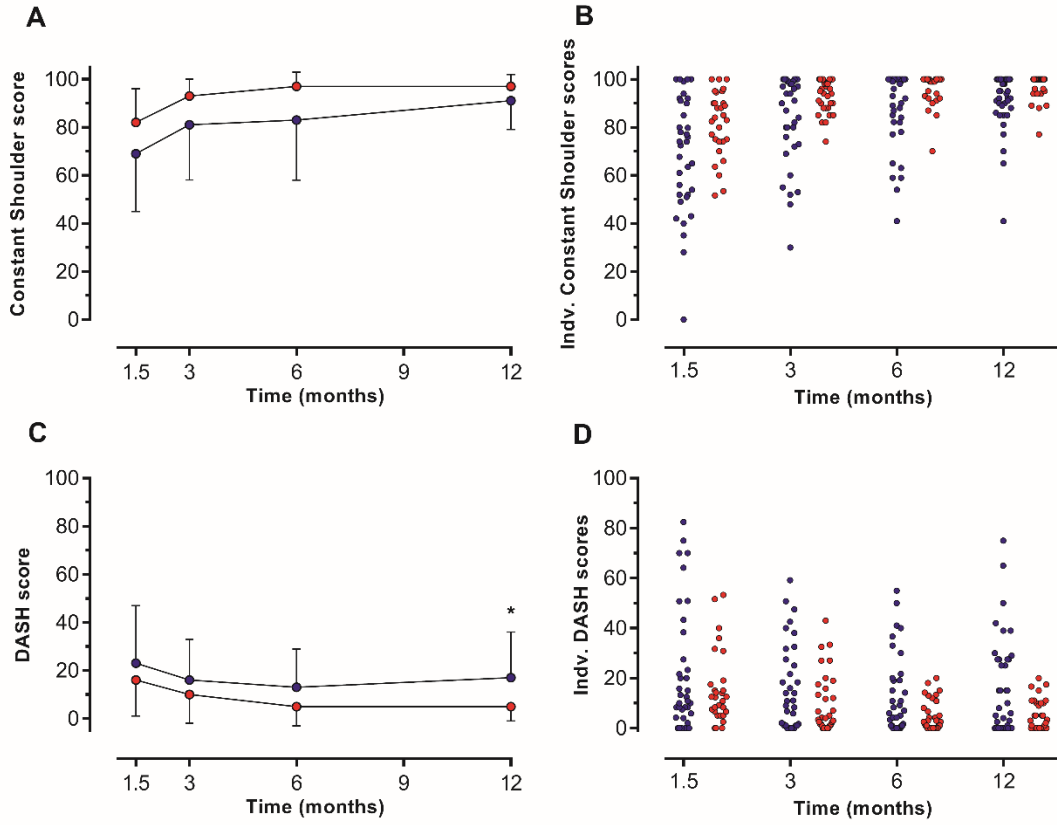
The nailing group had significantly better DASH scores at 12 months ( $p = 0.022$ ), whereas scores were similar between groups at 1.5, 3, and 6 months (Table 5.2, Fig. 5.2). However, only small to moderate Cohen effect sizes were found (Fig. 5.3). Interestingly, 2 patients in the plating group had a worse DASH score at 12 months than at 6 months (Fig. 5.2).

**Table 5.2.** Changes in functional outcome scores at 1.5, 3, 6 and 12 months post-operatively

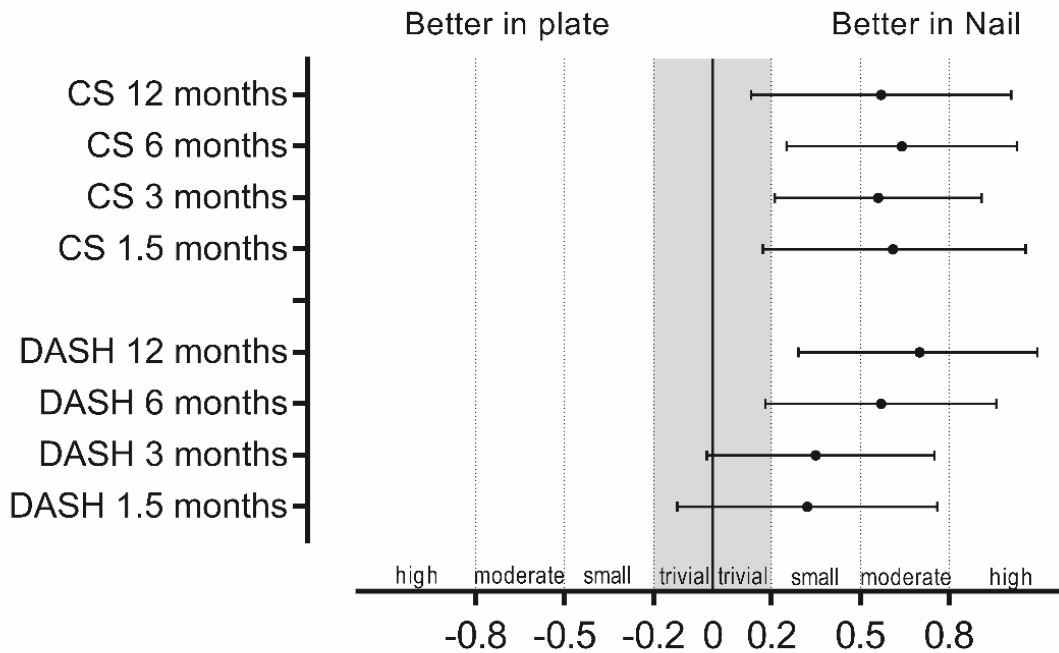
Parameter	Plating Group* (points)	Nailing Group*	Mean Difference between the Plating and Nailing Group (Points)	$p$ -value	Cohen effect size (95% CI) †	Descriptor
<b>DASH scores (points) ‡</b>						
1.5 months	23 ± 24	16 ± 15	7	0.590	0.32 (-0.12 – 0.76)	Small
3 months	16 ± 17	10 ± 12	6	0.670	0.37 (-0.02 – 0.75)	Small
6 months	13 ± 16	5 ± 6 <sup>b</sup>	8	0.419	0.57 (0.18 – -0.96)	Moderate
12 months	17 ± 19	5 ± 6	12	<b>0.022<sup>§</sup></b>	0.70 (0.29 – 1.10)	Moderate
<b>Constant Shoulder scores (points) ‡</b>						
1.5 months	71 ± 21	82 ± 14	11	0.091	0.61 (0.17 – 1.06)	Moderate
3 months	83 ± 19 <sup>c</sup>	93 ± 7 <sup>d</sup>	10	0.107	0.56 (0.21 – 0.91)	Moderate
6 months	87 ± 16	97 ± 6	10	0.173	0.64 (0.25 – 1.03)	Moderate
12 months	91 ± 12	97 ± 5	6	0.612	0.57 (0.13 – 1.01)	Moderate

\*Data are presented as the mean and SD. †Data are presented as the mean with the 95% confidence interval in parentheses; positive values reflect a better effect size in nailing and negative values reflect a better effect size in plating. ‡The MCID was 10.85 for DASH scores and 10.4 for CS scores<sup>18,19</sup>. <sup>§</sup>Significant.

Chapter 5



**Figure 5.2.** Functional outcome scores at 1.5, 3, 6 and 12 months after surgical intervention in the plating (blue circles) and in the nailing group (red circles), expressed as mean (2<sup>A</sup>) & individual (2<sup>C</sup>) scores and mean (2<sup>B</sup>) & individual (2<sup>D</sup>) CS scores.



**Figure 5.3.** Overview of the DASH and CS Cohen effect sizes

**Complications**

One patient in each group was treated with oral antibiotics for superficial wound infections. Hardware failure was also observed in 1 patient from each group. One patient in the nailing group, who resumed hard physical work directly after the operation against the postoperative treatment regimen, was diagnosed with hardware failure at the junction of the flexible and the rigid part of the nail. In 1 patient in the plating group, the screws of the lateral fragment of the plate were pulled out as a result of a fall in the shower; the plate was removed, but the patient declined any other further treatment to correct the malunion. Except for this removal, no other anatomical plates or intramedullary nails were surgically removed.



## DISCUSSION

The present randomized controlled trial aimed to compare the treatment of displaced and/or shortened clavicular shaft fractures with either an anatomically contoured locked plate or a flexible intramedullary nail that is locked into position with medial grippers and a lateral interlocking screw. Patients were well randomized, as the age, gender, and fracture types were similar both groups; however, surgical time and incision size differed by a factor of 1.4 and 3.1, respectively (Table 5.1). Treatment with both the anatomically contoured locked plate as well as the locked intramedullary nail resulted in a 100% union rate. Differences in shoulder function, as measured by DASH and CS scores, were assessed with use of traditional statistical methods as well as the Cohen effect size to determine the likelihood that these differences were clinically meaningful. Similar DASH and CS results were observed in the nailing and plating groups except at 12 months, at which point the mean DASH score was slightly better in the nailing group ( $p = 0.022$ ). However, only a moderate Cohen effect size was observed. In addition, individual data plots show that 2 patients in the plating group had substantially worse DASH scores at 12 months compared with 6 months (Fig. 5.2-D). Although no clear reason for this worsening could be found, excluding these points from the data set resulted in no longer finding a difference between the plating and nailing group for DASH scores at 12 months ( $p = 0.151$ ), which supports the finding that this difference might not be clinically relevant.

The DASH and CS scores observed in the plating group are in line with those of studies involving similar and/or the same plate.<sup>23</sup> DASH and CS scores reported in the flexible nail group of the present study tended to be higher than those reported in rigid nails or pins.<sup>24-27</sup> Whereas we observed a mean CS score of 97, Ferran *et al.*<sup>25</sup>, Liu *et al.*<sup>26</sup>, and Lee *et al.*<sup>27</sup> reported scores of 92, 86, and 95, respectively, with use of a Rockford nail, a titanium elastic nail, and a Knowles pin, respectively.

Similar to the present study, Calbiyik *et al.*<sup>24</sup> compared the use of a locking compression plate with the Sonoma CRx nail to treat clavicular fractures. In that study, a different surgical technique involving a medial entry point lateral to the sternoclavicular joint was utilized, rather than the standard lateral entry point utilized in the present study. In line with our study, Calbiyik *et al.*<sup>24</sup> reported better DASH scores in the nailing group; however, the main limitation of that study was that patients

did not undergo a standardized follow-up period (e.g. 12 months) but were assessed after “at least 12 months,” which might have influenced the findings. In contrast, Zehir *et al.*<sup>28</sup> found no differences in QuickDASH (an abbreviated version of the DASH questionnaire) scores between patients managed with a minimally invasive locking superior plate or with the Sonoma CRx nail; however, the difference in follow-up time between the plating (14.5 months) and nailing group (11.8 months) might have influenced those findings.

In the present study, hardware failure was minimal in both groups and could be related to extreme circumstances in both cases. Nail migration traditionally has been a problem and has resulted in a high rate of hardware removal<sup>8,29,30</sup>. However, with using modern nails such as the Sonoma nail, these hardware problems no longer seem to be a limitation,<sup>9,13,24,28</sup> and no signs of hardware migration in the nailing group were observed in the present study.

The limitations of the present study are that the randomized controlled trial was not a multicenter study and that all surgical procedures were performed by the same surgeon, who was experienced using both devices. Although the use of a single surgeon could be a confounding factor, it also minimizes the variation in surgical technique that exists between surgeons. Because the surgeon in the present study had extensive experience implanting the nail, other surgeons who are less familiar with the hardware might experience slightly longer surgical times. Lastly, although the medial part of the flexible nail becomes rigid after activation, it is likely not as strong as a 1-piece intramedullary nail, which can lead to hardware failure. However, the relatively low number of hardware failures reported in this device suggests that it is sufficiently strong.<sup>9,13,24,28</sup>

In conclusion, both the Acumed pre-contoured locked plate and the Sonoma CRx intramedullary nail effectively treated displaced and/or shortened clavicular shaft fractures, resulting in a union rate of 100% in both groups. Similar DASH and CS scores were observed at 1.5, 3, and 6 months. DASH scores at 12 months were better in the nailing group, although individual responses indicate that this finding might not be clinically meaningful. However, better DASH and CS Cohen effect sizes (small to moderate) were found in the nailing group. Overall, we conclude that both devices can be used to effectively treat displaced and/or shortened clavicular shaft fractures.

## Chapter 5

---

Factors such as preference, surgical skill, and cosmetic result are likely to influence the decision of the treating surgeon.

## Chapter 5

---

---

**REFERENCES**

1. Khan LAK, Bradnock TJ, Scott C, Robinson CM. Fractures of the clavicle. *J Bone Joint Surg Am.* 2009;91(2):447–460.
2. Zlowodzki M, Zelle BA, Cole PA, Jeray K, McKee MD. Treatment of acute midshaft clavicle fractures: systematic review of 2144 fractures: on behalf of the Evidence-Based Orthopaedic Trauma Working Group. *J Orthop Trauma.* 2005;19(7):504–7.
3. Hill JM, McGuire MH, Crosby LA. Closed treatment of displaced middle-third fractures of the clavicle gives poor results. *J Bone Jt Surg Br.* 1997;79(4):537–539.
4. Böhme J, Bonk A, Bacher GO, Wilharm A, Hoffmann R, Josten C. Current treatment concepts for mid-shaft fractures of the clavicle - results of a prospective multicentre study. *Z Orthop Unfall.* 2011;149:68–76.
5. Lazarides S, Zafiroopoulos G. Conservative treatment of fractures at the middle third of the clavicle: the relevance of shortening and clinical outcome. *J Shoulder Elbow Surg.* 2006;15(2):191–194.
6. Eskola A, Vainionpää S, Myllynen P, Pätäälä H, Rokkanen P. Outcome of clavicular fracture in 89 patients. *Arch Orthop Trauma Surg.* 1986;106(6):337–338.
7. Society COT. Nonoperative treatment compared with plate fixation of displaced midshaft clavicular fractures. A multicenter, randomized clinical trial. *J Bone Joint Surg Am.* 2007;89(1):1–10.
8. Jubel A, Andermahr J, Schiffer G, Tsironis K, Rehm KE. Elastic stable intramedullary nailing of midclavicular fractures with a titanium nail. *Clin Orthop Relat Res.* 2003;408:279–285.
9. King PR, Ikram A, Lamberts RP. The treatment of clavicular shaft fractures with an innovative locked intramedullary device. *J Shoulder Elb Surg.* 2015;24(1):e1-6.
10. Houwert RM, Smeeing DPJ, Ahmed Ali U, Hietbrink F, Kruyt MC, van der Meijden OA. Plate fixation or intramedullary fixation for midshaft clavicle fractures: a systematic review and meta-analysis of randomized controlled trials and observational studies. *J Shoulder Elb Surg.* 2016;25(7):1195–1203.
11. Wijdicks F-JG, Houwert RM, Millett PJ, Verleisdonk EJJM, Van der Meijden OAJ. Systematic review of complications after intramedullary fixation for displaced midshaft clavicle fractures. *Can J Surg.* 2013;56(1):58–64.
12. Van Der Meijden OA, Gaskill TR, Millett PJ. Treatment of clavicle fractures: current concepts review. *J Shoulder Elb Surg.* 2012;21(3):423–429.
13. King PR, Basamania CJ, Lamberts RP. A Novel Intramedullary Locked Fixation Device for Treatment of Clavicle Shaft Fractures. *JBJS Essent Surg Tech.* 2016;6(1):e8.
14. Allman FL. Fractures and ligamentous injuries of the clavicle and its articulation. *J Bone Joint Surg Am.* 1967;49(4):774–784.
15. Hudak PL, Amadio PC, Bombardier C. Development of an upper extremity outcome measure: the DASH (disabilities of the arm, shoulder and hand) [corrected]. The Upper Extremity Collaborative Group (UECG). *Am J Ind Med.* 1996;29(6):602–608.
16. Constant CR, Murley AH. A clinical method of functional assessment of the shoulder. *Clin Orthop Relat Res.* 1987;(214):160–164.
17. Gummesson C, Atroshi I, Ekdahl C. The disabilities of the arm, shoulder and hand (DASH) outcome questionnaire: longitudinal construct validity and measuring self-rated health change after surgery. *BMC Musculoskelet Disord.* 2003;16;4:11.

18. Franchignoni F, Vercelli S, Giordano A, Sartorio F, Bravini E, Ferriero G. Minimal clinically important difference of the disabilities of the arm, shoulder and hand outcome measure (DASH) and its shortened version (QuickDASH). *J Orthop Sport Phys Ther.* 2014;44:30–39.
19. Kukkonen J, Kauko T, Vahlberg T, Joukainen A, Aarimaa V. Investigating minimal clinically important difference for Constant score in patients undergoing rotator cuff surgery. *J Shoulder Elb Surg.* 2013;22:1650–1655.
20. Tamaoki MJS, Matsunaga FT, Costa ARFD, Netto NA, Matsumoto MH, Belloti JC. Treatment of Displaced Midshaft Clavicle Fractures: Figure-of-Eight Harness Versus Anterior Plate Osteosynthesis: A Randomized Controlled Trial. *J Bone Jt Surg Am.* 2017;99:1159–1165.
21. Woltz S, Krijnen P, Schipper IB. Plate Fixation Versus Nonoperative Treatment for Displaced Midshaft Clavicular Fractures. *J Bone Jt Surg.* 2017;99(12):1051–10517.
22. Cohen J. *Statistical Power Analysis for the Behavioral Sciences.* New Jersey: Lawrence Erlbaum Associates; 1988.
23. Gao Y, Chen W, Liu YJ, Li X, Wang HL, Chen ZY. Plating versus intramedullary fixation for mid-shaft clavicle fractures: a systemic review and meta-analysis. *Peer J.* 2016;4:e1540.
24. Calbiyik M, Ipek D, Taskoparan M. Prospective randomized study comparing results of fixation for clavicular shaft fractures with intramedullary nail or locking compression plate. *Int Orthop.* 2017;41:173–179.
25. Ferran N, Hodgson P, Vannet N, Williams R, Evans RO. Locked intramedullary fixation vs plating for displaced and shortened mid-shaft clavicle fractures: a randomized clinical trial. *J Shoulder Elb Surg.* 2010;19(6):783–789.
26. Liu H-H, Chang C-H, Chia W-T, Chen C-H, Tarng Y-W, Wong C-Y. Comparison of plates versus intramedullary nails for fixation of displaced midshaft clavicular fractures. *J Trauma.* 2010;69(6):E82–87.
27. Lee YS, Huang HL, Lo TY, Hsieh YF, Huang CR. Surgical treatment of midclavicular fractures: a prospective comparison of Knowles pinning and plate fixation. *Int Orthop.* 2008;32(4):541–545.
28. Zehir S, Zehir R, Sahin E, Calbiyik M. Comparison of novel intramedullary nailing with mini-invasive plating in surgical fixation of displaced midshaft clavicle fractures. *Arch Orthop Trauma Surg.* 2015;135:339–344.
29. Smekal V, Irenberger A, Struve P, Wambacher M, Krappinger D, Kralinger FS. Elastic stable intramedullary nailing versus nonoperative treatment of displaced midshaft clavicular fractures-a randomized, controlled, clinical trial. *J Orthop Trauma.* 2009;23:106–412.
30. Kettler M, Schieker M, Braunstein V, Konig M, Mutschler W. Flexible intramedullary nailing for stabilization of displaced midshaft clavicle fractures: technique and results in 87 patients. *Acta Orthop.* 2007;78:424–429.

## **SUMMARY AND CONCLUSIONS**

## Chapter 6

---



## CHAPTER SUMMARIES

The purpose of this chapter is to provide a short summary of the main findings of the previous 5 research chapters and to answer the overall research question of this thesis. As each chapter has its own discussion section the aim of this chapter is not to discuss the findings of each chapter.

### Chapter 1

#### **Management of clavicle shaft fractures with intramedullary devices: current concepts**

Chapter 1 presented a thorough overview of the literature with special emphasis on the intramedullary fixation of clavicle shaft fractures.

The research question was: Can the available literature shed light on whether intramedullary *or* extramedullary fixation of clavicle shaft fractures is superior?

The assumed hypothesis was that the literature would not be able to provide a clear answer to this research question.

Literature available on the topic of clavicle shaft fractures is extensive. The anatomy of the clavicle, as well as its anatomical variations, is well described.

The epidemiology of clavicle fractures is described, but almost exclusively within the context of developed countries. Although one available study does describe a Chinese population, no studies describe the epidemiology of patients presenting in Africa.

Clavicle shaft fractures were traditionally considered benign injuries and were treated conservatively with good results. Modern outcome-based studies propose a more aggressive approach to the treatment of displaced and shortened fractures. The topic remains controversial with numerous systematic reviews and meta-analyses providing conflicting conclusions. The literature seems to have come full circle. At one stage the available evidence seemed to clearly indicate that displaced and shortened clavicle shaft fractures should be treated surgically. However, some recent systematic reviews and meta-analyses seem to be challenging this belief. Current consensus is that each patient should be individualized in terms of fracture configuration and functional demand. Further high-quality research is needed to provide a definitive answer. What

has become clear is that clavicle shaft fractures are complex injuries and that it is unlikely that a single set of surgical indications could, or should, provide a definitive blueprint for treatment. The risks associated with operative fixation versus the risk of complications secondary to mal- and nonunion should be carefully weighed. In addition, the patient's age and functional demand should be considered.

It remains unclear which operative treatment modality is considered *the most effective*. Recent high-quality research studies maintain that there is no difference in outcomes between intra- and extramedullary fixation. The literature clearly addresses the unsuitability of K-wire and external fixation. The remaining modalities show similar effective outcomes with various positive and negative aspects associated with each.

Limited research has been conducted regarding the effectiveness of the Sonoma CRx device. Although early results are encouraging, there remains a dearth of long-term reviews and studies which compare this device to the current gold standard of treatment – extramedullary anatomically contoured locked plate fixation.

## **Chapter 2**

### **Fractures of the clavicle shaft – epidemiological study of patients treated at a tertiary hospital in South Africa**

Chapter 2 described the epidemiological profile of patients presenting with clavicle shaft fractures in a developing country.

The research question was: How common are clavicle shaft fractures in a tertiary hospital in South Africa and what is the epidemiological profile of these patients?

The hypothesis was that the epidemiological profile of patients presenting with clavicle shaft fractures in a *developing* country would differ from the epidemiological profile of patients presenting in a *developed* world context.

All patients presenting with clavicle shaft fractures to a tertiary hospital from 2008 to 2018 were identified. The patients' clinical notes were studied to determine: age, sex, lateralization, mechanism of injury and treatment rendered. Associated chest, abdominal and head injuries were noted. In addition, fractures incurred in association with the clavicle shaft fractures were determined. Patients' radiographs were studied

to determine fracture configuration and displacement. A total of 1 003 patients presenting with clavicle shaft fractures were reviewed retrospectively. Data were analyzed in accordance with: year of presentation, age, sex, mechanism of injury, neurovascular status, treatment rendered and associated injuries.

This epidemiological study is the first study, which described the profile of patients presenting with clavicle shaft fractures, in an African population. The profile of patients presenting in an urban African hospital differs from the profile of patients presenting in developed European countries. In the population studied, numbers are heavily skewed toward male and younger patients whilst incidences in elderly patients are very low. The mechanisms of injury differ from studies done in developed countries. Fractures predominantly occur secondary to motor vehicle accidents and falls and are rarely secondary to sporting activities. A significant number of fractures are caused by interpersonal violence including gunshots. Open fractures after non-penetrating trauma are exceptionally rare. Neurological and vascular injury, secondary to the fracture, is also exceptionally rare. In this review patients frequently presented with other injuries apart from the clavicle shaft fracture. Potentially life-threatening injuries commonly accompany clavicle shaft fractures if the fracture was sustained in a road traffic accident or secondary to interpersonal violence.

### **Chapter 3**

#### **The treatment of clavicle shaft fractures with an innovative locked intramedullary device**

Chapter 3 described the use of a novel intramedullary device in consecutive patients presenting with displaced and shortened clavicle shaft fractures to determine the effectiveness of the device.

The research question was: Can the Sonoma CRx intramedullary nail successfully treat displaced and shortened clavicle shaft fractures presenting at a tertiary hospital in South Africa?

The hypothesis was that the device could be used effectively to treat displaced and shortened clavicle shaft fractures.

This study shows that the CRx intramedullary device could be used to successfully treat displaced and shortened clavicle shaft fractures, resulting in a 100% union rate. Good functional outcome scores and range of movement of the affected shoulders were also evident.

Forty-seven patients with displaced and shortened clavicle shaft fractures were treated with the Sonoma CRx device. The mean operating time and incision length were recorded and, upon comparison, found to be quicker and shorter than in the case of traditional plate fixation. This was attributed to the fact that the surgical access needed to implant the intramedullary device was less invasive.

No migration of the novel intramedullary device, a common concern with traditional intramedullary devices, was evident in this study. In addition, no protruding or irritating hardware was found during this review – a problem commonly associated with certain other intramedullary devices.

Three patients developed complications after implantation of the device. One patient contracted a superficial infection, which was successfully managed. Two patients presented with hardware failures where the device had fractured at the junction of the flexible and non-flexible portion. Other authors have reported hardware failures using the Sonoma device previously. In our view the hardware failure was secondary to an inferior surgical technique, as the device had not inserted far enough medially past the fracture site to thus provide sufficient fracture stability.

A 100% union rate was reported in this study. Patients were assessed either at 3 to 6, 6 to 9 or 9 to 12 months post-op at the time of review. Consequently, no conclusion could be drawn regarding the time needed for union, but the results of Group I (3 to 6 months post-op) suggests that the fractures fully unite within 6 months.

A longitudinal study, which encompasses a larger sample size, is needed to determine the exact time frame at which clavicle shaft fractures generally unite when using the CRx device.

The post-operative functional capacity of the shoulder was measured in accordance with the range of motion division of the Constant Shoulder Score, the Constant Shoulder Score as well as the DASH score. DASH and Constant Shoulder scores observed 3 to 6 months post-operatively were similar to the values noted in patients 6

to 9 and 9 to 12 months and were also comparable to the findings of other authors using intra- and extramedullary devices.

This finding seems to suggest that patients attain a good functional outcome soon after treatment, which does not improve further with longer follow-up.

The main limitation in the design of the current study is that the follow-up of patients occurred longitudinally, thus making it impossible to determine the effects over time. As the CRx device was not compared to a traditional plating technique, no conclusion could be reached as to the superior effectiveness of either nailing or plating of clavicle shaft fractures. Further research should include a randomized controlled trial to establish which method would be best for the treatment of displaced and shortened clavicle shaft fractures.

## **Chapter 4**

### **Surgical techniques: A Novel Intramedullary Locked Fixation Device for Treatment of Clavicle Shaft Fractures**

Based on experience gained in Chapter 3, Chapter 4 presented a detailed description of the surgical technique used to implant the novel Sonoma CRx device.

The research question was: Can a reproducible and safe surgical technique be described which would guide other surgeons to use a novel intramedullary device effectively?

The hypothesis was that such a technique can indeed be described, effectively communicated and distributed.

A surgical technique was described in detail and published along with instructional illustrations and videos. The article was structured as a step-by-step guide to help ensure successful implantation of the device. In addition, it presented indications and contra-indications for the use of the device and highlighted possible pitfalls and precautions to be taken when using the device.

The guide was written in such a way that a relatively inexperienced surgeon would be able to implant the device successfully, provided he/she follows the steps meticulously.

The CRx device has been associated with hardware failure in some publications. It has been our experience, as noted in Chapter 3, that inferior surgical technique together with misplacement of the device is largely to blame for this. The technique guide should negate this risk.

Alternative surgical techniques, with a medial entry point and placement of the locking screw at the medial aspect of the clavicle, have been described. A similar article, which describes this technique, would be useful in ensuring the successful use of the device.

## Chapter 5

### **The Effectiveness of a Flexible Locked Intramedullary Nail and an Anatomically Contoured Locked Plate to Treat Clavicular Shaft Fractures. A 1-Year Randomized Control Trial**

Based on the findings presented in earlier chapters, the aim of Chapter 5 was to compare the treatment outcomes of patients with clavicle shaft fractures randomly treated by: traditional anatomically contoured locked plating (extramedullary fixation) or the novel locked intramedullary device.

The research question was: How effective is the Sonoma CRx intramedullary nail compared to traditional anatomically contoured plating of shortened and displaced clavicle shaft fractures in achieving union and restoring the functional capacity of the shoulder?

The hypothesis was that the intramedullary device would, due to its unique properties, provide similar union rates in addition to yielding superior functional and cosmetic results when compared to traditional extramedullary fixation.

This randomized controlled trial compared the treatment of displaced and shortened clavicle shaft fractures with either an anatomically contoured locked plate or a flexible intramedullary nail locked into position with medial grippers and a lateral interlocking screw.

Patients were well randomized, with age, gender and fracture types similarly represented in both groups.

A 100% union rate was found in both groups.

In line with the findings presented in Chapter 3, the nailing group presented with a shorter surgical time, which reflects the less invasive nature of the surgical technique.

The incision needed to place the device was also smaller in the nailing group.

Shoulder function, as measured by DASH and CS scores, was similar at 6 weeks, 3 months and 6 months post-operatively. At 12 months post-operatively the DASH score in the nailing group was slightly better with only a moderate Cohen effect size. We concluded that it is not clinically relevant.

Similar to our findings in Chapter 3, hardware migration and prominent subcutaneous hardware were *not* encountered, as is commonly the case when using traditional intramedullary devices.

The DASH and CS scores observed in the plating group are in line with those rendered by studies involving similar and/or the same plate. DASH and CS scores reported in the flexible nail group of the present study tended to be better than those noted in the groups that employed rigid nails or pins.

These findings are in line with two other studies, which compared the novel device to anatomical, locked plating. These studies were less structured and inconsistent follow-up periods and surgical techniques were noted.

In this randomized study, only one hardware failure was noted in the intramedullary group. This failure, once again, occurred at the junction of the flexible and non-flexible portion of the medial end of the device. In the period since the pilot study, the treating surgeon has gained additional valuable experience. This experience, in turn, has resulted in an improvement of the surgical technique used when implanting the nail, thus leading to less hardware failure. This confirms the conclusion reached in Chapter 4 that the failure of the nail is closely related to poor surgical technique.

The limitation of this study is that the same surgeon, experienced in the use of both devices, performed all surgical procedures. Although the use of a single surgeon could be considered a confounding factor, it does minimize possible variations in surgical techniques, which exists when different surgeons perform the procedures. We feel that this study accurately compared the different devices without being subjected to variances, which might result from inferior surgical techniques. The surgeon featured in this study had extensive experience implanting the nail. However, other surgeons

less familiar with the device might experience slightly longer surgical times and potentially more complications.

In conclusion, both the Acumed pre-contoured locked plate and the Sonoma CRx intramedullary nail effectively treated displaced and shortened clavicle shaft fractures, resulting in a union rate of 100% in both groups. Similar DASH and CS scores were observed at one and a half, three and six months. DASH scores at 12 months were better in the nailing group, although individual responses indicated that this finding might not be clinically meaningful.

Overall, we conclude that both devices can be used to effectively treat displaced and shortened clavicle shaft fractures. The locked intramedullary device holds potential advantages including the absence of prominent subcutaneous hardware and a better cosmetic result due to smaller incisions.



## THESIS RESEARCH QUESTION AND CONCLUSION

The over-arching research question of this thesis was:

Is the Sonoma CRx intramedullary nail able to achieve union and restore function of the affected shoulders in patients sustaining displaced and shortened clavicle shaft fractures and is it as effective as treating these fractures with anatomical contoured locked plating?

The review of the literature in Chapter 1 found that the management of clavicle shaft fractures remains a controversial issue with contradicting evidence supporting the conservative and invasive treatment of displaced and shortened fractures. This thesis does not focus on whether surgical or non-surgical management provides the best treatment outcome. For the purpose of this thesis surgical management of displaced and shortened fractures was believed to be treatment of choice. Displacement and shortening of the clavicle shaft fracture was the indication for surgery in both Chapter 3 and 5. Secondly, Chapter 1 could not provide a clear indication as to whether intra- or extramedullary fixation of clavicle shaft fractures provides the best outcomes. This was the focus of this thesis.

To determine whether displaced and clavicle shaft fractures are prevalent in the proposed community to be studied in the later treatment studies, an epidemiological study was done. Chapter 2 found clavicle shaft fractures to occur in 1003 patients over a 10-year period. The epidemiological profile of these patients as well as the incidence of secondary injuries complicating these fractures was determined. The percentages of patients with clavicle shaft fractures that are displaced as well as the incidence of different degrees of comminution of the fractures were determined.

Chapter 3 served as a pilot study to determine whether the novel intramedullary device could be used effectively to treat displaced and shortened clavicle shaft fractures. This case series determined the device to be effective, resulting in a 100% union rate and functional outcome comparable to other fracture fixation devices used in the treatment of clavicle shaft fractures. However, this study was not designed to compare the novel device to alternative treatment modalities.

The surgical technique needed to implant the device was found to be challenging in Chapter 3. Hardware failure was found in 2 patients with similar complications identified in other studies using the novel intramedullary device. One of the

conclusions of Chapter 3 was that inferior surgical technique implanting the intramedullary device leads to hardware failure. Chapter 4 aimed to describe the surgical technique needed to implant the device based on the experience gained in Chapter 3. This allows for a uniform, effective surgical technique in order to avoid treatment failure secondary to surgical error.

Chapter 5 compared anatomically contoured locked plating and the novel intramedullary device in a randomized controlled trial treating well randomized patients with displaced and shortened clavicle shaft fractures. This study found a 100% union rate in both groups and similar functional outcomes.

This provides level 1 evidence to answer the research question of this thesis - the novel locked intramedullary device is as effective in treating displaced and shortened clavicle shaft fractures as anatomically contoured locked plating.

### **Recommendations and future research**

This series of studies done to assess the effectiveness of a novel intramedullary device found the device to be as effective as anatomically contoured locked plating in achieving fracture union and restoring shoulder function.

The literature review highlighted certain deficiencies in the available literature and controversies that continue to exist.

High quality research is needed to effectively determine whether conservative or surgical management is the best treatment modality for displaced and shortened clavicle shaft fractures. At one point, the literature was fairly conclusive regarding the superior outcomes achieved with surgical management, but recently some contradicting evidence has been published. Level 1 evidence currently available comparing operative and non-operative treatment of displaced and shortened fractures does not differentiate between young, active individuals and more sedentary ones. Prospective, randomized multi-centre studies are needed which differentiate between patients with different functional demands, levels of physical activity and occupation.

It is possible that conclusions drawn from treatment studies would be strengthened by studies describing the functional and cosmetic disabilities of patients treated conservatively that develop non-unions and malunions. Prospectively gathered data

regarding the functional and cosmetic disabilities suffered by individuals with displaced and shortened fractures, which develop non- and malunions, need to be analysed in well-structured trials. The effect of the anatomical deformity of the shoulder girdle due to shortening of the clavicle needs to be assessed innovatively. Yet again, there needs to be distinguished between physically active, young individuals and more sedentary ones.

The available literature has not been able to determine whether intra- or extramedullary fixation of clavicle shaft fractures is superior. This thesis concludes that both a novel, locked intramedullary nail and anatomical contoured locked plating will result in fracture union and restoration of shoulder function. At a clinical level, the RCT study showed slightly less variability in functional outcome when using the intramedullary nail, while Cohen effect sizes (see also Fig. 5.3) were also slightly better using this device.

As both devices are effective in treating displaced and shortened clavicle shaft fractures, future research studies should focus on determining patient and fracture variables that could lead to superior outcomes using a specific treatment modality. Patient factors would include: age, expectations regarding cosmetic result, speed of return to normal activity, occupation and functional demands. Fracture variables, including the specific position of the fracture within the clavicle shaft as well as fracture comminution, should be studied to determine whether it could be a determinant of outcome using either device.

These studies need to include the incidence of secondary surgeries to remove hardware and the impact of the second operations – both economically and functionally for the patient.

## Chapter 6

---

## **PRACTICAL IMPLICATIONS**

This thesis has shown that the Sonoma CRx intramedullary nail is as effective as anatomical contoured locked plating of displaced and shortened clavicle shaft fractures in achieving union and restoring shoulder function.

The two treatment modalities give similar union rates and functional outcomes. This implies that surgeons can use both devices with good results.

However, as shown in chapter 5, surgical time needed to implant the intramedullary nail, when the surgeon is experienced with this device, is shorter than the anatomical contoured locked plate.

It was also shown in Chapter 5 that the surgical wound needed to implant the intramedullary nail is smaller than the one needed to implant the plate. The smaller surgical wound likely would result in a more pleasing cosmetic result. Similarly, the absence of prominent subcutaneous hardware when the intramedullary device is used may also lead to a better cosmetic result.

A high rate of secondary operations to remove hardware is commonly described in studies where either of the treatment modalities is used. In the case of intramedullary devices, the reason for removal of the devices is prominent subcutaneous hardware at the insertion site and the risk of hardware migration. Both these complications were not encountered during the studies described in this thesis. Potentially using the CRx device will negate the need for a second operation. Surgical time is extremely expensive and specifically in a resource poor environment, such as the one where these studies were done, in very short supply. In this setting the luxury of a second operation to remove prominent hardware is not feasible. It may be a very positive aspect of intramedullary fixation using the Sonoma device if second operations can be avoided. Valuable theatre time can then be better utilized.

Overall, the findings of this thesis show that both the anatomical plate and the Sonoma locked intramedullary nail can be used effectively to treat displaced and shortened clavicle shaft fractures. The intramedullary nail holds the advantages of a better cosmetic result and a potential economic benefit due to the avoidance of secondary operations to remove hardware.

## Chapter 6

---