

# Improving the Longevity and Results of Mastopexy and Breast Reduction Procedures: Reconstructing an Internal Breast Support System with Biocompatible Mesh to Replace the Supporting Function of the Ligamentous Suspension

Petrus V. van Deventer · Frank R. Graewe ·  
Elisabeth Würinger

Received: 16 May 2011 / Accepted: 16 October 2011  
© The Author(s) 2011. This article is published with open access at Springerlink.com

## Abstract

**Background** The reasons for recurrent ptosis in mastopexy and breast reduction procedures are twofold. First, available surgical techniques do not reconstruct the normal breast anatomy responsible for maintaining breast shape. Second, in many instances the techniques rely on atrophied tissue to provide long-term support. The discovery in 1997 of the ligamentous suspension (the supporting system of the breast) gave rise to the concept that reconstruction of this anatomical structure was needed to ensure a sustained postoperative result. Applying the latest knowledge regarding the structural and vascular anatomy of the breast in the surgical technique and utilizing material other than atrophied breast tissue enabled us to prevent the recurrence of breast ptosis.

**Methods** A surgical technique was developed to replace the supportive function of a failed ligamentous suspension in 112 patients with ptotic breasts. This was done by

reconstructing an internal breast-supporting system (IBSS) with biocompatible mesh.

**Results** Satisfactory breast shape, nipple projection, and upper breast fullness was obtained with this technique in mastopexy patients with moderate-sized ptotic breasts. In patients with larger breasts good results were obtained with a simultaneous breast reduction. The longest follow-up is 6 years 3 months.

**Conclusions** With this technique recurrent breast ptosis can be prevented in mastopexy and breast reduction procedures. The results are such that it eliminates the need for silicone prostheses to obtain satisfactory upper-breast fullness. The surgical technique is especially indicated in patients with skin of poor quality or patients with high expectations.

**Keywords** Breast ptosis · Mastopexy · Breast reduction · Ligamentous suspension · Internal breast support system (IBSS) · Internal bra

---

Presented at the Annual General Meeting of the Association of Plastic and Reconstructive Surgeons of South Africa combined with the 5th Pan African Congress, Natal, South Africa, 22–26 October 2006; International Society of Aesthetic Plastic Surgery, Cape Town, South Africa, 17–19 March 2007; International Society of Aesthetic Plastic Surgery, Melbourne, Australia, 10–13 February 2008; and British Association of Aesthetic Plastic Surgeons, London, UK, 22–23 September 2010.

---

P. V. van Deventer (✉) · F. R. Graewe  
Division of Plastic and Reconstructive Surgery, Faculty of  
Health Sciences, University of Stellenbosch, Tygerberg Campus,  
Bellville, Western Cape, South Africa  
e-mail: peet@breastsurgery.co.za;  
peetvandeventer@telkomsa.net

E. Würinger  
Department of Plastic and Reconstructive Surgery,  
Wilhelminenspital, Vienna, Austria

Breast ptosis is a result of weakening and lengthening of the supporting structures of the breast. In most instances current mastopexy procedures to correct ptosis rely on atrophied tissue for support. Understandably, this may result in recurrent ptosis and unsatisfactory long-term appearance. Previous attempts to prevent recurrent ptosis, utilizing materials other than atrophied tissue, did not stand the test of time [1, 2], probably because of the disregard of the normal breast anatomy.

In his personal mammoplasty technique, Goés [3–7] has used mesh as a support since 1988 and reported good results with minimal complications. His periareolar double-skin technique entails insertion of mesh that evokes connective tissue formation that functions as ligaments of Cooper. Recently, De Bruijn and Johannes [8, 9] used a preshaped polyester mesh for breast support. The disadvantage of their

technique is the fixed shape of the mesh, available in only four sizes, which limits the cosmetic results otherwise obtainable.

With inferior pedicle techniques, the maintenance of the breast shape relies mainly on the skin envelope and post-operative stretching results in recurrent ptosis. Skin tension to maintain breast shape, transferred onto the suture lines, may result in obvious scars as well.

New concepts of the structural anatomy of the breast have opened the door to combat these complications effectively. The ligamentous suspension of the breast, discovered and described by Würinger [10, 11], acts as a hammock to support the breast and is of much greater importance than the ligaments of Cooper. Reinforcement of the failed ligamentous suspension in the ptotic breast using a nonabsorbable biocompatible material can offer a long-term solution to the ptotic breast.

The aim of this study was to show that replacement of the failed ligamentous suspension with an internal breast-supporting system (IBSS) consisting of biocompatible, nonabsorbable mesh will prevent recurrent ptosis. A second goal was to obtain optimal and long-lasting breast shape, nipple projection, adequate upper-breast fullness, and inconspicuous and well-located short scars.

## Pertinent Anatomy

### Blood Supply

Success of breast surgery depends on ensuring adequate blood supply. The most reliable source is the internal

thoracic–anterior intercostal system by means of perforators 1–4 of the internal thoracic artery and the inferior mammary branches of the fourth to sixth anterior intercostal arteries, as described by van Deventer [12, 13] (Fig. 1).

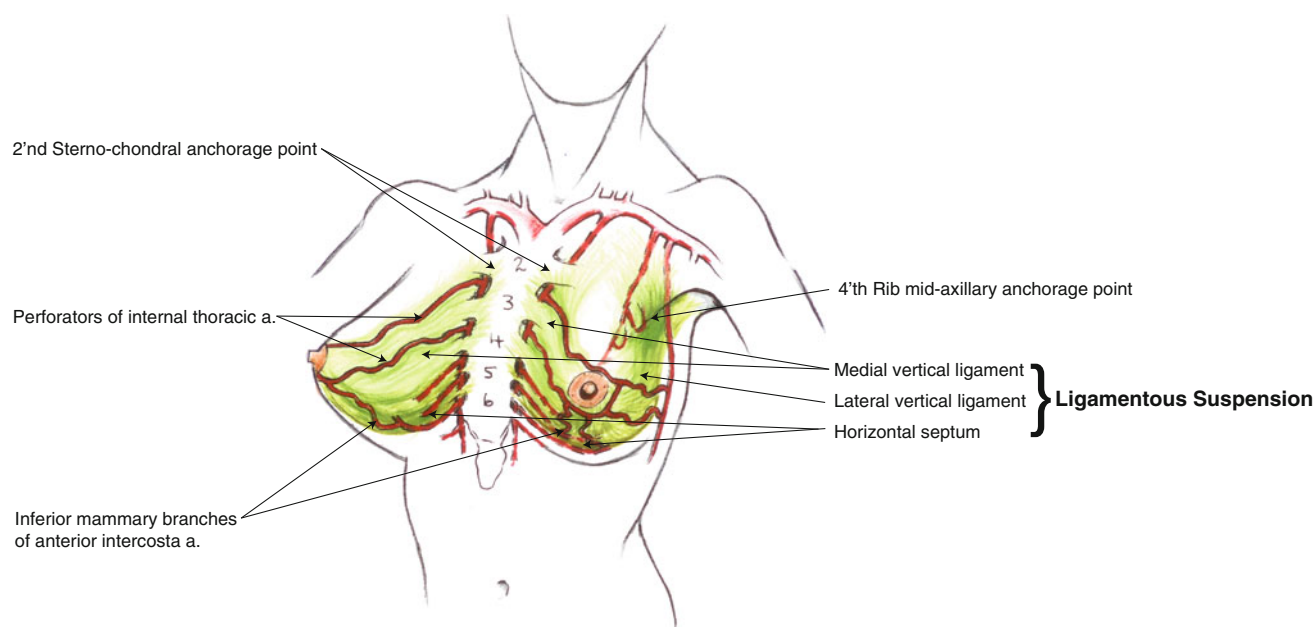
### Supporting System

The main supporting system of the breast is the ligamentous suspension as described by Würinger [10, 11]. This anatomical structure is U-shaped and attached to the thoracic cage. At its lower part it stretches from the fifth rib to the nipple as a horizontal septum and, in continuation, extends medially and laterally upward as vertical ligaments. It is attached medially to the sternum as high as the manubrium and laterally along the lateral border of the pectoralis minor muscle to the chest wall into the axilla; it supports the breast like a hammock (Fig. 1).

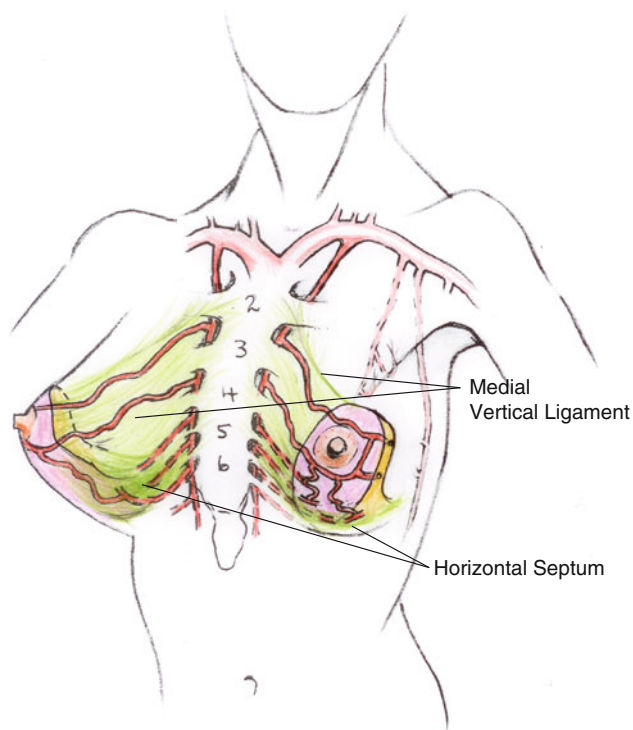
The neurovascular supply is guided by the ligamentous suspension, acting like a mesentery, as shown by Würinger [11]. The branches of the anterior intercostal arteries course in the horizontal septum. The medial and lateral vertical ligaments guide the perforating branches of the internal thoracic artery and the branches of the lateral thoracic artery, respectively [11].

### Application of the Relevant Anatomy

It is the authors' opinion that reliance on a postero-inferomedial pedicle with inclusion of the horizontal septum and medial vertical ligament is the optimal pedicle choice



**Fig. 1** Schematic presentation of the ligamentous suspension (*in green*) with the relevant blood supply. The anchor points of the mesh to the *fourth* rib in the midaxillary line and to the *second* sternochondral junction are indicated



**Fig. 2** Schematic presentation of the postero-inferomedial pedicle and its blood supply

in mastopexy and breast reduction procedures (Fig. 2) [13, 14]. Meticulous surgery allows preservation of the perforating branches of the internal thoracic artery in the medial vertical ligament and the inferior mammary branches of the anterior intercostal arteries in the horizontal septum.

## Materials and Methods

Approval for this study was obtained from the ethics committee of the Faculty of Health Sciences at the University of Stellenbosch, Western Cape, South Africa (project No. 04/03/053). The foundation to this work was laid in two stages. It consisted of anatomical studies followed by surgical procedures in a clinical trial in the human model.

### Preoperative Research

#### *Cadaver Study*

The aim of the cadaver study was to develop a surgical technique for insertion and attachment of a mesh to the chest wall to replace the function of the ligamentous suspension. The technique should cause the least damage to the neurovascular supply and minimal scarring.

Four breasts were dissected. In two breasts the standard Wise-skin incision was used, and in the other two, an incision along the superolateral areolar margin and a 5-cm incision in the lateral submammary crease were used. From the incision sites, subcutaneous dissection planes were created to expose the anatomical areas where the ligamentous suspension attaches. The perforator branches of the internal thoracic artery, emerging one-finger-breadth lateral to the sternal border, could be kept intact, attached to the nipple-bearing pedicle. The branches of the lateral thoracic artery had to be transected to expose the superolateral thoracic wall adequately. It was possible to obtain adequate exposure for attachment of the mesh using the periareolar submammary incisions. However, it was easier with the standard Wise skin incision.

This technique ensured a robust blood supply to the pedicle and nipple-areola complex. A U-shaped mesh was utilized that created a cone on overlapping the arms. It was anchored to the chest wall on areas corresponding to the attachment of the ligamentous suspension. By exerting tension on the mesh and altering the amount of overlap, different breast shapes could be created.

### *Patient Pilot Study*

The purpose of the study, including the risks and potential complications, was explained to 15 trial patients. They were all post-child-bearing, healthy patients without a history of bleeding tendencies or infection. Voluntary, informed, written consent was obtained from all the patients. The ages of the patients ranged from 27 to 62 years (mean = 37.8 years).

Biocompatible mesh was implanted in seven patients during a mastopexy procedure and in eight patients with reduction procedures, of which four were unilateral. Patients who underwent unilateral mesh implants had very large breasts with related symptoms and did not care about the cosmetic outcome of the procedure, they only wanted symptomatic relief.

The mesh consisted of equal amounts of nonabsorbable polypropylene and absorbable polyglactin (Johnson & Johnson, c/o European Logistics Centre, St-Stevens-Woluwe, Belgium).

### *Results*

Patient data and results are given in Table 1. In the mastopexy group, two patients were very satisfied with the result and two were satisfied. Two patients were dissatisfied due to poor breast shape with minimal improvement and recurrent ptosis. Both patients had large hypertrophic breasts. One patient was dissatisfied because of bilateral loss of nipple sensation.

**Table 1** Patient pilot study

No.	Age	Bra size	Preop measurements (cm)				Postop measurements (cm)				Complications	Patient satisfaction			
			SN-N		N-SF		SN-N		N-SF						
			R	L	R	L	R	L	R	L					
<b>A. Mastopexy patients with mesh implantations</b>															
1	34	36C	27	27	8	9	23	23	23	9	9	9	None	Very satisfied	
2	32	34B	24	23	9	9	22	21	21	8	8	8	None	Satisfied	
3	40	36C	27	28	9	8	25	26	26	10	9	9	None	Satisfied	
4	39	36DD	30	30	13	12	28	29	29	12	12	12	Recurrent ptosis	Not satisfied	
5	32	36C	26	26	8	8	24	24	24	7	7	7	Bilateral loss of nipple sensation	Not satisfied	
6	31	38C	24	23	8	7	22	22	22	8	8	8	None	Very satisfied	
7	37	38C	28	28	10	10	26	26	26	10	10	10	Minimal improvement	Not satisfied	
No.	Age	Bra size	Breast mass excised (g)		Preop measurements (cm)				Postop measurements (cm)				Complications	Patient satisfaction	
			R	L	SN-N		N-SF		SN-N		N-SF				
			R	L	R	L	R	L	R	L	R	L			
<b>B. Breast reduction patients with bilateral mesh implants</b>															
1	39	34DD	260	270	28	28	10	10	21	21	21	9	9	Temporary loss of nipple sensation	Very satisfied
2	39	38DD	550	500	29	30	10	10	23	22	10	10	10	Infection	Satisfied
3	35	36D	250	250	27	27	9	9	21	21	8	8	8	None	Very satisfied
4	38	38F	300	300	30	30	10	10	22	22	10	10	10	Fat necrosis	Very satisfied
No.	Age	Bra size	Breast mass excised (g)		Preop measurements (cm)				Postop measurements (cm)				Complications	Patient satisfaction	
			R	L	SN-N		N-SF		SN-N		N-SF				
			R	L	R	L	R	L	R	L	R	L			
<b>C. Breast reduction patients with unilateral mesh implanted</b>															
1	23	42DD	1000	1000	32	33	14	14	22	22	11	11	L	None	Satisfied
2	46	38C	450	425	28	28	11	11	22	22	9	11	R	None	Satisfied
3	44	44DD	700	950	33	36	13	13	23	22	11	12	L	Fat necrosis	Satisfied
4	62	38D	200	160	30	29	9	9	23	25	10	10	R	None	Satisfied

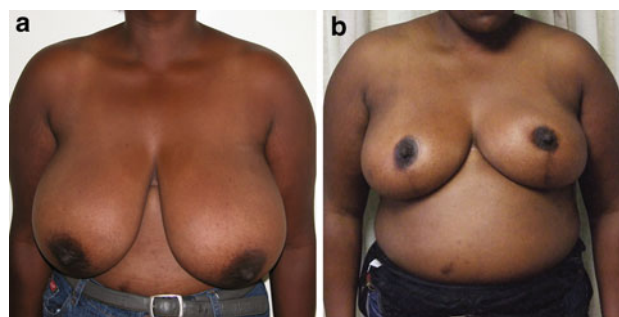
SN-N Supra-sternal notch to nipple distance, N-SF nipple to submammary fold distance, R right, and L left

In the reduction group with bilateral mesh implants, three patients were very satisfied and one was satisfied.

In the unilateral mesh-implanted breast reduction group, all four patients were satisfied. In two of them, 425 g or less of breast tissue was removed resulting in an improved breast shape in the mesh-implanted breast (Figs. 3, 4). In the other two patients, minimal improvement was observed in the mesh-implanted breast (Fig. 5). They had removal of 700 g or more of breast tissue per breast (Fig. 5).

**Complications**

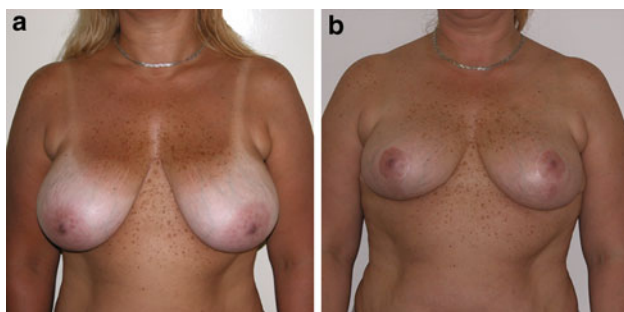
The complications encountered were comparable to those of conventional mastopexy and breast reduction procedures, as seen in Table 2. One patient developed a *Streptococcus milleri* infection resulting in a sinus that was successfully treated by exploration and partial excision of the mesh. One patient developed a breast lump that was surgically removed and the histology confirmed fatty



**Fig. 5** **a** Preoperative photo of a 23-year-old patient (BMI = 30) with gross breast hypertrophy (42DD cup bra size) scheduled for a breast reduction and a unilateral mesh implant in her left breast. **b** The same patient 4 years 10 months after a reduction of 1,000 g from each breast. Note the minimal improvement in the shape of the mesh implanted left breast

**Table 2** Complications of the pilot study of 15 patients (26 breasts)

Complications	Breasts	%
Loss of nipple sensation	2	7.6
Fat necrosis	2	7.6
Infection	1	3.8

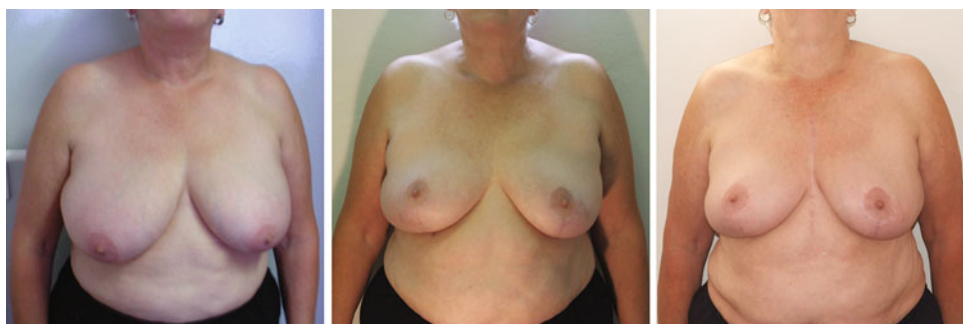


**Fig. 3** **a** Preoperative photo of a 46-year-old patient (BMI = 28) with breast hypertrophy scheduled for a breast reduction and a unilateral mesh implant in her right breast. **b** The same patient 1 year 6 months postoperatively after a reduction of 450 g from the right breast and 425 g from the left breast. Note the improved shape of the right breast

necrosis. Two patients developed bilateral loss of nipple sensation, one of which was only temporary.

**Conclusions**

Mesh implantation to function as a ligamentous suspension is successful in patients with moderate-sized ptotic breasts (B or C cup). In larger breasts (D cup or larger), simultaneous breast reduction is needed to obtain satisfactory results. Good results can be obtained if there is a need for excision of 550 g or less. In very large breasts (DD or larger), the results of mesh implantation are not ideal, and if more than 700 g needs to be excised, the procedure is of less benefit to the patient.



**Fig. 4** A 63-year-old patient (BMI = 31) with breast hypertrophy who had a breast reduction, which removed 200 g from the right breast and 160 g from the left, and insertion of an IBSS in the right breast only. A 2.5-year follow-up and a 6.25-year follow-up show

maintenance of the breast shape in the mesh-implanted breast. Note the smaller areola diameter and less conspicuous scars of the right breast. She was one of the trial patients and not an ideal patient for the procedure

## Operations Performed

From May 2004 to June 2009 a total of 112 patients were operated on (Table 3), including the 15 patients in initial pilot study. In two postmastectomy patients, the device was implanted in the opposite breast to match the reconstructed breast. In the pilot study group, four patients had breast reductions with unilateral implantation of the mesh. In total, 218 breasts were operated on (152 mastopexies and 66 reductions).

The average operating time was 3 h 20 min. The age of the patients was between 20 and 69 years (mean = 42.6 years). The body mass index was in the range of 20–39 kg/m<sup>2</sup> (mean = 25.3). All patients were healthy with no comorbidities. Exclusion criteria included bleeding disorders, infection of any kind, and breast disease. Smokers were instructed to stop smoking 3 months before surgery.

## Surgical Technique

### Preoperative Skin Markings

The new nipple position is identified with the patient in the upright position. The inferior areola border is marked on

**Table 3** Patient data

No. of patients operated	112	
Age at operation		
Range	20–69 years	
Mean	42.6 years	
Body mass index		
Range	20–39	
Mean	25.3	
Indications for surgery		
Breast ptosis	76	
Breast hypertrophy and ptosis	34	
Contralateral symmetrization	2	
Surgical procedures		
Total No. of breasts operated	218	
Mastopexy	156	
Breast reduction	62	
Mean preoperative measurements (cm)	Right	Left
Jugular notch to nipple	28.5	28.9
Nipple to submammary fold	9.7	9.8
Mean postoperative measurements (cm)	Right	Left
Jugular notch to nipple	21.7	21.8
Nipple to submammary fold	8.8	8.9
Breast mass resected (g)	Right	Left
Range	50–1,561	60–1,735
Mean	285	307
Follow-up time after operation		
Longest follow-up	6 years 3 months	
Mean	2 years 2 months	

the level of the submammary fold, just lateral to the mid-clavicular line and the nipple 2 cm higher. A modified Wise-pattern approach is used. By displacing the breast tissue medially and laterally, the vertical arms of the “keyhole” are determined and the marks continued from the future nipple position inferiorly to meet at a point 2 cm above the submammary fold.

### Exposure and Developing the Pedicle

In essence, the technique entails separation of the skin from the glandular component, exposing the anchoring points of the ligamentous suspension (Fig. 1). All the operations were performed with the patient under general anesthesia. Dissection planes were infiltrated with 10 ml 0.5% bupivacaine and 1:200,000 adrenalin diluted with 20 ml normal saline for each breast.

After deepithelialization, a medial flap approximately 1-cm thick is developed by incising the skin and subcutaneous tissue down to the anterior chest wall, extending from the submammary region to the level of the second sternochondral junction (Fig. 6a). A similar lateral flap is developed, exposing the lateral free border of the pectoralis major muscle (Fig. 6b). Superiorly, the dissection planes are then joined (Fig. 6c). Care must be taken that the medial vertical ligament remains attached to the anterior thoracic wall as part of the pedicle. The upper flap is beveled to become thicker until the pectoral fascia is reached. This thicker flap adds volume to the upper breast. Blunt dissection is performed superiorly, exposing the subclavicular pectoral fascia.

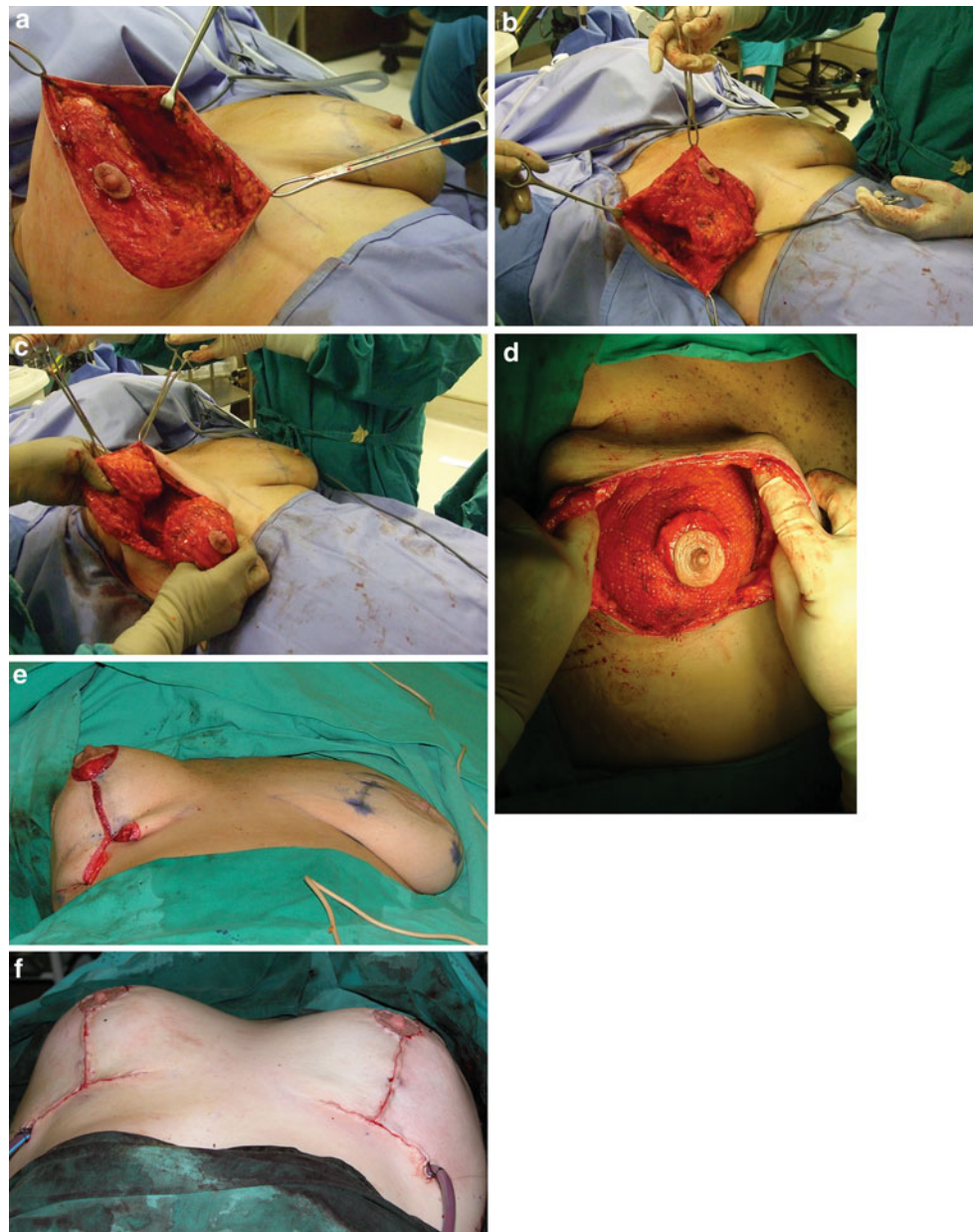
In the hypertrophied breast, the axillary tail and adequate breast tissue from the central mound are excised. A postero-inferomedial pedicle with an intact horizontal septum and medial vertical ligament is developed [13, 14] (Fig. 2). Meticulous hemostasis is obtained.

### Applying the Mesh

The lower part of the U-shaped mesh is attached in the submammary region with a 3/0 nonabsorbable suture to the periosteum of the fifth rib. Tension is exerted on the vertical arms of the mesh to avoid folds, and sutures are applied circumferentially, superiorly, fixing the mesh to the lateral thoracic wall. On reaching the midaxillary line, a nonabsorbable 1/0 suture is used to anchor the mesh to the periosteum of the fourth rib behind the free inferolateral border of the pectoralis major muscle (Fig. 1). Due to the slant of the ribs, this level is well above the level of the normal nipple position.

The same procedure is followed on the medial side, and superomedially an anchoring suture of the same material is passed through the perichondrium of the second

**Fig. 6** **a** Development of the medial flap from the submammary region superiorly to expose the anterior thoracic wall. The dissection must be superficial to the perforators in the medial vertical ligament that form part of the pedicle. **b** Development of the lateral flap to expose the lateral thoracic wall. Superiorly, the lateral free border of the pectoralis major muscle must be exposed. **c** Beveling the superior flap to become thicker toward the anterior chest wall. This procedure will add fullness to the upper breast postoperatively. **d** Intraoperative photo showing the cone of breast tissue created with the mesh. **e** Intraoperative photo illustrating the breast shape obtained with resultant dog-ears on skin closure. By increasing the length of the vertical suture line, the horizontal scar can be shortened to be limited to the inframammary fold. **f** After excision of the dog-ears and final closure of the flaps with the horizontal scar limited to the submammary crease



sternochondral junction (Fig. 1), creating a supporting hammock. The vertical arms of the mesh are overlapped until a satisfactory breast shape is obtained, and the mesh is attached to the subclavicular pectoral fascia for additional support. A cone of mesh-supported breast tissue, thus created with medial and lateral vertical vectors, is attached to the chest wall (Fig. 6d). The same procedure is repeated on the opposite breast and evaluated for symmetry.

#### Closure

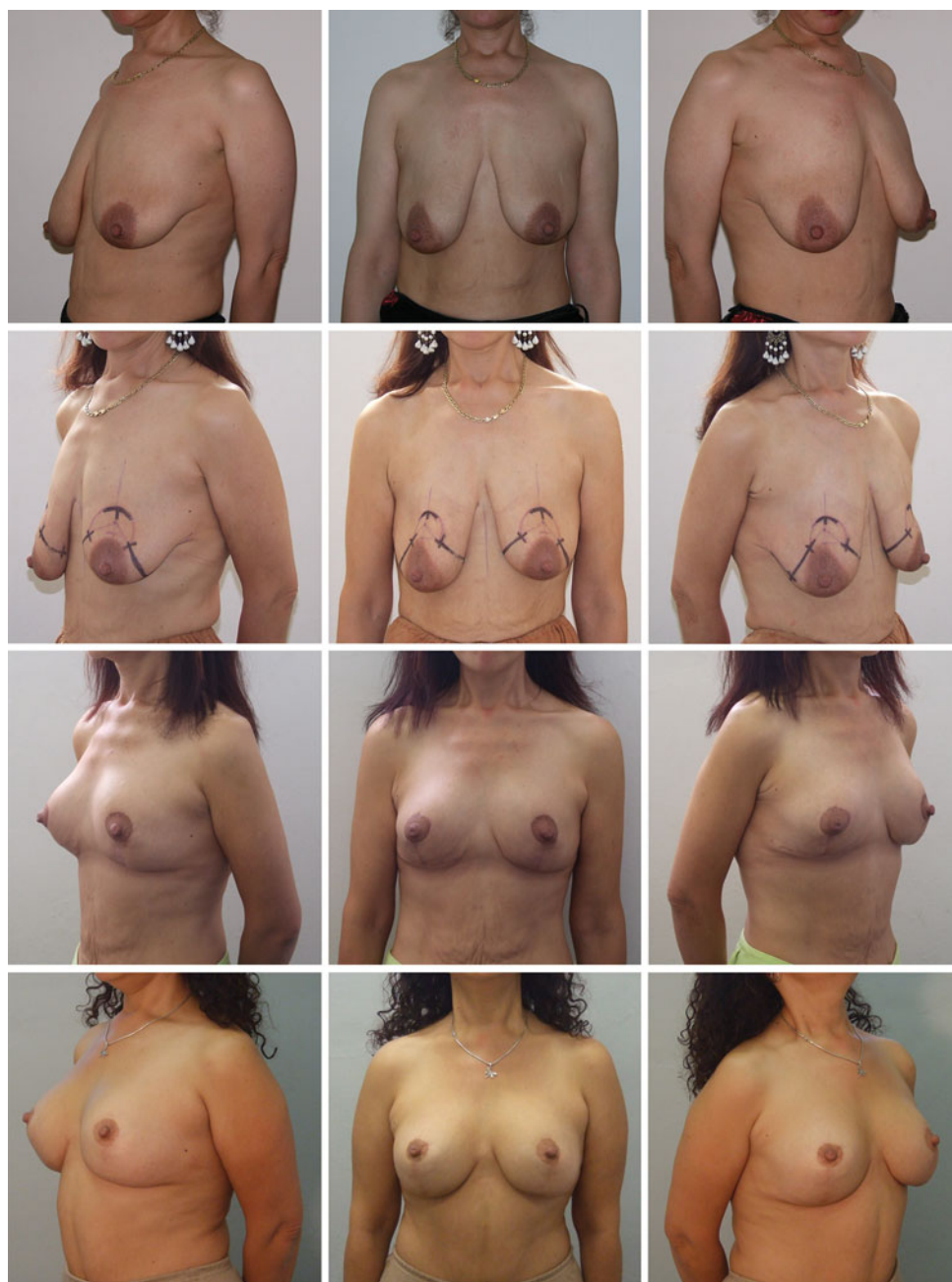The skin flaps are draped over the breast cone and sutured with minimal tension using subcutaneous and subcuticular 3/0 absorbable sutures. If excessive skin (dog-ears) needs

to be removed, the length of the vertical incision line is increased to limit the horizontal scar to the submammary crease (Fig. 6e, f). The nipple–areola complex is sutured with four subcutaneous sutures to obtain even tension followed by a subcuticular suture. Suction drains are used routinely and removed on the first postoperative day. Intraoperatively, the patients receive an intravenous antibiotic (cefuroxime 1.5 g).

#### Postoperative Care

Patients preferably were kept in the hospital overnight. They were warned that this procedure is more painful than the conventional techniques due to the fact that the mesh is

**Fig. 7** A 38-year-old patient (BMI = 23) with severe breast ptosis and poor-quality skin who had mastopexy and reconstruction of an internal breast support system (IBSS) with biocompatible, nonabsorbable mesh to replace the supportive function of the ligamentous suspension. Postoperative result at 5 months (3rd row) and follow-up at 3 years 8 months (4th row) with adequate upper-breast fullness, good nipple projection, and inconspicuous, well-located, short scars. Although the patient gained weight after surgery, the result is still satisfactory without recurrent ptosis



anchored to the chest wall. The recovery period may be longer as well. In some patients, discomfort lasted 6 weeks postoperatively. For this reason they were instructed to wear firm breast support and to refrain from strenuous physical activities during this period. Patients were followed up after 1 week, 3 months, 6 months, and annually thereafter.

## Results

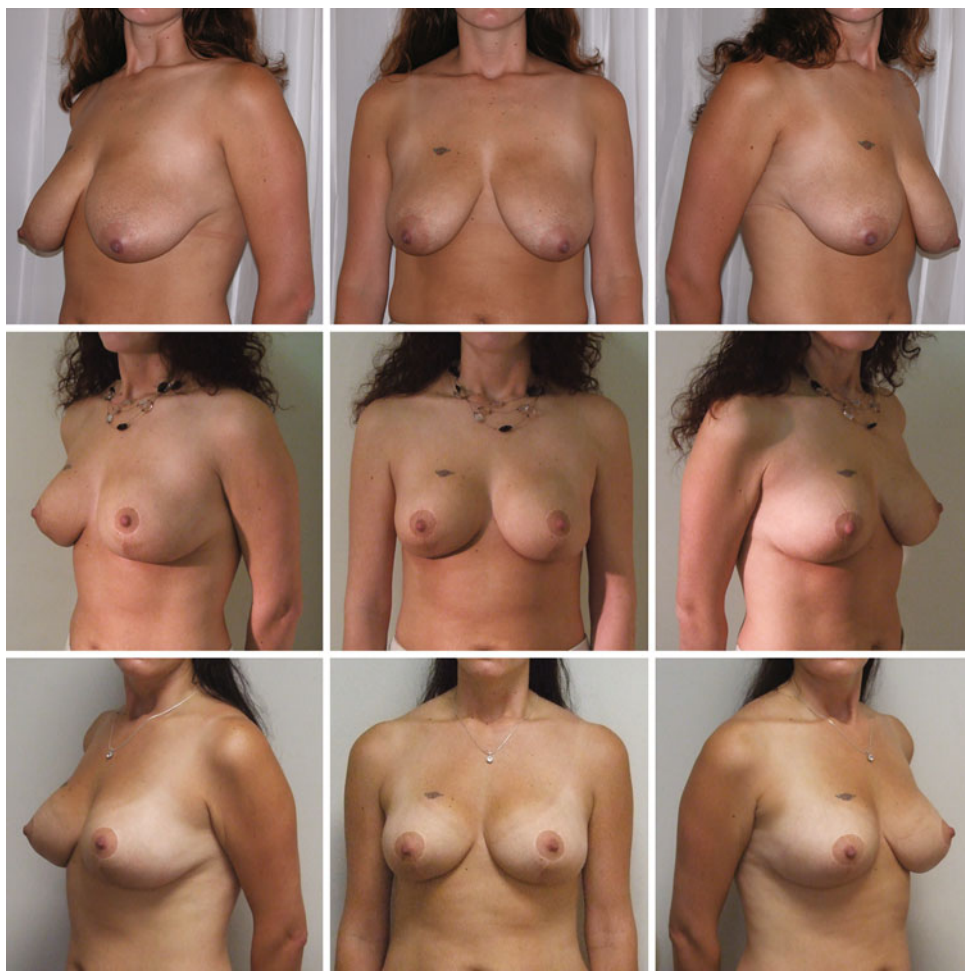Patient characteristics and surgical data are summarized in Table 3. Satisfactory long-lasting breast shape, nipple

projection, and upper-breast fullness were obtained in most patients (Figs. 7, 8, 9, 10, 11). A coincidental decrease in areola diameter was observed, seen in most patients from 1 year postoperatively (Fig. 12). One patient lost 10 kg of body mass postoperatively, resulting in a decrease in breast volume but without recurrent ptosis (Fig. 13).

Patients in the pilot study group with unilateral mesh implants, and in whom less than 550 g was excised, revealed long-term maintenance of breast shape in the mesh-implanted breast (Figs. 3, 4). On the other hand, in those patients in whom 700 g or more was excised, very little difference was observed postoperatively between the



**Fig. 8** A 32-year-old patient (BMI = 21) who had breast reduction and reconstruction of an IBSS with mesh. A mass of 160 g was excised from the right breast and 180 g from the left. The postoperative result at 10 months (*middle row*) and follow-up at 3 years 4 months (*bottom row*)



mesh-implanted and contralateral breasts. The longest follow-up is 6 years 3 months (mean = 2 years 2 months) (Table 4).

## Discussion

Results in plastic surgery can be improved by application in the surgical technique of principles based on normal anatomy. The described technique is based on recent discoveries in breast anatomy. Reconstructing a structure to replace the supporting function of the ligamentous suspension resulted in aesthetically pleasing and long-term results (Figs. 7, 8, 9, 10, 11, 12).

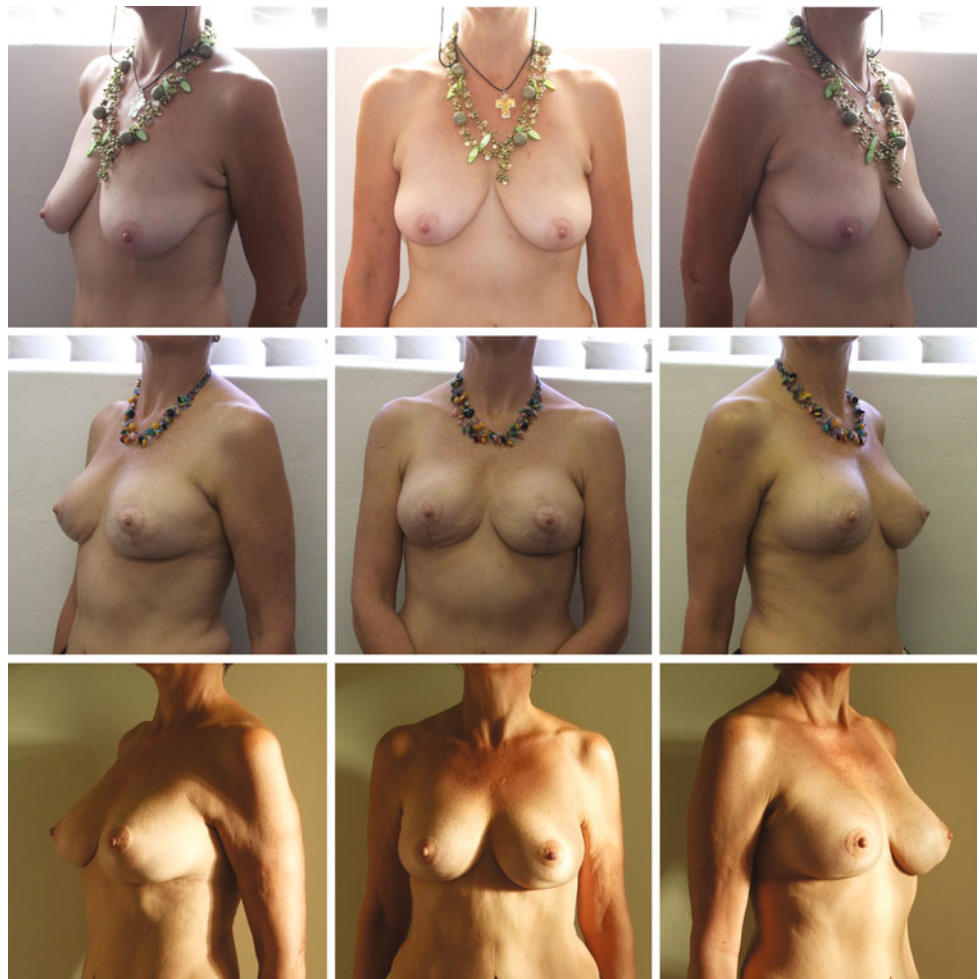The observation of a decrease in areola diameter postoperatively (Fig. 12) is an indication that the mass of the breast parenchyma is effectively supported by the mesh. The mesh replaces the ligamentous suspension and releases the skin from the function of maintaining breast shape postoperatively. Due to its inherent elasticity, skin shrinkage results in the decreased areola diameter. Another indication of the effective breast support function of the

mesh is noted in the patient who lost 10 kg of body mass: despite reduction in breast volume, she did not develop recurrent ptosis (Fig. 13).

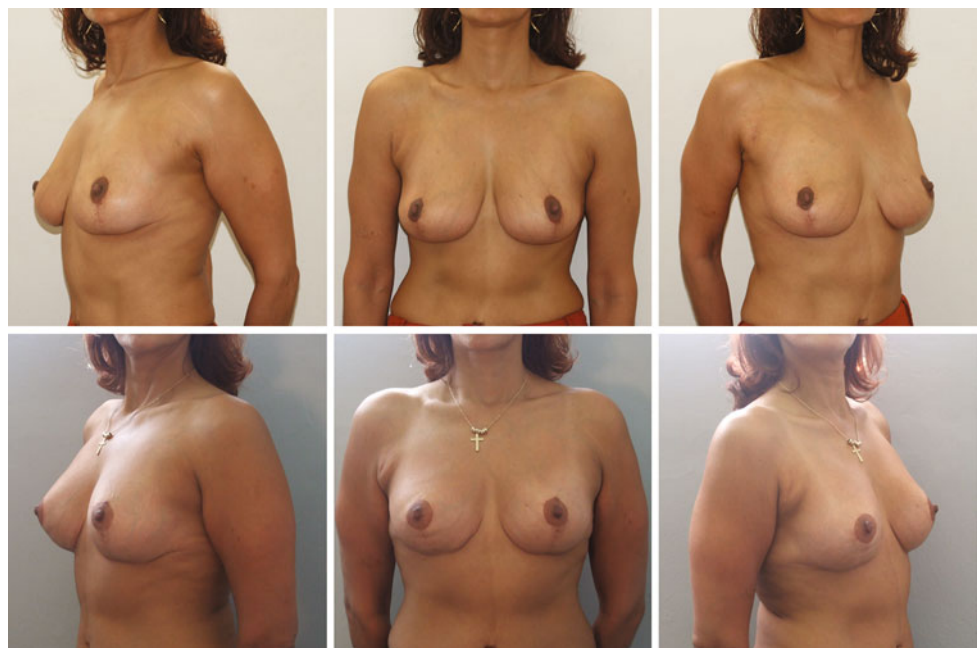
The breast mass is an important factor in the success of the procedure. With inadequate breast volume the results will be suboptimal. On the other hand, if the breast mass to be supported by the mesh is too large, the results may not be satisfactory. Therefore, for optimal results large breasts must be reduced when applying the mesh. If in these instances the remaining breast mass is less than 550 g, good results can be obtained. In patients with gross breast hypertrophy, where more than 1,000 g per breast must be excised, the insertion of mesh will not be beneficial to the patient. It is the first author's opinion that these patients do better, functionally as well as cosmetically, with a free nipple graft procedure. It is also recommended that overweight patients should obtain a normal body mass index preoperatively to obtain satisfactory results for obvious reasons.

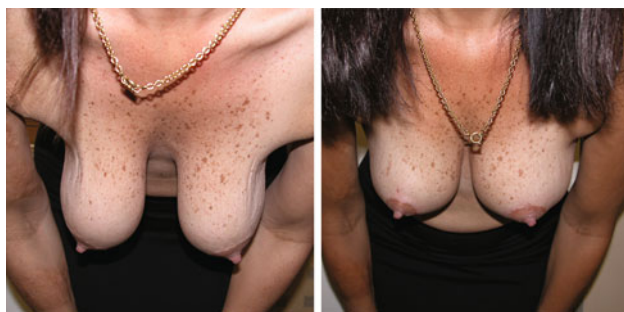
In the many years of performing mastopexy and breast reduction procedures, the first author could never obtain the cosmetic results comparable with those obtainable with the

**Fig. 9** A 55-year-old patient (BMI = 23) who underwent mastopexy and reconstruction of an IBSS with mesh. The 2-month postoperative result (*middle row*) and follow-up at 3 years 6 months (*bottom row*). Note the skin creases in the lower pole of the breasts in the early postoperative stage and improvement as result of skin shrinkage with time



**Fig. 10** A 48-year-old patient (BMI = 20) who had a conventional inferior pedicle reduction but was unhappy because of loss of upper-breast fullness and slight pseudoptosis. A reoperation with reconstruction of an IBSS with mesh was done to solve the problem and 3-year postoperative results are shown in the bottom row





**Fig. 11** Pre- and postoperative photos of a 39-year-old patient who had mastopexy and reconstruction of an IBSS. Bending forward illustrates the supportive function of the mesh to counteract the effect of gravity

“internal breast support system” technique. The procedure is ideally suited for the post-child-bearing patient with ptotic breasts and an adequate amount of breast tissue. The procedure does not enlarge the breasts but gives the illusion of an enlarged breast due to the more youthful shape and upper-breast fullness obtained. Should the patient request enlargement, fat grafting would be an option to consider 3 months after the insertion of the mesh. This technique avoids the need for augmentation of the upper pole of the breast with silicone prosthesis and the potential risks of combining mastopexy with an augmentation procedure.

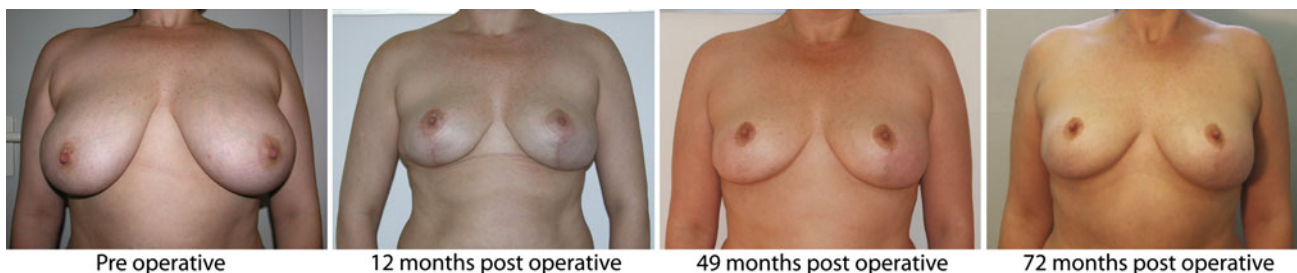
The infection complication rate of 0.91% in this series compares well with infection rates when utilizing silicone

prostheses. Khan [15] reported infection rates of 1.2% superficial and 0.52% periprosthetic in 3,256 breast augmentations over a period of 10 years. Goés [7] applied mesh in breast procedures and reported on the safety thereof, as did de Bruijn and Johannes [8, 9].

The learning curve for this technique is long due to the care to be taken when anchoring the mesh to obtain optimal results and symmetry; however, the final result is most gratifying to both patient and surgeon. At a later stage (July 2009 to November 2010, not included in this series) a preshaped polyester mesh (Aspide Medical, La Talaudiere, France) was used as well in 22 patients (44 breasts) (Fig. 14). It was easier to implant. The learning curve was shorter and the operating time decreased by approximately 20 min, with an average theatre time of 3 h.

**Table 4** Complications in 218 breast procedures with mesh implants

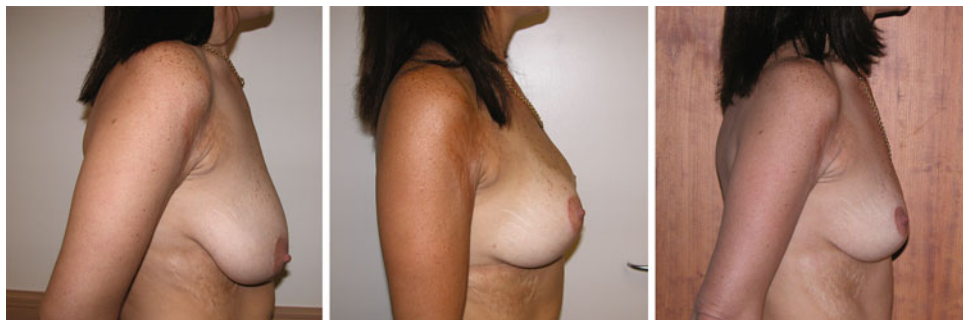
Long-term loss of nipple sensation	8	3.66%
Infection	2	0.91%
Fat necrosis	3	1.37%
Superficial areola epidermolysis	1	0.45%
Hematoma	1	0.45%
Hypertrophic scars	2	0.91%

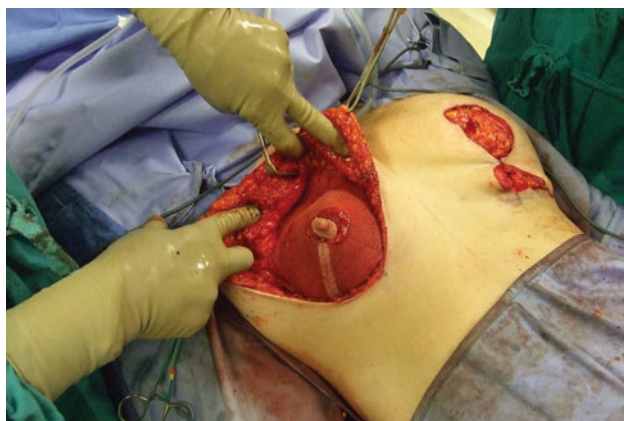


**Fig. 12** Long-term follow-up of a 33-year-old patient (BMI = 27) who had breast reduction, with excision of 300 g from each breast, and reconstruction of an IBSS with mesh to replace the supportive

function of the ligamentous suspension. Note a decrease in the areola diameter from 1 year onward

**Fig. 13** A 39-year-old patient (BMI = 21) with breast ptosis who had mastopexy and IBSS reconstructed with mesh. The 6-month postoperative result is seen in the centre. She subsequently lost 10 kg of body mass over 1 year 3 months and despite reduction in breast volume, she did not develop recurrent breast ptosis, as can be seen on the photo on the right





**Fig. 14** Intraoperative photo of the preshaped polyester mesh

## Conclusion

Recurrent breast ptosis can be avoided and satisfactory long-term results can be obtained in mastopexy and breast reduction procedures by reconstructing an internal breast-supporting system with nonabsorbable biocompatible mesh to replace the supportive function of the ligamentous suspension. The surgical procedure is effective and an adjunct to the armamentarium of the plastic surgeon. It is especially indicated in the ptotic breast patient with thin skin of poor quality or in patients with high expectations.

**Acknowledgment** The authors thank the South African company Breform™ Limited, which sponsored the operations on the trial patients, and the Department of Anatomy, University of Stellenbosch, for providing female cadavers for the preoperative research.

**Disclosure** P. V. van Deventer has an interest (shares) in Breform™ Limited. None of the authors have a financial interest or commercial association with the manufacturer of the mesh used in this project.

**Open Access** This article is distributed under the terms of the Creative Commons Attribution Noncommercial License which permits any noncommercial use, distribution, and reproduction in any medium, provided the original author(s) and source are credited.

## References

1. Bustos RA (1992) Periareolar mammoplasty with silicone supporting lamina. *Plast Reconstr Surg* 89:646–657
2. Johnson GW (1981) Central core reduction mammoplasties and Marlex suspension of breast tissue. *Aesthet Plast Surg* 5:77–84
3. Goés JC (1998) Periareolar mastopexy and reduction with mesh support—double skin technique. In: *Surgery of the Breast: Principles and Art*. Lippincott-Raven Publishers, Philadelphia, pp 697–707
4. Goés JC (1996) Periareolar mammoplasty. Double skin technique with application of polyglactin or mixed mesh. *Plast Reconstr Surg* 97:959–968
5. Goés JC (2002) Periareolar mammoplasty. Double-skin technique with application of mesh support. *Clin Plast Surg* 29:349–364
6. Goés JC (2003) Periareolar mammoplasty. Double skin technique with mesh support. *Aesthet Surg J* 23:129–135
7. Goés JC, Godoy PM, Goes RS, Henriques LJ, Landecker A, Lyra EC (2004) The application of mesh support in periareolar breast surgery: clinical and mammographic evaluation. *Aesthet Plast Surg* 28:268–274
8. De Bruijn HP, Johannes S (2008) Mastopexy with 3D preshaped mesh for long-term results: development of the internal bra system. *Aesthet Plast Surg* 32:757–765
9. De Bruijn HP, Ten Thije RHW, Johannes S (2009) Mastopexy with mesh reinforcement: the mechanical characteristics of polyester mesh in the female breast. *Plast Reconstr Surg* 124:364–371
10. Würinger E, Mader N, Posch E, Holle J (1998) Nerve and vessel supplying ligamentous suspension of the mammary gland. *Plast Reconstr Surg* 101:1486–1493
11. Würinger E, Tschabitscher M (2002) New aspects of the topographical anatomy of the mammary gland regarding its neurovascular supply along a regular ligamentous suspension. *Eur J Morphol* 40:181–189
12. van Deventer PV (2004) The blood supply to the nipple-areola complex of the human mammary gland. *Aesthet Plast Surg* 28:393–398
13. van Deventer PV, Page BJ, Graewe FR (2008) The safety of pedicles in breast reduction and mastopexy procedures. *Aesthet Plast Surg* 32:307–312
14. van Deventer PV, Graewe FR (2010) Enhancing pedicle safety in mastopexy and breast reduction procedures: the posteroinferomedial pedicle, retaining the medial vertical ligament of Würinger. *Plast Reconstr Surg* 126:786–793
15. Khan UD (2010) Breast augmentation, antibiotic prophylaxis, and infection: comparative analysis of 1, 628 primary augmentation mammoplasties assessing the role and efficacy of antibiotics prophylaxis duration. *Aesthet Plast Surg* 34:42–47