

Anatomy of the clavicle and its medullary canal - a computer tomography study

BY

Dr Paul Reginald King

DIVISION OF ORTHOPAEDIC SURGERY
DEPARTMENT OF SURGICAL SCIENCES
FACULTY OF MEDICINE AND HEALTH SCIENCES
STELLENBOSCH UNIVERISTY



Submitted for the fulfilment of the degree of
MMed in Orthopaedic Surgery.

Supervisor: Dr Ajmal Ikram

Co-supervisor: Dr Robert Patrick Lamberts

April 2014

Tygerberg, Western Cape, South Africa

DECLARATION

I, Paul Reginald King (student number: 13091603), hereby declare that the work on which this dissertation is based on is my original work (except where acknowledgements indicate otherwise) and that neither the whole work nor any part of it has been, is being, or will be submitted for another degree at this or any other university.

I empower the university to reproduce for the purpose of research either the whole or any portion of the contents in any matter whatsoever.

Signature

Date: 1 April 2014

ACKNOWLEDGEMENTS

I would like to thank my supervisors, Dr Ajmal Ikram and Dr Robert Lamberts, for their guidance and inspiration in completing this dissertation.

My sincere gratitude to the following contributors to this thesis:

My co-investigator, Dr Shaun Scheepers, for his assistance and technical expertise in analysing the computer tomography images.

Dr Justin Harvey for the statistical analysis of the data.

Thank you to my Head of Department, Dr Jacques du Toit, for his motivation and for providing an environment that makes quality research possible.

TABLE OF CONTENTS

Declaration	iii
Acknowledgements	iv
Abstract	1
Background	
Description of methods	
Summary of results	
Conclusion	
PROBLEM DEFINITION AND HYPOTHESIS	2
CHAPTER 1. LITURATURE REVIEW	3
CHAPTER 2. RESEARCH STUDY	9
Introduction	11
Materials and Methods	12
Inclusion criteria	12
Exclusion criteria	12
Results	17
Discussion	20
REFERENCES	23

ABSTRACT

Background

With recent literature indicating certain clavicle shaft fracture types are best treated surgically; there is renewed interest in the anatomy of the clavicle. Intramedullary fixation of clavicle shaft fractures requires an adequate medullary canal to accommodate the fixation device used. This computer tomography anatomical study of the clavicle and its medullary canal describes its general anatomy and determines the suitability of its medullary canal to intramedullary fixation.

Description of methods

Four hundred and eighteen clavicles in 209 patients were examined using computer tomography imaging. The length and curvatures as well as the height and width of the clavicle and its canal at various pre-determined points were measured. In addition the start and end of the medullary canal from the sternal and acromial ends of the clavicle were determined. The data was grouped according to age, gender and lateralization.

Summary of results

The average length of the clavicle was 151.15 mm with the average sternal and acromial curvature being 146° and 133° respectively. The medullary canal starts on average 6.59 mm from the sternal end and ends 19.56 mm from the acromial end with the average height and width of the canal at the middle third being 5.61 mm and 6.63 mm respectively.

Conclusion

The medullary canal of the clavicle is large enough to accommodate commonly used intramedullary devices in the majority of cases. The medullary canal extends far enough medially and laterally for an intramedullary device to adequately bridge most middle third clavicle fractures. An alternative surgical option should be available in theatre when treating females as the medullary canal is too small to pass an intramedullary device past the fracture site on rare occasions.

PROBLEM DEFINITION AND HYPOTHESIS

The treatment of displaced and shortened clavicle shaft fractures has evolved from purely supportive to more aggressive and invasive. Surgical treatment has been shown to have superior outcomes in these more complicated fracture patterns. The emphasis on surgical treatment has caused renewed interest in the anatomy of the clavicle. Accurate fracture reduction and fixation relies on anatomical compatibility of the specific implant used. Treatment options for these more complicated fractures include intramedullary and extramedullary fixation. Intramedullary fixation has shown some benefits over extramedullary fixation, but its use is reliant on a medullary canal being present and large enough in order to accommodate the fixation device.

Our study hypothesis is that the clavicle has a distinct medullary canal that is large enough to accommodate intramedullary devices and extend far enough medially and laterally in order to span a clavicle shaft fracture adequately.

CHAPTER 1

LITERATURE REVIEW

The clavicle is the first bone in the body to ossify (5th week of fetal life), while it is also the only long bone to ossify by intramembranous ossification without going through the cartilaginous stage.¹ The medial growth plate of the clavicle is the last growth plate in the body to close – closure occurs between 22 and 25 years of age.²

The clavicle consists of cancellous bone, enveloped by cortical bone, which is much thicker in the middle 3/5 of the clavicle than in the lateral and medial fifths.³ The configuration of the clavicle presents a double curvature - a convex anterior curve in the medial half and a concave anterior curve in the lateral half.⁴ It has an apex superior curvature located in the medial half of the clavicle. The cross sectional anatomy of the clavicle differs in shape along its length. Distally the outer third is virtually flat with the medial third being prismatic. The middle third is circular in shape.⁴ The clavicle articulates medially with the sternum at the sternoclavicular joint and laterally with the acromion at the acromioclavicular joint. The clavicle varies greatly in size and shape from person to person, male and female and at different ages.¹

Andermahr *et al.*³ determined that female clavicles are shorter, less curved and to have lower concentrations of calcium. Daruwalla *et al.*⁵ found in a small series of 27 clavicles using 3D computer tomography reconstructions that the clavicles of men were longer, wider and thicker than in women. They found the sternal curvature of clavicles in women to be more than in men. Bernat *et al.*⁶ found the male clavicle to be significantly longer (166.8 ± 7.3 mm vs. 151.0 ± 8.2 mm), wider and more curved than the female clavicle. They also found the left clavicle to be slightly longer than the right on average (159.8 ± 10.9 mm vs. 158.0 ± 11.2 mm).

Walters *et al.*⁷ found in a series of 100 dry bone specimens that the total length of the clavicles in their series varied from 121 to 183 mm. They found the angle of deviation between the sternoclavicular end and the shaft to be an average of 25.2° with a standard deviation of 7.3° . The angle between the outer acromioclavicular end and the shaft was found to be an average of 38.6° with a standard deviation of 9.8° . The bow angle in the coronal plane showed variation from 0° to 29° with an average of 13.5° .

Andermahr *et al.*³ analyzed 196 cadaver clavicles to determine the anatomical variations in the medullary canal. They found the medullary canal to measure 6.7 ± 2.6 mm at its narrowest part. They determined that reaming of the canal prior to insertion of titanium rods used in the treatment of midshaft clavicle fractures to not be necessary.³ Mathieu *et al.*⁸ showed the medullary canal had a gradually decreasing size from the distal portion to the middle segment, but that it never disappears. They concluded that evaluation of the morphological data of the medullary canal can clarify the specifications of an intramedullary nail.⁸

The clavicle has various functions. It serves as an attachment site for muscles allowing movement of the shoulder girdle joints. The clavicle acts as a strut suspending the shoulder away from the body.⁹ This increases the range of motion of the shoulder and allows the hand to be placed in space for greater function. It has been shown in a cadaver model that clavicular discontinuity results in a decreased thorax-scapula distance and in reduced external rotation, upward rotation, and posterior tilting of the scapula. These kinematic changes were observed during elevation in all 3 planes but were greatest in the sagittal plane compared with the scapular and coronal planes.⁹ The major vessels at the base of the neck and the brachial plexus lie deep to the clavicle to be protected from trauma.¹⁰ Sinha *et al.*¹¹ was able to accurately measure the distance between the clavicle and the neurovascular structures it protects using reconstructed three dimensional CT arteriograms. They were able to suggest safe zones for the placement of screws during the plating of clavicle fractures using this data.¹¹

Clavicle fractures are common fractures comprising 2,6 to 4% of all adult fractures and account for 35% of injuries to the shoulder girdle.² 68% of fractures occur in men with the left clavicle being affected in 61%. The annual incidence of clavicular fractures vary between 29 and 64 per 100 000 population per year. Fractures of the middle third of the clavicle account for 69% of fractures of the clavicle.² Fractures occurring in the middle third of the clavicle are displaced in 48% and comminuted in 19% of cases.¹² Postacchini *et al.*¹² found in their series that middle third clavicle fractures account for 81% of clavicle fractures. They found fractures occurring in the middle third of the clavicle are displaced in 48% and comminuted in 19% of cases.¹³ Robinson found middle third fractures to comprise 69%, medial third fractures comprised 2% of fractures and lateral third fractures the balance.¹⁴

Stanley *et al.*¹⁵ found the first and largest peak of clavicle fractures in males under 30 years and a second peak occurring in women older than 80 years of age. These fractures are thought to be related to osteoporosis.¹⁵

The mechanism of injury causing middle third clavicle fractures can be divided into direct and indirect trauma. Indirect trauma to the clavicle occurs with falls onto an outstretched hand or, more commonly, falls onto the point of the shoulder. These fractures commonly occur during sporting activities including mountain biking or horse riding. Direct trauma can cause a clavicle fracture by a blunt or a penetrating mechanism. Postacchini *et al.*¹² found motor vehicle accidents to be the main mechanism of injury.¹³ Stanley *et al.*¹⁵ found fractures occurring in the elderly to occur secondary to low energy falls from standing. Nowak *et al.*¹⁶ found bicycle accidents to be the most common mechanism of injury, but sporting injuries caused most clavicle fractures in males. Robinson¹⁴ found the mechanism of injury in younger males to be predominantly sporting accidents while the fractures in women occurred more commonly due to simple falls. Nordqvist¹⁷ found in a series of 2035 fractures that there was a

significant increase in the incidence of clavicle fractures during the 35 year period of his review. Zhu *et al.*¹⁸ found the vast majority of fractures were caused by road traffic accidents in a Chinese study.

The treatment of clavicle shaft fractures has evolved recently from almost exclusively supportive to more aggressive and interventional.² A recent meta-analysis of the available literature supports surgical management of displaced clavicle shaft fractures.¹⁹ The indications for surgical treatment have been related to the radiological picture. Fracture displacement, shortening and comminution has been suggested to be indications for surgery.^{20,21} These indications have stemmed from various studies that showed inferior results when these specific fracture configurations are treated non-surgically. It has been shown that malunion of a middle third clavicle fracture with shortening of the clavicle may alter the position of the glenoid fossa which in turn may affect glenohumeral mobility and scapular rotation.²² Different amounts of shortening of the fracture have been linked to inferior treatment outcomes when non-operative modalities are used. These values have ranged from 14 to 20 mm of shortening in the axial plane.^{23,24}

Operative treatment consist of open reduction and internal fixation using locked or non-locked plates or open or closed reduction with internal fixation using intramedullary rods, wires or nails.²⁵

Huang *et al.*²⁶ measured the apex superior curve of the clavicle to determine the effectiveness of a specific anatomically contoured locked plate. They showed the curve to be located mostly on the lateral side of the clavicle with a mean distance of 37.2 mm ± 18.4 mm from the acromial articulation and with a mean magnitude of 5.9 mm. They found no significant difference in the location or magnitude of the apex of the bow between males and females. They showed that certain population groups have clavicle shapes more suited to fit the specific plate than other groups.²⁶

Intramedullary fixation of displaced middle third clavicle fractures is associated with a significantly reduced non-union rate compared to conservative treatment.²⁵ Thyagarajan²⁷ recommended intramedullary fixation of displaced middle third clavicle fractures over plating and conservative treatment. He reported no non-unions in the intramedullary group and scar related complications and prominent hardware in the plating group in 42% (8 out of 17 patients). Ferran *et al.*²⁸ compared Rockwood pin fixation with plating of displaced middle third clavicle fractures and found no difference between the union rates, Constant Shoulder score or the Oxford Shoulder score between the two groups. However, in this study all the Rockwood pins had to be removed and 53% of the plates had to be removed due to infection or soft tissue irritation.²⁸ The shape and size of the medullary canal as well as the curvature of the clavicle in the axial plane are factors making the placement of intramedullary devices difficult.³ Bouchara *et al.*²⁹ attempted to show the correlation between the clavicle's curvature and the quality of

fixation of a midshaft fracture using a straight intramedullary device using a computer simulation model in computer tomography reconstructions of normal cadaveric clavicles. They found that in 15 of 22 clavicles the midpoint of the clavicle could be bypassed by 2 cortical diameter and 6 midpoints could be bypassed by one cortical diameter. The authors concluded that stable fixation using a straight intramedullary could be achieved in the majority of midshaft fractures of the clavicle.

Millett *et al.*³⁰ showed a major complication (non-union, malunion and infection) rate of 8.6% using intramedullary fixation. Wijdicks *et al.*³¹ showed a lower complication rate following intramedullary fixation versus patients treated by plating.

Retrospective and prospective studies comparing intra- and extramedullary fixation have shown similar outcomes when union rates and functional outcomes are compared.^{32,33,34} Prominent hardware in plated clavicles complicate most cases.^{35,36} A very high proportion of fractures treated with plate fixation require a second operation to remove the plate. This has to be done through the original skin incision with further scarring and soft tissue compromise. The second surgery also increases the risk of supraclavicular nerve injury leading to reduced patient satisfaction.³⁷ It has been shown when intramedullary devices and plates are removed following union of the fracture that the clavicles treated with an intramedullary device has a higher load to failure. This decreases the risk of a fracture shortly after removal of the fixation device.³⁸ Intramedullary nailing of the clavicle employs a percutaneous operative technique with minimal periosteal stripping and no bone/plate compression interface, thus the periosteal blood supply is preserved promoting union.^{21,39} Fixation of the fracture can be achieved through a much smaller wound than that needed for fixation using a plate and screws.^{21,32,40,41}

Daruwalla *et al.*⁵ analyzed 27 clavicles using specialized software with computer tomography three dimensional reconstructions. They found that 3D statistical shape analysis standardized the study of the anatomy of the clavicle. It rules out variability, calculates morphological parameters that are accurate and that are reproduceable.⁵

The study of computer tomograms of the clavicles of living subjects are more accurate as it is well known that the anatomy of the clavicle differs in dry specimens to that found in live specimens. This is thought to be secondary to the preservation and drying process needed to preserve the dry bone specimens.⁴²

Ahmad *et al.*⁴³ examined 78 clavicles using computer tomography and 3 dimensional reconstructions of the images to describe the general anatomy of the clavicle and its intramedullary canal. They found a high level of variation in the cross-sectional anatomy and the anterior and posterior curvature of the clavicle. They did determine that the clavicle has a distinct intramedullary canal.⁴³

CHAPTER 2

RESEARCH STUDY

ANATOMY OF THE CLAVICLE AND ITS MEDULLARY CANAL:

A COMPUTER TOMOGRAPHY STUDY

The content of this chapter was used for the following scientific publication: King P.R., Scheepers S., Ikram A. Anatomy of the clavicle and its medullary canal: a computer tomography study. Eur J Orthop Surg Traumatol. 2014 Jan; 24(1): 37-42

Introduction

The clavicle is a bone with a complex anatomy. It has been widely studied using cadaver and bone bank specimens with wide variation in the dimensions of the clavicle between different age, gender and race groups being found. These anatomical variations have made the design of extramedullary fixation devices for the treatment of clavicle fractures difficult. Various devices have been designed taking these variations into account, but no single plate and screw configuration has been able to address all variations. Intramedullary devices are less reliant on standard anatomy, but variations in the size of the intramedullary canal have made these devices difficult to use.

Clavicle fractures are commonly seen in young, active patients with high functional requirements. These fractures are difficult to treat and prone to complications. Less than satisfactory outcome in economically and physically active individuals leads to loss of income and quality of life. The inferior treatment outcome can be explained partly by the lack of high quality anatomically designed internal fixation devices.

Intramedullary fixation of the clavicle holds certain advantages over plate fixation, but outcome is less reliable due to inferior fixation obtained secondary to variations in the medullary canal of the clavicle. Pre-operative radiographs are not sensitive to predict the size or abnormalities of the medullary canal and thus anatomical anomalies are normally only found at the time of surgery.

The size of the medullary canal of the clavicle in particular can be a prohibiting factor to the use of intramedullary devices. If the canal is too small to allow reamers or nails to be inserted the fixation of the fracture by means of an intramedullary device is impossible.⁴⁴ Another prohibiting factor is absence of an intramedullary canal at the medial side of the clavicle. This causes problems passing the intramedullary device far enough past the fracture site to give adequate fracture stability. The intramedullary canal size and its medial and lateral starting points are variable and differs between gender groups and between different sides.³

This study determines the general anatomy of the clavicle and its medullary canal in living subjects using computer tomography imaging. The data was used to determine whether the anatomy of the clavicle and its medullary canal is amendable to intramedullary fixation in case of a shaft fracture.

Materials and Methods

Patients who had computer tomography imaging of their upper trunk were identified using the PACS radiology system. The patients all had computer tomography studies done for unrelated reasons as part of their diagnostic workup and were randomly selected. Examination protocols reviewed included standard CT chest, CT angiogram of the neck, CT angiogram of the pulmonary arteries and standard CT of the neck. All examinations were performed on either a Siemens SOMATOM Sensation 40-slice, a Siemens SOMATOM Emotion 6-slice or a Toshiba Aquilion 4-slice CT scanner. Slice thickness according to clinical indication and scan protocol varied between 1.25 and 2.5mm. A standard soft tissue kernel was used for image reconstruction. Raw scan data was transferred to a Philips PACS server. Data was then loaded into Philips Brilliance Workspace Portal v 2.6.0.18, a dedicated CT software package. Images were reviewed in a bone window (window width 2000 – 2500 and window level 450 – 800). Clavicles were reviewed in true axial, coronal and sagittal planes and measurements performed. In patients with marked clavicular angulation or curvature, in which true anatomic planes could not be obtained, curved reconstructions were used. All measurements were performed by a single final year radiology resident. The shape of the clavicle was described by a radiologist and an orthopaedic surgery resident, in agreement.

Inclusion criteria

Minimum of 16 years of age

Computer tomography imaging done that includes imaging of both clavicles.

Exclusion criteria

- Congenital malformation of the clavicle.
- Previous surgery to the clavicle.
- Previous clavicle fracture.

The group was divided according to age, gender and lateralization.

The clavicle length was determined utilizing a 3-point measuring system on axial images to obtain the true length. It's sternal and acromial curvature was measured in the axial plane by determining the angle between lines drawn paralleling the proximal, middle and distal portions of the clavicle. The coronal curvature was obtained by measuring the angle between lines drawn paralleling the proximal and distal clavicle ends.

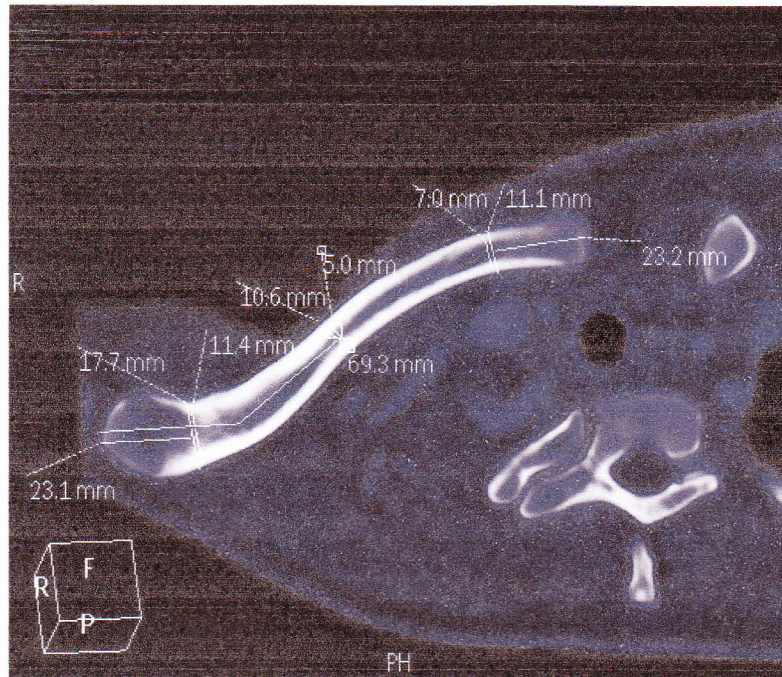


Figure 1. Determining reference points.

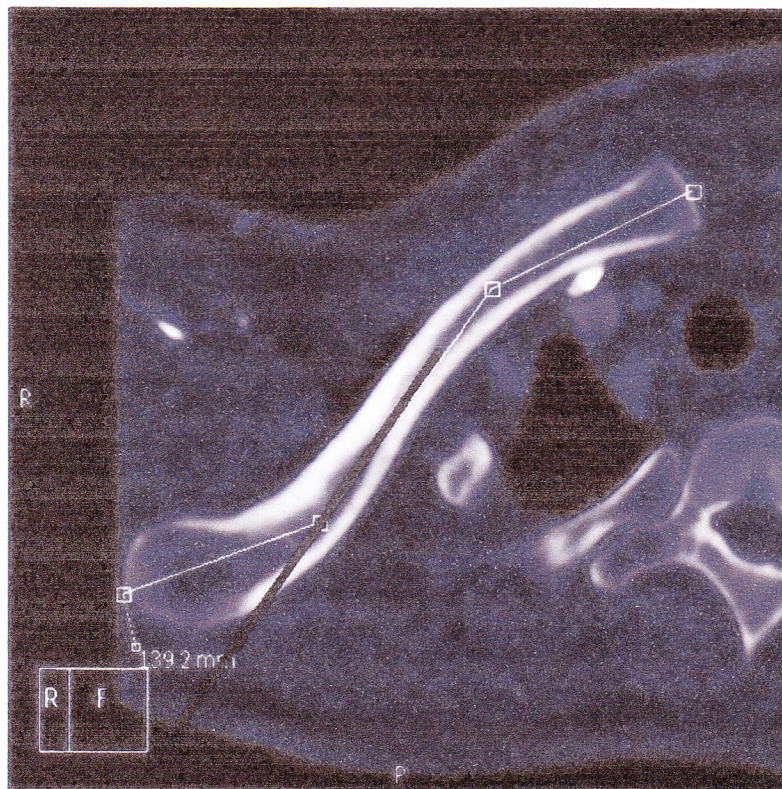


Figure 2. Measuring the length of the clavicle

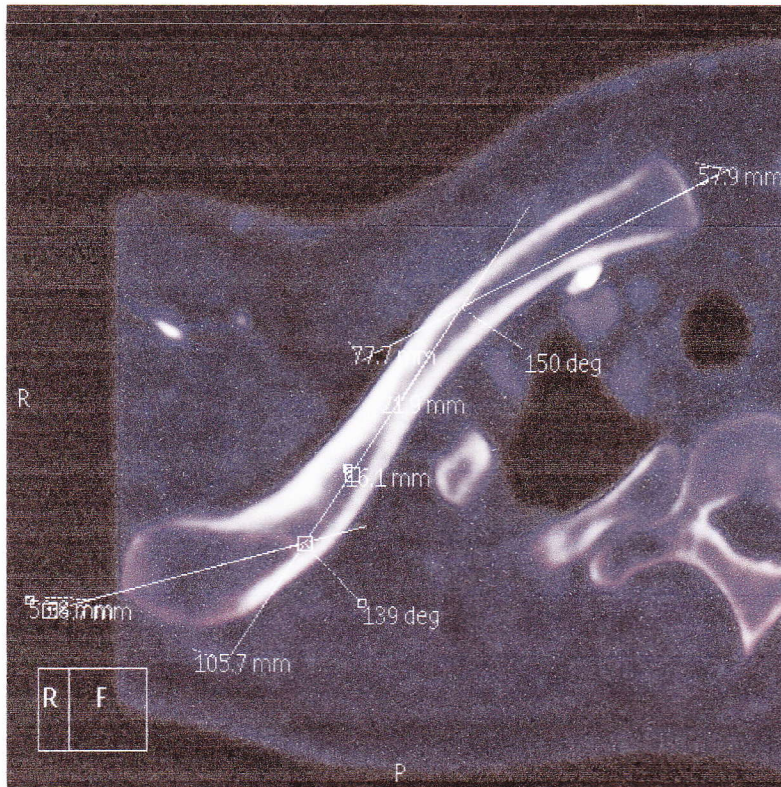


Figure 3. Measuring the sternoclavicular and acromioclavicular angles

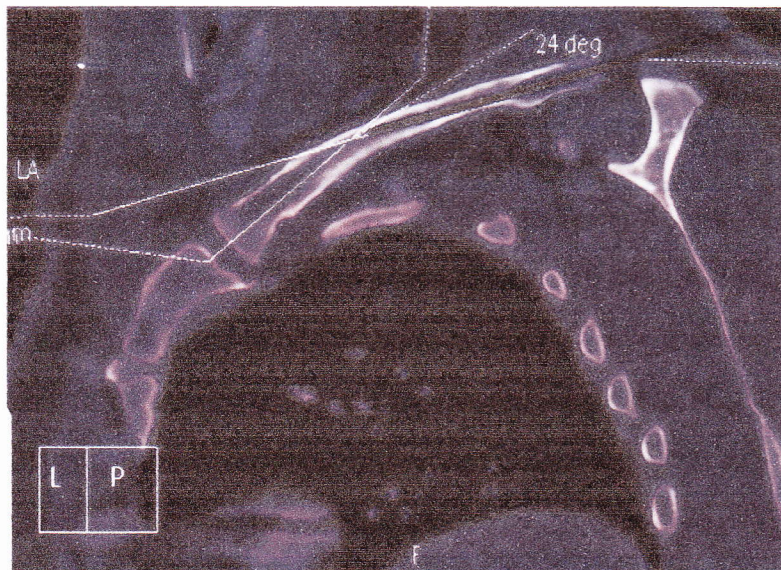


Figure 4. Measuring the coronal curvature of clavicle

Three points were taken as reference points on each clavicle. This was done by dividing each clavicle in 3 equal parts. These thirds were each halved to determine three points that were used as reference points – the middle of the sternal third, the middle of the middle third and the middle of the acromial third. At each of these points the height and width of the clavicle and its medullary canal were measured.

The difference in densities of the sponge bone and the medullary canal at the lateral and medial ends were utilized to measure the distance from the medial and lateral ends to the start of the medullary canal.

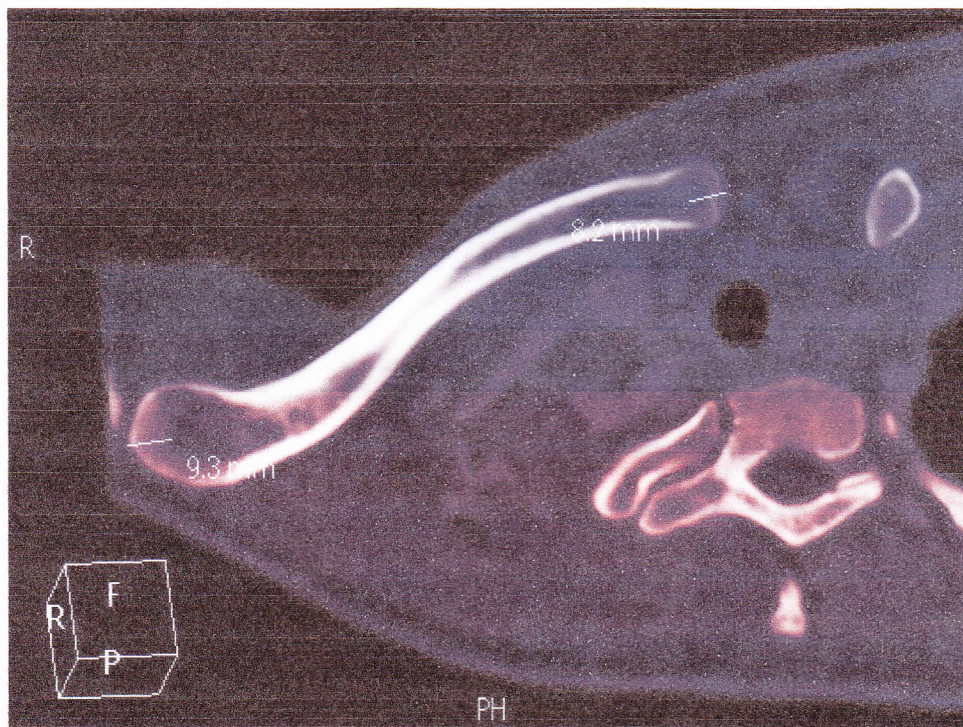


Figure 5. Determining the start and finish of the medullary canal

The shape of the clavicle and its medullary canal was determined at the 3 reference points. Sagittal images of the clavicle were reviewed at the midpoint of the proximal, middle and distal segments respectively, in order to determine and describe the visualized shape of the clavicle as well as the medullary canal. The shape was described using a predetermined template as described by Walters *et al.*⁷ in an anatomical study of dry bone clavicles.









	1. Mostly rectangular with facets in transverse and longitudinal planes
	2. Oval with long axis in longitudinal plane
	3. Mostly circular
	4. Mostly triangular with flat surface superiorly and long axis in longitudinal plane
	5. Mostly triangular with flat surface posteriorly and long axis in transverse plane
	6. Oval with long axis in transverse plane
	7. Mostly triangular with flat surface superiorly and short in longitudinal plane.
	8. Flattened with widest dimension in transverse plane

Figure 6. Clavicle shape template

Results

Two hundred and nine patients with 418 clavicles were included in the review of which 108 were female and 101 males. The patients had an even distribution of ages with a mean of 49 years (16 – 84).

The average length of the clavicle was 151.15 mm (121.50 – 183.30). Male clavicles were 156.87mm and female clavicles 145.79 mm in length on average (Table 1 and 2). The average length difference between the left and right clavicles in men were 4.55 mm with the left clavicle being longer than the right in 66 of 101 (65%) cases. In women the difference between the left and right clavicles were 3.14mm on average with the left clavicle being longer than the right in 72 of 108 (67%) cases.

Table 1. Variables in male patients (N = 202)

Variable	Mean ± SD	Minimum	Maximum
Age (years)	49.31 ± 16.63	16.00	84.00
Length (mm)	156.87 ± 9.75	121.50	183.30
SC-curve (degrees)	146.34 ± 7.12	126.00	164.00
AC-curve (degrees)	134.03 ± 12.38	95.00	164.00
Clavicle Width: Medial (mm)	14.55 ± 2.25	9.40	23.00
Clavicle Width: Middle (mm)	12.71 ± 7.10	9.00	25.50
Clavicle Width: Lateral (mm)	18.26 ± 3.04	10.80	26.80
Clavicle Height: Medial (mm)	14.55 ± 2.77	9.40	21.80
Clavicle Height: Middle (mm)	10.97 ± 1.25	8.00	14.70
Clavicle Height: Lateral (mm)	10.56 ± 1.96	6.30	18.60
Canal start: Medial (mm)	6.77 ± 3.48	2.90	30.30
Canal start: Lateral (mm)	20.67 ± 3.97	13.80	42.00
Canal Width: Medial (mm)	10.24 ± 2.15	5.90	18.60
Canal Width: Middle (mm)	7.34 ± 1.43	4.10	12.00
Canal Width: Lateral (mm)	13.47 ± 3.14	5.70	23.50
Canal Height: Medial (mm)	9.82 ± 2.62	4.60	17.70
Canal Height: Middle (mm)	6.26 ± 1.08	3.60	9.50
Canal Height: Lateral (mm)	6.23 ± 1.76	2.70	12.10

Table 2. Variables in female patients (N = 216)

Variable	Mean \pm SD	Minimum	Maximum
Age (years)	48.39 \pm 16.70	17.00	82.00
Length (mm)	145.79 \pm 7.95	126.90	168.70
SC-curve (degrees)	146.56 \pm 6.79	128.00	164.00
AC-curve (degrees)	132.96 \pm 11.69	98.00	160.00
Clavicle Width: Medial (mm)	12.27 \pm 1.85	7.60	18.40
Clavicle Width: Middle (mm)	11.08 \pm 1.14	8.80	14.50
Clavicle Width: Lateral (mm)	15.14 \pm 2.53	8.20	21.70
Clavicle Height: Medial (mm)	13.57 \pm 2.25	9.30	22.30
Clavicle Height: Middle (mm)	9.36 \pm 1.06	7.10	13.10
Clavicle Height: Lateral (mm)	9.74 \pm 1.65	4.60	16.20
Canal start: Medial (mm)	6.42 \pm 2.85	2.80	24.10
Canal start: Lateral (mm)	18.53 \pm 2.84	11.70	30.00
Canal Width: Medial (mm)	8.12 \pm 1.67	4.20	12.40
Canal Width: Middle (mm)	5.97 \pm 1.30	2.90	10.90
Canal Width: Lateral (mm)	10.49 \pm 2.58	5.10	16.80
Canal Height: Medial (mm)	8.88 \pm 2.04	4.90	15.80
Canal Height: Middle (mm)	5.00 \pm 0.97	3.00	8.60
Canal Height: Lateral (mm)	5.62 \pm 1.48	2.90	11.80

The medullary canal at the medial reference point had an average width and height of 9.14 mm and 9.34 mm respectively. At the middle reference point the dimensions were 6.63 mm by 5.61 mm. At the lateral reference point the width of the canal was 11.93 mm and the height 5.91 mm. The dimensions in females were consistently smaller and the dimensions varied widely across the clavicles studied.

The start of the medullary canal at the medial end of the clavicle was on average 6.59mm (2.80 – 30.30 mm) from the sternal end. The medullary canal ends on average 19.56 mm (11.70 – 42.00 mm) from the acromial end of the clavicle.

Three (1.4%) male clavicle canals had a height or width smaller than 4.50 mm at the middle third reference point. The smallest measured 3.60 mm by 5 mm. Sixty six (31%) female medullary canals

had a width or height smaller than 4.50 mm. The average width of the medullary canal of these clavicles was 5.20 mm and the average height 4.05 mm. These females had an average age of 45.50 years with 59% being the left clavicle. The clavicles had an average length of 145.90 mm. In only 12 (5%) clavicles the height and width of the canal measured less than 4.50 mm.

The average sternal curvature of the clavicle was 146° (126 – 164) with the average acromial curvature 133° (95 – 164).

The patients reviewed showed a wide variation in coronal curvatures. It varied from apex superior, apex inferior and even s-shaped curves. Ten clavicles had apex inferior curvatures ranging from 3° to 17° . Twenty four clavicles displayed s-shaped curves (Figure 7) with the medial end of the clavicle having an apex superior curve and the lateral end having an apex inferior curve. The remaining 384 clavicles had an apex superior curve ranging from 2° to 35° . The average apex superior curvature was 17° .

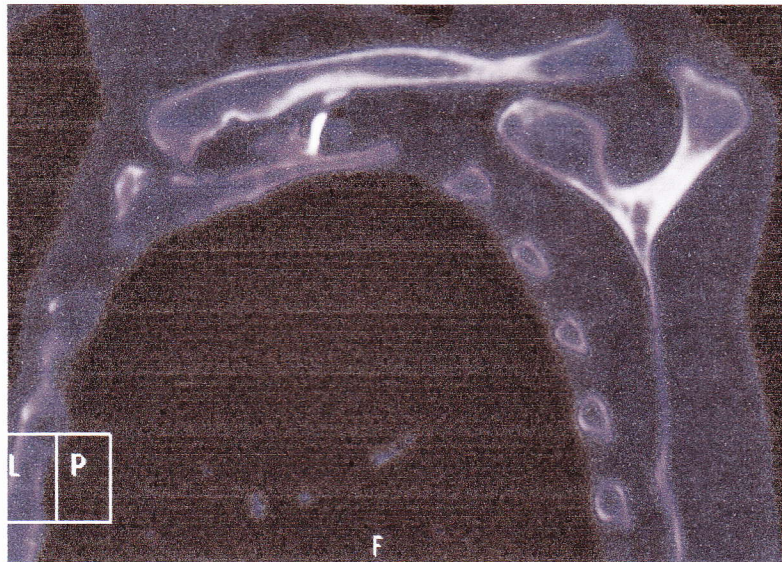


Figure 7. S-shaped in coronal plane clavicle

The medial third of the clavicle had a rectangular shape in 103 (25%) cases, an oval shape in 128 (31%) cases, 116 (28%) clavicles were circular and 60 (14%) had a triangular shape. The middle third of the clavicle had a circular shape in 346 (83%) of cases and an oval shape in 45 (11%) of cases. The lateral third was oval in 126 (30%), flat in 121 cases (29%), triangular in 89 (21%) and rectangular in 63 (15%).

The shape of the medullary canal only very rarely (1%) differed from the shape of the clavicle at the corresponding reference point.

Discussion

This series accurately describes the anatomy of the clavicle and in particular its medullary canal. Wide variations in dimensions across different age and gender groups were found. This is in keeping with previous studies done.^{1,3,5,7} Computer tomography imaging has been shown to be an accurate method of describing the anatomy of the clavicle.^{11,5} The dimensions of the clavicle and its canal were determined in living subjects avoiding possible post-mortem changes in the dimensions secondary to the preservation process.⁴²

As in previous series a marked difference between the dimensions of male and female clavicles were found.^{5,6} The female clavicle is generally shorter and its cross-sectional dimensions smaller than the clavicles of males. The difference in length between the left and right clavicles in the same individual is significant and difficult to explain. It might be explained by hand dominance and different workloads of the respective upper limbs during growth. Whether a longer clavicle holds mechanical advantage is unknown. The curvatures of the clavicle in the coronal and axial plane differ only marginally between gender groups and between left and right. This differs from previous groups studied where more significant differences were found.^{1,5} However, a wide spectrum of curvatures was found similar to previous findings reported on.^{4,37}

Intramedullary fixation of midshaft clavicle fractures is an effective mode of treatment.^{44,28,35,32} However, the size of the canal can be a prohibiting factor to the use of intramedullary devices. If the canal is too small to allow reamers or nails to be inserted the fixation of the fracture by means of an intramedullary device is impossible. Another prohibiting factor is absence of an adequate medullary canal at the far medial and lateral sides of the clavicle. This causes problems passing the intramedullary device far enough past the fracture site to give adequate fracture stability.⁴⁴ Various intramedullary devices are available with different sizes and fixation methods. These include the Hagie pin (Du Puy), 4.00 mm in diameter, the Rockwood nail (Du Puy), sizes 2.50 – 4.50 mm, the Acumed clavicle pin, sizes 3.00 mm and 3.80 mm, the Sonoma CRx system (4 mm) and flexible titanium nails (Synthes), 2 – 4 mm. Logic dictates that the medullary canal should at least be of similar size or larger to allow the device to be passed into the canal.

This study shows that the clavicle's anatomy is suitable for intramedullary fixation. The canal is large enough to accommodate above mentioned intramedullary devices in the majority of cases. The canal extends far enough medial and lateral to allow middle third clavicle fractures to be bridged adequately by an intramedullary device. The medullary canal at the middle third of the clavicle is relatively small in approximately a third of women. Only very rarely is the canal smaller than 4.50 mm in both the coronal and axial planes. Passing an intramedullary device into these medullary canals will prove difficult or

even impossible. It is advisable to have a second surgical option available in theatre when treating females by intramedullary means. If the canal is too small to insert the intramedullary device into the canal the surgeon can revert to plating the clavicle with an anatomically contoured locked plate.

REFERENCES

1. Moseley HF. The clavicle: its anatomy and function. *Clin Orthop Relat Res.* 1964;58:17–27.
2. Khan L a K, Bradnock TJ, Scott C, Robinson CM. Fractures of the clavicle. *J Bone Joint Surg Am.* 2009;91(2):447–60. doi:10.2106/JBJS.H.00034.
3. Andermahr J, Jubel A, Elsner A, et al. Anatomy of the clavicle and the intramedullary nailing of midclavicular fractures. *Clin Anat.* 2007;20(1):48–56. doi:10.1002/ca.20269.
4. Bucholz RW, Heckman Jd, Court-Brown C R and GF in adults. *Rockwood and Green's Fractures in adults.* 6th ed. Lippencot; 2005.
5. Daruwalla ZJ, Courtis P, Fitzpatrick C, Fitzpatrick D, Mullett H. Anatomic variation of the clavicle: A novel three-dimensional study. *Clin Anat.* 2010;23(2):199–209. doi:10.1002/ca.20924.
6. Bernat A, Huysmans T, Glabbeek F Van, Sijbers J, Gielen J, Van Tongel A. The anatomy of the clavicle: A Three-dimensional Cadaveric Study. *Clin Anat.* 2013. doi:10.1002/ca.22288.
7. Roche S, Solomons S WJ. A morphometric study of the clavicle. *South African Orthop J.* 2010;9(3):47–52.
8. Mathieu P-A, Marcheix P-S, Hummel V, Valleix D, Mabit C. Anatomical study of the clavicle: endomedullary morphology. *Surg Radiol Anat.* 2014;36(1):11–5. doi:10.1007/s00276-013-1140-2.
9. Matsumura N, Nakamichi N, Ikegami H, et al. The function of the clavicle on scapular motion: a cadaveric study. *J Shoulder Elbow Surg.* 2013;22(3):333–9. doi:10.1016/j.jse.2012.02.006.
10. Terry GC, Chopp TM. Functional anatomy of the shoulder. *J Athl Train.* 2000;35(3):248–55.
11. Sinha A, Edwin J, Sreeharsha B, Bhalaiik V, Brownson P. A radiological study to define safe zones for drilling during plating of clavicle fractures. *J Bone Joint Surg Br.* 2011;93(9):1247–52. doi:10.1302/0301-620X.93B9.25739.
12. Postacchini F, Gumina S, De Santis P, Albo F. Epidemiology of clavicle fractures. *J Shoulder Elb Surg.* 2002;11(5):452–456. doi:10.1067/mse.2002.126613.
13. Postacchini R, Gumina S, Farsetti P, Postacchini F. Long-term results of conservative management of midshaft clavicle fracture. *Int Orthop.* 2010;34(5):731–6. doi:10.1007/s00264-009-0850-x.
14. Robinson CM. Fractures of the clavicle in the adult. Epidemiology and classification. *J Bone Joint Surg Br.* 1998;80(3):476–84.
15. Stanley D, Trowbridge EA, Norris SH. The mechanism of clavicular fracture. A clinical and biomechanical analysis. *J Bone Joint Surg Br.* 1988;70(3):461–4.
16. Nowak J, Mallmin H, Larsson S. The aetiology and epidemiology of clavicular fractures. A prospective study during a two-year period in Uppsala, Sweden. *Injury.* 2000;31(5):353–8.
17. Nordqvist A, Petersson C. The incidence of fractures of the clavicle. *Clin Orthop Relat Res.* 1994;(300):127–32.
18. Zhu X, Li W, Chen Z. [Analyses of epidemiology in 363 cases of clavicle fractures]. *Zhongguo Xiu Fu Chong Jian Wai Ke Za Zhi.* 2004;18(4):275–6.

19. Xu C-P, Li X, Cui Z, Diao X-C, Yu B. Should displaced midshaft clavicular fractures be treated surgically? A meta-analysis based on current evidence. *Eur J Orthop Surg Traumatol*. 2012. doi:10.1007/s00590-012-1063-3.
20. Canadian Orthopaedic Trauma Society. Nonoperative treatment compared with plate fixation of displaced midshaft clavicular fractures. A multicenter, randomized clinical trial. *J Bone Joint Surg Am*. 2007;89(1):1–10. doi:10.2106/JBJS.F.00020.
21. Van der Meijden O a, Gaskill TR, Millett PJ. Treatment of clavicle fractures: current concepts review. *J Shoulder Elbow Surg*. 2012;21(3):423–9. doi:10.1016/j.jse.2011.08.053.
22. Eskola A, Vainionpää S, Myllynen P, Päätiälä H, Rokkanen P. Outcome of clavicular fracture in 89 patients. *Arch Orthop Trauma Surg*. 1986;105(6):337–8.
23. Hill JM, McGuire MH, Crosby LA. Closed treatment of displaced middle-third fractures of the clavicle gives poor results. *J Bone Joint Surg Br*. 1997;79(4):537–9.
24. Lazarides S, Zafiroopoulos G. Conservative treatment of fractures at the middle third of the clavicle: the relevance of shortening and clinical outcome. *J Shoulder Elbow Surg*. 2006;15(2):191–4. doi:10.1016/j.jse.2005.08.007.
25. Zlowodzki M, Zelle BA, Cole PA, Jeray K, McKee MD. Treatment of acute midshaft clavicle fractures: systematic review of 2144 fractures: on behalf of the Evidence-Based Orthopaedic Trauma Working Group. *J Orthop Trauma*. 2005;19(7):504–7.
26. Huang JI, Toogood P, Chen MR, Wilber JH, Cooperman DR. Clavicular anatomy and the applicability of precontoured plates. *J Bone Joint Surg Am*. 2007;89(10):2260–5. doi:10.2106/JBJS.G.00111.
27. S Thyagarajan D, Day M, Dent C, Williams R, Evans R. Treatment of mid-shaft clavicle fractures: A comparative study. *Int J Shoulder Surg*. 2009;3(2):23–7. doi:10.4103/0973-6042.57895.
28. Ferran N a, Hodgson P, Vannet N, Williams R, Evans RO. Locked intramedullary fixation vs plating for displaced and shortened mid-shaft clavicle fractures: a randomized clinical trial. *J Shoulder Elbow Surg*. 2010;19(6):783–9. doi:10.1016/j.jse.2010.05.002.
29. Bachoura A, Deane AS KS. Clavicle anatomy and the applicability... [J Shoulder Elbow Surg. 2012] - PubMed - NCBI. *J Shoulder Elb Surg* 2012 Oct;21(10)1384-90. 2012:1384–90.
30. Millett PJ, Hurst JM, Horan MP, Hawkins RJ. Complications of clavicle fractures treated with intramedullary fixation. *J Shoulder Elbow Surg*. 2011;20(1):86–91. doi:10.1016/j.jse.2010.07.009.
31. Wijdicks F-J, Houwert M, Dijkgraaf M, et al. Complications after plate fixation and elastic stable intramedullary nailing of dislocated midshaft clavicle fractures: a retrospective comparison. *Int Orthop*. 2012;36(10):2139–45. doi:10.1007/s00264-012-1615-5.
32. Liu H-H, Chang C-H, Chia W-T, Chen C-H, Tarng Y-W, Wong C-Y. Comparison of plates versus intramedullary nails for fixation of displaced midshaft clavicular fractures. *J Trauma*. 2010;69(6):E82–E87. doi:10.1097/TA.0b013e3181e03d81.
33. Lee Y-S, Huang H-L, Lo T-Y, Hsieh Y-F, Huang C-R. Surgical treatment of midclavicular fractures: a prospective comparison of Knowles pinning and plate fixation. *Int Orthop*. 2008;32(4):541–5. doi:10.1007/s00264-007-0352-7.

34. Kleweno CP, Jawa A, Wells JH, et al. Midshaft clavicular fractures: comparison of intramedullary pin and plate fixation. *J Shoulder Elbow Surg.* 2011;20(7):1114–7. doi:10.1016/j.jse.2011.03.022.
35. Houwert RM, Wijdicks F-J, Steins Bisschop C, Verleisdonk E-J, Kruyt M. Plate fixation versus intramedullary fixation for displaced mid-shaft clavicle fractures: a systematic review. *Int Orthop.* 2012;36(3):579–85. doi:10.1007/s00264-011-1422-4.
36. Duan X, Zhong G, Cen S, Huang F, Xiang Z. Plating versus intramedullary pin or conservative treatment for midshaft fracture of clavicle: a meta-analysis of randomized controlled trials. *J Shoulder Elbow Surg.* 2011;20(6):1008–15. doi:10.1016/j.jse.2011.01.018.
37. Wang K, Dowrick A, Choi J, Rahim R, Edwards E. Post-operative numbness and patient satisfaction following plate fixation of clavicular fractures. *Injury.* 2010;41(10):1002–5. doi:10.1016/j.injury.2010.02.028.
38. VanBeek C, Boselli KJ, Cadet ER, Ahmad CS, Levine WN. Precontoured plating of clavicle fractures: decreased hardware-related complications? *Clin Orthop Relat Res.* 2011;469(12):3337–43. doi:10.1007/s11999-011-1868-0.
39. Liu P-C, Chien S-H, Chen J-C, Hsieh C-H, Chou P-H, Lu C-C. Minimally invasive fixation of displaced midclavicular fractures with titanium elastic nails. *J Orthop Trauma.* 2010;24(4):217–23. doi:10.1097/BOT.0b013e3181b8ba33.
40. Lee H-J, Oh C-W, Oh J-K, et al. Percutaneous plating for comminuted midshaft fractures of the clavicle: a surgical technique to aid the reduction with nail assistance. *Injury.* 2013;44(4):465–70. doi:10.1016/j.injury.2012.09.030.
41. Boehme D, Curtis RJ, DeHaan JT, Kay SP, Young DC, Rockwood CA. Non-union of fractures of the mid-shaft of the clavicle. Treatment with a modified Hagie intramedullary pin and autogenous bone-grafting. *J Bone Joint Surg Am.* 1991;73(8):1219–26.
42. Galley IJ, Watts AC, Bain GI. The anatomic relationship of the axillary artery and vein to the clavicle: a cadaveric study. *J Shoulder Elbow Surg.* 18(5):e21–5. doi:10.1016/j.jse.2009.01.021.
43. Ahmad M, Trawhella MJ BN. Study to describe the morphology of a series of clavicles and the dimensions of its intramedullary canal. In: *Journal of Bone and Joint Surgery.*; 2006:401.
44. King, P R IA. Intramedullary locked fixation of clavicle shaft fractures – review of early results. *South African Orthop J.* 2011;10(4):67–74.