

Laparoscopic Strassman's metroplasty for bicornuate uterus – is it relevant?

T Matsaseng, T F Kruger

Department of Obstetrics and Gynaecology, Stellenbosch University, Tygerberg, Western Cape

T Matsaseng, FCOG (SA), MMed (O&G), Cert Reprod Med (SA)

T F Kruger, MPharmMed, MMed (O&G), FCOG (SA), MRCOG, MD

Corresponding author: T F Kruger (tfk@sun.ac.za)

The mean incidence of bicornuate uterus in Müllerian duct anomalies is approximately 25%, and it is associated with abortion, preterm delivery and term delivery rates of 36%, 23% and 40.6%, respectively. Open abdominal metroplasty has been shown to significantly improve pregnancy outcomes in patients with bicornuate uterus. However, minimally invasive laparoscopic metroplasty could be an alternative.

A 24-year-old woman with a bicornuate uterus and poor reproductive outcomes underwent laparoscopic Strassman's metroplasty. The procedure was completed safely within 180 minutes with minimum blood loss. At follow-up hysteroscopy and laparoscopy 2 months later, minimal adhesions in the pelvis were noted and removed. There were no synechiae in the uterine cavity.

It is concluded that laparoscopic metroplasty is a safe and relevant alternative to conventional abdominal metroplasty, with minimal adhesion formation.

S Afr J OG 2012;18(3):85-87. DOI:10.7196/SAJOG.565

Müllerian duct anomalies occur in 2 - 4% of fertile women with normal reproductive outcomes.¹⁻⁴ A well-designed critical appraisal reported the prevalence of congenital uterine anomalies to be approximately 6.7% in the general population, 7.3% in the infertile population and 16.7% in women with recurrent miscarriages.⁵

The mean incidence of bicornuate uterus in Müllerian duct anomalies is approximately 25%, and it is associated with abortion, preterm delivery and term delivery rates of 36%, 23% and 40.6%, respectively.⁶ The benefit of traditional abdominal metroplasty is not clear,⁷ but some reports have shown significant improvement in pregnancy outcomes.⁸ However, abdominal metroplasty is associated with a certain risk of complications, including adhesions and possible uterine rupture in the next pregnancy.

The first laparoscopic metroplasty, reported in January 2006, was a success, and it was also demonstrated to be a safe procedure.⁹ In the following case report we wish to emphasise the feasibility, safety and relevance of laparoscopic metroplasty for bicornuate uterus. To our knowledge this is the first reported case in South Africa.

Case report

A 24-year-old woman had had 3 second-trimester and 2 first-trimester miscarriages. A further pregnancy had ended in preterm delivery of a stillborn baby at 28 weeks' gestation, making 6 losses in total. No abnormalities were detected on initial clinical examination. Pelvic examination revealed normal external

genitalia, a normal vagina and a single fully formed cervix. Two-dimensional pelvic ultrasound led us to suspect a uterine anomaly, and a bicornuate uterus was confirmed on diagnostic laparoscopy and hysteroscopy (Fig. 1). Both ovaries were normal, as was an ultrasound scan of the kidneys. Investigations for other possible causes of recurrent miscarriages and preterm births, such as hormonal, genetic, infective and immunological disorders, were negative.

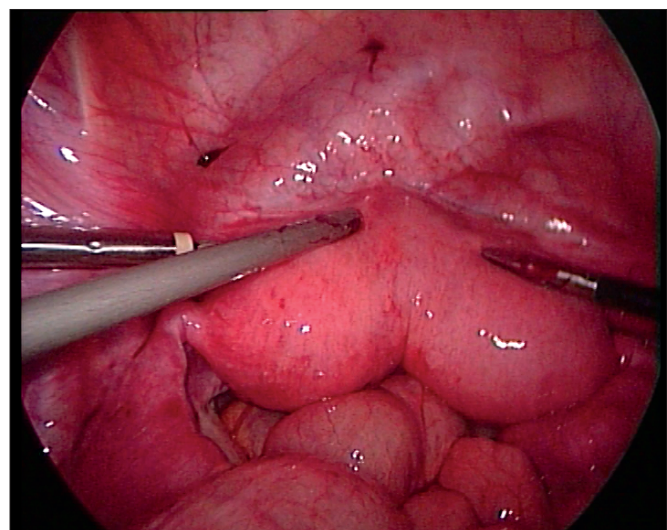


Fig. 1. Bicornuate uterus.

Operative procedure

The patient was placed in the Lloyd-Davies position and antibiotics were administered at the start of the surgery, to which she had given written informed consent.

A 10 mm trocar was inserted in the umbilicus and insufflated with 35° carbon dioxide at a preset pressure of 15 mmHg. A 30°, 10 mm telescope was inserted and its safe entrance into the abdomen confirmed. Under direct vision, two 5 mm trocars were placed in the right and left lower quadrants of the abdomen, lateral to the inferior epigastric vessels, and a third 5 mm trocar was placed equidistant between the left lower quadrant trocar and the umbilical trocar, with a 60° angle of manipulation between the two operating instruments. Both fallopian tubes and ovaries were normal.

Vasopressin solution (a dilution of 1 mg in 30 ml saline) was infiltrated sub-serosally along the medial aspect of both uterine horns. A deep incision to cut through the myometrium was made, using a monopolar hook at 80 W pure cutting current. The incision extended from the superomedial aspect of each horn, about 2 cm medial and caudal to the origin of the fallopian tube towards the medial aspect and the base of the horn (Fig. 2, A - C and B - C). The endometrial cavity was opened with hook scissors along the length of the incision. The uterus was manipulated using blunt-tipped metallic curettes. The vagina was packed with swabs to prevent the leakage of carbon dioxide.

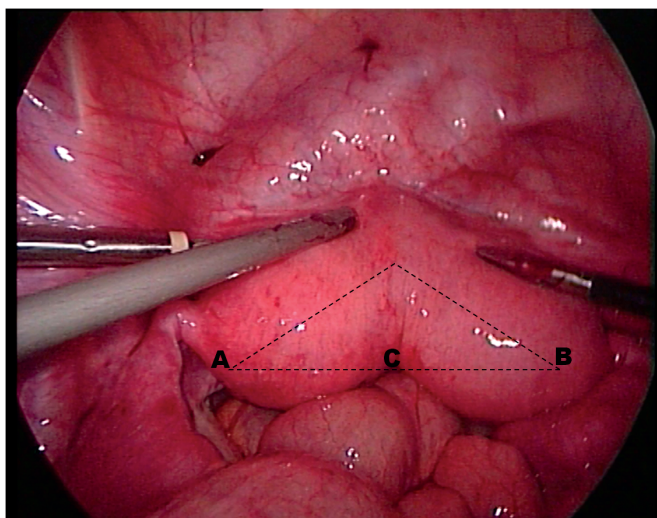


Fig. 2. The myometrium was incised with monopolar pure cutting current and the endometrial cavity was opened with scissors.

The opposing myometrial edges were sutured with a combination of interrupted and continuous simple intracorporeal sutures with 1.0 Vicryl. Initial interrupted sutures were carefully placed in the posterior and anterior wall of the uterus, with caution taken to exclude the endometrium.

Finally, the serosa of the uterus was closed with continuous intracorporeal sutures using 4.0 Prolene to prevent adhesion formation (Fig. 3). The peritoneal surface was irrigated with saline and haemostasis was confirmed. No barrier methods to prevent adhesion were used. All the sites of insertion of the instruments

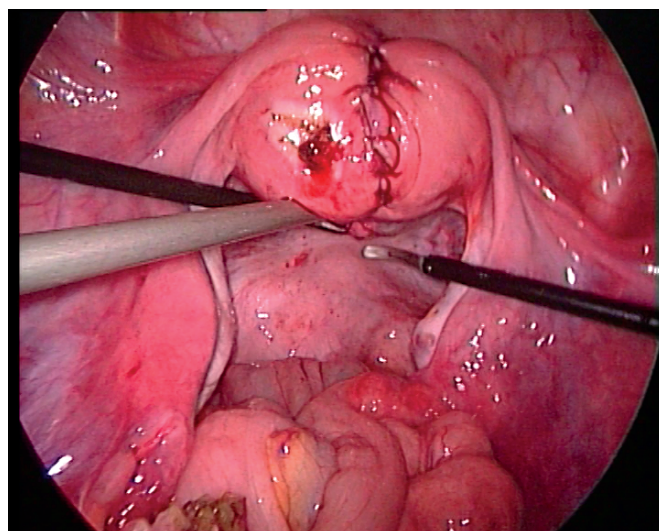


Fig. 3. Reconstructed uterus after completion of suturing.

were closed in one layer of rapid Vicryl suture for the skin. The intra-operative blood loss was approximately 150 ml and the duration of surgery was 180 minutes. The patient recovered uneventfully and was discharged on the 2nd day after surgery with an intra-uterine device *in situ* and instructions to take 2.5 mg conjugated oestrogen (Premarin) daily for 2 months.

Second-look hysteroscopy and laparoscopy

A repeat hysteroscopy and laparoscopy was performed 2 months later. On hysteroscopy (Bettochi, Karl Storz), the uterus was seen to have a uniform spacious cavity with a small residual sub-septum (<1 cm), which was resected with scissors (Fig. 4). There were no synechiae. The laparoscopy revealed filmy adhesions between the uterus, the omentum and the small bowel. Simple adhesiolysis was done and tubal patency was confirmed. The integrity of the scar was not tested.

Discussion

Metroplastic surgery was described by Strassman in 1952 for class III, IV and V anomalies, and it was subsequently modified and

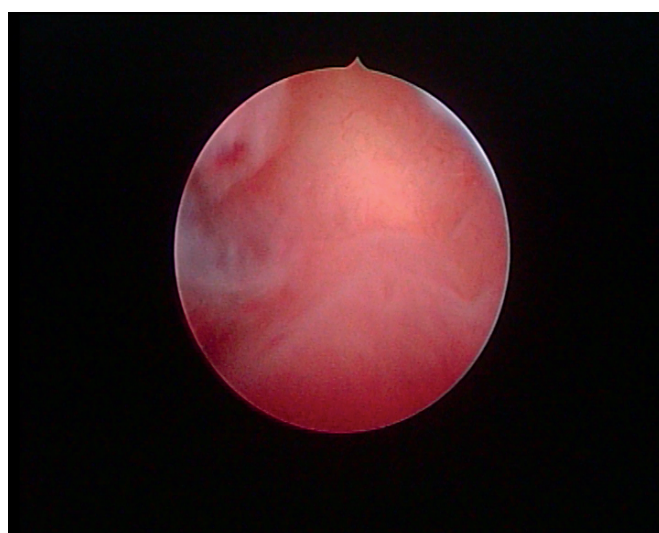


Fig. 4. Follow-up hysteroscopy after metroplasty.

simplified by Jones in 1953 (wedge excision of the septum) and Tompkins in 1962 (incision of the septum).¹⁰ Despite controversy about its role,⁷ there is good evidence that live birth rates following abdominal metroplasty improved from 3.7% to 80%.¹¹⁻¹³

However, abdominal metroplasty is associated with complications such as adhesions, uterine perforation, intra-operative bleeding, infection, and possible uterine rupture in subsequent pregnancies.¹⁰ The first laparoscopic metroplasty was reported to be a safe and successful surgical option.⁹ It was followed by a series of other case reports showing good restoration of the uterine anatomy, minimal peritoneal adhesions, less blood loss, creation of a spacious uniform uterine cavity, shorter hospital stay and good scar integrity.^{14,15} Our findings were similar, with the exception that we did not test scar integrity on follow-up.

With the application of good surgical principles, including complete mastery of laparoscopic suturing, the use of monopolar pure cutting current for the incision, approximation of the edges without tension, and prevention of haematoma formation deep in the myometrium, the risk of a weak scar can be significantly minimised and safety in subsequent pregnancy ensured.^{16,17} For our patient, we plan to perform elective caesarean section at 37 weeks' gestation.

Furthermore, with the inherent properties of laparoscopy such as reduced tissue handling and reduced tissue dryness, the overall prevalence of adhesion formation can also be reduced to a minimum.^{18,19} The routine use of adhesion barrier methods, suggested by some authors,²⁰ needs to be validated in large trials and is therefore not routine practice in our unit.

Conclusion

Laparoscopic metroplasty has been shown to be a safe procedure,⁹ and with all the additional benefits of minimally invasive surgery it is certainly a viable alternative to conventional open abdominal metroplasty. Despite the controversy in the literature, surgical

metroplasty is indicated in symptomatic patients with recurrent poor reproductive outcomes, and laparoscopic metroplasty should almost certainly be the preferred option. These debates still need to be evaluated in large randomised clinical trials.

Acknowledgement. We wish to thank Mr Willie Myburgh for the photography.

1. Acien P. Incidence of Mullerian defects in fertile and infertile women. *Hum Reprod* 1997;12:1372-1376.
2. Raga F, Bauset C, Rehomi J, Bonilla-Musoles F, Simon C, Pellicer A. Reproductive impact of congenital Müllerian anomalies. *Hum Reprod* 1997;2:2277-2281.
3. Jurkovic D, Gruboeck K, Taylor A, Nicolaides KH. Ultrasound screening for congenital uterine anomalies. *BJOG* 1997;104:1320-1321.
4. Simon C, Martinez L, Pardo F, Tortajada M, Pellicer A. Müllerian defects in women with normal reproductive outcome. *Fertil Steril* 1991;56:1192-1193.
5. Saravelos SH, Cocksedge KA, Li TC. Prevalence and diagnosis of congenital uterine anomalies in women with reproductive failure: a critical appraisal. *Hum Reprod Update* 2008;14(5):415-429.
6. Grimbizis GF, Camus M, Tarlatzis BC, Bontis JN, Devroey P. Clinical implications of uterine malformations and hysteroscopic treatment results. *Hum Reprod Update* 2001;7:161-174.
7. Rackow BW, Arici A. Reproductive performance of women with müllerian anomalies. *Curr Opin Obstet Gynecol* 2007;19:229-237.
8. Papp Z, Mezei G, Gávai M, Hupuczai P, Urbancsek J. Reproductive performance after transabdominal metroplasty: a review of 157 consecutive cases. *J Reprod Med* 2006;51(7):544-552.
9. Sinha R, Mahajan C, Hedge A, Shukla A. Laparoscopic metroplasty for bicornuate uterus. *J Minim Invasive Gynecol* 2006;13:70-73.
10. Whittaker MD, Garry R. Modern management of congenital abnormalities of the uterus. *Curr Obstet Gynaecol* 1995;5:41-45.
11. Rock JA, Jones HW. The clinical management of the double uterus. *Fertil Steril* 1977;28:798-806.
12. Candiani GB, Fedele L, Parazzini F, Zamberletti D. Reproductive prognosis after abdominal metroplasty in bicornuate or septate uterus: life table analysis. *Br J Obstet Gynaecol* 1990;97:613-617.
13. Ayhan A, Yucel I, Tuncer ZS, Kisinisci HA. Reproductive performance after conventional metroplasty: an evaluation of 102 cases. *Fertil Steril* 1992;57:1194-1196.
14. Alborzi S, Asadi N, Zolghadri J, Alborzi S, Alborzi M. Laparoscopic metroplasty in bicornuate and didelphic uteri. *Fertil Steril* 2009;92:352-355.
15. Pisat S, Tas B, van Herendaal B. Laparoscopic Strassman's metroplasty for bicornuate uterus. *Gynecol Surg* 2009;6:153-158.
16. Jelsema RD, Wittingen JA, Vanderkolk KJ. Continuous, nonlocking, single-layer repair of the low transverse uterine incision. *J Reprod Med* 1993;38:393-396.
17. Sinha R, Hedge A, Warty N, Patil N. Laparoscopic excision of very large myomas. *Journal of the American Association of Gynecologic Laparoscopists* 2003;10:461-468.
18. Sinha R, Hedge A, Warty N, Bhat P, Singhal T. Laparoscopic removal of large multiple myomas with cumulative weight of 2,3 kg. *Journal of the American Association of Gynecologic Laparoscopists* 2003;10:403-406.
19. Stringer NH, Walker JC, Meyr PM. Comparison of 49 laparoscopic myomectomies with 49 open myomectomies. *Journal of the American Association of Gynecologic Laparoscopists* 1997;4:457-464.
20. Mettler L, Audebert A, Lehmann-Willenbrock E, Schive K, Jacobs VR. Prospective clinical trial of SprayGel as a barrier to adhesion formation: an interim analysis. *Journal of the American Association of Gynecologic Laparoscopists* 2003;10:339-344.