

General Practice

Radiology as an Aid in the Diagnosis and Management of Cardiac Diseases

J. A. BEYERS

SUMMARY

Conventional radiology is a routine examination in the diagnosis and management of cardiac diseases. A brief review of its value and limitations is given. A number of technical and/or physiological factors which may influence the cardiopulmonary configuration are mentioned. An approach is suggested for analysis of radiographs of the heart.

S. Afr. med. J., 55, 201 (1979).

A wide variety of radiological methods of examination can be used as an aid to the diagnosis and management of cardiac diseases. Radiology can either be of great value or completely useless, depending on the clinical problem and the type of radiological examination used. The type of radiological examination is determined by the clinical problem, and the radiological picture must be interpreted with due consideration of the clinical picture, physical findings, ECG findings and all other relevant special examinations.

The available methods of radiological examination cover a wide spectrum. At the one extreme there are complicated, highly sophisticated, potentially dangerous examinations which must be performed only on specially selected patients. These examinations require special apparatus, entail a smaller or greater invasive procedure and also deliver a considerable dose of radiation to the patient. They require the injection of contrast medium into various parts of the cardiovascular system after which serial films, cine films or videotape recordings are rapidly made. By these means the haemodynamics and anatomy of the cardiovascular system are shown in fine detail, enabling accurate diagnoses to be made. These sophisticated examinations are indispensable in the pre-operative work-up of many cardiac lesions, but will not be discussed any further in this article. At the other extreme there are uncomplicated, potentially harmless, routine, conventional examinations which require no special apparatus. They are non-invasive and deliver only a very small dose of radiation to the patient.

A conventional radiological examination of the heart consists of at least a postero-anterior and a left lateral view of the chest, sometimes supplemented with screening

and a barium swallow. It may also be necessary to take oblique, penetrated and supine views.

Conventional radiology is of limited value in the diagnosis of cardiac lesions. In this respect it can be stated that in general the hand, eye, ear, the stethoscope and the ECG are of more value in the diagnosis of cardiac lesions than conventional radiology. Although a diagnosis cannot usually be made by conventional radiology, these two-dimensional static views of three-dimensional dynamic organs can provide useful information with regard to physiological and pathological haemodynamics, and normal and pathological anatomy. It is thus an essential routine examination in the diagnosis of cardiac lesions.

PRELIMINARY QUESTIONS

When the clinician is confronted with a set of radiographs of the heart, the following questions need an answer: Has the correct examination been done? A correct examination in any individual will depend on the clinical problem. Are the films technically of diagnostic quality? An opinion should never be given about films which are not of a high standard. Are there any technical and/or physiological factors which may influence the cardiopulmonary configuration? Of these, the following are most important:

1. At what distance were the films exposed and was the examination done postero-anterior or anteroposterior? To limit geometrical enlargement of the heart shadow, films must always be taken at a minimum distance of 1,5 m and frontal views must be taken postero-anterior (Fig. 1). In infants and young children, anteroposterior views are, however, acceptable.

2. Have the films been taken with the patient in an erect, sitting or supine position? Films must always be taken with the patient standing erect, except in the case of infants.

3. In which phase of respiration were the films taken? All films, without exception, must be taken immediately after a full inspiration (Fig. 2).

4. Were the exposures made during systole or diastole? Under normal circumstances, there is an insignificant difference in heart size between systole and diastole. In severe bradycardia, however, there may be a significant difference in size.

5. Is there a pericardial fat pad which may give a false impression of cardiac enlargement?

6. Is a prominent left middle arc normal? A prominent left middle arc of the heart in a young patient may be within normal limits whereas the same degree of promi-

Department of Radiology, Tygerberg Hospital, Parowvallei, CP
J. A. BEYERS, M.D., M.MED. (RAD.), Part-time Consultant Radiologist

Date received: 30 October 1978.

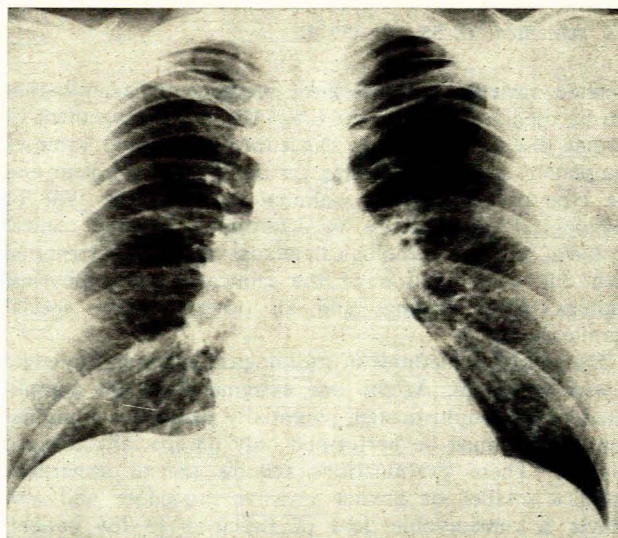
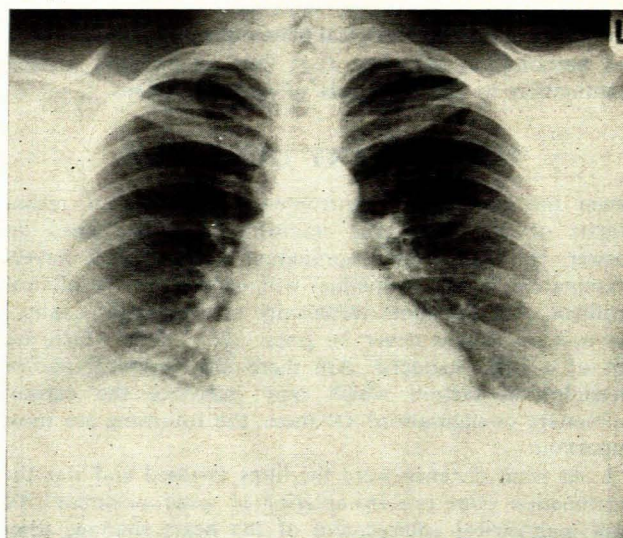
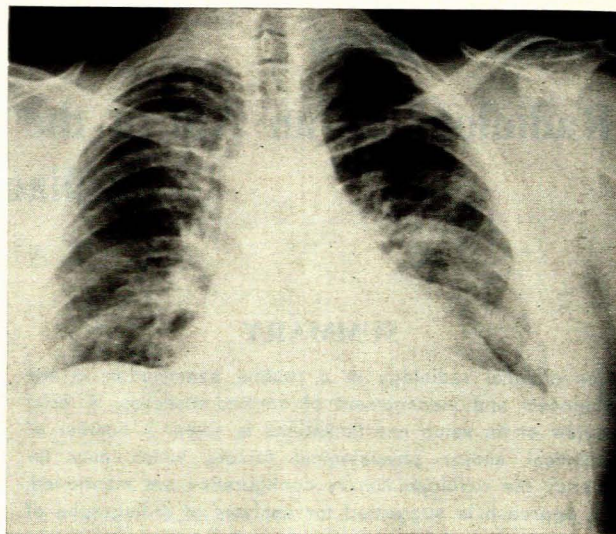
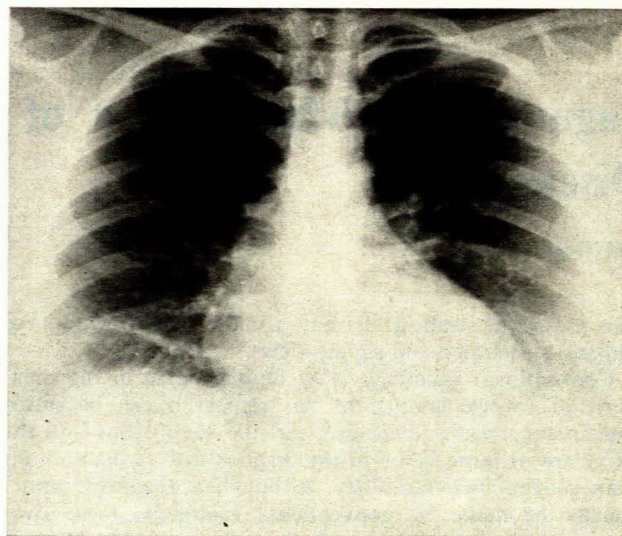


Fig. 1. The importance of distance and position on the apparent heart size in an adult can be seen. Top: antero-posterior radiograph done at 1 metre and the heart shadow appears to be considerably enlarged; bottom: postero-anterior radiograph done at 2 metres and the heart shadow is within normal limits.

Fig. 2. The effect of respiration on the cardiovascular configuration in an adult is illustrated. Top: on the radiograph taken at expiration, the heart shadow appears large and the lung fields appear 'congested'; bottom: on the radiograph taken at inspiration, the heart shadow and lung fields are within normal limits.

nence in an older patient may be abnormal.

The wide spectrum of normal appearances of the heart shadow and pulmonary vasculature must always be borne in mind.

ANALYSIS OF THE RADIOGRAPHS

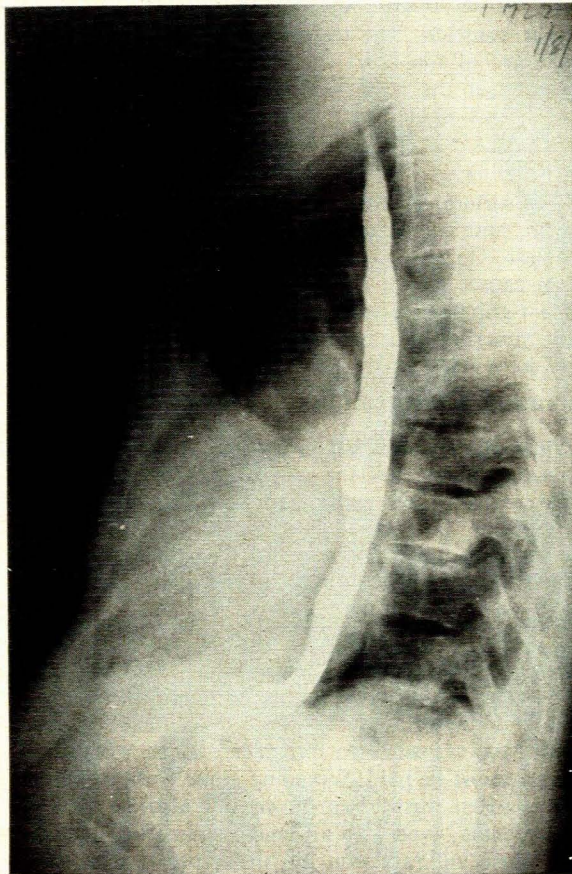
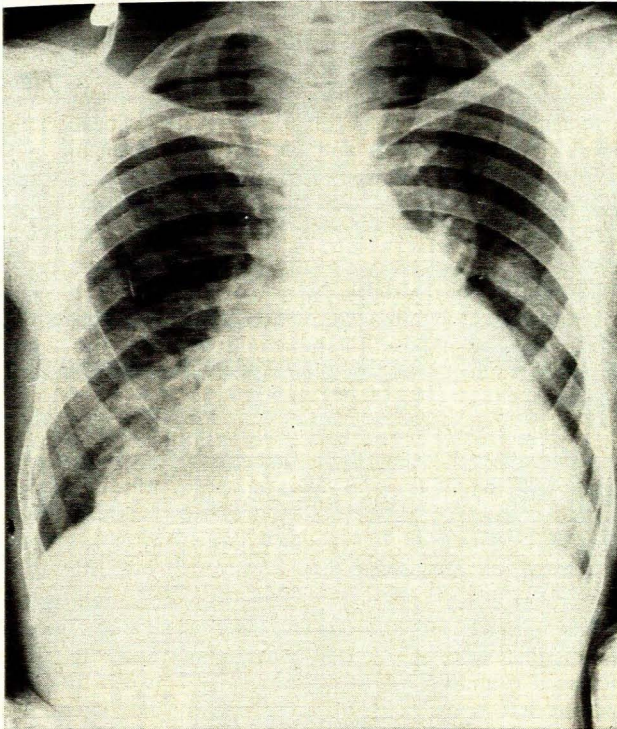
In analysing the radiographs, it is necessary to start as far away as possible from the heart shadow. In clinical examination of the heart one should start at the fingertips. When examining radiographs of the heart it is advisable to proceed as follows:

Bony thorax. Kyphoscoliosis and ankylosing spondylitis can cause cor pulmonale. A depressed sternum can give

a false impression of cardiac enlargement (Fig. 3). Loss of the normal dorsal kyphosis, the so-called 'straight-back syndrome', can also give a false impression of cardiac enlargement. Rib notching probably indicates coarctation of the aorta.

Domes of the diaphragm. Bilateral elevation of the domes of the diaphragm may give a false impression of cardiac enlargement. Bilateral, low, flat domes of the diaphragm may indicate emphysema. Unilateral elevation of a dome of the diaphragm may draw attention to a pulmonary embolism.

Pleural spaces. A pleural effusion due to cardiac failure is usually found when there is combined right and left ventricular failure, and then there is usually more fluid in



the right than in the left pleural space. A trace of pleural fluid in a costophrenic angle or in an interlobar fissure, or a so-called 'thickened' fissure, can be found as well as pulmonary oedema in pure left ventricular failure. Sometimes a transient encapsulated interlobar pleural effusion, the so-called 'vanishing tumour', is found in congestive cardiac failure.

Lung fields. The lung fields must always be very carefully examined and if any abnormality is detected it must be determined whether such an abnormality is primary, secondary or coincidental. Primary pulmonary abnormalities such as emphysema and diffuse fibrosis can give rise to cor pulmonale. Secondary pulmonary abnormalities may be pulmonary oedema, pulmonary embolism, haemosiderosis or bony nodules. Because pulmonary oedema is such a common complication of cardiac lesions it is important to ascertain specifically whether there is any evidence of pulmonary oedema. This may be interstitial, intra-alveolar or a combination of the two. Pulmonary changes may also be coincidental as in the case of tuberculosis or a tumour.

Pulmonary blood vessels. An evaluation of these blood vessels is important and in every case it should be ascertained whether there is evidence of (i) increased pulmonary blood flow; (ii) decreased pulmonary blood flow; (iii) raised pulmonary venous pressure; or (iv) raised pulmonary arterial pressure. These changes in the pulmonary vasculature are of great importance and must always be analysed carefully. The correct evaluation of these changes is, however, difficult and requires long experience.

Aorta. The size and shape of the aorta should be noted and calcification and abnormal pulsations should be looked for.

Right and left main pulmonary arteries. The size, shape and pulsations of these arteries should be carefully noted.

Superior vena cava and azygos vein. Dilatation of the superior vena cava and the azygos vein must be looked for because such dilatation is an indication of raised systemic venous pressure.

Heart Shadow

It is only at this stage that the heart shadow is analysed and the following questions must be asked: is the heart shadow enlarged, is there individual cardiac chamber enlargement, and is there abnormal calcification?

By means of measurements on postero-anterior and left lateral views, the surface area and/or volume of the heart shadow can be calculated and this can then be compared with normal standards. These methods are fairly accurate but are time-consuming and are not used as routine procedures.

The simplest method which depends on measurements is comparison of the widest transverse diameter of the

Fig. 3. The heart shadow appears large and the form of the heart shadow is so suggestive of a mitral valve lesion that a barium swallow was requested to demonstrate an enlarged left atrium. The heart is entirely normal and the apparent abnormal size and configuration are due to the markedly depressed sternum (the round opacity in the left mid lung field and the big opacity in the right cardiophrenic region are due to neurofibromas on the skin).

heart shadow with the widest transverse diameter of the chest. In adults the ratio must be less than 1 to 2. This method is not very accurate or reliable but does give a rough idea of heart size. Even so, it is more reliable, particularly in obese or thickset adults, than clinical estimation.

The least complicated method of all is a subjective one. Here it is necessary to look at the postero-anterior and left lateral views of the chest, and by taking into consideration the age, sex and physique of the patient as well as the form of the chest and the phase of respiration, it can be decided whether a particular heart shadow in a particular chest is within or outside the limits of normal. This method may produce very accurate or very inaccurate results, depending on the experience, judgement or prejudice of the clinician involved.

Conventional radiology is the most reliable simple method of examination for the determination of heart size. There are often borderline cases where it is of value to have preceding and follow-up radiographs for comparison.

The pericardium, whether normal, thickened or filled with fluid, cannot be identified separately from the heart shadow. An enlarged cardiac shadow may thus be due to a pericardial effusion or to enlargement of the heart itself (Fig. 4). Structures such as tumours or cysts which border on the heart shadow may fuse with the shadow and give a false impression of enlargement of the heart.

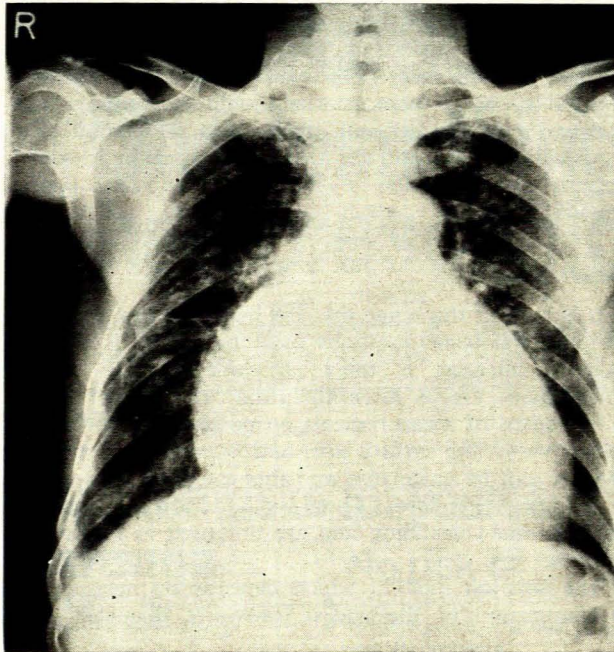


Fig. 4. The large cardiac shadow is due to a pericardial effusion. The heart itself is normal.

Cardiac Chamber Enlargement

Left atrium. Enlargement of the left atrium can be diagnosed at an early stage and with confidence. Signs of

enlargement of the left atrium are: on the postero-anterior view the left atrial appendage causes a bulge between the pulmonary artery and the left ventricle; a double density is visible through the heart shadow; the enlarged left atrium may cause a bulge on the left cardiac border; the carina may be widened; and the left main bronchus may be elevated and narrowed. On the left lateral and right anterior oblique views the enlarged left atrium bulges posteriorly and displaces the barium-filled oesophagus posteriorly.

Left and right ventricles. No radiological signs are sensitive or reliable enough to demonstrate mild degrees of enlargement of these chambers. Even a considerable degree of enlargement may be overlooked or interpreted incorrectly.

To diagnose left and/or right ventricular enlargement and to differentiate between these two, the examiner's hand is often, and the ECG is always, of more value than conventional radiology. There are, however, certain classic signs of left and right ventricular enlargement which should be looked for because, if they are present and fit in with the clinical picture, they strengthen the clinical impression.

Left ventricle. On the postero-anterior view the cardiac apex is displaced downwards and laterally and also shows increased rounding, while the concavity between the aorta and the left ventricle is increased. On the left lateral and left anterior oblique views, the enlarged left ventricle bulges further posteriorly than it normally does.

Right ventricle. On the postero-anterior view the left middle arc of the heart shadow is enlarged owing to enlargement of the right ventricular outflow tract, and the cardiac apex is elevated. On the left lateral and left anterior oblique views the enlarged right ventricle bulges anteriorly.

Right atrium. Right atrial enlargement is usually secondary to, and dominated by, enlargement of other cardiac chambers. On the postero-anterior view an enlarged right atrium causes lateral displacement and increased rounding of the right heart border, often associated with dilatation of the superior vena cava and azygos vein.

Abnormal Calcification

Calcification within the heart shadow is sometimes seen on routine views, but the correct method of examination is by means of screening with an image intensifier and TV monitor, a sensitive and reliable method to demonstrate calcification.

Screening

Screening is valuable especially to demonstrate pulsations and calcification but must be done after the postero-anterior and left lateral films have been studied so that one knows what to look for and to what particular attention must be paid. Screening alone without films of the chest is often misleading. It should also be remembered that screening, even with an image intensifier, gives a much larger dose of radiation to the patient than does the taking of films.

CONCLUSIONS

The value of conventional radiology in the diagnosis of cardiac disease can be summarized as follows: it may clinch or cast doubt on the clinical diagnosis. It gives an indication of the degree of general cardiac enlargement and/or individual cardiac chamber enlargement. Valuable information on cardiopulmonary haemodynamics can be obtained and it is the only means by which interstitial

pulmonary oedema can be diagnosed. Additional information can be obtained about a cardiac lesion, e.g. pulmonary oedema, pleural fluid or pulmonary embolism, and it may demonstrate a primary pulmonary lesion such as emphysema or diffuse fibrosis which is responsible for the lesion. It may demonstrate incidental findings, and can give valuable information about the development of the cardiac lesion and the effect of treatment. Screening can demonstrate abnormal pulsations and calcification.

Acid-Base Balance Made Simple

T. H. J. DUNSTON

SUMMARY

The control of extracellular acid-base balance is difficult to grasp unless it is realized that the pH of the blood depends upon the ratio $H_2CO_3/NaHCO_3$ and that, without alteration of pulmonary ventilation, the H_2CO_3 neither rises nor falls. It must also be understood that the H^+ ions, excreted by the kidneys, are byproducts of $NaHCO_3$ reclamation and neogenesis and are not derived from metabolic acids.

S. Afr. med. J., 55, 205 (1979).

There are two concepts that must be clear if the acid-base balance of the blood is to be understood. The lungs control the level of H_2CO_3 in the extracellular fluid by setting the P_{CO_2} between narrow limits, and the lungs, not the kidneys, deal with the H^+ ions produced by metabolic processes, both normal and abnormal.

Provided the temperature remains constant, the pressure of gas on the surface of a liquid determines the amount of gas that will remain dissolved in the liquid. As air is made up of a mixture of gases, each individual gas will exert a pressure proportional to its molecular concentration. These individual pressures are called partial pressures. From this we can deduce that the amount of CO_2 dissolved in

the extracellular fluid is controlled by the partial pressure of the CO_2 (P_{CO_2}) in the alveoli of the lungs.

When CO_2 dissolves in water (extracellular fluid) two important things happen. A small amount of CO_2 is hydrated to H_2CO_3 by combination with water. The amount of H_2CO_3 formed is directly proportional to the amount of CO_2 in solution and therefore to the P_{CO_2} . (No enzyme is required for this reaction.) H_2CO_3 is a weak acid and so a small but constant proportion dissociates into H^+ ions and HCO_3^- ions.

The result of these events is that an increase in P_{CO_2} in the alveoli will increase the CO_2 in solution and also the amount of H_2CO_3 in the extracellular fluid. A decrease in P_{CO_2} will allow CO_2 to come out of solution and the amount of H_2CO_3 will decrease. The extra CO_2 which can no longer be held in solution will be removed as rapidly as possible.

CO_2 in the extracellular fluid arises in the tissues from aerobic metabolism of carbohydrates and fats. Being produced in so many places at once, it immediately saturates the extracellular fluid to a concentration dependent upon the P_{CO_2} in the alveoli. Actually a considerable excess is produced and this is taken to the lungs by the red cells for excretion. The process is shown in Fig. 1.

In the tissues the excess CO_2 diffuses into red cells, which in this situation contain a proportion of reduced Hb. Within the red cells there is an enzyme, carbonic anhydrase, which catalyses the reaction $CO_2 + H_2O \rightleftharpoons H_2CO_3$. This reaction can proceed in either direction, depending on whether the concentration of CO_2 or H_2CO_3 is higher. If CO_2 is present in greater quantity, it will proceed to

Department of Chemical Pathology, Medical University of Southern Africa, Pretoria

T. H. J. DUNSTON, M.B. B.CH., M.D., Professor

Date received: 25 July 1978.