

Rupture of sinus of Valsalva aneurysm into both right atrium and right ventricle

A case report

J. Z. PRZYBOJEWSKI, R. S. BLAKE, J. J. DE WET LUBBE, J. ROSSOUW, J. J. VAN DER WALT

Summary

A young man had a congenital sinus of Valsalva aneurysm originating from the right coronary sinus, complicated by fistulas draining into both right atrium and right ventricle, as well as a congenitally abnormal aortic valve with mild aortic insufficiency. His dramatic clinical presentation, with the sudden appearance of severe biventricular cardiac failure unresponsive to intensive medical therapy, was an important clue to making the correct pre-operative diagnosis. The use of non-invasive techniques, such as phonocardiography and M-mode and two-dimensional echocardiography, is highlighted. Full cardiac catheterization was employed to define the cardiac pathophysiology. This was one of the few cases documented in which a catheter could be passed from the aorta into the right ventricle via the fistula connecting these two chambers. The fistulas were closed and the aortic valve replaced. Postoperative investigations confirmed the success of corrective surgery.

As far as we are aware this is the first documented case of successful repair of a congenital sinus of Valsalva aneurysm rupturing into both the right atrium and right ventricle, accompanied by aortic insufficiency.

S Afr Med J 1983; 63: 616-625.

It has been estimated that sinus of Valsalva aneurysms occur in 3,5% of patients who undergo surgery for congenital heart disease.¹ Most of these are congenital but some are secondary to Marfan's syndrome, infective endocarditis, aortic dissection,² and, very rarely, syphilis. There have been many reports of unruptured sinus of Valsalva aneurysms associated with right ventricular outflow tract obstruction,³ tricuspid valve insufficiency,

aortic valve insufficiency,^{1,4} ventricular tachycardia,⁵ and coronary artery obstruction.⁶ However, many patients with unruptured aneurysms remain asymptomatic until rupture occurs, when an acute clinical condition supervenes. These symptoms usually depend upon the direction of rupture as well as the extent of ensuing left-to-right shunting. The most common sites of communication are with the right atrium or right ventricle, and more rarely the left ventricle, giving rise to acute volume overload of the involved cardiac chamber. Very rarely there is rupture into the interventricular septum, when the outcome is usually fatal. Congenital aneurysms are generally confined to the right sinus, and those related to infective endocarditis or syphilis to the left coronary sinus. Associated aortic insufficiency is often due to prolapse of the aneurysm into the left ventricle, mimicking aortic valve disease of congenital or rheumatic origin. Non-invasive techniques, especially M-mode and two-dimensional echocardiography, have recently become important in diagnosis. Nevertheless, formal cardiac catheterization with obligatory aortic cine angiography is essential to make a correct diagnosis. Treatment, whether the aneurysm has ruptured or not, is surgical, failing which the patient lapses into progressive and fatal biventricular cardiac failure.

A case is presented in which two fistulas, into both the right atrium and the right ventricle, together with an associated patent foramen ovale (PFO) and aortic insufficiency, were successfully repaired. As far as we know, this case is unique.

Case presentation

A 27-year-old Ovambo male teacher was admitted to the Oshakati Hospital, SWA, in January 1982. He had been completely well and participated in soccer and other strenuous sport up until December 1981, at which time he noticed the sudden onset of increasing severe dyspnoea both at rest and on effort. On admission he was in 'massive heart failure' with anasarca, pulmonary oedema and hepatomegaly. There was no past history of acute rheumatic fever or any other cardiac illness. On examination he was severely dyspnoeic and tachypnoeic with diffuse bilateral crepitations. He had a tachycardia of 100/min, regular, with a collapsing radial pulse. The blood pressure was 120/50 mmHg and 'pistol-shot' femoral arteries and a positive Corrigan sign were noted. An elevated jugular venous pressure was accompanied by a 6 cm tender, pulsatile hepatomegaly and prominent ascites and oedema of the lower limbs. He was therefore in significant biventricular cardiac failure. The left ventricle was enlarged with a grade 4/6 aortic insufficiency murmur. There were no signs of infective endocarditis and the teeth were normal. A chest radiograph showed massive cardiomegaly with pulmonary plethora, and a resting ECG left ventricular, left atrial and right atrial enlargement. The antistreptolysin O titre was 200 Todd units (normal) and repeated blood cultures were

Cardiac Unit, Department of Internal Medicine, and Departments of Cardiothoracic Surgery and Anatomical Pathology, Tygerberg Hospital and University of Stellenbosch, Parowvallei, CP

J. Z. PRZYBOJEWSKI, M.B. CH.B., F.C.P. (S.A.)

R. S. BLAKE, M.B. CH.B., M.MED. (INT.)

J. J. DE WET LUBBE, M.B. CH.B., M.MED. (THORAC. SURG.)

J. ROSSOUW, M.B. CH.B., M.MED. (THORAC. SURG.), PH.D. (MED.)

J. J. VAN DER WALT, M.MED. (PATH.), M.D.

negative. A full blood count, the haemoglobin level, white cell count and erythrocyte sedimentation rate were normal. The patient was immediately started on digoxin 0,25 mg/d, furose-mide 200 mg/d, potassium supplements, penicillin V 250 mg twice daily, and prazosin 2 mg 3 times daily. He was then seen by Professor A. J. Brink who made a clinical diagnosis of ruptured sinus of Valsalva aneurysm with aortic insufficiency; he was particularly impressed with the loudness of the continuous murmur to the right of the sternum. It was then decided to arrange for urgent transfer of the patient to Tygerberg Hospital.

Physical examination

The patient was admitted to the medical wards where he was seen in consultation with the Cardiac Clinic on 6 March 1982. He was apyrexial but rather distressed on account of severe biventricular cardiac failure. There were no obvious signs of possible infective endocarditis. Sacral and pedal oedema were extensive, as was ascites, and there was slight right upper quadrant abdominal discomfort from a 10 cm pulsatile, quite firm hepatomegaly in the absence of splenomegaly. He had a regular radial pulse of 90/min, markedly collapsing in quality. There was also a positive Corrigan's sign with 'pistol-shot' femoral arteries, all the peripheral pulses being readily palpable. The blood pressure was 110/50 mmHg and the jugular venous pressure was raised to 10 cm with very prominent 'a' and 'v' waves. The apical impulse was best palpated in the 6th left intercostal space in the anterior axillary line and was left ventricular in nature. A prominent left parasternal heave was evident, in keeping with probable right ventricular or right atrial enlargement. A systolic/diastolic thrill was easily palpable at the base of the heart. Auscultation at the mitral area (apex) revealed a normal first heart sound, as well as easily audible second and third heart sounds. There was a grade 3/6 ejection systolic murmur which radiated up to the left parasternum, as well as a grade 2/4 high-pitched mid-diastolic murmur localized to the mitral area. The 4th left intercostal space (tricuspid) revealed a grade 5/6 ejection systolic murmur which masked the second heart sound and spilled over into early diastole where it fused with a grade 4/4 high-frequency pandiastolic murmur. This 'machinery' or continuous murmur was remarkable in that it was just as loud to the right of the sternum and did not vary in character with respiration. In the pulmonary area there was a grade 4/6 ejection systolic murmur separated from a

grade 2/4 early diastolic murmur by an accentuated pulmonic component of the second heart sound. The aortic area revealed similar but somewhat softer murmurs. There were diffuse bilateral crepitations in the lungs, without bronchospasm or any other abnormal signs. The rest of the clinical examination was negative.

Routine urinalysis and microscopy were negative, and the full blood count and erythrocyte sedimentation rate were normal. A chest radiograph (Fig. 1) delineated striking generalized cardiomegaly, significant pulmonary oedema with a right-sided pleural effusion, as well as pulmonary plethora. The resting ECG (Fig. 2a) showed a sinus rhythm of 98/min, a P-R interval of 0,20 second and a mean QRS axis of $+50^\circ$. Striking right atrial enlargement was evident and associated with diffuse, non-specific ST-T-wave flattening. There were no features of right or left ventricular hypertrophy. Repeated blood cultures and serological tests were all negative. The patient's serum potassium level was initially quite low in the presence of normal renal function and a normal serum digoxin level. Liver function test results were in keeping with severe hepatic congestion secondary to cardiac failure.

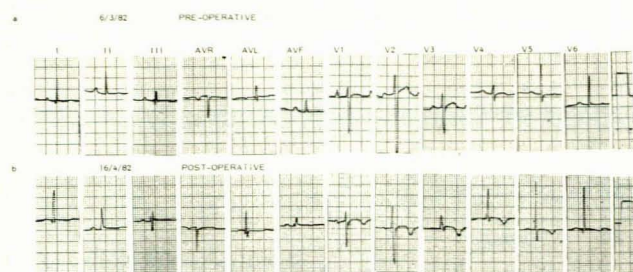


Fig. 2. (a) Pre-operative resting ECG showing marked right atrial enlargement as well as diffuse ST-T wave flattening. (b) Post-operative resting ECG — right atrial enlargement no longer present; antero-septal injury pattern secondary to cardiac surgery is evident.

The patient was diagnosed as having a ruptured sinus of Valsalva aneurysm into the right atrium or ventricle, accompanied by significant aortic regurgitation. Non-invasive tests were employed to help delineate his lesions.

Pre-operative echocardiography

M-mode. The left ventricle had significant diastolic overloading but exhibited good contractility (Table I). Aortic insufficiency was suggested by the presence of fluttering of the anterior leaflet of the mitral valve (Fig. 3a); an interesting feature was that of systolic and diastolic fluttering of the tricuspid valve leaflets (Fig. 3b). Signs of possible infective endocarditis could not be detected.

Cross-sectional (two-dimensional). The patient was positioned in the left lateral decubitus position and a 60° cross-section scan was used. Long-axis views of the left ventricular outflow delineated a large defect in the anterior aortic wall just cephalad to the aortic valve cusps. This defect was particularly prominent during diastole (Fig. 4).

Pre-operative cardiac catheterization

This procedure was carried out on 10 March 1982 using the Seldinger technique from the right femoral vein and artery. The oximetry results, intracardiac pressures and haemodynamic calculations are detailed in Tables II, III and IV respectively. There was evidence of significant biventricular cardiac failure, as indicated by the markedly raised pressures in all the heart chambers. The catheter was also passed from the right atrium

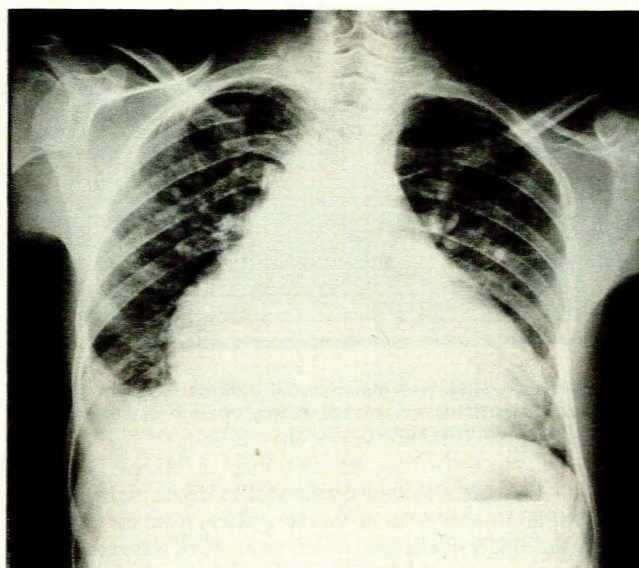


Fig. 1. Chest radiograph (postero-anterior view) showing generalized cardiomegaly, pulmonary oedema and a right-sided pleural effusion. Pulmonary plethora is also present.

TABLE I. PRE-OPERATIVE ECHOCARDIOGRAPHIC MEASUREMENTS

Parameter	Result	Normal range
Left ventricle end-diastole (mm)	58	35 - 56
Left ventricle end-systole (mm)	45	
Interventricular septum thickness (IVS) (mm)	13	7 - 11
Left ventricular posterior wall (LVPW) (mm)	13	7 - 11
IVS/LVPW ratio	1,07	< 1,3
Left atrial dimension (mm)	40	19 - 40
Right ventricle end-diastole (mm)	14	10 - 26
Ejection fraction (%)	44	> 60
Shortening fraction (%)	22	28 - 38
Systemic isovolumic contraction time (ms)	40	28 - 38
Pulmonary isovolumic contraction time (ms)	20	0 - 20
Systemic pre-ejection period (PEP) (ms)	87	
Left ventricular ejection time (LVET) (ms)	337	
PEP/LVET ratio	0,34	< 0,28 - 0,38
Pulmonary pre-ejection period (PEP) (ms)	87	
Right ventricular ejection period (RVET) (ms)	370	
PEP/RVET ratio	0,30	> 0,25 - < 0,30
Left atrium/aortic dimension ratio	1,05	< 1,3

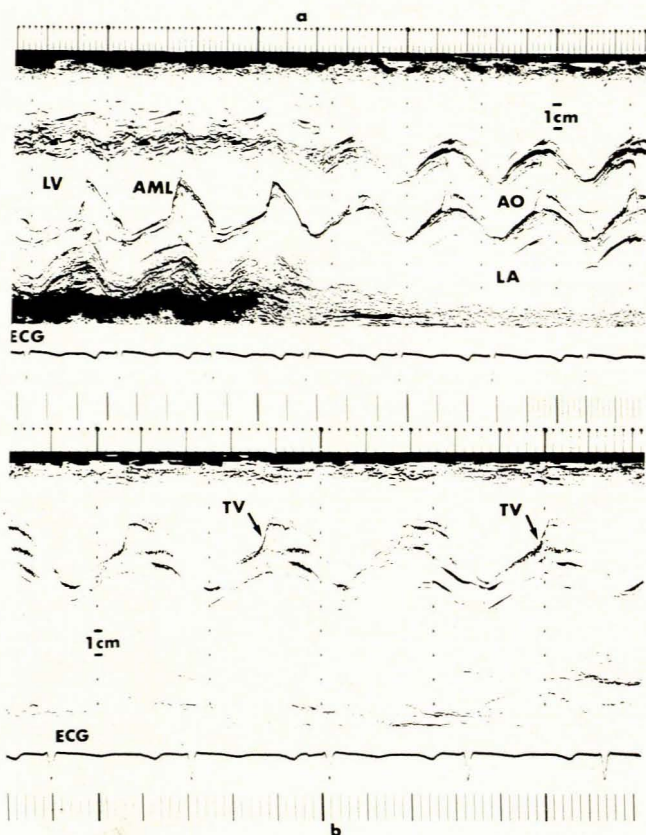


Fig. 3. (a) Pre-operative M-mode echocardiogram. Fine fluttering of the anterior leaflet of the mitral valve (AML) secondary to mild aortic insufficiency (LA = left atrium; LV = left ventricle; AO = aorta; ECG = electrocardiogram). (b) Pre-operative M-mode echocardiogram. Systolic and diastolic fine fluttering of the tricuspid valve (TV) is present.

into the left atrium and pulmonary veins via a patent foramen ovale (Fig. 5). In addition, the 7F pigtail catheter was advanced from the ascending aorta into the right ventricular cavity by way of the fistula connecting these two structures (Fig. 6). Oximetry showed a large left-to-right shunt of 69% via this fistula, as well as a separate step-up in the mid-right atrium initially thought to be due to tricuspid regurgitation rather than a patent foramen

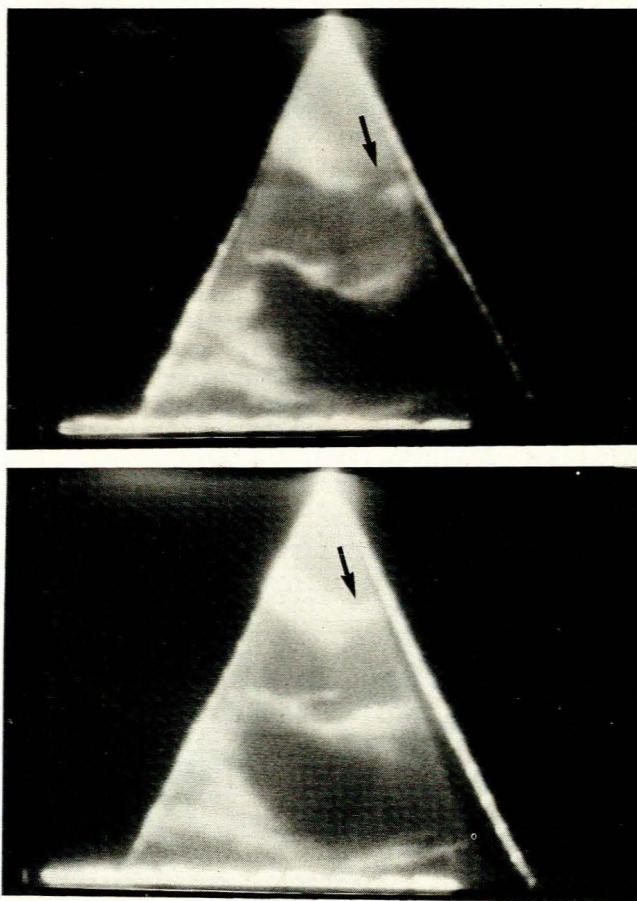


Fig. 4. Pre-operative two-dimensional echocardiogram. Long-axis view shows fistula (arrowed) widely open in diastole (top), but much smaller in systole (bottom).

ovale. In retrospect, this step-up was due to left-to-right shunting via the additional sinus of Valsalva fistula from the aorta to the right atrium. A small right-to-left shunt of 7% was assessed as taking place at atrial level. There was no evidence of mitral valve or aortic valve stenosis.

The following cine angiograms were done: left ventricular (right and left anterior oblique projections); ascending aorta (left

TABLE II. PRE-OPERATIVE OXIMETRY RESULTS

Catheter position	O ₂ saturation (%)	Comment
Superior vena cava	57	Step-up in saturation
Right atrium (high)	81	due to sinus of Valsalva
Right atrium (low)	87	fistula from aorta into
Inferior vena cava (at diaphragm)	74	right atrium shunting left-to-right
Main pulmonary artery	89	Left-to-right shunt from
Right ventricle (high)	89	aorta to right ventricle
Right ventricle (low)	88	via fistula. Additional
Right atrium (at tricuspid)	87	left-to-right shunting at
Right atrium (low)	81	atrial level due to second
Inferior vena cava (at diaphragm)	79	fistula draining into right atrium
Pulmonary vein	96	Possible small right-to-
Left atrium	95	left shunt via the patent
Right atrium (mid)	89	foramen ovale. Left-to-
Right atrium (high)	82	right shunt via aorta-
Right atrium (low)	83	right atrium fistula
Inferior vena cava (at diaphragm)	80	
Main pulmonary artery (after 100% oxygen)	87	High pulmonary artery
Central (ascending) aorta (after 100% oxygen)	92	saturation due to stream-
	94	ing from the fistula
	98	

TABLE III. PRE-OPERATIVE INTRACARDIAC PRESSURES

Catheter position	Pressure (mmHg)	Comment
Right atrium	'a' wave 20; 'x' descent 15 'v' wave 28; 'y' descent 12 (mean 18)	Markedly raised pressures
Right ventricle	47/0-17	Raised pressures
Main pulmonary artery	47/21 (mean 33)	Moderately severe pulmonary hypertension
Pulmonary capillary wedge (left)	'a' wave 34; 'x' descent 21 'v' wave 45; 'y' descent 21 (mean 29)	Very raised Large 'v' waves
Left ventricle	120/0-18	Raised end-diastolic
Ascending aorta	120/62 (mean 86)	Wide pulse pressure
Right ventricle	48/0-18	Pressure withdrawal via fistula
↓ Ascending aorta	90/52 (mean 66)	
Left atrium	'a' wave 21; 'x' descent 13 'v' wave 29; 'y' descent 17 (mean 18)	Markedly raised pressures which have equalized
↓ Right atrium	'a' wave 22; 'x' descent 17 'v' wave 30; 'y' descent 14 (mean 18)	

anterior oblique projection); left atrial (shallow half-axial left anterior oblique view). The left ventricle was moderately dilated with slightly reduced generalized contractility (Fig. 7). There was no mitral valve calcification or insufficiency. Filling of the right ventricle and its outflow tract could be visualized due to the fistulas draining from the aorta into both the right atrium and right ventricle. There was no ventricular septal defect. Injection of dye into the ascending aorta delineated mild aortic insufficiency. The right atrium and right ventricle also filled because of the fistulas draining from the sinus of Valsalva aneurysm (Fig. 8). Left atrial injection of dye outlined an enlarged chamber with

normal pulmonary venous drainage but no passage of contrast into the right atrium (Fig. 9a). Right ventricular angiography (Fig. 9b) revealed a markedly dilated ventricle with preserved generalized contractility. Cardiac catheterization thus demonstrated the presence of a sinus of Valsalva aneurysm with rupture into both the right atrium and right ventricle producing significant left-to-right shunting. Mild aortic insufficiency and a patent foramen ovale were also diagnosed.

The patient continued on medical therapy with no further significant improvement in his clinical condition and was therefore subjected to cardiac surgery on 16 March 1982.

TABLE IV. PRE-OPERATIVE HAEMODYNAMIC CALCULATIONS

Parameter	Result
Pulmonary blood flow (l/min)	11,2
Index (Fick) (l/min/m ²)	7,5
Systemic blood flow (l/min)	3,6
Index (Fick)(l/min/m ²)	2,5
Pulmonary vascular resistance (U)	1,6
Index (U/m ²)	2,4
Systemic vascular resistance (U)	21,9
Index (U/m ²)	32,4
Pulmonary/systemic resistance ratio (%)	7,0
Left-to-right shunt (by saturation)(%)	69,0
Right-to-left shunt (by saturation)(%)	7,0
Diastolic filling period (s/min)*	24,6
Systolic ejection period (s/min)*	23,5
Left ventricular dp/dt (mm/s)	2104

*s = rate of change of pressure rise in the left ventricle. This is an index of contractility.

Operative findings and surgical correction

A median sternotomy approach was used and venous cannulas were inserted into the superior and inferior vena cava. Moderate body hypothermia to 25°C was employed during cardiopulmonary bypass. Cold cardioplegic solution was then rapidly infused into the aortic root for myocardial protection. After incision into the pericardium massive enlargement of all the cardiac chambers was noted and a thrill could be felt over the right atrium as well as the right ventricle. The right atrium was explored and a jet of blood could be felt in this chamber originating from a sinus of Valsalva aneurysm which had perforated at its distal end with a 4 mm opening. The aneurysm could be clearly seen projecting into the right atrium at the junction of the septal and anterior leaflets of the tricuspid valve. The three aortic valve leaflets were extremely thin and contained perforations near the implantation at the apex of the commissures. The aortic root was dilated.

The right sinus of Valsalva had two perforations, one on the right side about 4 mm in diameter and the one on the left side

about 6 mm. Two separate probes were passed through these orifices and it was confirmed that the right fistula led into the right atrium and the left fistula into the right ventricle. The fistulas were then closed with interrupted Tycron sutures and buttressed with felt pledgets.

The aortic valve was excised and replaced with a 23 mm Ionescu-Shiley bioprosthesis. The transverse aortotomy was closed and all the air removed from the left side of the heart. After rewarming, electrical defibrillation was successful. During the rewarming phase the right atrium was closed.

No evidence of any infected vegetations could be seen in the aortic valve. Microscopy delineated slight fibrosis with features of myxomatous degeneration, i.e. congenital abnormality.

Postoperative clinical course

The cardiac failure subsided quite rapidly, leaving slight systemic venous congestion. Auscultation of the aortic Ionescu-Shiley bioprosthesis confirmed an adequately functioning valve. A repeat resting ECG demonstrated a quite dramatic decrease in the right atrial enlargement (Fig. 2b), as well as the usual antero-septal injury pattern related to cardiac surgery. All medication was gradually withdrawn without any untoward effect, and non-invasive investigation was repeated some 4 weeks postoperatively.

Postoperative echocardiography

M-mode. The indices of left ventricular function were significantly improved. There was also no longer any evidence of systolic and diastolic fluttering of the tricuspid valve leaflets. Multiple echoes from the aortic bioprosthesis made it difficult to assess the opening and closing characteristics of this valve. There was no longer any fluttering of the anterior leaflet of the mitral valve, suggesting correction of the pre-operative aortic regurgitation.

Two-dimensional. The previous features of the sinus of Valsalva fistulas were absent (Fig. 10), and the defect in the anterior wall of the aorta caused by maximum diastolic opening of the aortic-right ventricular and aortic-right atrial communication was no longer visible.

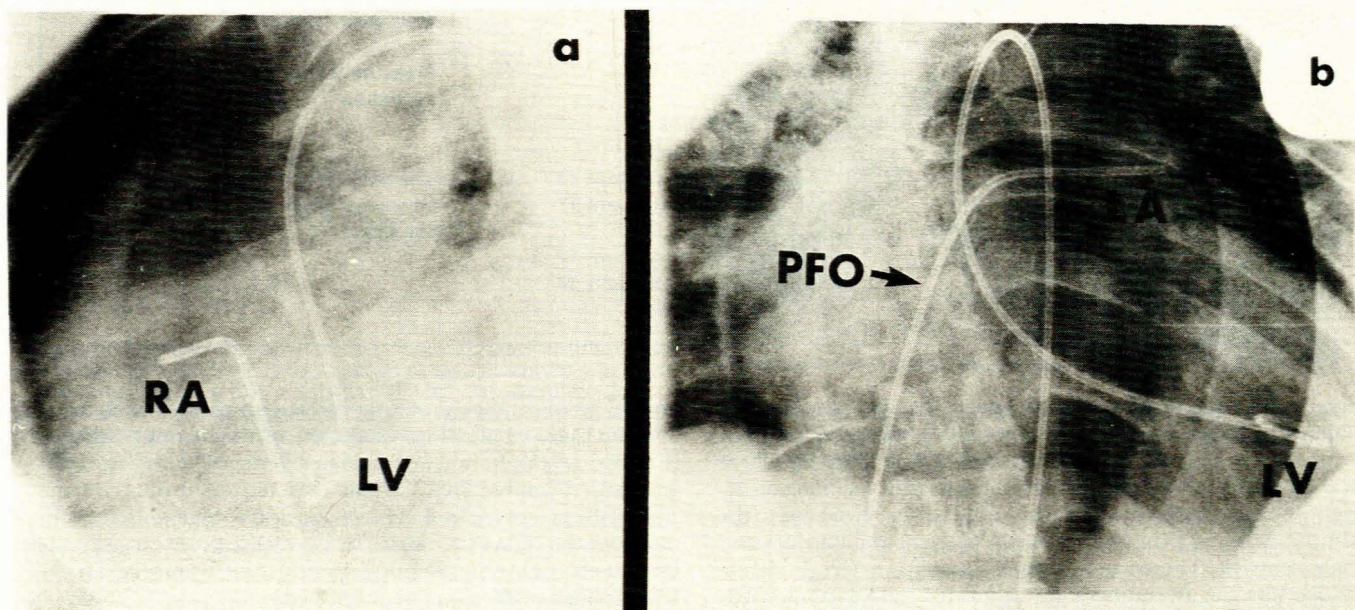


Fig. 5. (a) Pigtail catheter in left ventricle (LV) and other catheter in right atrium (RA). (b) Venous catheter (arrowed) in left atrium (LA) via patent foramen ovale and pigtail in LV.

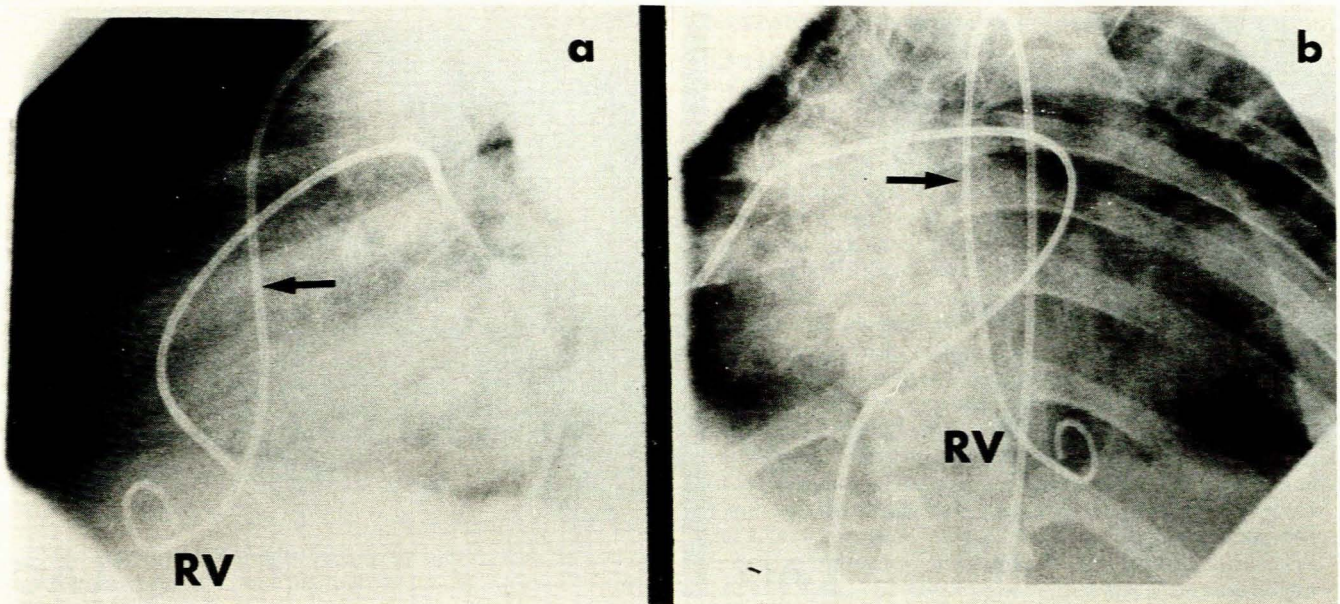


Fig. 6. (a) Pigtail catheter (arrowed) in right ventricle (RV) via fistula; other catheter in right pulmonary artery (left lateral projection). (b) Same catheter positions in frontal projection.

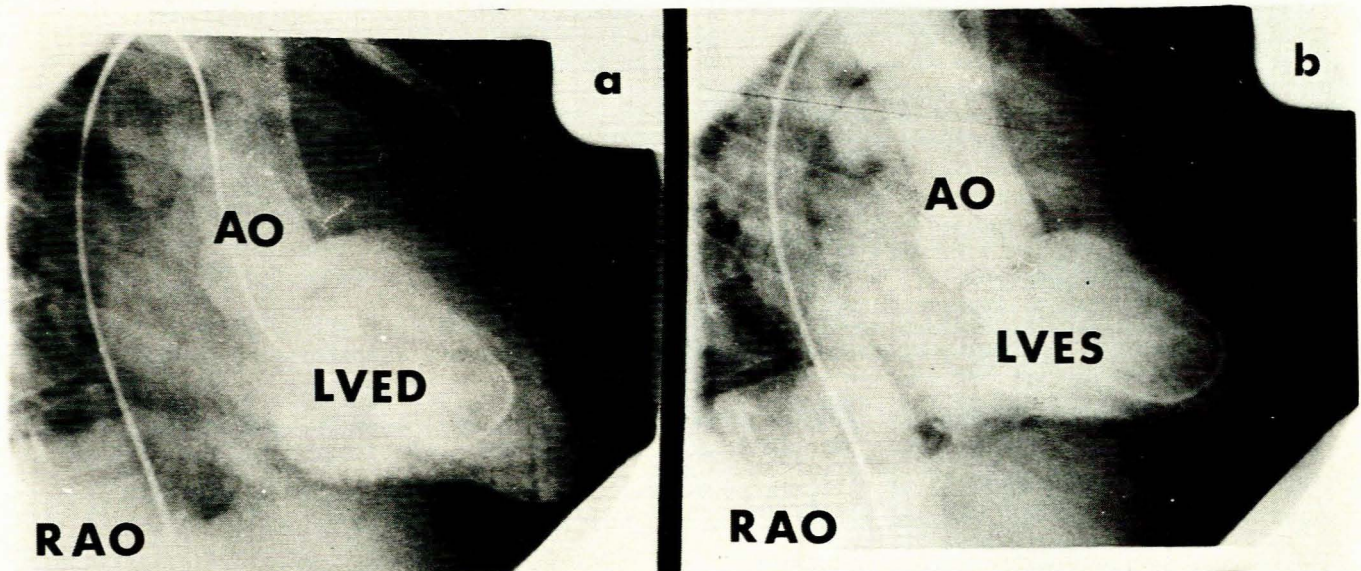


Fig. 7. Left ventricular cine angiogram (right anterior oblique projection) showing dilatation and reduced general contractility in (a) end-diastole (LVED) and (b) end-systole (LVES). There is filling of the right heart and outflow tract via the fistula (AO = ascending aorta).

Postoperative cardiac catheterization

This procedure was undertaken some 5 weeks after surgery. The intracardiac pressures were almost all normal, oximetry no longer delineated any left-to-right or right-to-left intracardiac shunting and the haemodynamics had significantly improved. Cine angiography no longer showed any aortic insufficiency or dye filling the right atrium or left ventricle (Fig. 11).

At this stage the patient was totally asymptomatic. Clinical examination showed a slightly enlarged, soft liver but no other abnormal signs. He was discharged on 17 April 1982 and returned to SWA where he was followed up by staff of our Cardiac Clinic.

Discussion

Usually the right sinus of Valsalva lies anteriorly and the non-coronary and left sinuses posteriorly. However, in some 15% of cases the two coronary sinuses are anterior in position. More than 95% of these aneurysms arise from the right coronary sinus and the right-sided aspect of the non-coronary sinus.⁷ The basic underlying lesion in a ruptured sinus of Valsalva is a lack of fusion or separation between the annulus fibrosus of the aortic valve and the medial coat of the aortic wall.² In turn this is said to stem directly from failure of fusion of the bulbar septum⁸ or of the truncus or conus ridges.⁷ Generally, rupture of a right sinus

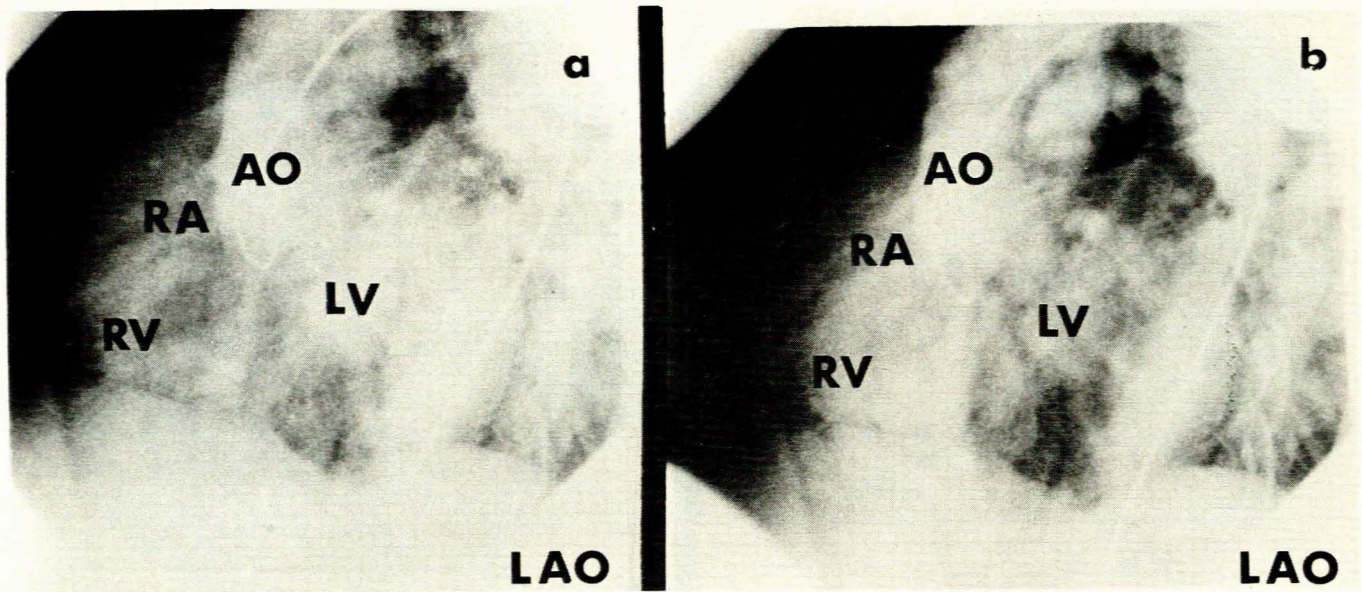


Fig. 8. Aortic cine angiogram (left anterior oblique view) showing filling of right atrium (RA) and right ventricle (RV) via the fistulas. There is filling of the left ventricle (LV) due to slight aortic insufficiency (AO = ascending aorta).

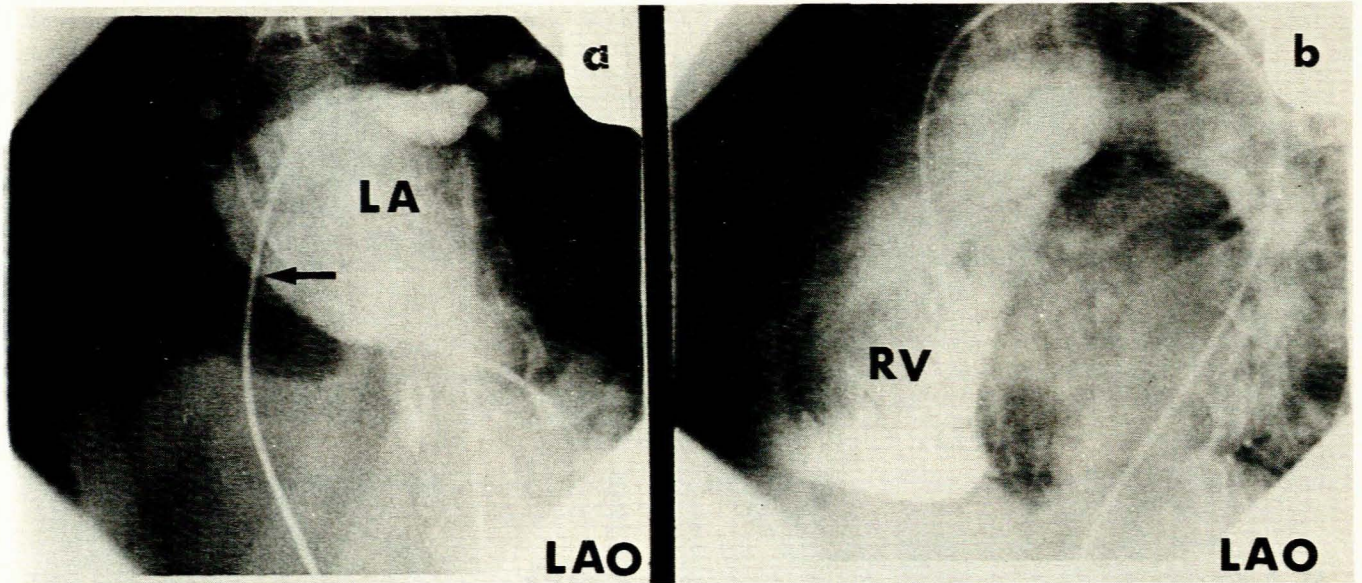


Fig. 9. (a) Left atrial (LA) angiogram (left anterior oblique view) done via patent foramen ovale (arrowed). (b) Right ventricular (RV) angiogram (left anterior oblique view) showing marked dilatation of chamber.

of Valsalva aneurysm is into the right ventricle; a non-coronary sinus aneurysm into the right atrium; and a left sinus of Valsalva aneurysm into the left heart. Very rarely, rupture may ensue with dissection of the interventricular septum.⁹ The most common associated cardiac defect is a ventricular septal defect. Aortic valvular insufficiency has been documented in 15% of cases.¹⁰ The most frequent cause is a congenital defect, followed by bacterial endocarditis giving rise to a mycotic aneurysm.¹¹ Syphilis is said to be a most unusual cause, and so is rupture due to severe rheumatoid heart disease.¹²

A single rupture with fistula formation is by far the most usual consequence of a sinus of Valsalva aneurysm, which is usually single. The only other case of a sinus of Valsalva aneurysm of the right coronary sinus rupturing into the right atrium as well as the right ventricle was that documented by Oram and East.¹³ However, in contrast to our case, their patient did not have associated

aortic insufficiency commonly found in the cases reported by Taguchi *et al.*¹⁴

Clinical presentation

Patients with unruptured sinus of Valsalva aneurysm are usually asymptomatic, unless they have an associated lesion such as coarctation of the aorta with symptoms attributable to the coarctation.¹⁵ Murmurs are invariable, usually systolic and widespread over the precordium. Some patients also have diastolic and systolic murmurs at the base of the heart if there is any obstruction to the outflow tract of the left ventricle or associated aortic valvular lesions.

With the onset of rupture of an aneurysm an acute clinical picture becomes evident. The patient usually complains of the

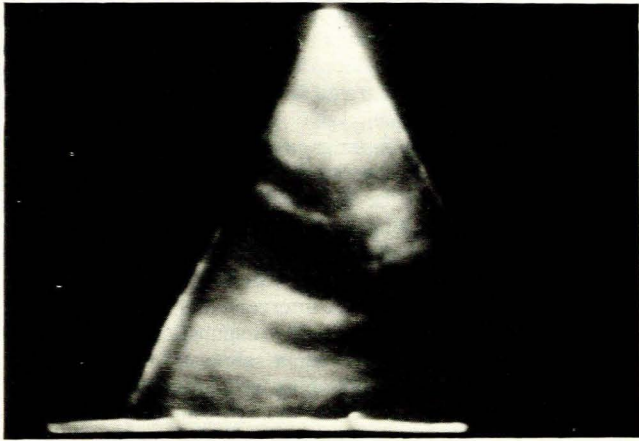


Fig. 10. Postoperative two-dimensional echocardiogram. Fistula no longer visualized.

sudden appearance of dyspnoea, chest pain simulating an acute myocardial infarction and palpitations, as in our case. This is usually followed by a fairly symptom-free 'latent period'¹³ of varying length, and subsequently by the insidious development of left ventricular and then biventricular cardiac failure. Interestingly, there have been asymptomatic cases with rupture and the acute onset is said to be less likely if there has been a pre-existing left-to-right shunt such as a ventricular septal defect.¹⁶

Physical examination classically delineates signs of a hyperdynamic cardiac state. Thus, a collapsing pulse is invariable with concomitant biventricular cardiac enlargement. A left parasternal thrill is usually present, as is a continuous murmur, making the diagnosis of associated aortic valvular insufficiency exceptionally difficult to establish unless the diastolic component is best heard to the right of the sternum. However, in some cases there were either systolic murmurs or diastolic murmurs alone.¹⁷ Occasionally, an apical mid-diastolic flow murmur is encountered, suggesting true mitral valve stenosis. Signs of pulmonary hypertension are sometimes evident and the presence of a third and fourth heart sound is most frequent. Spontaneous closure of fistulas is unknown and therefore deterioration leading to death is usual without surgical intervention.

Electrocardiographic features

The ECG does not display typical features with rupture of a sinus of Valsalva aneurysm, and is sometimes abnormal in the absence of such rupture. An aneurysm involving the anterior aspect of the right coronary sinus commonly shows either left ventricular hypertrophy or biventricular hypertrophy.⁷ However, an aneurysm of the posterior part of the right coronary sinus or the non-coronary sinus gives rise to conduction defects.¹³ Thus, rupture into the right atrium would be expected to cause right ventricular hypertrophy or right bundle-branch block or both; rupture into the right ventricle gives rise to left ventricular or biventricular hypertrophy. Incomplete right bundle-branch block, which may be intermittent, appears in some 25% of cases, half of whom have associated left ventricular hypertrophy, and this combination may be highly suggestive of this condition.¹⁰ Complete heart block has been recorded, as have varying degrees of atrioventricular block as well as atrial fibrillation and atrial tachycardia. On the ECG the combination of right axis deviation with suspected clinical aortic valvular insufficiency has been claimed by some to be of diagnostic significance. Nevertheless, left axis deviation has also occurred,⁸ prompting Oram and East¹³ to state that 'the electrocardiographic findings are so inconstant that they give little assistance to diagnosis'.

Our case demonstrated sinus rhythm with a normal mean QRS axis and diffuse, nonspecific, ST-T-wave flattening but no evidence of left or right ventricular hypertrophy. The most impressive feature on the ECG was right atrial enlargement which decreased dramatically after surgical correction. These findings are surprising considering the radiological features as well as the large left-to-right intracardiac shunting, and the presence of two simultaneous defects into the right atrium and right ventricle with the additional mild aortic valvular insufficiency. One would have expected some evidence of diastolic overload of either the right atrium or the right ventricle, or both. The only other comparable case was that documented by Oram and East¹³ in which the pre-operative ECG demonstrated low-voltage changes in the anterolateral leads with intermittent Mobitz type I second-degree atrioventricular block. However, right atrial changes were not commented on and there did not appear to be ventricular hypertrophy.

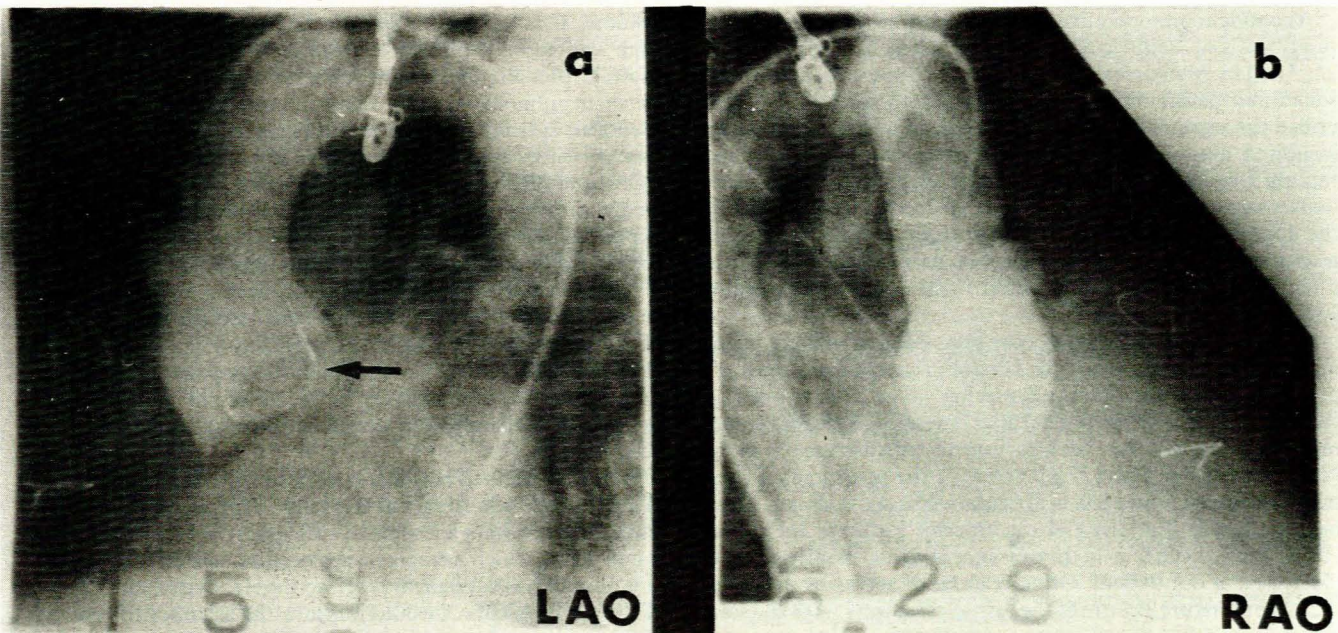


Fig. 11. Aortic cine angiograms in (a) left anterior oblique projection and (b) right anterior oblique view. Ionescu-Shiley aortic prosthesis *in situ* (arrowed). No aortic insufficiency or dye delineation of the right atrium and right ventricle visualized.

Phonocardiography

The literature is scanty on the use of phonocardiography in ruptured sinus of Valsalva aneurysm. A continuous murmur is classically seen with maximum intensity in mid-systole, contrasting with the continuous murmur of a patent ductus arteriosus in which the murmur peaks at the second heart sound.¹⁰ This is well demonstrated in the present case with a recording at the lower left sternal border (Fig. 12). A mid-diastolic flow murmur at the apex could not be elicited and neither could the third and fourth heart sounds. The upstroke of the carotid pulse was not particularly brisk, indicating insignificant concomitant aortic insufficiency. Prominent diastolic waves (dicrotic pulses) were quite clearly shown in the carotid artery tracing, a feature first documented by Morgan *et al.*¹⁶ Early diastolic accentuation of the continuous murmur could not be demonstrated although this finding has been shown to correlate with the period of maximum left-to-right shunting in diastole.¹⁶

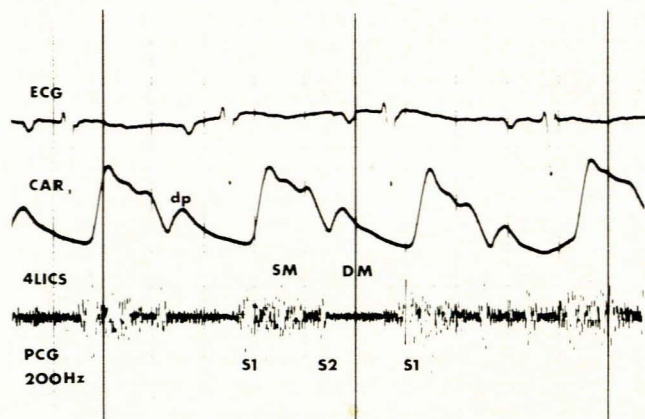


Fig. 12. Phonocardiogram (PCG) done at 4th left intercostal space (4LICS). Systolic (SM) and diastolic murmurs (DM) seen. Prominent dicrotic pulses (dp) noted on carotid artery tracing (CAR) (S1 = first heart sound; S2 = second heart sound; ECG = electrocardiogram).

Echocardiographic characteristics

A confident pre-operative echocardiographic diagnosis of ruptured sinus of Valsalva aneurysm was made by Cooperberg *et al.*,¹⁸ and by Matsumoto *et al.*¹⁹ M-mode echocardiography can sometimes detect the aneurysmal sac. Rothbaum *et al.*²⁰ described the rupture into the left ventricle of an aneurysm which exhibited diastolic movement away from the interventricular septum and systolic motion towards the septum, a feature verified by angiography. The diagnosis may further be suggested by the appearance of echoes within the right ventricular outflow tract situated anterior to the aortic root, particularly if they are in a redundant double-layered pattern and occur between mid-systole and early diastole.

M-mode echocardiography may also reveal premature opening of the pulmonary valve²¹ and systolic fluttering of the tricuspid valve,¹⁹ as well as diastolic fluttering.²² The latter was clearly shown in our case before but not after operation. Systolic fluttering of the tricuspid valve has also been described in membranous ventricular septal defect,²³ aneurysm of the membranous ventricular septum,²⁴ and left ventricular-right atrial shunts (Gerbode defect).²⁵ Fluttering of the anterior leaflet of the mitral valve has also been seen in the presence of aortic insufficiency, as illustrated in our patient. Other features of aortic insufficiency such as premature closure of the mitral valve were not to be seen in our case.

More recently, two-dimensional echocardiography has been employed to improve the accuracy of pre-operative diagnosis.

Matsumoto *et al.*¹⁹ first convincingly demonstrated rupture of a sinus of Valsalva aneurysm with and without associated supra-cristal ventricular septal defect. They observed discontinuity in the echo from the aneurysm wall as well as herniation of the right coronary cusp of the aortic valve into the outflow tract of the right ventricle; these findings disappeared after corrective surgery. We clearly demonstrated discontinuity of the anterior aortic wall cephalad to the aortic valve cusps which was eliminated by operation. Engel *et al.*⁹ made an accurate two-dimensional echocardiographic diagnosis of a congenital aneurysm of the right coronary sinus of Valsalva which ruptured and subsequently dissected into the interventricular septum. Schatz *et al.*²⁶ documented the invaluable diagnostic use of contrast echocardiography using intravenous saline and viewing the left ventricle outflow tract in both short- and long-axis views.

The combined use of M-mode and two-dimensional echocardiography is vital in establishing a diagnosis, especially since the former method alone cannot accurately differentiate between a ruptured sinus of Valsalva aneurysm and such conditions as ventricular septal aneurysm, aneurysms of the coronary arteries and coronary artery fistula. The latter cannot even be definitely excluded by additional two-dimensional echocardiography.

Haemodynamic pathophysiology

The rupture of a sinus of Valsalva aneurysm into the right heart may be justifiably considered an arteriovenous fistula. It is generally accepted that the resulting left-to-right shunting is greatest during diastole, and it is this haemodynamic mechanism, rather than any associated aortic insufficiency, which gives rise to the wide pulse pressure classically encountered. Our patient had mild aortic insufficiency delineated by aortography. The significant left-to-right shunting creates stress on the receiving right heart chambers in the form of volume overloading, but since the right atrium is fairly compliant this is not initially a problem. However, with increasing shunting over a longer period the right atrium can no longer cope and pressures rise. The finding of a patent foramen ovale pre-operatively, which could no longer be crossed at catheterization after operation, indicates that this was stretched by the increased right atrial volume. With additional rupture into the right ventricle, as in our case, this chamber ultimately cannot handle the increased volume. This fact was clearly illustrated by the simultaneously high and most comparable mean right atrial pressure, end-diastolic pressure in the right ventricle, and diastolic pressure in the main pulmonary artery. These three pressures were virtually identical, indicating almost non-functioning tricuspid and pulmonary valves as in right ventricular myocardial infarction. The significant discrepancy between the mean pulmonary capillary wedge pressure and the mean left atrial pressure could not be explained since adequate pressure wave forms were obtained and the degree of pulmonary hypertension was mild.

The increased inflow into the right heart in time affects the left heart, since the increase in volume must be off-loaded in the left atrium and ventricle. This eventually causes a rise in mean left atrial and left ventricular end-diastolic pressure. A hyperdynamic heart state analogous to biventricular cardiac failure ensues. All the parameters returned to normal following surgical correction.

Oximetry defined reasonably accurately the degree and level of left-to-right shunting, but this can be exceptionally difficult if there is concomitant tricuspid insufficiency, or a secundum atrial septal defect which has sometimes been associated with rupture of a sinus of Valsalva aneurysm into the right ventricle. The use of dye dilution curves would improve the accuracy of determining the size and site of these shunts. Unfortunately, our case seems to be the only one in the literature with full haemodynamic assessment, hence findings cannot be compared.

Passage of the cardiac catheter from the ascending aorta into the right atrium or right ventricle through the ruptured sinus of Valsalva aneurysm is diagnostic. This procedure was first described by Magidson and Kay²⁷ in a patient with rupture into the right atrium. Morgan *et al.*¹⁶ described a further 4 cases; the catheter entered the right atrium in 2 and the right ventricle in the other 2. We attempted this, advancing the catheter into the right ventricle from the aorta, on several occasions with a pigtail catheter, giving an indication of the size of the defect (Fig. 13). However, the fistulous opening into the right atrium could not be traversed.

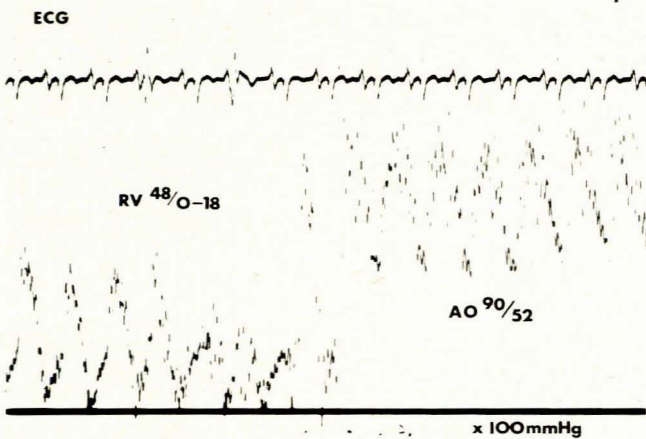


Fig. 13. Catheter pressure withdrawal from right ventricle (RV) to ascending aorta (AO) via one of the sinus of Valsalva fistulas.

Very rarely, an inexplicable cyanosis accompanies ruptured sinus of Valsalva aneurysm,¹³ but there have been no reported cases of an Eisenmenger reaction despite significant levels of pulmonary hypertension. The reason for this is probably that these patients are operated upon early enough or that they die from severe biventricular cardiac failure beforehand.

Surgical correction and prognosis

Once a diagnosis of a sinus of Valsalva aneurysm is established, surgical correction should be undertaken^{16,27} in view of the fact that these aneurysms rupture easily and pursue a fatal course. The other well-known complication is infective endocarditis, often giving rise to haemodynamically significant aortic insufficiency.

The first reported repair of ruptured aneurysm of the sinus of Valsalva was that of Lillehei *et al.*²⁸ who advocated immediate surgical intervention after establishment of the diagnosis. Taguchi *et al.*¹⁴ published a series of 45 consecutive cases of this operation, 8 with aortic valve replacement. The most prominent postoperative problem in their series was residual aortic insufficiency caused by prolapse of an aortic cusp at the site of the aneurysm, stimulating them to advocate the more frequent employment of aortic valve replacement. Their mortality rate was relatively low at 15,6%. It has been noted that a poor surgical result is achieved if there is a concomitant supracristal ventricular septal defect associated with aortic insufficiency.⁷

Oram and East¹³ were the only other authors to report the presence of simultaneous fistulas draining into both right atrium and right ventricle. However, their patient died on the operating table; in our patient surgery was successful, including an aortic valve replacement.

Without operation the condition is uniformly fatal, mainly through relentless congestive cardiac failure. Some patients have died from superadded infective endocarditis; most unoperated patients die within 1 year of diagnosis, although a 5-year survival²⁹ and even a 17-year survival⁸ have been reported. Sanchez *et al.*³⁰ reported 10 patients operated upon over a period of 16 years with no postoperative deaths; 2 had to be re-operated on, one of them having a fistula draining from the non-coronary sinus to

the left atrium, left ventricle and right atrium. All these patients remained asymptomatic at follow-up and there were no long-term deaths or any deterioration in those who had mild aortic insufficiency on initial assessment.

Our patient should have a normal survival since no intracardiac shunting could be detected postoperatively and there were no features of left or right ventricular cardiac failure. The only possible complications would be those related to aortic valve replacement in general, such as infective endocarditis or emboli arising from the aortic prosthesis.

We wish to sincerely thank Miss H. Weymar of the Cardiology Unit, Tygerberg Hospital, for preparing the manuscript. Thanks are also due to Mr Chris Wilberforce, head of the department of photography, and Mrs Inge Blicke for their painstaking preparation of the photographs. Dr M. Nelson and Mrs. R. Meyer were instrumental in the echocardiographic assessment. Finally, due appreciation is shown towards Dr D. Vivier, Chief Medical Superintendent of Tygerberg Hospital, for permission to publish.

REFERENCES

- Bontefeu JM, Moret PR, Hahn C, Hauf E. Aneurysms of the sinus of Valsalva: report of seven cases and review of the literature. *Am J Med* 1978; **65**: 18-24.
- Edwards JE, Burchell HB. The pathological anatomy of deficiencies between the aortic root and the heart, including aortic sinus aneurysms. *Thorax* 1957; **12**: 125-139.
- Kerber RE, Ridges JD, Kriss JP, Silverman JF, Anderson ET, Harrison DC. Unruptured aneurysm of the sinus of Valsalva producing right ventricular outflow obstruction. *Am J Med* 1972; **53**: 775-783.
- London SB, London RE. Production of aortic regurgitation by unperforated aneurysm of the sinus of Valsalva. *Circulation* 1961; **24**: 1403-1406.
- Raizes GS, Smith HC, Vlietstra RE, Puga FJ. Ventricular tachycardia secondary to aneurysm of sinus of Valsalva. *J Thorac Cardiovasc Surg* 1979; **78**: 110-115.
- Eliot RS, Wolbrink A, Edwards JE. Congenital aneurysm of the left aortic sinus: a rare lesion and a rare cause of coronary insufficiency. *Circulation* 1963; **28**: 951-956.
- Sakakibara S, Konno S. Congenital aneurysm of the sinus of Valsalva: anatomy and classification. *Am Heart J* 1962; **63**: 405-424.
- Morgan-Jones A, Langley FA. Aortic sinus aneurysms. *Br Heart J* 1949; **11**: 325-341.
- Engel PJ, Held JS, Van der Bel-Kahn J, Spitz H. Echocardiographic diagnosis of congenital sinus of Valsalva aneurysm with dissection of the interventricular septum. *Circulation* 1981; **63**: 705-711.
- Wright JS. Ruptured aneurysm of the sinus of Valsalva. *Q J Med* 1970; **39**: 493-513.
- Shumacker HB. Aneurysms of the aortic sinuses of Valsalva due to bacterial endocarditis, with special reference to their operative management. *J Thorac Cardiovasc Surg* 1972; **63**: 896-902.
- Howell A, Say J, Hedworth-Whitty R. Rupture of the sinus of Valsalva due to severe rheumatoid heart disease. *Br Heart J* 1972; **34**: 537-540.
- Oram S, East T. Rupture of aneurysm of aortic sinus of Valsalva into the right side of the heart. *Br Heart J* 1955; **17**: 541-551.
- Taguchi K, Sasaki N, Matsuura Y. Surgical correction of aneurysm of the sinus of Valsalva: a report of 45 consecutive patients including 8 with total replacement of the aortic valve. *Am J Cardiol* 1969; **23**: 180-191.
- Steinberg I, Finby N. Clinical manifestations of the unperforated aortic sinus aneurysm. *Circulation* 1956; **14**: 115-124.
- Morgan JR, Rogers AK, Fosburg RG. Ruptured aneurysm of the sinus of Valsalva. *Chest* 1972; **61**: 640-643.
- Anzai N, Yamada M, Fujii N, Kazama Y, Miyazawa S. Ruptured aneurysm of aortic sinus of Valsalva into the right ventricle. *Chest* 1979; **76**: 594-596.
- Cooperberg P, Mercer EN, Mulder DS, Winsberg F. Rupture of a sinus of Valsalva aneurysm: report of a case diagnosed preoperatively by echocardiography. *Radiology* 1974; **113**: 171-172.
- Matsumoto M, Matsuo H, Beppu S *et al.* Echocardiographic diagnosis of ruptured aneurysm of sinus of Valsalva: report of two cases. *Circulation* 1976; **53**: 382-389.
- Rothbaum DA, Dillon JC, Chang S, Feigenbaum H. Echocardiographic manifestation of right sinus of Valsalva aneurysm. *Circulation* 1974; **49**: 768-771.
- Weyman AE, Dillon JC, Feigenbaum H, Chang S. Premature pulmonic valve opening following sinus of Valsalva aneurysm rupture into the right atrium. *Circulation* 1975; **51**: 556-560.
- DeSáNeto A, Padnick MB, Desser KB, Steinhoff NG. Right sinus of Valsalva-right atrial fistula secondary to nonpenetrating chest trauma: a case report with description of noninvasive diagnostic features. *Circulation* 1979; **60**: 205-209.
- Alam M, Folger GM, Goldstein S. Tricuspid valve fluttering: echocardiographic features of ventricular septal defect. *Chest* 1980; **77**: 517-520.
- Snider AR, Silverman NH, Schiller NB, Ports TA. Echocardiographic evaluation of ventricular septal aneurysm. *Circulation* 1979; **59**: 920-926.
- Mills P, McLaurin L, Smith C, Murray G, Craige E. Echocardiographic findings in left ventricular to right atrial shunts. *Br Heart J* 1977; **39**: 594-597.
- Lichtz RA, Schiller NB, Tri TB, Bowen TE, Ports TA, Silverman NH. Two-dimensional echocardiographic diagnosis of a ruptured right sinus of Valsalva aneurysm. *Chest* 1981; **79**: 584-586.
- Magidson O, Kay JH. Ruptured aortic sinus aneurysm: clinical and surgical aspects of seven cases. *Am Heart J* 1963; **65**: 597-606.
- Lillehei CW, Stanley P, Varco RL. Surgical treatment of ruptured aneurysm of the sinus of Valsalva. *Ann Surg* 1957; **146**: 459-472.
- Szweda JA, Drake EH. Ruptured congenital aneurysm of the sinuses of Valsalva: a report of two cases treated surgically. *Circulation* 1962; **25**: 559-567.
- Sanchez HE, Barnard CN, Barnard MS. Fistula of the sinus of Valsalva. *J Thorac Cardiovasc Surg* 1977; **73**: 877-879.