

lokale nekrotiserende enterokolitis is, omdat die perforasie gewoonlik by die apeks voorkom. Ongelukkig is daar geen vroeë kliniese tekens wat op die toestand kan dui nie. Verskeie outeurs meld die aanwesigheid van umbilikale sepsis en edeem van die buikwand teenoor die regter-fossa iliaca. Hierdie tekens was ook by ons pasiëntjie teenwoordig.

Die diagnose van appendisitis moet dus oorweeg word indien 'n pasiëntjie tekens van septisemie met gepaardgaande umbilikale sepsis toon. Indien 'n buikoorsigfoto boonop abnormaal is, is 'n laparotomie aangedui.

Ons dank aan die Superintendent, dr. J. Stewart, vir verlof tot publikasie.

#### VERWYSINGS

1. Bax NMA, Pearce RG, Dommering N, Molenaar JC. Perforation of the appendix in the neonatal period. *J Pediatr Surg* 1980; **15**: 200-202.
2. Trojanowski JQ, Gang DC, Goldblatt A, Akins CW. Fatal postoperative acute appendicitis in a neonate with congenital heart disease. *J Pediatr Surg* 1981; **16**: 85-86.
3. Shaul WL. Clues to the early diagnosis of neonatal appendicitis. *J Pediatr* 1981; **98**: 473-476.
4. Kwong M, Dinner M. Neonatal appendicitis masquerading as necrotizing enterocolitis. *J Pediatr* 1980; **96**: 917-918.

# Pseudosolid appearance of simple and echinococcal cysts on ultrasonography

## A report of 2 cases

A. SCHULMAN, J. VAN JAARSVELD, A. J. LOXTON, W. H. GROVÉ

### Summary

The 2 cases reported here indicate that on ultrasound examination uninfected simple and echinococcal cysts can sometimes show a pseudosolid internal consistency like that of a neoplasm, probably owing to floating crystals or particles. This has important implications as far as further diagnostic and therapeutic measures are concerned. The presence of a regular and well-defined rim remains an important clue to the possibly cystic nature of such lesions.

*S Afr Med J* 1983; **63**: 905-906.

It is accepted that one of the necessary ultrasonographic signs for the diagnosis of a cyst as opposed to a neoplasm is a generally anechoic internal consistency. The following 2 cases are a reminder that this sign may be absent.

### Case reports

#### Case 1

A 29-year-old woman with pain of recent onset in the left

Department of Radiology, Tygerberg Hospital and University of Stellenbosch, Parowvallei, CP

A. SCHULMAN, F.R.C.R., M.R.C.P.

J. VAN JAARSVELD, M.B. CH.B.

A. J. LOXTON, M.B. CH.B., M.MED. (RAD.D.)

W. H. GROVÉ, M.D.R. (D. & T.)

upper quadrant was found to have an enlarged or displaced spleen. Ultrasonography showed a 12 cm spherical lesion below the left hemidiaphragm pushing the spleen downwards (Fig. 1). It was very well defined, with a thin hyperechoic rim, and its internal consistency appeared solid and of similar echogenicity to spleen. Just below it were two smaller, purely cystic lesions. Splenic arteriography showed an entirely avascular lesion in the upper pole of the spleen with a compressed rim of splenic tissue around it. Pathological examination of the excised spleen revealed a simple cyst containing clear, straw-coloured fluid which was not analysed further.

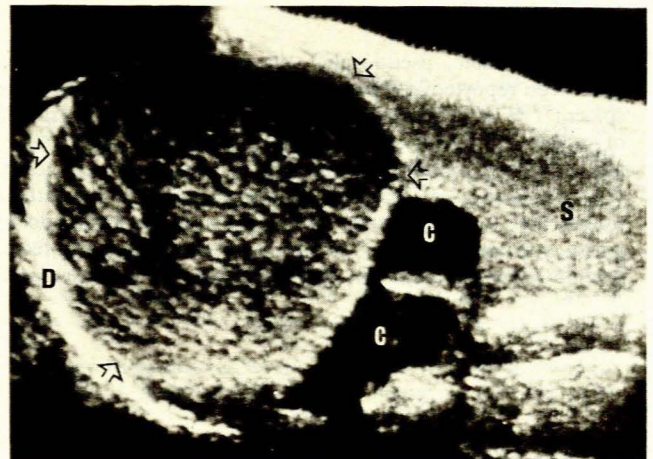


Fig. 1. Case 1. Longitudinal ultrasonogram through spleen (S) revealing a large pseudosolid simple cyst with well-defined rim (arrows) in its upper pole (Cs — two smaller cystic lesions; D — diaphragm).

## Case 2

A 52-year-old woman from a rural area had had right upper quadrant discomfort for some years, which had increased during the months prior to admission. She was afebrile, but her liver was enlarged and tender. Ultrasonography revealed a 16 cm lesion in the right lobe of the liver (Fig. 2). It was spherical, very well defined and with a hyperechoic rim; its internal consistency was mainly hyperechoic and fairly homogeneous, although it contained some purely cystic areas. The serum alkaline phosphatase level was twice the normal upper limit. A latex agglutination test for echinococcosis was negative but this was thought to be an unreliable result. Hepatic arteriography showed an entirely avascular lesion with a hypervascular rim. Laparotomy revealed a typical echinococcal cyst, which was confirmed on microscopy of the aspirated watery fluid, endocyst and daughter cysts.

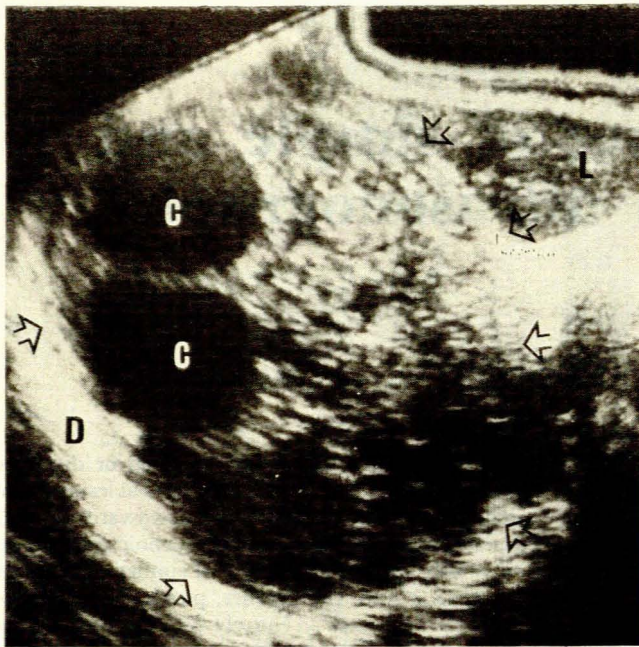


Fig. 2. Case 2. Longitudinal ultrasonogram through right lobe of liver (L) revealing a large pseudosolid echinococcal cyst with well-defined rim (arrows) and containing daughter cysts (Cs) (D — diaphragm).

## Discussion

Diffusely echoic, pseudosolid, ultrasonographic appearances have been reported in 5 previous cases of simple cyst, all in the spleen.<sup>1-3</sup> *In vitro* studies have shown that small concentrations of undissolved cholesterol crystals can produce this appearance,<sup>4</sup> and such crystals were present in 2 *in vivo* cases in which the cyst fluid was examined.<sup>1,2</sup> Concentrated or viscous solutions without undissolved floating crystals or protein macro-aggregates do not produce this appearance.<sup>5,6</sup> In our case 1 a simple, uninfected splenic cyst containing thin, clear fluid appeared homogeneously

solid and iso-echoic with spleen, although it had a visible hyperechoic capsule around it (Fig. 1).

Echinococcal cysts most commonly have the same ultrasonographic appearances as simple cysts; less commonly seen appearances include a calcified wall which casts an acoustic shadow, a dependent layer of 'hydatid sand', daughter cysts within the parent cyst, and a floating water-lily appearance due to germinal layer detachment.<sup>7</sup> Our previous experience of 23 echinococcal cysts included all these appearances, the last two of which are considered diagnostic. Scattered echoes within the cyst have been seen in a few cases but were attributed or proved to be due to pus produced by secondary bacterial infection;<sup>7-10</sup> in at least some of these infected cases irregularity and poor definition of the normally sharply defined and regular cyst wall were found.<sup>7</sup> In our case of uninfected echinococcal cyst the wall was well defined and regular, and the internal echoes were uniformly scattered between the daughter cysts to produce an appearance like that of a neoplasm (Fig. 2). A similar though less extensive appearance has been mentioned in 2 cases of renal echinococcal cysts.<sup>11</sup> The probable explanation is that the usually dependent 'hydatid sand', consisting of scolices and brood capsules, had been shaken up in an ambulant patient and was floating freely in the fluid. There is no reason why this pseudosolid appearance should not be found in echinococcal cysts not containing daughter cysts; such a case will resemble a solid neoplasm even more closely.

As the management of solid neoplasms differs radically from that of cysts, it is important to recognize that apparently solid lesions which have regular, smooth and well-defined walls, may be cystic; in addition, needle aspiration of an echinococcal cyst can produce fatal anaphylactic shock as well as seeding of lesions.

It is possible that repeat ultrasonography after the patient has remained recumbent for some time, allowing the crystals or particles to settle, would reveal more typical appearances. A relevant geographical history should raise suspicion of echinococcal infestation, and computed tomography in uncertain cases will confirm the low attenuation inside simple and echinococcal cysts.<sup>12</sup>

## REFERENCES

1. Thurber LA, Cooperberg PL, Clement JG, Lyons EA, Gramiak R, Cunningham J. Echogenic fluid: a pitfall in the ultrasonic diagnosis of cystic lesions. *JCU* 1979; 7: 273-278.
2. Glancy JJ. Fluid-filled echogenic epidermoid cyst of the spleen. *JCU* 1979; 7: 301-302.
3. Hare WSC, Blecher CM. Echogenic splenic cyst: a misdiagnosis. *Australas Radiol* 1980; 24: 293-297.
4. Glancy JJ, Goddard J, Pearson DE. *In vitro* demonstration of cholesterol crystals' high echogenicity relative to protein particles. *JCU* 1980; 8: 27-29.
5. Cunningham JJ, Wooten W, Cunningham MA. Gray scale echography of soluble protein and protein aggregate fluid collections (*in vitro* study). *JCU* 1976; 4: 417-419.
6. Filly RA, Sommer FG, Minton MJ. Characterization of biological fluids by ultrasound and computed tomography. *Radiology* 1980; 134: 167-171.
7. Niron EA, Özer H. Ultrasound appearances of hydatid disease. *Br J Radiol* 1981; 54: 335-338.
8. Hadidi A. Ultrasound findings in liver hydatid cysts. *JCU* 1979; 7: 365-368.
9. Itzhak Y, Rubinstein Z, Heyman Z, Gerzof S. Role of ultrasound in the diagnosis of abdominal hydatid disease. *JCU* 1980; 8: 341-345.
10. Gharbi HA, Hassine W, Brauner MW, Dupuch K. Ultrasound examination of the hydatid liver. *Radiology* 1981; 139: 459-463.
11. Gilsanz V, Lozano F, Jimenez J. Renal hydatid cysts: communicating with collecting system. *AJR* 1980; 135: 357-361.
12. Ismail MA, Al-Dabagh MA, Al-Janabi TA *et al.* The use of computerized axial tomography in the diagnosis of hydatid cysts. *Clin Radiol* 1980; 31: 287-290.