

Ultrasonic demonstration of fetal skeletal dysplasia

Case reports

LINNIE M. MULLER, B. J. CREMIN

Summary

Reports on prenatal diagnosis in cases of skeletal dysplasia have mostly been in high-risk mothers with a suspect genetic background where the fetal lesion could probably be predetermined. We deal with routine ultrasonographic appraisal of the fetal skeleton when dysplasia is not initially suspected, and relate our experience of the lethal forms of this condition. During the 4-year period 1981 - 1984, 6 cases of skeletal dysplasia, including thanatophoric dysplasia, achondrogenesis, the Ellis-van Creveld syndrome (chondro-ectodermal dysplasia) and osteogenesis imperfecta, were detected; the ultrasonographic findings are discussed.

S Afr Med J 1985; **67**: 222-226.

The ultrasonic demonstration of fetal abnormalities is well known, but only recently has there been extensive documentation of prenatal diagnosis of skeletal dysplasias. Most of these reports have been of high-risk mothers with a suspect genetic background, so that the likely lesion was predetermined.^{1,2} This report is concerned with the more difficult task of routine appraisal of the skeleton when dysplasia is not initially suspected, and relates our experience of the lethal varieties.

Features of the lethal bone dysplasias include limb shortening and, in some cases, a decreased thoracic/abdominal circumference ratio. In the second trimester careful ultrasonographic technique can show both limb shortening and decreased echo brightness of bones.^{3,4} Other features of the fetal skeleton, such as limb-bowing, fractures and supernumerary digits, must be correlated. The size of the thorax and abdomen must be noted and the presence of hydrops or hydramnios excluded.

Radiological diagnosis is usually effective only in the third trimester, and for obvious reasons has been superseded by ultrasonography. However, it does still have a place in confirming the ultrasonic diagnosis in later pregnancy.

Patients and methods

The examinations were carried out by both static and dynamic ultrasound equipment. These included Siemens, Aloka and

Department of Obstetrics and Gynaecology, Tygerberg Hospital, Parowvallei, CP

LINNIE M. MULLER, M.B. CH.B., *Head of Ultrasound Department*
 Department of Paediatric Radiology, Red Cross War Memorial Children's Hospital and University of Cape Town
 B. J. CREMIN, D.R.C.O.G., F.R.C.R., F.R.A.C.R., *Professor and Head*

Reprint requests to: Dr L. M. Muller, Ultrasound, Dept of Obstetrics and Gynaecology, Tygerberg Hospital, Tygerberg, 7505 RSA.

Toshiba linear array scanners (with 3,5 MHz transducers) and a Philips SDU 7000 Sector/Static scanner. A routine obstetric scan does not involve complete examination of all limbs, but when a bony abnormality is noted a skeletal survey is attempted. Real-time ultrasound offers a flexible technique, and when the infant is in the prone vertex position the linear array has the advantage of a wider range of skeletal visualization.

A complete skeletal survey consists of an evaluation of the bones of the skull, spine, thorax and limbs and of correlating these other fetal structures. We first measured the biparietal diameter (BPD) and then noted the echogenic characteristics of the skull and facial contours. A comprehensive evaluation of the spine is possible from 17 weeks' gestation onwards. In a longitudinal plane the posterior elements form segmented bands of echoes that conform to the fetal kyphosis, but it is not always possible to visualize the whole spine. In the transverse plane the identification of a separate body and two posterior elements is possible. Both planes must be correlated because some confusion may exist through twisting of the fetal trunk. The shape of the thorax is noted and the thoracic and abdominal diameters are measured. Any obvious abnormality is noted. To assess bone brightness the time-compensation gain is varied and this procedure is performed on the skull, ribs and limbs. The most accessible limb bones to examine are usually the femora since these are flexed at roughly 70° to the spine. Having identified the long axis of the fetus by noting the spinal plane and the pulsations of the abdominal aorta, the transducer is swept at a right-angle across the iliac bones until the long axis of a femur is identified. Using the calipers, multiple measurements are taken and the longest consistent assessment accepted as limb length. The humeri may easily be examined when they are freely floating in the amniotic fluid, but access is frequently difficult if the upper limbs are flexed behind the head. Identification of individual metatarsals and metacarpals is possible after the 4th month and, even though the hand is often clenched, polydactyly should be looked for in all cases of limb shortening.

The following is a brief account of the abnormalities noted during the 4-year period 1981 - 1984 at Tygerberg Hospital, Parowvallei, CP. The conditions are not grouped together according to order of appearance but under specific headings. In each section a brief description is given, with further amplification in the discussion.

Thanatophoric dwarfism

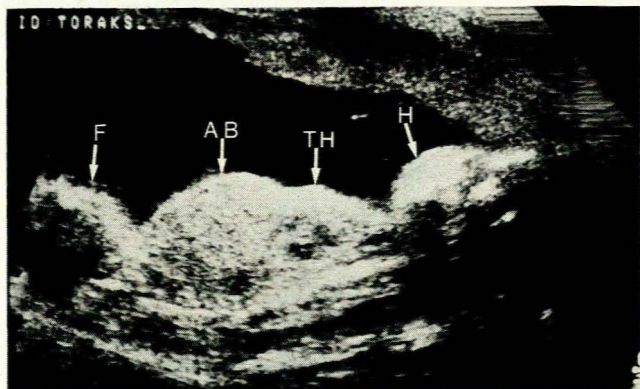
This is the commonest form of lethal neonatal dwarfism. It is characterized by marked limb shortening, a normal trunk and a comparatively large head. It may be associated with a clover-leaf skull deformity. Most infants are stillborn but some may survive for a few hours before dying from respiratory failure.

Case 1

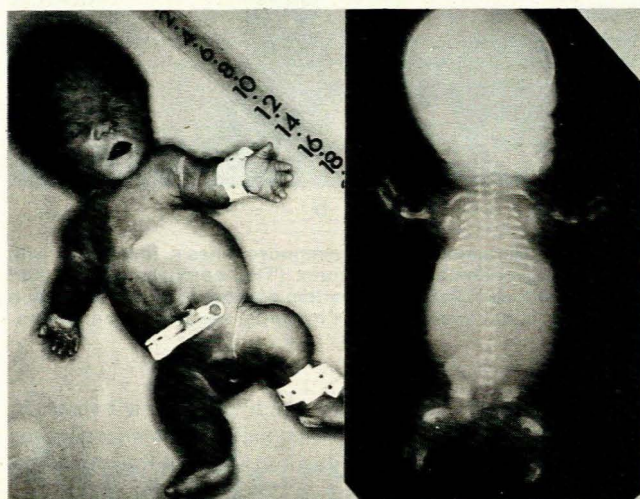
A 40-year-old woman, gravida 12, para 11, first attended the antenatal clinic at 34 weeks' gestation and was immediately

hospitalized for pre-eclampsia. She was referred for an ultrasound-guided amniocentesis for estimation of fetal lung maturity.

Ultrasonic examination showed a single fetus in cephalic lie. The fetal head had an irregular shape with a pronounced forehead and a BPD of 90 mm. This was consistent with a mean gestational age of 36 weeks. The thorax was small and the abdomen bulged to give the whole trunk a pear-like shape. The fetal limbs measured 31 mm, which was consistent with a gestational age of 20 weeks. The marked limb shortening, pear-shaped body and large head with frontal bossing suggested a diagnosis of thanatophoric dysplasia, and a prone oblique radiograph confirmed this. Labour was induced and a stillborn male infant weighing 1509 g was delivered (Fig. 1).



a



b

c

Fig. 1. (a) Ultrasound demonstration of thanatophoric dysplasia (short curved femora (F), pear-shaped trunk formed by abdomen (AB) and thorax (TH), large head (H)). (b) Stillborn fetus with dwarfed limbs. (c) Postmortem radiograph confirmed thanatophoric dysplasia. Featured are the short curved limbs, the large head and small thorax and the flattened vertebral bodies.

Cases 2 and 3

A 25-year-old primigravida and a 23-year-old primigravida were both referred for ultrasonic evaluation of hydramnios at 32 weeks' gestation. The ultrasonographic features in both cases were similar to those in case 1 and included a large head with prominent forehead, pear-shaped trunk and normal ossification of the calvarium and spine. Measurements of long bones compared with the BPD yielded a difference in estimated gestational age of 10-16 weeks (Figs 2 and 3). A diagnosis of short-limbed dysplasia, probably thanatophoric dysplasia, was made and this was confirmed after both infants were stillborn.

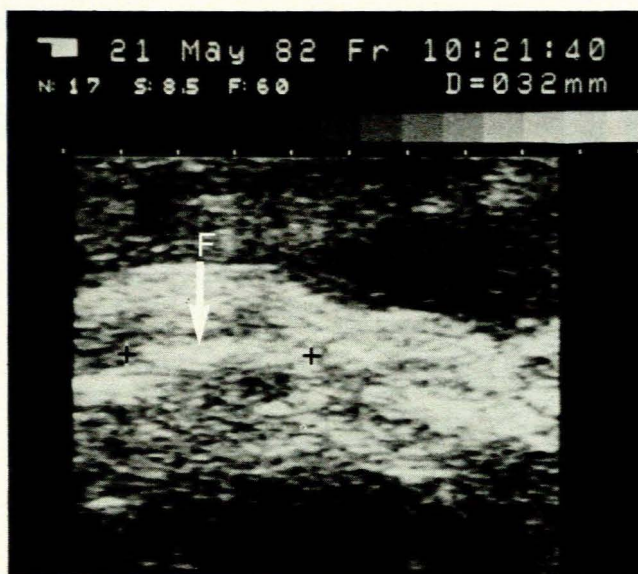


Fig. 2. Caliper measurement of short femur (F) measuring 32 mm.

Achondrogenesis

In this severe form of dysplasia the infants are stillborn. It is characterized by extreme micromelia, a relatively large head, a squat trunk and a prominent abdomen.

Case 4

A 23-year-old primigravida was referred for ultrasonographic determination of gestational age. The examination showed a single fetus with unstable lie due to polyhydramnios. The BPD was 66 mm, consistent with a gestational age of 27 weeks. The fetus was severely hydropic with pronounced skull oedema. The spine could be demonstrated only in the cervical and thoracic regions. The absent lumbosacral vertebrae and iliac bones gave the body a squat appearance (Fig. 4a). The fetal limbs appeared as extremely short, rudimentary appendages against the trunk and no long-bone measurements were possible. A 3 cm echodense mass at umbilical level was thought to be an omphalocele (Fig. 4a).

The ultrasonographic diagnosis of severe micromelic dwarfism with hydrops fetalis and absent lower spine and pelvis was made. The most likely condition was considered to be achondrogenesis. Labour was induced and a dead female infant weighing 1099 g was delivered. An omphalocele was present. The postmortem radiograph confirmed the absent caudal spine, the severe micromelia and achondrogenesis type I (Fig. 4b).

Chondro-ectodermal dysplasia

This condition (the Ellis-van Creveld syndrome) is characterized by limb-shortening, narrowing of the thorax, post-axial polydactyly and cardiac and ectodermal abnormalities. The last-mentioned include abnormalities of the hair, teeth and nails.

Case 5

A 19-year-old primigravida was referred for ultrasound examination at 28 weeks' gestation. This revealed a fetus with

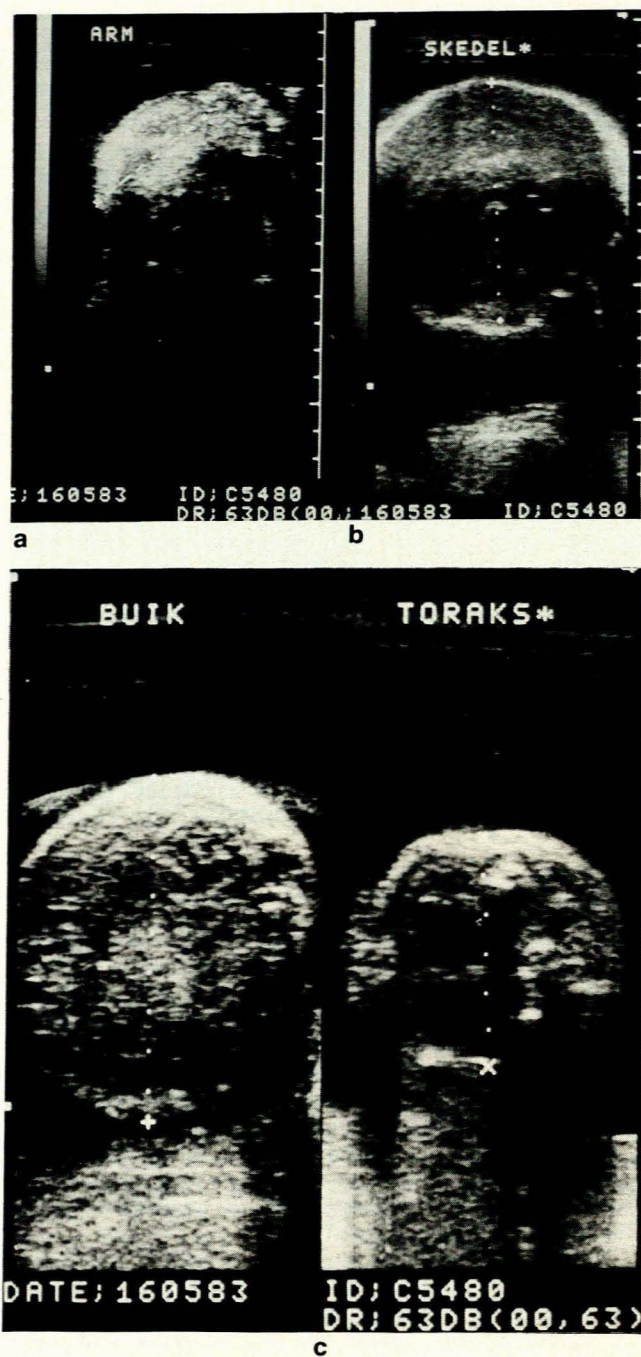


Fig. 3. (a) Short curved arm between caliper points. (b) The relatively large head. (c) Disproportion between abdomen and thorax.

a BPD of 79 mm, consistent with a gestational age of 32 weeks. The thorax was very small and remained extremely rigid during periods of breathing movements. The abdominal circumference was normal by comparison. Both femora appeared bowed and measured 42 mm, normal for a 24-week fetus (Fig. 5a). The other long bones were also short (equivalent to 23-24 weeks) but not bowed. The facial bones, calvarium and spine were normal. A second ultrasound examination revealed bilateral post-axial polydactyly of the hands, and the ultrasonographic diagnosis of dysplasia with bowed femora, polydactyly and constricting thorax was made (Fig. 5b). The pregnancy was terminated at 36 weeks because of the severity of the dysplasia, and a female infant weighing 2660 g died

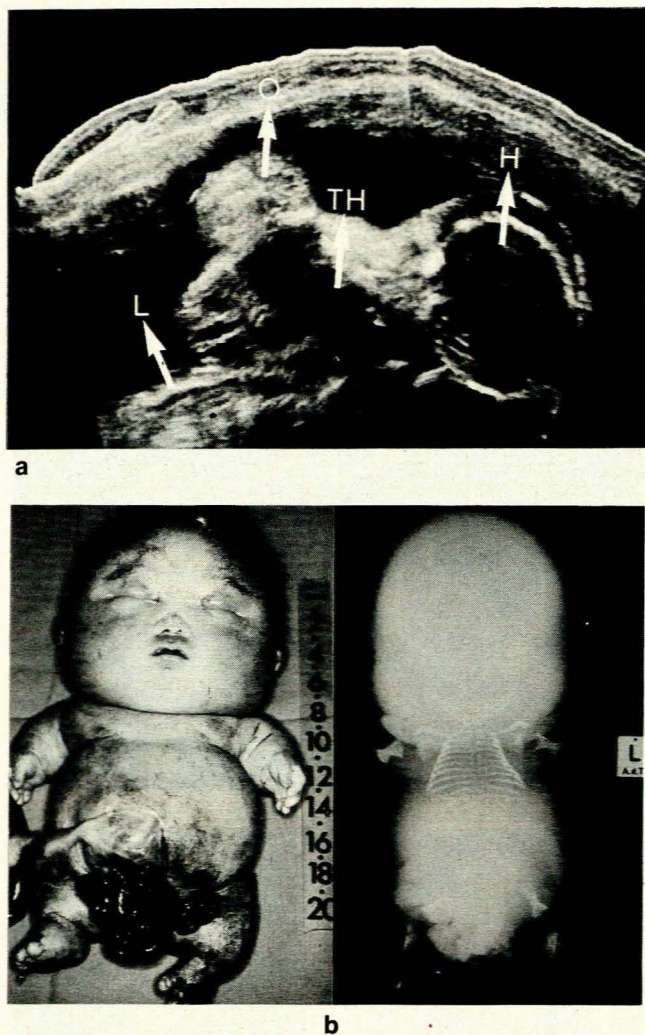


Fig. 4. (a) Ultrasonogram of achondrogenesis (head (H) with surrounding oedema, short thorax (TH), omphalocele (O) and short lower limb (L)). (b) Postmortem photograph and radiograph of stillborn infant showing gross hydrops, squat trunk and micro-melia.

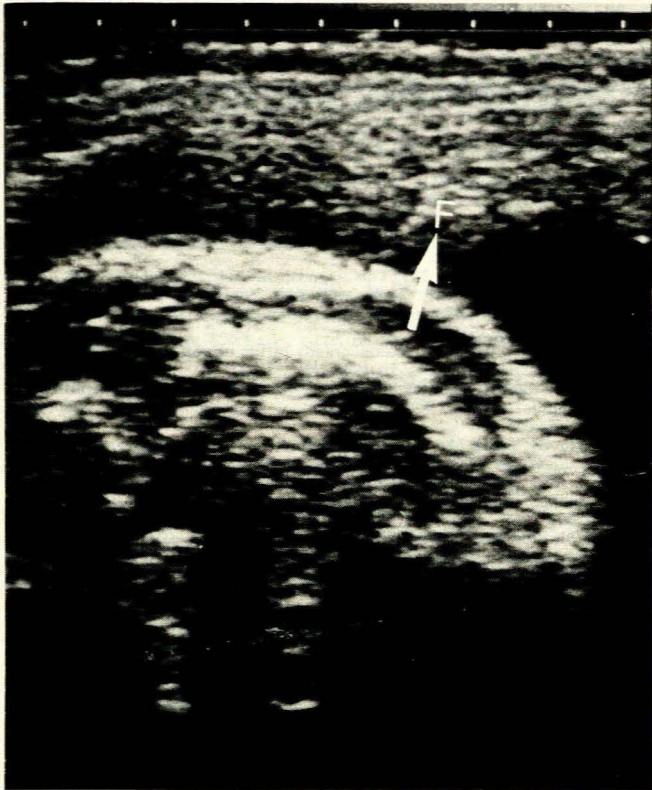
shortly after birth. Autopsy showed a hypoplastic left ventricle, coarctation of the aorta, hypoplastic nails and polydactyly, and the radiograph confirmed the diagnosis of chondro-ectodermal dysplasia.

Osteogenesis imperfecta

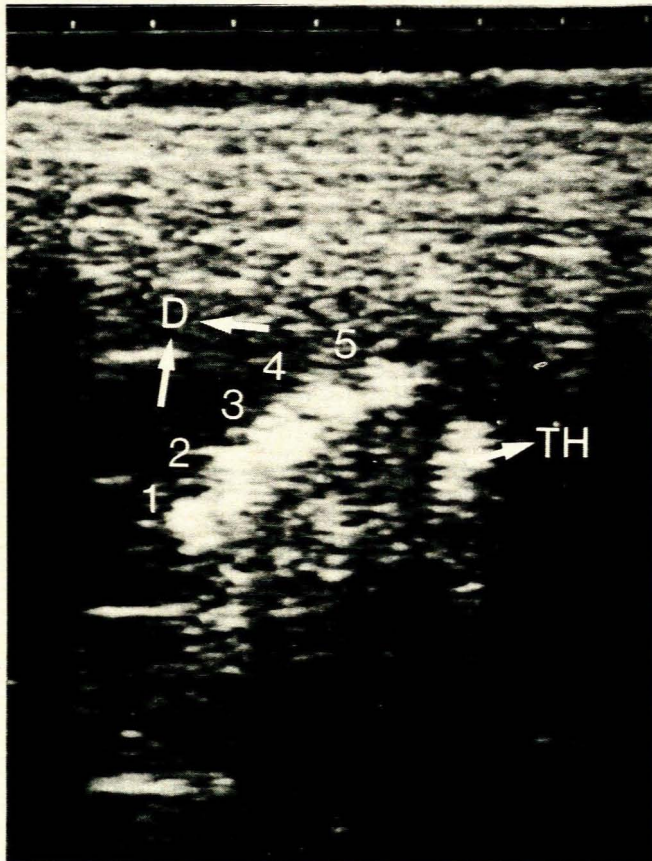
This is one of the more common types of bone dysplasia, and has its origins in a widespread collagen defect. Classification is complex, but the recessive congenital form or type II is frequently lethal and may be diagnosed by ultrasound.

Case 6

A 24-year-old primigravida with premature rupture of the membranes at 32 weeks' gestation was referred for amniocentesis. The ultrasonographic examination of the singleton breech fetus proved extremely difficult because of severe oligohydramnios. The BPD of 74 mm indicated a mean gestational age of 30 weeks. The calvarium appeared irregular, poorly ossified and indented (Fig. 6). The spine was normal, as were the intrathoracic organs. A single 3 cm cyst was demonstrated between the two normal kidneys and the bladder. The bony



a



b

Fig. 5. (a) Short bowed femur. (b) Polydactyly with 5 digits (D) and thumb (TH).

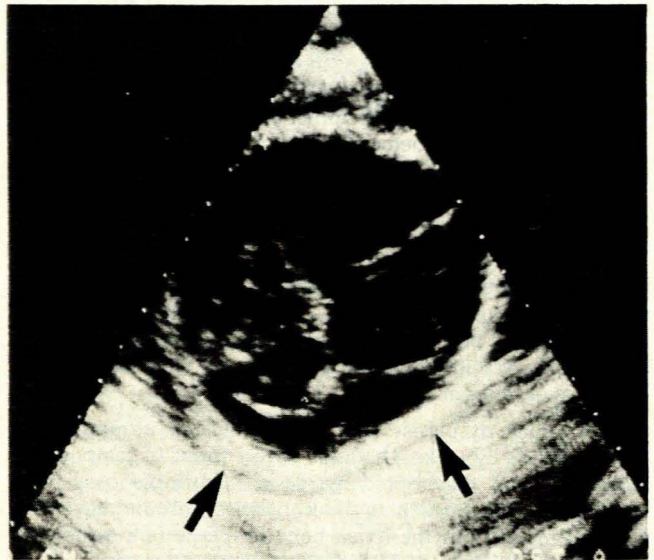


Fig. 6. Poorly ossified calvarium with irregular outline (arrows).

elements of the fetal limbs, despite the use of the spine and trunk as landmarks, could not be demonstrated. The ultrasonographic diagnosis was that of a severe skeletal abnormality with affected calvarium. Hypophosphatasia and osteogenesis imperfecta were both considered, with the latter most likely on the grounds of probability. Labour was induced and a female infant of 1 180 g died 40 minutes after delivery. The diagnosis of the lethal form of osteogenesis imperfecta type II with a simple ovarian cyst was made on postmortem radiological and pathological examinations.

Discussion

The three conditions of thanatophoric dysplasia, achondrogenesis and the Ellis-van Creveld syndrome have micromelia (dwarfism) in common. However, the preferred term for these conditions is dysplasia rather than dwarfism. Knowledge of their presence will obviously affect the management of a pregnancy and influence early termination.

To assess micromelia the length of the limb bones may be compared with the growth of the BPDs^{4,5} or by individual measurements.³ When the bones are curved it is not always easy to assess their end-points; in all cases the image must be carefully assessed before the picture is frozen, and the longest length accepted only after three measurements within 2 mm of each other are obtained.²

One of the earliest ultrasonic descriptions of thanatophoric dysplasia noted the shortness of the fetal limbs.⁶ Its other features, such as a large head and small thorax compared to the abdomen, and redundant soft tissue, have made it the most commonly recognized dysplasia.^{3,7-10} A variation in which there is a lambdoid craniostenosis causing a clover-leaf skull has also been recognized on ultrasonography.¹⁰

Achondrogenesis is a condition with marked limb shortening, and on the basis of skeletal and histological findings it is divided into two types. Type I affects membranous and enchondral bone growth so that the skull as well as the limbs and the spine are incompletely ossified. Type II affects mainly endochondral growth and the limbs are only rudimentary spicules. The findings noted on ultrasonography^{11,12} have been the extreme (unmeasurable) limb shortening, poor skull visualization, short thorax and an association with hydrops and polyhydramnios.

In the Ellis-van Creveld syndrome constant and inconstant manifestations have been recognized. The constant signs include skeletal abnormalities and ectodermal dysplasia. The inconstant signs are multiple, the most common being congenital heart disease.¹³ There are other potentially lethal thoracic dysplasias, and these include the spectrum of the asphyxiating thoracic dystrophy and the short rib polydactyly syndromes.¹³ These may not be ultrasonically distinguishable, and a clinical, pathological, radiological and genetic assessment is required.¹⁴

Osteogenesis imperfecta is a condition that involves a defect in collagen synthesis. The manifestation of interest to obstetricians is the type II lethal recessive form. Ultrasonic reports^{15,16} have noted the poor ossification of the skull, so that compression (as in our case) produces an irregular outline. Fractures of limbs and ribs may also be noted.

Other bone dysplasias have been evaluated ultrasonically. These include hypophosphatasia,² severe forms of campomelic dysplasia¹⁰ and diastrophic dysplasia.¹⁷ Multiple congenital anomaly conditions such as the Roberts' syndrome³ have also been diagnosed, but the lethal bone dysplasias are associated with polyhydramnios,¹⁰ which makes limb assessment much easier.

When radiological confirmation is required, an exact technique that projects the fetus away from the maternal spine is necessary.¹⁴ However, ultrasonic diagnosis also requires an exact technique that correlates both the fetal bone and soft-tissue configuration.

The conditions described are among the commonest lethal bone dysplasias in southern Africa. This view is supported by an independent 4-year radiological survey of stillborn fetuses at Groote Schuur Hospital during 1977-1980, which showed them to be the dysplasias that were consistently identified.

The importance of identifying these conditions is that knowledge of their presence will radically alter the management of the pregnancy and allow subsequent genetic counselling.

We would like to thank both Dr Molly Nelson of the Department of Human Genetics, Groote Schuur Hospital, Cape Town, and the staff of the South African Medical Research Council for their help and assistance in the analysis of these skeletal dysplasias.

REFERENCES

- Hobbins JC, Bracken MB, Mahoney MJ. Diagnosis of fetal skeletal dysplasias with ultrasound. *Am J Obstet Gynecol* 1982; **142**: 306-312.
- Kurtz AB, Wapner RJ. Ultrasonographic diagnosis of second-trimester skeletal dysplasias: a prospective analysis in a high-risk population. *J Ultrasound Med* 1983; **2**: 99-105.
- Hobbins JC, Mahoney MJ. The diagnosis of skeletal dysplasias with ultrasound. In: Sanders RC, James AE, eds. *The Principles and Practice of Ultrasonography in Obstetrics and Gynecology*. 2nd ed. New York: Appleton-Century-Crofts, 1980.
- Filly RA, Golbus MS. Ultrasonography of the normal and pathologic fetal skeleton. *Radiol Clin North Am* 1982; **20**: 311-323.
- Filly RA, Golbus MS, Carey JC, Hall JG. Short-limbed dwarfism: ultrasonographic diagnosis by mensuration of fetal femoral length. *Radiology* 1981; **138**: 653-656.
- Cremin BJ, Shaff MI. Ultrasonic diagnosis of thanatophoric dwarfism *in utero*. *Radiology* 1977; **124**: 479-480.
- Shaff MI, Fleischer AC, Battino R, Herbert C, Boehm FH. Antenatal sonographic diagnosis of thanatophoric dysplasia. *J Clin Ultrasound* 1980; **8**: 363-365.
- Fink IJ, Filly RA, Callen PW, Fiske CC. Sonographic diagnosis of thanatophoric dwarfism *in utero*. *J Ultrasound Med* 1982; **1**: 337-339.
- Wong WS, Filly RA. Polyhydramnios associated with fetal limb abnormalities. *AJR* 1983; **140**: 1001-1003.
- Chervenak FA, Blakemore KJ, Isaacson G, Mayden K, Hobbins JC. Antenatal sonographic findings of thanatophoric dysplasia with cloverleaf skull. *Am J Obstet Gynecol* 1983; **146**: 984-985.
- Smith WL, Breitweiser TD, Dinno N. *In utero* diagnosis of achondrogenesis Type I. *Clin Genet* 1981; **19**: 51-54.
- Graham D, Tracey J, Winn K, Corson V, Sanders RC. Early second trimester sonographic diagnosis of achondrogenesis. *J Clin Ultrasound* 1983; **11**: 336-338.
- Cremin BJ, Beighton P. *Bone Dysplasias of Infancy: A Radiological Atlas*. New York: Springer-Verlag, 1978.
- Kozlowski K, Szmigiel C, Barylak A, Stopyprowa M. Difficulties in differentiation between chondroectodermal dysplasia (Ellis-van Creveld syndrome) and asphyxiating thoracic dystrophy. *Australas Radiol* 1972; **16**: 401-410.
- Chervenak FA, Romero R, Berkowitz RL et al. Antenatal sonographic findings of osteogenesis imperfecta. *Am J Obstet Gynecol* 1982; **143**: 228-230.
- Woo JSK, Ghosh A, Lian ST, Wong VCW. Ultrasonic evaluation of osteogenesis imperfecta congenita *in utero*. *J Clin Ultrasound* 1983; **11**: 42-44.
- Mantagos S, Weiss RR, Mahoney M, Hobbins JC. Prenatal diagnosis of diastrophic dwarfism. *Am J Obstet Gynecol* 1981; **139**: 111-113.