

# Progressive familial heart block

## Part II. Clinical and ECG confirmation of progression — report on 4 cases

P.-L. VAN DER MERWE, H. W. WEYMAR, MARIE TORRINGTON, A. J. BRINK

### Summary

Two types of progressive familial heart block controlled by a single gene have been described; 4 cases show that type I is progressive and that the pathogenesis is still unknown.

*S Afr Med J* 1986, 70: 356-357.

In 1977 Brink and Torrington<sup>1</sup> reported the existence of two types of progressive familial heart block (PFHB) in white South Africans (type I — right bundle-branch block (RBBB), left anterior hemiblock (LAHB), complete heart block (CHB), and a broad QRS complex; type II — sinus bradycardia (SB), left posterior hemiblock (LPHB), complete heart block (CHB), a narrow QRS complex). Both types are inherited as a single autosomal dominant gene. It was emphasized that these conditions were likely to be widely prevalent in the RSA.

Four patients with PFHB are presented. From 3 different families, these patients are genetically linked to one initial immigrant (Part I, Fig. 1, p. 353), with type I PFHB.<sup>1</sup>

### Case reports

#### Case 1

A white girl aged 2 years 8 months (born 21 February 1978) was admitted to Tygerberg Hospital with the history of a cyanotic attack during which her mother could not palpate her pulse. She recovered spontaneously.

On examination the pulse rate was 62/min in spite of a temperature of 39,6°C. The blood pressure was 80/60 mmHg. The patient had enlarged, acutely inflamed tonsils. All other systems were normal. The ECG showed a second degree heart block of the Wenckebach Type (Fig. 1-1a). A repeat ECG 3 months later showed a Mobitz type II second degree heart block (Fig. 1-1b). In the light of her family history (Part I, Fig. 1, family W) a permanent pacemaker was implanted prophylactically. She is now completely pacemaker-dependent.

#### Case 2

A 13-month-old white girl (born 13 September 1978) was admitted to Tygerberg Hospital. While playing, she had suddenly begun crying and became very pale. She had no convulsions or

loss of consciousness during this episode. Two of her cousins were known to have PFHB. The patient's heart block was diagnosed at birth.

On examination the pulse rate was 46/min, the blood pressure 100/60 mmHg and temperature 36,8°C. The patient's right eardrum was congested and red. All other systems were normal. An ECG showed a Mobitz type II heart block (Fig. 1-2a). A final diagnosis of PFHB and otitis media was made. She developed a Stokes-Adams attack in the ward and a temporary pacemaker was inserted. The same day several ECGs were taken, which showed varying blocks (Fig. 1-2b), and a permanent pacemaker was implanted.

#### Case 3

A 10-year-old white boy was referred to Tygerberg Hospital with a diagnosis of PFHB. On examination the pulse rate was

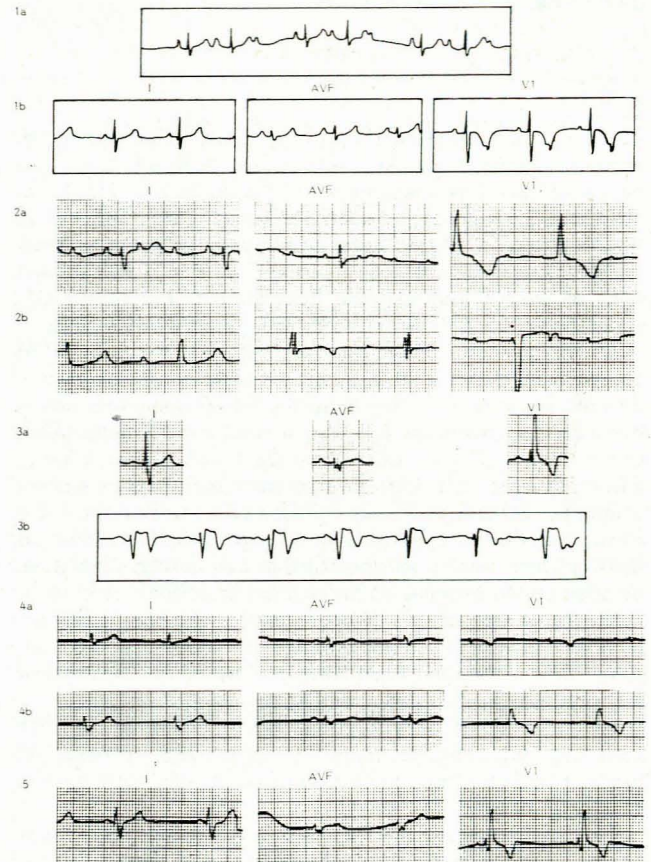


Fig. 1. (1a) Wenckebach second degree heart block. (1b) Sinus bradycardia, narrow QRS complex, V1 shows Mobitz type II second degree heart block. (2a) 3:1 Mobitz type II second degree heart block, RBBB, LPHB. (2b) CHB with AV dissociation. (3a) Bifascicular block, RBBB with LAHB; broad complexes. (3b) Holter monitor strip showing Mobitz type II second degree heart block. (4a) ECG taken during 1981 — normal. (4b) ECG taken during 1984 — bifascicular block, RBBB with LPHB. (5) Sinus bradycardia, RBBB with LPHB.

Institute of Biostatistics of the South African Medical Research Council and Cardiac Unit, Departments of Internal Medicine and Paediatrics, Tygerberg Hospital and University of Stellenbosch, Parowvallei, CP

P.-L. VAN DER MERWE, M.B. CH.B., M.MED., F.C.P. (S.A.)

H. W. WEYMAR, R.C.T. (CARDIOLOGY)

MARIE TORRINGTON, D.PHIL.

A. J. BRINK, M.D., F.R.C.P., D.S.C.

TABLE I. ECG ANALYSES — TYPE I AND TYPE II

Case	Type I				Type II			
	RBBB	LAHB	CHB	Broad QRS	SB	LPHB	CHB	Narrow QRS
1					*			*
2	*			*	*	*		
3	*	*		*				
4	*			*	*	*		
Son/Case 4	*			*	*	*		

66/min; all other systems were within normal limits. An ECG showed an RBBB with an LAHB (Fig. 1-3a). An ambulatory Holter ECG recording showed a Mobitz type II second degree heart block (Fig. 1-3b). A permanent pacemaker was implanted prophylactically. Follow-up examination 2 months later showed that he was pacemaker-dependent.

#### Case 4

The 34-year-old mother of case 1, also an offspring of the type I family and who has already lost a sister due to a CHB, is followed up yearly. The ECGs taken during 1981, 1983 and 1984 showed progression from an incomplete RBBB to a bifascicular heart block (Fig. 1-4a and b). Her son's ECG shows the presence of a sinus bradycardia, an RBBB and an LPHB (Fig. 1-5; Table I).

#### Discussion

Brink and Torrington<sup>1</sup> identified two types of PFHB, the considered progressive nature of which was based on the family history of sudden deaths only.

Each of the 4 patients described here developed symptoms of or showed definite progression to a more severe form of heart block. Patient 1 progressed from a Wenckebach second degree heart block (Fig. 1-1a) to a more severe form of second degree heart block (Fig. 1-1b; Mobitz type II) and also had a syncopal attack. Patient 2 progressed from a Mobitz type II second degree heart block (Fig. 1-2a) to CHB (Fig. 1-2b) with an associated Stokes-Adams attack. Patient 3 progressed from a bifascicular heart block (RBBB, LAHB; Fig. 1-3a) to a Mobitz type II second degree heart block (Fig. 1-3b). Patient 4 progressed, over a 3-year period, from an ECG showing an incomplete RBBB (Fig. 1-4a) to a bifascicular heart block (RBBB, LPHB).

Table I shows that only case 1 fits the features of the type II PFHB (narrow QRS complex) described by Brink and Torrington,<sup>1</sup> while cases 1, 2 and 4 have ECG findings fitting type I PFHB (broad QRS complex).

It has been stated (A.J.B.) that the type II PFHB was thought to be due to an autosomal inherited cardiomyopathy suggested by gross pathology and clinical course. In the light of the related family history and the difference in the clinical courses of the two types<sup>1</sup> it must be postulated that all the cases discussed belong to type I PFHB, but represent different manifestations of the disease process.

The pathogenesis of these conditions has still not been clarified. The degenerative hypothesis<sup>2,3</sup> is still the most acceptable, but the mechanism triggering the degenerative process is unknown. Brink and Torrington<sup>1</sup> favour the theory that a vascular lesion precedes the degenerative changes. Looking at cases 1 - 4, the vascular theory would not fit easily because the ECGs of these patients do not imply a selective involvement of the nutrient arteries to the conduction fascicles.<sup>1,4</sup>

Congenital heart block occurs in infants of mothers suffering from systemic lupus erythematosus (SLE) and other connective tissue diseases.<sup>5</sup> Lanham *et al.*<sup>5</sup> postulate that the increased susceptibility of fetal compared with adult conduction tissue may be explained by expression of antigens in fetal tissue that are lost during ontogeny. The familial nature of PFHB makes this unlikely.

#### Conclusion

The cases described provide evidence for the progressive nature of PFHB but at this stage it is not known whether all patients with the disease will progress or what the rate of such progression might be. The case reports also indicate that patients with type I PFHB may present with ECGs featuring narrow complexes before developing bundle-branch conduction abnormalities, as in case 1. These different ECG manifestations probably depend on varying sites of conduction tissue involvement.

While the pathogenesis and exact course of events is unclear, all members of affected families should be traced and regularly followed up for timely intervention. We are in the process of establishing clearer criteria for pacemaker insertion in PFHB.

#### REFERENCES

1. Brink AJ, Torrington M. Progressive familial heart block — two types. *S Afr Med J* 1977; **52**: 53-59.
2. Lev M, Cuadros H, Paul MH. Interruption of the atrioventricular bundle with congenital atrioventricular block. *Circulation* 1971; **43**: 703-710.
3. Lev M. Pathogenesis of congenital atrioventricular block. *Prog Cardiovasc Dis* 1972; **15**: 145-157.
4. Frink RJ, James TN. Normal blood supply to the human His bundle and proximal bundle branches. *Circulation* 1973; **47**: 8-18.
5. Lanham JG, Walport MJ, Hughes GRV. Congenital heart block and familial connective tissue disease. *J Rheumatol* 1983; **10**: 823-825.