

# Mitral valve prolapse complicated by acute cerebral embolism, arrhythmias and painless myocardial infarction

## A case presentation and overview

J. Z. PRZYBOJEWSKI, J. G. TREDoux, J. J. VAN DER WALT, F. A. C. TIEDT

### Summary

A case of 'primary' mitral valve prolapse is documented. The patient was admitted with right-sided hemiplegia of sudden onset, probably caused by a cerebral embolus from the mitral valve. He also had a painless transmural inferior myocardial infarction (MI) of indeterminate age which was diagnosed electrocardiographically and on left ventricular cine angiography. Since selective coronary arteriography delineated the absence of fixed obstructive atherosclerotic disease, and since coronary vasospasm could not be provoked with the ergonovine (ergometrine) maleate test, it is further postulated that a coronary embolus from the abnormal mitral valve apparatus was responsible for the painless MI. A percutaneous right ventricular endomyocardial biopsy specimen displayed findings not indicative of a 'cardiomyopathy'.

*S Afr Med J* 1984; 65: 390-396.

### Case presentation

The patient, a 34-year-old Coloured man, was perfectly well until 12 April 1982 when he suddenly collapsed while watching rugby. He did not lose consciousness but had a right-sided paralysis, difficulty with speech and an ensuing headache. There was no previous history of palpitations, presyncope, syncope or chest pain. His only complaint was of occasional frontal headaches. He smoked some 20 cigarettes daily and there was no family history of heart disease or sudden death. He was admitted to Tygerberg Hospital on 12 April. Clinical examination demonstrated marfanoid features in this young man, with a dense right-sided upper motor neuron paralysis accompanied by a right-sided upper motor neuron facial lesion. The cardiovascular system and the rest of the systems were normal. The urine, a full blood count, the erythrocyte sedimentation rate and serum biochemical values were all normal, as were radiographs of chest and skull. The cerebrospinal fluid was normal, with negative cultures and serological tests, as was an electro-encephalogram.

Cardiac Clinic, Department of Internal Medicine and Department of Anatomical Pathology, University of Stellenbosch and Tygerberg Hospital, Parowvallei, CP

J. Z. PRZYBOJEWSKI, M.B. CH.B., F.C.P. (S.A.)

J. G. TREDoux, M.B. CH.B.

J. J. VAN DER WALT, M.MED. (PATH.), M.D.

F. A. C. TIEDT, A.S.M.L.T.

On 14 April 1982 a resting ECG revealed a sinus rhythm of 80/min, numerous unifocal ventricular extrasystoles, a P-R interval of 0,16 second, a mean QRS axis of  $-76^\circ$ , left anterior hemiblock and nonspecific changes in the inferior leads. A repeat tracing on the following day demonstrated a mean QRS axis of  $-87^\circ$  (a superior axis), right atrial hypertrophy, possible right ventricular hypertrophy and a definite old transmural inferior myocardial infarction (MI) (Fig. 1). Because of the abnormal ECG the patient was referred to the Cardiac Clinic for an opinion. The abnormal features then present were a loud left ventricular fourth heart sound and an intermittent non-ejection mid-to-late systolic click, but there was no evidence of a mitral systolic murmur. A diagnosis of mitral valve prolapse (MVP) (Barlow's syndrome) was suggested. Furthermore, it was postulated that the patient had suffered a possible asymptomatic transmural inferior MI of unknown age secondary to a coronary embolus which probably originated from the myxomatous mitral valve apparatus. The acute cerebrovascular episode might have been due to an embolus from the same source. Daily serial serum enzyme values were within normal limits, while resting ECGs were unchanged from Fig. 1. A technetium-99m ('hot spot') scan failed to show evidence of acute MI. Further investigations, including collagen screening and serological testing, were all negative. A fasting lipogram was normal. Isotopic brain scans and flow studies on 15 and 28 April revealed a slightly increased uptake in the left parietal area and decreased flow to the left cerebral hemisphere, indicating a lesion in the middle cerebral artery distribution. Computed tomography of the brain (26 April) demonstrated an area of low density in the high left parietal region in keeping with a cerebral infarction (Fig. 2a). An M-mode echocardiogram failed to establish a diagnosis of MVP. Twenty-four-hour Holter monitoring revealed numerous unifocal ventricular extrasystoles, frequent periods of ventricular bigeminy and salvos, but no evidence of ventricular tachycardia or fibrillation.

Cardiac catheterization and selective coronary angiography on 3 May showed that all the intracardiac pressures and indices of cardiac contractility were normal. A left ventricular cine angiogram in the right anterior oblique projection delineated segmental inferior akinesia secondary to previous MI; the remainder of the ventricle was seen to contract normally (Fig. 3). Prolapse of the posterior leaflet of the mitral valve without accompanying mitral insufficiency was visualized. An aortic cine angiogram in the left anterior oblique projection delineated a normal aortic valve. Selective coronary angiography demonstrated that both the right coronary artery (RCA) (Fig. 4) and the left coronary artery (LCA) (Fig. 5) were normal. An ergonovine (ergometrine) maleate provocation test to exclude the possibility of underlying coronary vasospasm as a cause of the previous MI was carried out. A 12-lead ECG was set up and standard lead II and lead V2 were monitored on the oscilloscope, as was the aortic pressure. Ergonovine maleate was initially given as a bolus of 0,025 mg injected into the main pulmonary artery, and 12-lead ECGs were recorded every minute. Since there was no angina and no ECG



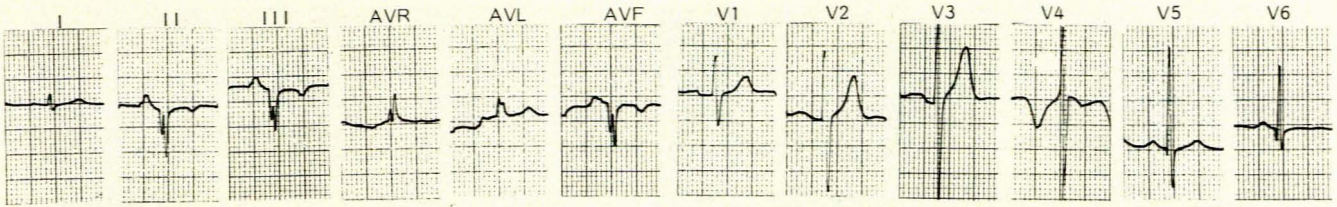


Fig. 1. Resting 12-lead ECG — mean QRS axis  $-87^{\circ}$ , possible right atrial and right ventricular hypertrophy, old transmural inferior MI (Q waves in leads II, III and aVF).

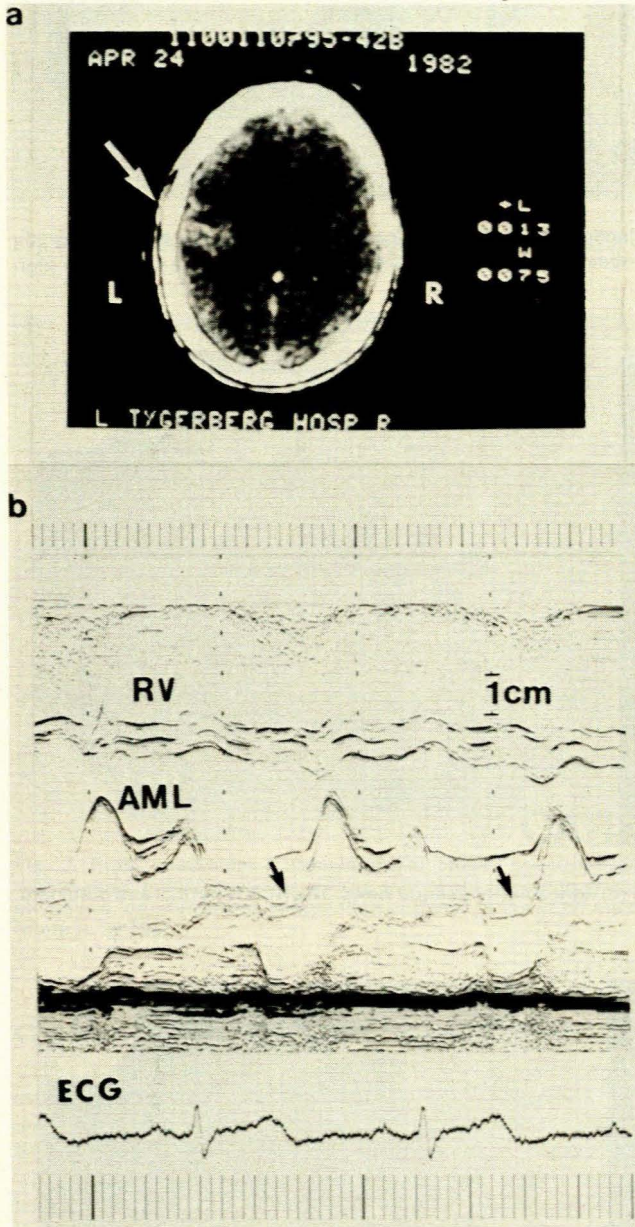


Fig. 2. a — computed tomogram of the brain; there is an area of low density (arrowed) in keeping with a high left parietal cerebral infarction. b — M-mode echocardiogram demonstrating prolapse of posterior mitral leaflet (arrowed) (RV = right ventricle; AML = anterior mitral leaflet).

features of myocardial ischaemia, a further bolus of 0,025 mg ergonovine was injected 4 minutes after the initial injection. The drug was then administered every 4 minutes at doses of 0,05 mg, 0,05 mg, 0,10 mg and 0,15 mg to a total dose of 0,40 mg. Again the ECG remained unchanged and the patient did not experience

any angina. Repeat cine angiograms of the LCA and RCA failed to document any coronary vasospasm. An Olympus FB-2 Biop-tome was employed to take multiple right ventricular endomyocardial biopsy specimens. Cardiac catheterization was then completed without complication.

The right ventricular endomyocardial biopsy material showed slight focal interstitial fibrosis on light microscopy. Endocardium was not visualized. Transmission electron microscopy confirmed the interstitial fibrosis (Fig. 6). The other ultrastructural findings were nonspecific. There was an unequivocal mitochondriosis, but only some mitochondria were questionably abnormal with cristolysis, vacuolation and loss of the outer membrane (Fig. 7). No dystrophic or degenerate myocytes could be detected. There was possibly some intracellular oedema which could have led to the formation of subsarcolemmal blebs (Fig. 8). Occasional myocytes contained tiny lipid droplets. A diagnosis of a 'cardiomyopathy' could not be established.

Repeat M-mode echocardiography demonstrated the presence of mid-to-late systolic prolapse of the posterior mitral leaflet (Fig. 2b), but there were no features of a cardiac myxoma. It was therefore decided not to perform two-dimensional echocardiography. Frequent auscultation of the heart elicited an intermittent mid-to-late non-ejection systolic click without accompanying mitral insufficiency. Repeat 24-hour Holter monitoring only documented the occasional unifocal ventricular extrasystole. The patient's right-sided hemiplegia improved very slightly. It was decided to administer long-term treatment with warfarin and dipyridamole in order to prevent future emboli. The patient was discharged on 11 May 1982. He was seen on numerous occasions at the Cardiac Clinic as an outpatient; repeated resting ECGs remained unchanged and several 24-hour Holter monitoring sessions failed to demonstrate any significant supraventricular or ventricular arrhythmias. The patient has remained asymptomatic, apart from his severe neurological deficit.

## Discussion

This case illustrates many important clinicopathophysiological points regarding MVP. The association of cerebral embolic phenomena with MVP has only really been fully appreciated recently, highlighting the controversy surrounding the role of prophylactic anticoagulant and antiplatelet drug therapy in this condition. Coronary emboli and cerebral emboli possibly originate from the redundant mitral valve apparatus. The inter-relationship between coronary emboli and painless MI is an interesting one. Cardiomyopathy is believed to be an accompaniment of MVP, particularly if the patient complains of chest pain. Bizarre ECG patterns have for many years been known to occur as part of the clinical spectrum of MVP, cerebrovascular incidents and cardiomyopathy of various types. Arrhythmias have been well established as a complication of MVP, cerebrovascular incidents and painless MI. An understanding of these important aetiological and pathophysiological aspects helps to give direction to the acute and long-term management of the individual patient.



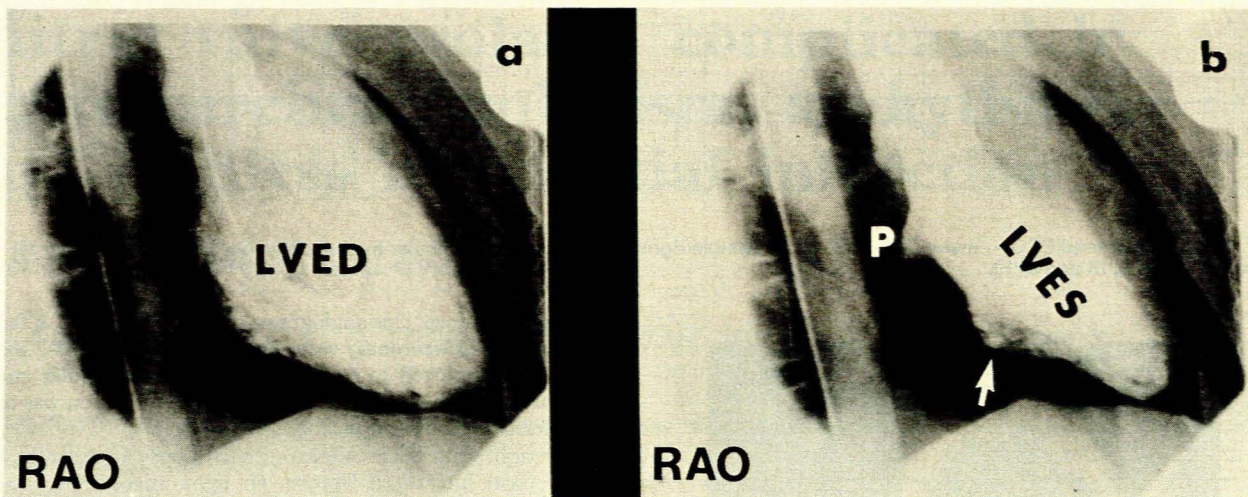


Fig. 3. Left ventricular cine angiograms in right anterior oblique projection delineating inferior akinesia secondary to MI (arrowed). Prolapse (P) of posterior mitral leaflet is seen (a — left ventricle in end-diastole; b — left ventricle in end-systole).

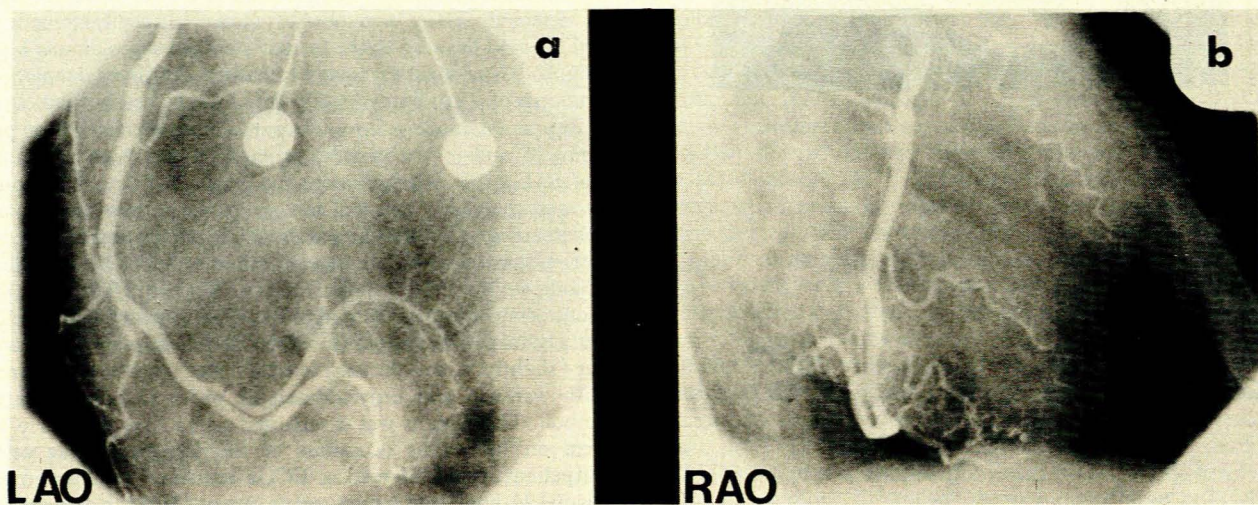


Fig. 4. Right coronary cine angiograms in the (a) left anterior oblique and (b) right anterior oblique views. The RCA is normal and dominant.

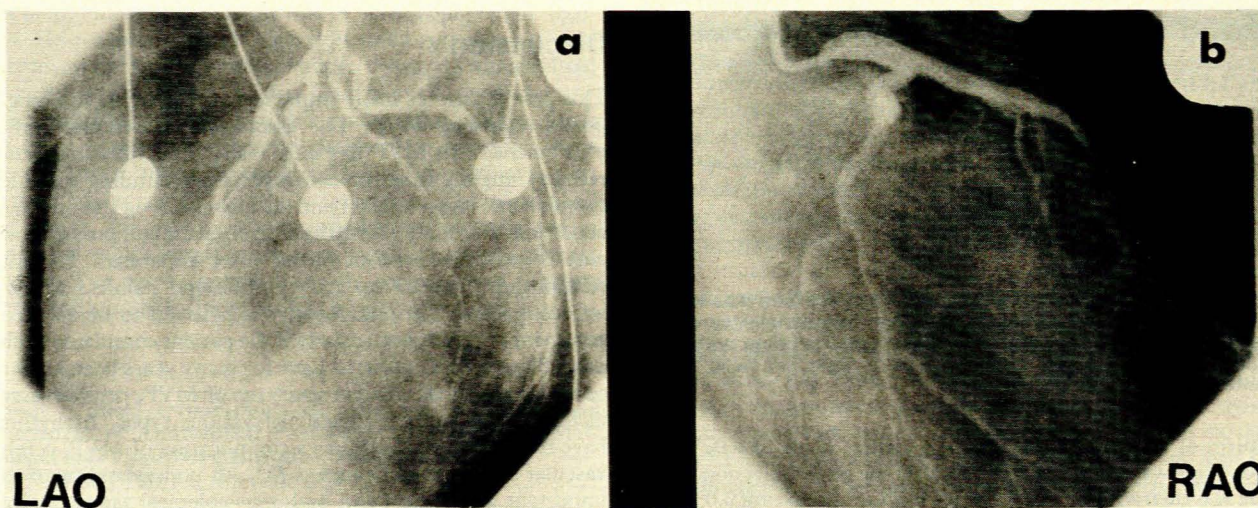


Fig. 5. Left coronary cine angiograms in the (a) left anterior oblique and (b) right anterior oblique views demonstrating normal vessels.



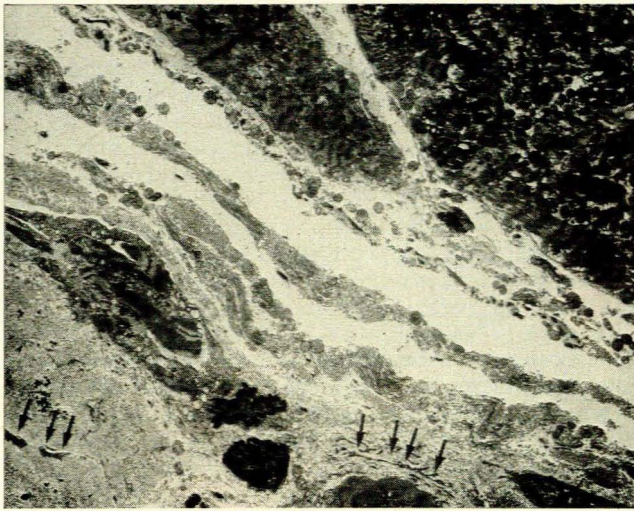


Fig. 6. Interstitial fibrosis. Arrows indicate remnants of myocyte in right ventricular endomyocardial biopsy material (x 5 660).

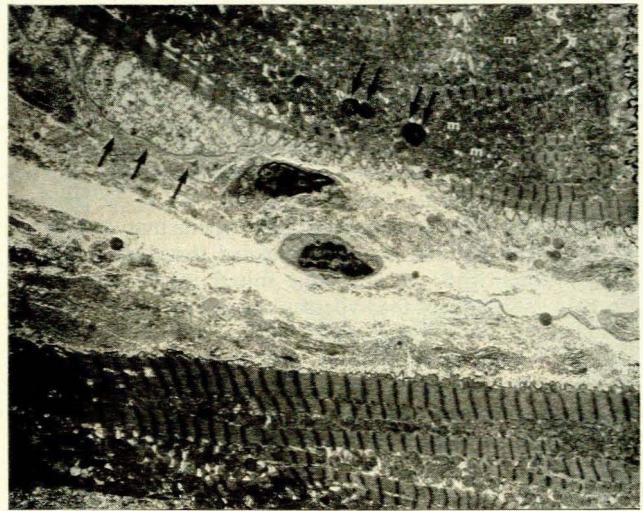


Fig. 8. Right ventricular endomyocardial biopsy specimen showing subsarcolemmal blebs (arrowed). Note mitochondriosis (m) and lipofuscin pigment (arrowed) (x 5 660).

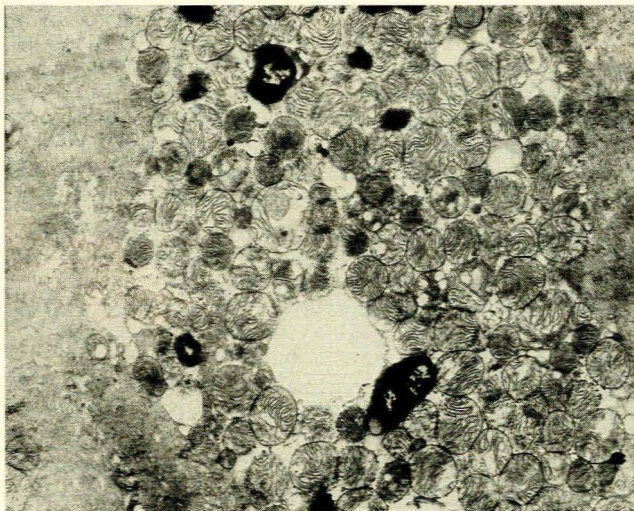


Fig. 7. Right ventricular endomyocardial biopsy specimen demonstrating mitochondriosis. Some mitochondria show partial cristolysis, condensation, vacuolation and loss of the outer membrane (x 20 700).

### Cerebral embolic complications of MVP

The first suggestion of a transient cerebral ischaemic event associated with MVP was reported by Barlow and Bosman,<sup>1</sup> who described the case of a woman with left-sided hemiparesis whose ECG revealed T-wave inversion in the inferolateral leads and who had documented 'aneurysmal protrusion of the posterior leaflet of the mitral valve' on left ventricular cine angiography. Subsequently Barnett<sup>2</sup> briefly alluded to the occurrence of neurological disturbances in this condition. It was not until 1976 that Barnett *et al.*<sup>3</sup> confidently proposed that there was a definite causal relationship between MVP and cerebral emboli; they based this on a series of 12 patients with angiographically proven MVP, 10 of whom had signs indicative of carotid artery ischaemia and the remaining 2 signs of vertebrobasilar involvement. Some had intermittent signs of bilateral cerebral hemisphere ischaemia. Nine had transient hemiparesis or major permanent stroke, other features being hemianopia, aphasia, dysarthria and vestibulocochlear signs. Three had proven paroxysmal atrial fibrillation which was possibly related to the

cerebral emboli. Barnett *et al.*<sup>3</sup> supported their proposal of a direct MVP-cerebral embolus link on the basis of the 'fibrinous endocarditis' noted by Pomerance<sup>4</sup> in autopsy cases of MVP and the documentation by Silver<sup>5</sup> of thrombus overlying the roughened endocardial surface of such a valve. Kostuk *et al.*<sup>6</sup> (one of the co-authors being Barnett) later added more cases. However, Pomerance and Davies<sup>7</sup> were doubtful whether, in the absence of underlying infective endocarditis, the thrombotic lesions noted by Kostuk *et al.*<sup>6</sup> at the junction of the abnormal mitral leaflet and left atrial wall could give rise to large enough emboli, but accepted that these emboli could be incriminated in transient neurological symptoms and retinal artery obstruction.

Malcolm and co-workers<sup>8</sup> reported on a series of 85 patients, 11 of whom suffered major neurological strokes. Hirsowitz and Saffer<sup>9</sup> documented 4 patients with MVP complicated by permanently disabling hemiplegia. These patients, aged 16 - 37 years, had no evidence of hypertension, coagulation abnormalities, vasculitis or cerebrovascular atherosclerosis. A further 8 patients were encountered by Hanson *et al.*,<sup>10</sup> some presenting with primarily neurological problems. Nevertheless, Saffro and Talano<sup>11</sup> made the statement that 'it is distinctly unusual for neurological abnormalities to be the initial complaint of a patient with MVP', but suggested that platelet-inhibiting drugs be used because of the 'imminent embolization'. Exceptionally staggering statistics were provided by Barnett and co-workers,<sup>12</sup> who documented 60 patients with definite prior transient ischaemic attacks; MVP was diagnosed in 24 of these. Surprisingly, there was a wide age range, arteriosclerosis making interpretation more difficult in the older age group. Nevertheless, Barnett *et al.*<sup>12</sup> claimed that 'a growing body of circumstantial evidence links cerebral and retinal ischemic events, particularly in the young, to mitral-valve prolapse'. This opinion was further supported by the report of Caltrider *et al.*<sup>13</sup> on 6 cases of MVP with varying forms of retinal artery occlusion, including the first case of atypical Eales' disease (retinal neovascularization) secondary to MVP. Other authors, such as Woldoff *et al.*,<sup>14</sup> Kimball and Hedges<sup>15</sup> and Wilson *et al.*,<sup>16</sup> also documented patients with MVP complicated by retinal artery embolization. None of these patients had any evidence of other sources of retinal emboli. Despite this, Baker *et al.*<sup>17</sup> emphasize that carotid artery atherosclerosis, especially in the older patient, can be a source of retinal artery emboli in the presence of MVP, and therefore recommend routine investigation to exclude these other possible sources.



Recently Walsh *et al.*,<sup>18</sup> in a study involving 29 patients with documented MVP, found that all 9 patients who had had thrombo-embolic events (retinal, cerebral and deep venous) had proven platelet coagulant hyperactivity. Eight others complained of transient visual disturbance, 6 having platelet coagulant hyperactivity. The remaining 12 patients had no visual changes or thrombo-embolism, and only 58% displayed platelet coagulant hyperactivity. Therefore, overall, 76% of the patients with MVP exhibited platelet coagulant hyperactivity as against 6% of controls. Walsh *et al.*<sup>18</sup> postulated that contact of the flowing blood with the abnormal mitral valve surface was directly responsible for the hyperactivity and increased number of circulating platelet aggregates, this leading in turn to the transient visual abnormalities and more severe cerebral thrombo-embolic complications. The further incrimination of platelets was strongly suggested by the work of Steele *et al.*,<sup>19</sup> who reported on diminished platelet survival in these patients.

### Painless MI

Tradition has always demanded the presence of the triad of constricting retrosternal pain, acute ECG changes and serum enzyme elevation before the making of a confident diagnosis of acute MI. This concept has been somewhat modified over the years, mainly because of more sophisticated diagnostic techniques. Perhaps what is less commonly appreciated by the practising clinician is the reality of completely pain-free acute MI, which must often invoke the consideration of ECG 'pseudomyocardial infarction patterns' in the differential diagnosis — our patient was just such an example. Many clinical symptoms may masquerade as an acute MI.<sup>20</sup> Acute dyspnoea or persistent non-productive cough may be in the forefront, or there may be a variety of abdominal symptoms, including dyspepsia, nausea and vomiting. Syncope and other central nervous system manifestations such as hemiparesis, convulsions and varying mental aberrations may present themselves. The presence of simple fatigue, listlessness and lassitude may be all that is necessary to alert the astute clinician to the remote likelihood of an acute MI. These latter symptoms are usually included in the term 'pre-infarction syndrome'.

The incidence of completely painless MI has been variously estimated at between 0% and 60%,<sup>21</sup> but most of these series were based on autopsy findings and retrospective analyses of ECG features in patients admitted for non-cardiac complaints. Perhaps one of the most significant reports was that of Margolis *et al.*<sup>22</sup> relating to an 18-year follow-up (the Framingham Study), in which the incidence of unrecognized MI among 5 127 men and women was established as being 23% on the basis of ECG criteria, with 53% being totally silent. A further important feature, substantiated by several other groups, was the fact that a history of angina pectoris was exceptionally uncommon in patients with unrecognized MI. Uretsky *et al.*<sup>23</sup> documented a 25.5% incidence of symptomatic MI in the absence of chest pain among 102 consecutive patients, this group having a 50% mortality compared with 18% in the group admitted with chest pain. The longer the period between the onset of the infarction and the time of interrogation, the less likely is the patient to complain of chest pain.<sup>24</sup> On objective testing the pain threshold has been noticed to be far higher than normal in these patients.<sup>25</sup> Generally, these patients tend to smoke less, suffer from diabetes or essential hypertension and have a history of chronic heart failure. They also frequently have supraventricular arrhythmias, especially atrial fibrillation.

An exceptionally uncommon cause of painless acute MI is cerebral embolism or thrombosis. Dozzi,<sup>26</sup> in a series of 1 000 consecutive autopsies, documented 12 cases of cerebral embolism or thrombosis associated with acute MI; only 2 of these 12 patients had earlier complained of chest pain. As emphasized by

Levine,<sup>27</sup> this association should always be considered in a normotensive patient presenting with sudden hemiplegia and underlying unsuspected MI. Evans and Sutton<sup>28</sup> documented 1 such patient in a series of 70 patients with painless MI. The source of the embolus in these patients has always been accepted as being a mural thrombus at the site of myocardial necrosis. Our patient certainly did not have an acute MI at the time of his admission for the cerebral embolism. Nevertheless, the cerebral embolus may have been related to his older infarction. We prefer to believe that the source was the myxomatous mitral valve itself, this having been reported to have occurred in Barlow's syndrome (MVP; billowing mitral leaflet syndrome).

There are two possible causes of the MI in our patient: (i) a coronary embolus originating either in the myxomatous mitral valve apparatus or left atrium, or from the left ventricular endocardium, precipitated by the platelet abnormalities previously described in MVP, and lodging in the dominant RCA; and (ii) acute painless coronary vasospasm in an angiographically normal artery.

Prizel *et al.*<sup>29</sup> found evidence of mural thrombi in one-third of 55 cases of coronary artery embolism and MI. Valvular heart disease was the predisposing feature in 40% of those cases with documented coronary emboli, idiopathic cardiomyopathy in 29%, chronic atrial fibrillation in 24% and coronary atherosclerosis in 16%. Approximately two-thirds of these cases had emboli involving the LCA which lodged distally and thus gave rise to transmural MIs with angiographically normal coronary arteries. Coronary emboli were fatal in only 20%. Only 15 of the 55 patients actually presented with clinically diagnosed MI, while only 9 complained of chest pain. Interestingly, 1 of the patients suffered a paradoxical embolus. Since there is a definite association between MVP and secundum atrial septal defect,<sup>30</sup> and since the latter could not be demonstrated at cardiac catheterization in our patient, a possible paradoxical embolus originating in the abnormal mitral valve could not be entertained as the cause of the painless MI. In Prizel *et al.*'s<sup>29</sup> series 9% had no obvious predisposing cause for the coronary emboli, and the authors postulated that thrombi may have originated in normal coronary arteries. This cannot be discounted entirely in our case since platelet abnormalities giving rise to thrombo-embolism have been well documented in MVP.<sup>18,19</sup> Most recently, Waller *et al.*<sup>31</sup> postulated that multiple intramural coronary artery obstruction within the inner half of the myocardium, as might occur with platelet-fibrin emboli arising from a myxomatous mitral valve apparatus, is unlikely to give rise to myocardial necrosis on account of the extensive intramyocardial blood supply. However, if these same emboli involve the outer half of the myocardial wall, one of the epicardial feeding coronary artery branches that arise at a 'right angle' may be thrombosed secondarily due to poor distal run-off. If this occurs then a major coronary artery branch may become occluded with subsequent MI.

The possible role of coronary artery spasm in our patient cannot be completely discounted. Chesler *et al.*<sup>32</sup> reported 4 cases of billowing mitral leaflet syndrome with acute MI and angiographically normal coronary arteries. They postulated that coronary vasospasm was responsible for the infarction since the initial ECGs revealed marked ST-segment elevation. However, they did not carry out the ergonovine (ergometrine) maleate provocation test. The fact that this was negative in our patient makes coronary artery spasm less likely. It has previously been suggested that some reflex is initiated by the billowing posterior leaflet which provokes coronary vasospasm, this resulting in angina, acute MI, arrhythmias and sudden death. MI in association with the billowing mitral leaflet syndrome has also been reported by others,<sup>33,34</sup> but again coronary artery spasm could not be incriminated with certainty.

The concept of 'primary' and 'secondary' MVP has also tended to cause confusion. Barlow *et al.*<sup>35</sup> defined these dif-



ferences quite clearly, stating that the secondary form is usually due to associated coronary artery disease involving the posterior papillary muscle and thus causing dysfunction. Cheng<sup>36</sup> has suggested that left ventricular cine angiography delineates a 'beak' appearance in primary MVP and a 'nipple' configuration in the secondary type. Although the patient under discussion had had a painless infarction at an unknown time and was therefore a candidate for papillary muscle dysfunction or actual infarction, the left ventricular cine angiographic appearance is quite typical of a primary MVP.

### ECG in MVP and cerebrovascular accidents

Since MVP is a common cause of chest pain, albeit atypical, it is important to be aware of the associated ECG peculiarities. Our patient had no chest pain but a frankly abnormal ECG from the start. The most common abnormality is T-wave flattening or frank inversion in leads II, III and aVF,<sup>37</sup> changes occasionally seen in the lateral precordial leads when they may be confused with acute non-transmural MI. However, prominent Q waves in the inferior leads with significant left axis deviation, as in our patient, are not generally documented. A confident diagnosis of transmural inferior MI could therefore be made before catheterization. False-positive stress ECGs occur in MVP, but recently normalization of the test result has been achieved by  $\beta$ -blocker administration, and this feature might be of some use in the differential diagnosis.<sup>38</sup> A far less common ECG finding in MVP has been Q-T-interval prolongation, which may play an important role in sudden death in these patients.<sup>39</sup>

ECG changes in cerebrovascular disorders were first documented in 1954 by Burch *et al.*,<sup>40</sup> who noted Q-T-interval prolongation and deeply inverted and wide T waves in the standard and chest leads. Prominent U waves are also commonly encountered,<sup>41</sup> as are ST-segment elevation and depression which may be misinterpreted as myocardial ischaemia. These findings, comparable with those described in profound electrolyte disturbance, are seen in some 90% of patients during the first 3 days of observation. Yamour *et al.*<sup>42</sup> reported on the high frequency of these 'neurogenic T waves' in patients with anterior cerebral (frontal lobe) and brainstem lesions, stressing the importance of not misdiagnosing a 'primary myocardial event' such as an acute MI. Yamour *et al.*<sup>42</sup> noted that 10% of their patients presenting with temporoparietal haemorrhage had Q waves in leads II, III and aVF which were greater than 30 msec in width; these could have been mistaken for previous transmural MIs.

Hence the patient's ECG could have been caused by either the MVP or the cerebral embolus. Since the patient had no history of chest pain or any symptoms accepted as a 'MI equivalent', the true diagnosis would almost certainly have been missed without left ventricular cine angiography. This stresses the point that an ECG diagnosis of 'pseudo-MI' should not be made without complete investigation.

### Arrhythmias in MVP and cerebrovascular accidents

Unifocal ventricular extrasystoles and ventricular bigeminy were documented by Holter monitoring during the initial few days after our patient's admission, but they had disappeared by the time of discharge. No atrial arrhythmias could be demonstrated. The question therefore arises as to whether these arrhythmias were due to the acute cerebral embolism or part of the MVP, in which event they could well have been partly responsible for initiating the cerebral embolus.

Swartz *et al.*<sup>43</sup> reviewed the literature on arrhythmias in 589 cases of MVP; atrial extrasystoles and/or ventricular extra-

systoles had occurred in 55%, pure ventricular extrasystoles in 45%, ventricular tachycardia in 6.3%, and supraventricular tachycardia in 6.1%. There have been many theories of the pathogenesis of these arrhythmias in MVP. 'Diastolic dumping' has been offered as a cause of the ventricular arrhythmias,<sup>44</sup> whereas Wit *et al.*<sup>45</sup> suggested that stretching of the abnormal mitral valve leaflets stimulated spontaneous pacemaker activity in the valve tissue which propagated to the left atrium and thus caused the atrial arrhythmias (the most common being re-entrant supraventricular tachycardia<sup>46</sup>). Others, such as Gulotta *et al.*<sup>33</sup> and Scampardonis *et al.*,<sup>47</sup> have claimed that a primary myocardial disorder ('cardiomyopathy') is responsible for the various ventricular contraction abnormalities which in turn initiate the arrhythmias.

Various arrhythmias may complicate the acute phase of a cerebrovascular accident, whether this be due to a cerebral embolus, cerebral infarction or subarachnoid haemorrhage,<sup>42</sup> but the precise pathogenesis is not clear. The fact that the arrhythmias virtually disappeared a few days after the initial admission, as well as the fact that repeated Holter monitoring several months later failed to show anything apart from the occasional unifocal ventricular extrasystole, suggests that the cerebral embolus was responsible in our patient. Nevertheless, MVP cannot be excluded entirely in pathogenesis. Several publications have stressed that irrespective of the underlying cardiac disease, arrhythmias give rise to transient ischaemic attacks which are usually of a diffuse nature.<sup>48</sup> Walter *et al.*,<sup>49</sup> Reed *et al.*<sup>50</sup> and McAllen and Marshall<sup>51</sup> documented patients with generalized central nervous system ischaemia as represented by presyncope, syncope and generalized convulsions, but only rarely features of focal neurological ischaemia. Haemodynamic alterations secondary to intermittent cardiac arrhythmias usually lower cardiac output, although Kendell and Marshall<sup>52</sup> strongly disputed the controversial role of hypotension in focal transient cerebral ischaemia. Our patient had no symptoms of transient ischaemic attacks before his acute severe hemiplegia, this suggesting that arrhythmia *per se* was not of significance in the pathogenesis of his stroke.

### The 'cardiomyopathy' of MVP

Is there a true identifiable 'cardiomyopathy' in MVP which could explain all the abnormalities encountered clinically? Hancock and Cohn<sup>53</sup> first suggested that a cardiomyopathy was responsible for MVP, and they were then soon succeeded by Engle,<sup>54</sup> who described segmental left ventricular contraction abnormalities. Liedtke *et al.*,<sup>55</sup> Gooch *et al.*<sup>56</sup> and Grossman *et al.*<sup>57</sup> contributed further data in support of a primary myocardial disorder. Scampardonis *et al.*<sup>47</sup> documented the classic angiographic pattern of the 'ballerina foot' or 'hour-glass' left ventricular deformities caused by excessive posteromedial or midventricular contraction in 86% of their cases, and Gulotta *et al.*<sup>33</sup> found similar changes on left ventricular cine angiography in 77% of their cases of MVP.

It was not until 1978 that subtle but distinctive histological suggestions of a cardiomyopathy were documented by Mason *et al.*<sup>58</sup> These researchers obtained endomyocardial biopsy material from the apical part of the right ventricular septum at cardiac catheterization, and studied 14 patients whose diagnosis of MVP had been established by auscultation, echocardiography or angiography. Light microscopy revealed increased fibrosis in the endocardium as well as in the interstitium in 8 patients (57%), and focal myocyte hypertrophy in 5 patients (36%). Eleven of the patients underwent electron microscopy of the biopsy tissue and in all features of mitochondrial degeneration were seen. In 4 (36%) of these patients undoubted degeneration of myocytes was seen, while intracellular oedema and clumping of the nuclear chromatin was more noticeable. The authors postu-



lated that the 'mitochondrial dystrophy' was probably the ultrastructural precursor of endocardial and interstitial fibrosis, and accepted that these cardiomyopathic changes could account for the chest pain, arrhythmia and mild congestive cardiac failure. Since tricuspid valve prolapse can accompany MVP and give rise to tricuspid regurgitation, the authors<sup>58</sup> concede that this haemodynamic state could have caused the histological features, although there were no signs of tricuspid regurgitation.

Compared with the biopsy findings reported by Mason *et al.*<sup>58</sup> features of our biopsy specimens were slight and nonspecific and precluded us from being emphatic about an associated 'cardiomyopathy'.

### Therapeutic implications

The complications which our patient has sustained as a result of his 'primary' MVP (billowing mitral leaflet syndrome or Barlow's syndrome) have been quite devastating. This is particularly true as regards the dense hemiplegia — this has necessitated premature retirement from a lucrative profession. At present he is being maintained on strict anticoagulant and antiplatelet drug therapy. After many months of follow-up it would seem that his clinical condition has stabilized. Nevertheless, theoretically a situation may be encountered where the systemic emboli are not kept in check by this medical therapy; this would then raise the point of whether excision of the myxomatous mitral valve and its replacement with a prosthesis is indicated. The whole question of systemic embolism in MVP is still somewhat vexed.

The authors wish to sincerely thank Miss H. Weymar of the Cardiac Clinic, Tygerberg Hospital, for preparing the manuscript and some of the illustrations. Thanks are also due to Mrs Jill Myers of the Department of Clinical Photography for her painstaking preparation of the photographs. We would also like to thank Dr F. S. Hough of the Department of Internal Medicine for referring the patient to the Cardiac Clinic, and Dr C. Vivier, Chief Medical Superintendent of Tygerberg Hospital, for permission to publish.

### REFERENCES

- Barlow JB, Bosman CK. Aneurysmal protrusion of the posterior leaflet of the mitral valve: an auscultatory-electrocardiographic syndrome. *Am Heart J* 1966; **71**: 166-178.
- Barnett HJM. Transient cerebral ischemia: pathogenesis, prognosis and management. *Ann R Coll Phys Surg Can* 1974; **7**: 153-173.
- Barnett HJM, Jones MW, Boughner DR, Kostuk WJ. Cerebral ischemic events associated with prolapsing mitral valve. *Arch Neurol* 1976; **33**: 777-782.
- Pomerance A. Ballooning deformity (mucoid degeneration) of atrioventricular valves. *Br Heart J* 1969; **31**: 343-351.
- Silver M. Rheumatic carditis: acute and chronic atrioventricular valve disease. In: Edwards J, Lev M, Abel M, eds. *The Heart*. Baltimore: Williams & Wilkins, 1974: 87-109.
- Kostuk WJ, Boughner DR, Barnett HJM, Silver MD. Strokes: a complication of mitral-leaflet prolapse? *Lancet* 1977; **ii**: 313-316.
- Pomerance A, Davies MJ. Strokes: a complication of mitral-leaflet prolapse. *Lancet* 1977; **ii**: 1186.
- Malcolm AD, Boughner DR, Kostuk WJ, Ahuja SP. Clinical features and investigative findings in the presence of mitral leaflet prolapse: study of 85 consecutive patients. *Br Heart J* 1976; **38**: 244-256.
- Hirsworth GS, Saffer D. Hemiplegia and the billowing mitral leaflet syndrome. *J Neurol Neurosurg Psychiatry* 1978; **41**: 381-383.
- Hanson MR, Hodgman JR, Conomy JP. A study of stroke associated with prolapsed mitral valve (Abstract). *Neurology* 1978; **28**: 341.
- Saffro R, Talano JV. Transient ischemic attack associated with mitral systolic clicks. *Arch Intern Med* 1979; **139**: 693-694.
- Barnett HJM, Boughner DR, Taylor DW, Cooper PE, Kostuk WJ, Nichol PM. Further evidence relating mitral-valve prolapse to cerebral ischemic events. *N Engl J Med* 1980; **302**: 139-144.
- Caltrider ND, Irvine AR, Kline HJ, Rosenblatt A. Retinal emboli in patients with mitral valve prolapse. *Am J Ophthalmol* 1980; **90**: 534-539.
- Woldoff HS, Gerber M, Desser KB, Benchimol A. Retinal vascular lesions in two patients with prolapsed mitral valve leaflets. *Am J Ophthalmol* 1975; **79**: 382-385.
- Kimball RW, Hedges TR. Amaurosis fugax caused by a prolapsed mitral leaflet in the midsystolic click, late systolic murmur syndrome. *Am J Ophthalmol* 1977; **83**: 469-470.
- Wilson LA, Keeling PWN, Malcolm AD, Ross Russel RW, Webb-Peploe MM. Visual complications of mitral leaflet prolapse. *Br Med J* 1977; **2**: 86-88.
- Baker RS, Tibbs PA, Millett AJ. Carotid-retinal embolism with coexistent mitral valve prolapse. *Neurology (NY)* 1981; **31**: 1192-1193.
- Walsh PN, Kansu TA, Corbett JJ, Savino PJ, Golubgh WP, Schatz NJ. Platelets, thromboembolism and mitral valve prolapse. *Circulation* 1981; **63**: 552-559.
- Steele P, Weily H, Rainwater J, Vogel R. Platelet survival time and thromboembolism in patients with mitral valve prolapse. *Circulation* 1979; **60**: 43-45.
- Bean WB. Masquerades of myocardial infarction. *Lancet* 1977; **ii**: 1044-1046.
- Roseman MD. Painless myocardial infarction: a review of the literature and analysis of 220 cases. *Ann Intern Med* 1954; **41**: 1-8.
- Margolis JR, Kannel WB, Feinleib M, Dawber TB, McNamara PM. Clinical features of unrecognized myocardial infarction — silent and symptomatic. Eighteen year follow-up: Framingham Study. *Am J Cardiol* 1973; **32**: 1-7.
- Uretsky BF, Farquhar DS, Berezin AF, Hood WB. Symptomatic myocardial infarction without chest pain: prevalence and clinical course. *Am J Cardiol* 1977; **40**: 498-503.
- Papp C. Acute cardiac infarction without pain. *Br Heart J* 1952; **14**: 250-259.
- Keele KD. Pain complaint threshold in relation to pain of cardiac infarction. *Br Med J* 1968; **1**: 670-673.
- Dozzi DL. Cerebral embolism as complication of coronary thrombosis. *Am J Med Sci* 1937; **194**: 824-830.
- Levine S. *Clinical Heart Disease*. 3rd ed. London: WB Saunders, 1945.
- Evans W, Sutton GC. Painless cardiac infarction. *Br Heart J* 1956; **18**: 259-272.
- Prizel KR, Hutchins GM, Bulkley BH. Coronary artery embolism and myocardial infarction: a clinicopathologic study of 55 patients. *Ann Intern Med* 1978; **88**: 155-161.
- Pocock WA, Barlow JB. An association between the billowing posterior mitral leaflet syndrome and congenital heart disease, particularly atrial septal defect. *Am Heart J* 1971; **81**: 720-722.
- Waller BF, Dixon DS, Kim RW, Roberts WC. Embolus to the left main coronary artery. *Am J Cardiol* 1982; **50**: 658-660.
- Chesler E, Matisonn RE, Lakier JB, Pocock WA, Obel IWP, Barlow JB. Acute myocardial infarction with normal coronary arteries: a possible manifestation of the billowing mitral leaflet syndrome. *Circulation* 1976; **54**: 203-209.
- Gulotta SJ, Gulco L, Padmanabhan V, Miller S. The syndrome of systolic click, murmur, and mitral valve prolapse — a cardiomyopathy? *Circulation* 1974; **49**: 717-728.
- Tuqan SK, Mau RD, Schwartz MJ. Anterior myocardial infarction patterns in the mitral valve prolapse-systolic click syndrome. *Am J Med* 1975; **58**: 719-723.
- Barlow JB, Pocock WA, Obel IWP. Mitral valve prolapse: primary, secondary, both or neither? *Am Heart J* 1981; **102**: 140-143.
- Cheng TO. Primary versus secondary mitral valve prolapse. *Am Heart J* 1981; **102**: 946.
- Devereux RB, Perloff JK, Reichek N, Josephson ME. Mitral valve prolapse. *Circulation* 1976; **54**: 3-14.
- Abinader EG, Shahar J. Exercise testing in mitral valve prolapse before and after beta blockade. *Br Heart J* 1982; **48**: 130-133.
- Shappell SD, Marshall CE, Brown RE, Bruce TA. Sudden death and the familial occurrence of mid-systolic click, late systolic murmur syndrome. *Circulation* 1973; **48**: 1128-1134.
- Burch GE, Meyers R, Abildskov JA. A new electrocardiographic pattern observed in cerebrovascular accidents. *Circulation* 1954; **9**: 719-723.
- Hughenoltz PG. Electrocardiographic abnormalities in cerebral disorders: report of six cases and review of the literature. *Am Heart J* 1962; **63**: 451-461.
- Yamour BJ, Sridharan MR, Rice JF, Flowers NC. Electrocardiographic changes in cerebrovascular hemorrhage. *Am Heart J* 1980; **99**: 294-300.
- Swartz MH, Teichholz LE, Donoso E. Mitral valve prolapse: a review of associated arrhythmias. *Am J Med* 1977; **62**: 377-389.
- Criley JM, Zeilenga DW, Morgan MT. Mitral dysfunction: a possible cause of arrhythmias in the prolapsing mitral leaflet syndrome. *Trans Am Clin Climatol Assoc* 1973; **85**: 44-53.
- Wit AL, Fenoglio JJ, Hordof AJ, Reemtsma K. Ultrastructure and transmembrane potentials of cardiac muscle in the human anterior mitral valve leaflet. *Circulation* 1979; **59**: 1284-1292.
- Perloff JK. Evolving concepts of mitral-valve prolapse (Editorial). *N Engl J Med* 1982; **307**: 369-370.
- Scamporrison G, Yang SS, Maranhao V *et al.* Left ventricular abnormalities in prolapsed mitral leaflet syndrome. *Circulation* 1973; **48**: 287-297.
- De Bono DP, Warlow CP, Hyman NM. Cardiac rhythm abnormalities in patients presenting with transient non-focal neurological symptoms: a diagnostic grey area? *Br Med J* 1982; **284**: 1437-1439.
- Walter PF, Reid SD, Wenger NK. Transient cerebral ischemia due to arrhythmia. *Ann Intern Med* 1970; **72**: 471-474.
- Reed RL, Siekert RG, Merideth J. Rarity of transient focal cerebral ischemia in cardiac dysrhythmia. *JAMA* 1973; **223**: 893-895.
- McAllen PM, Marshall J. Cardiac dysrhythmia and transient cerebral ischaemic attacks. *Lancet* 1973; **ii**: 1212-1215.
- Kendell RE, Marshall J. Role of hypotension in the genesis of transient focal cerebral ischaemic attacks. *Br Med J* 1963; **2**: 344-348.
- Hancock EW, Cohn K. The syndrome associated with midsystolic click and late systolic murmur. *Am J Med* 1966; **41**: 183-196.
- Engle MA. The syndrome of apical systolic click, late systolic murmur, and abnormal T waves. *Circulation* 1969; **39**: 1-2.
- Liedtke AJ, Gault JH, Leaman DM *et al.* Geometry of left ventricular contraction in the systolic click syndrome: characterization of a segmental myocardial abnormality. *Circulation* 1973; **47**: 27-35.
- Gooch AS, Fiorello V, Maranhao V *et al.* Arrhythmias and left ventricular asynergy in the prolapsing mitral leaflet syndrome. *Am J Cardiol* 1972; **29**: 611-620.
- Grossman H, Fleming RJ, Engle MA *et al.* Angiography in the apical systolic click syndrome. *Radiology* 1968; **91**: 898-904.
- Mason JW, Koch FH, Billingham ME, Winkle RA. Cardiac biopsy evidence for a cardiomyopathy associated with symptomatic mitral valve prolapse. *Am J Cardiol* 1978; **42**: 557-562.