

Lipoid proteinosis

A case report

S. W. HARDCASTLE, W. J. C. J. ROSENSTRAUCH

Summary

A 31-year-old Coloured man was admitted to Tygerberg Hospital in 1981 with hoarseness, hyperkeratotic skin lesions and nodules on the eyelids. There was a history of an episode of loss of consciousness. Skull radiographs demonstrated bilateral symmetrical calcifications in the temporal region. Skin biopsy was consistent with a diagnosis of lipoid proteinosis.

S Afr Med J 1984; 66: 273-274.

Lipoid proteinosis (Urbach-Wiethe disease or hyalinosis cutis et mucosae) is a distinctive dermatosis associated with hoarseness. There is a particularly high incidence of this condition in the Namaqualand district of South Africa. Of the 171 patients reported up to 1969, 1 in 5 were from South Africa.¹ Genealogical studies have shown that the gene responsible was introduced into South Africa in the mid-17th century.^{1,2}

Case report

A 31-year-old Coloured man from Namaqualand was admitted to Tygerberg Hospital in October 1981. He was referred for evaluation of headaches of recent onset and possible epilepsy. The patient gave a history of loss of consciousness in April 1981 while underground in the local mine. According to collateral sources the patient became stiff, but there was no history of tonic-clonic convulsions. The duration of loss of consciousness was not known, and there was no incontinence. The patient regained consciousness when brought to the surface of the mine. His headaches started shortly after this and were bitemporal, throbbing in nature and intermittent. There were no associated fortification spectra or visual disturbances. There was no radiation but the patient felt lame and weak. Analgesics received from his general practitioner had brought temporary relief.

The patient also complained that he had been hoarse since birth. This had been non-progressive and had caused minimal disability. Associated with the hoarseness were skin lesions which affected his hands and extensor surfaces of the arms and knees, as well as the lower eyelids. He also complained of patchy hair loss over the occiput. The patient's family history revealed that his maternal aunt had also suffered from hoarseness before her death in 1979. Of this aunt's children, 3 out of 5 are also hoarse and have skin lesions. None of the patient's siblings have hoarseness or skin lesions. The personal history and systematic interrogation of the patient did not reveal any points of note.

Department of Medicine, University of Stellenbosch and Tygerberg Hospital, Parowvallei, CP

S. W. HARDCASTLE, M.B. CH.B., M.MED. (INT.), F.C.P. (S.A.)

W. J. C. J. ROSENSTRAUCH, M.B. CH.B., M.MED. (INT.), M.D.

On examination the most striking features were the presence of skin lesions and hoarseness. Hyperkeratotic skin lesions were present on the extensor surfaces of the upper and lower limbs and in the axillae (Fig. 1). The lesions on the limbs were predominantly over pressure sites. The skin of the palms was thickened and calloused. The exposed skin of the face and limbs was more severely affected than the trunk; these lesions also appeared hyperpigmented. Fine nodular lesions were also present on the margins of the eyelids. The lower eyelid was more affected than the upper and there was associated loss of eyelashes. The lesions resembled a 'string of pearls' (Fig. 2). Mucosal lesions were present on the lips, which were thickened and fissured. A white nodule was present on the tongue which appeared indurated and rigid and had a woody consistency on palpation. Severe dental caries and periodontitis were also present. Patchy alopecia was evident over the occiput.

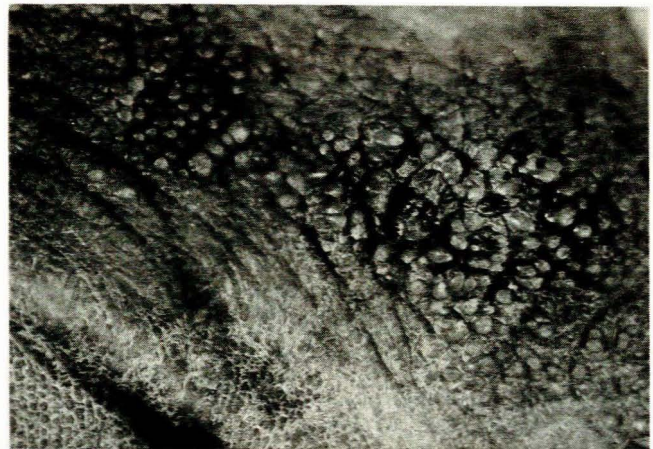


Fig. 1. Skin lesions in right axillary fold.

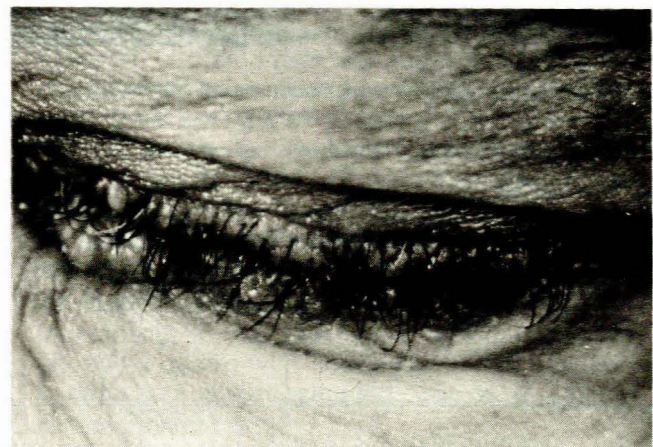


Fig. 2. 'String of pearls' on left eyelid.

Examination of the cardiovascular, respiratory and gastrointestinal systems revealed no abnormalities. Neurological examination was essentially normal. The patient was, however, of low intelligence. Ophthalmoscopy revealed that the retina had a fine granular appearance in the region of the macula. There were no focal neurological signs.

Special investigations

Routine blood studies and chest radiographs were normal. Skull radiographs showed the presence of two oval, bean-shaped calcifications on the lateral views. These were situated slightly above and behind the posterior clinoid processes (Fig. 3). The blood glucose level was 4,8 mmol/l (fasting) and cholesterol 4,96 mmol/l. The Wassermann reaction was negative. Lumbar puncture revealed a protein level of 0,5 g/l but was otherwise normal, while tests for syphilis were negative. Biochemical values and the protein electrophoretic pattern were normal. The effective thyroxine index was 0,94 (normal 0,86 - 1,13) and the fasting lipogram was normal. An electro-encephalogram (EEG) showed irregular 9 - 10 cycles/s alpha rhythm. Irregular continuous 3 - 6 cycles/s waves with low amplitude were also present in the left temporal recording, and were thought to reflect nonspecific organic changes. Computed tomography confirmed the presence of dense calcifications on the antero-medial aspects of both temporal lobes, thought to represent calcification in both hippocampi. The brain substance and ventricular systems were normal. A biopsy specimen of one of the skin lesions on the hands demonstrated histological changes consistent with lipid proteinosis.

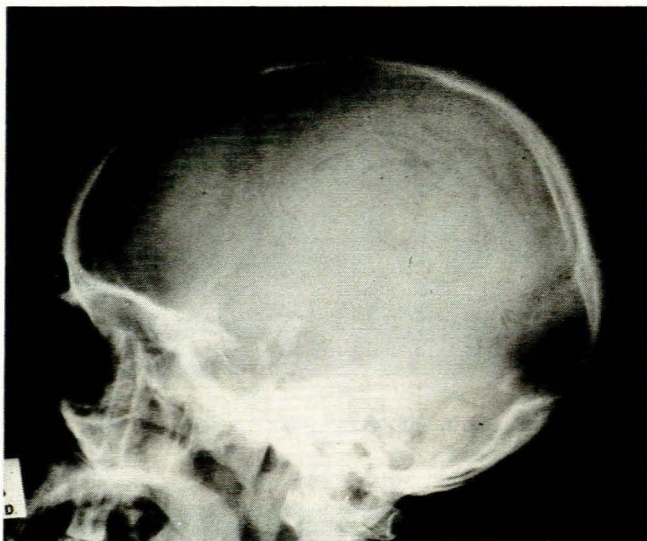

Fig. 3. Skull radiograph showing bean-shaped calcifications.

Discussion

The combination of hoarseness and skin lesions present since childhood is so characteristic of lipid proteinosis that it may be regarded as diagnostic. A feature of the epidemiology of lipid

proteinosis is the relatively high frequency of the disease in South Africa, and especially in the Namaqualand area.^{1,2} Gordon *et al.*¹ and Heyl² in their genealogical studies have traced the progenitor to the trekboer Gerrit Cloete who arrived in Namaqualand in about 1742. Gerrit Cloete was one of the great-grandsons of Jacob Cloete, one of the original settlers who came to the Cape in 1652.

Lipoid proteinosis is an autosomal recessive condition in which lipid, mucopolysaccharide hyaline material is deposited in the walls of blood vessels and in the extracellular space.³ It would appear that the deposition of hyaline material is not confined to the skin and mucous membranes. It has also been demonstrated in blood vessel walls in the jejunum, lungs, kidneys and skeletal muscles, suggesting a systemic disease.⁴

Hoarseness results from laryngeal involvement. Thickening and nodules occur on the vocal cords. Involvement may be so severe as to result in upper airway obstruction necessitating tracheostomy.² Other features, not found in our patient, include absent upper incisors and persistent milk teeth,² involvement of the oesophagus, rectum and anus,² salivary gland obstruction,¹ and an association with diabetes mellitus and hypercholesterolaemia.³

The intracranial calcifications were first reported in 1943.⁵ Although not invariably present, this radiographic sign is characteristic of lipid proteinosis.¹ Computed tomography localized these calcifications to the hippocampal gyri of the temporal lobes in our patient, which is in accordance with the autopsy findings of Holtz.⁶ There is a reported increased frequency of epilepsy, confusional states, hallucinations and *déjà vu* experiences in patients with lipid proteinosis.² This might possibly explain our patient's loss of consciousness and abnormal EEG recording.

The skin lesions are characteristic (Figs 1 and 2). Additional changes include atrophic scars, a waxy appearance of the skin and discrete or confluent nodular lesions affecting the eyelids, neck and distal phalanges.¹ The precise biochemical defect is unknown.

Conclusion

The association of skin lesions and hoarseness should suggest a diagnosis of lipid proteinosis. The disease is not incompatible with a normal lifespan, although the skin lesions may be progressive until early adult life. However, laryngeal involvement may be life-threatening and for this reason patients should be followed up regularly.

REFERENCES

- Gordon H, Gordon W, Botha V, Edelstein I. Lipoid proteinosis. *Birth Defects*. (Original Article Series, vol. VIII, No. 8). New York: National Foundation - March of Dimes, 1971: 164-177.
- Heyl T. Lipoiedproteinose: 'n plaaslike studie van die siekte met spesiale verwysing na die genealogiese aspekte daarvan (M.D. thesis). Stellenbosch: University of Stellenbosch, 1969: 6-12, 19-21, 39-50.
- Burnett JW. Lipoid proteinosis. In: Fitzpatrick TB *et al.*, eds. *Dermatology in General Medicine*. New York: Optima/McGraw-Hill, 1971: 1202-1203.
- Caplan RM. Visceral involvement in lipid proteinosis. *Arch Dermatol* 1967; **95**: 149-151.
- Ramosé Silva J. Lipoid proteinosis (Urbach-Wiethe). *Arch Dermatol Syph (Chic.)* 1943; **47**: 301-302.
- Holtz KH. Über Gehirn- und Augenveränderungen bei Hyalinosis cutis et mucosae (Lipoidproteinose) mit Autopsiebefund. *Arch Klin Exp Dermatol* 1962; **214**: 289-292.