

# Hydatid cyst of the pancreatic tail

## A case report

D. F. DU TOIT, A. J. LOXTON, L. LAKER, J. F. DREYER

### Summary

A case of calcified hydatid cyst of the pancreatic tail is presented. The ultrasonographic and computed tomographic features of the lesion suggested the presence of a cystadenoma or a calcified hydatid cyst. Computed tomography proved the most useful investigation and accurately localized the lesion. A distal pancreatectomy and splenectomy were performed because on the basis of the results of pre-operative investigations and macroscopic operative findings, carcinoma of the pancreatic tail could not be ruled out with certainty. The patient made an uneventful recovery.

S Afr Med J 1984; 66: 781-782.

Hydatid disease is caused by the *Echinococcus granulosus* tapeworm.<sup>1,2</sup> Hydatid cysts of the liver account for approximately 60% of all cases of this disease and pulmonary involvement for 20%, cysts of bone, kidney, brain and heart making up the rest.<sup>3,4</sup> Pancreatic involvement is rare.<sup>3,5</sup> This paper describes the pre-operative evaluation and surgical treatment of a patient with asymptomatic hydatid disease of the tail of the pancreas.

### Case report

A 70-year-old White woman was admitted to Tygerberg Hospital with severe chronic arterial insufficiency of the lower legs. She had lived on a sheep farm for many years. Other than bilateral calf claudication, she had no complaints. On clinical examination the patient was obese but otherwise well. Her blood pressure was 150/75 mmHg, her pulse rate 76/min, and her temperature normal; the haemoglobin value was 11 g/dl. The cardiovascular and respiratory systems were normal. Abdominal palpation revealed a non-tender immobile mass in the left hypochondrium. Popliteal and foot pulses were absent and segmental arterial pressure studies of the lower legs before and after exercise confirmed significant arterial insufficiency.

A radiograph of the abdomen showed a round calcified mass in the region of the left kidney. Aortography confirmed extensive atherosclerosis of the aorta with bilateral multiple occlusions of the femoral arteries and vessels below the knee. On selective arteriography of the renal artery normal renal vasculature was

noted. An intravenous pyelogram showed a mild degree of displacement of the left kidney by an extrinsic mass.

Ultrasonographic studies of the abdomen revealed a mass measuring 7-8 cm in diameter anterior to the left kidney. The mass exhibited hyper- and hypo-echoic areas and marked sound attenuation suggesting calcification of the wall (Fig. 1). A pancreatic tumour was suspected. Computed tomography (CT) of the abdomen confirmed the presence of a calcified mass in the tail of the pancreas (Fig. 2).

The patient's haematological profile was normal, including the eosinophil count. A Casoni skin test was not performed. Cystadenoma, cystadenocarcinoma and calcified hydatid cyst of the pancreatic tail were considered in the differential diagnosis and the patient was subjected to an elective laparotomy.

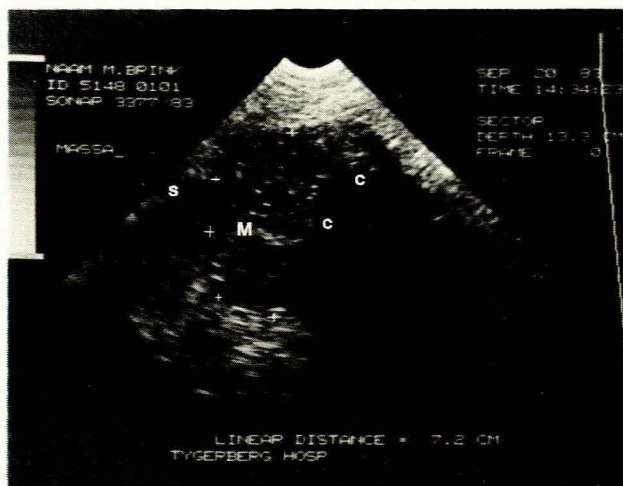


Fig. 1. Sagittal ultrasonogram of left hypochondrium (M = mass; C = sound attenuated by calcific wall; S = spleen).

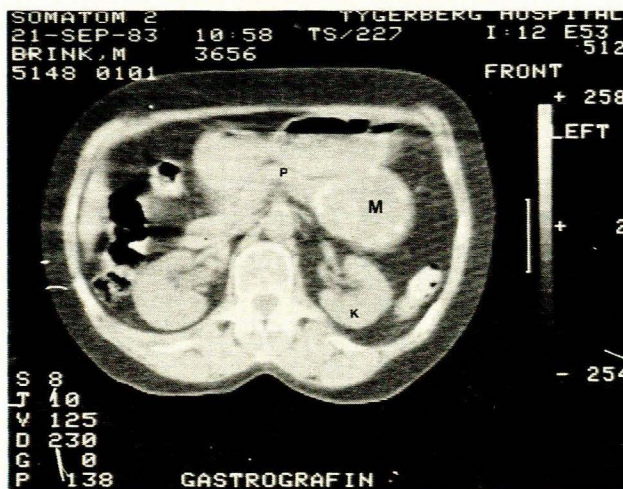


Fig. 2. CT scan (M = calcified mass situated in pancreatic tail; P = body of the pancreas; K = left kidney).

Department of Surgery, University of Stellenbosch and Tygerberg Hospital, Parowvallei, CP

D. F. DU TOIT, D.PHIL., F.R.C.S., *Principal Surgeon*  
A. J. LOXTON, M.MED. (RAD.D.), *Principal Radiologist*  
E. LAKER, B.SC., *Research Assistant*  
J. F. DREYER, M.B. CH.B., *Registrar*

Reprint requests to: Dr D. F. du Toit, Dept of General Surgery, University of Stellenbosch Medical School, PO Box 63, Tygerberg, 7505 RSA.

At laparotomy a calcified mass measuring 8 x 8 cm was present in the pancreatic tail; it was intimately related to the hilum of the spleen and its vasculature. Since a neoplasm of the pancreas could not be discounted with certainty, distal pancreatectomy and splenectomy were performed. Further examination of the abdominal contents revealed no abnormality. Macroscopic inspection of the resected specimen after sectioning revealed a typical calcified hydatid cyst containing multiple daughter cysts.

The patient made an uneventful recovery and was discharged 10 days after operation. She was not considered a suitable candidate for direct arterial surgery because of the extent of the underlying arterial disease in her legs.

## Discussion

Surgical extirpation is the orthodox treatment of choice for patients with viable hydatid cysts. Nevertheless, no controlled studies have been reported comparing the risks and benefits of the different forms of management and treatment. Treatment of hydatid disease is strongly indicated to reduce the risk of anaphylactic reaction and dissemination of larvae following rupture of the cyst. Although the aims of surgery are to remove the cyst safely and prevent recurrence, its indications are controversial. Surgery is clearly indicated in a young, fit patient with a large symptomatic cyst situated in the liver, while a conservative approach would clearly be more appropriate for a frail elderly patient with a small asymptomatic or calcified cyst.

Surgery may be impossible or impractical because of the extent or location of the cyst, the patient's general condition, or lack of adequate laboratory facilities. In these cases mebendazole, a benzimidazole derivative which kills the larval stages of *E. granulosus* by limiting glucose uptake, should be considered.<sup>6-8</sup> Results of data available to date indicate that patients selected for treatment with mebendazole should receive 50 - 100 mg/kg/d for a minimum of 3 months.<sup>8</sup> Not all reports of medical treatment of hydatid disease have been encouraging. 'Improvement' has been reported in the majority of cases,<sup>6,7</sup> but many patients have had evidence of disease progression, recurrence or parasite viability after treatment had been discontinued.<sup>8</sup> Side-effects include febrile and allergic reactions, alopecia, glomerulonephritis, gastric irritation, pruritus, reversible leucopenia and transient liver dysfunction.<sup>1,7,8</sup> Because of the limited absorption of mebendazole from the gut it has been suggested that plasma drug concentrations should be monitored. At present 80 ng/ml is considered the minimal plasma concentration for pharmacological effectiveness.

Enucleation of the entire cyst followed by obliteration of the cavity is the standard operative treatment for hydatid cysts.<sup>1</sup> If a hydatid cyst is encountered at operation, evacuation of the cyst

should be preceded by aspiration, avoiding spillage of the antigenic material into the peritoneal cavity. After aspiration an equal volume of a scolicidal agent, usually hypertonic glucose or 5 - 10% hypertonic saline, is injected into the cyst. After 10 minutes the cyst is opened, and all fluid and daughter cysts are removed. For liver cysts, cystectomy, partial hepatectomy and omentoplasty, marsupialization or tube drainage have been advocated.<sup>1</sup> The most appealing surgical procedure is evacuation of the contents of the cyst including the cyst wall and closure of the cyst cavity with a viable omental pedicle pack. In this case the lesion in the pancreas could not be differentiated from an underlying tumour with certainty. Despite pre-operative investigations and the operative appearance, a distal pancreatectomy was mandatory.

The diagnosis of hydatid cyst may be substantiated by positive serological tests, which include haemagglutination inhibition and complement-fixation tests, together with a positive Casoni skin test.<sup>1</sup> Ultrasonography and CT readily demonstrate the presence and anatomical localization of the fluid-filled cyst.<sup>1-5,9</sup> Besides straight abdominal radiographs, on which the characteristic abdominal calcifications are seen, arteriography may prove an important adjunct before surgery.

In this case CT proved the most useful non-invasive investigation and accurately localized the lesion, thereby making its subsequent surgical removal easier.

We are indebted to the Departments of Chemical Pathology, Anatomical Pathology and Radiology at Tygerberg Hospital, and thank Mrs M. van Dalen for typing the manuscript and the Medical Superintendent of Tygerberg Hospital for permission to publish.

## REFERENCES

1. Morris DL. Management of hydatid disease. *Br J Hosp Med* 1981; **26**: 86-90.
2. Babcock DS, Kaufman L, Cosnow I. Ultrasound diagnosis of hydatid disease (echinococcosis) in two cases. *AJR* 1978; **131**: 895-897.
3. Ismail MA, Al-Dabagh MA, Al-Janabi TA *et al.* The use of computerised axial tomography (CAT) in the diagnosis of hydatid cysts. *Clin Radiol* 1980; **31**: 287-290.
4. Niron EA, Özer H, Dolunay H. Encysted peritoneal hydatosis, unusual ultrasonographic and clinical presentation of liver echinococcosis. *Br J Radiol* 1981; **54**: 339-340.
5. Andrew WK, Glyn Thomas R. Hydatid cyst of the pancreatic tail. *S Afr Med J* 1981; **59**: 235-236.
6. Bekhti A, Schaaps J-P, Capron M *et al.* Treatment of hepatic hydatid disease with mebendazole: preliminary results in four cases. *Br Med J* 1977; **2**: 1047-1051.
7. Murray-Lyon IM, Reynolds KW. Complications of mebendazole treatment for hydatid disease. *Br Med J* 1979; **2**: 1111-1112.
8. Schantz PM, Kammerer WS. Echinococcosis. In: Conn HF, ed. *Current Therapy*. Philadelphia: WB Saunders, 1983: 15-16.
9. Meire HB, Husband J. Demonstration of focal liver disease by ultrasound and computed tomography. In: Taylor KJW, ed. *Diagnostic Ultrasound in Gastrointestinal Disease*. New York: Churchill Livingstone, 1979: 35-58.