

# Barton's forceps deliveries at Paarl Hospital

V. P. DE VILLIERS

## Summary

Experience in using Barton's forceps for mid-pelvic arrest of the fetal head in 348 cases has proved that this instrument is both easy to apply and safe for the baby, provided rigid adherence to safety criteria are observed. As modern obstetric practice is favourably disposed towards mid-pelvic forceps vaginal delivery, the particular advantages of Barton's forceps should be more widely extolled. Their use is an invaluable addition to the obstetrician's armamentarium. Training in their use should, however, be thorough and extensive and under the guidance of a skilled senior obstetrician.

*S Afr Med J* 1988; 73: 175-178.

Barton's forceps are the only true American forceps. The concept was first developed in 1911 by Dr Layman Guy Barton, a qualified mechanical engineer, who later graduated as a doctor in order to follow in the footsteps of his father who practised as a general practitioner in Willsboro, Essex County, New York. The forceps were first used at Sloane Maternity Hospital on 24 November 1924, and Bachman<sup>1</sup> reported on their use in 1927. Barton also published his experience in 1928 (Barton *et al.*<sup>2</sup>). The forceps are unique in modern obstetrics as they are the only example of an 'anteroposterior' instrument, i.e. forceps designed specifically for grasping the fetal head when it is lying in the transverse position in the anteroposterior diameter of the pelvis. Because the forceps were originally designed for the high transverse head, they may be considered to have no place in modern obstetrics. This is not true. Parry-Jones<sup>3</sup> reported on 291 procedures in 1968, with a gross perinatal mortality rate of 16/1 000.<sup>3</sup> He replaced his previously adored Kjelland's forceps with Barton's forceps in cases of transverse arrest since he found that the latter were much easier to apply and that there was more patient comfort. Parry-Jones followed this report with a superb monograph<sup>4</sup> published in 1972. However, not much support was generated by his work. In the recent literature there is at best only a casual mention of Barton's forceps by Healey *et al.*<sup>5</sup> from the Royal Women's Hospital, Melbourne, Australia.

Experience with Barton's forceps in 348 patients at Paarl Hospital, CP, is reported and the benefits of the instrument are discussed in comparison with other instruments for mid-rotation of the fetus.

Department of Obstetrics and Gynaecology, University of Stellenbosch and Paarl Hospital, CP  
V. P. DE VILLIERS, F.R.C.O.G.

Accepted 13 Aug 1987.

Reprint requests to: Dr V. P. de Villiers, 15 Septimus Street, Paarl, 7646 RSA.

## Patients and methods

Out of the total of 20 667 babies delivered from 1976 to the end of 1985 at the University of Stellenbosch maternity unit at Paarl Hospital, Barton's forceps were used in 348 (1,68%). During this same period 1 337 (6,47%) Wrigley's forceps and 55 (0,27%) Kjelland's forceps deliveries were carried out.

The indications for the use of Barton's forceps were mainly deep transverse arrest of the fetal head and poor bearing down after an epidural block (Table I).

TABLE I. INDICATIONS FOR BARTON'S FORCEPS DELIVERIES\*

Indication	No. of patients	%
Deep transverse arrest of the fetal head	143	41,1
Poor bearing-down after an epidural block	72	20,7
Previous failed vacuum extraction	51	14,7
Fetal distress with late decelerations of the fetal heart and/or meconium in the liquor	40	11,5
Maternal exhaustion	28	8,0
Imminent eclampsia or eclampsia	22	6,3
Previous caesarean section	14	4,0
Previous failed application of Wrigley's forceps	5	1,4
Cardiac disease of pregnancy	1	0,3
Face presentation	2	0,6

\*In some cases there was more than one indication.

Before application of the forceps the following rigid criteria must be fulfilled: (i) patient in the lithomy position; (ii) buttocks of the patient must overlap the end of the delivery couch to prevent obstruction to posterior traction of the forceps; (iii) the operator must be in a sitting position, both to maintain axis traction on the head and to prevent excessive traction; (iv) adequate intravenous infusion; (v) careful palpation of the abdomen to ensure that no more than two-fifths of the baby's head is still palpable; (vi) absolute certainty of the position, flexion and station of the fetal head by vaginal examination is necessary; if in any doubt, the baby's ear must be palpated after the pudendal block is administered; (vii) administration of bilateral pudendal block with 10 ml 1% lignocaine; full relaxation of the sphincter ani ensures that the local anaesthesia is complete; (viii) full dilatation of the cervix; (ix) the bladder is always catheterised; and (x) a mock application of the forceps is always attempted before the procedure itself (Fig. 1).

## Application of the anterior blade

One of the unusual features of Barton's forceps is the hinge which unites the fenestration of the anterior blade with the shank. This hinge allows easy application without the handle butting onto the thighs, and accommodates varying cephalic diameters. The apex of the forceps is introduced posterolaterally until the hinge is just visible. Two fingers are placed behind the fenestration while

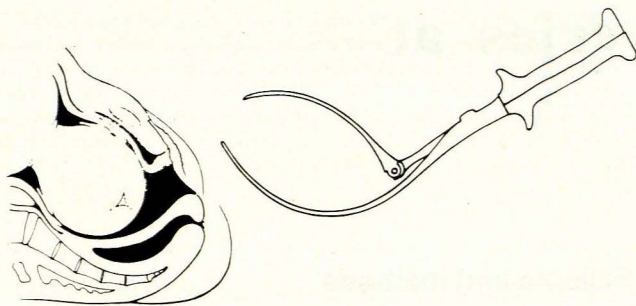


Fig. 1. Mock application.

the other hand supports the main weight of the blade and keeps the leading edge gently against the fetal head. The blade is then gently manoeuvred anteriorly. When the mid-line is reached the blade is pushed upwards by the external hand and may be held by an assistant while the second blade is inserted (Fig. 2). The manoeuvring may be made on either side of the pelvis but since the shape of the blade approximates that of the face of the fetus this direction is often easier than over the occiput. After manoeuvring, the head is palpated to see whether the occiput has shifted. A symmetrical cephalic application is essential. Occasionally the anterior blade is manoeuvred over the occiput, particularly if this is in a posterior position. This will help to shift the occiput to a transverse position.

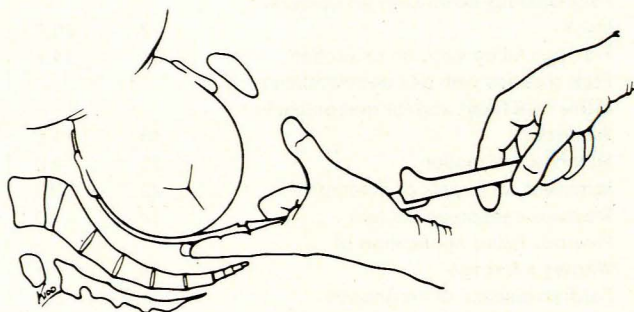


Fig. 2. Anterior blade application.

The direct method of application is an alternative with the advantage of not altering the position of the head during introduction of the blade.

### Application of the posterior blade

The posterior blade is always introduced on the operator's left side to make locking of the blade easier. This blade has no hinge and runs into the shank with a smooth curve, the lowest part being below the axis of the shank and handle. This curve reproduces that of the sacrum and gives the forceps a marked pelvic curve when viewed from the side (Fig. 3). The end of the handle is lightly held in three fingers and the apex of the blade is introduced and guided by two fingers of the other hand (Fig. 4). The thumb of this hand helps to push the blade further into the vagina while the other hand allows the blade to descend gently until it assumes its correct position in front of the sacrum and behind the head. Should full descent not occur, further gentle movement to the right or left may succeed. After full entry, the fingers in the vagina move the blade into its correct position. When both blades are in place they should lock well and easily and be in the exact anteroposterior position. The position of the handles will vary with the station of the fetal head — the higher the head the more horizontal the handles become.

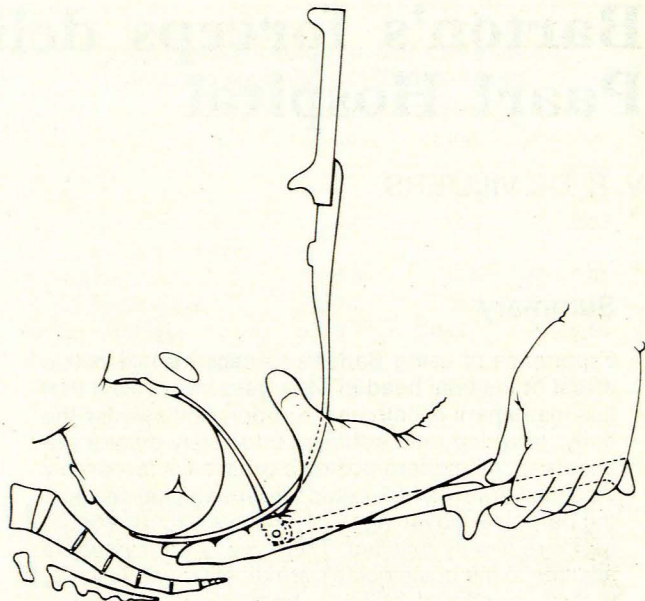


Fig. 3. Posterior blade application.

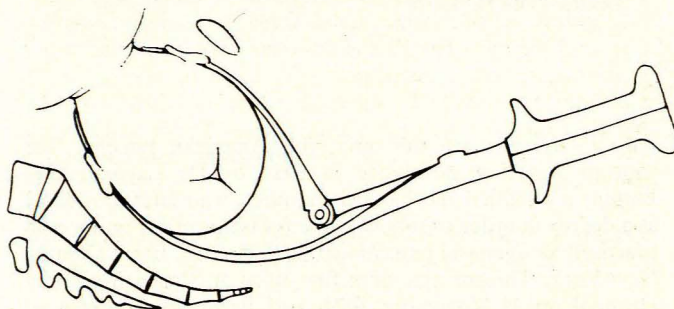


Fig. 4. Application completed.

After locking, the posterior fontanelle should be checked since the sagittal suture should be equidistant from both blades. Difficult locking is the result of a bad application or occasionally because of a large head. The patient should be reassessed and a large fetal head assumed if a biparietal application is confirmed. No further attempts should be made if resistance is encountered in approximating the handles.

### Traction

The axis traction rod increases the ease with which the forceps can be used. It consists of a clamp, rod and traction bar and is attached to the shank between lock and handle. Two joints permit traction to be exerted in the pelvic axis, irrespective of the position or station of the head, and they allow spontaneous rotation of the head during traction. Usually the line of pull is more posterior than expected and this takes the line of force away from the bladder and urethra. Rod traction should always be performed with one hand and excessive force avoided. Traction should be intermittent and co-ordinated with a contraction (Fig. 5).

### Rotation

Usually rotation is spontaneous and occurs with traction. Very often rotation occurs only on the perineum. Occasionally, however, traction may be difficult and artificial rotation should be attempted by dislodging the head upwards. Traction and artificial rotation should never be combined. Rotation should only be attempted

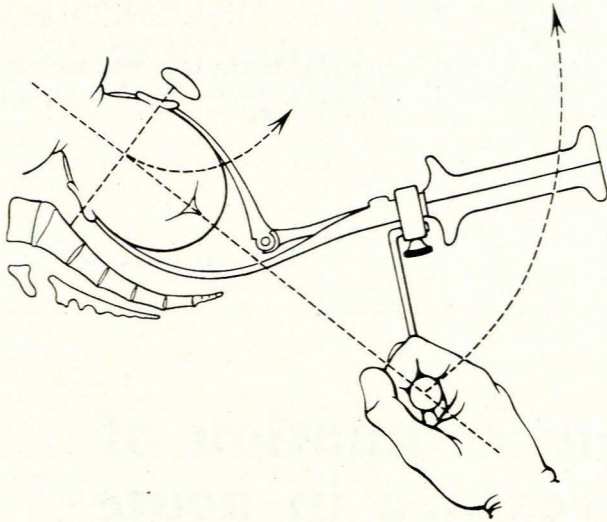


Fig. 5. Posterior traction of Barton's forceps.

using the fingers which are in the vagina and never with the handles. Two fingers are placed behind the posterior blade while three fingers of the other hand support the weight of the forceps.

If, in spite of traction and attempted rotation, the fetal head is immovable, the procedure should be abandoned and a caesarean section performed.

## Results

There was no maternal mortality and no serious morbidity in any of the 348 mothers delivered.

A postpartum haemorrhage rate of 14.7% was recorded. All patients at Paarl Hospital who have either a measured 500 ml postpartum blood loss or a fall of haematocrit reading of 3 points relative to the intrapartum level are regarded as cases of postpartum haemorrhage.

The gross perinatal mortality rate was 11.5/1000 deliveries. Details of the 1 stillbirth and 3 neonatal deaths follow:

1. A 20-year-old woman, para 2, gravida 3, who had had a previous caesarean section, was delivered with Barton's forceps because of prematurity. The male infant weighed 2095 g and the Apgar scores were 10 at 1 minute and 8 at 5 minutes; a maturity assessment was 32 weeks. Neonatal death occurred at 18 hours from respiratory distress syndrome.

2. A 17-year-old primigravida had a failed vacuum extraction for late decelerations of the fetal heart. Application of and extraction with Barton's forceps were uncomplicated and a male infant weighing 3100 g was delivered (Apgar scores 1 at 1 minute and 4 at 5 minutes; maturity index 40 weeks). Neonatal death occurred within 2 hours, probably because of intrapartum anoxia already present at time of application of Barton's forceps.

3. No fetal heart sound could be heard on admission of a 23-year-old primigravida. A fresh male stillbirth of 3300 g was delivered by Barton's forceps. The fetus was meconium-stained and had all the features of postmaturity.

4. A 20-year-old primigravida had a failed Kjelland's forceps application, which caused prolapse of the cord on withdrawal of the forceps blade. Easy Barton's forceps application and extraction was performed and a female infant weighing 3000 g delivered (Apgar scores 1 at 1 minute and 5 at 5 minutes). Neonatal death occurred on day 6 and was probably due to intrapartum anoxia.

None of the 4 perinatal deaths could be attributed directly to the use of Barton's forceps.

## Discussion

Reports from North American obstetricians in the early 1970s incriminated mid-pelvis forceps deliveries as a significant factor

in perinatal mortality and morbidity.<sup>6</sup> Even in the late 1970s Friedman and Sachtleben<sup>7</sup> were still attributing low IQs to the Kjelland's forceps babies monitored for years after their delivery. This unfavourable climate existed when Parry-Jones's<sup>3,4</sup> work was published and probably accounts for the lack of popularity of Barton's forceps. O'Driscoll *et al.*<sup>8</sup> were the most vociferous of critics and reported 27 stillbirths — all these infants had traumatic intracranial haemorrhage and all had been delivered with Kjelland's forceps. Their conclusions were substantiated by the work of paediatricians of Chiswick and Jones,<sup>9</sup> who also reported such stillbirths. Their work, however, led to an improvement of quality control in their unit, and a subsequent publication<sup>10</sup> refuted these poor results and reported 101 babies delivered by Kjelland's forceps with no mortality and no morbidity and no handicapped children assessed at the age of 2 years. Several recent reports<sup>11,12</sup> have also shown that the mid-forceps delivery can be a safe procedure provided that adequate quality control is practised. In particular, Paintin<sup>11</sup> identified 7 definite precautions for any mid-pelvic forceps delivery: (i) no more than one-fifth of the fetal head should be palpable at the pelvic brim; (ii) no excessive moulding of the fetal head should be present; (iii) adequate analgesia — pudendal block analgesia being insufficient for Kjelland's forceps during delivery; (iv) a senior obstetrician should be present during the procedure and, if not carrying out the procedure himself, he should take full responsibility for the result if performance is delegated to a junior; (v) if any doubt exists about the procedure, a trial of forceps should take place in an operating theatre; (vi) if the blades of Kjelland's forceps cannot be applied easily, the procedure should be abandoned; and (vii) traction should be limited to a maximum of three contractions.

I feel that the advantages of Barton's forceps for mid-forceps deliveries have not been adequately praised: the hinged anterior blade is easily applied and caters individually for a varying biparietal diameter; the posterior blade is also easily applied since it has the exact pelvic configuration of the sacral contour, unlike its Kjelland counterpart, which often causes pain and is difficult to apply; the rod action traction guarantees that rotation of the fetal head takes place at its natural station; and, lastly, asynclitism is often corrected at locking of the anterior and posterior blades. Complete pudendal block offers adequate analgesia in all cases. The only controlled series reporting mid-pelvic deliveries mentioned Barton's forceps, but provided no specific breakdown of the results.<sup>5</sup>

Since the obstetric climate now appears to favour mid-pelvic instrumental deliveries provided adequate quality control is practised, I feel strongly that Barton's forceps deserve extensive and thorough double-blind re-evaluation together with other methods such as Kjelland's forceps, manual rotation and vacuum extraction. Training, however, should be by a skilled and senior obstetrician, since poor training perpetuates and aggravates poor results with mid-pelvic forceps deliveries.<sup>13</sup> Has the time not come for all such deliveries to be recorded and re-examined on an accurate video-recording?

## REFERENCES

- Bachman C. The Barton obstetric forceps — a review of its use in fifty-five cases. *Surg Gynecol Obstet* 1927; 45: 805-808.
- Barton LG, Caldwell WE, Studdiford WE. The new obstetric forceps. *Am J Obstet Gynecol* 1928; 15: 16-26.
- Parry-Jones E. Barton's forceps — its use in transverse position of the fetal head. *J Obstet Gynaecol Br Cwlth* 1968; 75: 892-902.
- Parry-Jones E. *Barton's Forceps*. London: Pitmans, 1972.
- Healy DL, Quinn MA, Pepperell RJ. Rotational delivery of the fetus: Kjelland's forceps and two other methods compared. *Br J Obstet Gynaecol* 1982; 89: 501-506.
- Friedman EA, Sachtleben MR. High risk labour. *J Reprod Med* 1971; 7: 28-32.
- Friedman EA, Sachtleben MR. Dysfunctional labour: XII. Longterm effects on infant. *Am J Obstet Gynecol* 1977; 127: 779-783.

8. O'Driscoll K, Meagler D, MacDonald D, Geoghegan F. Traumatic firstborn infants and delivery with obstetric forceps. *Br J Obstet Gynaecol* 1981; **8**: 577-581.
9. Chiswick ML, Jones DK. Kjelland's forceps: association with neonatal morbidity and mortality. *Br Med J* 1979; **1**: 7-9.
10. Chiswick ML. Forceps delivery — neonatal outcome. In: Beard RW, Paintin DB, eds. *Outcome of Obstetric Intervention in Britain* (Proceedings of a scientific meeting of the Royal College of Obstetricians and Gynaecologists). London: RCOG, 1980: 37.
11. Paintin DB. Mid-cavity forceps delivery. *Br J Obstet Gynaecol* 1982; **89**: 495-496.
12. Cardozo LD, Gibb DMF, Studd JWW, Cooper DJ. Should we abandon Kjelland's forceps? *Br Med J* 1983; **387**: 315-317.
13. Healey DL, Laufer LE. Survey of obstetric forceps in North America in 1981. *Am J Obstet Gynecol* 1985; **151**: 54-58.

# Echophonocardiographic estimation of pulmonary capillary pressure in acute myocardial infarction

J. GOURASSAS, J. M. BENNETT, S. KONSTANTINIDES

## Summary

Non-invasive estimation of pulmonary capillary wedge (PCW) pressure by an echophonocardiographic technique is reported. The ratio of time interval from the Q-wave to the C-point (echocardiogram) (Q-C) and from aortic closing (A2) to the E-point (A2-E) correlated well with the measured PCW pressure ( $r = 0.89$ ;  $P = 0.001$ ). When these two intervals were subtracted (A2-E)-(Q-C) the correlation was  $r = -0.90$  ( $P = 0.001$ ).

*S Afr Med J* 1988; **73**: 178-180.

The mean pulmonary capillary wedge (PCW) pressure reflects the mean left atrial pressure and left ventricular filling pressure in the absence of mitral stenosis or venous occlusive diseases of the lung. Management of patients with myocardial infarction frequently requires measurement of PCW by right heart catheterisation with a balloon-tipped flow-directed catheter.<sup>1</sup> This is an expensive procedure and may occasionally be hazardous.<sup>2</sup> Therefore a non-invasive and safe but reliable method would be helpful to determine PCW pressure in some patients.

In patients with mitral stenosis, it was shown that PCW pressure or left atrial pressure varied inversely with the interval between aortic valve closure (A2) and the opening snap (A2-OS)<sup>3</sup> and also directly with the interval between the onset of

QRS complex and the first high-frequency component of first heart sound (Q-MI).<sup>4</sup> These correlations improved significantly when the difference or the ratio of these intervals were compared with PCW or mean left atrial pressure.

These two indices, determined by echocardiography (since it provides visible evidence of closure and opening of mitral valve and obviates the need for an audible opening snap and first heart sound), were applied to predict PCW pressure in different conditions such as mitral regurgitation<sup>5</sup> and in a very limited number of patients with ischaemic heart diseases.<sup>6,7</sup>

To test this technique further in patients with acute myocardial infarction in the setting of a coronary care unit, these ECG, phonographic and echocardiographic intervals were evaluated in relation to PCW pressure as measured by balloon-tipped flow-directed catheters.

## Patients and methods

Forty-one patients with an acute myocardial infarction who required bedside invasive haemodynamic monitoring with a flow-directed balloon-tipped catheter were examined.

The criteria for selection were: (i) absence of major arrhythmias, left bundle-branch block and first-degree atrioventricular block (these conditions cause a delay in the onset of left ventricular contraction and thus influence the electromechanical measurements independently); (ii) valvular lesions (aortic and mitral regurgitation) were excluded for the same reason; and (iii) availability of technically satisfactory echophonocardiographic tracings.

## PCW pressure measurements

PCW pressure measured by a balloon-tipped catheter was compared with the information derived from non-invasive data obtained simultaneously in all patients.

In all patients the mean PCW pressure was measured by a balloon flotation catheter inserted into the pulmonary artery via a subclavian vein according to a standard technique.<sup>1</sup> The position was verified by waveform and chest radiography. Special attention was paid to avoid overdamping of the pressures. The readings were recorded directly by looking at the electronic signal display.

Cardiology Division, Department of Medicine, University of Pretoria and H. F. Verwoerd Hospital, Pretoria

J. GOURASSAS, DIP. IN MED. (ATHENS)

J. M. BENNETT, M.B. CH.B., M.MED. (INT.)

S. KONSTANTINIDES, DIP. IN MED. (THESSALONIKA)