

Staging of endometrial cancer by hysteroscopy

H. S. CRONJÉ, C. J. C. DEALE

Summary

Twenty-four consecutive patients with endometrial adenocarcinoma were staged pre-operatively by hysteroscopy and by fractional dilatation and curettage (D & C) to evaluate the accuracy of each method in differentiating between International Federation of Gynaecology and Obstetrics stage I and II cancer. Hysteroscopic staging was correct in 16 patients (69,6%) and incorrect in 7 (30,4%). In 1 additional patient hysteroscopy failed to diagnose the endometrial cancer. D & C staged 16 patients correctly (66,7%) and 8 incorrectly (33,3%). Where the hysteroscopic and D & C stagings correlated, the staging was correct in 16 patients (75%) and incorrect in 4 (25%). Therefore hysteroscopy and D & C are of similar value in the pre-operative staging of endometrial adenocarcinoma and their combined use has a slight advantage.

S Afr Med J 1988; 73: 716-717.

Hysteroscopy is a relatively new development in gynaecology and its usefulness in the diagnosis and localisation of endometrial cancer has been inadequately evaluated. Diagnostic fractional dilatation and curettage (D & C) is routinely performed in the work-up of endometrial cancer, but it is a blind procedure with inherent inadequacies. A lesion may pass undiagnosed by D & C or its localisation may be misinterpreted. Hysteroscopy may improve the gynaecologist's ability to diagnose and localise the lesion accurately.

A study was undertaken to evaluate the accuracy of hysteroscopy in localising endometrial cancer in order to differentiate between International Federation of Gynaecology and Obstetrics (FIGO) stage I and II disease.

Patients and methods

Thirty-seven consecutive patients with proven or suspected endometrial adenocarcinoma were prospectively examined with a hysteroscope over a period of 24 months. Of these, 7 patients did not have endometrial cancer, 5 had mixed Müllerian mesodermal tumours and 1 hysteroscopy failed because of uterine perforation in a patient with stage IV adenocarcinoma of the endometrium. The remaining 24 patients with histologically proven adenocarcinoma were included in this analysis.

Department of Obstetrics and Gynaecology, University of Stellenbosch and Tygerberg Hospital, Parowvallei, CP

H. S. CRONJÉ, M.MED. (O. ET G.), F.C.O.G. (S.A.), M.D. (Present address: Department of Obstetrics and Gynaecology, University of the Orange Free State, Bloemfontein)

C. J. C. DEALE, M.MED. (O. ET G.), F.C.O.G. (S.A.), M.MED. (ANAT. PATH.)

All hysteroscopic procedures and fractional D & Cs were done by one of the authors (H.S.C.) and the histology was reviewed by the other (C.J.C.D.). The hysteroscopy was done immediately before D & C. If a patient had had a previous D & C, the D & C was repeated and the second staging by fractional D & C was used in this study. Hysteroscopy was performed with a Storz hysteroscope No. 26165A with saline or Dextran 40% distension of the uterus. The aim was to localise the inferior margin of the tumour and to determine whether the tumour extended to the endocervix or not.

After hysteroscopy and D & C, all patients underwent total abdominal hysterectomy and bilateral salpingo-oophorectomy. The uterine specimens were carefully examined for endocervical involvement of endometrial adenocarcinoma. When infiltration of endometrial cancer was present within the endocervix the patient was classified as having stage II disease and those without infiltration were classed as stage I. The final histological staging was then compared with the previous hysteroscopic staging and the staging at D & C.

Results

The hysteroscopic staging was correct in 16 of 23 patients (69,6%) and incorrect in 7 (30,4%). In 1 additional patient the endometrial adenocarcinoma was not diagnosed at hysteroscopy. The staging at D & C was also correct in 16 of 24 patients (66,7%) and incorrect in 8 (33,3%) (Table I). In 5 patients the hysteroscopy was done elsewhere without a D & C first or without previous knowledge of the diagnosis. In these 5 patients the hysteroscopic staging was correct in only 2 and D & C staging correct in 4. When the hysteroscopic and D & C staging were similar, both were correct in 12 of 16 patients (75%) and incorrect in 4 (25%).

TABLE I. PRE-OPERATIVE STAGING AT HYSTEROSCOPY AND FRACTIONAL D & C v. FINAL POSTOPERATIVE HISTOLOGICAL STAGING

	Final staging	
	FIGO I	FIGO II
Hysteroscopy		
Correct	14*	2
Incorrect	3	4†
D & C		
Correct	13*	3
Incorrect	4	4

* Including 2 patients with stage IV disease but without endocervical involvement of tumour.

† In 1 additional patient hysteroscopy failed to diagnose the carcinoma.

Discussion

Cervical involvement may vary between free tumour cells in the endocervical canal and endometrial infiltration of the endocervix.¹ In this study only endometrial infiltration was used as a criterion for endocervical involvement of endometrial cancer. Free tumour cells can be found within the endocervical mucus but are unlikely to cause spread of disease.

Several pitfalls should be avoided in the pre-operative staging of endometrial cancer. It was difficult to locate the endocervix in many patients both at hysteroscopy and D & C. In postmenopausal women the uterus may be small (± 6 cm in total length) but with a relatively long endocervical canal (± 4 cm). On the other hand, a uterus of 10 cm length may have an endocervical canal of only 3 cm. In some patients the endocervical ring was incompetent and extremely difficult to locate both by hysteroscopy and D & C. In rare cases it was virtually impossible to decide where the junction between endocervix and endometrium was.

A second problem at hysteroscopy was the localisation of the inferior margin of the tumour. Well-differentiated exophytic lesions were easily located (Fig. 1). Poorly differentiated lesions, which tended to infiltrate diffusely into neighbouring tissues, were difficult to locate. In these cases, D & C may be superior in staging.

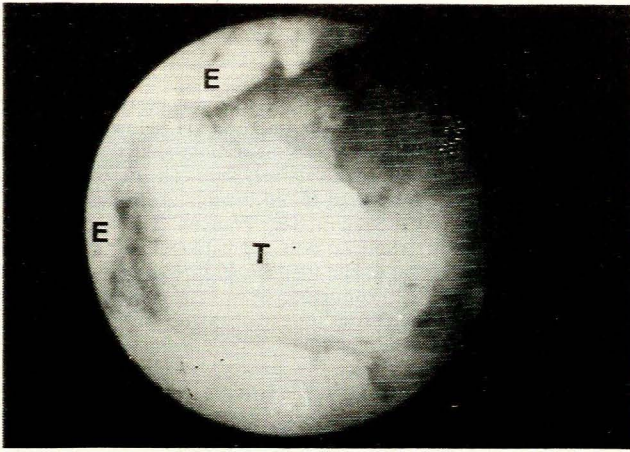


Fig. 1. An exophytic endometrial adenocarcinoma (T) (centre) seen through the hysteroscope just above the endocervix (E) (peripherally on left).

Bleeding is another problem encountered at hysteroscopy. This may be a major problem during diagnosis when the whole uterine cavity has to be visualised. For staging only the inferior margin of the tumour need be seen. This was not difficult even in patients with active bleeding.

Is hysteroscopy safe in patients with endometrial carcinoma? Between 1976 and 1979 hysteroscopy was used in certain

centres and considered safe although not of much value.²⁻⁴ Tumour cells do spread spontaneously through the fallopian tubes⁵ and procedures such as hysteroscopy, hystero-graphy and even D & C may exaggerate this process. No evidence could be found that these procedures increase the risk for metastases, even though D & C may cause dissemination of tumour cells into the blood stream.⁶⁻⁸ In this study, the distension pressure at hysteroscopy was always kept at 70 mmHg or below which is well below the official maximum of 120 mmHg.⁸

In conclusion, hysteroscopy and D & C are of similar value in the staging of endometrial cancer, with a sensitivity of about 67%. With combined use the sensitivity rises slightly to 75% when the staging of both methods correlated. These figures are lower than expected and confirm that the correct pre-operative staging of endometrial cancer is an extremely difficult procedure. The Hamou microhysteroscope is claimed to be more sensitive than the conventional hysteroscope and fractional D & C,⁹ but experience with this relatively new instrument is limited.

In view of the inadequacy of these procedures, pre-hysterectomy treatment with radium should be omitted and a fresh operative specimen carefully scrutinised for the final histological typing of the lesion, depth of myometrial invasion, cervical involvement by the lesion, and metastases to tubes, ovaries and other sites.¹⁰

REFERENCES

1. Kader NRD, Kohorn EI, Livolsi VA, Kapp DS. Histologic variants of cervical involvement by endometrial carcinoma. *Obstet Gynecol* 1982; **59**: 85-92.
2. Anderson B, Marchant DJ, Munzenrider JE *et al.* Routine noninvasive hysteroscopy in the evaluation and treatment of endometrial carcinoma. *Gynecol Oncol* 1976; **4**: 354-367.
3. Tak WK, Anderson B, Vardi JR *et al.* Myometrial invasion and hystero-graphy in endometrial carcinoma. *Obstet Gynecol* 1977; **50**: 159-165.
4. Edinger DD, Watring WG, Anderson B. Hystero-graphy as a diagnostic technique in endometrial carcinoma. *Clin Obstet Gynecol* 1979; **22**: 729-735.
5. Dahle T. Transtubal spread of tumor cells in carcinoma of the body of the uterus. *Surg Gynecol Obstet* 1956; **103**: 332-336.
6. Roberts S, Long L, Jonasson O *et al.* The isolation of cancer cells from the blood stream during uterine curettage. *Surg Gynecol Obstet* 1960; **111**: 3-11.
7. Merrill JA. Dissemination of cancer cells during surgical curettage. *Am Surg* 1963; **29**: 206-209.
8. Sugimoto O. Hysteroscopic diagnosis of endometrial carcinoma. *Am J Obstet Gynecol* 1975; **121**: 105-113.
9. Goldberg GL, Altaras MM, Levin V, Bloch B. Microhysteroscopy in evaluation of the endocervix in endometrial carcinoma. *Gynecol Oncol* 1986; **24**: 189-193.
10. Du Toit JP. The prognostic significance of adenosquamous carcinoma of the endometrium: a clinico-pathological analysis. M.D. thesis, University of Stellenbosch, 1985, p. 238.