

# Lupus nephritis

## Part I. Histopathological classification, activity and chronicity scores

W. D. BATES, A.-M. HALLAND, R. D. TRIBE, D. J. ROSSOUW

### Summary

Renal biopsy has made a major contribution to the understanding and management of patients with lupus nephritis. In a 5-year retrospective study the renal morphology of 55 biopsies from 51 patients with lupus nephritis was classified according to World Health Organisation criteria. In addition, semi-quantitative activity and chronicity scores were documented. The findings were similar to series from other parts of the world. Of the biopsies reviewed, 6 were class II, 13 class III, 32 class IV and 4 class V. In situations of overlap, segmental proliferative features determined the class to which a biopsy specimen was assigned. Twenty-five of the patients, all WHO class IV, showed activity scores in the severe range. Most of the activity score features were common and easily recognised but necrotising angiitis was only seen in 1 patient. Haematoxylin bodies were difficult to document and the nature and value of the haematoxylin body is questioned.

S Afr Med J 1991; 79: 256-259.

A recent large Australian series<sup>1</sup> on lupus nephritis emphasises the value of renal biopsy together with urinalysis as an accurate guide to activity and progression of disease and as the major guide to treatment. In view of this and as there has been little detailed documentation of lupus nephritis in southern Africa,<sup>2-5</sup> a retrospective study of lupus nephritis at Tygerberg Hospital was undertaken using recent developments in the histological classification as well as the quantification of activity and chronicity indices. The aim was to determine whether the histological features of lupus nephritis in our centre were comparable to other studies, to provide an accepted basis for clinicopathological correlation and comparison, and to add our experience of lupus nephritis to the growing number of publications on this important disease in southern Africa.

### Patients and methods

The morphological material from 51 patients who underwent renal biopsies for clinically significant lupus nephritis from 1983 to 1987 was reviewed. All biopsies were assigned to World Health Organisation classes, and activity and chronicity scores were determined. In 1 patient only, autopsy tissue was examined, since fulminant disease precluded a biopsy during life. Four patients underwent two biopsies each, providing a total of 55 specimens. Patients were classified according to their latest biopsy. All patients fulfilled the 1982 American

Rheumatism Association (ARA) criteria for systemic lupus erythematosus (SLE)<sup>6</sup> — 47 were women (39 coloured, 5 white, 3 black) and 4 were men (2 coloured, 2 white).

Renal biopsy material for light and electron microscopy was initially fixed in 2,5% glutaraldehyde in 0,1M phosphate buffer and then halved under a dissecting microscope. Serial 2-3  $\mu$ m sections were stained with haematoxylin and eosin, Alcian blue, periodic acid-Schiff, periodic acid-methenamine silver, Masson trichrome and Verhoeff-Van Gieson stains. Electron microscopy (EM) specimens were post-fixed in osmium tetroxide embedded in Spurr's resin. Sections were stained with uranyl acetate and lead nitrate. Material for immunofluorescence was received on saline and then frozen. Cryostat sections were cut and labelled for IgA, IgG, IgM, C3 and fibrinogen.

The WHO classification<sup>7</sup> was used: class I — normal at light microscopic level; class II — mesangial; class III — focal proliferative; class IV — diffuse proliferative; and class V — membranous glomerulonephritis. All segmental lesions were classified as focal or diffuse proliferative. Some of these classes are illustrated in Fig. 1. Severity of disease does not correlate entirely with increasing class, since I, II and V are the milder forms of disease. Classes III and IV are the more severe forms with at least segmental proliferation in less than or more than 80% of glomeruli, respectively. Biopsies were then scored semi-quantitatively using a table as proposed by Morel-Maroger *et al.*<sup>8</sup> and modified by Leaker *et al.*<sup>1</sup> Ten morphological changes constitute the activity score: endocapillary proliferation; nuclear debris; wire loops; hyaline thrombi; interstitial inflammation; tubular epithelial lesions; fibrinoid necrosis; epithelial crescents; haematoxylin (haematoxyphil) bodies; and necrotising angiitis. Several of these features are illustrated in Fig. 2. The histological features were scored on a scale of 0 - 3 denoting the absence or mild, moderate or prominent presence, respectively, of the particular feature. The scores of the last four features on the activity index are doubled to weight them as they are believed to be more significant markers of activity.<sup>8</sup> The maximum total score is 42. Class IV lesions were then divided into class IV(a), where the activity score was 8 or less, while scores of 9 or more were placed in class IV(b).<sup>1</sup>

The two features in the chronicity score are glomerular sclerosis and interstitial sclerosis. The demarcation lines between mild, moderate and severe glomerular sclerosis are 30% and 80% involvement. The chronicity score is therefore out of a maximum of 6.

### Results

Fig. 3 shows the age, race and sex of the patients. The well-documented dominance of female patients below the age of 40 years is seen, as well as the prominence of coloured patients in all decades. The rate of biopsied lupus nephritis per 1000 patients admitted to the medical wards during the study period was calculated for males and females of each racial group. The rates for the females were as follows: coloured 1,4; black 0,85; white 0,33. The WHO classes of the latest biopsies in each of the 51 patients were as follows: class I — 0; class II

Departments of Anatomical Pathology and Internal Medicine, University of Stellenbosch and Tygerberg Hospital, Parowallei, CP

W. D. BATES, M. MED. (ANAT. PATH.)

A.-M. HALLAND, M. MED. (INT.), F.C.P. (S.A.)

R. D. TRIBE, F.C.P. (S.A.)

D. J. ROSSOUW, M. MED. (ANAT. PATH.), PH.D.



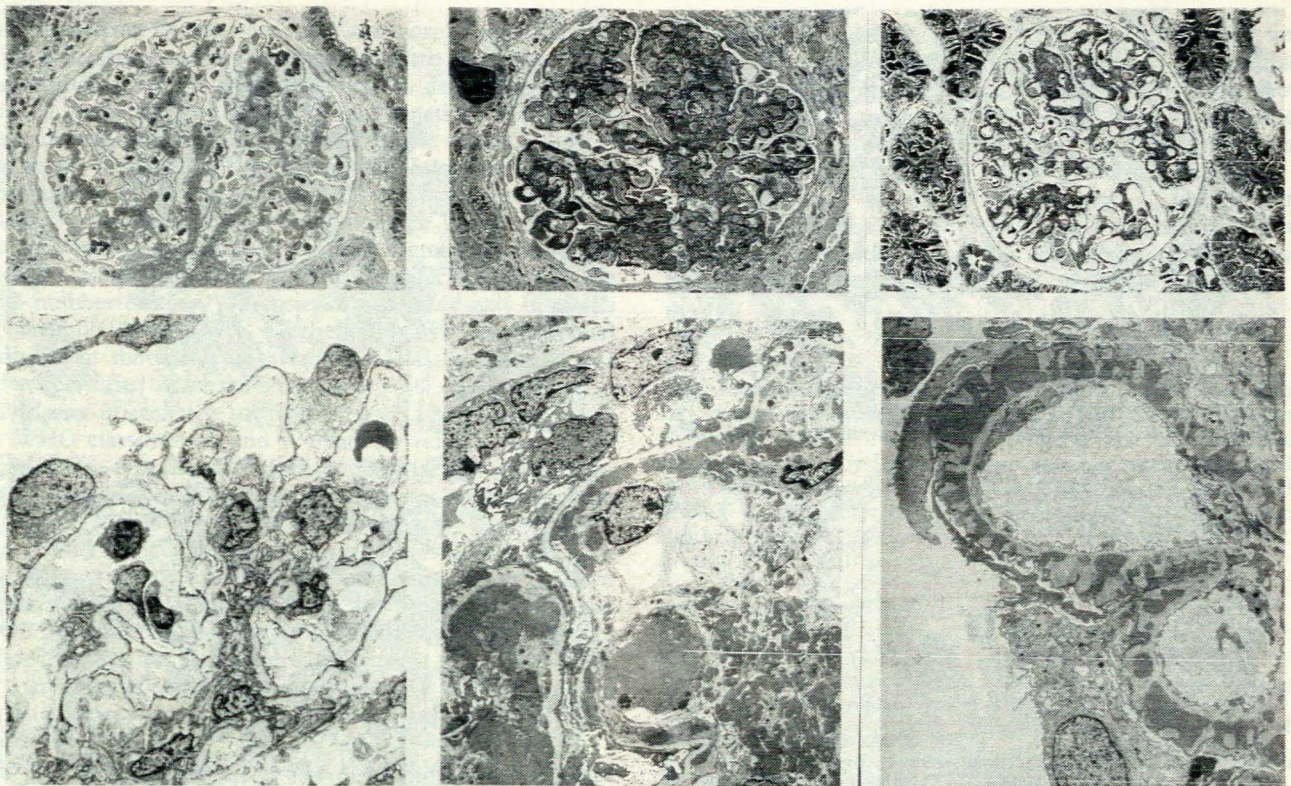


Fig. 1. WHO classification of lupus nephritis — light and electron microscopic features of some of the classes. Left: class II — mesangial; whole glomerulus (above) shows enlarged mesangial areas with normal peripheral capillary lumina. Ultrastructure (below) shows Bowman's capsule (top left) with peripheral capillaries (below). The mesangium is prominent with increased cellularity. Deposits present in the mesangium are not easily seen. Centre: class IV — diffuse proliferative; the glomerulus (above) appears irregular with thick wire-loop-type capillary wall lesions especially in lower left quadrant. Capillary lumina show narrowing and obliteration. Ultrastructure (below) shows large deposits especially subendothelially but also mesangial, subepithelial and in capillary lumina. Right: class V — membranous; the glomerulus (above) is relatively symmetrical with patent capillary lumina and thickened capillary walls. Ultrastructure (below) shows the dark subepithelial deposits alternating with lighter basement membrane-like material ('spikes'), which in places incorporates the deposits.

— 5; class III — 12; class IV(a) — 7; class IV(b) — 25; and class V — 2. The majority of patients had the severest form of the disease (class IV) and within that class most showed high activity scores  $> 8$  (class IV(b)). Table I compares the relative frequency of WHO classes from series from all five continents over a 20-year period. The incidence of class IV is remarkably constant, being also the commonest class in all 5 series. Activity and chronicity scores in the various WHO classes are shown in Fig. 4. Classes II and V tended to show low activity scores with class III a little higher. Class IV was characterised by prominent activity scores with the majority being above 8, making class IV(b) the largest single group. The pattern of chronicity scores was less clear, with classes III, IV(a) and IV(b) tending to show similar ranges of figures. Immunofluorescence positivity in glomeruli was as follows: IgA — 24/40 (60%); IgG — 33/40 (82.5%); IgM — 22/36 (61%); C3 — 28/39 (72%); and fibrinogen — 11/40 (27.5%).

Four patients underwent second renal biopsies. The histological pattern had changed from class V to class IV(b) in 2 and from III to IV(a) in 1. The fourth patient changed from class II to class III. Activity and chronicity scores increased markedly in all 4 patients.

## Discussion

The WHO classification scheme for lupus nephritis<sup>7</sup> is at present accepted world-wide and provides a standard that enables comparison to be made between clinical studies. Since 1973 at least four series of southern African patients with SLE

TABLE I. RELATIVE FREQUENCIES OF WHO CLASSES IN LUPUS NEPHRITIS

Author	No. of patients	WHO classes (%)		
		I, II, III	IV	V
Baldwin <i>et al.</i> <sup>9</sup> (1970) (USA)	52	27	46	27
Sinniah and Feng <sup>10</sup> (1976) (Singapore)	56	27	60	13
Cameron <i>et al.</i> <sup>11</sup> (1979) (UK)	71	30	55	14
Leaker <i>et al.</i> <sup>1</sup> (1987) (Australia)	135	27	58	15
This study (RSA)	51	33	63	4

have been documented.<sup>2-5</sup> All included patients with lupus nephritis, but while the series from Natal<sup>3</sup> gave a detailed list of renal histological changes in its patients, the others gave little renal morphological data. Moreover, none of these studies has provided a detailed correlation of both clinical and histological manifestations using the WHO classification. The relative frequencies of the different histological classes demonstrated in our study is comparable with that from other continents (Table I),<sup>1,9-11</sup> with 50-60% of biopsies demonstrating class IV disease on histological examination. The variations may be due in part to varied biopsy criteria, since some groups



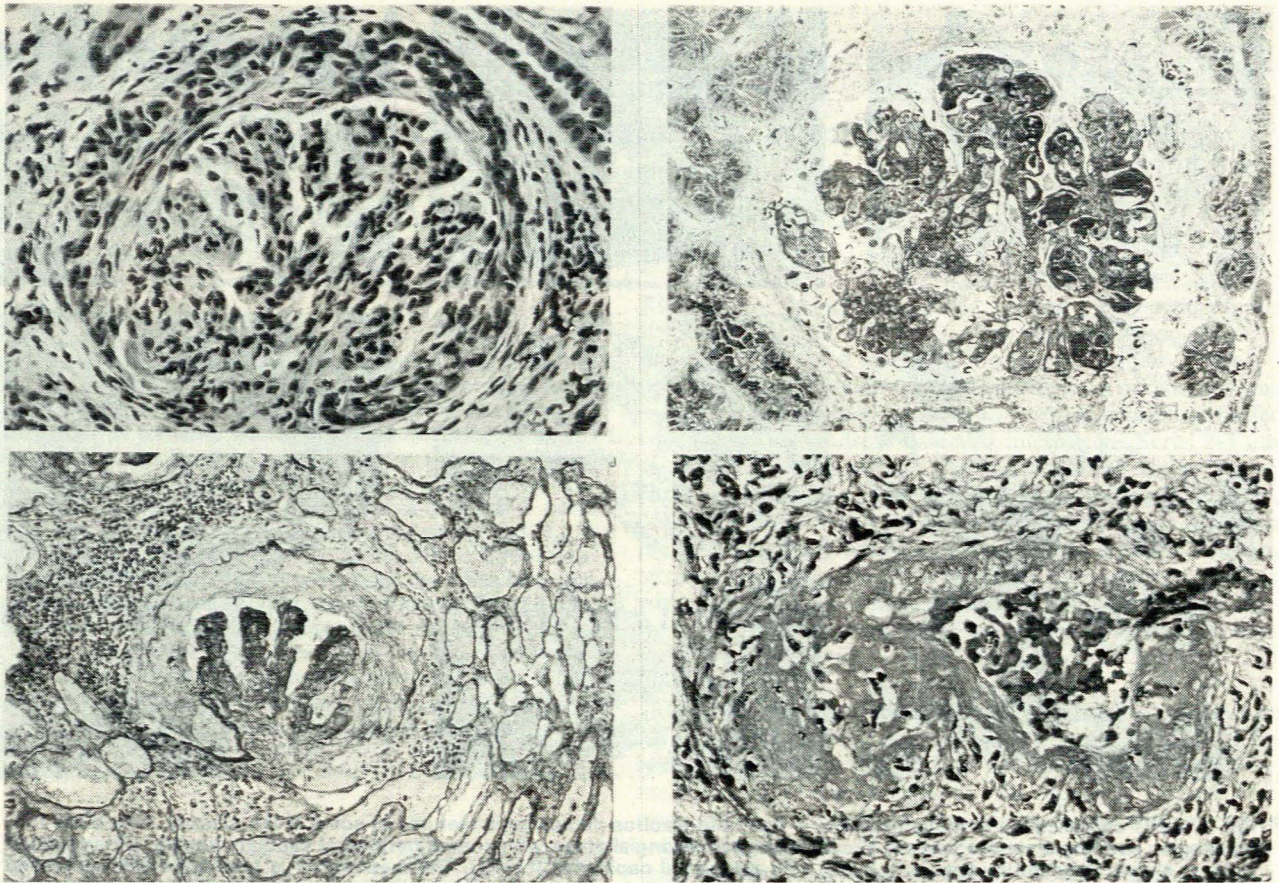


Fig. 2. Composite microphotograph to illustrate some morphological features used in the activity score. Top left: cellular proliferation in the glomerulus surrounded by a cellular crescent. Bottom left: a silver stain outlines a disrupted Bowman's capsule and the glomerular tuft with a crescent between them. Prominent interstitial inflammatory infiltrate is present in the left upper area. Top right: hyaline thrombi in capillary lumina and thickened capillary walls are prominent in this proliferative glomerulus. Bottom right: necrotising angiitis with fibrinoid necrosis in a vessel in the renal interstitium.

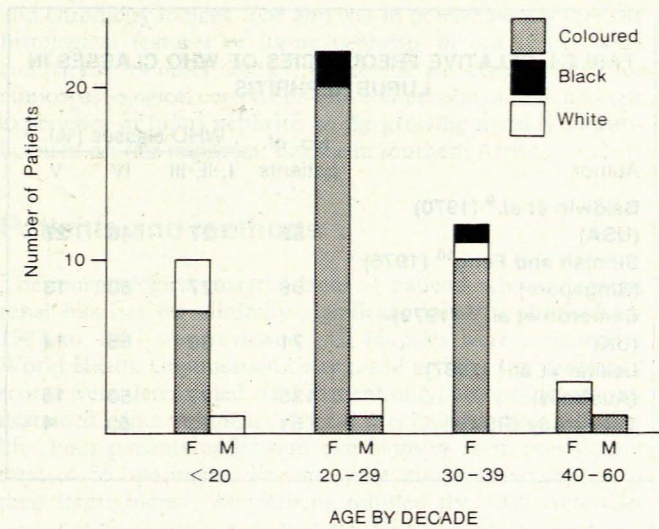


Fig. 3. Histogram to illustrate the spectrum of age, race and sex in the patient population.

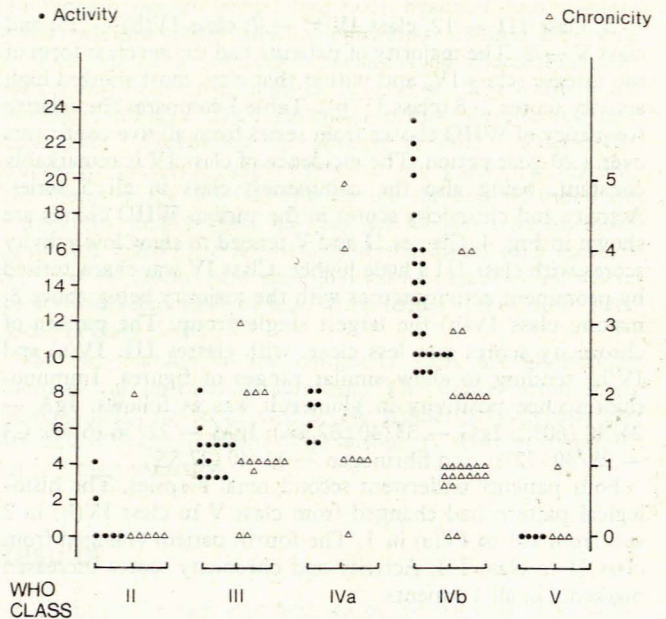


Fig. 4. Distribution of activity and chronicity scores in histological classes.

biopsy only patients with clinical evidence of renal disease and others all patients with SLE. The greater range in the membranous pattern (class V) may reflect different approaches to mixed and pure forms of disease.

SLE, and more specifically lupus nephritis, have been found to be more common in France, the UK and the USA in

patients other than whites,<sup>11-13</sup> but the situation in South Africa is still not clear. Our study supports the previous findings from this region<sup>2</sup> that the disease is disproportionately common in the coloured hospital patient.



As pointed out by many authors,<sup>14</sup> the morphological classification is arbitrary and overlapping forms are seen. The WHO classification presents various options for dealing with cases showing features of two categories (combinations of proliferative and membranous lesions being the most common overlap situation).<sup>15</sup> Banfi *et al.*<sup>15</sup> created class VI in which to place combinations of class V and class III or IV. In our study we followed an option used by, among others, Leaker *et al.*<sup>1</sup> In this approach all biopsies containing segmental lesions are classified in either the focal or diffuse proliferative group. The small number of class V biopsies in our study may be partly explained by this approach. Furthermore, 2 patients with class V disease at the outset transformed to class IV at re-biopsy and are classified under the latter class.

The semi-quantitative scoring system is a helpful adjunct to the WHO classification and is relatively reliable and reproducible. This type of system was originally described by Pirani *et al.*<sup>16</sup> but the system used in this study was according to the method of Morel-Maroger *et al.*<sup>8</sup> as used by Leaker *et al.*<sup>1</sup> These methods have shown a poor prognosis for patients with high activity scores or advanced chronic disease.<sup>1,8</sup> It has been shown that active treatment brings about rapid resolution of active lesions but that chronic lesions progress despite therapy.<sup>1,8</sup> Patients with inactive or chronic lesions may thus be spared unnecessary immunosuppressive treatment — an important consideration, since sepsis remains a major cause of death.<sup>1,11</sup>

As McCluskey<sup>14</sup> notes, the list of glomerular changes seen in lupus nephritis is virtually a catalogue of glomerular abnormalities. The activity score includes features noted to be indicative of active glomerular damage, and some of these factors are probably interrelated.<sup>17</sup>

The haematoxylin body was the only activity score feature that provided major difficulties, since we could not confirm its presence or absence with any confidence. The major review of lupus nephritis morphology by McCluskey<sup>14</sup> in 1970 indicated that these bodies were so uncommon, at least in a form sufficiently recognisable even to seasoned observers, as to be of little value. Our experience concurs with this assessment. It appears unlikely that a morphological feature can survive and remain useful unless it is easily recognised on routine stains or has distinctive histochemical, immunological or ultrastructural features, none of which is shown by the haematoxylin body. The widely used scoring system of the National Institutes of Health, Bethesda, Maryland USA,<sup>18</sup> does not have a category for haematoxylin bodies and thereby avoids these uncertainties.

Necrotising angiitis is rare in our experience (only shown in the autopsy case), and difficulties with haematoxylin bodies have already been discussed. The remaining 8 features in the activity table were relatively common, especially in class IV.

It is not easy to compare activity and chronicity scores between series, since slightly different systems have been used,

but comparing with Banfi *et al.*,<sup>15</sup> the extent of activity and chronicity changes in our patients appears similar. For example, our worst group on histological examination did not show more advanced features than their series. Our immunofluorescent figures are similar to other series<sup>10-12,15</sup> and confirm the frequent presence of especially IgG and C3 in the deposits.

Since this study was undertaken, re-biopsy is being more frequently employed in our institution and it seems likely that the documented incidence of transformations will increase. Transformations were noted in the re-biopsies of 4 patients.

We thank the medical illustration unit of the Bureau for Medical and Dental Education of the University of Stellenbosch and Tygerberg Hospital for help with figures and the Diagnostic Electron Microscopy Laboratory for assistance with photographs. We also thank Mrs L. L. Eygelaar for typing the manuscript. W.D.B. is in receipt of a short-term South African Medical Research Council grant.

#### REFERENCES

1. Leaker B, Fairley KF, Dowling J, Kincaid-Smith P. Lupus nephritis: clinical and pathological correlation. *Q J Med* 1987; 62: 163-179.
2. Jessop S, Meyers OL. Systemic lupus erythematosus in Cape Town. *S Afr Med J* 1973; 47: 222-225.
3. Seedat YK, Pudifin D. Systemic lupus erythematosus in black and Indian patients in Natal. *S Afr Med J* 1977; 51: 335-337.
4. Taylor HG, Stein CM. Systemic lupus erythematosus in Zimbabwe. *Ann Rheum Dis* 1986; 45: 645-648.
5. Dessein PHMC, Gledhill RF, Rossouw DS. Systemic lupus erythematosus in black South Africans. *S Afr Med J* 1988; 74: 387-389.
6. Tan EM, Cohen AS, Fries JF *et al.* The 1982 revised criteria for the classification of systemic lupus erythematosus. *Arthritis Rheum* 1982; 25: 1271-1277.
7. Churg J, Sobin LH. *Renal Disease-Classification and Atlas of Glomerular Disease*. Tokyo: Igaku-Shoin, 1982: 127-149.
8. Morel-Maroger L, Mery JP, Droz D *et al.* The course of lupus nephritis: contribution of serial renal biopsies. *Adv Nephrology* 1972; 6: 79-118.
9. Baldwin DS, Lowenstein J, Rothfield NF, Gallo G, McCluskey RT. The clinical course of the proliferative and membranous forms of lupus nephritis. *Ann Intern Med* 1970; 73: 929-942.
10. Sinniah R, Feng PH. Lupus nephritis: correlation between light, electron microscopic and immunofluorescent findings and renal function. *Clin Nephrol* 1976; 6: 340-351.
11. Cameron JS, Turner DR, Ogg CS *et al.* Systemic lupus with nephritis: a long-term study. *Q J Med* 1979; 189: 1-24.
12. Hill GS, Hinglais N, Tron F, Bach JF. Systemic lupus erythematosus: morphologic correlations with immunologic and clinical data at the time of biopsy. *Am J Med* 1978; 64: 61-79.
13. Studenski S, Allen NB, Caldwell DS, Rice JR, Polisson RP. Survival in systemic lupus erythematosus. *Arthritis Rheum* 1987; 30: 1326-1332.
14. McCluskey RT. Lupus nephritis. *Pathol Annu* 1970; 5: 125-144.
15. Banfi G, Mazzucco G, Di Belgiojoso GB *et al.* Morphological parameters in lupus nephritis: their relevance for classification and relationship with clinical and histological findings and outcome. *Q J Med* 1985; 217: 153-168.
16. Pirani CL, Pollak VE, Schwartz FD. The reproducibility of semi-quantitative analyses of renal histology. *Nephron* 1964; 1: 230-237.
17. Hill GS. Systemic lupus erythematosus. In: Heptinstall RH, ed. *Pathology of the Kidney*. 3rd ed. Boston: Little, Brown, 1983: 839-906.
18. Austin HA, Muenz LR, Joyce KM *et al.* Prognostic factors in lupus nephritis: contribution of renal histologic data. *Am J Med* 1983; 75: 382-391.