



5. Cook JM. *The Persians*. London: Folio Society, 1983.
6. Sigerist HE. *A History of Medicine*. Vol. I. New York: Oxford University Press, 1955: 409-494.
7. Saggs HWF. *The Babylonians*. London: Folio Society, 1988: 379-408.
8. Heessel NP. Diagnosis, divination and disease. In: Horstmanshoff HFJ, Stol M, eds. *Magic and Rationality in Ancient Near Eastern and Graeco-Roman Medicine*. Leiden: Brill, 2004: 97-114.
9. Herodotus 3. 129, 130. *The Persian Wars* (transl. by Rawlinson G). New York: Modern Library Edition, 1942.
10. Cook JM. *The Persians*. London: Folio Society, 1983: 25-29.
11. Van der Eijk PJ. Divination, prognosis and prophylaxis. In: Horstmanshoff HFJ, Stol M, eds. *Magic and Rationality in Ancient Near Eastern and Graeco-Roman Medicine*. Leiden: Brill, 2004: 187-218.
12. Geller MJ. West meets East: Early Greek and Babylonian diagnosis. In: Horstmanshoff HFJ, Stol M, eds. *Magic and Rationality in Ancient Near Eastern and Graeco-Roman Medicine*. Leiden: Brill, 2004: 11-61.
13. Geller MJ. Bloodletting in Babylonia. In: Horstmanshoff HFJ, Stol M, eds. *Magic and Rationality in Ancient Near Eastern and Graeco-Roman Medicine*. Leiden: Brill, 2004: 305-324.
14. Stol M. An Assyriologist reads Hippocrates. In: Horstmanshoff HFJ, Stol M, eds. *Magic and Rationality in Ancient Near Eastern and Graeco-Roman Medicine*. Leiden: Brill, 2004: 63-77.
15. Kinnier-Wilson JV, Reynolds EH. Translation and analysis of a cuneiform text forming part of a Babylonian treatise on epilepsy. *Med Hist* 1990; **34**: 185-198.
16. Thomas R. Greek medicine and Babylonian wisdom. In: Horstmanshoff HFJ, Stol M, eds. *Magic and Rationality in Ancient Near Eastern and Graeco-Roman Medicine*. Leiden: Brill, 2004: 175-186.

CLINICAL IMAGES

Unusual midline neck mass

H B Louw, M Pienaar, G Dekker, S Andronikou, S Hlongwane, K Naidu

A 39-year-old woman presented to a day hospital with a midline neck mass that had been evident for 3 - 4 years. Clinically the patient was euthyroid.

Ultrasound showed a solid midline neck mass. Fine-needle aspiration cytology was performed, but was inconclusive and the patient was referred to a tertiary institution for further imaging.

A computed tomography (CT) scan of the neck revealed a well-circumscribed midline neck mass, anterior to the hyoid bone, with the same enhancement characteristics as normal thyroid. There was also a normal thyroid present (Figs 1a and 1b).

A ^{99m}Tc-pertechnetate thyroid scan showed a normally located and functioning thyroid gland as well as midline ectopic thyroid tissue (Fig. 2).

Ectopic thyroid tissue may be encountered in the tongue, anywhere along the midline from the foramen caecum at the base of the tongue to the normal position of the thyroid, mediastinum, lateral neck and oral cavity.¹

Prevalence of ectopic thyroid tissue is between 7% and 10% with lingual thyroid accounting for 90% of these cases.² Although very rare, the most common location for extralingual ectopic thyroid tissue, is the thyroglossal duct in the anterior

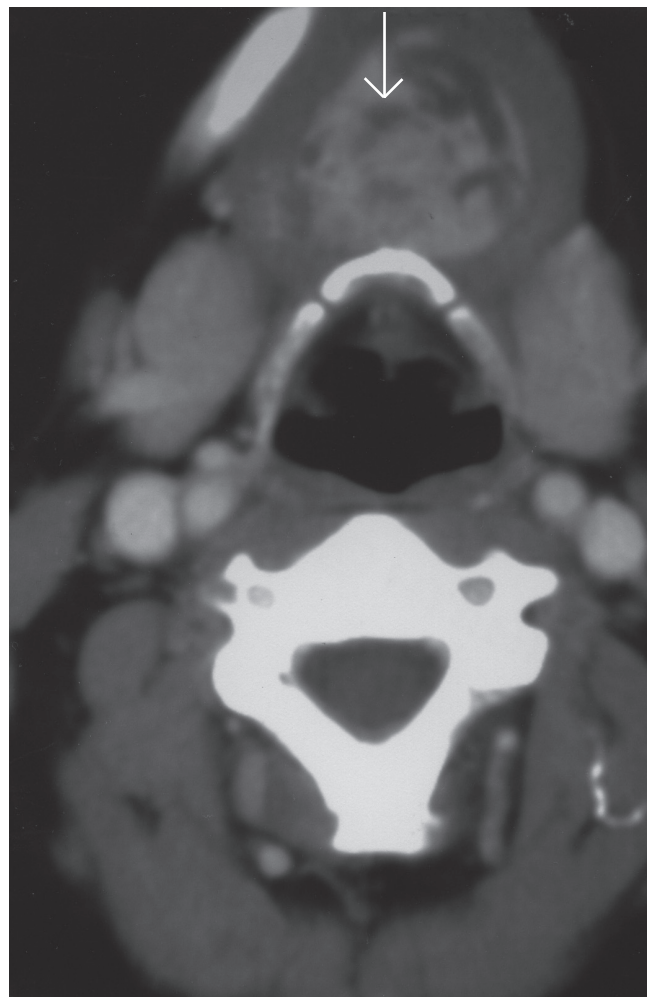


Fig. 1a. Axial CT scan of the neck showed a well-circumscribed midline neck mass anterior to the hyoid bone with the same enhancement characteristics as normal thyroid (arrow – ectopic thyroid tissue).

Drs H B Louw, M Pienaar, G Dekker and S Hlongwane are registrars in the Department of Radiology, Tygerberg Hospital and Stellenbosch University. Dr K Naidu is a radiologist at Panorama MediClinic, Parow, and Professor S Andronikou is Professor of Radiology at Tygerberg Hospital and Stellenbosch University.

Corresponding author: H B Louw (m.louw@shisas.com)

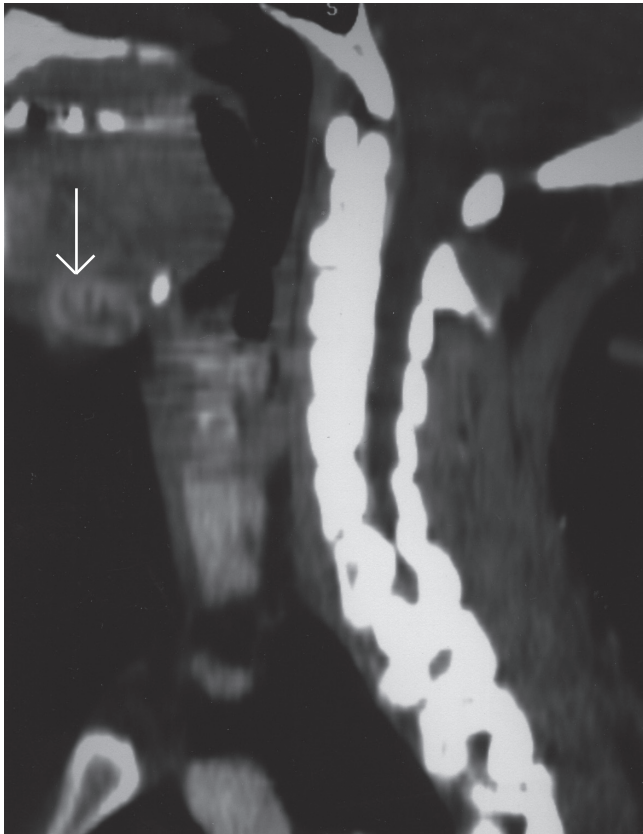


Fig. 1b. Multiplanar reconstruction – sagittal reconstruction of midline neck mass (arrow – ectopic thyroid tissue).

cervical area.³ In 75% of cases this is the only functioning thyroid tissue.⁴

Preoperatively it is very important to demonstrate all functioning thyroid tissue via scintigraphy as a standard procedure so that the patient is not left hypothyroid postoperatively.^{3,5}

1. Weber AL, Randolph G, Aksoy FG. The thyroid and parathyroid glands. CT and MR imaging and correlation with pathology and clinical findings. *Radiol Clin North Am* 2000; 38: 1105-1129.

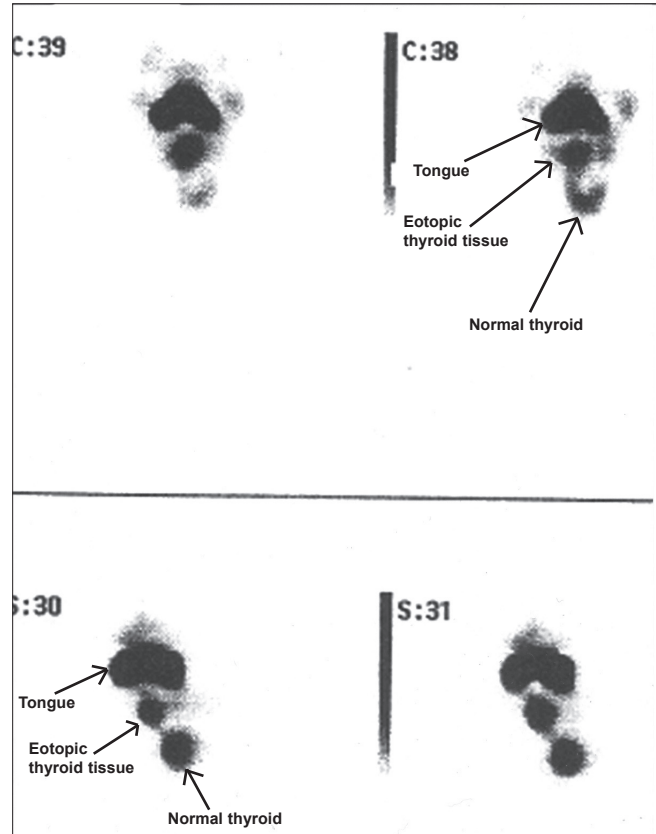


Fig. 2. ^{99m}Tc-pertechnetate thyroid scan showed a normal thyroid gland as well as midline ectopic thyroid tissue. Note normal uptake in the salivary glands, and increased uptake in the region of the tongue, the significance of which was uncertain.

2. Basaria S. Lingual thyroid. *Postgrad Med J* 2000; 76: 419.
3. Damiano A, Glickman AB, Rubin JS, Cohen AF. Ectopic thyroid tissue presenting as a midline neck mass. *Int J Pediatr Otorhinolaryngol* 1996; 34: 141-148.
4. Wiggins RH. Lingual thyroid. In: Harnsberger HR, Wiggins RH, Hudgins PA, Michel MA, Swartz J. *Diagnostic Imaging Head and Neck*. 1st ed. Salt Lake City, Utah: Amirsys Inc., 2004: III-4-6.
5. Okstad S, Mair JW, Sundsfjord JA, Eide TJ, Nordrum I. Ectopic thyroid tissue in the head and neck. *J Otolaryngol* 1986; 15(1): 52-55.