

**THE DEVELOPMENT OF
MALIGNANCIES IN
RENAL ALLOGRAFT
RECIPIENTS WITH
SPECIAL EMPHASIS ON
KAPOSI'S SARCOMA**

Mohammed Rafique Moosa

**Dissertation presented for the Degree Doctor of Medicine at
the University of Stellenbosch**

Volume 2

Promotor: Professor D.F. Du Toit

Co-Promotor: Professor P.A.B. Wranz

March 2002

TABLE OF CONTENTS

SUMMARY	iii
OPSOMMING	viii
DEDICATION	xiii
ACKNOWLEDGEMENTS	xiv
CHAPTER	

Volume 1

SECTION 1

1. Introduction	1.1
2. Kidney Transplantation: A History	2.1
3. Aims and Methods	3.1
4. Results	4.1
5. Outcome of Renal Transplantation	5.1
6. Frequency of Cancer Following Renal Transplantation	6.1
7. A Brief History of Kaposi: The Man and The Disease	7.1
8. Kaposi's Sarcoma: Epidemiology	8.1
9. Kaposi's Sarcoma: Clinical Aspects	9.1

Volume 2

10. Kaposi's Sarcoma: Pathology	10.1
11. Kaposi's Sarcoma: Treatment and Outcome	11.1
12. Skin Cancer	12.1
13. Non-skin Cancer	13.1

SECTION 2

14. The Aetiology of Kaposi's Sarcoma	14.1
--	------

SECTION 3

15. The Immune System in Kaposi's Sarcoma	15.1
16. The Role of Immunosuppression	16.1

SECTION 4

17. The Sero-epidemiology of HHV-8	17.1
18. Conclusions and Recommendations	18.1

ADDENDUM: Publications and Congress Presentations

Chapter 10

KAPOSI'S SARCOMA PATHOLOGY

All clinico-epidemiological forms of Kaposi's sarcoma share the same histopathological features and the various patterns are the same whether in the skin or extracutaneous tissue (Francis *et al.*,1986;Gottlieb *et al.*,1982;Leu *et al.*,1985;McNutt *et al.*,1983). There is some evidence that patients with epidemic Kaposi's sarcoma may have some histological features that distinguish it from the other forms (Francis *et al.*,1986) but these are subtle and appear to reflect the evolving features of Kaposi's sarcoma lesions during the course of their development (Bergfeld *et al.*,1987;Niedt *et al.*,1990;Santucci *et al.*,1988). With the discovery of the human herpesvirus 8 (HHV-8) by Chang *et al.* (1994), the emphasis in Kaposi's sarcoma research switched dramatically from the pathological to the molecular and seroepidemiological aspects (Chang *et al.*,1994;Sitas *et al.*,1999). As a consequence, there are no studies specifically of the pathological aspects of

iatrogenic Kaposi's sarcoma, making it somewhat difficult to place our study of the pathology of posttransplant Kaposi's sarcoma in perspective. With the minimal differences found between epidemic Kaposi's sarcoma and the other forms, it is perhaps not surprising that we found essentially the same lesions in our patients as are usually described in other forms of Kaposi's sarcoma.

The clinical presentation of Kaposi's sarcoma takes the form of macules-patches, papules-plaques, and nodules-tumours with a corresponding histological pattern to each of these forms (Chor *et al.*,1992). It has been suggested that macules may enlarge horizontally to form patches or vertically to form papules or plaques and later still nodules and tumors that may ulcerate (Ackerman *et al.*,1988). This clinical evolution is accompanied by corresponding histopathological changes. Although this concept is widely accepted, the evidence for it, admittedly, remains circumstantial (Francis *et al.*,1986) and it may well be that the evolutionary progression is not as orderly as suggested. While the lesions of all clinical types of Kaposi's sarcoma are indistinguishable from each other, the reason for variation in the biological behaviour in the clinical types of the disease in individual patients remains to be established (Friedman-Birnbaum *et al.*,1993). Morphologically, Kaposi's sarcoma preserves the architecture of the involved organ and initially spreads along surrounding structures such as skin appendages and blood vessels before invading the parenchyma. Despite the well-recognised histological patterns, a universally accepted histopathological classification of the disease is still lacking (Kalengayi *et al.*,1984;O'Connell,1977b;Reynolds *et al.*,1965;Taylor *et al.*,1971).

HISTOLOGICAL FEATURES

Although there have been several advances in the clinical evaluation of the patient with Kaposi's sarcoma (Del val Gómez *et al.*,1994;Deziel *et al.*,1991;Gottesman *et al.*,1993;Lee *et al.*,1991;Presant *et al.*,1990;Primack *et al.*,1994), histology remains the only proof of diagnosis. Kaposi's sarcoma has three main histological features (Leu *et al.*,1985): the spindle cell, the abnormal vascular channels, and the inflammatory cell infiltrate consisting of mononuclear cells. Other features of the tumour include the extravasation of red cells in the vascular structures, deposition of hemosiderin within tissue macrophages and the presence of eosinophilic globules.

The spindle cell

The spindle cell is the main neoplastic cell in Kaposi's sarcoma. Typical of Kaposi's sarcoma, these cells are sparse in the early forms of the disease and are often limited to a cuff surrounding dermal vessels. In the advanced stages of the disease, however, these cells predominate. As the lesion evolves from the patch to the nodule stage the degree of cellular atypia and amount of mitotic activity increases (Blumenfeld *et al.*,1985).

Origin

The cell of origin in Kaposi's sarcoma remains one of the greatest enigmas of the disease (Becker *et al.*,1991;Gray *et al.*,1991;Herndier *et al.*,1994;Huang *et al.*,1993;Karasek,1994;O'Connell *et al.*,1993;Roth *et al.*,1992;Zhang *et al.*,1994). The main contenders are the dermal dendrocyte (Nickoloff *et al.*,1989), pericyte (Ruszczak *et al.*,1987), mesenchymal cell, vascular or lymph endothelium (Schulze *et al.*,1987;Schwartz,1996). Although a pluripotential mesenchymal stem cell is a likely possibility more recent evidence from a variety of sources favour the endothelial cell, most probably of lymphatic origin. This conclusion is based on light microscopic and morbid anatomical observations, and is further supported by the unique distribution of lesions in the skin and in the submucosa of the gastrointestinal tract, following lines of lymphatics; by the remarkable predilection of Kaposi's sarcoma for lymph nodes (often without skin involvement) and absence of lesions in organs that are devoid of lymphatics such as the brain and the eyeball (Dorfman,1988).

Immunohistochemistry of spindle cells has shown consistent and extensive positivity for CD34 and often CD31 (see Fig. 10-6, page 10-39) (Calonje, 2000). There is a general pattern of reactivity to other endothelial antigens including factor VIII-related antigen, laminin, EN4, and lectin binding with *Ulex europaeus* agglutinin (UEA-1) in the spindle cells strongly favouring lymphatic endothelial derivation of the tumour (Jones *et al.*,1986). The synthesis and expression of endothelial leucocyte adhesion molecule-1, tissue factor and thrombomodulin in Kaposi's sarcoma tissue, using immunocytochemistry and mRNA expression by *in situ* hybridisation, provides further evidence for the vascular origin of Kaposi's sarcoma (Schulze *et al.*,1987;Zhang *et al.*,1994). The lack of desmin and cytokeratin and S-100 argues strongly against the

derivation of the spindle cells from epithelial, smooth muscle or Schwann cells (Leu *et al.*,1985).

The ultrastructural examination of cells lining the vascular spaces reveals the presence of characteristic organelles such as Weibel-Palade bodies, microfilaments, pinocytic vesicles, tight junctions and basement membrane (Holzhausen *et al.*,1988;Leu *et al.*,1985). There is no clear distinction between endothelial cells and those cells lying outside the vascular channels (Leu *et al.*,1985). The spindle cells may lack basement membrane and only rarely contain Weibel-Palade bodies. Spindle cells and vascular tumour cells are frequently involved in the phagocytosis of extravasated red cells. Fibroblasts, macrophages, and other phagocytic cells often participate in the process (Schenk,1986). This phenomenon of erythrophagocytosis seems to be particularly prominent in Kaposi's sarcoma cells of AIDS patients (Schenk,1986). In addition, Kaposi's sarcoma lesions of patients who have HIV infection have tubuloreticular bodies, often in large numbers, which are absent in patients with the classic form of the disease (Konrad *et al.*,1986). Beside these minor differences, electron microscopic findings are identical in all forms of Kaposi's sarcoma (Leu *et al.*,1985). However, other investigators have been unable to confirm many of these ultrastructural findings (Bosman *et al.*,1996).

The central idea is that chronic stimulation of endothelial cell results in transdifferentiation of the cell and its remarkable and permanent conversion into a spindle cell (Karasek,1994). The only other cell in the body with a similar capacity to alter its phenotypic expression is the Langerhans cell, but the alteration is less dramatic (Valcuende-Cavero *et al.*,1994). Although the weight of evidence is in favour of an endothelial origin of the Kaposi's sarcoma malignant cell, the proof is by no means incontrovertible and ongoing investigation will no doubt continue until this important issue is conclusively resolved.

Malignancy or hyperplasia

Another important observation is that HHV-8 is latently present in the vast majority of Kaposi's sarcoma spindle cells in established lesions (Dupin *et al.*,1999); in early Kaposi's sarcoma only a fraction of the cells are infected. It has therefore been

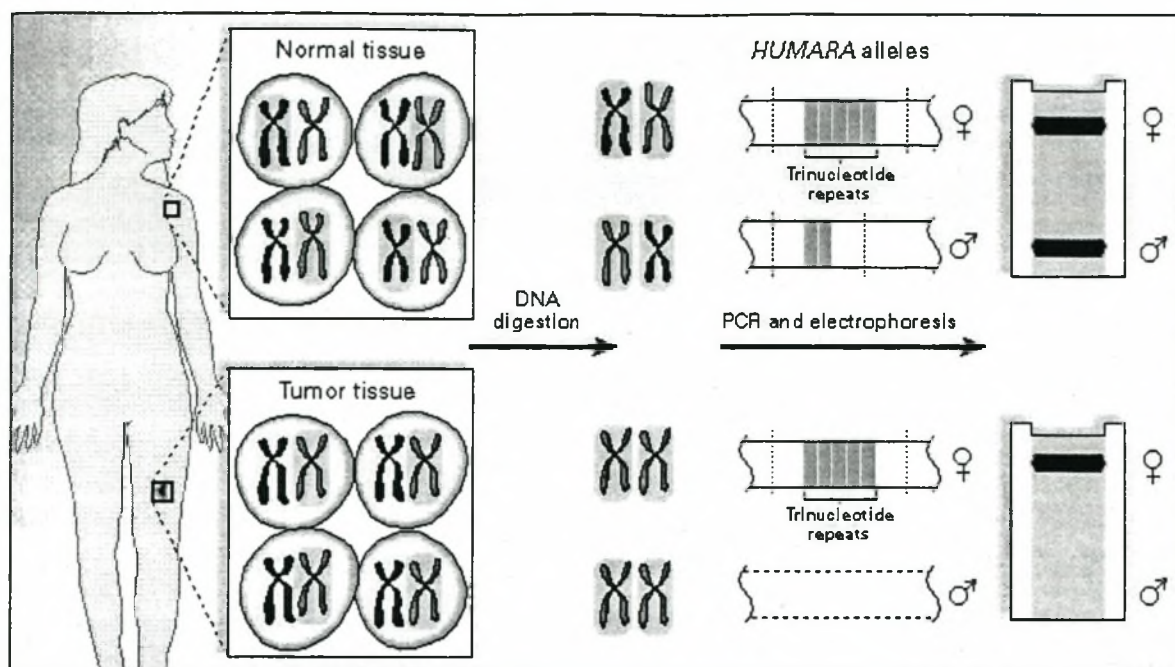


Fig. 10.1 The principles of the clonality assay of the HUMARA gene is illustrated (Rabkin *et al.*, 1997).

predicted that early lesions are polyclonal hyperplasias while advanced lesions are demonstrated that some lesions are polyclonal whereas others, usually the clonal tumours (Weiss *et al.*, 2000). This is supported by recent evidence derived from several groups examining the X-chromosome inactivation pattern of the human androgen receptor gene in women with Kaposi's sarcoma (Fig. 10-1); the advanced lesions were monoclonal (Delabesse *et al.*, 1997; Gill *et al.*, 1998; Rabkin *et al.*, 1997). However, these studies were performed in small numbers of patients most with AIDS (with the uncertain confounding influence of the HIV) and whether the findings can be extrapolated to non-AIDS Kaposi's sarcoma patients remains to be seen. Further studies involving larger number of patients and with special emphasis on the stage of the disease, are required. Parenthetically, clonality is the fundamental characteristic of any neoplastic process, and suggests origin from a single cell (Sidransky *et al.*, 1992); reactive processes are derived from polyclonal proliferation. These molecular observations are supported by the histological paucity of cellular atypia in spindle cells, such as nuclear atypia and aneuploidy in early lesions and their increase in advanced lesions (Cottoni, 1996).

An alternative approach was used by another group who studied the other malignancies caused by HHV-8 (Judde *et al.*,2000). Judde and his colleagues (2000) found monoclonal bands associated with primary effusion lymphoma but in multicentric Castleman's disease the bands were polyclonal. An alternative proposal is that all cases of Kaposi's sarcoma begin as a neoplasm with the malignant cells being rare, and morphologically indistinguishable from spindle cells (Reitz *et al.*,1999). The model for this proposal is Hodgkin's disease where the abnormal Reed-Sternberg cells are interspersed among other cells, but in contrast to Kaposi's sarcoma these cells are easily identifiable. Thus, whether Kaposi's sarcoma is truly a malignancy remains perhaps the biggest enigma of the disease.

Inflammatory infiltrate

The presence of the Kaposi's sarcoma cells triggers an immunological response in the host. Morphologically this manifests with mononuclear cells that are present at all stages of the disease. Kaposi's sarcoma cells mimic endothelial structures by regulating extravasation of lymphocytes into the lesions (Galea *et al.*,1998). In early lesions, the infiltrate is sparse and perivascular but becomes more dense and diffuse as the lesions advance (Blumenfeld *et al.*,1985). This inflammatory infiltrate is more prominent in cutaneous than visceral lesions and is independent of ulceration. It has been established that the plasma cells are polyclonal in nature (Moskowitz *et al.*,1985). Beside mononuclear cells there is recruitment of other cell types, including fibroblasts and endothelial cells by the neoplastic cells as part of a reactive hyperplasia (Reitz *et al.*,1999). The tumour secretes a number of inflammatory cytokines that are responsible for this reaction. Interleukin-6 (IL-6) is a B-cell growth and differentiation factor whose altered expression has been linked to plasma cell abnormalities (Staskus *et al.*,1999). As such, viral IL-6 has also been implicated in primary effusion lymphoma and multicentric Castleman's disease (both HHV-8 mediated lesions), in which it also acts as an autocrine or paracrine factor in the lymphoproliferative processes common to both (Asou *et al.*,1998). It is more than likely that once Kaposi's sarcoma lesions are expressed clinically that the subsequent behaviour is consequential upon a complex interplay between the nature of the host cell-mediated immune response and the putative aetiological factors (Matondo *et al.*,1996).

Vasculature

Vascular differentiation depends on the stage of the disease. In early Kaposi's sarcoma irregularly shaped vessels occur throughout the dermis. The blood vessels are thin walled (often consisting of single layers of cells only), dilated and appear distorted. They may or may not contain red blood cells. In more advanced forms of the disease, atypical but small, well-formed vessels are often present within and around a Kaposi's sarcoma nodule and appear to be an admixture of blood vessels and lymph vessels (Thijs,1957). In spindle cell Kaposi's sarcoma the vasculature consists of slits (containing red blood cells) between the abnormal tumour cells (Fig. 10-11). The cells comprising the endothelial cells of the vessels, exhibit little atypia or mitotic activity. Extravasated red cells may be seen lying adjacent to the abnormal vessels in early stages of the disease. In later stages, red cells are haphazardly scattered throughout the tumour. Normal blood vessels and adnexal structures may protrude into the newly formed peculiarly shaped, dilated vascular spaces in a manner described as the "promontory sign" (see Fig.10-4) (Tappero *et al.*,1993). This sign is characteristic of Kaposi's sarcoma but it may rarely be seen in some benign and malignant conditions (Calonje, 2000;Ackerman *et al.*,1988). On ultrastructure, very characteristically, red cells may be present within the cytoplasm of spindle cells. This phenomenon of erythrophagocytosis has been discussed in detail above and is considered by some to be the single most useful sign of Kaposi's sarcoma (Waldo *et al.*,1989). We do not routinely perform electron microscopy on skin biopsy material at our institution and are therefore unable to verify any of the ultrastructural observations. Variable degrees of hemosiderin deposition also occur (Reynolds *et al.*,1965) that can be detected both by light (Figs. 10-5 and 10-9) and electron microscopy; these lesions are present especially in the early lesions, and typically in lesions arising in the legs, probably as a result of stasis.

Eosinophilic globules are also characteristic of Kaposi's sarcoma (Fig. 10-13). Intra- or extracellular hyaline (eosinophilic) globules probably represent degenerate red blood cells (Calonje, 2000; Ackerman *et al.*,1988) because they stain bright red with phloxine tartrazine. The globules are also periodic acid-Schiff positive and diastase resistant (Fukunaga *et al.*,1991;Kao *et al.*,1990;Massarelli *et al.*,1989). They measure 0.4 to 10 μ m (Aziz *et al.*,1985), which makes them smaller than individual red blood cells. On ultrastructural examination, these structures have a homogenous

dark grey colour, characteristic of red blood cells and when they are intracellular they lie within the rough endoplasmic reticulum (Aziz *et al.*,1985). They are found within the spindle cells characteristic of Kaposi's sarcoma, typically in the perinuclear region (Ackerman *et al.*,1988). The globules are rarely seen in the patch form of Kaposi's sarcoma but are found with increasing frequency in the plaque and nodular forms of Kaposi's sarcoma (Ackerman *et al.*,1988). These are present in all forms of Kaposi's sarcoma (Dorfman,1986;O'Connell,1977b) but particularly in epidemic Kaposi's sarcoma (Blumenfeld *et al.*,1985). The presence of these globules assists in differentiating Kaposi's sarcoma from the myriad of other skin lesions to which AIDS patients and renal transplant recipients are prone. The presence of these intracytoplasmic, hyaline globules is virtually diagnostic of Kaposi's sarcoma, when they occur together with the other features described above (Ackerman *et al.*,1988).

CLASSIFICATION

The current histological depiction of Kaposi's sarcoma is a chronological continuum with lesions progressing through macule-patch, papule-plaque and nodule-tumour stages (Ackerman *et al.*,1988;Tappero *et al.*,1993); this orderly evolution of lesions has however been questioned by some investigators (Francis *et al.*,1986). The histological morphology of the lesions of the disease has corresponding clinical features. The three distinctive stages can overlap in a particular lesion. Harawi (1989) has suggested an alternative classification of the lesions based on which of the three major histological features of Kaposi's sarcoma (vascular structures, inflammatory cells or spindle cells) predominate. This classification, however, corresponds with the earlier classification. Most authors still prefer to use the earlier classification, with modifications including some of the variants noted by Harawi (1989). All epidemiological forms of the disease, and all organs involved, share the same spectrum of histological changes (Calonje, 2000). In our own group of renal transplant patients there was a fairly close but not a strict relationship between the clinical morphology of the lesions and their histological features (see Table 4-9). On immunohistochemistry the blood vessels in Kaposi's sarcoma show variable reactivity to different endothelial markers (compared to spindle cells that are negative for factor VIII-related antigen and positive for CD34) (Calonje, 2000).

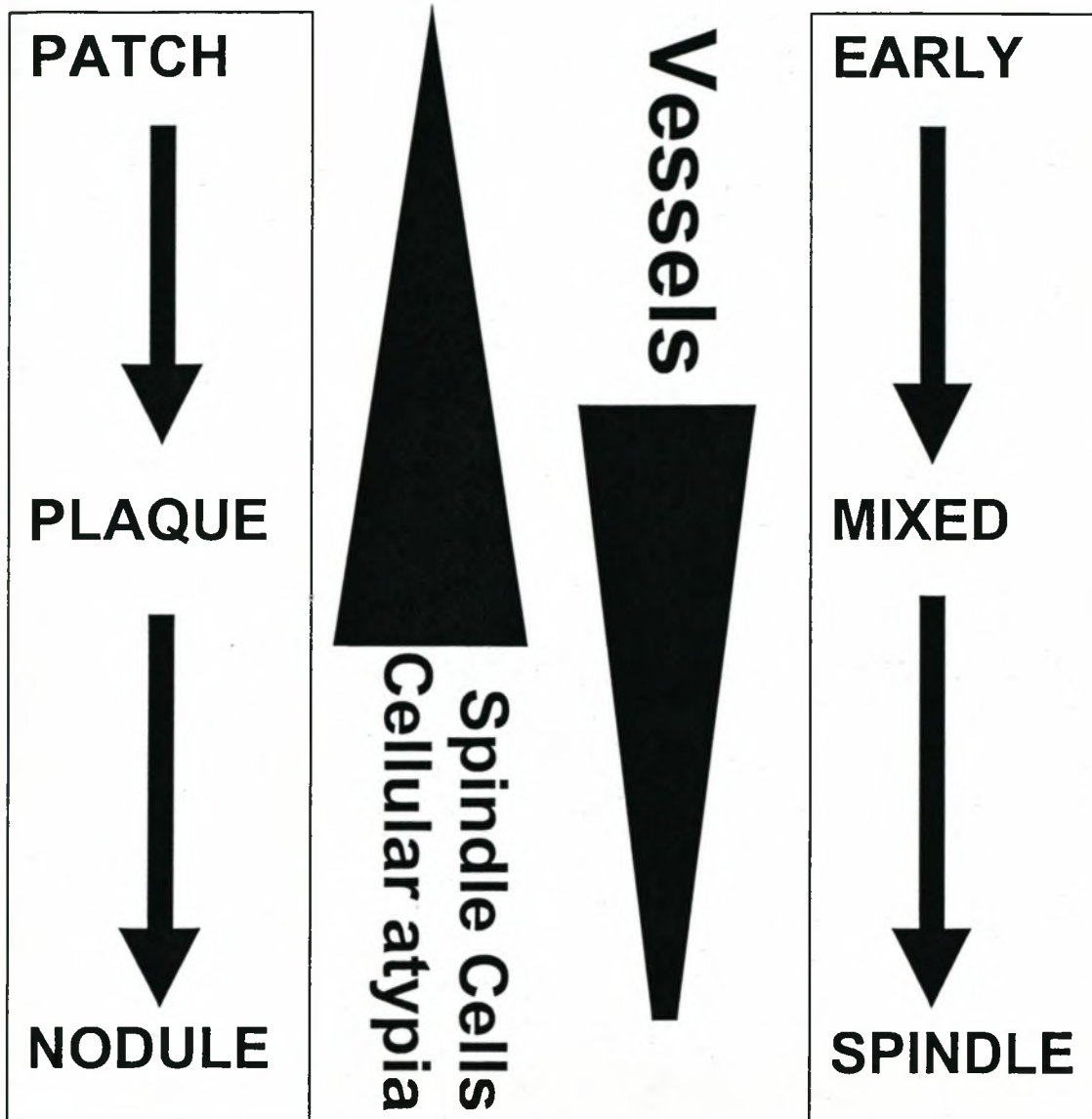


Fig. 10-2 *The classification of Kaposi's sarcoma.*

Fig. 10-2 illustrates that the amount of abnormal vessels, the main feature of early lesions, decreases, while the number of spindle cells and abnormal mitotic figures progressively increase with increasing maturity of the lesion. In addition, the hemosiderin deposition becomes more prominent and eosinophilic globules are found more easily. See pathology photographic plates (Figs. 10-3 to 10-14) for detailed histological description of the various stages. Rare variants of Kaposi's sarcoma are the lymphangiomatous, haemangiomatous, and inflammatory patterns (Friedman-Birnbaum *et al.*, 1993). The so-called lymphangiomatous form (see Fig. 10-14, page 10-49) represents classical patch/plaque stage Kaposi's sarcoma in

which vascular channels dissect between bundles of collagen (Cossu *et al.*,1997;Templeton,1981). A rare pleomorphic form has been described almost exclusively in endemic Kaposi's sarcoma (O'Connell,1977b;Qunibi *et al.*,1988), although its existence is questioned (Calonje, 2000). The spindle and mixed cell pattern predominates in our cohort of renal transplant recipients and occurred in almost 90% of our patients. This is in keeping with most reported cases of classic Kaposi's sarcoma (Francis *et al.*,1986; Harawi,1989). In AIDS-related Kaposi's sarcoma the early pattern is relatively more common (Safai,1984), accounting for 86% of biopsy specimens from AIDS patients in one report (Francis *et al.*,1986). Although the lesions are similar in all clinical types, the biological behavior differs in the different types. As mentioned above, there is currently no explanation for the variability in the biological behavior of the disease among individuals in the same group (see Chapter 11).

DIAGNOSTIC GUIDES

At every stage of Kaposi's sarcoma there are important clues to aid diagnosis. Some of these have already been mentioned and include the "promontory" sign in the early stages of Kaposi's sarcoma and the presence of plasma cells at all stages. An important point that has also been mentioned earlier is the tendency for changes to occur around existing vascular structures. As a result, in the early lesions interstitial changes seem to emanate from the vascular plexuses, and the cellular proliferations from vascular plexuses that are near adnexa often extend into and around the epithelial and non-epithelial structures of adnexa. Other useful features of Kaposi's sarcoma are that the presence of neoplastic cells of Kaposi's sarcoma with red cells within their cytoplasm (erythrophagocytosis) and the so-called eosinophilic (hyaline) globules (Ackerman *et al.*,1988). Erythrophagocytosis is characterized by one or more red cells in the cytoplasm of spindle cells.

THE EXPERIENCE AT OUR INSTITUTION

To the best of our knowledge none of the reports on Kaposi's sarcoma in renal transplant recipients specify the histological variants of the disease, with most of the recent publications being on AIDS-related Kaposi's sarcoma. A recent report on the

Table 10-1 Histological patterns according to clinical types and course in Kaposi's sarcoma compared to renal transplant recipients in present study

	Early No. (%)	Spindle No. (%)	Mixed No. (%)	Haemangiomas n (%)	Lymphangiomas n (%)
Classic (n=41)	11 (27)	13 (32)	15 (37)	1 (2)	1 (2)
Slow (n = 31)	9(29)	9(29)	11(36)	1(3)	1(3)
Rapid (n = 10)	2(20)	4(40)	4(40)	-	-
Iatrogenic (n = 9)	3(33)	3(33)	3(33)	-	-
Renal Transplant (n = 19) ¹	3(16)	5(26)	10(53)	-	1(5)

Modified from (Friedman-Birnbaum *et al.*,1993); ¹ Present study

histological patterns and clinical course of classic and iatrogenic Kaposi's sarcoma, included only a single case of Kaposi's sarcoma following renal transplantation (Friedman-Birnbaum *et al.*,1993). In our experience the primary lesion may be a macule, a patch, a plaque or a nodule. These lesions generally regressed with treatment. In the 19 patients in whom tissue was available for review, 10 (53%) had the mixed form of Kaposi's sarcoma as the presenting lesion (Table 10-1). This is in keeping with endemic and epidemic forms of Kaposi's sarcoma where this is also the most frequently diagnosed variant of the disease (Ackerman *et al.*,1988;Friedman-Birnbaum *et al.*,1993;Harawi,1989). In a report from Malawi, approximately 70% of 299 patients with endemic Kaposi's sarcoma had the mixed cell variety (Kalengayi *et al.*,1984). Spindle cell Kaposi's sarcoma followed mixed pattern Kaposi's sarcoma in relative frequency, accounting for 5 (26%) lesions. The early lesions occurred in 3 (16%) and the lymphangiomas form in 1 (5.3%) patient. In patients with AIDS, the early form of Kaposi's sarcoma seems to be more common. Francis *et al.* (1986) reported that of 21 biopsies 18 (86%) exhibited the early form of Kaposi's sarcoma. None of our patients had the pleomorphic, inflammatory or angiomatous variants, which are all rare (Ackerman *et al.*,1988). The general pattern of Kaposi's sarcoma occurring in our patients after renal transplantation is therefore similar to that of the other forms of Kaposi's sarcoma. In our study, none of the individual histological features or type of cutaneous tumour seemed to be prognostically important, a finding which concurs with that of Friedman *et al.* (1993) and Francis *et al.* (1986). Our experience was that the extent of disease (cutaneous vs visceral) appeared to be a more important indicator of prognosis.

All four of our patients with visceral organ involvement had spindle cell Kaposi's sarcoma in the non-cutaneous tissue and this did not correspond with the primary histology of the skin lesion, except in one case (Tables 4-9 and 4-10). Of the 4 patients with visceral organ involvement, the corresponding skin lesions were mixed pattern variant of Kaposi's sarcoma in 2 patients and one each of early and spindle cell Kaposi's sarcoma. All the patients with visceral organ involvement had a fatal outcome. There was no clear-cut age or gender bias in the distribution of the various histological forms of Kaposi's sarcoma. The racial make-up of the cohort, with very few white patients did not allow a meaningful analysis of the data with regard to histological differences.

EXTRACUTANEOUS KAPOSII'S SARCOMA

Kaposi's sarcoma may involve many other organs beside the skin, with the disease only becoming apparent when the tissue is examined pathologically (Amazon *et al.*,1979;Anthony *et al.*,1960;Ecklund *et al.*,1962;Temime *et al.*,1961). Estimates of the proportion of patients with visceral lesions vary widely but are usually thought to be in the region of 10% (Ecklund *et al.*,1962). However, in a review of 102 postmortem cases 93 (91%) had evidence of visceral involvement and in many the disease would have been clinically silent (Templeton,1972). Templeton (1972) therefore suggests that visceral involvement is much more common than is currently appreciated and predicted that it occurs in at least 50% of cases. The cases reviewed by Templeton (1972) were those of endemic and epidemic Kaposi's sarcoma. Our postmortem finding of Kaposi's sarcoma at many sites that were not under suspicion clinically, would also support the contention that in renal transplant recipients the disease is also generally more widespread than is appreciated.

The histological patterns of Kaposi's sarcoma in extracutaneous tissue including lymph nodes resemble that seen in the skin, with lesions going through the same evolutionary changes (O'Connell,1977a). In our experience the histology of the lesions in the visceral tissue represented fairly advanced disease (spindle cell variant) and the poor prognosis of these patients, who all died of widespread Kaposi's sarcoma, corroborated the observation. In lymph nodes the lesion arises initially in the nodal capsule and subcapsular sinus and consists of poorly defined

vascular spaces associated with plasma cells (Harawi,1989). This early stage may be mistaken for a non-specific inflammatory infiltrate. From the sinuses the tumour infiltrates the interfollicular tissue to resemble fibrous septa. The lymphoid follicles appear resistant to infiltration by tumour (O'Connell,1977a). Early lesions may be confined to a few millimetres and only detected on serial sections of lymph node. The changes in the parenchyma of the lymph nodes are variable. In a series of African patients, a plasma cell infiltrate occurred around the tumour in almost 90% of cases (O'Connell,1977a). Details of other visceral organ involvement are discussed below.

HISTOLOGICAL DIFFERENCES BETWEEN THE CLINICO-EPIDEMIOLOGICAL TYPES OF KAPOSI'S SARCOMA

The bulk of available evidence suggests that there are no major differences in the histological patterns of the various epidemiological types of Kaposi's sarcoma (Calonje,2000;Friedman-Birnbaum *et al.*,1993;Ruszczak *et al.*,1987). Some of the minor differences have been alluded to above. With increased awareness of epidemic Kaposi's sarcoma, it is perhaps not surprising that patch and plaque lesions are seen most often in AIDS patients, as early lesions are more likely to be biopsied in these patients (Calonje,2000). A major criticism of studies (Chow *et al.*,1990;Leu *et al.*,1985) that report differences between epidemic Kaposi's sarcoma and the other forms of Kaposi's sarcoma is that these are based on very small patient numbers that makes it impossible to control for the stage of the disease. Comparing lesions at different stages of evolution is unacceptable, as different features of Kaposi's sarcoma predominate at different stages as discussed above.

Endemic Kaposi's sarcoma is a disease that is diagnosed long after the onset of the lesions because patients remain relatively asymptomatic and ignore what they consider are trivial lesions. The lesions seen in endemic Kaposi's sarcoma would therefore have a preponderance of advanced lesions (Taylor *et al.*, 1971). Few post-renal transplantation patients with Kaposi's sarcoma, in our experience, present with early lesions. Of the 19 patients with tissue available for pathological examination, almost 90% presented with either plaque or nodular lesions.

A recent study has suggested that there may be some morphological differences in classic Kaposi's sarcoma and that seen in patients who are immunocompromised (Castelli *et al.*,1997). In Kaposi's sarcoma the endothelial and spindle cells, the two main components, may exhibit one of two patterns of growth. A dense fibrous pseudocapsule, seen in the nodular lesions, limits the *expansile* pattern of growth. The *infiltrative* pattern is seen in patches and plaques, with the components spreading freely through the connective tissue and merging with the normal tissue at the margins of the lesion. Although the Kaposi's sarcoma seen in immunocompromised patients resembles that seen in classic Kaposi's sarcoma, the former is characterised by an outstanding infiltrative pattern (Castelli *et al.*,2000), that occurs in patches, plaques, and nodules at all stages. In the patches and plaques it is expressed to such an extent that arborising haematic and lymphatic lacunae deeply dissect the collagen bundles, and infiltrate deep into the adventitial dermis encircling the adnexae, sometimes completely (Castelli *et al.*,2000). In addition, there is proliferation of endothelial cells with inward protrusion into the lumen, giving the impression of a "vessel within a vessel". Moreover, the proliferating cells arranged in sheets or forming vessels intrude into the tissue by colonising the perineural spaces and following long tracts of nerves.

It has been claimed that the nodules found in immunocompromised patients with Kaposi's sarcoma also differ from those with classic Kaposi's sarcoma. The nodules lack a collagenous capsule and penetrate host tissue unchecked without any distinct boundaries (Castelli *et al.*,2000). They often involve the deep reticular dermis and sometimes even the subcutaneous fat. Whether the lesions are patches, plaques, or nodules extravasated red cells are present in much larger numbers than in classic Kaposi's sarcoma, which manifests clinically as more prominent bruising (Castelli *et al.*,2000). Other features indicative of the immunodeficiency-related forms are both the greater architectural and cytological abnormalities. A last feature unique to the plaque seen in AIDS-associated Kaposi's sarcoma is the presence of intravascular papillary projections composed of highly atypical epithelioid endothelial cells that pile up toward the lumen (Castelli *et al.*,1997). The authors conclude that "immunodeficiency does impart special features that are related to its clinical picture and reflect its biological behaviour", although they do admit that there are no histopathological markers distinctive between the two forms. However, the

conclusions reached by the authors were based on their experience of only eight cases of immunodeficiency-related Kaposi's sarcoma, of which only two were iatrogenic. Further study will be necessary to confirm their interesting findings. Our own study was not designed to compare the morphologies of the different epidemiological types with each other, but our impression of the 19 cases of post-renal transplant Kaposi's sarcoma is that differences in light microscopy features are minor, if any.

DIFFERENTIAL DIAGNOSIS OF KAPOSI'S SARCOMA

A number of benign and malignant skin conditions may pathologically mimic the lesions of Kaposi's sarcoma but there are clues that may assist in distinguishing other pathological lesions from Kaposi's sarcoma. The differential diagnosis of Kaposi's sarcoma varies considerably with the stage of the disease and to some extent the clinical morphology of the lesion. It should, however, be emphasised that the differential diagnosis of posttransplant Kaposi's sarcoma is not too difficult, despite the extensive list: many of the lesions are of import only in epidemic Kaposi's sarcoma (e.g. bacillary angiomatosis and dermatofibroma), while most of the benign angiomas occur predominantly in children and young adults.

Benign lesions

Stasis dermatitis The vascular proliferation and haemosiderin deposits may be associated with plasma cells (Fig. 10-15). However, in contrast to early Kaposi's sarcoma the vessels have thick walls and are associated with fibrosis. Small thick-walled vessels are not a feature of early Kaposi's sarcoma and are usually a manifestation of stasis in specimens taken from the legs (Gottlieb *et al.*, 1989a).

Scars The fibrovascular proliferation seen in granulation tissue may mimic early Kaposi's sarcoma. The fibroblasts however tend to be orderly and oriented parallel to the skin surface and the vessels perpendicular to the surface (Blumenfeld *et al.*, 1985).

Pseudo-Kaposi's sarcoma Acroangiodermatitis of Mali is an exaggerated form of stasis dermatitis and is a complication of venous occlusion (Boyle *et al.*, 1986; Mali *et*

al.,1965). Together with the Stewart-Bluefarb syndrome, which is an arteriovenous malformation that clinically resembles Kaposi's sarcoma, acroangiokeratitis of Mali constitute pseudo-Kaposi's sarcoma (Strutton *et al.*,1987). The small thick-walled vessels seen in acrodermatitis are not a feature of early Kaposi's sarcoma, whereas in the Stewart-Bluefarb syndrome an arteriovenous shunt can be identified (Requena *et al.*,1997).

Pyogenic granuloma The older literature emphasises this lesion in the differential diagnosis of Kaposi's sarcoma but histologically the lesion is easily distinguished from Kaposi's sarcoma. It shows marked intravascular oedema, neutrophilic infiltrate and has no spindle cells. The deeper vascular component of pyogenic granuloma however, might resemble Kaposi's sarcoma (Lee,1968). On the other hand, nodular lesions of Kaposi's sarcoma may ulcerate and this is associated with the proliferation of granulation tissue on the surface. Such lesions may resemble pyogenic granulomas (Gottlieb *et al.*,1989a).

Palisaded granulomatous dermatitides This group of dermatitides, especially granuloma annulare and necrobiosis lipoidica may have an interstitial component consisting of plump cells with round or oval nuclei, and may thus resemble Kaposi's sarcoma. Granuloma annulare (Fig. 10-16) mimics the inflammatory type of Kaposi's sarcoma but can easily be differentiated. In Kaposi's sarcoma the aggregations of epithelioid neoplastic cells are concentrated around the vessels together with a small number of lymphocytes and plasma cells. In granuloma annulare there are usually only lymphocytes around the blood vessels; in addition, there are plump histiocytes, some of which may be multinucleated, in the interstitium, often in a palisade around a focus of mucin and collagen degeneration (Ghadially *et al.*,1989). Necrobiosis lipoidica also has a prominent interstitial component often with a number of plasma cells but can be distinguished from Kaposi's sarcoma by the absence of the bizarre vascular spaces, and the presence of scattered granulomas many of which contain multinucleated giant cells (Gottlieb *et al.*,1989a).

Bacillary angiomatosis This condition, first described in 1983 by Stoler *et al.* (1983) occurs predominantly in patients with advanced AIDS (Berger *et al.*,1989; Cockerell *et al.*,1987; LeBoit *et al.*,1988; LeBoit *et al.*,1989; Stoler *et al.*,1983). Two species of

Bartonella, *B. quintana* and *B. henselae* cause bacillary angiomatosis and these can be cultured from blood, skin and tissue (Cockerell,1995). Clinically, the disease manifests with papules that progress to skin nodules and tumours (Requena *et al.*,1997). Histological features are a lobular pattern with capillary proliferation, with connective septa intersecting the lesion (Cockerell,1990; LeBoit *et al.*,1989; Szaniawski *et al.*,1990). The blood vessels are lined by plump endothelial cells that appear epithelioid and protrude into the vascular lumina. An important clue to the diagnosis is the presence of neutrophils and leucocytoclastic debris. This makes it easy to differentiate from early Kaposi's sarcoma. However, the most characteristic and specific differential finding is the presence of aggregates of granular material that give a positive Warthin-Starry stain or electron microscopy that reveal masses of bacteria.

Neoplastic lesions

Vascular tumours In general, haemangiomas (Fig. 10-18) are composed of rounder, better formed, blood vessels with thicker walls that are lined by plump endothelial cells. In contrast to lesions in Kaposi's sarcoma, the endothelial cells display a lobular growth pattern and may contain intravascular thrombi (Gottlieb *et al.*,1989a). A number of benign haemangiomas have recently been described that are important to distinguish from Kaposi's sarcoma. *Spindle cell haemangioendothelioma* (Weiss *et al.*,1986b) resembles Kaposi's sarcoma both clinically and pathologically. Microscopically, the tumour consists of an admixture of dilated vascular spaces and spindle cells reminiscent of Kaposi's sarcoma. The endothelial cells may be focally epithelioid with vacuolar changes. This feature together with the presence of organising clots and phleboliths permit its differentiation from Kaposi's sarcoma in virtually all cases (Harawi,1989). *Targetoid haemangioma* must be distinguished from a patch-stage Kaposi's sarcoma lesion. This lesion is characterised by ectatic vascular structures that sometimes exhibit papillary projections and fibrin thrombi. The vascular channels dissect between collagen bundles and, in this setting, extravasated red cells and hemosiderin deposits as well as mononuclear infiltration may be found (Santa Cruz *et al.*,1988). *Microvenular haemangioma* also needs to be differentiated from patch-stage Kaposi's sarcoma. The lesion characteristically consists of monomorphous, small elongated blood vessels with inconspicuous lumina involving the full thickness of the

reticular dermis. There are no spindle cells or inflammatory infiltrate (Bantel *et al.*,1989;Hunt *et al.*,1991). *Acquired tufted angioma* affects children and young adults. Histologically the lesion has a "cannonball" appearance made up of multiple separated cellular lobules within the dermis and subcutaneous fat. The lobules consist of whorls of endothelial cells arranged concentrically around a blood vessel. The lesion resembles the nodular-variant of Kaposi's sarcoma except that the latter consists of interlacing fascicles of spindle cells lining slit like vessels, with the presence of an inflammatory cell infiltrate (Macmillan *et al.*,1971; Nakagawa,1949; Wilson Jones,1976; Wilson Jones *et al.*,1989). *Kaposiform haemangioendothelioma* is a condition exclusively of children. Histologically, the neoplasm consists of poorly circumscribed nodules separated by connective tissue. The nodules are composed of a combination of small round capillaries, and solid nests of round and epithelioid endothelial cells containing hemosiderin, hyaline globules or vacuoles. Within these nodules, fascicles of spindle cells occur with interspersed vascular space containing red cells and fibrin thrombi. These areas of fascicular nodules strongly resemble the nodular-stage of Kaposi's sarcoma except that the nodules of the latter are not multiple and an inflammatory infiltrate usually surrounds the nodules. Atypia and mitotic figures are usually absent in kaposiform haemangioendothelioma (Requena *et al.*,1997). *Spindle cell haemangioendothelioma* is a condition that affects children and young adults (Weiss *et al.*,1986a). The histopathology resembles that of kaposiform haemangioendothelioma in that the lesions consist of nodules except that these are well circumscribed. The nodules are made up of small blood vessels containing organised thrombi and phleboliths. Fascicles of spindle cells are found between these dilated vessels, but can be differentiated from those of nodular-stage Kaposi's sarcoma by the presence within the fascicles of rounded cells with vacuolated cytoplasm. *Benign lymphangioendothelioma* is a disease of adolescents and young adults. Histopathologically the lesion resembles the patch-stage of Kaposi's sarcoma with anastomosing thin-walled cleft like vascular channels dissecting the collagen bundles. The resemblance is so close that some authorities claim that it is impossible to distinguish the two diseases pathologically in the absence of clinical information (Sanchez *et al.*,1993;Wilson Jones *et al.*,1990). However, clues to the differential diagnosis are the absence of red cells, hemosiderin deposits and plasma cells in the early phase of Kaposi's sarcoma.

Fibrohistiocytic tumours Dermatofibroma (Fig. 10-17) is the skin lesion which is most commonly misdiagnosed as Kaposi's sarcoma in the setting of men with AIDS (Blumenfeld *et al.*,1985). Histologically, dermatofibroma consists of a mixture of fibroblast-like cells, histiocytes, and blood vessels. The lesion is associated with prominent spindle cells that can be mistaken for Kaposi's sarcoma. However, the arrangement of the spindle cells is orderly as in a scar or have a storiform pattern (Harawi,1989). In addition, multinucleated giant cells are usually present especially at the margins of the lesions. In more than 80% of cases there is hyperplasia of the overlying epidermis with or without hyperpigmentation of the basal layer (Harawi,1989).

Other sarcomas Angiomatous Kaposi's sarcoma may be difficult to distinguish from both benign and malignant vascular neoplasms (Uys *et al.*,1959). Angiomatous Kaposi's sarcoma with large anastomosing vascular spaces may resemble angiosarcomas. The latter also has areas composed of spindle cells and there are often bizarre-shaped, dilated vascular spaces resembling those of early Kaposi's sarcoma (Gottlieb *et al.*,1989a). In Kaposi's sarcoma, however, typical, flat endothelial cells line these spaces whereas angiosarcoma the endothelial cells are atypical and contain many mitotic figures. Angiosarcoma (Fig. 10-19) may also have large aggregates of "epithelioid" neoplastic cells (Gottlieb *et al.*,1989a). Both classic and iatrogenic Kaposi's sarcoma have a predilection for involving the legs and this mimics the development of lymphangiosarcomas that involve similar areas in the setting of chronic lymphoedema (Muller *et al.*,1987). Spindle cell Kaposi's sarcoma can be distinguished from other monomorphic sarcomas by the presence of the characteristic vascular channels, absence of a specific architectural pattern that occurs in sarcomas (herringbone, storiform, pallasading) and the occasional presence of dense plasma cell infiltrate between the spindle cells.

Other malignancies The late plaque and nodular lesions of Kaposi's sarcoma must be differentiated from spindle-cell squamous-cell carcinomas, spindle-cell malignant melanomas and leiomyosarcoma. Even with an adequate biopsy the differential diagnosis can be difficult and the pathologist may have to resort to immunohistochemistry and/or electron microscopy. If the malignant cells show

evidence of either melanocytic, squamous or smooth muscle differentiation then the diagnosis is quite apparent.

POSTMORTEM FINDINGS IN KAPOSII'S SARCOMA

Postmortem examinations were performed on 3 of 4 patients in our cohort dying as a direct consequence of visceral Kaposi's sarcoma. Little information is available on the postmortem findings in patients with iatrogenic Kaposi's sarcoma (Siegel *et al.*, 1969), but several reports on endemic and epidemic Kaposi's sarcoma exist.

The most striking difference between Kaposi's sarcoma in patients with AIDS and those associated with the other clinical forms, is its highly aggressive nature in those with AIDS (Gottlieb *et al.*, 1982). Earlier reports, before the onset of the AIDS epidemic, generally described Kaposi's sarcoma as a disease that tended to remain confined to the skin for many years (Rothman, 2001); in contrast most patients with

Table 10-2 Comparison of sites of organ involvement in 64 AIDS patients, 34 Africans and 47 white patients dying with Kaposi's sarcoma (expressed as percentages).

Site	AIDS	Endemic	Classic
Skin	94	73	83
Gastrointestinal tract	57	65	60
Lung	52	15	45
Lymph nodes	50	53	45
Spleen	13	12	11
Pharynx/Larynx	11	-	-
Adrenals	8	32	19
Pericardium	6	18	19

Rarely: epididymis, conjunctivae, gallbladder, bladder, bone marrow, thyroid.

Data obtained from postmortem studies: Guarda *et al.* (1984); Hui *et al.* (1984); Niedt *et al.* (1985); Reichert *et al.* (1983); Templeton (1972); Welch *et al.* (1984).

Note: The number of postmortem studies on renal transplant patients is too small to allow meaningful comparisons.

AIDS develop widely disseminated, multifocal disease within a very short period of time. The pattern of involvement of organs with AIDS is similar to that seen in non-AIDS Kaposi's sarcoma (Gottlieb *et al.*,1989b). The most common sites of involvement (excluding the skin) are lymph nodes, gastrointestinal tract, lungs, liver, and spleen. The gallbladder, pericardium, bone marrow, conjunctivae, testes, epididymis and heart may also be involved. Neural tissue is seldom affected, presumably because of the paucity of lymphatic vessels (Table 10-2).

Pathological findings at postmortem examination (Figs. 10-20 to 10-25)

Morphologically, the appearance of Kaposi's sarcoma in viscera is the same as in the skin. In addition to spindle cell morphology with slit-like vessels, corresponding to a cutaneous nodule, forms appear that resemble the patch and plaque forms of cutaneous Kaposi's sarcoma. Forms of Kaposi's sarcoma that resemble angiosarcoma (*vide supra*) or that contain spindle-shaped cells with marked atypia also occur (Gottlieb *et al.*,1989b). Histological patterns of Kaposi's sarcoma are characteristic in particular organs.

Lymph nodes (Fig. 10-20) In lymph nodes, Kaposi's sarcoma may be found in either the subcapsular sinuses or the medullae. Involvement may range from slight to replacement of the entire node with spread beyond. Histologically, the nodular pattern is most frequently seen with spindle cells attached to the wall of subcapsular sinuses. In our experience all the patients who had postmortem examinations had deep lymph node involvement and the morphology corresponded with that of advanced disease, as was the experience in the report in patients with AIDS (Gottlieb *et al.*,1989b).

Lungs (Figs. 10-21 and 10-22) The lungs were also involved in all three of our patients. In the lungs we observed that the lesions spread along bronchi and peribronchial blood vessels, as it did in patients with AIDS-associated and endemic Kaposi's sarcoma (Templeton,1972). From these sites the lesion infiltrates the parenchyma (Gottlieb *et al.*,1989b). The peribronchial location of Kaposi's sarcoma suggests that the lesions should be accessible by transbronchial biopsy.

Gastrointestinal tract (Fig. 10-23) In the gastrointestinal tract the patterns of Kaposi's sarcoma most closely resemble the cutaneous lesions. All three stages of Kaposi's sarcoma (patch, plaque and nodule) may occur simultaneously in the same patient. The lesions arise from around the vessels in the serosa or the mucosa and spreads from there through the muscularis. The stomach/small bowel was involved in 2 of the 3 patients in our postmortem studies. All three patients however, had liver involvement. In the liver Kaposi's sarcoma extends for long distances along the portal structures and infiltrates the parenchyma. The portal involvement may be so severe (Uys *et al.*,1959) as to result in biliary obstruction or cholangitis (Niedt *et al.*,1985). In this setting the Kaposi's sarcoma may be mistaken for fibrosis or cirrhosis. Careful examination will however reveal the characteristic spindle cell pattern (corresponding to the nodular pattern). Cavernous haemangioma is the other differential diagnosis of Kaposi's sarcoma of the liver (Lothe *et al.*,1962;Niedt *et al.*,1985). In one of our patients the renal allograft was also involved by Kaposi's sarcoma (Fig. 10-24). The lesion appeared as a subcapsular nodule and the histology was that of spindle cell Kaposi's sarcoma.

Spleen The spleen is also occasionally involved in patients with Kaposi's sarcoma. Of our three patients, the spleen was involved in one. The surface of the organ had "raspberry-like" nodules and morphologically the vascular spaces appeared more ectatic than lesions elsewhere in the body. The spindle cells surrounded the arterioles and the lesions occurred almost exclusively in the white pulp. It has been reported that Kaposi's sarcoma manifests in the spleen as a densely fibrotic area with spindle cells on the periphery and occasionally haemosiderin deposition (Gottlieb *et al.*,1989b).

Postmortem findings in endemic Kaposi's sarcoma

The postmortem findings of African patients dying of Kaposi's sarcoma before the outbreak of the AIDS epidemic were documented by Templeton (Templeton,1972) who compared the findings with those of white patients reported in the literature (Table 10-2). Of the 624 patients with the disease postmortem examinations were performed on 34 (5.4%) of them. Kaposi's sarcoma contributed significantly to the death of 21 (62%) patients and was an incidental finding in 13 (38%). A similar proportion of patients died as a direct result of Kaposi's sarcoma in the different

groups that Templeton (1972) was comparing. The early lesions of Kaposi's sarcoma are seldom seen in black patients because the skin pigmentation masks the patch and plaque lesions. The more advanced the disease the more extensive the visceral organ involvement appeared to be. Morphologically, the diagnosis was made without much difficulty. The classical spindle cells and plasma cells were found in the majority of patients. Interestingly, Templeton (1972) found remarkably little variation in the histology of longstanding nodules compared to rapidly fatal cases and he concluded that histological appearance does not correlate with prognosis. In the Templeton report (1972), gastrointestinal involvement was common but the lesions seldom resulted in complications in the African patients. The pericardium was involved in 15 of the postmortem cases overall but no clinically detectable disease was produced. Although there are some reports of involvement of the brain by Kaposi's sarcoma (Ayer *et al.*, 1962; Epstein, 1957; Nesbitt *et al.*, 1945), in the Ugandan series of Templeton (1972) no cases with central nervous system involvement were found. The association of Kaposi's sarcoma with second malignancies, particularly lymphomas, is well recognised (Anonymous, 1967; Berg, 1967). In the Templeton report, 4 (12%) of the 34 patients had a second malignancy, compared to 1 (2%) of the 47 white patients with classic Kaposi's sarcoma. The difference in the prevalence of malignancies in the race groups is despite the younger age of the black patients and the more aggressive nature of the disease that resulted in their earlier demise. None of our patients with postrenal transplant Kaposi's sarcoma has developed a second malignancy thus far. Templeton (1972) reflects that both Kaposi's sarcoma and lymphoma may be associated with immunodeficiency states (Master *et al.*, 1970), and suggests that this may explain why so many of the Ugandan Kaposi's sarcoma patients died of infective causes especially tuberculosis. Although we agree with the contention that a state of deficient immune responsiveness exists in these patients, our experience surprisingly has been that none of our renal transplant patients with Kaposi's sarcoma suffered from or died of tuberculosis, despite their residing in the region with the highest prevalence of tuberculosis in the world (Moosa *et al.*, 1997).

The most serious threat to AIDS-associated Kaposi's sarcoma patients is the development of opportunistic infections (Francis *et al.*, 1986). This is reflected in United Kingdom mortality data which show a 48% mortality in AIDS-patients with

Kaposi's sarcoma alone but a mortality of 77% in patients with Kaposi's sarcoma and *Pneumocystis carinii* pneumonia (Francis *et al.*,1986). All 3 of our patients with extensive visceral involvement who died had vital organ involvement. All 3 patients died of respiratory failure due Kaposi's sarcoma lung involvement. Pulmonary Kaposi's sarcoma has a very poor prognosis with 8 out of 10 Kaposi's sarcoma patients with proven lung involvement patients dying as a direct result of the disease in a recent report (Purdy *et al.*,1986).

SUMMARY

Histopathologically, lesions of Kaposi's sarcoma are characterised by three main features, namely vascular channels, spindle cells, and a mononuclear inflammatory infiltrate. As the lesion matures the vascular structures become less prominent giving way to increasing amounts of spindle cells. Other relatively unique findings on histology are the promontory sign in early Kaposi's sarcoma and the presence of hemosiderin and eosinophilic nodules in maturing lesions. The histological appearance of all epidemiological forms of Kaposi's sarcoma is essentially the same. Ours is the only study to detail the histology of posttransplant Kaposi's sarcoma but our experience concurs with the latter observation. On ultrastructure the presence of erythrophagocytosis is very characteristic. No universally accepted form of pathological classification exists, although the simplest form based on the corresponding clinical stages of patch, plaque and nodule remains the most widely applied.

One of the most controversial aspects of Kaposi's sarcoma is whether it is a true malignancy or hyperplasia. Recent studies of the clonality of the disease seems to indicate that at least in the advanced lesion, Kaposi's sarcoma is neoplastic rather than hyperplastic in nature. The origin of the neoplastic spindle cell remains a mystery although there is increasing evidence of its endothelial origin, either vascular or lymphatic. The evidence of the nature of the cell has been largely based on immunohistochemical studies.

Although the differential diagnosis of Kaposi's sarcoma in general remains very broad, it does depend on the epidemiological form of the disease, the stage of the disease, as well as the clinical features. For posttransplant Kaposi's sarcoma the differential diagnosis is much more limited than for epidemic Kaposi's sarcoma.

Kaposi's sarcoma can prove fatal in posttransplant Kaposi's sarcoma, probably as a result of vital organ involvement. Postmortem examination reveals that the disease may affect all organ systems in the body, with the notable exception of the nervous system.

LITERATURE CITED

- Ackerman, A. B. and Gottlieb, G. J. (1988). Atlas of the gross and microscopic features. *In* Kaposi's sarcoma: A Text and Atlas, (Gottlieb, G. J. and Ackerman, A. B., eds.), p.29, Lea Febiger, Philadelphia.
- Amazon, K. and Rywlin, A. M. (1979). Subtle clues to diagnosis by conventional microscopy. Lymph node involvement in Kaposi's sarcoma. *Am J Dermatopathol.* **1**, 173.
- Anonymous. (1967). Mysterious sarcoma. *Lancet.* **2**, 1290.
- Anthony, C. W. and Koneman, E. W. (1960). Visceral Kaposi's sarcoma. *Arch.Pathol.* **70**, 740.
- Asou, H., Said, J. W., Yang, R., *et al.* (1998). Mechanisms of growth control of Kaposi's sarcoma-associated herpes virus-associated primary effusion lymphoma cells. *Blood.* **91**, 2475.
- Ayer, J. P., Paul, O., and Capps, R. B. (1962). Clinico-pathological conference. *Am.Heart J.* **63**, 566.
- Aziz, D., Srolovitz, H. D., Brisson, M. L., *et al.* (1985). Characterisation of eosinophilic hyaline bodies in KS (Abstract). *J Clin.Invest.* **52**, 4A.
- Bantel, E., Grosshans, E., and Ortonne, J. P. (1989). Kenntnis mickrokapillärer angiome, beobachtungen bei schwangeren bzw. unter hormoneller antikozeption stehenden Frauen. [Understanding microcapillary angioma, observations in pregnant patients and in females treated with hormonal contraceptives]. *Z.Hautkr.* **64**, 1071.

- Becker, J., Schuppan, D., Rabanus, J. P., Gelderblom, H. R., and Reichart, P. (1991). Immunoelectron microscopy shows an atypical pattern and a quantitative shift of collagens type I, III and VI in oral Kaposi's sarcoma of AIDS. *Virchows Arch.A Pathol.Anat.Histopathol.* **419**, 237.
- Berg, J. W. (1967). The incidence of multiple primary cancers. I. Development of further cancers in patients with lymphomas, leukemias, and myeloma. *J Natl.Cancer Inst.* **38**, 741 .
- Berger, T. G., Tappero, J. W., Kaymen, A., and LeBoit, P. E. (1989). Bacillary (epithelioid) angiomatosis and concurrent Kaposi's sarcoma in acquired immunodeficiency syndrome. *Arch.Dermatol.* **125**, 1543.
- Bergfeld, W. F., Zemtsov, A., and Lang, R. S. (1987). Differentiation between AIDS-related and non-AIDS-related Kaposi's sarcoma. *Cleve.Clin.J Med.* **54**, 315.
- Blumenfeld, W., Egbert, B. M., and Sagebiel, R. W. (1985). Differential diagnosis of Kaposi's sarcoma. *Arch.Pathol.Lab Med.* **109**, 123.
- Bosman, C., Bisceglia, M., and Quirke, P. (1996). Ultrastructural study of Kaposi's sarcoma. *Pathologica.* **88**, 8.
- Boyle, J. and Burton, J. L. (1986). Pseudo-Kaposi sarcoma. *Lancet.* **2**, 921.
- Calonje, E. (2000). Tumors of blood vessels and lymphatics. *In* Diagnostic histopathology of tumors, Second ed. (Fletcher, C. D. M., eds.), p.63, Churchill Livingstone, New York.
- Castelli, E. and Wollina, U. (1997). Mediterranean and immunodeficiency associated Kaposi's sarcoma - Does micromorphology reflect clinical patterns? A clinicopathologic study with phenotypic characterization of tumor cells. *Oncology Reports.* **4**, 289.
- Castelli, E., Wollina, U., Hodak, E., and Feinmesser, M. (2000). Histopathologic features of progression in Mediterranean and immunodeficiency-related Kaposi sarcoma [1] (multiple letters). *American Journal of Dermatopathology.* **22**, 89.
- Chang, Y., Cesarman, E., Pessin, S., *et al.* (1994). Identification of herpes-like DNA sequences in AIDS-associated Kaposi's sarcoma. *Science.* **266**, 1865.
- Chor, P. J. and Santa Cruz, D. J. (1992). Kaposi's sarcoma. A clinicopathologic review and differential diagnosis. *J Cutan.Pathol.* **19**, 6.
- Chow, J. W. and Lucas, S. B. (1990). Endemic and atypical Kaposi's sarcoma in Africa--histopathological aspects. *Clin.Exp.Dermatol.* **15**, 253.

- Cockerell, C. J. (1990). The clinicopathologic spectrum of bacillary (epithelioid) angiomatosis. *Prog.AIDS Pathol.* **2**, 111.
- Cockerell, C. J. (1995). Bacillary angiomatosis and related diseases caused by *Rochalimaea*. *J.Am.Acad.Dermatol.* **32**, 783.
- Cockerell, C. J., Whitlow, M. A., Webster, G. F., and Friedman-Kien, A. E. (1987). Epithelioid angiomatosis: a distinct vascular disorder in patients with the acquired immunodeficiency syndrome or AIDS-related complex. *Lancet.* **2**, 654.
- Cossu, S., Satta, R., Cottoni, F., and Massarelli, G. (1997). Lymphangioma-like variant of Kaposi's sarcoma: clinicopathologic study of seven cases with review of the literature. *Am J Dermatopathol.* **19**, 16.
- Costa, M. J. and Weiss, S. W. (1990). Angiomatoid malignant fibrous histiocytoma. A follow-up study of 108 cases with evaluation of possible histologic predictors of outcome. *Am J Surg.Pathol.* **14**, 1126.
- Cottoni, F. (1996). Reticuloendothelial origin and metastasis of Kaposi's sarcoma: historical update on the literature. *Blood.* **87**, 2605.
- Del val Gómez, M. A., Castro Beiras, J. M., Gallardo, F. G., and Verdejo, J. (1994). Thallium and gallium scintigraphy in pulmonary Kaposi's sarcoma in an HIV-positive patient. *Clin.Nucl.Med.* **19**, 467.
- Delabesse, E., Oksenhendler, E., Lebbe, C., Verola, O., Varet, B., and Turhan, A. G. (1997). Molecular analysis of clonality in Kaposi's sarcoma. *J.Clin.Pathol.* **50**, 664.
- Deziel, D. J., Saclarides, T. J., Marshall, J. S., and Yaremko, L. M. (1991). Appendiceal Kaposi's sarcoma: a cause of right lower quadrant pain in the acquired immune deficiency syndrome. *Am.J.Gastroenterol.* **86**, 901.
- Dorfman, R. F. (1986). Kaposi's sarcoma. With special reference to its manifestations in infants and children and to the concepts of Arthur Purdy Stout. *Am J Surg.Pathol.* **10 Suppl 1**, 68.
- Dorfman, R. F. (1988). Kaposi's sarcoma: evidence supporting its origin from the lymphatic system. *Lymphology.* **21**, 45.
- Dupin, N., Fisher, C., Kellam, P., et al. (1999). Distribution of human herpesvirus-8 latently infected cells in Kaposi's sarcoma, multicentric Castleman's disease, and primary effusion lymphoma. *Proc.Natl.Acad.Sci.U.S.A.* **96**, 4546.
- Ecklund, R. E. and Valaitis, J. (1962). Kaposi's sarcoma of lymph nodes: a case report. *Arch.Pathol.* **74**, 224.

- Epstein, E. (1957). Extracutaneous manifestations Kaposi's sarcoma - a systemic lymphoblastoma. *Calif.Med.* **87**, 98.
- Francis, N. D., Parkin, J. M., Weber, J., and Boylston, A. W. (1986). Kaposi's sarcoma in acquired immune deficiency syndrome (AIDS). *J.Clin.Pathol.* **39**, 469.
- Friedman-Birnbaum, R., Bergman, R., Bitterman-Deutsch, O., Weltfriend, S., and Lichtig, C. (1993). Classic and iatrogenic Kaposi's sarcoma. Histopathological patterns as related to clinical course. *Am.J.Dermatopathol.* **15**, 523.
- Fukunaga, M. and Silverberg, S. G. (1991). Hyaline globules in Kaposi's sarcoma: a light microscopic and immunohistochemical study. *Mod.Pathol.* **4**, 187.
- Galea, P., Frances, V., Dou-Dameche, L., Sampol, J., and Chermann, J. C. (1998). Role of Kaposi's sarcoma cells in recruitment of circulating leukocytes: implications in pathogenesis. *J.Hum.Virol.* **1**, 273.
- Ghadially, R., Sibbald, R. G., Walter, J. B., and Haberman, H. F. (1989). Granuloma annulare in patients with human immunodeficiency virus infections. *J.Am.Acad.Dermatol.* **20**, 232.
- Gill, P. S., Tsai, Y. C., Rao, A. P., et al. (1998). Evidence for multiclonality in multicentric Kaposi's sarcoma. *Proc.Natl.Acad.Sci.U.S.A.* **95**, 8257.
- Gottesman, D., Dyrszka, H., Albarran, J., and Hilfer, J. (1993). AIDS-related hepatic Kaposi's sarcoma: massive bleeding following liver biopsy. *Am.J.Gastroenterol.* **88**, 762.
- Gottlieb, G. J. and Ackerman, A. B. (1982). Kaposi's sarcoma: an extensively disseminated form in young homosexual men. *Hum.Pathol.* **13**, 882.
- Gottlieb, G. J. and Ackerman, A. B. (1989a). Atlas of the gross and microscopic features of simulators. In *Kaposi's Sarcoma: A Text and Atlas*, (Gottlieb, G. J. and Ackerman, A. B., eds.), p.73, Lea & Febiger, Philadelphia.
- Gottlieb, G. J. and Ackerman, A. B. (1989b). Autopsy findings in patients with AIDS. In *Kaposi's Sarcoma: A Text and Atlas*, (Gottlieb, G. J. and Ackerman, A. B., eds.), p.271, Lea & Febiger, Philadelphia.
- Gray, M. H., Trimble, C. L., Zirn, J., McNutt, N. S., Smoller, B. R., and Varghese, M. (1991). Relationship of factor XIIIa-positive dermal dendrocytes to Kaposi's sarcoma. *Arch.Pathol.Lab Med.* **115**, 791.
- Guarda, L. A., Luna, M. A., Smith-JL, Jr, Mansell, P. W., Gyorkey, F., and Roca, A. N. (1984). Acquired immune deficiency syndrome: postmortem findings. *Am J Clin.Pathol.* **81**, 549.

- Harawi, S. J. (1989). Kaposi's sarcoma. *In* Pathology and pathophysiology of AIDS and HIV- related diseases, 1st ed. (Harawi, S. J. and O'Hara, C. J., eds.), p.83, Chapman and Hall Medical, London.
- Herndier, B. G., Werner, A., Arnstein, P., *et al.* (1994). Characterization of a human Kaposi's sarcoma cell line that induces angiogenic tumors in animals. *AIDS*. **8**, 575.
- Holzhausen, H. J., Stiller, D., and Sachs, M. (1988). Morphologische Pathologie des klassischen Kaposi-Sarkoms. Ultrastrukturelle Untersuchungen und Betrachtungen zur Histogenese. [Morphological pathology of classic Kaposi's sarcoma. Ultrastructural studies and reflections on histogenesis]. *Zentralbl.Allg.Pathol.* **134**, 435.
- Huang, Y. Q., Friedman-Kien, A. E., Li, J. J., and Nickoloff, B. J. (1993). Cultured Kaposi's sarcoma cell lines express factor XIIIa, CD14, and VCAM-1, but not factor VIII or ELAM-1. *Arch.Dermatol.* **129**, 1291.
- Hui, A. N., Koss, M. N., and Meyer, P. R. (1984). Necropsy findings in acquired immunodeficiency syndrome: a comparison of premortem diagnoses with postmortem findings. *Hum.Pathol.* **15**, 670.
- Hunt, S. J., Santa Cruz, D. J., and Barr, R. J. (1991). Microvenular hemangioma. *J.Cutan.Pathol.* **18**, 235.
- Jones, R. R., Spaul, J., Spry, C., and Jones, E. W. (1986). Histogenesis of Kaposi's sarcoma in patients with and without acquired immune deficiency syndrome (AIDS). *J.Clin.Pathol.* **39**, 742.
- Judde, J. G., Lacoste, V., Briere, J., *et al.* (2000). Monoclonality or oligoclonality of human herpesvirus 8 terminal repeat sequences in Kaposi's sarcoma and other diseases. *J.Natl.Cancer Inst.* **92**, 729.
- Kalengayi, M. M. and Kashala, L. (1984). Clinicopathological features of Kaposi's sarcoma in Zaire. *IARC Sci.Publ.* 559.
- Kao, G. F., Johnson, F. B., and Sulica, V. I. (1990). The nature of hyaline (eosinophilic) globules and vascular slits of Kaposi's sarcoma. *Am J Dermatopathol.* **12**, 256.
- Karasek, M. A. (1994). Origin of spindle-shaped cells in Kaposi sarcoma. *Lymphology.* **27**, 41.

- Konrad, K., Schenk, P., and Rappersberger, K. (1986). Tubuloreticular structures in Kaposi's sarcoma: a comparison of the classical and AIDS-associated forms. *Acta Derm.Venereol.* **66**, 207.
- LeBoit, P. E., Berger, T. G., Egbert, B. M., Beckstead, J. H., Yen, T. S., and Stoler, M. H. (1989). Bacillary angiomatosis. The histopathology and differential diagnosis of a pseudoneoplastic infection in patients with human immunodeficiency virus disease. *Am.J.Surg.Pathol.* **13**, 909.
- LeBoit, P. E., Berger, T. G., Egbert, B. M., et al. (1988). Epithelioid haemangioma-like vascular proliferation in AIDS: manifestation of cat scratch disease bacillus infection? *Lancet.* **1**, 960.
- Lee, F. D. (1968). A comparative study of Kaposi's sarcoma and granuloma pyogenicum in Uganda. *J Clin.Pathol.* **21**, 119.
- Lee, V. W., Fuller, J. D., O'Brien, M. J., Parker, D. R., Cooley, T. P., and Liebman, H. A. (1991). Pulmonary Kaposi sarcoma in patients with AIDS: scintigraphic diagnosis with sequential thallium and gallium scanning. *Radiology.* **180**, 409.
- Leu, H. J. and Odermatt, B. (1985). Multicentric angiosarcoma (Kaposi's sarcoma). Light and electron microscopic and immunohistological findings of idiopathic cases in Europe and Africa and of cases associated with AIDS. *Virchows Arch.A Pathol.Anat.Histopathol.* **408**, 29.
- Lothe, F. and Murray, J. F. (1962). Kaposi's sarcoma: Autopsy findings in the African. *Acta.Un.Int.Cancer.* **18**, 429.
- Macmillan, A. and Champion, R. H. (1971). Progressive capillary haemangioma. *Br.J.Dermatol.* **85**, 492.
- Mali, J. W., Kuiper, J. P., and Hamers, A. A. (1965). Acro-angiodermatitis of the foot. *Arch.Dermatol.* **92**, 515.
- Massarelli, G., Scott, C. A., Mura, A., Tanda, F., and Cossu, A. (1989). Hyaline bodies in Kaposi's sarcoma: an immunocytochemical and ultrastructural study. *Appl.Pathol.* **7**, 26 .
- Master, S. P., Taylor, J. F., Kyalwazi, S. K., and Ziegler, J. L. (1970). Immunological studies in Kaposi's sarcoma in Uganda. *Br.Med.J.* **1**, 600.
- Matondo, P. and Zumla, A. (1996). The spectrum of African Kaposi's sarcoma: is it consequential upon diverse immunological responses? *Scand.J.Infect.Dis.* **28**, 225.

- McNutt, N. S., Fletcher, V., and Conant, M. A. (1983). Early lesions of Kaposi's sarcoma in homosexual men. An ultrastructural comparison with other vascular proliferations in skin. *Am.J.Pathol.* **111**, 62.
- Moosa, M. R. and Bouwens, C. (1997). Tuberculosis in renal allograft recipients: The South African experience. *Transplant Rev.* **11**, 84.
- Moskowitz, L. B., Hensley, G. T., Gould, E. W., and Weiss, S. D. (1985). Frequency and anatomic distribution of lymphadenopathic Kaposi's sarcoma in the acquired immunodeficiency syndrome: an autopsy series. *Hum.Pathol.* **16**, 447.
- Muller, R., Hajdu, S. I., and Brennan, M. F. (1987). Lymphangiosarcoma associated with chronic filarial lymphedema. *Cancer.* **59**, 179.
- Nakagawa, K. (1949). Case report of angioblastoma of the skin. *Nippon Hifuka Gakki Zasshi.* **59**, 92.
- Nesbitt, S., Mark, P. F., and Zimmerman, H. M. (1945). Disseminated visceral idiopathic sarcoma (Kaposi's disease). Report of a case with necropsy findings. *Ann.Intern.Med.* **22**, 601.
- Nickoloff, B. J. and Griffiths, C. E. (1989). The spindle-shaped cells in cutaneous Kaposi's sarcoma. Histologic simulators include factor XIIIa dermal dendrocytes. *Am.J.Pathol.* **135**, 793.
- Niedt, G. W., Myskowski, P. L., Urmacher, C., Niedzwiecki, D., Chapman, D., and Safai, B. (1990). Histology of early lesions of AIDS-associated Kaposi's sarcoma. *Mod.Pathol.* **3**, 64.
- Niedt, G. W. and Schinella, R. A. (1985). Acquired immunodeficiency syndrome. Clinicopathologic study of 56 autopsies. *Arch.Pathol.Lab Med.* **109**, 727.
- O'Connell, K. A. and Rudmann, A. A. (1993). Cloned spindle and epithelioid cells from murine Kaposi's sarcoma-like tumors are of endothelial origin. *J.Invest Dermatol.* **100**, 742 .
- O'Connell, K. M. (1977a). Kaposi's sarcoma in lymph nodes: histological study of lesions from 16 cases in Malawi. *J Clin.Pathol.* **30**, 696.
- O'Connell, K. M. (1977b). Kaposi's sarcoma: histopathological study of 159 cases from Malawi. *J Clin.Pathol.* **30**, 687.
- Presant, C. A., Blayney, D., Proffitt, R. T., et al. (1990). Preliminary report: imaging of Kaposi sarcoma and lymphoma in AIDS with indium-111-labelled liposomes. *Lancet.* **335**, 1307.

- Primack, S. L. and Muller, N. L. (1994). High-resolution computed tomography in acute diffuse lung disease in the immunocompromised patient. *Radiol.Clin.North Am.* **32**, 731.
- Purdy, L. J., Colby, T. V., Yousem, S. A., and Battifora, H. (1986). Pulmonary Kaposi's sarcoma. Premortem histologic diagnosis. *Am.J.Surg.Pathol.* **10**, 301.
- Qunibi, W., Akhtar, M., Sheth, K., et al. (1988). Kaposi's sarcoma: The most common tumor after renal transplantation in Saudi Arabia. *Am.J.Med.* **84**, 225 .
- Rabkin, C. S., Janz, S., Lash, A, et al. (1997). Monoclonal origin of multicentric Kaposi's sarcoma lesions. *N.Engl.J Med.* **336**, 988.
- Reichert, C. M., O'Leary, T. J., Levens, D. L., Simrell, C. R., and Macher, A. M. (1983). Autopsy pathology in the acquired immune deficiency syndrome. *Am.J.Pathol.* **112**, 357.
- Reitz, M. S., Nerurkar, L. S., and Gallo, R. C. (1999). Perspective on Kaposi's sarcoma: facts, concepts, and conjectures. *J.Natl.Cancer Inst.* **91**, 1453.
- Requena, L. and Sanguenza, O. P. (1997). Cutaneous vascular proliferation. Part II. Hyperplasias and benign neoplasms. *J.Am.Acad.Dermatol.* **37**, 887.
- Reynolds, W. A., Winkelmann, R. K., and Soule, E. H. (1965). Kaposi's sarcoma: a clinicopathologic study with particular reference to its relationship to the reticuloendothelial system. *Medicine (Baltimore).* **44**, 419.
- Roth, W. K., Brandstetter, H., and Sturzl, M. (1992). Cellular and molecular features of HIV-associated Kaposi's sarcoma [editorial] [published erratum appears in AIDS 1992 Nov;6(11):following 1410]. *AIDS.* **6**, 895.
- Rothman, S. (2001). Some remarks of Moricz Kaposi and on the history of Kaposi's sarcoma. *Acta.Un.Int.Cancer.* **18**, 322.
- Ruszczak, Z., Mayer-Da-Silva, A., and Orfanos, C. E. (1987). Kaposi's sarcoma in AIDS. Multicentric angioneoplasia in early skin lesions. *Am.J.Dermatopathol.* **9**, 388.
- Safai, B. (1984). Kaposi's sarcoma: a review of the classical and epidemic forms. *Ann.N.Y.Acad.Sci.* **437**, 373.
- Sanchez, J. L. and Ackerman, A. B. (1993). Vascular proliferations of the skin and subcutaneous fat. In *Dermatology in General Practice* , 4th ed. (Fitzpatrick, T. B., Eisen, A. Z., Wolff, K., Freedberg, I. M., and Austen, K. F., eds.), p.1209, McGraw-Hill, New York.

- Santa Cruz, D. J. and Aronberg, J. (1988). Targetoid hemosiderotic hemangioma. *J.Am.Acad.Dermatol.* **19**, 550.
- Santucci, M., Pimpinelli, N., Moretti, S., and Giannotti, B. (1988). Classic and immunodeficiency-associated Kaposi's sarcoma. Clinical, histologic, and immunologic correlations. *Arch.Pathol.Lab Med.* **112**, 1214.
- Schenk, P. (1986). Erythrophagocytosis in Kaposi's sarcoma in acquired immune deficiency syndrome. *ORL J.Otorhinolaryngol.Relat Spec.* **48**, 167.
- Schulze, H. J., Rutten, A., Mahrle, G., and Steigleder, G. K. (1987). Initial lesions of HIV-related Kaposi's sarcoma--a histological, immunohistochemical, and ultrastructural study. *Arch.Dermatol.Res.* **279**, 499.
- Schwartz, R. A. (1996). Kaposi's sarcoma: advances and perspectives. *J Am Acad.Dermatol.* **34**, 804 .
- Sidransky, D., Frost, P., Von Eschenbach, A., Oyasu, R., Preisinger, A. C., and Vogelstein, B. (1992). Clonal origin bladder cancer. *N.Engl.J.Med.* **326**, 737.
- Siegel, J. H., Janis, R., Alper, J. C., Schutte, H., Robbins, L., and Blaufox, M. D. (1969). Disseminated visceral Kaposi's sarcoma. Appearance after human renal homograft operation. *JAMA.* **207**, 1493.
- Sitas, F., Carrara, H., Beral, V., *et al.* (1999). Antibodies against human herpesvirus 8 in black South African patients with cancer [see comments]. *N.Engl.J.Med.* **340**, 1863.
- Staskus, K. A., Sun, R., Miller, G., *et al.* (1999). Cellular tropism and viral interleukin-6 expression distinguish human herpesvirus 8 involvement in Kaposi's sarcoma, primary effusion lymphoma, and multicentric Castleman's disease. *J.Virol.* **73**, 4181.
- Stoler, M. H., Bonfiglio, T. A., Steigbigel, R. T., and Pereira, M. (1983). An atypical subcutaneous infection associated with acquired immune deficiency syndrome. *Am.J.Clin.Pathol.* **80**, 714.
- Strutton, G. and Weedon, D. (1987). Acro-angiodermatitis. A simulant of Kaposi's sarcoma. *Am.J.Dermatopathol.* **9**, 85.
- Szaniawski, W. K., Don, P. C., Bitterman, S. R., and Schachner, J. R. (1990). Epithelioid angiomatosis in patients with AIDS. Report of seven cases and review of the literature. *J.Am.Acad.Dermatol.* **23**, 41.

- Tappero, J. W., Conant, M. A., Wolfe, S. F., and Berger, T. G. (1993). Kaposi's sarcoma. Epidemiology, pathogenesis, histology, clinical spectrum, staging criteria and therapy. *J Am Acad.Dermatol.* **28**, 371.
- Taylor, J. F., Templeton, A. C., Vogel, C. L., Ziegler, J. L., and Kyalwazi, S. K. (1971). Kaposi's sarcoma in Uganda: a clinico-pathological study. *Int.J Cancer.* **8**, 122.
- Temime, P., Stahl, A., and Berard-Badier, M. (1961). The visceral lesions of Kaposi's sarcoma. *Br J Dermatol.* **73**, 303.
- Templeton, A. C. (1972). Studies in Kaposi's sarcoma. Postmortem findings and disease patterns in women. *Cancer.* **30**, 854.
- Templeton, A. C. (1981). Kaposi's sarcoma. *Pathol Annu.* **16**, 315.
- Thijs, A. (1957). L'Angiosarcomatose de Kaposi au Congo Belge et au Ruanada-Urundi. *Ann.Soc.Belge.Med.Trop.* **37**, 295.
- Uys, C. J. and Bennett, M. B. (1959). Kaposi's sarcoma: A neoplasm of reticular origin. *S.Afr.J.Lab.J.Clin.Med.* **5**, 39.
- Valcuende-Cavero, F., Febrer-Bosch, M. I., and Castells-Rodellas, A. (1994). Langerhans' cells and lymphocytic infiltrate in AIDS-associated Kaposi's sarcoma. An immunohistochemical study. *Acta Derm.Venereol.* **74**, 183.
- Waldo, E. and Sidhu, G. S. (1989). Electron microscopy. In Kaposi's Sarcoma: A Text and Atlas,(Gottlieb, G. J. and Ackerman, A. B., eds.), p.129, Lea & Febiger, Philadelphia.
- Weiss, R. and Boshoff, C. (2000). Addressing controversies over Kaposi's sarcoma. *J.Natl.Cancer Inst.* **92**, 677.
- Weiss, S. W. and Enzinger, F. M. (1986b). Spindle cell hemangioendothelioma. A low-grade angiosarcoma resembling a cavernous hemangioma and Kaposi's sarcoma. *Am J Surg.Pathol.* **10**, 521.
- Weiss, S. W. and Enzinger, F. M. (1986a). Spindle cell hemangioendothelioma. A low-grade angiosarcoma resembling a cavernous hemangioma and Kaposi's sarcoma. *Am.J.Surg.Pathol.* **10**, 521.
- Welch, K., Finkbeiner, W., Alpers, C. E., et al. (1984). Autopsy findings in the acquired immune deficiency syndrome. *JAMA.* **252**, 1152.
- Wilson Jones, E. (1976). Dowling oration 1976. Malignant vascular tumours. *Clin.Exp.Dermatol.* **1**, 287.

- Wilson Jones, E. and Orkin, M. (1989). Tufted angioma (angioblastoma). A benign progressive angioma, not to be confused with Kaposi's sarcoma or low-grade angiosarcoma. *J.Am.Acad.Dermatol.* **20**, 214.
- Wilson Jones, E., Winkelmann, R. K., Zachary, C. B., and Reda, A. M. (1990). Benign lymphangi endothelioma. *J.Am.Acad.Dermatol.* **23**, 229.
- Zhang, Y. M., Bachmann, S., Hemmer, C., *et al.* (1994). Vascular origin of Kaposi's sarcoma. Expression of leukocyte adhesion molecule-1, thrombomodulin, and tissue factor. *Am.J.Pathol.* **144**, 51.

PATHOLOGY

All sections of Kaposi's sarcoma have been derived from our own patients. All the common varieties of the disease have been depicted with comments on the main features of each. The sections on the differential diagnosis have been supplied courtesy of Professor J. Schneider, Head, Department of Anatomical Pathology, Faculty of Health Sciences, University of Stellenbosch, from his own collection.

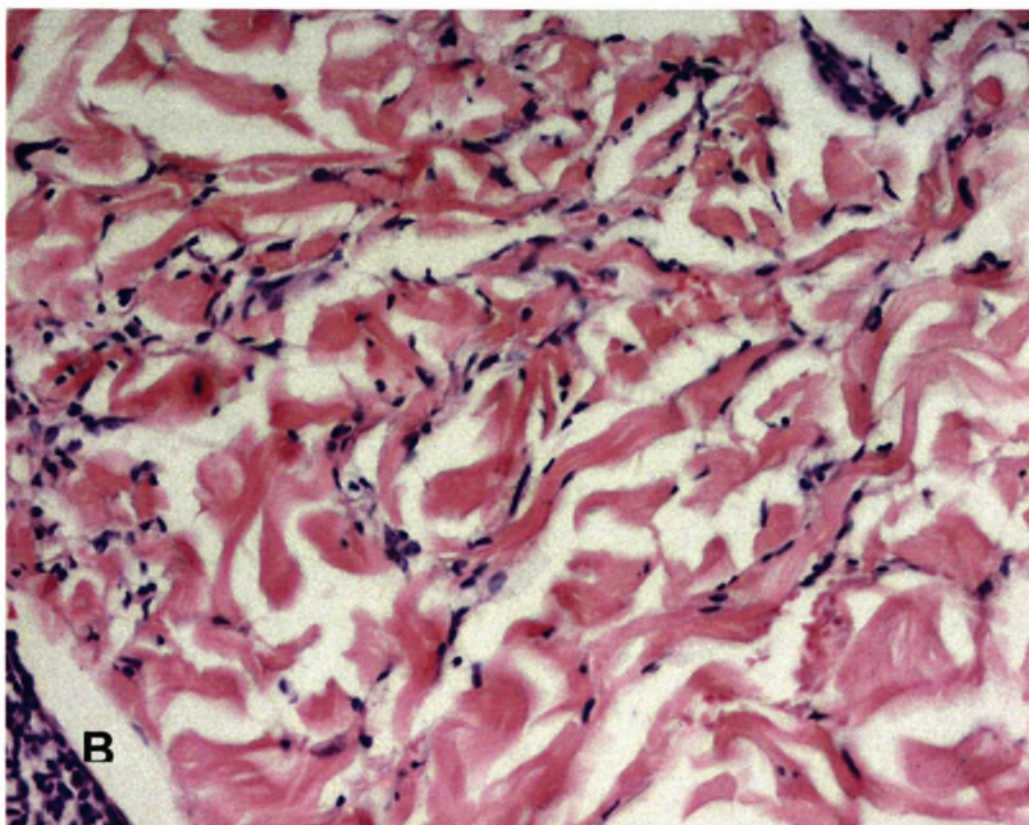
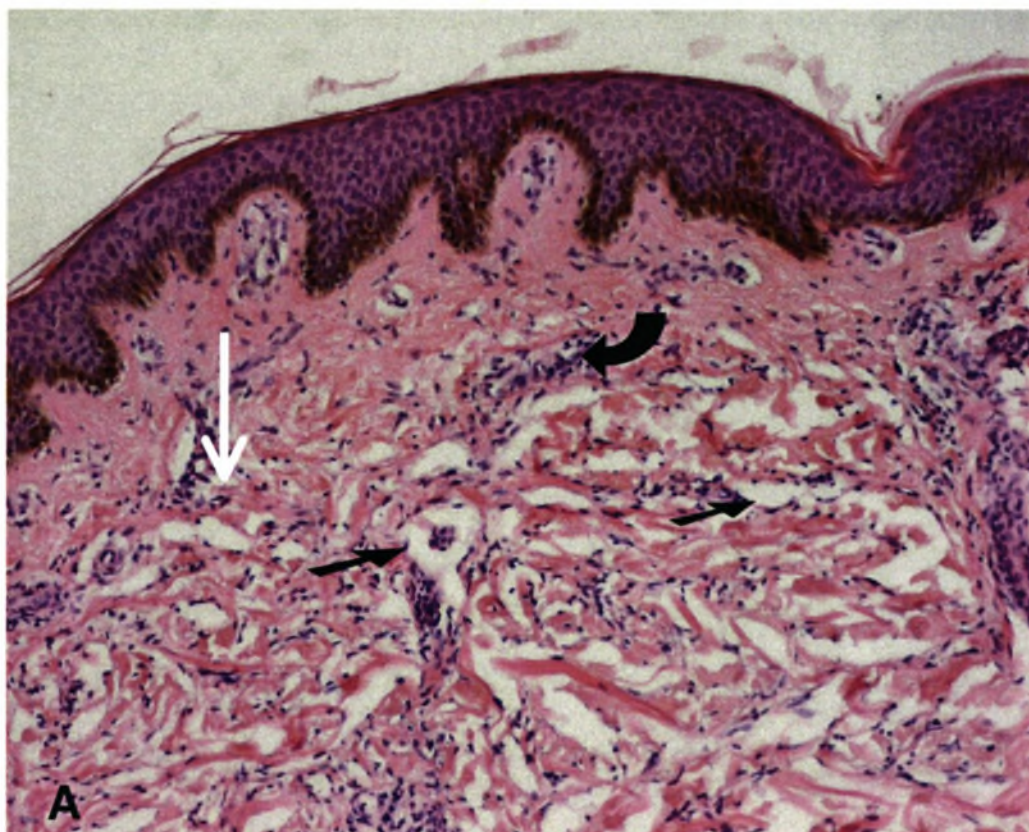


Fig. 10-3 (A, B) Early Kaposi's sarcoma

The earliest histological changes in the skin in Kaposi's sarcoma are present in macules and patches. These early changes in the patch stage can be very subtle

and can be confused with a number of inflammatory dermatoses. The changes are seen predominantly in the upper half of the dermis and around pre-existing vascular structures. The early lesions have two main features. Firstly, there are the very delicate, irregular and thin walled vascular spaces, which dissect between collagen bundles (*black arrows*). These vessels are concentrated around pre-existing blood vessels and adnexal structures (such as hair follicles or hair erector muscles), and tend to be oriented parallel to the epidermis. Mitoses and cytologic abnormalities are not prominent features. The second feature of early Kaposi's sarcoma is the presence of aggregations of cells that are fairly uniform and surround pre-existing vascular complexes (*white arrow*). Note the scanty mononuclear inflammatory cells that are typically present at all stages of Kaposi's sarcoma (*curved arrow*). (B) Higher magnification emphasises the subtle dissecting vascular spaces between collagen bundles. Note the absence of mitotic figures and the presence of the increased number of dilated thin-walled, interconnecting vascular spaces with jagged and irregular configurations lined by thin, flat endothelial cells. A sparse mononuclear infiltrate is present around some of the vessels.

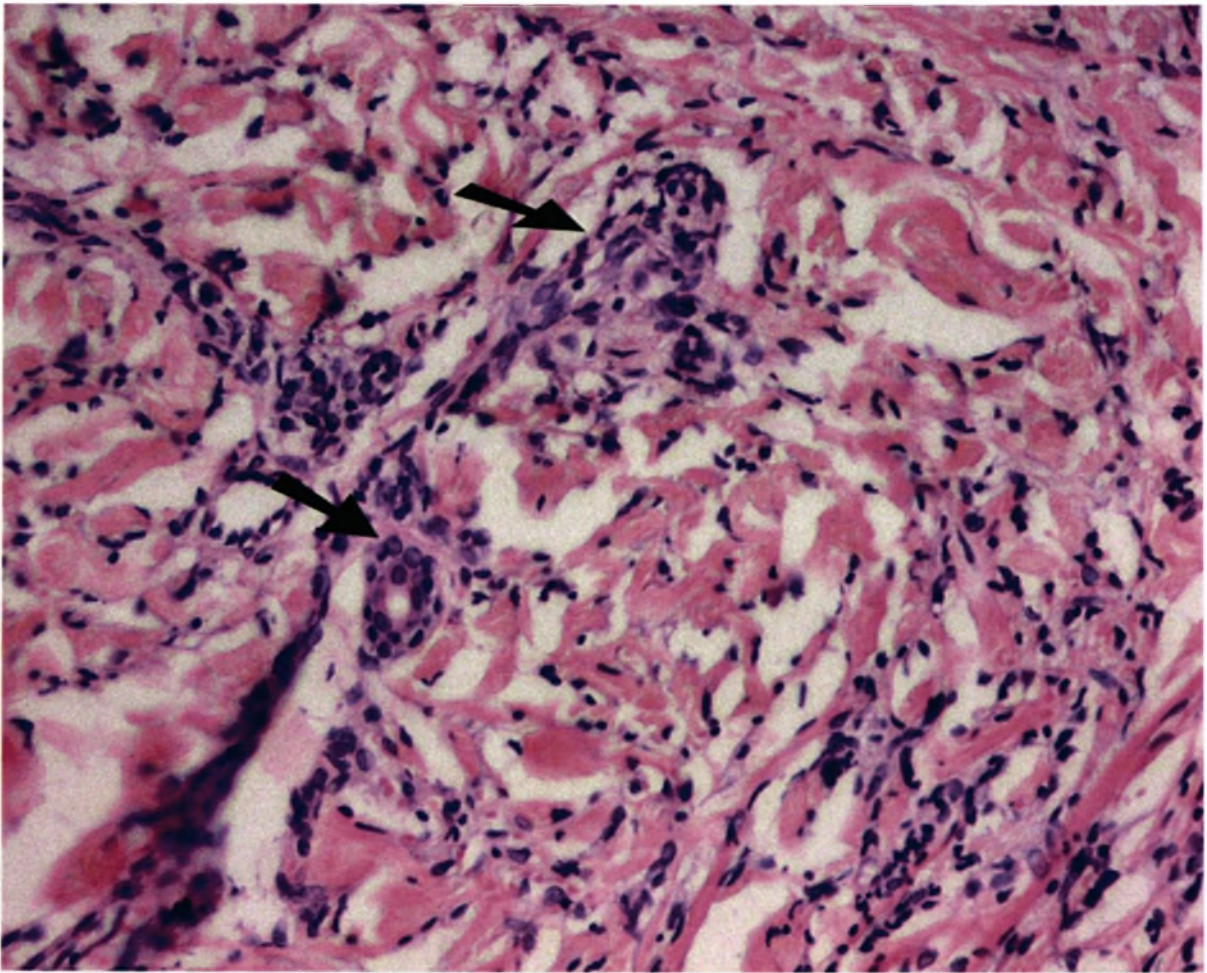


Fig. 10-4 Early Kaposi's sarcoma

The so-called "promontory" phenomenon is illustrated here, with dissecting vascular spaces surrounding native blood vessels and cutaneous adnexae with apparent separation from the adjacent stroma (*arrows*). This "promontory" sign is a helpful clue to the diagnosis of Kaposi's sarcoma but is not diagnostic because it can rarely be seen in haemangiomas. The "promontory" sign is characteristic of the early (patch and plaque) stages of the disease.

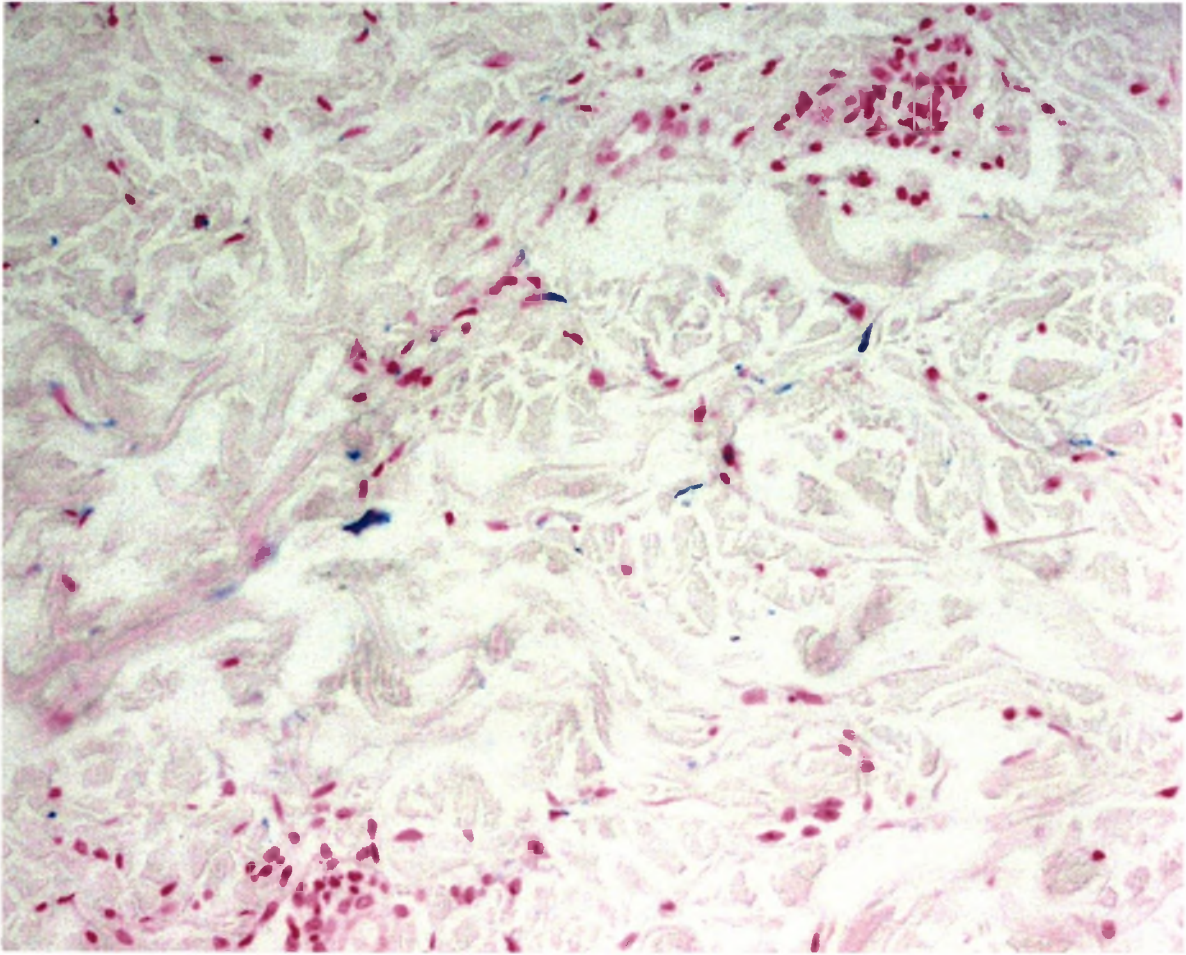


Fig. 10-5 *Early Kaposi's sarcoma (Perl's stain)*

This stain highlights the blue-staining hemosiderin pigment that occurs in early Kaposi's sarcoma. It is however not a constant finding. Dermal haemorrhage may also be present in the early stages of the disease.

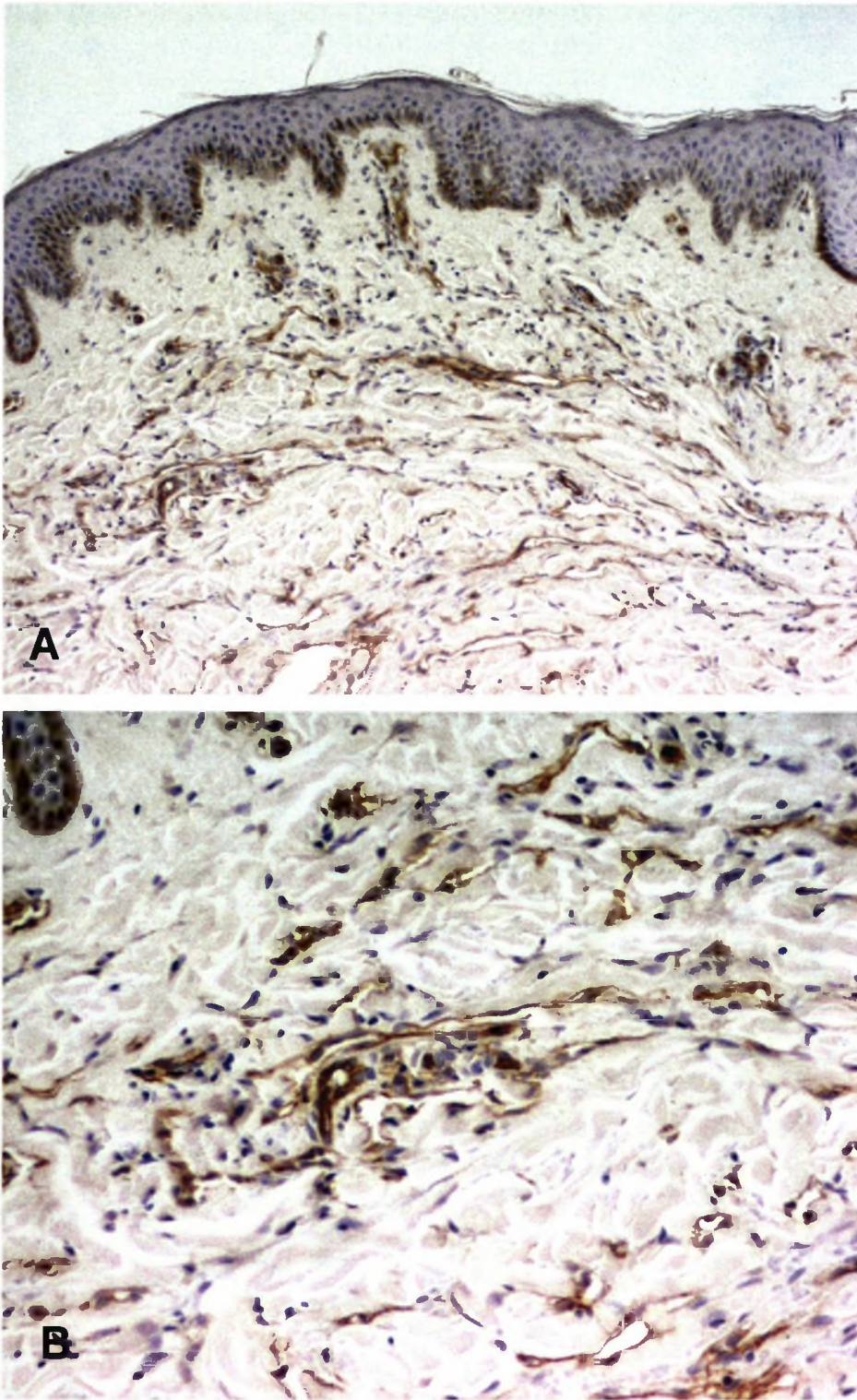


Fig. 10-6 (A, B) Early Kaposi's sarcoma immunohistochemistry for CD 31.

Two magnifications of the positive staining for CD 31 antigen that decorates the spindle cells between the collagen bundles and confirms their endothelial origin.

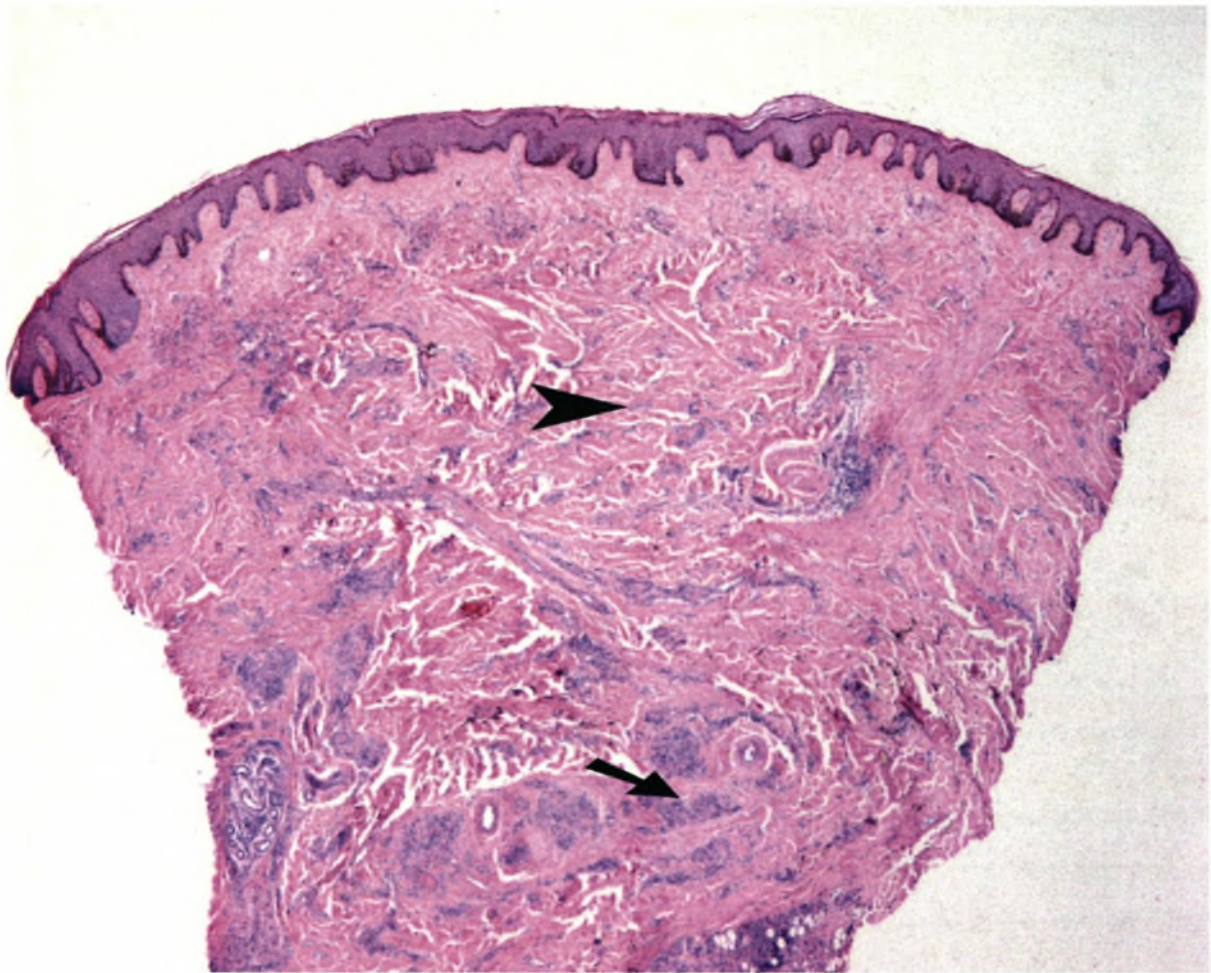


Fig. 10-7 *Mixed cell Kaposi's sarcoma*

The changes that occur in the papules and plaques of Kaposi's sarcoma are merely exaggerations of those of the earlier lesions. This stage corresponds with mixed Kaposi's sarcoma and involves the entire reticular dermis and occasionally the subcutis. Demonstrated here is a plaque of Kaposi's sarcoma at low magnification showing the presence of both dissecting vascular spaces (*arrow point*) and spindle cell areas (*arrow*) throughout the dermis.

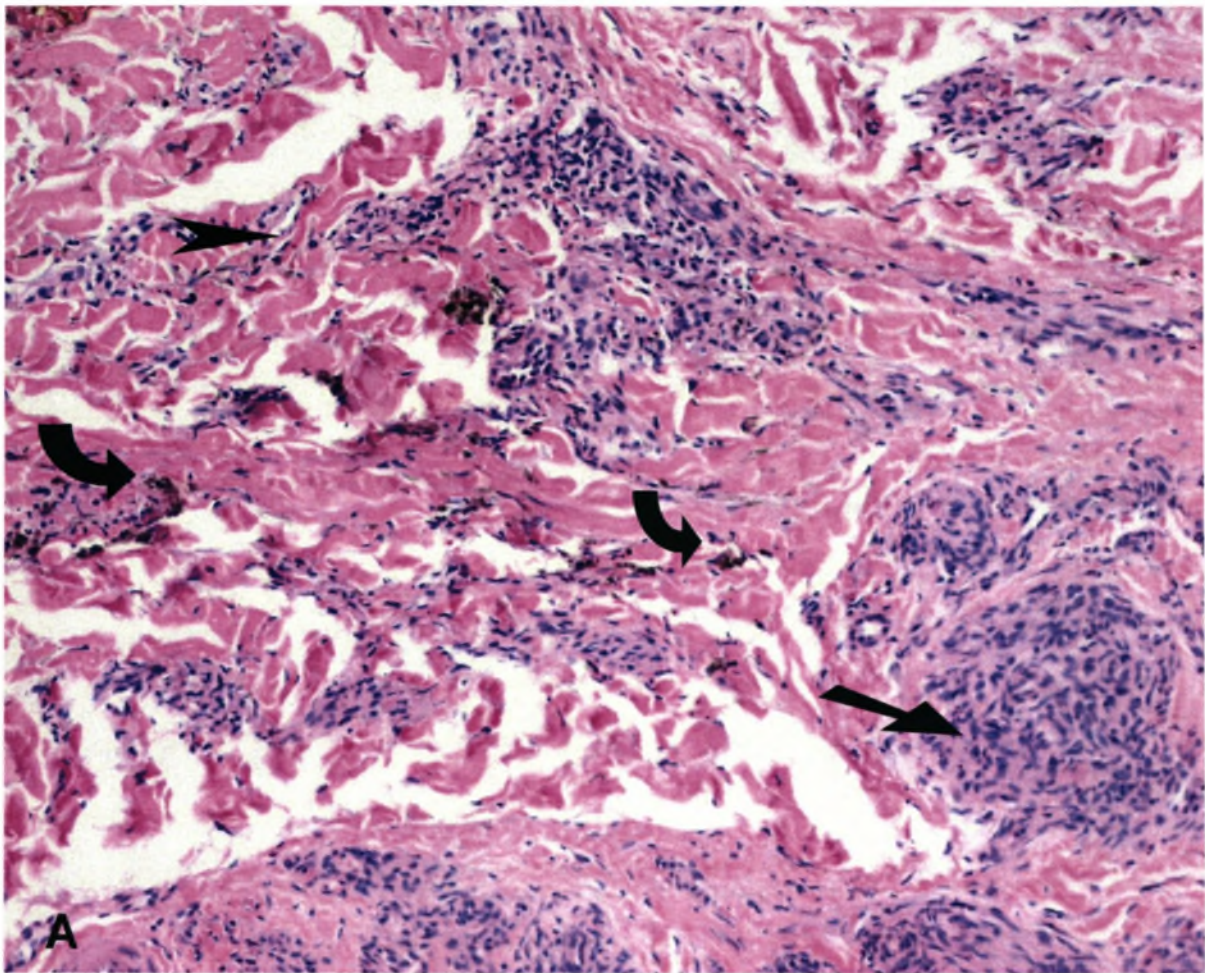
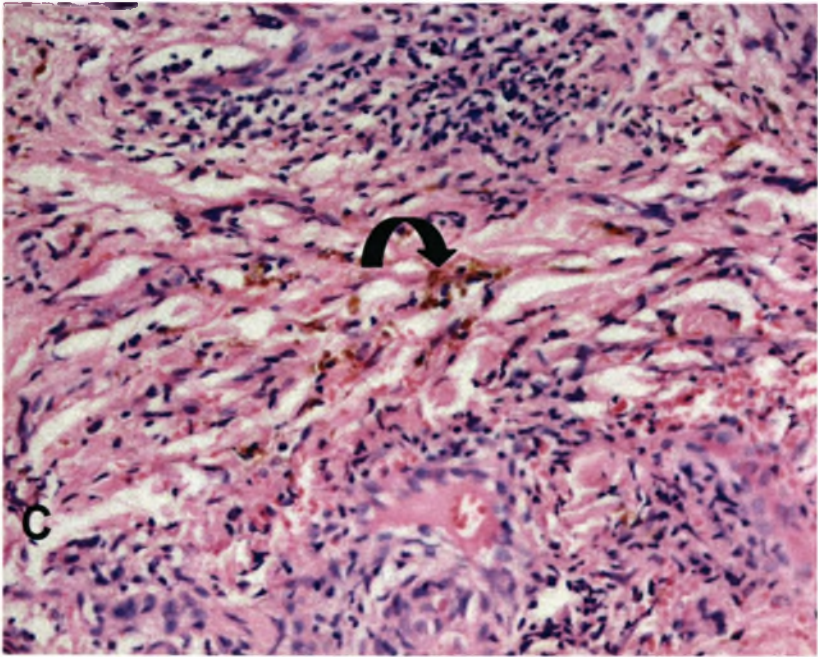
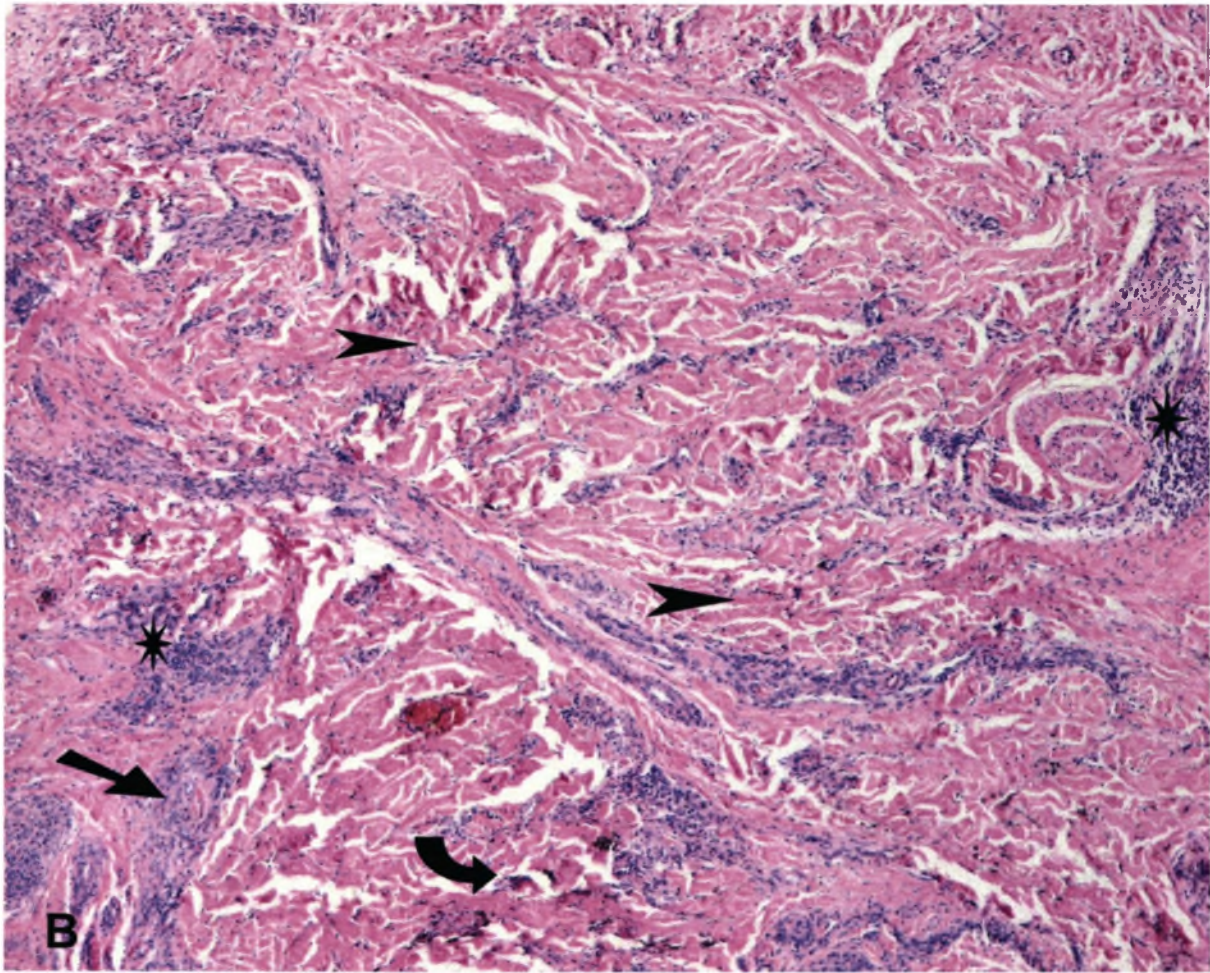


Fig. 10-8 (A, B, C) *Mixed cell Kaposi's sarcoma*

These features are clearer at higher magnification. Note that in addition to the vascular spaces (*arrow point*) and spindle cell areas (*arrow*) there are hemosiderin deposits (*circular arrow*) and inflammatory cells (*star*). The malignant cells resemble collections of epithelioid histiocytes (and have been referred to the "pseudogranulomatous" pattern) but form small spaces that contain a few red cells. Many of the interstitial spindle cells line tiny pointed vascular spaces.



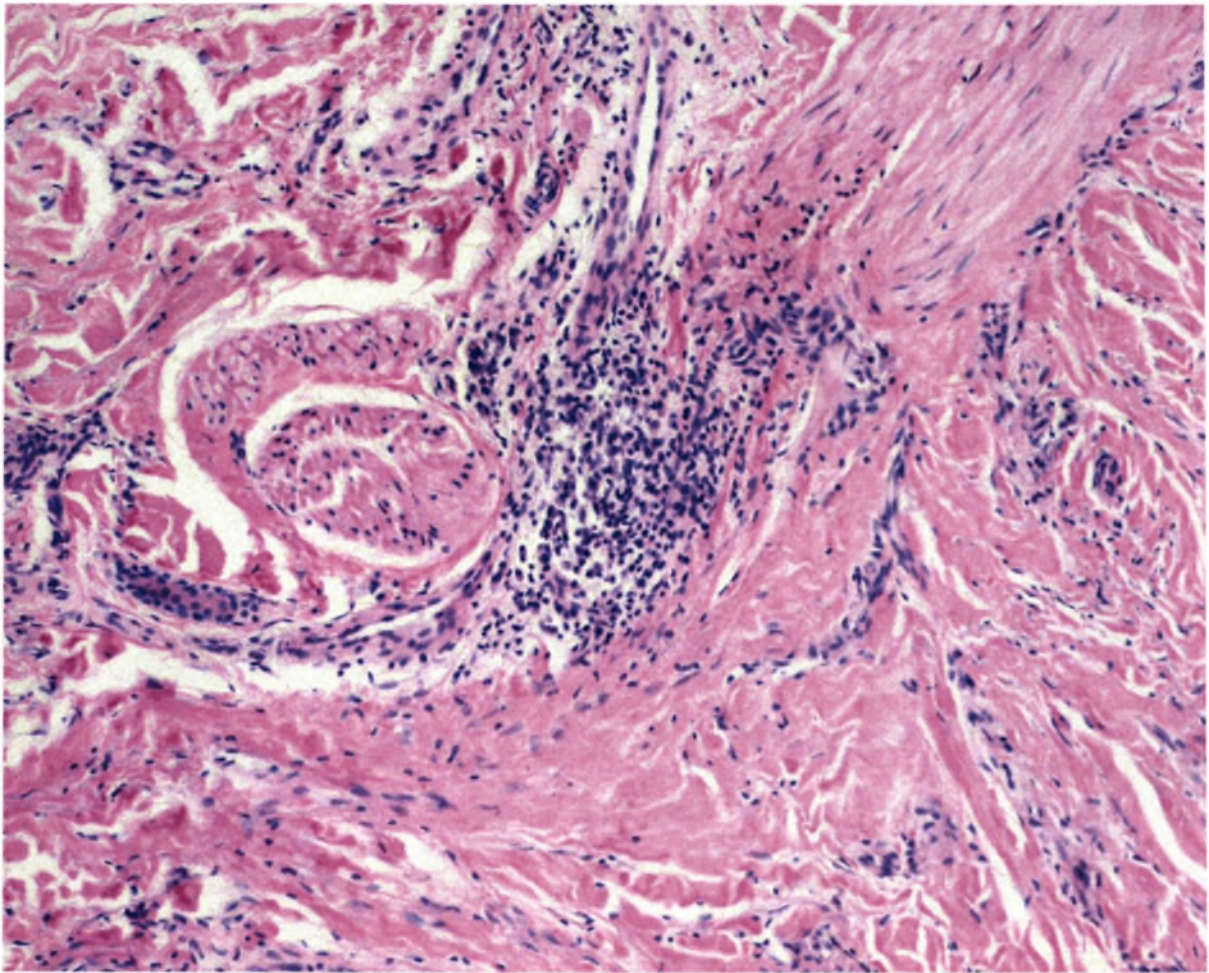


Fig. 10-9 *Mixed cell Kaposi's sarcoma*

Mononuclear inflammatory cells are well demonstrated in association with the vascular proliferation. The process is more cellular but still present are the interadnexal and vasocentric changes consisting of the abnormal vascular structures with their bizarre shapes and the infiltrate of inflammatory cells. In addition, extending well away from existing vascular plexuses, there may be numerous, relatively uniform spindle cells between collagen bundles where they are associated with prominent clefts.

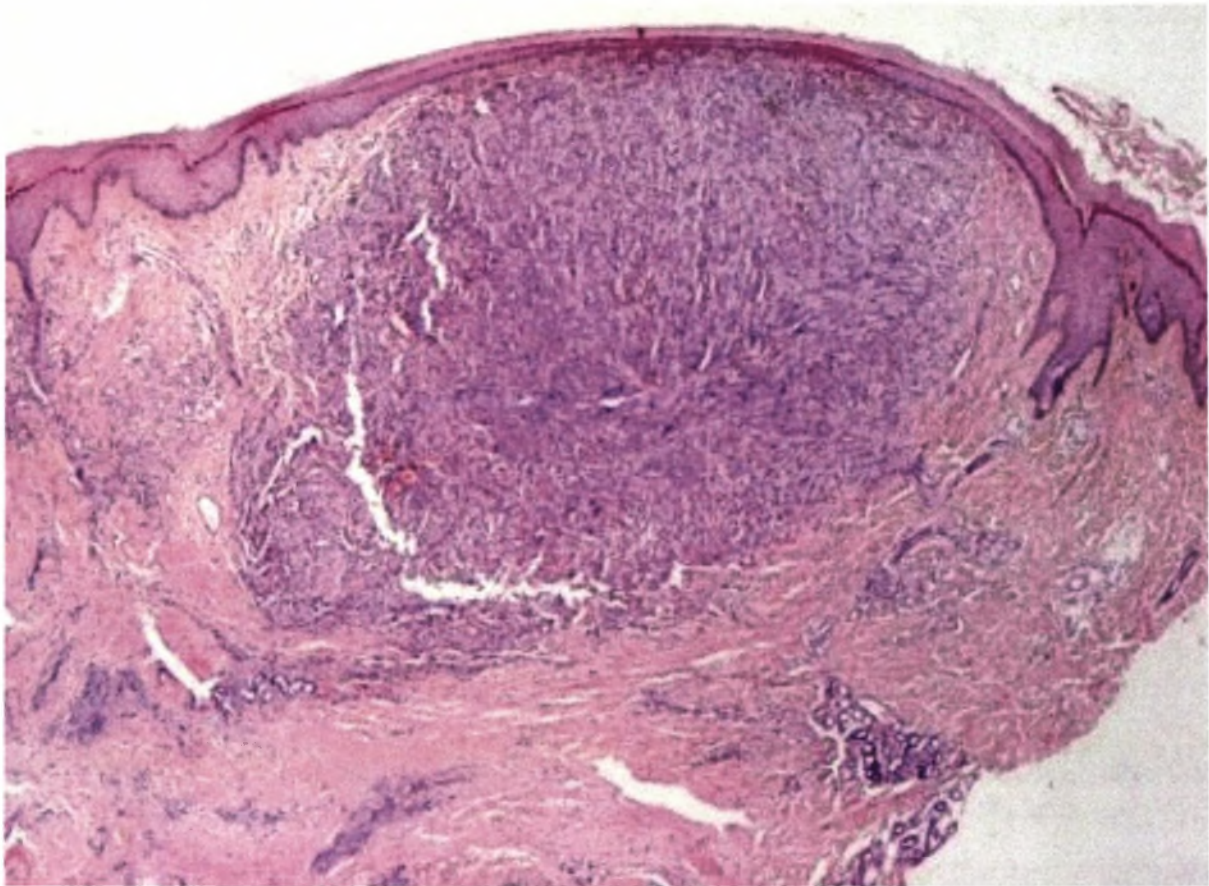


Fig. 10-10 *Nodular Kaposi's sarcoma*

In time some of the earlier lesions of Kaposi's sarcoma become nodules and tumours. A nodular lesion may occupy any part or all of the dermis. At this stage the lesion consists of predominantly nodular aggregates of spindle cells that involve the dermis with occasional extension into the deeper subcutaneous tissue. A nodule may be a single, discrete spherical mass (*above*) or it may be the coalescence or juxtaposition of several smaller nodules (*see below*). Plasma cells are often present.

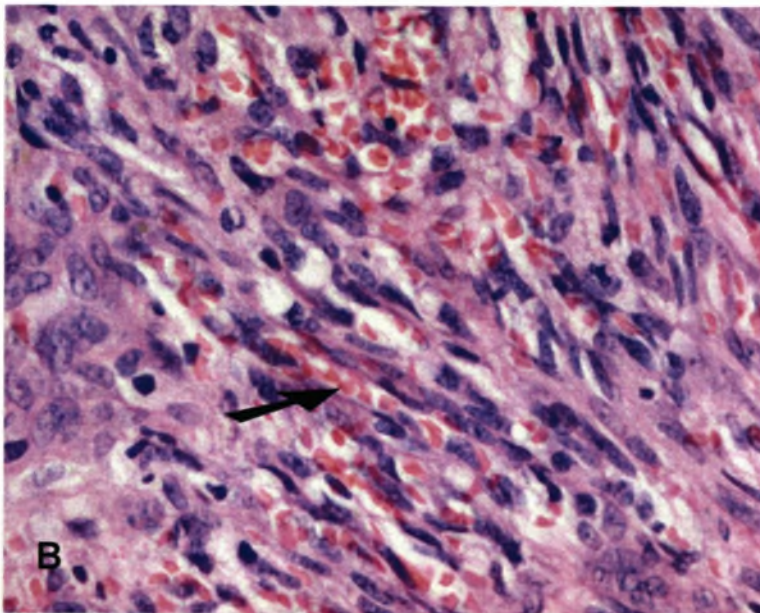
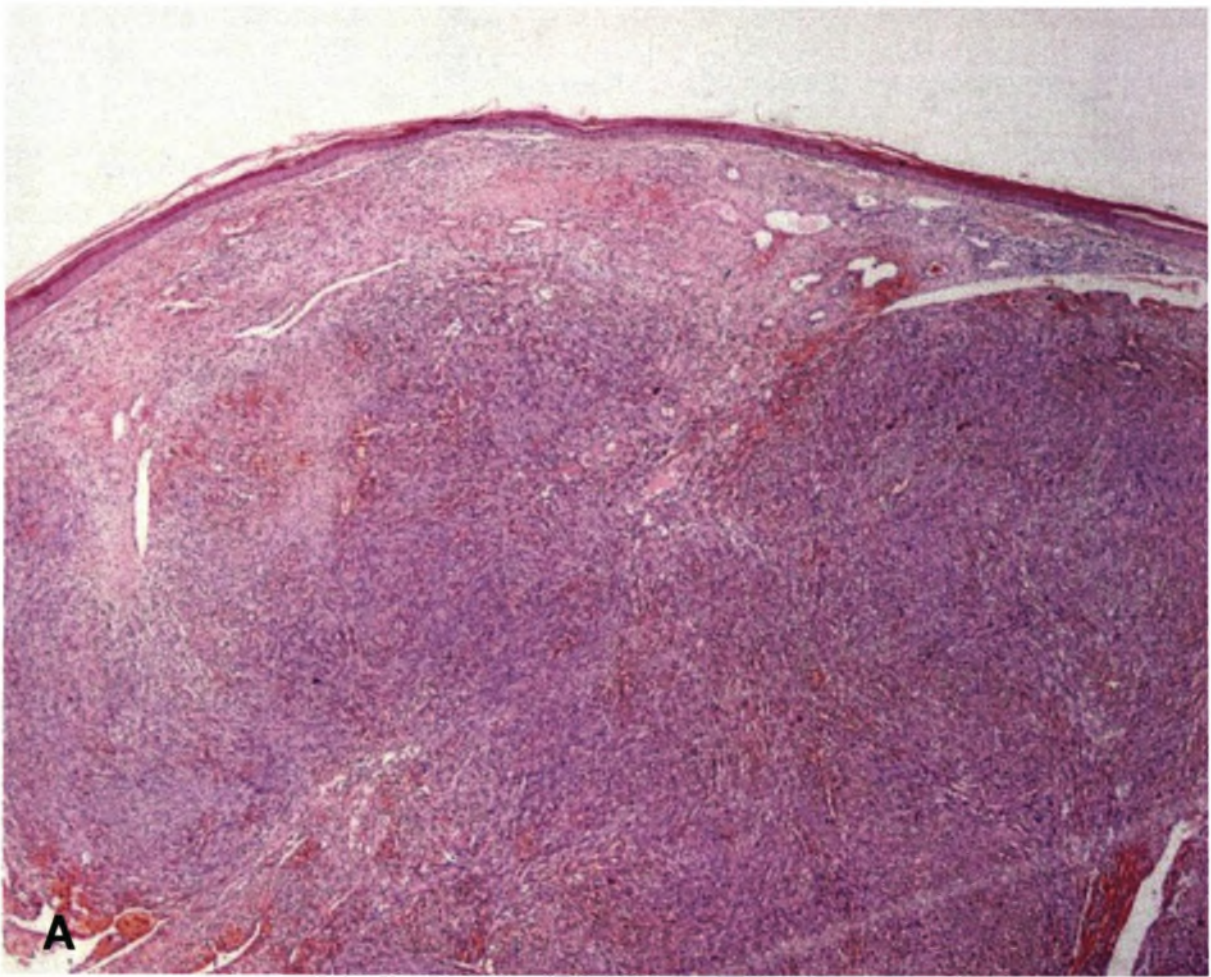


Fig. 10-11 (A,B) Nodular Kaposi's sarcoma

The spindle cells that predominate in this stage form interweaving fascicles with red cells trapped in the spaces between the spindle cells (*arrow*). In contrast to the early stages, spindle cells show cytologic atypia and pleomorphism.

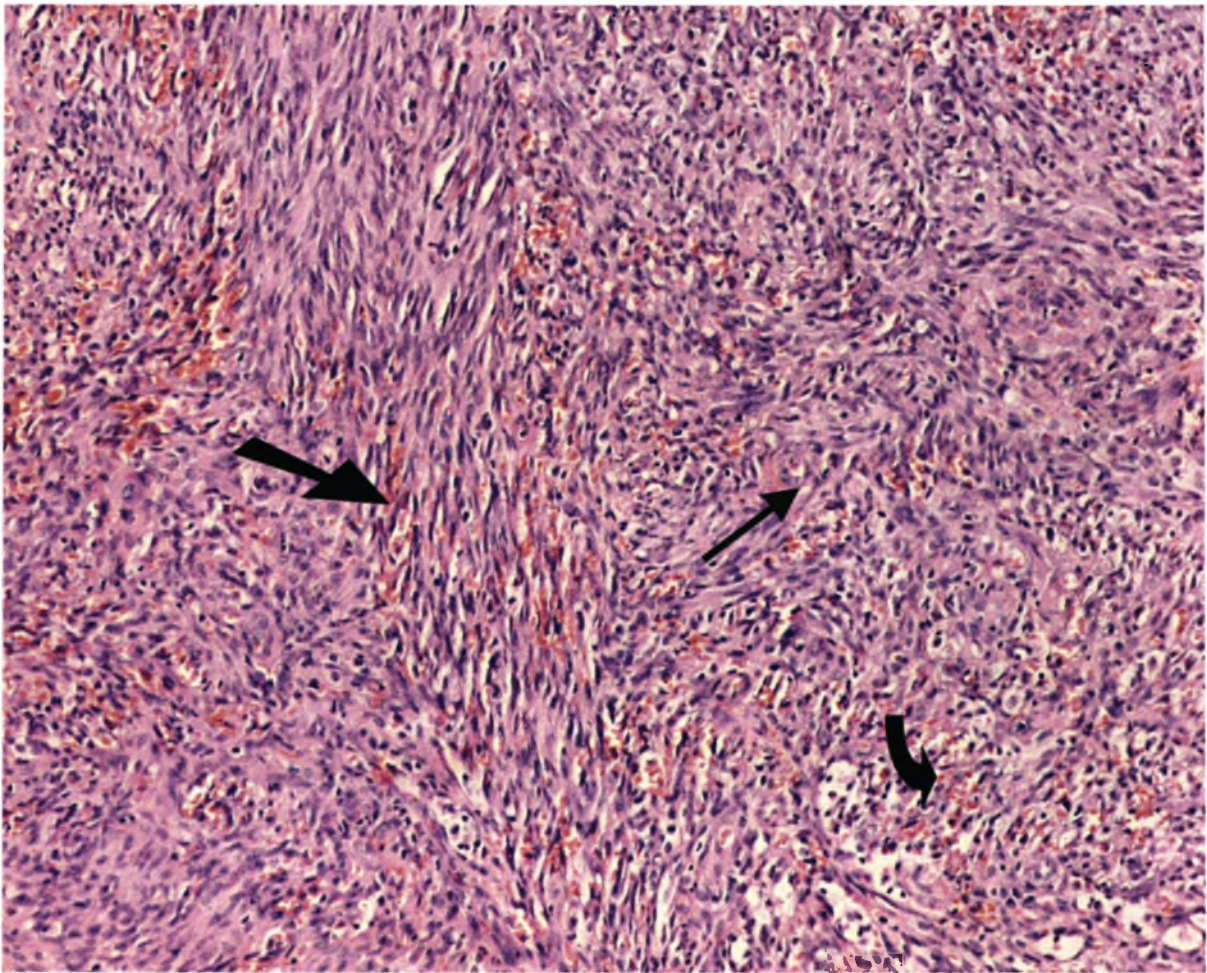


Fig. 10-12 Nodular Kaposi's sarcoma

In this stage spindle cells proliferate in long fascicles. Note the blood-filled slits between tumour cells (*arrow*). Tangential sectioning of fascicles with clefts result in a sieve-like appearance with numerous extravasated red blood cells (*curved arrow*). The advanced lesions of Kaposi's sarcoma often bear little resemblance to the early lesions. Vascular channels both endothelial-lined and formed by the fascicles of spindle cells predominate in this stage of the disease and inflammatory cell infiltrates are less prominent than in the earlier stages.

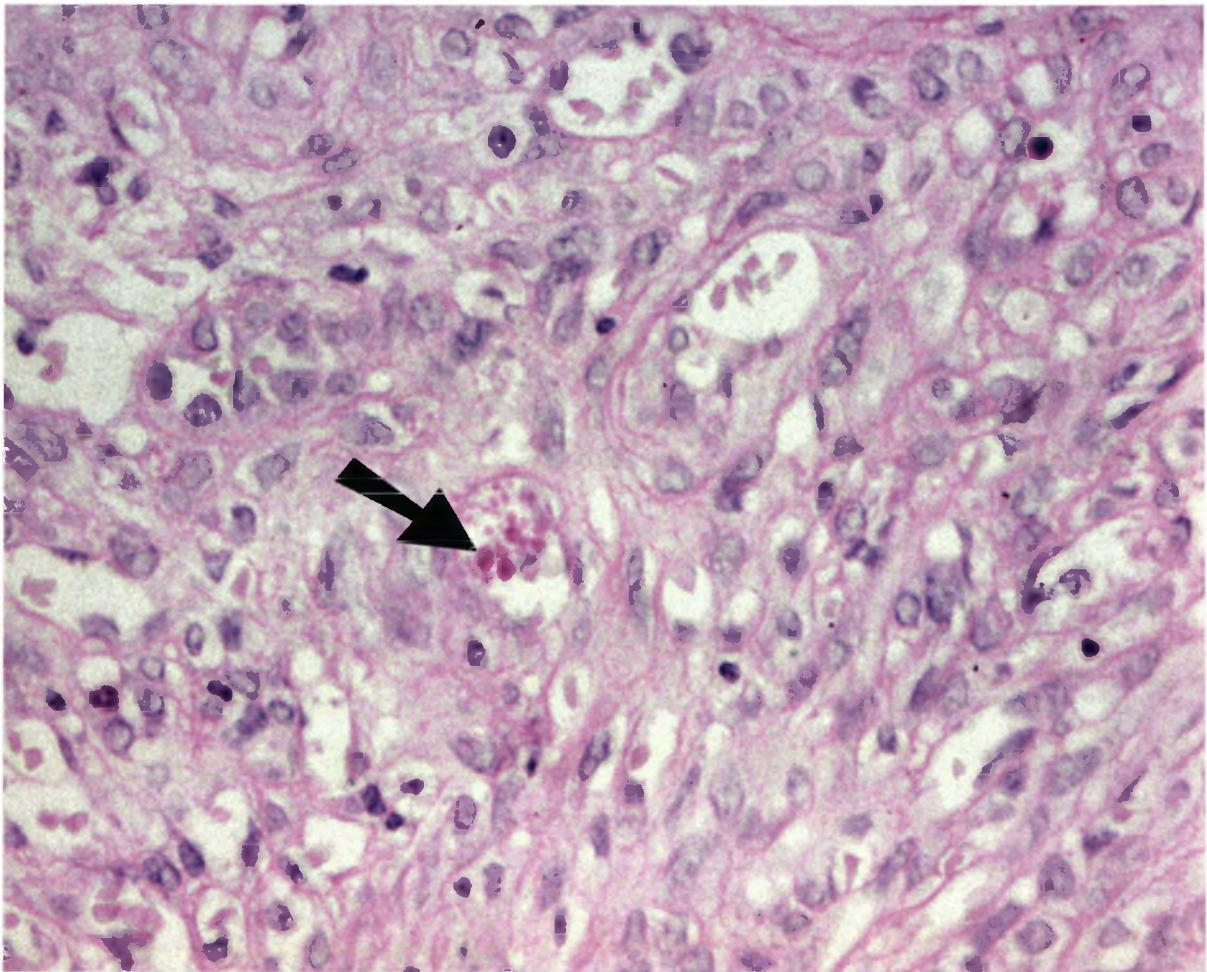


Fig. 10-13 *Nodular Kaposi's sarcoma (PAS and Diastase)*

Characteristic globules within clefts stain positive with PAS and are diastase resistant. These so-called hyaline bodies are found within oval and spindle-shaped neoplastic cells. They are rarely seen, with increasing frequency in the plaque and nodular stages. The hyaline bodies are characterised by many glassy homogenous eosinophilic globules that range in size from 1 to 8 microns. The origin of these globules remains a matter of dispute but the presence of these intracytoplasmic globules is virtually diagnostic of Kaposi's sarcoma.

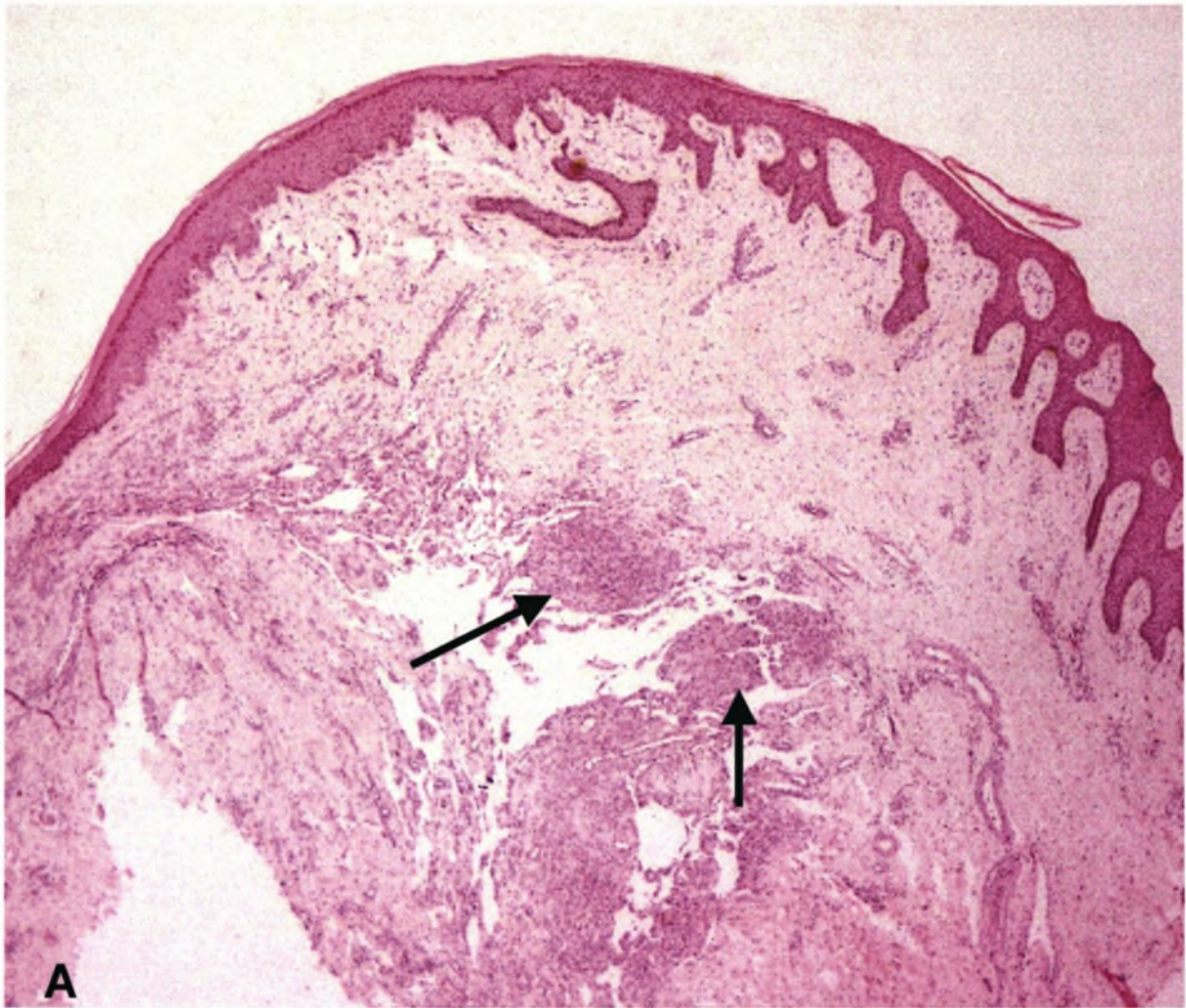
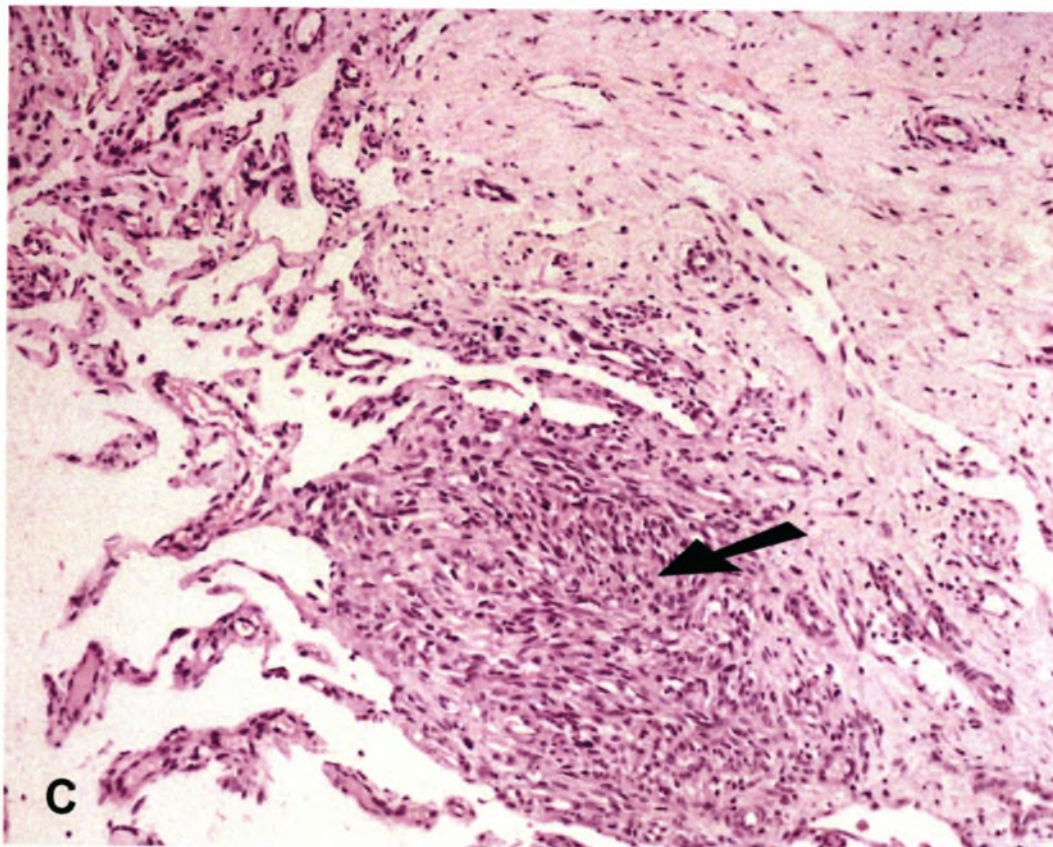
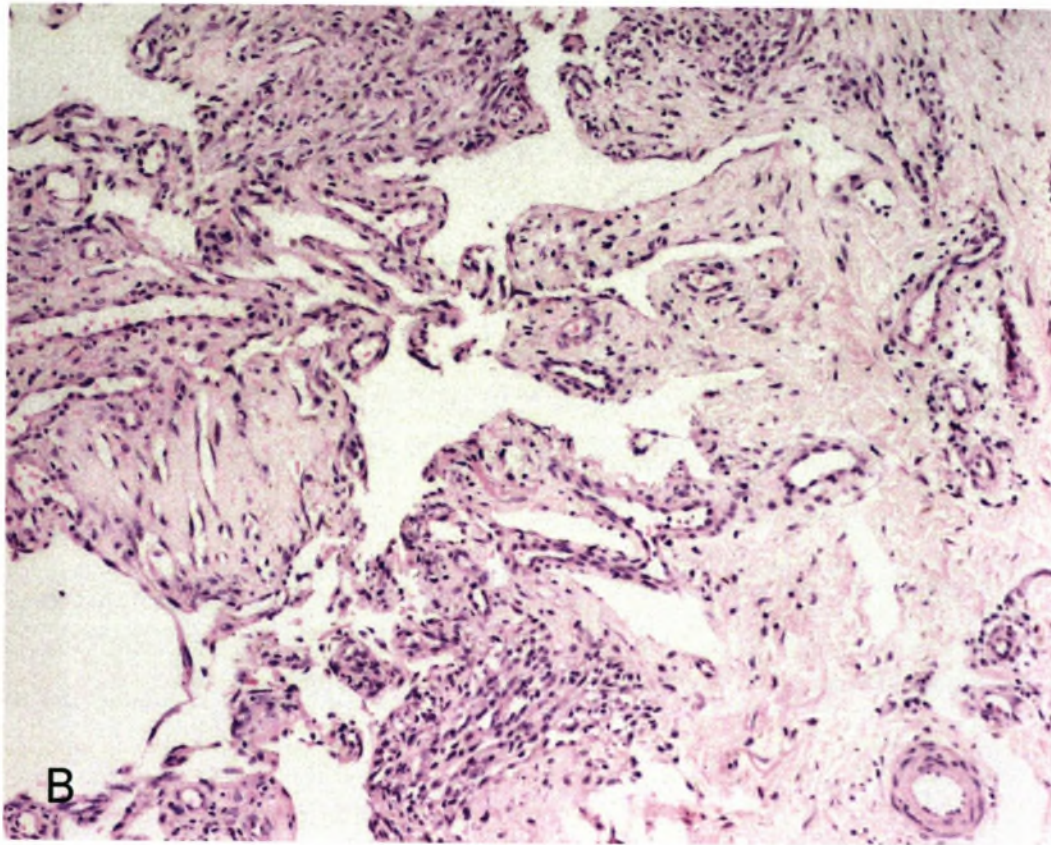


Fig. 10-14 (A, B, C) Lymphangiomatous Kaposi's sarcoma

This is rare variant of Kaposi's sarcoma that is characterised by very delicate branching and dissecting vascular spaces between collagen bundles without significant red blood cells. The lesion resembles lymphatic vessels and must be distinguished from a lymphangioma. Focal spindle areas are present (*arrows*) and may indicate progression to a morphologically mixed pattern.



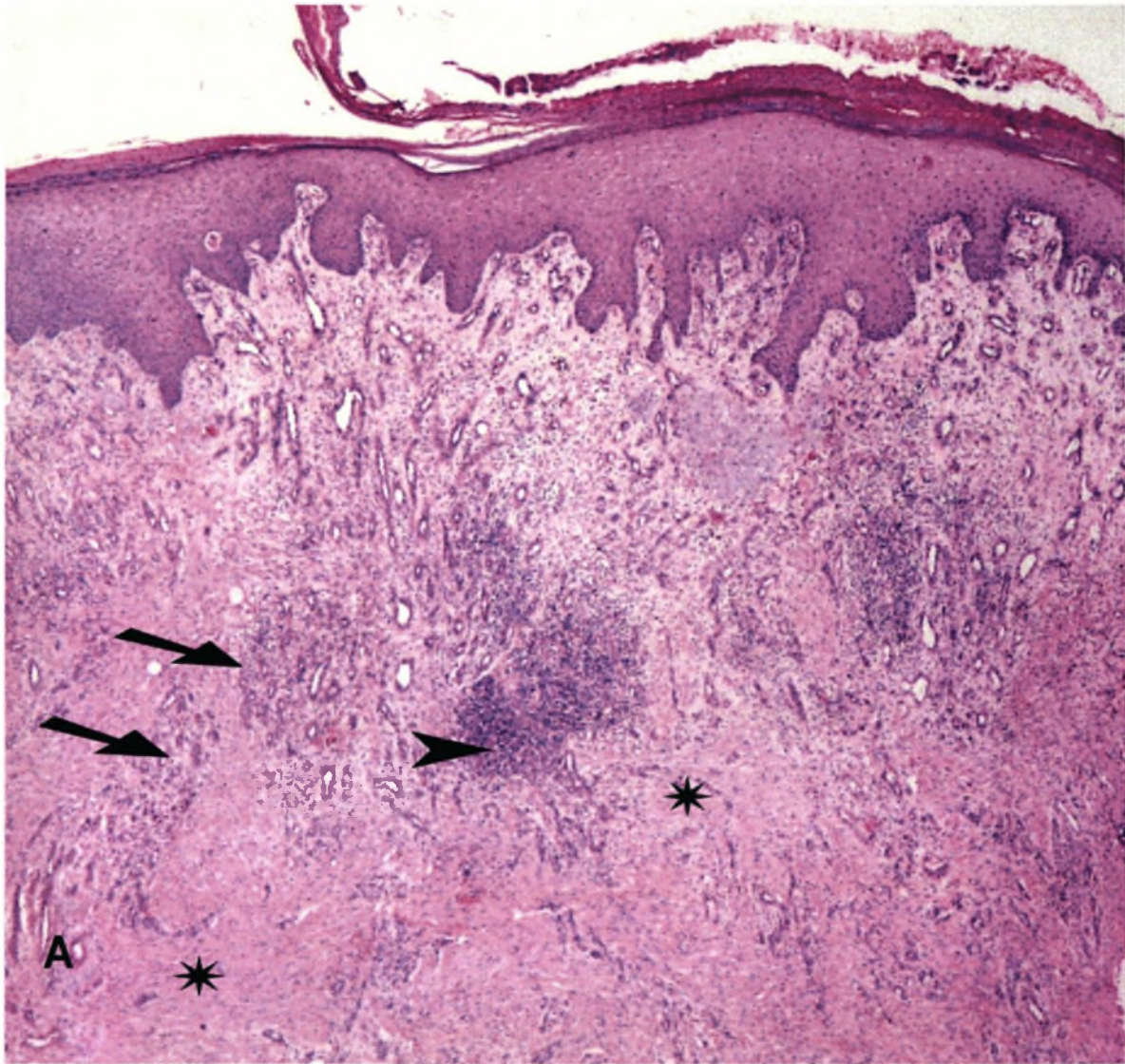
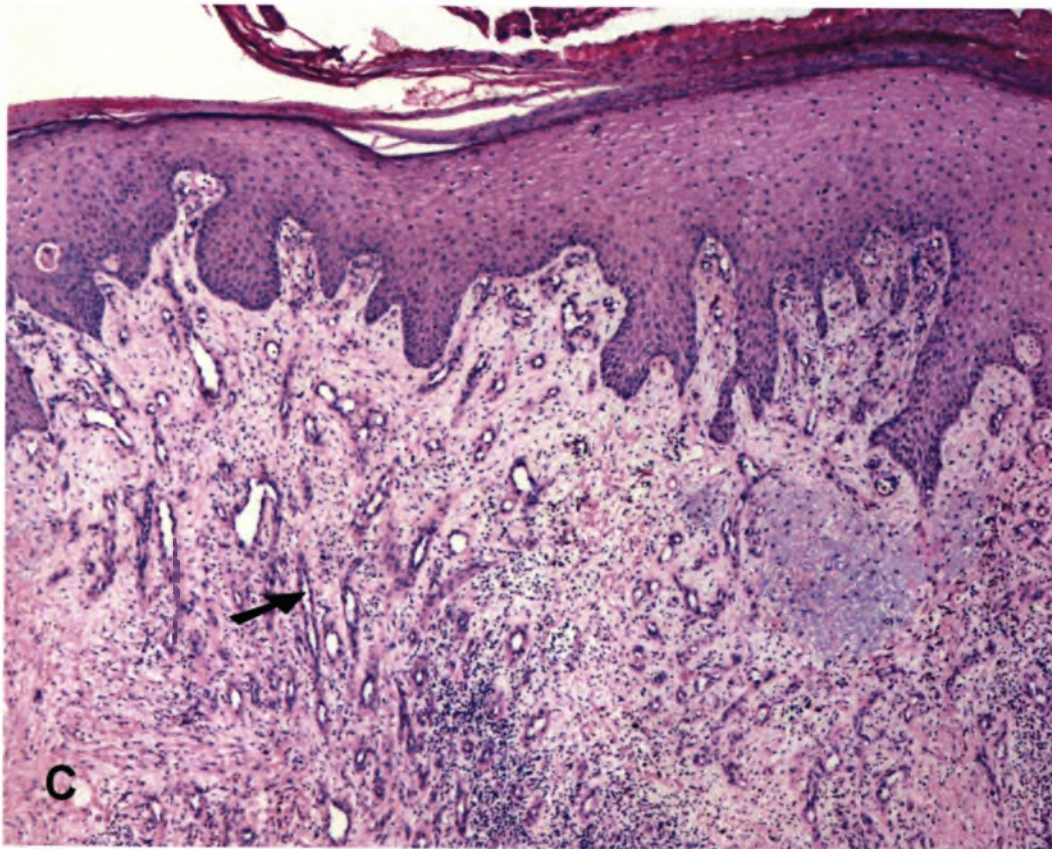
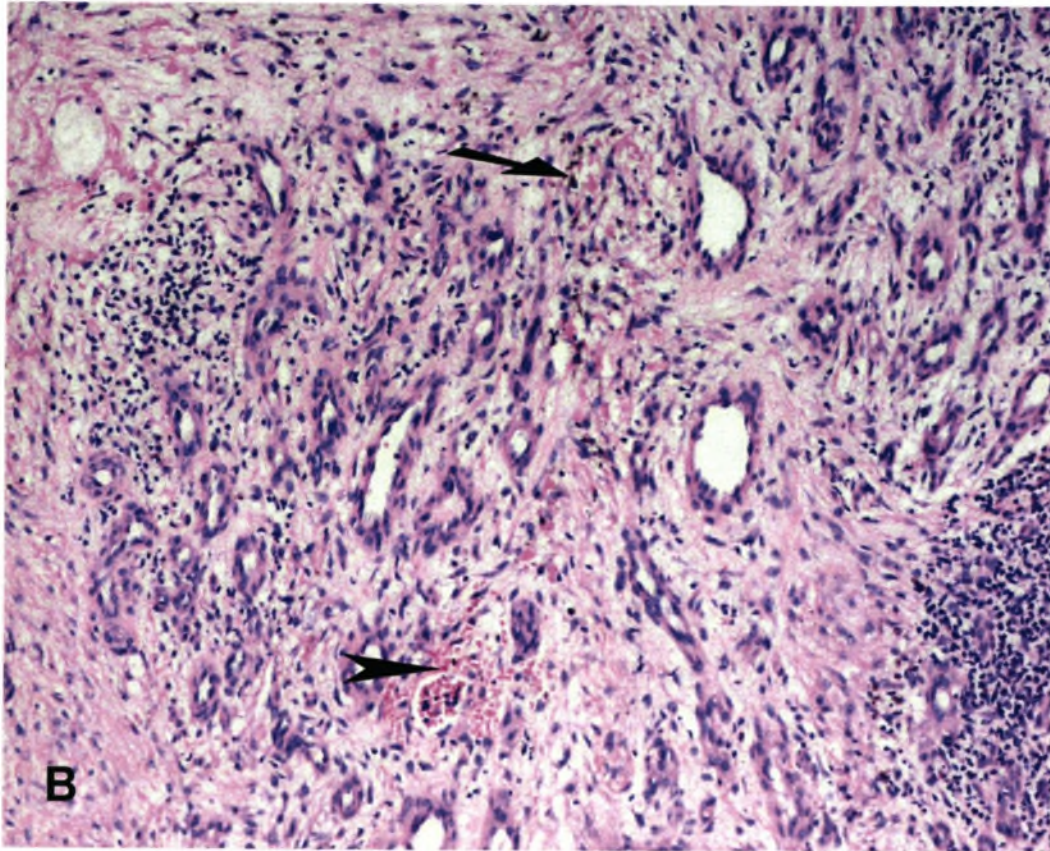


Fig. 10-15 *Stasis dermatitis*

(A) There is pseudo-epitheliomatous hyperplasia of the epidermis with lobular proliferation of capillary vessels (*arrows*) in a dense fibrous stroma with scarring (*stars*) and focal chronic inflammation (*arrow point*). (B) At higher magnification hemosiderin pigment (*arrow*) and red cell extravasations (*arrow point*) can be seen. However, there are no dissecting vessels that are characteristic of Kaposi's sarcoma. There is also striking lobular arrangement of the small blood vessels. (C) The perpendicular orientation of small blood vessels in relation to the epidermis is characteristic of dermal scarring.



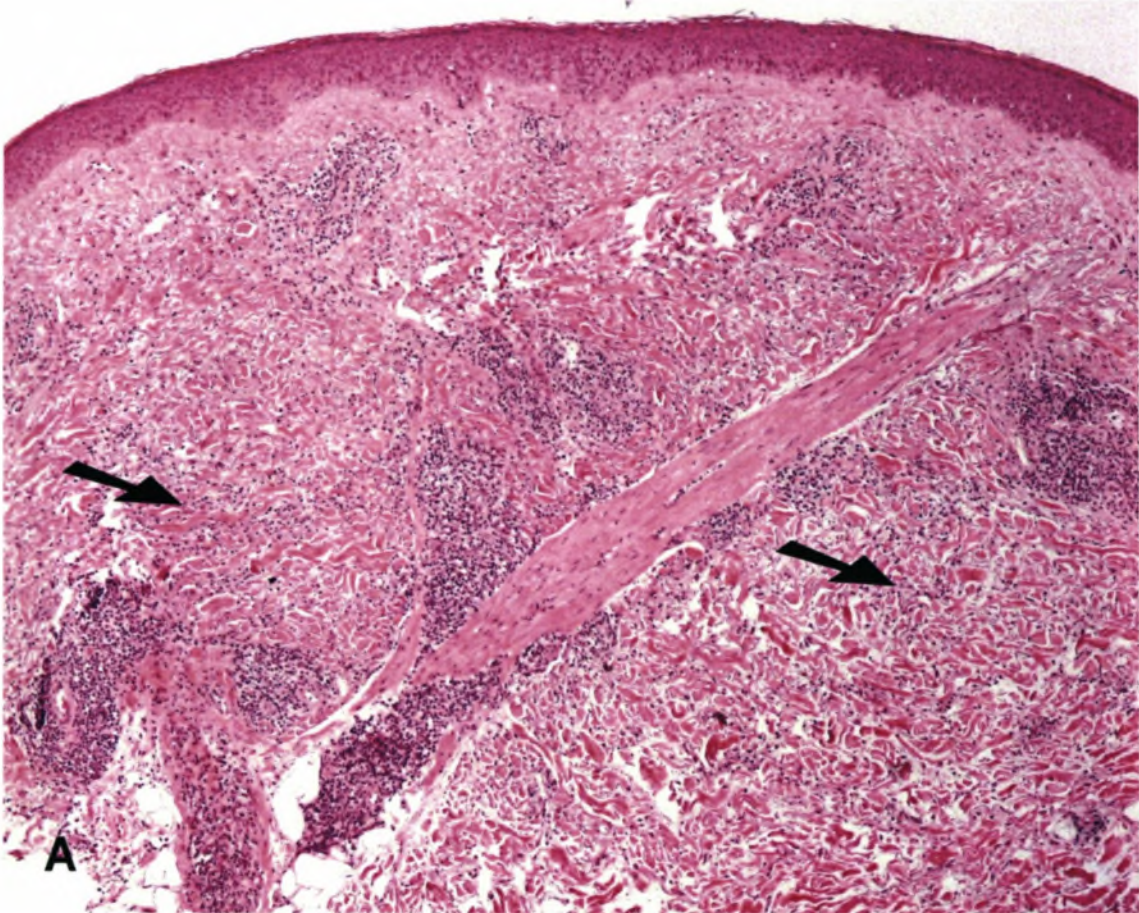
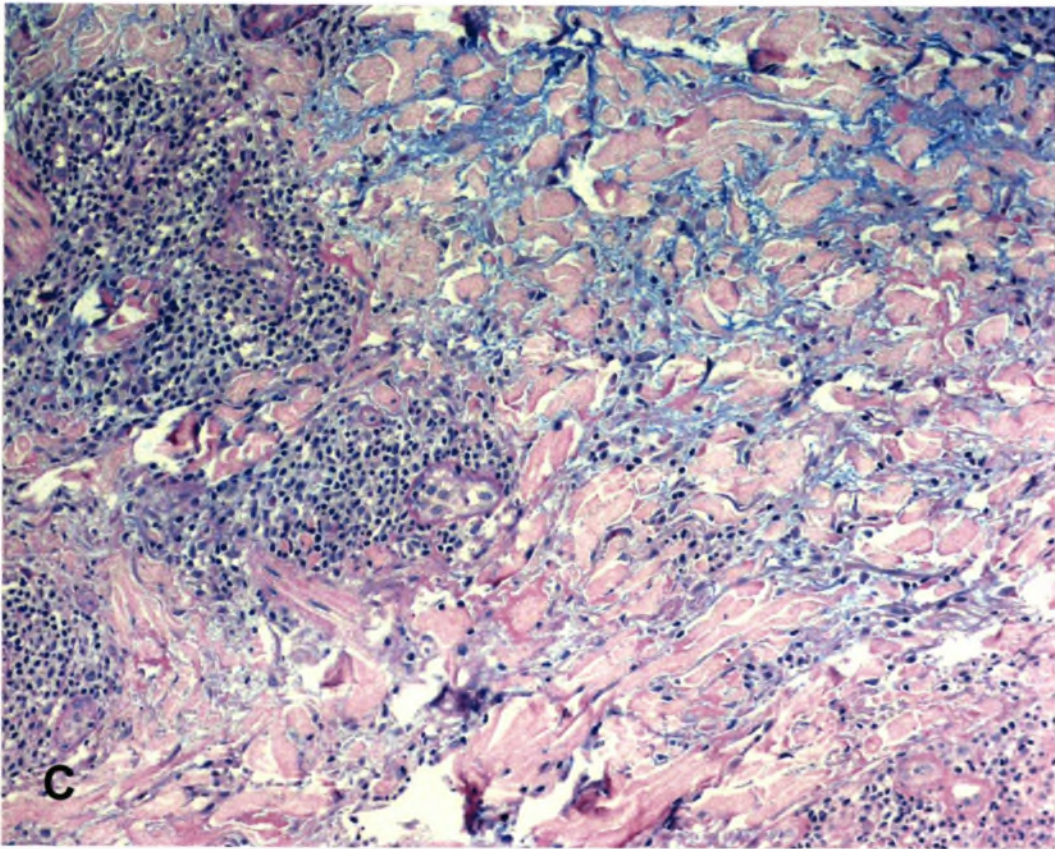
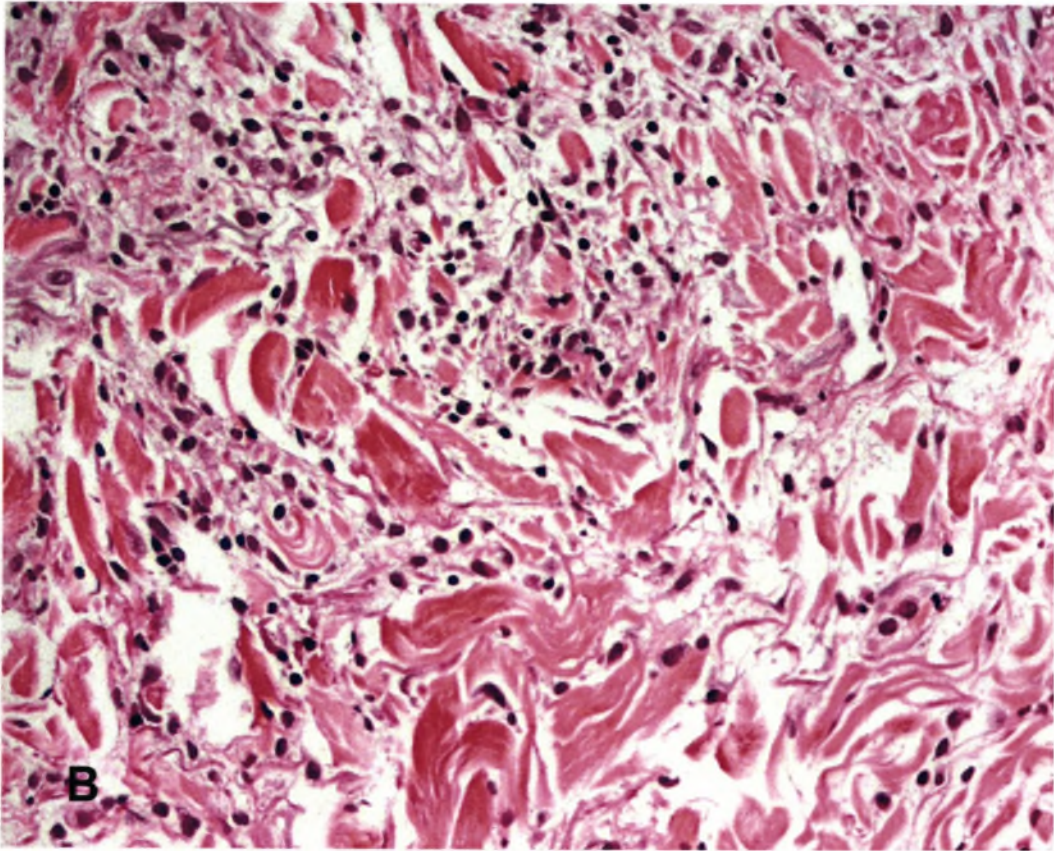


Fig. 10-16 *Granuloma annulare*

(A) Note the "busy dermis" appearance due to an interstitial infiltrate of macrophages (arrows). (B) At higher magnification the macrophages are easier to appreciate. The basophilic hue of the collagen fibres is due piecemeal degeneration. (C) An Alcian-blue & PAS stain reveals abundant stromal mucin between collagen bundles.



WJ 368 MOO

GENE

T

WJ

368

MOO

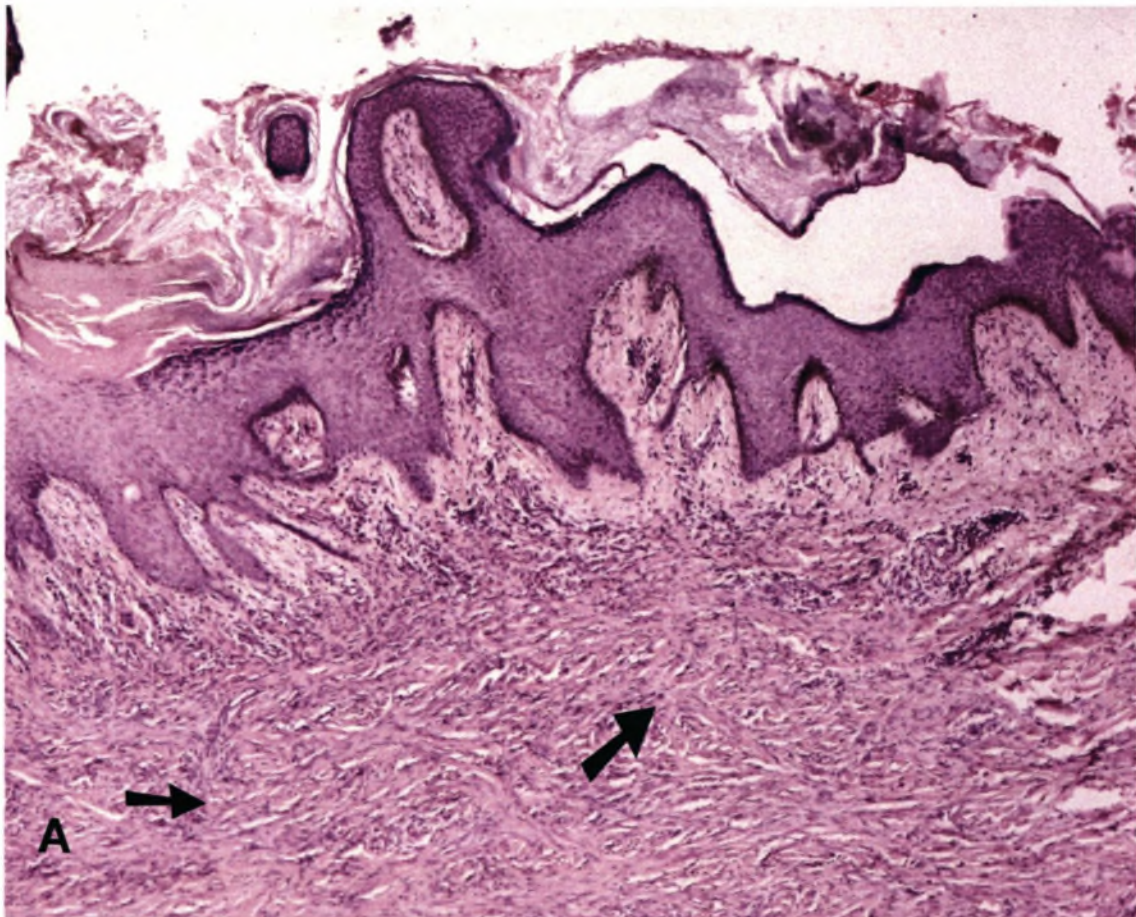
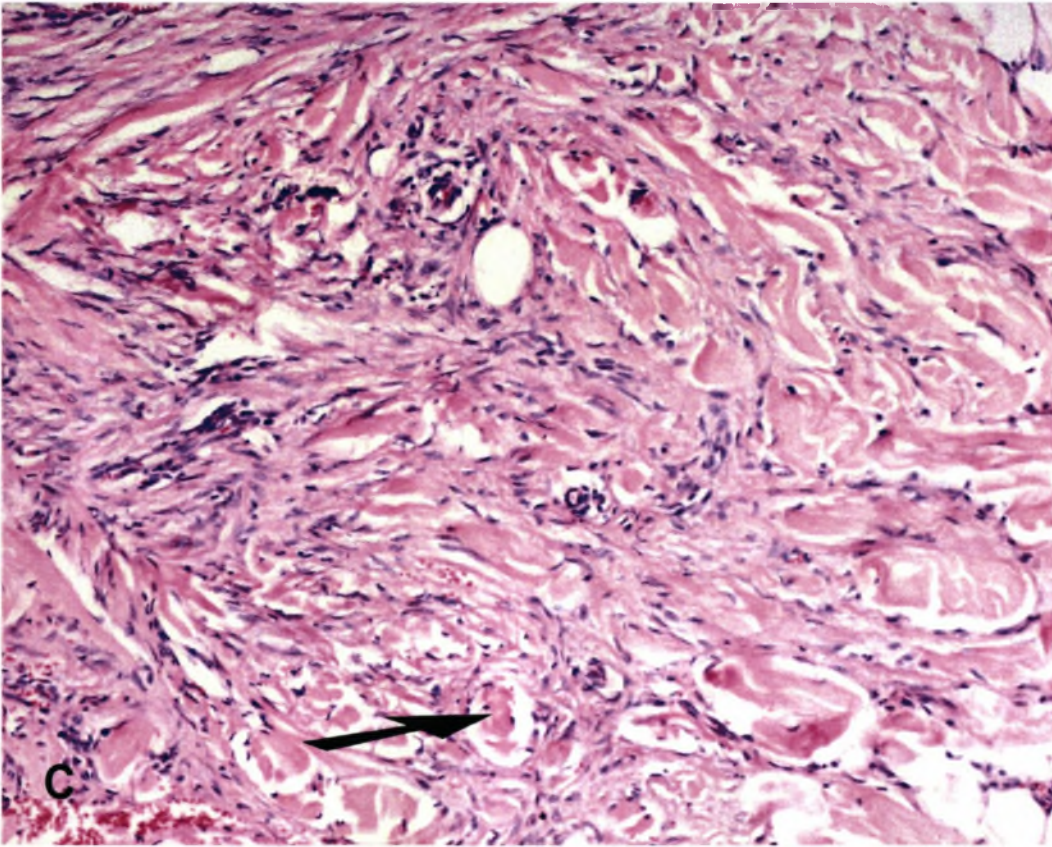
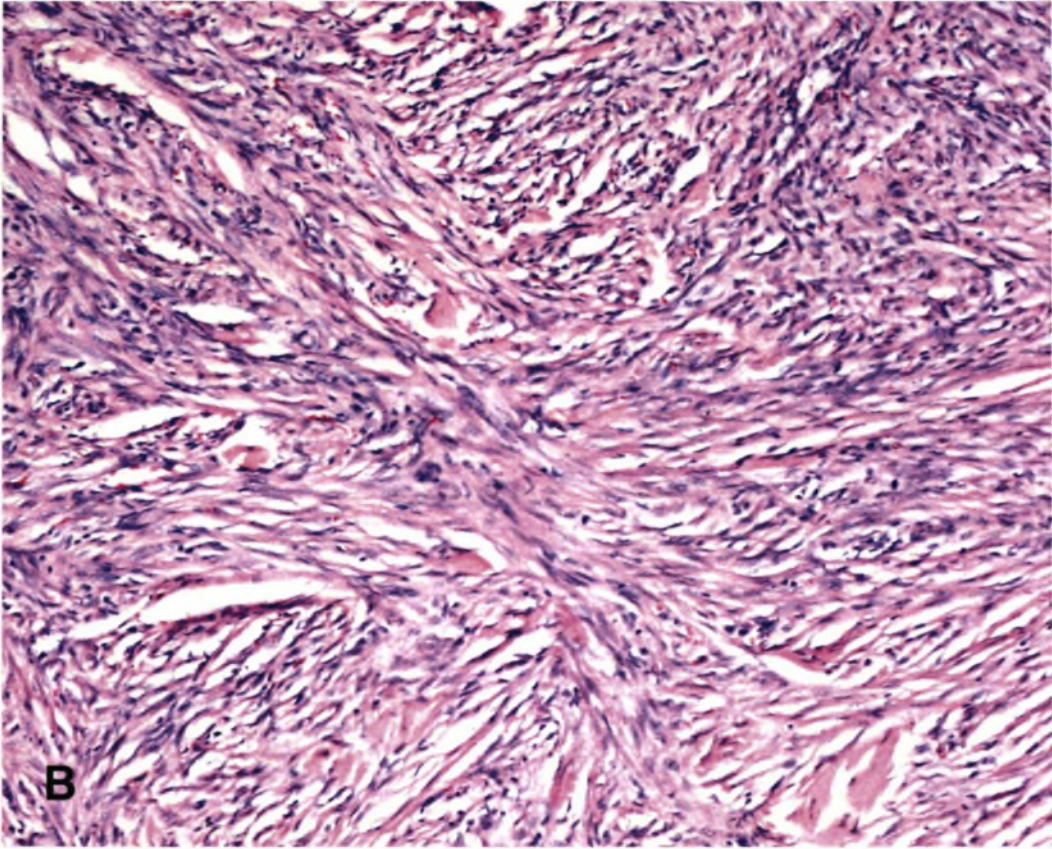


Fig. 10-17 *Dermatofibroma*

(A) The characteristic epidermal acanthosis associated with this condition is demonstrated. Note the lack of involvement of the papillary dermis. The cells in the lesion display a very typical storiform growth pattern (*arrows*). (B) Typical storiform growth pattern of cytologically bland spindle cells at higher magnification. There is no attempt to form vascular channels. (C) Note the entrapment of thick collagen bundles by the spindle cells at the periphery of the dermatofibroma (*arrow*).



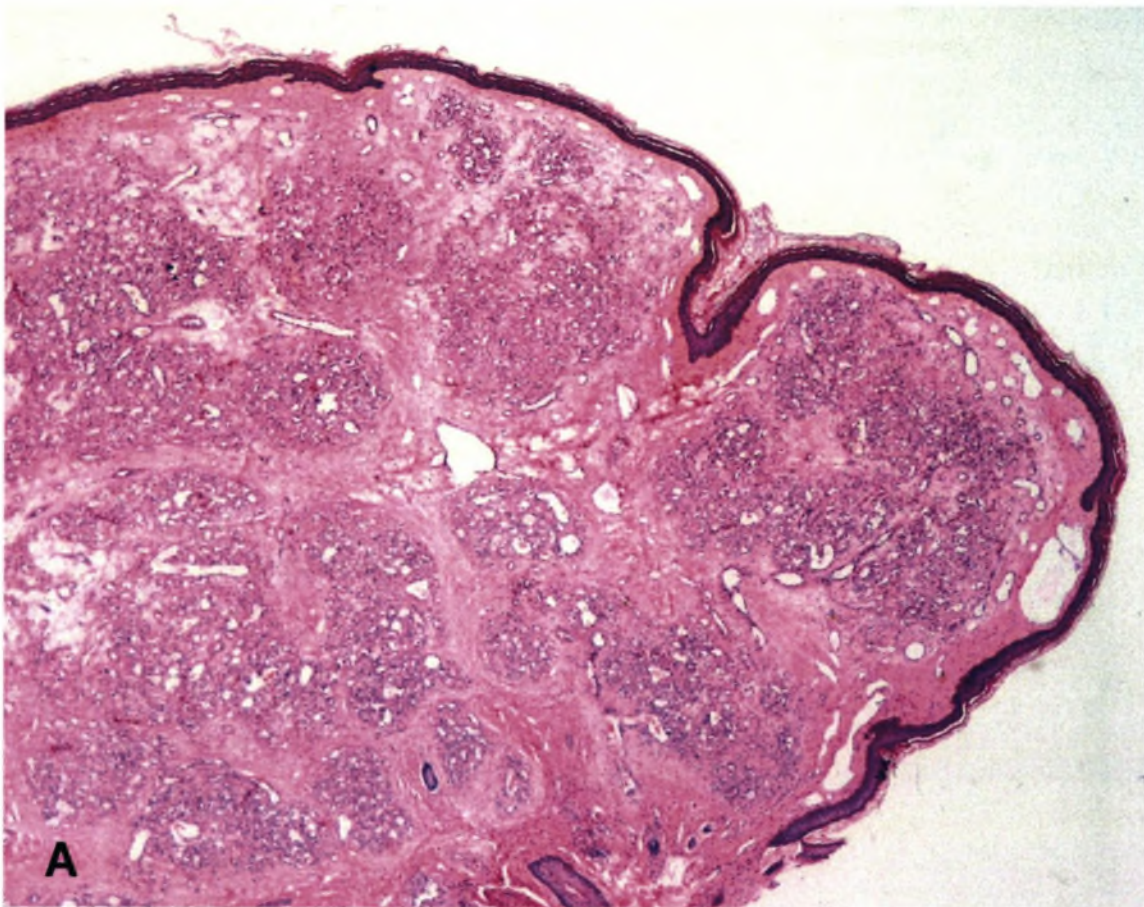
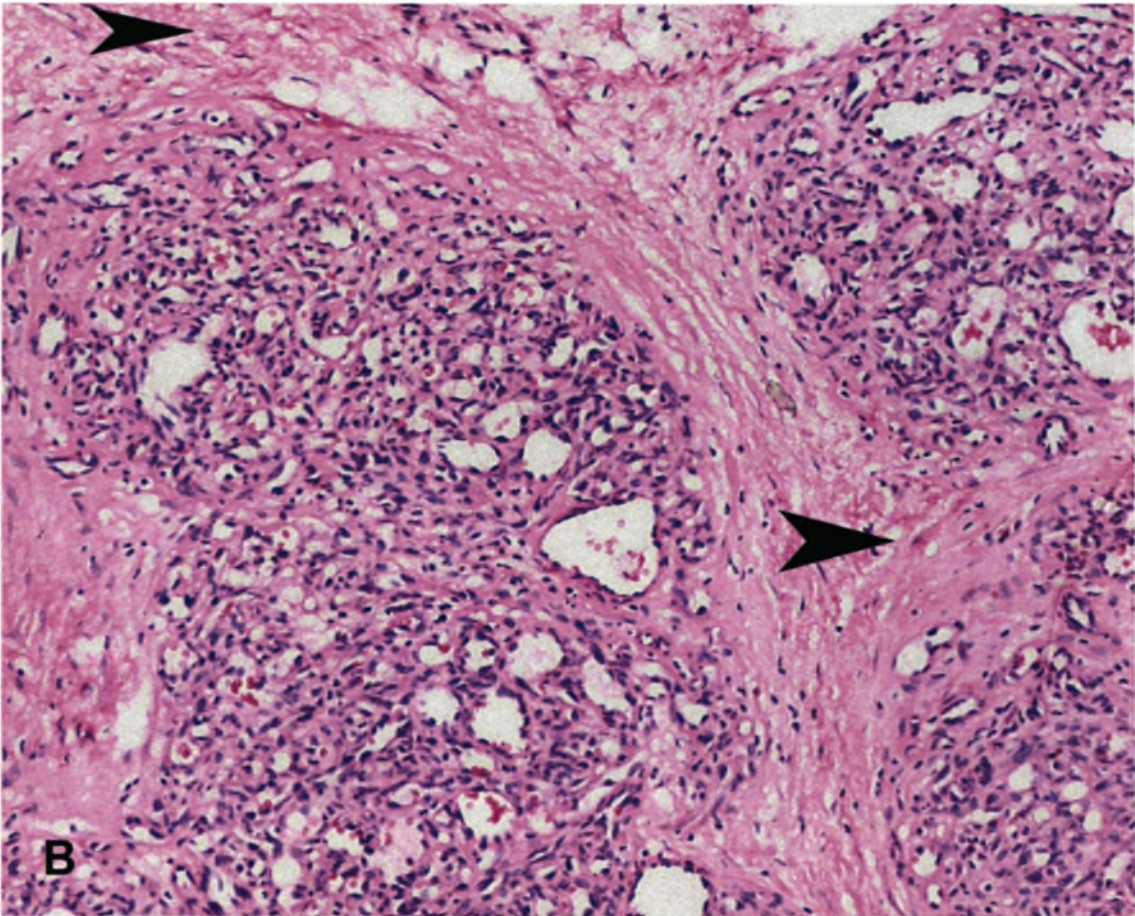


Fig. 10-18 *Lobular haemangioma*

(A) Lobular haemangioma displays a characteristic exophytic growth pattern and consists of well-defined lobules of small capillary vessels. Delicate collagenous stroma separates the vascular lobules and there is no evidence of dissecting vascular channels between collagen bundles. (B) Endothelial cells without cytological atypia line the small capillary-sized vessels. Note the very typical lobular growth and collagenous septa (*arrow point*).



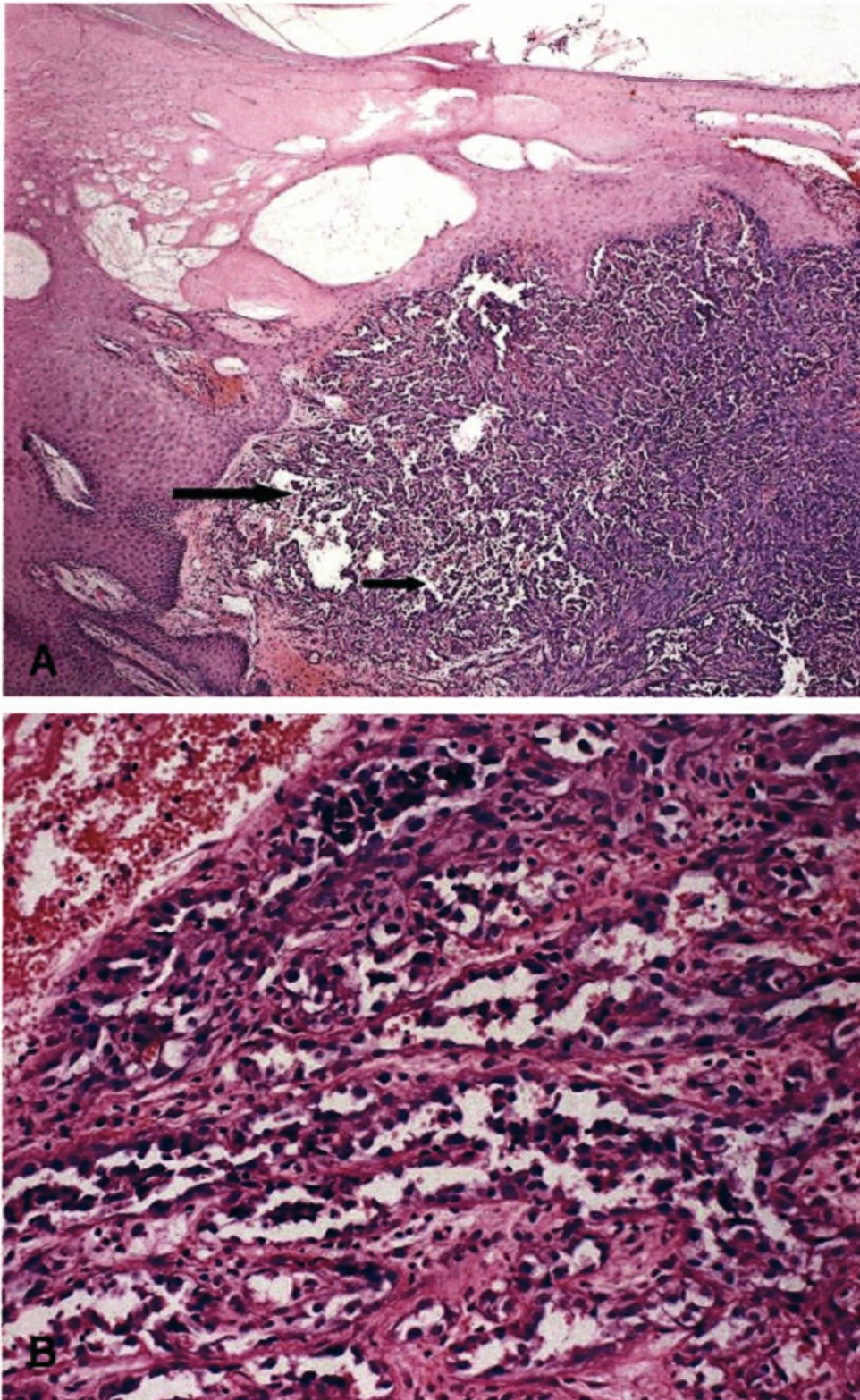


Fig. 10-19 Angiosarcoma

(A) Irregular, arborising and anastomosing vascular channels (*arrows*) are lined by atypical, hyperchromatic and pleomorphic endothelial cells. (B) Higher magnification highlights the cytological features of the malignant endothelial that line the vascular channels.

Postmortem Findings (Patient RJ)

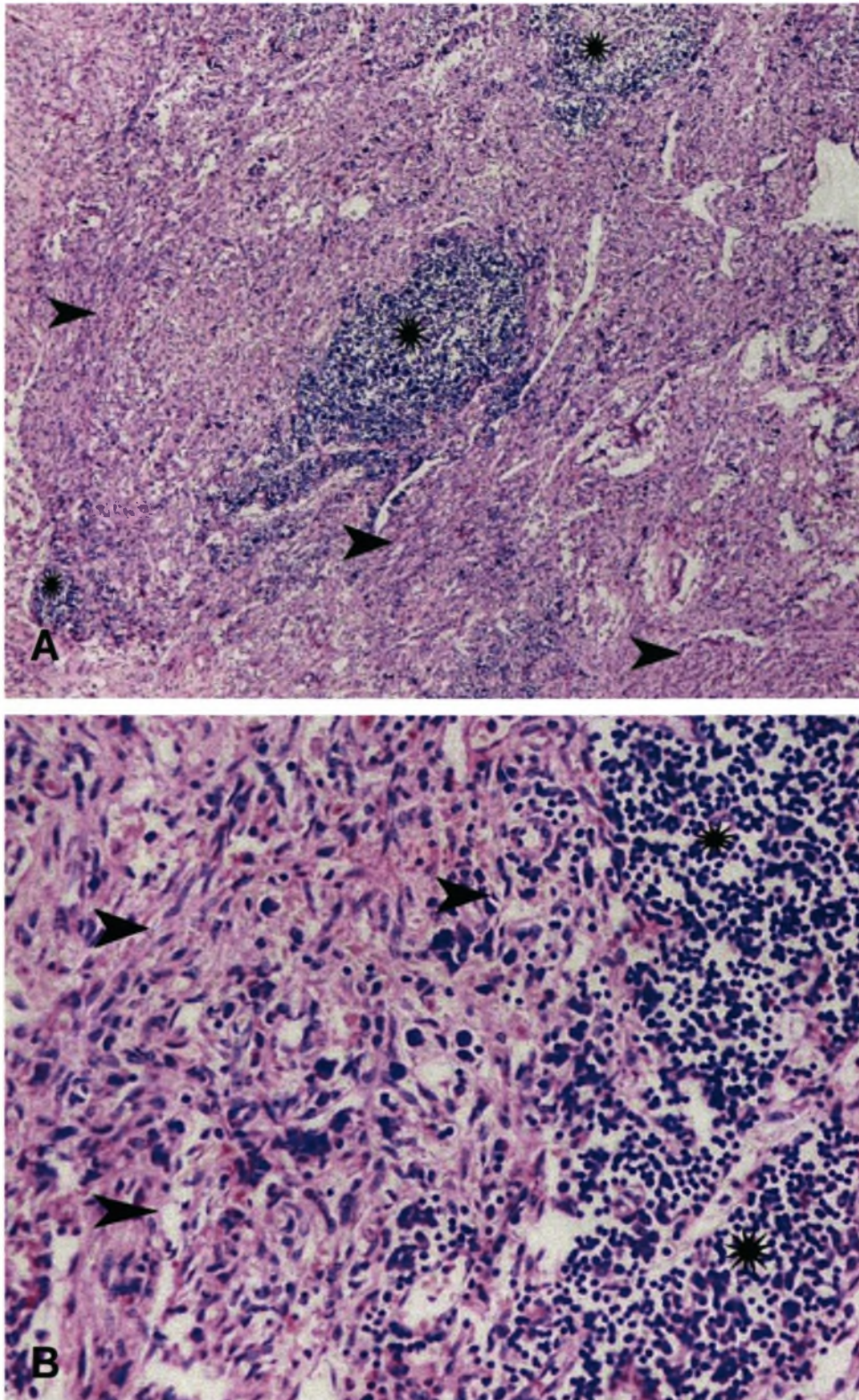


Fig. 10-20 (A, B) Nodal Kaposi's sarcoma

There is extensive replacement of the lymph node by Kaposi's sarcoma (*arrow points*). There is some residual lymphoid tissue (*stars*).

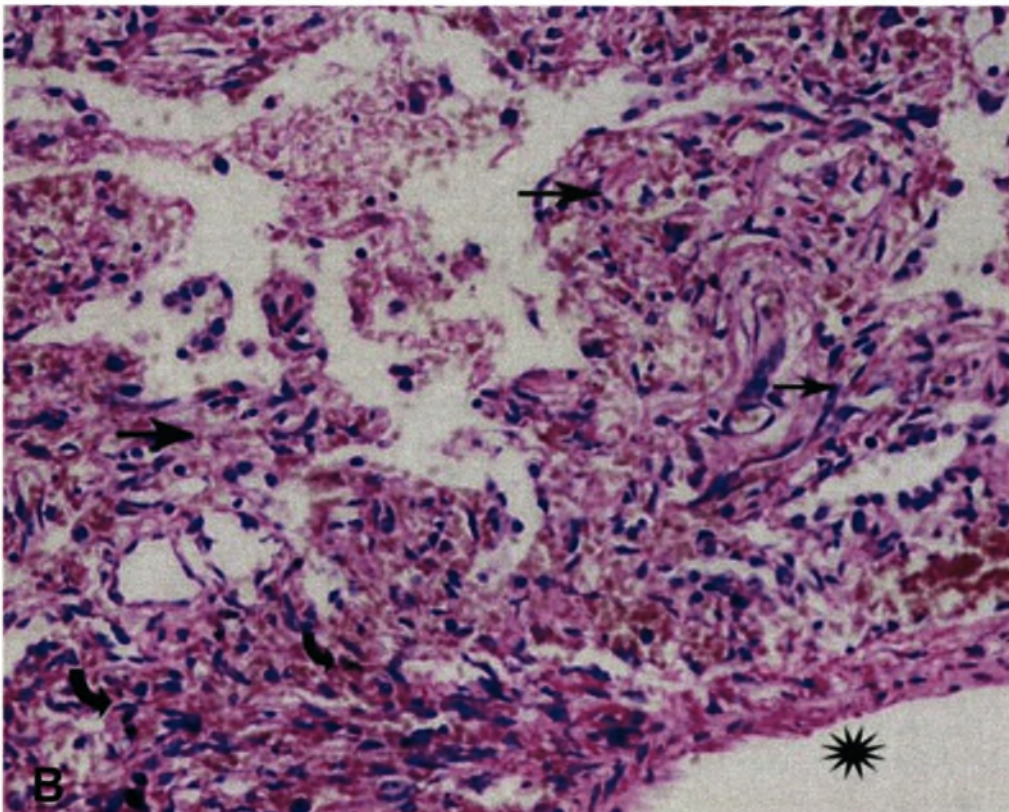
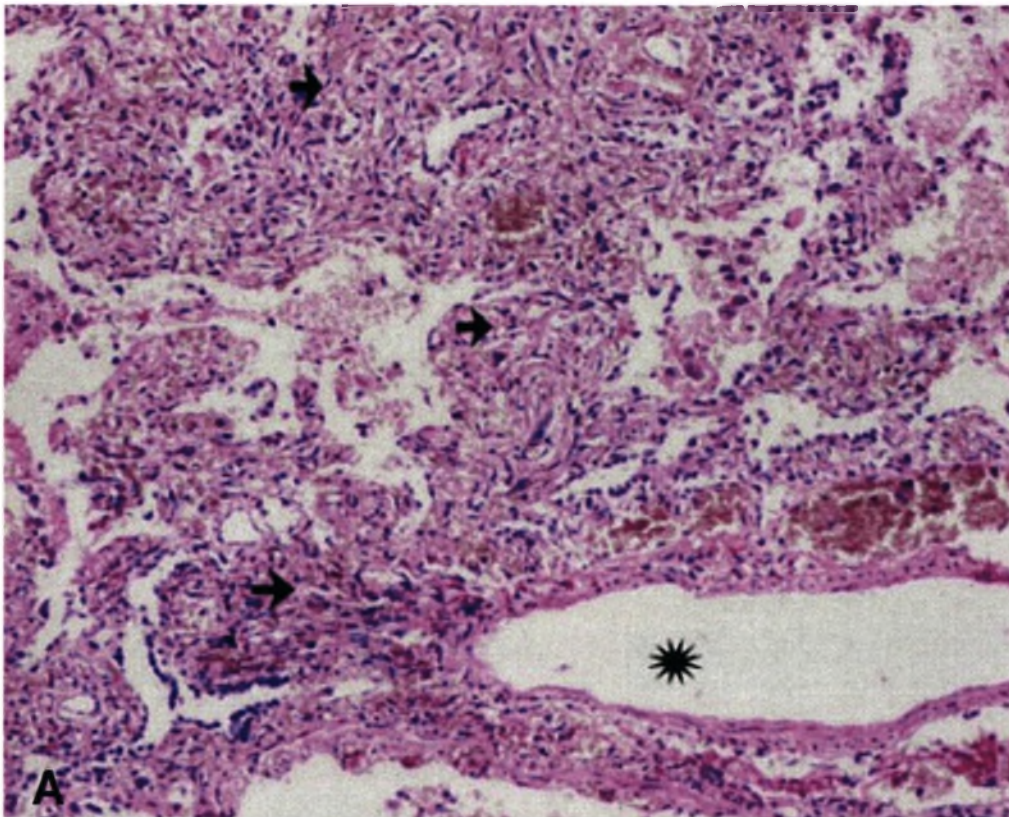


Fig. 10-21 (A, B) Lung Kaposi's sarcoma

The large blood vessel (*star*) is surrounded by proliferating vascular spaces and spindle cells extending into the interstitial component of the lung (*arrows*).

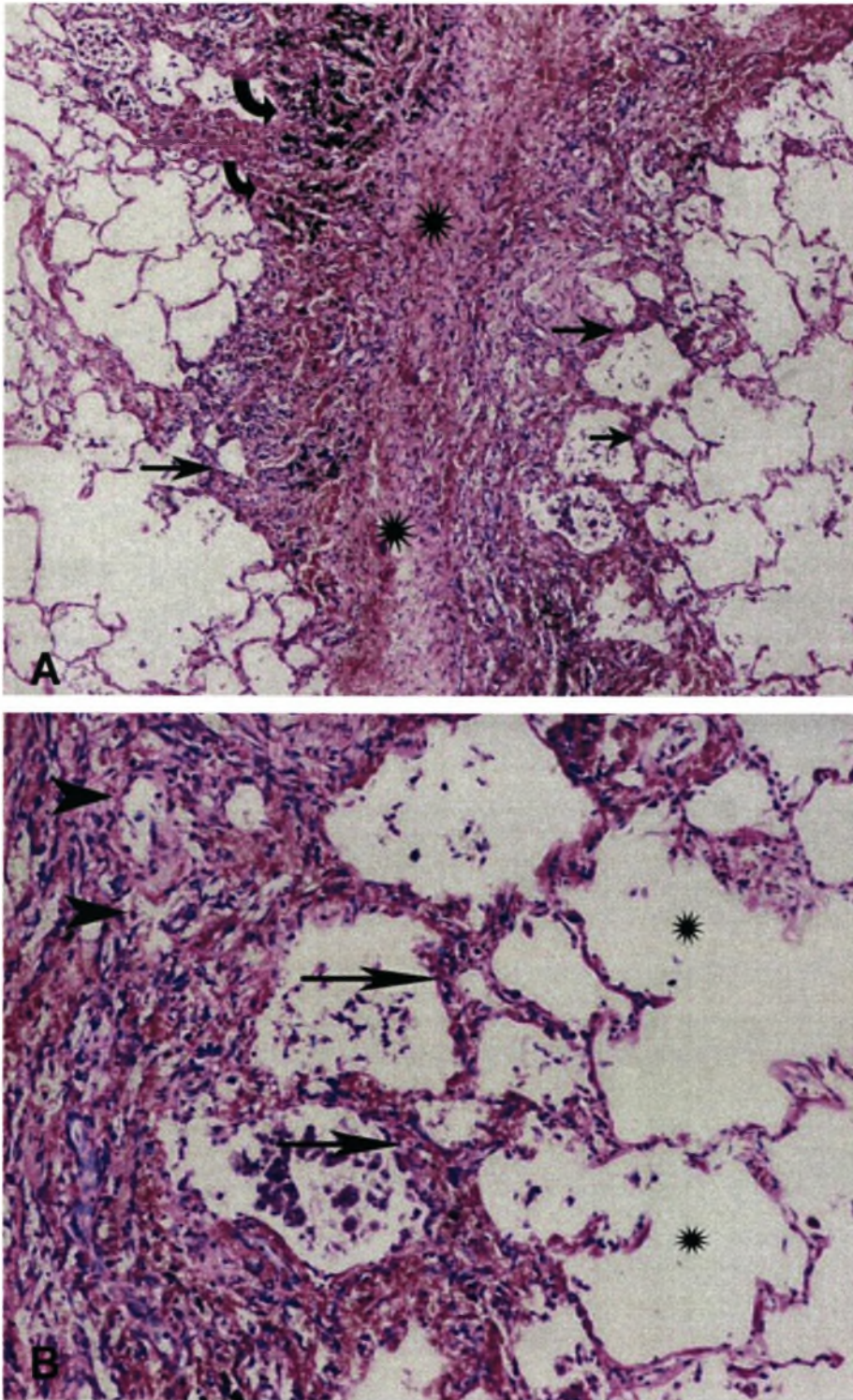


Fig. 10-22 Lung Kaposi's sarcoma

(A) The fibrous septum shows fibrosis (*star*) with proliferation of vascular spaces and spindle cells that extend into the adjacent pulmonary interstitium (*arrows*). Hemosiderin is present (*curved arrows*). (B) The alveolar septae are involved (*arrows*); some alveolar spaces are spared (*stars*) but elsewhere alveoli are obliterated by Kaposi's sarcoma (*arrow points*).

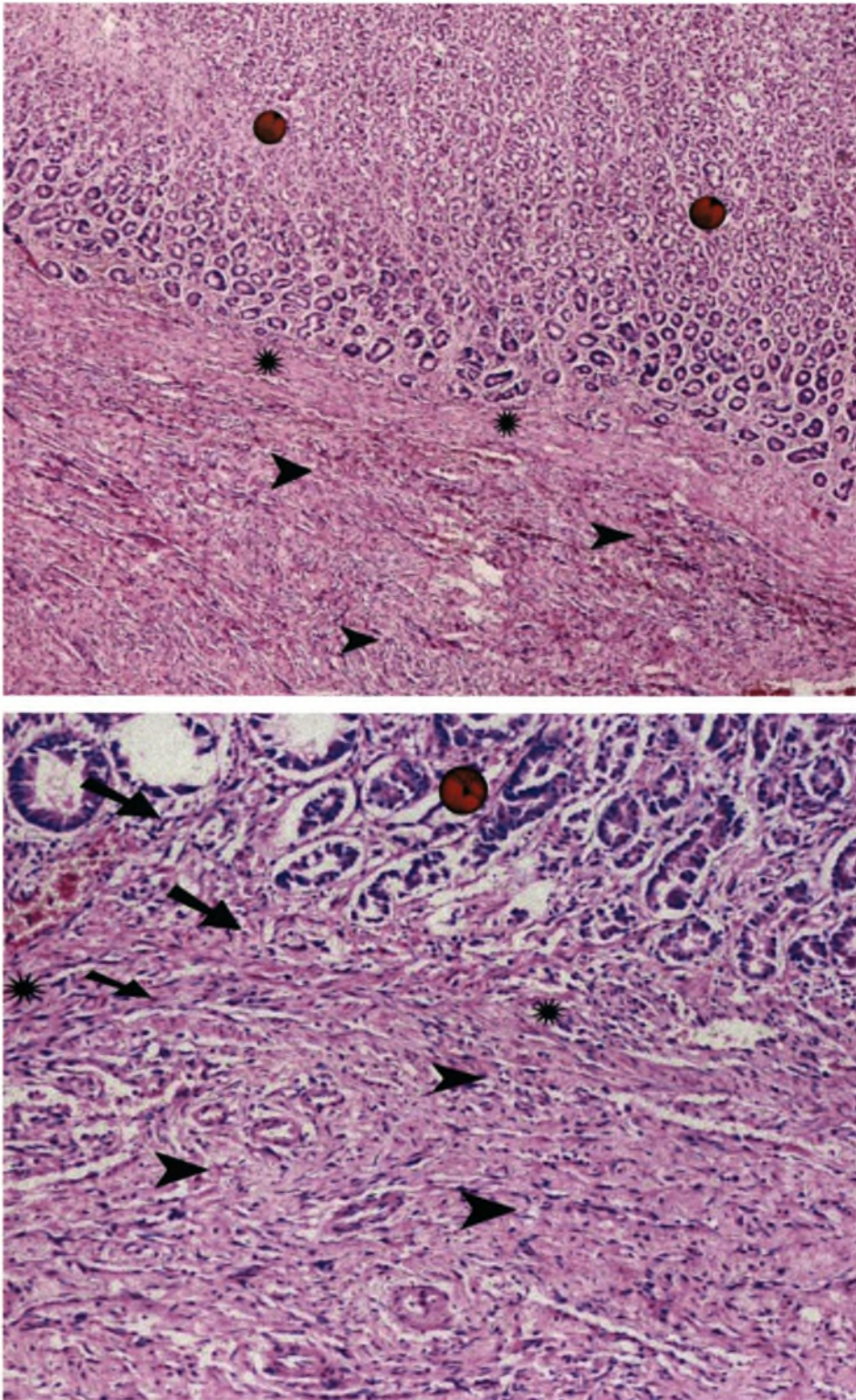


Fig. 10-23 *Gastrointestinal Kaposi's sarcoma*

Stomach and small bowel involvement are common. In this section the gastric mucosa is spared (*red buttons*), but there is extensive involvement of the submucosa (*arrow points*) that abuts the muscularis mucosae (*stars*). Elsewhere tumour is present within the muscularis mucosa and adjacent lamina propria (*arrows*).

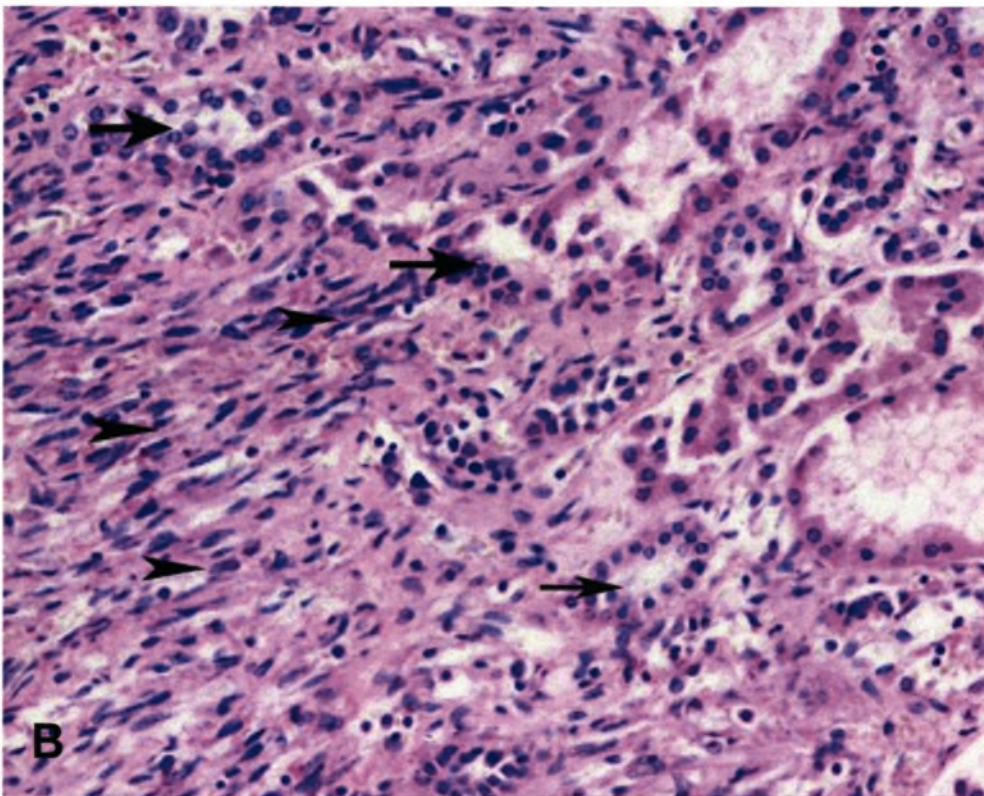
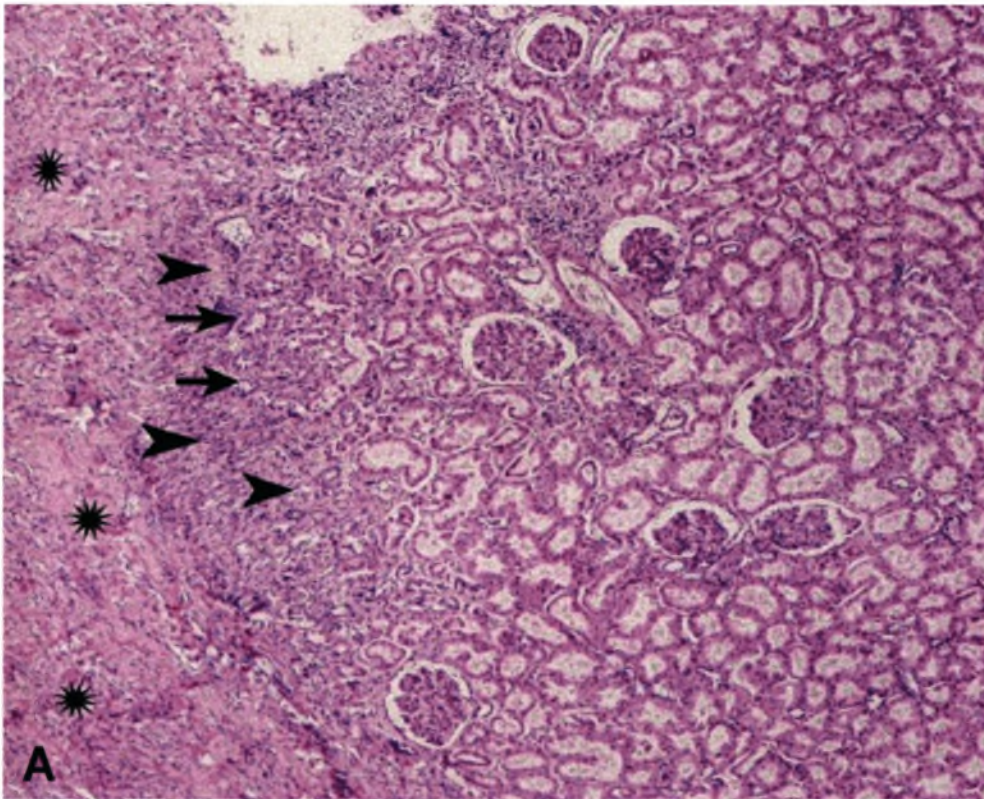


Fig. 10-24 (A, B) Renal allograft Kaposi's sarcoma

There is extensive involvement of the allograft capsule by Kaposi's sarcoma (*stars*). Residual tubules (*arrows*) with interstitial proliferation of vascular spaces and occasional spindle cells can be seen (*arrow points*).

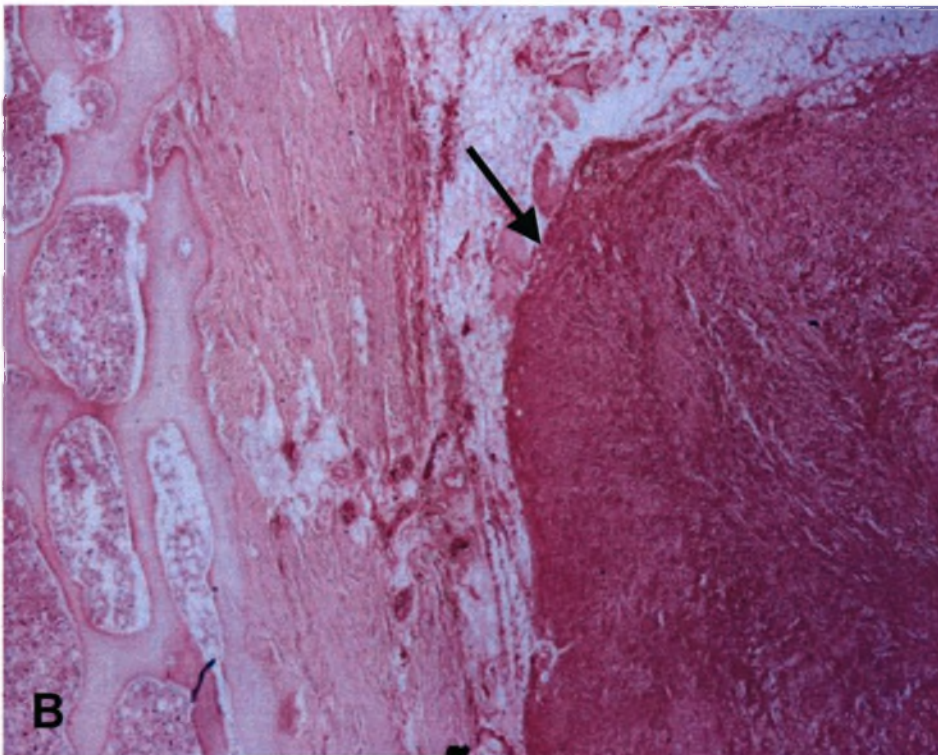
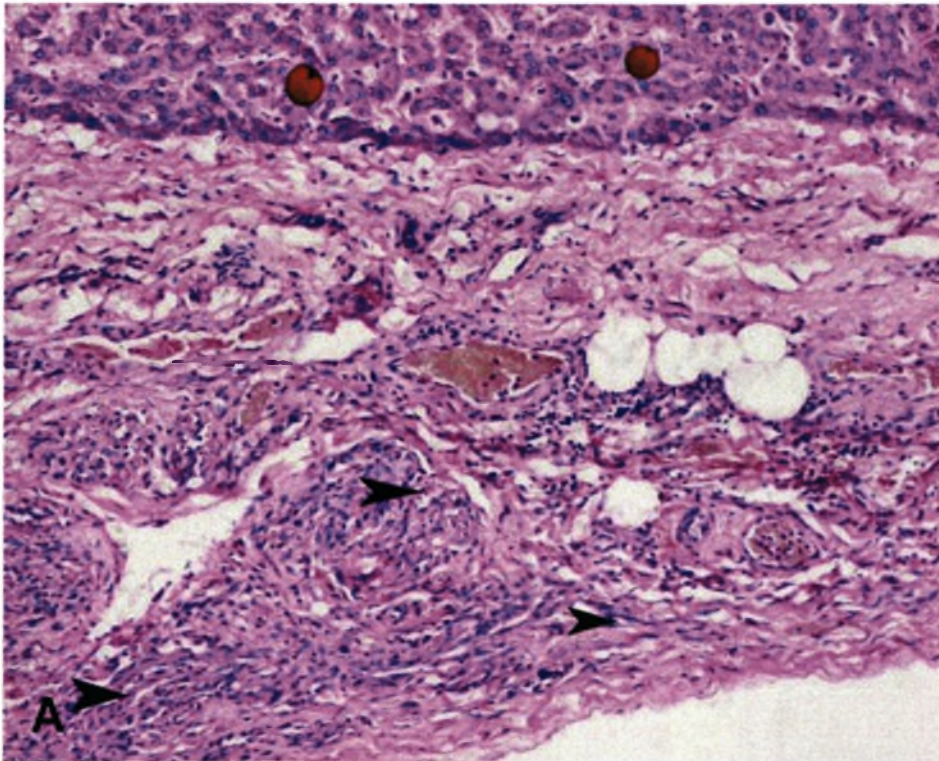


Fig. 10-25 Rare organ involvement in Kaposi's sarcoma

(A) In this section of liver the parenchyma is spared (*red buttons*) but Kaposi's sarcoma lesions are clearly visible within the liver capsule (*arrow points*). (B) In this section of bone there is nodular proliferation of Kaposi's sarcoma in the region of the periosteum (*arrow*).

Chapter 11

KAPOSI'S SARCOMA TREATMENT AND OUTCOME

Appropriate management of Kaposi's sarcoma should be based on an understanding of the pathogenesis of the disease. The development of Kaposi's sarcoma requires (1) the genetic susceptibility, (2) infection with human herpesvirus type 8 (HHV-8), and (3) immunosuppression (see Chapter 14). Since little is known or understood of the first aspect of the pathogenesis, emphasis falls on the other two components of the pathogenesis, *viz.*, HHV-8 infection and immunosuppression. The behaviour of iatrogenic Kaposi's sarcoma provides interesting clues to the pathogenesis of other forms of Kaposi's sarcoma and the role played by immunosuppression. Of all clinico-epidemiological forms of Kaposi's sarcoma, the iatrogenic subtype is potentially the simplest, most cost-effective and rewarding to treat. It is hoped that an understanding of the treatment of this form of Kaposi's sarcoma will provide valuable clues to the aetiopathogenesis of Kaposi's sarcoma and can perhaps be a guide to the treatment of other forms of Kaposi's sarcoma.

THE CURRENT EXPERIENCE

First line of treatment

Based on current experience in the literature, the mainstay of treatment of iatrogenic Kaposi's sarcoma is reduction or withdrawal of immunosuppressive treatment (Al-Sulaiman *et al.*, 1987; Antman *et al.*, 2000; Bhoopchand *et al.*, 1986; Harwood *et al.*, 1979; Margolius *et al.*, 1994; Nickoloff *et al.*, 1989; Penn, 1983; Penn, 1987; Penn, 1993; Qunibi *et al.*, 1988; Sheil, 1977). Although, Kaposi's sarcoma usually regresses after manipulation of the immunosuppressive regimen, the price that patients often have to pay may be heavy (Frances, 1998): almost half of the patients in whom the therapy is withdrawn or reduced lose their grafts (Antman *et al.*, 2000). Those patients who reject their grafts after the cessation of immunosuppression may benefit from reinstatement of anti-rejection therapy but there are cases where the graft has had to be abandoned (Al-Khader *et al.*, 1988). Gotti *et al.* (1997) state, and we concur, that the decision to discontinue all immunosuppression is not an easy one to make and should take into account the severity and extension of the cutaneous lesions, and the degree of visceral involvement. In the case of renal transplants, the patient can return to dialysis but such an option does not exist for most other solid organ transplant recipients.

Responses to withdrawal or reduction

Based on their experience Qunibi *et al.* (1998) have suggested a management algorithm that is based on the progressive reduction and ultimate cessation of immunosuppression (Fig. 11-1). At least 50% of the patients died or returned to dialysis when immunosuppression was discontinued. The remaining patients generally experienced varying degrees of remission. The discontinuation of immunosuppressive therapy led to the resolution of Kaposi's sarcoma in four of five renal allograft recipients in the Johannesburg study (Margolius *et al.*, 1994). In an Italian study of 13 patients with post-renal transplant Kaposi's sarcoma, the withdrawal or reduction of immunosuppressive treatment (plus radiotherapy and chemotherapy in 2 patients) led to complete responses in 9 and partial responses in 2 of the patients (Montagnino *et al.*, 1994). Of the 13 patients 5 had skin lesions only and eight had skin and either mucosal or visceral lesions. However, 4 patients lost

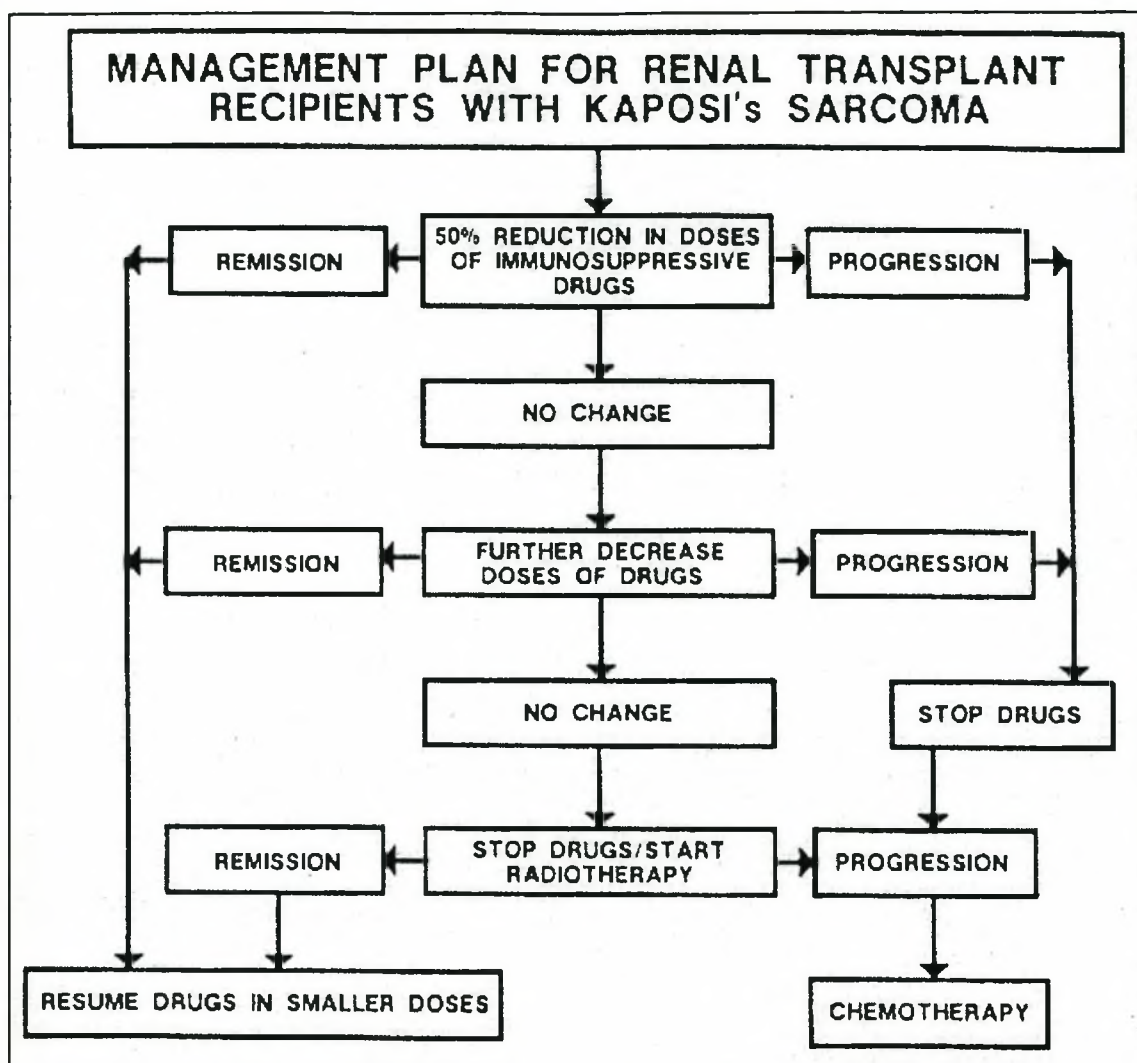


Fig. 11-1. Algorithm for the management of iatrogenic Kaposi's sarcoma suggested by Qunibi (1988).

their renal allografts. In another Italian study the response to reduction of immunosuppression was less satisfactory with only 4 of 10 renal transplant recipients with Kaposi's sarcoma having a complete response (Lesnoni La Parola *et al.*, 1997).

Management based on staging

Al-Sulaiman *et al.* (1994) have taken a slightly different approach. They base their treatment protocol on their staging of the disease (see Chapter 10). For stages I and II mere reduction of immunosuppressive therapy is recommended and according to the authors this is sufficient to result in the regression of the tumour while preserving

renal function. For stages IIIA and IVA a trial of reduction of steroids should be attempted and if there is still evidence of progression of the tumour following reduction of therapy then discontinuation of immunosuppressive therapy is advocated. However, with pulmonary involvement they recommend cessation of all immunosuppression at the time of diagnosis, as disease of this organ is associated with a particularly poor outcome. Al-Sulaiman *et al.* (1994) also advise immediate discontinuation of immunosuppressive treatment for stages IIIB and IVB.

An important innovation of our study was the conservative management of superficial lymphadenopathy due to Kaposi's sarcoma. In terms of the above protocol of Al-Sulaiman *et al.* (1994), patients with adenopathy would be treated more aggressively with possible discontinuation of immunosuppressive treatment. Our experience has been that these patients also have a good prognosis and that the lymph nodes involute if the same treatment strategy is applied as that for skin lesions (see Figure 10-4).

Cessation or withdrawal for cutaneous/nodal disease?

One of the major criticisms of published data is that often no clear distinction is made between *reduction* and *withdrawal* of immunosuppression, a difference that we have found to be critically important. To the best of our knowledge our study is the first to directly compare the results of reduction as opposed to cessation of immunosuppression. In our own experience, patients with disease localised to the skin/mucous membranes and lymph nodes respond well to treatment. We have shown that there is little difference in the clinical outcome of the Kaposi's sarcoma disease, whether the immunosuppressive agents were discontinued or whether the drugs were reduced. The lesions in all patients improved and the Kaposi's sarcoma remitted. The main difference in the two management strategies *i.e.* reduction of immunosuppression *vs.* withdrawal, was in the outcome of the renal allografts, a fact which has not been emphasised before and is unique to our study. All the patients in whom the immunosuppressive therapy was discontinued returned to dialysis within weeks, whereas the only patients in the second treatment strategy group to lose their renal grafts were those who had advanced renal failure when they were diagnosed with Kaposi's sarcoma. An added benefit of our strategy was the reduction in the plasma creatinine values in those patients who retained their grafts (Fig. 4-10). Our

approach is supported by the experience of Qunibi *et al.* (1993) who found that all five patients in whom they stopped immunosuppression lost their grafts and returned to dialysis. On the other hand, of the 15 patients in whom they only reduced the immunosuppression only 2 returned to dialysis and the creatinine values remained the same or even improved in 10 patients. In our study, adjuvant radiotherapy was only necessary in some patients to treat skin lesions that failed to respond to reduction of immunosuppression alone, and for the management of painful lymphadenopathy.

Importance of time frame

Another problem with published reports is that no time frames are given within which initial treatment outcomes are judged, before resorting to other modalities of treatment. In the Canadian report, patients were managed with reduction of immunosuppression for a minimum of one month only before other forms of therapy were introduced (Shepherd *et al.*, 1997). We have shown that extensive lesions may take several months to regress, an experience shared by others (Frances, 1998) and may in fact show initial deterioration before improvement becomes manifest (Figs. 10-2 to 10-4). This raises the issue of when alternative therapies should be implemented. From our own experience we would recommend a waiting period of at least 2-4 months before implementing more potent therapies, realising that there might be an initial deterioration of the developing Kaposi's sarcoma lesions before improvement occurs. Serial photographs of the lesions provide a useful objective tool for the evaluation of the number, size and colour of the lesions. Regression can also be monitored by assessment of the size of lesions (Frances, 1998).

Results of conservative treatment

In contrast to the excellent results of conservative treatment in our cohort of patients who all improved, the literature suggests that complete remission is achieved in less than one third of cases with limited cutaneous disease and less than 20% of patients who have visceral disease (Penn, 1993). This experience was shared by a Canadian study that found that no patient with widespread cutaneous disease or visceral involvement responded to withdrawal of immunosuppression alone (Shepherd *et al.*, 1997). The shortcomings of the Canadian study have already been commented upon (*vide supra*).

Visceral disease

With regard to visceral disease our recommendation would concur with those of others who suggest that all immunosuppression should be discontinued when the diagnosis of Kaposi's sarcoma is made (Al-Sulaiman *et al.*,1994). The disease is often fulminant and rapidly fatal leaving little opportunity for other intervention (Qunibi *et al.*,1993), as was our own experience.

Mortality

The mortality rate of patients with non-visceral disease is very low, even in patients who return to dialysis. In our study the one-year mortality was 6% with a single patient dying of sepsis, probably related to the Kaposi's sarcoma skin lesions. Several other patients died many years later but were clinically free of Kaposi's sarcoma disease. The causes of death were infection and heart failure. The Saudi experience was similar to ours with infections the commonest cause of delayed mortality (Al-Sulaiman *et al.*,1994).

Which drug to withdraw?

It would appear that exactly which immunosuppressive agent is withdrawn or reduced is immaterial. In most reported studies azathioprine was discontinued, with or without a reduction in the dose of cyclosporine (Qunibi *et al.*,1988;Shepherd *et al.*,1997). Patients may respond to surgical excision and discontinuation of steroids (Qunibi *et al.*,1988). Our own bias was to withdraw the most potent immunosuppressive agent, namely cyclosporine. The other reason for selecting cyclosporine was that the drug may have direct oncogenic potential (See Chapter 16) (Hojo *et al.*,1999). An added benefit to the choice of cyclosporine, besides the saving in the cost of the drug, was the reduction in the plasma creatinine level in the majority of the patients. Despite this, none of our patients suffered episodes of acute rejection, although this is well described in other studies after reduction of immunosuppression (Penn,1995; Petersen *et al.*,1975). In the Canadian series, all the acute rejection episodes were successfully reversed with no patient requiring anti-lymphocyte products (Shepherd *et al.*,1997).

New immunosuppressive drugs

Some of the novel immunosuppressive agents have also been associated with Kaposi's sarcoma. We report in our study a patient who developed Kaposi's sarcoma under mycophenolate mofetil; the lesions regressed with discontinuation of the latter and maintenance of cyclosporine. Another report (Gomez *et al.*,1998) documents the recurrence of Kaposi's sarcoma in a patient who had previously had Kaposi's sarcoma after renal transplantation who went into remission after withdrawal of cyclosporine. The patient's renal function remained stable for seven years before starting to deteriorate, at which point mycophenolate mofetil was introduced. Perhaps, predictably, the Kaposi's sarcoma recurred 90 days later. The lesions improved, but did not disappear, after reduction in the dose of mycophenolate mofetil and the use of ganciclovir (Gomez *et al.*,1998). There has been a report of the regression of the tumour after maintenance of mycophenolate mofetil, but the discontinuation of cyclosporine in a patient receiving both agents (Vella *et al.*,1997). In another case the tumour appeared after changing of cyclosporine to mycophenolate mofetil and tacrolimus (Lee *et al.*,1998). On the other hand, conversion of cyclosporine to tacrolimus halted the progression of Kaposi's sarcoma disease that relapsed after the use of liposomal doxorubicin (Boehringer *et al.*,1999). With the development and more widespread use of more potent immunosuppressive drugs, neoplastic complications including Kaposi's sarcoma will become more frequent.

Other Treatment Modalities

RADIOTHERAPY

Kaposi's sarcoma is a highly radiosensitive tumour (Cohen,1962;Holecek *et al.*,1978) and before the AIDS epidemic was the primary form of local treatment available. The usual indications for radiotherapy in Kaposi's sarcoma are relief of painful lesions, lymphoedema due to lymphatic obstruction by infiltrative Kaposi's sarcoma or to reduce the mass effect of the tumour (Al-Sulaiman MH *et al.*,1994). However, the multifocal nature of the disease and risk of radiation toxicity limit the use of this therapeutic modality. It is the treatment of choice for localised skin lesions in classic Kaposi's sarcoma with regression in over 85% of cases (Cohen,1962;Krown *et*

al.,1992;Mann,1974). Radiotherapy has also been used to good effect in epidemic Kaposi's sarcoma with partial or complete regression of skin lesions in over 50% of cases (Chak *et al.*,1988;Mitsuyasu *et al.*,1984). Extended field radiation has produced good results in renal transplant patients with Kaposi's sarcoma (Harwood *et al.*,1979;Harwood,1981). We have used radiotherapy for painful nodal lesions in 2 patients and for occasional relapse of skin lesions in 2 other patients, with satisfactory results. Lesions regress faster after radiotherapy but it does pose the risk of cutaneous cancer in a susceptible population.

ANTIVIRAL AGENTS

HHV-8 infection is thought to play an important role in the development of Kaposi's sarcoma and it would therefore be logical to consider the use antiviral agents in the battle against Kaposi's sarcoma.

Specific antiherpes treatment

Although several antiherpetic molecules including cidovir, foscavir, and ganciclovir inhibit HHV-8 replication *in vitro*, none has proven to be effective in Kaposi's sarcoma in transplant recipients (Frances,1998). It is doubtful whether the virus can be eradicated at all since the HHV-8, like other human herpesviruses, is integrated into the genome and remains in the body in a latent state. The role of these specific agents in the treatment of Kaposi's sarcoma therefore remains questionable.

Interferon

Recombinant interferon alpha (IFN- α), with its known modulatory effects on the immune system and its antiretroviral and antiproliferative properties, has been used in the treatment of AIDS-associated Kaposi's sarcoma singly or in combination with zidovudine, where it produces partial or complete remission of lesions in 20-60% of cases (Abrams *et al.*,1986;de Wit *et al.*,1988;de Wit *et al.*,1991;Groopman *et al.*,1984;Krown *et al.*,1983;Krown,1987;Lane *et al.*,1988;Schaart *et al.*,1991;Stadler *et al.*,1990). Response rates correlate with baseline CD4 counts (Mitsuyasu,1991). The dose-limiting toxic effects are fever, myalgia, and bone marrow suppression (Gotti *et al.*,1997). Intralesional IFN- α injection has also been attempted in epidemic Kaposi's sarcoma with some encouraging results (Dupuy *et al.*,1993). Preliminary

studies of IFN- α in patients with classic and African forms of Kaposi's sarcoma showed a major response of cutaneous lesions in 70% of treated patients (Rybojad *et al.*,1990). Recombinant interferon has not been widely used in transplant-associated Kaposi's sarcoma. There is a report of its successful use in the treatment of Kaposi's sarcoma that developed after a bone marrow transplant (Porta *et al.*,1991); there is also another report of its use in a child with systemic Kaposi's sarcoma after renal transplantation, but the child died before the effect of the drug could become established (Fournet *et al.*,1992). In iatrogenic Kaposi's sarcoma the use of interferon is limited as in most cases, as we have shown, reduction or withdrawal of immunosuppression does halt progress of the disease. In addition, interferon is known to induce immunologically mediated steroid resistant acute rejection (Kovarik *et al.*,1988;Kramer *et al.*,1984). The use of interferon in iatrogenic Kaposi's sarcoma would therefore be limited to situations where the lesions continue to progress despite the discontinuation of immunosuppressive therapy and loss of the graft (Al-Sulaiman *et al.*,1994). Other biological agents including interferon- β and - δ , tumour necrosis factor and interleukin-2 have been tested less widely and data so far are inconclusive despite occasional claims of benefit for systemic interferon- β and intralesional tumour necrosis factor injections (Krown,1991).

AIDS and HAART

Currently, the treatment of Kaposi's sarcoma presenting as the initial manifestation of AIDS may involve the use of highly active antiretroviral therapy (HAART) with or without specific treatment directed against Kaposi's sarcoma (Antman *et al.*,2000). The resolution of immunosuppression as a result of HAART may also affect the Kaposi's sarcoma (Bennett *et al.*,1998;Volm *et al.*,1997). In one study of 13 AIDS patients with Kaposi's sarcoma who were given HAART none had progression of Kaposi's sarcoma lesions after a median of 10 (range, 0-41) weeks follow-up (Wit *et al.*,1998). In another report there was shrinkage of the Kaposi's sarcoma lesions and a decline in HHV-8 viral loads with HAART (Robles *et al.*,1999). In other reports the Kaposi's sarcoma responded concurrently with the decrease in serum level of the HIV RNA and an increase in the CD4 count (Winceslaus,1998;Wit *et al.*,1998). In a group of patients receiving either foscarnet or ganciclovir — both of which are effective against cytomegalovirus — those receiving foscarnet had a significantly

longer interval before the progression of Kaposi's sarcoma than those receiving ganciclovir (Robles *et al.*,1999). Because the response of Kaposi's sarcoma to HAART is unpredictable, specific local or systemic therapy is usually instituted (Antman *et al.*,2000).

CYTOTOXIC DRUGS

The use of cytotoxic drugs in patients with iatrogenic Kaposi's sarcoma is fraught with difficulty. The finding of HHV-8 in patients with Kaposi's sarcoma in the setting of immunosuppression supports the general principle that the immune system may regulate replication of the virus that through various mechanisms has the potential to contribute to malignant transformation. Reduction of the cellular immunity as a result of the use of immunosuppressive drugs shifts the balance in favour of viral replication and tumour growth (Shepherd *et al.*,1997). Theoretically at least, the use of cytotoxic agents that further compromise cellular immunity may aggravate Kaposi's sarcoma. This therefore brings into question use of these agents in the treatment of Kaposi's sarcoma, a concern shared by others who also consider Kaposi's sarcoma development in organ transplant patients the consequence of over-immunosuppression (Revillard,1979; Sheil,1984; Studniberg *et al.*,1991).

Use in iatrogenic Kaposi's sarcoma

There are currently no controlled studies available on the use of cytotoxic agents in iatrogenic Kaposi's sarcoma and most of the experience has been in other forms of the disease. It has been claimed that drugs used for classic Kaposi's sarcoma may be effective for iatrogenic Kaposi's sarcoma (Antman *et al.*,2000). In a Canadian study, five patients who had failed to respond to withdrawal of immunosuppression or local irradiation received a combination of doxorubicin, bleomycin, and vincristine (Shepherd *et al.*,1997). Two patients had a complete response and two patients a partial response. The major criticism of the study is that patients were followed for a minimum of one month before treatment was deemed to have failed and this, in our opinion, is not long enough.

Indications

Widespread lesions that fail to respond to reduction of immunosuppressives (possibly supplemented by local radiotherapy), lymphoedema, or visceral disease have been treated with chemotherapy, *viz.*, vincristine, vinblastine, and bleomycin as single agents or in combination (Al-Khader *et al.*,1988;Hess *et al.*,1984;Penn,1987). Other agents that also have activity include liposomal anthracyclines, paclitaxel (Dezube,2000) while molecules such as TNP-470 and thalidomide, both antiangiogenesis drugs, have been shown to induce a response in Kaposi's sarcoma and are being used in clinical or early preclinical trials (Yarchoan,1999). The guidelines to therapy still rest however, on studies in AIDS and epidemic Kaposi's sarcoma because there are no data on iatrogenic forms of Kaposi's sarcoma.

The AIDS-Kaposi's sarcoma experience with cytotoxics

Early treatment of AIDS-associated Kaposi's sarcoma was largely based on a consensus from the US National Cancer Institute workshop held in 1981 (De Wys *et al.*,1982). Patients with minimal disease were recommended for single-agent chemotherapy and those with advanced disease for combined chemotherapy. Three molecules were suggested as single agents: etoposide, vinblastine, and bleomycin (Hardy *et al.*,1976;Richman *et al.*,1988). The effectiveness of doxorubicin and bleomycin appears to be confined to isolated cases (Hengge *et al.*,1993). Several uncontrolled studies in patients with pulmonary or extensive mucocutaneous disease showed a better response to combined treatment than single agents (Gotti *et al.*,1997). More severe cases with organ involvement require combination therapy, which can consist of bleomycin and vincristine with or without doxorubicin (Odajnyk *et al.*,1985). A new formulation, liposomal doxorubicin has been found to be superior when compared with conventional combined therapy in controlled studies (Bennett *et al.*,1998;Grunaug *et al.*,1998). A recent introduction to the armamentarium against Kaposi's sarcoma is paclitaxel, a drug that stabilises microtubules and also has antiangiogenic properties (Belotti *et al.*,1996;Sgadari *et al.*,2000).

Results of cytotoxic treatment

The cytotoxic drugs with activity against classic Kaposi's sarcoma are also active against epidemic Kaposi's sarcoma but are associated with lower response rates and shorter responses. Studies have reported rates of partial response of 26% for

weekly vinblastine (Volberding *et al.*,1985), 10-48% for doxorubicin (Gill *et al.*,1991), and 36% for weekly etoposide (Paredes *et al.*,1995). The most effective treatment was the combination of doxorubicin, bleomycin and vincristine which was well tolerated and resulted in partial and complete responses of 88% (Gill *et al.*,1991). In a recent report these agents were successfully used in patients with posttransplant Kaposi's sarcoma that failed other treatment modalities (Shepherd *et al.*,1997). The newer drugs and combinations include the liposomal anthracyclines that are less toxic than the nonliposomal anthracyclines. Liposomal anthracyclines have been shown to have response rates of 25 to 62% (Gill *et al.*,1996;Money-Kyrle *et al.*,1993;Presant *et al.*,1993;Uthayakumar *et al.*,1996). In a randomised study comparing liposomal daunorubicin with a combination of doxorubicin, bleomycin and vincristine the response rate was similar (25% vs. 28%) (Gill *et al.*,1996). However, in a randomised comparison of polyethylene glycol (PEG)-conjugated liposomal doxorubicin with a combination of bleomycin and vincristine the doxorubicin therapy was associated with a much better response rate (59% vs. 23%) (Stewart *et al.*,1998). On the basis of this and other studies, liposomal doxorubicin, although more myelosuppressive than the bleomycin and vincristine combination, is considered to be the first line of treatment for advanced Kaposi's sarcoma (Nasti *et al.*,1999). The new agent paclitaxel was used in three studies totaling 105 patients, and response rates ranged from 49% to 71% (Gill *et al.*,1999;Saville *et al.*,1995;Welles *et al.*,1998), making it an excellent second-line agent. There are others who are of the opinion that paclitaxel is the new gold standard for treatment of patients with advanced disease (Lee *et al.*,1996). The experience with liposomal doxorubicin (Boehringer *et al.*,1999) and paclitaxel (Wu *et al.*,1998) in posttransplant Kaposi's sarcoma has been limited to isolated reports.

LOCAL TREATMENT

Indications for the use of local modalities of treatment include patients with a limited number of mucocutaneous lesions, localised disease associated with complications caused by mass effects and for cosmetic improvement of isolated lesions (Tappero *et al.*,1993). None of our patients required local treatment of their lesions. In AIDS patients the presence of disfiguring lesions are much more of a problem and

warrants aggressive intervention, as the social stigmatisation and the constant visual reminder of fatal illness can cause severe psychological stress (Tappero *et al.*,1993).

Cryosurgery, cryotherapy, laser or surgical removal yields acceptable cosmetic results. Intralesional chemotherapy has also been recommended but is less popular because it is painful (Frances,1998) and is frequently associated with post inflammatory hyperpigmentation (Boudreaux *et al.*,1993). There is little experience with these treatment modalities in patients with iatrogenic Kaposi's sarcoma. In epidemic Kaposi's sarcoma cryotherapy has an 85% complete or partial response rate irrespective of the CD4 count (Tappero *et al.*,1991). For both AIDS and non-AIDS Kaposi's sarcoma intralesional chemotherapy (with a vinca alkaloid) gives a 60% to 88% complete or partial response for cutaneous lesions (Boudreaux *et al.*,1993;Brambilla *et al.*,1984;Conant,1995;Klein *et al.*,1980;Schofer *et al.*,1991). In AIDS patients laser therapy has been used to treat larger oral lesions (Marcusen *et al.*,1985;Schweitzer,1988;Schweitzer *et al.*,1990), but the technique does pose a risk to the laser operator (Baggish *et al.*,1991;Garden *et al.*,1988;Sawchuk *et al.*,1989;Starr *et al.*,1992;Tappero *et al.*,1992). Laser has also been proven effective for macular cutaneous lesions but these recur within 12 weeks (Bacchetti *et al.*,1988).

SUMMARY

Reducing the degree of immunosuppression in patients with Kaposi's sarcoma after renal transplantation is now unquestionably the first line of treatment. In our experience this is a highly effective therapeutic intervention in patients with mucocutaneous disease and disease limited to superficial lymph nodes. Lesions regress over weeks to months with additional radiotherapy treatment seldom required. The less satisfactory results reported in the literature may be due to the failure to allow lesions adequate time to regress. It also makes it difficult to interpret the results of other forms of treatment that are used, because any response could be interpreted as due to the spontaneous involution of the lesions to immunosuppressive drug reduction rather than the effect of the additional treatment.

We showed conclusively that *cessation* of immunosuppression had to be differentiated from *reduction*, as therapeutic options: with both, Kaposi's sarcoma lesions improved but, with the maintenance of immunosuppression albeit reduced, renal function was preserved (see pages 4-25 to 4-27).

With visceral Kaposi's sarcoma, the indications from the literature, and with our limited experience we concur, is that all immunosuppression should be discontinued when the diagnosis of iatrogenic Kaposi's sarcoma is confirmed and the use of chemotherapy considered, especially if there is pulmonary involvement.

There is no proven cytotoxic regimen that has been proven to be superior. The mainstay of treatment has been vincristine, bleomycin and doxorubicin in various combinations. Newer regimens include liposomal doxorubicin and paclitaxel. None of these regimens have been used in control trials in renal transplant patients.

Local treatments beside radiotherapy have limited use in the management of iatrogenic Kaposi's sarcoma.

LITERATURE CITED

- Abrams, D. I. and Volberding, P. A. (1986). Alpha interferon therapy of AIDS-associated Kaposi's sarcoma. *Semin.Oncol.* **13**, 43.
- Al-Khader, A. A., Suleiman, M., Al-Hasani, M., and Haleem, A. (1988). Posttransplant Kaposi sarcoma: staging as a guide to therapy and prognosis. *Nephron.* **48**, 165.
- Al-Sulaiman MH and Al-Kader, A. A. (1994). Kaposi's sarcoma in renal transplant recipients. *Transplant.Sci.* **4**, 46.
- Al-Sulaiman, M., Haleem, A., and Al-Khader, A. A. (1987). Kaposi's sarcoma after renal transplantation. *Transplant Proc.* **19**, 2243.
- Antman, K. and Chang, Y. (2000). Kaposi's sarcoma. *N Engl J Med.* **342**, 1027.
- Bacchetti, P., Osmond, D., Chaisson, R. E., *et al.* (1988). Survival patterns of the first 500 patients with AIDS in San Francisco. *J Infect.Dis.* **157**, 1044.

- Baggish, M. S., Poiesz, B. J., Joret, D., Williamson, P., and Refai, A. (1991). Presence of human immunodeficiency virus DNA in laser smoke. *Lasers Surg.Med.* **11**, 197.
- Belotti, D., Vergani, V., Drudis, T., *et al.* (1996). The microtubule-affecting drug paclitaxel has antiangiogenic activity. *Clin Cancer Res.* **2**, 1843.
- Bennett, C. L., Golub, R. M., Stinson, T. J., *et al.* (1998). Cost-effectiveness analysis comparing liposomal anthracyclines in the treatment of AIDS-related Kaposi's sarcoma. *J Acquir.Immune.Defic.Syndr.Hum.Retrovirol.* **18**, 460.
- Bhoopchand, A., Cooper, D. K., Novitzky, D., Rose, A. G., and Reichart, B. (1986). Regression of Kaposi's sarcoma after reduction of immunosuppressive therapy in a heart transplant patient. *J Heart Transplant.* **5**, 461.
- Boehringer, M., Schwarz, A., and Keller, F. (1999). Kaposi's sarcoma after renal transplantation: treatment with liposomal doxorubicin [letter]. *Nephrol Dial Transplant.* **14**, 1342.
- Boudreaux, A. A., Smith, L. L., Cosby, C. D., Bason, M. M., Tappero, J. W., and Berger, T. G. (1993). Intralesional vinblastine for cutaneous Kaposi's sarcoma associated with acquired immunodeficiency syndrome. A clinical trial to evaluate efficacy and discomfort associated with infection. *J Am Acad.Dermatol.* **28**, 61.
- Brambilla, L., Boneschi, V., Beretta, G., and Finzi, A. F. (1984). Intralesional chemotherapy for Kaposi's sarcoma. *Dermatologica.* **169**, 150.
- Chak, L. Y., Gill, P. S., Levine, A. M., Meyer, P. R., Anselmo, J. A., and Petrovich, Z. (1988). Radiation therapy for acquired immunodeficiency syndrome-related Kaposi's sarcoma. *J Clin Oncol.* **6**, 863.
- Cohen, L. (1962). Dose, time and volume parameters in irradiation therapy of Kaposi's sarcoma. *Br J Radiol.* **35**, 485.
- Conant, M. A. (1995). Management of human immunodeficiency virus-associated malignancies. *Recent Results Cancer Res.* **139**, 423.
- de Wit, R., Danner, S. A., Bakker, P. J., Lange, J. M., Eeftinck Schattenkerk, J. K., and Veenhof, C. H. (1991). Combined zidovudine and interferon-alpha treatment in patients with AIDS-associated Kaposi's sarcoma. *J Intern.Med.* **229**, 35.
- de Wit, R., Schattenkerk, J. K., Boucher, C. A., Bakker, P. J., Veenhof, K. H., and Danner, S. A. (1988). Clinical and virological effects of high-dose recombinant interferon- alpha in disseminated AIDS-related Kaposi's sarcoma. *Lancet.* **2**, 1214.

- De Wys, W. D., Curran, J., Henle, W., and Johnson, G. (1982). Workshop on Kaposi's sarcoma: meeting report. *Cancer Treat.Rep.* **66**, 1387.
- Dezube, B. J. (2000). Acquired immunodeficiency syndrome-related Kaposi's sarcoma: clinical features, staging, and treatment. *Semin.Oncol.* **27**, 424.
- Dupuy, J., Price, M., Lynch, G., Bruce, S., and Schwartz, M. (1993). Intralesional interferon-alpha and zidovudine in epidemic Kaposi's sarcoma. *J Am Acad.Dermatol.* **28**, 966.
- Fournet, J. C., Peuchmaur, M., Eckart, P., et al. (1992). Multicentric Kaposi's sarcoma in a 5-year-old human immunodeficiency virus-negative renal allograft recipient. *Hum.Pathol.* **23**, 956.
- Frances, C. (1998). Kaposi's sarcoma after renal transplantation. *Nephrol Dial Transplant.* **13**, 2768.
- Garden, J. M., O'Banion, M. K., Shelnitz, L. S., et al. (1988). Papillomavirus in the vapor of carbon dioxide laser-treated verrucae. *JAMA.* **259**, 1199.
- Gill, P. S., Rarick, M., McCutchan, J. A., et al. (1991). Systemic treatment of AIDS-related Kaposi's sarcoma: results of a randomized trial. *Am J Med.* **90**, 427.
- Gill, P. S., Tulpule, A., Espina, B. M., et al. (1999). Paclitaxel is safe and effective in the treatment of advanced AIDS-related Kaposi's sarcoma. *J Clin Oncol.* **17**, 1876.
- Gill, P. S., Wernz, J., Scadden, D. T., et al. (1996). Randomized phase III trial of liposomal daunorubicin versus doxorubicin, bleomycin, and vincristine in AIDS-related Kaposi's sarcoma. *J Clin Oncol.* **14**, 2353.
- Gomez, E., Aguado, S., Rodriguez, M., and Alvarez, Grande J. (1998). Kaposi's sarcoma after renal transplantation--disappearance after reduction of immunosuppression and reappearance 7 years later after start of mycophenolate mofetil treatment [letter]. *Nephrol Dial Transplant.* **13**, 3279.
- Gotti, E. and Remuzzi, G. (1997). Post-transplant Kaposi's sarcoma. *J.Am.Soc.Nephrol.* **8**, 130.
- Groopman, J. E., Gottlieb, M. S., Goodman, J., et al. (1984). Recombinant alpha-2 interferon therapy for Kaposi's sarcoma associated with the acquired immunodeficiency syndrome. *Ann.Intern.Med.* **100**, 671.
- Grunaug, M., Bogner, J. R., Loch, O., and Goebel, F. D. (1998). Liposomal doxorubicin in pulmonary Kaposi's sarcoma: improved survival as compared to patients without liposomal doxorubicin. *Eur.J Med Res.* **3**, 13.

- Hardy, M. A., Goldfarb, P., Levine, S., *et al.* (1976). De novo Kaposi's sarcoma in renal transplantation. Case report and brief review. *Cancer*. **38**, 144.
- Harwood, A. R. (1981). Kaposi's sarcoma. An update on the results of extended field radiotherapy. *Arch.Dermatol.* **117**, 775.
- Harwood, A. R., Osoba, D, Hofstader, Sophie. L, *et al.* (1979). Kaposi's sarcoma in recipients of renal transplants. *Am.J.Med.* **67**, 759.
- Hengge, U. R., Brockmeyer, N. H., Baumann, M., Reimann, G., and Goos, M. (1993). Liposomal doxorubicin in AIDS-related Kaposi's sarcoma. *Lancet*. **342**, 497.
- Hess, A. D., Donnenberg, A. D., Engel, P., Tutschuka, P. Y., and Santos, G. W. (1984). Suppressor-cell amplification circuitry in cyclosporine-treated MLR cultures. *In Cyclosporine Biological Activity and Clinical Applications* , 1st ed. (Kahan, B. D., eds.), p.127, Grune and Stratton, Orlando.
- Hojo, M., Morimoto, T., Maluccio, M., *et al.* (1999). Cyclosporine induces cancer progression by a cell-autonomous mechanism [see comments]. *Nature*. **397**, 530.
- Holecek, M. J. and Harwood, A. R. (1978). Radiotherapy of Kaposi's sarcoma. *Cancer*. **41**, 1733.
- Klein, E., Schwartz, R. A., Laor, Y., Milgrom, H., Burgess, G. H., and Holtermann, O. A. (1980). Treatment of Kaposi's sarcoma with vinblastine. *Cancer*. **45**, 427.
- Kovarik, J., Mayer, G., Pohanka, E., *et al.* (1988). Adverse effect of low-dose prophylactic human recombinant leukocyte interferon-alpha treatment in renal transplant recipients. Cytomegalovirus infection prophylaxis leading to an increased incidence of irreversible rejections. *Transplantation*. **45**, 402.
- Kramer, P., ten Kate, F. W., Bijnen, A. B., Jeekel, J., and Weimar, W. (1984). Recombinant leucocyte interferon A induces steroid-resistant acute vascular rejection episodes in renal transplant recipients. *Lancet*. **1**, 989.
- Krown, S. E. (1987). The role of interferon in the therapy of epidemic Kaposi's sarcoma. *Semin.Oncol.* **14**, 27.
- Krown, S. E. (1991). Interferon and other biologic agents for the treatment of Kaposi's sarcoma. *Hematol.Oncol.Clin North Am.* **5**, 311.
- Krown, S. E., Myskowski, P. L., and Paredes, J. (1992). Medical management of AIDS patients. Kaposi's sarcoma. *Med Clin North Am.* **76**, 235.

- Krown, S. E., Real, F. X., Cunningham-Rundles, S., *et al.* (1983). Preliminary observations on the effect of recombinant leukocyte A interferon in homosexual men with Kaposi's sarcoma. *N Engl J Med.* **308**, 1071.
- Lane, H. C., Kovacs, J. A., Feinberg, J., *et al.* (1988). Anti-retroviral effects of interferon-alpha in AIDS-associated Kaposi's sarcoma. *Lancet.* **2**, 1218.
- Lee, F. C., Mitsuyasu, R. T., and Miles, S. A. (1996). Kaposi's sarcoma: relationship to a novel herpesvirus and advances in therapy. *AIDS.* **10 Suppl A**, S173.
- Lee, P. C., Wang, Y. W., Su, I. J., Lin, Y. J., and Lei, H. Y. (1998). Immunosuppressive drugs and HHV-8 in a patient with a renal transplant and Kaposi's sarcoma [letter]. *Lancet.* **351**, 1175.
- Lesnoni La Parola, I, Masini, C., Nanni, G., Diociaiuti, A., Panocchia, N., and Cerimele, D. (1997). Kaposi's sarcoma in renal-transplant recipients: experience at the Catholic University in Rome, 1988-1996. *Dermatology.* **194**, 229.
- Mann, S. G. (1974). Kaposi's sarcoma. Experience with ten cases. *Am J Roentgenol.Radium.Ther.Nucl.Med.* **121**, 793.
- Marcusen, D. C. and Sooy, C. D. (1985). Otolaryngologic and head and neck manifestations of acquired immunodeficiency syndrome (AIDS). *Laryngoscope.* **95**, 401.
- Margolius, L, Stein, M, Spencer, D, and Bezwoda, W. R. (1994). Kaposi's sarcoma in renal transplant recipients. *S.Afr.Med.J.* **84**, 16.
- Mitsuyasu, R. T. (1991). Interferon alpha in the treatment of AIDS-related Kaposi's sarcoma. *Br J Haematol.* **79 Suppl 1**, 69.
- Mitsuyasu, R. T. and Groopman, J. E. (1984). Biology and therapy of Kaposi's sarcoma. *Semin.Oncol.* **11**, 53.
- Money-Kyrle, J. F., Bates, F., Ready, J., Gazzard, B. G., Phillips, R. H., and Boag, F. C. (1993). Liposomal daunorubicin in advanced Kaposi's sarcoma: a phase II study. *Clin Oncol.(R.Coll.Radiol).* **5**, 367.
- Montagnino, G., Bencini, P. L., Tarantino, A., Caputo, R, and Ponticelli, C. (1994). Clinical features and course of Kaposi's sarcoma in kidney transplant recipients:report of 13 cases. *Am.J.Nephrol.* **14**, 121.
- Nasti, G., Errante, D., Santarossa, S., Vaccher, E., and Tirelli, U. (1999). A risk and benefit assessment of treatment for AIDS-related Kaposi's sarcoma. *Drug Saf.* **20**, 403.

- Nickoloff, B. J. and Griffiths, C. E. (1989). Factor XIIIa-expressing dermal dendrocytes in AIDS-associated cutaneous Kaposi's sarcomas. *Science*. **243**, 1736.
- Odajnyk, C. and Muggia, F. M. (1985). Treatment of Kaposi's sarcoma: overview and analysis by clinical setting. *J Clin Oncol*. **3**, 1277.
- Paredes, J., Kahn, J. O., Tong, W. P., et al. (1995). Weekly oral etoposide in patients with Kaposi's sarcoma associated with human immunodeficiency virus infection: a phase I multicenter trial of the AIDS Clinical Trials Group. *J Acquir.Immune.Defic.Syindr.Hum.Retrovirol*. **9**, 138.
- Penn, I. (1983). Kaposi's sarcoma in immunosuppressed patients. *J Clin.Lab.Immunol*. **12**, 1.
- Penn, I. (1987). Cancers following cyclosporine therapy. *Transplantation*. **43**, 32.
- Penn, I. (1993). Incidence and treatment of neoplasia after transplantation. *J Heart Lung Transplant*. **12**, S328.
- Penn, I. (1995). Sarcomas in organ allograft recipients. *Transplantation*. **60**, 1485.
- Petersen, V. P., Olsen, T. S., Kissmeyer, Nielsen F., et al. (1975). Late failure or human renal transplants. An analysis of transplant disease and graft failure among 125 recipients surviving for one to eight years. *Medicine Baltimore*. **54**, 45.
- Porta, F., Bongiorno, M., Locatelli, F., et al. (1991). Kaposi's sarcoma in a child after autologous bone marrow transplantation for non-Hodgkin's lymphoma. *Cancer*. **68**, 1361.
- Presant, C. A., Scolaro, M., Kennedy, P., et al. (1993). Liposomal daunorubicin treatment of HIV-associated Kaposi's sarcoma. *Lancet*. **341**, 1242.
- Qunibi, W., Akhtar, M., Sheth, K., et al. (1988). Kaposi's sarcoma: The most common tumor after renal transplantation in Saudi Arabia. *Am.J.Med*. **84**, 225.
- Qunibi, W., Barri, Y., Alfurayh, O., et al. (1993). Kaposi's sarcoma in renal transplant recipients: a report on 26 cases from a single institution. *Transplant.Proc*. **25**, 1402.
- Revillard, J. P. (1979). Immunologic alterations in chronic renal insufficiency. *Adv.Nephrol.Necker Hosp*. **8**, 365.
- Richman, S. P. and Vogel, C. L. (1988). Kaposi's sarcoma. *In* Current therapy in Haematology-Oncology-3, (Brain, M. C. and Carbone, P. P., eds.), p.353, Marcel Dekker, Toronto.

- Robles, R., Lugo, D., Gee, L., and Jacobson, M. A. (1999). Effect of antiviral drugs used to treat cytomegalovirus end-organ disease on subsequent course of previously diagnosed Kaposi's sarcoma in patients with AIDS. *J Acquir.Immune.Defic.Syndr.Hum.Retrovirol.* **20**, 34.
- Rybojad, M., Borradori, L., Verola, O., Zeller, J., Puissant, A., and Morel, P. (1990). Non-AIDS-associated Kaposi's sarcoma (classical and endemic African types): treatment with low doses of recombinant interferon-alpha. *J Invest Dermatol.* **95**, 176S.
- Saville, M. W., Lietzau, J., Pluda, J. M., et al. (1995). Treatment of HIV-associated Kaposi's sarcoma with paclitaxel. *Lancet.* **346**, 26.
- Sawchuk, W. S., Weber, P. J., Lowy, D. R., and Dzubow, L. M. (1989). Infectious papillomavirus in the vapor of warts treated with carbon dioxide laser or electrocoagulation: detection and protection. *J Am Acad.Dermatol.* **21**, 41.
- Schaart, F. M., Bratzke, B., Ruszczak, Z., Stadler, R., Ehlers, G., and Orfanos, C. E. (1991). Long-term therapy of HIV-associated Kaposi's sarcoma with recombinant interferon alpha-2a. *Br J Dermatol.* **124**, 62.
- Schofer, H., Ochsendorf, F. R., Hochscheid, I., and Milbradt, R. (1991). Kaposi-Sarkome im Gesicht. Palliative Behandlung mit Kryochirurgie, intralasionaler Chemotherapie, Rontgenweichstrahltherapie und Camouflage. [Facial kaposi's sarcoma. Palliative treatment with cryotherapy, intralesional chemotherapy, low-dose roentgen therapy and camouflage]. *Hautarzt.* **42**, 492.
- Schweitzer, V. G. (1988). Photodynamic therapy improves Kaposi's sarcoma in AIDS patients. *Am Fam.Physician.* **38**, 260.
- Schweitzer, V. G. and Visscher, D. (1990). Photodynamic therapy for treatment of AIDS-related oral Kaposi's sarcoma. *Otolaryngol.Head Neck Surg.* **102**, 639.
- Sgadari, C., Toschi, E., Palladino, C., et al. (2000). Mechanism of paclitaxel activity in Kaposi's sarcoma. *J Immunol.* **165**, 509.
- Sheil, A. G. (1977). Cancer in renal allograft recipients in Australia and New Zealand. *Transplant Proc.* **9**, 1133.
- Sheil, A. G. (1984). Cancer in organ transplant recipients: part of an induced immune deficiency syndrome. *Br Med J (Clin Res Ed).* **288**, 659.
- Shepherd, F. A., Maher, E., Cardella, C., et al. (1997). Treatment of Kaposi's sarcoma after solid organ transplantation. *J Clin.Oncol.* **15**, 2371.

- Stadler, R., Bratzke, B., Schaart, F., and Orfanos, C. E. (1990). Long-term combined rIFN-alpha-2a and zidovudine therapy for HIV- associated Kaposi's sarcoma: clinical consequences and side effects. *J Invest Dermatol.* **95**, 170S.
- Starr, J. C., Kilmer, S. L., and Wheeland, R. G. (1992). Analysis of the carbon dioxide laser plume for simian immunodeficiency virus. *J Dermatol Surg.Oncol.* **18**, 297.
- Stewart, S., Jablonowski, H., Goebel, F. D., *et al.* (1998). Randomized comparative trial of pegylated liposomal doxorubicin versus bleomycin and vincristine in the treatment of AIDS-related Kaposi's sarcoma. International Pegylated Liposomal Doxorubicin Study Group. *J Clin Oncol.* **16**, 683.
- Studniberg, H. M., Rivers, J. K., Cooke, B. E., and Barnetson, R. S. (1991). The coexistence of lymphangiosarcoma and Kaposi's sarcoma in a renal transplant recipient. *Cancer.* **68**, 2330.
- Tappero, J. W., Berger, T. G., Kaplan, L. D., Volberding, P. A., and Kahn, J. O. (1991). Cryotherapy for cutaneous Kaposi's sarcoma (KS) associated with acquired immune deficiency syndrome (AIDS): a phase II trial. *J Acquir.Immune.Defic.Syindr.* **4**, 839.
- Tappero, J. W., Conant, M. A., Wolfe, S. F., and Berger, T. G. (1993). Kaposi's sarcoma. Epidemiology, pathogenesis, histology, clinical spectrum, staging criteria and therapy. *J Am Acad.Dermatol.* **28**, 371.
- Tappero, J. W., Grekin, R. C., Zanelli, G. A., and Berger, T. G. (1992). Pulsed-dye laser therapy for cutaneous Kaposi's sarcoma associated with acquired immunodeficiency syndrome. *J Am Acad.Dermatol.* **27**, 526.
- Uthayakumar, S., Bower, M., Money-Kyrle, J., *et al.* (1996). Randomized cross-over comparison of liposomal daunorubicin versus observation for early Kaposi's sarcoma. *AIDS.* **10**, 515.
- Vella, J. P., Mosher, R., and Sayegh, M. H. (1997). Kaposi's sarcoma after renal transplantation. *N Engl J Med.* **336**, 1761.
- Volberding, P. A., Abrams, D. I., Conant, M., Kaslow, K., Vranizan, K., and Ziegler, J. (1985). Vinblastine therapy for Kaposi's sarcoma in the acquired immunodeficiency syndrome. *Ann.Intern.Med.* **103**, 335.
- Volm, M. D. and Wenz, J. (1997). Patients with advanced AIDS-related Kaposi's sarcoma (EKS) no longer require systemic therapy after the introduction of effective antiretroviral therapy. *Proc.Am.Soc.Clin.Oncol.* **16**, 46a.abstract.

- Welles, L., Saville, M. W., Lietzau, J., *et al.* (1998). Phase II trial with dose titration of paclitaxel for the therapy of human immunodeficiency virus-associated Kaposi's sarcoma. *J Clin Oncol.* **16**, 1112.
- Winceslaus, J. (1998). Regression of AIDS-related pleural effusion with HAART. Highly active antiretroviral therapy. *Int.J STD AIDS.* **9**, 368.
- Wit, F. W., Sol, C. J., Renwick, N., *et al.* (1998). Regression of AIDS-related Kaposi's sarcoma associated with clearance of human herpesvirus-8 from peripheral blood mononuclear cells following initiation of antiretroviral therapy [letter]. *AIDS.* **12**, 218.
- Wu, C. J. and Scadden, D. T. (1998). Posttransplant Kaposi's sarcoma treated with paclitaxel. *J Clin Oncol.* **16**, 3478.
- Yarchoan, R. (1999). Therapy for Kaposi's sarcoma: recent advances and experimental approaches. *J Acquir.Immune.Defic.Syindr.* **21 Suppl 1** S66.

Chapter 12

SKIN CANCER IN RENAL ALLOGRAFT RECIPIENTS

Skin malignancies are the most common cancers to occur in patients who have received renal allografts and are an important cause of morbidity in long-term survivors (Bencini *et al.*,1983;Blohme *et al.*,1990;Boyle *et al.*,1984;Gupta *et al.*,1986;Hardie *et al.*,1980;Hartevelt *et al.*,1990;Hoover *et al.*,1973;Koranda *et al.*,1974;Lindelöf *et al.*,2000;Walder *et al.*,1971). This must however be seen in the context of skin cancers in the general population. Nonmelanoma skin cancers are the most common cancers in the general Caucasian population of the United States (Boring *et al.*,1992) as well as in Great Britain, where the prevalence was 1.9% in 1970 (Beirn *et al.*,1970). The incidence appears to be increasing, with a 60% to 70% increase being observed between 1973 to 1987 (Gallagher *et al.*,1990). Because most skin cancers are diagnosed and treated in outpatient or general practitioner's office and not reported to central registries, the

available statistics both in South Africa and elsewhere grossly underestimate the actual number patients with of skin cancer. Basal cell carcinoma is the most common skin cancer in white patients and accounts for 75% to 80% of all reported skin cancer cases (Roberts,1990;Yiannias *et al.*,1988). Squamous cell carcinoma is the second most common skin cancer and is estimated to account for 20% to 25% of all reported cases. The incidence of skin cancers following renal transplantation has been discussed in detail in Chapter 6.

COMMENTS ON INCIDENCE

The increased incidence of skin cancer in solid organ transplant recipients was first noted in Australia and New Zealand (Marshall,1974;Sheil,1977;Walder *et al.*,1971) where it was related the high levels of ultraviolet-B (UV-B) radiation associated with extended periods of sunlight (Hardie *et al.*,1980;Marshall,1974;Sheil,1977;Sheil *et al.*,1979;Sheil *et al.*,1993;Walder *et al.*,1971). However, whereas skin cancers were initially thought to be uncommon in low risk countries such as Europe (Barr *et al.*,1989;Bencini *et al.*,1983;Blohme *et al.*,1984;Jacobs *et al.*,1981), Scandinavia (Birkeland,1983;Lindelöf *et al.*,2000), and the United States (Hoxtell *et al.*,1977;Koranda *et al.*,1974;Matas *et al.*,1975), the passage of time has confirmed that renal transplant patients in these countries are also at a greatly increased risk of developing skin cancer (Hartevelt *et al.*,1990). In the Australasian experience the incidence of skin cancers at 10 and 20 years were 27% and 57% respectively (Sheil *et al.*,1993), compared with 10% and 40% for the corresponding intervals in the report from the Netherlands (Hartevelt *et al.*,1990). In a later study there was an even larger discrepancy between an Australian group of patients and a Dutch control population (Table 12-1). In a report from Oxford, the authors found that not only were skin cancers more common in Australia, but the lesions also appeared earlier than in the temperate climates (Liddington *et al.*,1989). In the latter report no skin malignancies were diagnosed in the first three years after transplantation, as was the case in a similar report from Sweden (Blohme *et al.*,1984). This geographical difference in incidence is probably due to the influence of solar UV-B radiation but both these reports emphasise that the risk of developing skin cancers increases

Table 12-1. Cumulative incidence of skin cancer (in percentages) in cohorts of transplant patients from two different latitudes.

	Years Posttransplant						
	1	3	5	7	11	15	20
Australian	7	16	25	33	45	59	70
Dutch	0.2	0.7	3	6	16	24	41

Drawn from data from Bouwes *et al.*,1996. The incidence of skin cancer in this Australian cohort is the highest ever reported.

progressively. The rareness of skin cancers in non-Anglo Saxon populations, including our own non-white patients was also noted in Chapter 6. This corresponds to the observations of Glover and his colleagues (1994) who found no skin cancers in patients with skin types V or VI.

REVERSAL OF RATIOS

Another important observation made in Chapter 6, was the change in the proportions of skin cancers that develop following renal transplantation in comparison to the general population. In the latter, basal cell carcinoma is the most common lesion, whereas following transplantation squamous cell carcinoma is 4 times more common than basal cell carcinoma in certain reports (Hartevelt *et al.*,1990;Walder *et al.*,1971) and equally common in our experience. Compared to the general population, squamous cell carcinoma has been estimated to occur with frequencies of between 40 and 250 times higher (Hardie *et al.*,1980;Hartevelt *et al.*,1990) and basal cell carcinoma 10 times higher (Hartevelt *et al.*,1990). Malignant melanoma is estimated to be 5 times more frequent following transplantation than expected (Greene *et al.*,1981).

DEMOGRAPHIC OBSERVATIONS

Gender

We observed that female patients were less at risk of developing skin cancers than males, confirming the findings of others (Bouwes *et al.*,1996; Disler *et al.*,1981; Liddington *et al.*,1989; Lindelöf *et al.*,2000; Sheil *et al.*,1985; Sheil,1994a). The

reason for this is unclear, although differences in sun-exposure, hormonal responses or skin types may all be relevant (Liddington *et al.*,1989). In the absence of accurate data from the National Cancer Registry, we were unable to calculate the relative risk of developing skin cancer. This was done, however, in a report from Scandinavia, where it was found that the relative risk of non-melanoma skin cancer was 109 for men and 93 for women (Lindelöf *et al.*,2000). In their study there was no increase in the relative risk of malignant melanoma.

Age

The mean age of our patients who developed skin cancers was 43.8 years and it has been recognised that, in general, skin cancers occur 20 to 30 years earlier than in non-immunosuppressed patients (Beatty *et al.*,1980;Sequeira *et al.*,1992). In Melbourne, Australia, the average age at which patients with transplanted organs develop their first skin cancers is 47 years. For immunocompetent individuals in the same region the average age at which basal cell carcinoma occurs is 64 years and it is 72 years for squamous cell carcinoma of the skin (Czarnecki *et al.*,1991b).

TYPES OF SKIN CANCER (Colour Plates: Figs. 12-2 to 12- 4)

Neoplastic skin lesions that can occur in post-renal transplant patients include solar keratosis, Bowen's disease, keratoacanthomas, squamous cell carcinoma, basal cell carcinoma, and malignant melanoma. Some cancers present as metastatic malignancies or undifferentiated anaplastic lesions (Sheil,1994a). The sequence of changes that result in the malignancy have been described (Walder *et al.*,1971). Initially, skin lesions present as areas of thickening or scaliness and are described as solar keratosis. These lesions occur in sun-exposed areas and are often multiple. These lesions may undergo spontaneous regression but do recur. It has been shown that strong association exists between the number of keratotic skin lesions and the occurrence of both squamous cell carcinoma and basal cell carcinoma (Bouwes *et al.*,1991b). Patients with solar keratosis also often have areas of erythema, that may be flattened or nodular, and histological examination of the lesions reveals the presence of Bowen's disease, a premalignant condition. Another tumour that commonly occurs in renal transplant recipients, is keratoacanthoma that is considered a benign lesion in immunocompetent patients. However, in allograft

recipients all these lesions have the potential of rapid progress to invasive squamous cell carcinoma (Marshall,1974;McLelland *et al.*,1988). In addition, in these patients squamous cell carcinoma tend to be aggressive and often metastasise (Sheil *et al.*,1979). Another important observation is that patients with skin cancers are more likely to develop other more fulminant types of cancer than are allograft recipients without skin cancer (Sheil,1977).

SITES OF OCCURRENCE

The skin lesions occur predominantly in areas of the body exposed to sunlight, but are by no means confined to these areas (Sheil,1994a). At least 2 patients in our cohort developed almost generalised squamous cell carcinoma of the skin and required repeated operations to have the lesions removed. None of our patients had lesions involving the groin or axilla, but involvement of the vulva and vagina has been described (Sheil,1994a). Some of these lesions may have their origin in viral warts but most do not (Cateron *et al.*,1984). Approximately 40% of transplant recipients develop warts (Koranda *et al.*,1974;Spencer *et al.*,1970). The majority of patients who develop warts have a childhood history of the problem suggesting that their development after transplantation is the result of reactivation of latent virus rather than a primary infection. Patients with widespread warts have been described to develop multiple squamous cell carcinoma and it has been suggested therefore that these may be virally induced, as a result of activation of immunosuppression (Koranda *et al.*,1974;Mullen *et al.*,1976). However, the malignant lesions occurred only in sun-exposed areas suggesting interaction between various carcinogenic stimuli (Koranda *et al.*,1974).

AETIOLOGY

The aetiology of skin malignancies in the renal transplant patient is the result of the influence of a number of factors, both intrinsic and extrinsic. By far the most important extrinsic factors are the exposure to sunlight and type of skin according to the classification of Fitzpatrick (Table 12-2). Chemical carcinogens have been widely studied especially in animals as agents of cutaneous cancers. Also of relevance to transplant patients has been the recent focus on the role of viruses, especially human papillomavirus, on the aetiology of cutaneous and mucous

Table 12-2 Skin type assessment

Skin Type	Sunburn and Tanning History
I	Always burns, never tans
II	Always burns
III	Burns often, tans gradually
IV	Burns minimally, tans gradually (light brown)
V	Burns rarely, tans profusely (dark brown)
VI	Never burns, deeply pigmented (black)

From Fitzpatrick, (1975)

membrane carcinomas (Barr *et al.*,1989;Lutzner *et al.*,1980;Lutzner,1978;Lutzner *et al.*,1983). Host genetic makeup and host immunity also play important roles in the development of skin cancers as do ionizing radiation and primary irritation (Brash,1997).

Exposure to UV light and skin type

Exposure to UV radiation in the form of sunlight is overwhelmingly the most important aetiological factor for the development of nonmelanoma skin cancer (MacKie *et al.*,1987; Marks,1995) as indicated by the occurrence of tumours predominantly on sun-exposed sites, particularly in fair-skinned individuals who have high levels of exposure to UV radiation (Barr *et al.*,1989;Beatty *et al.*,1980;Bouwes *et al.*,1991b;Boyle *et al.*,1984;Hardie *et al.*,1980). The amount of exposure, the timing of exposure and the skin type being exposed determine the rate of carcinogenesis. Light-skinned people with blonde or red hair who tend to burn rather than tan develop cancer much more readily than dark-skinned individuals who are protected by the melanin pigment in their skin (Urbach,1984). We have shown that sun-exposed areas of the body are more susceptible to skin cancers. Squamous cell carcinoma usually occurs on the head, neck and dorsum of the hands, which are the sites of maximal chronic sun-exposure, and development of malignant lesions is directly related to the amount of solar radiation received (Bouwes *et al.*,1991b).

Sites

An important finding in our study was that basal cell carcinomas were more likely to occur in areas not exposed to sunlight than squamous cell carcinomas. Another recent study has shown that 97% of squamous cell carcinomas occurred in sun-exposed areas of the skin with preference for the dorsum of the hand and the face (Hartevelt *et al.*,1990). However, basal cell carcinomas were frequently found on the chest (34%) and did not occur on the back of the hands (Hartevelt *et al.*,1990). There is an increased incidence of skin cancer in Australia as compared with Scandinavian countries where the population has similar skin types but the UV light exposure is different.

The importance of distance from the equator on the risk of skin cancer is demonstrated in Table 12-3: the prevalence of skin cancer correlates inversely with the geographic latitude away from the equator (Doll *et al.*,1970). Although it is the cumulative amount of lifetime UV exposure that influences the development of skin cancer (Aubry *et al.*,1985;Kwa *et al.*,1992;Luande *et al.*,1985), epidemiological studies indicate that sunlight exposure critical for skin cancer occurs before the age of 15 to 20 years (Kricker *et al.*,1991;Marks *et al.*,1990). There is currently considerable concern about the depletion of the ozone layer of the global atmosphere by certain chemicals. The ozone layer acts as a powerful barrier in

Table 12-3. *The occurrence of skin cancer in renal/organ transplant recipients*

Country	No. of recipients	No. of patients with tumours	Frequency (%)	Latitude	Follow-up (Yrs)	Latent Period (mo.)	Reference
Brisbane, Australia	1098	271	24.7	27°28'N	2-11	55.2	Hoxtell <i>et al.</i> ,1977
Australasia	735	76	10.3	30°52'N	0-11	75.6	Sheil <i>et al.</i> ,1980
Cape Town, RSA	542	13	2.4 (7) ¹	33°55'S	2-22	72.8	Present study
Maryland, USA	6297	21	0.33	39°N	1-20	-	Hoover <i>et al.</i> ,1973
Toronto, Canada	523	27	5.3	43°40'N	2-20	86.6	Gupta <i>et al.</i> ,1986
Minnesota, USA	495	7	1.4	44°50'N	2-11	43.4	Hoxtell <i>et al.</i> ,1977
Oxford, UK	598	31	5	51°45'N	3-12	84.6	Liddington <i>et al.</i> ,1989
London, UK	121	5	4.1	51°50'N	1-21	-	McLelland <i>et al.</i> ,1988
The Netherlands	764	47	6.2	52°N	1-21	109.2	Hartevelt <i>et al.</i> ,1990
Belfast, N. Ireland	223	9	4.0	54°50'N	2-21	NS	Brown <i>et al.</i> ,1988
Göteborg, Sweden	129	13	10.1	57°43'N	3-16	NS	Blohme <i>et al.</i> ,1984
Stockholm, Sweden	5356	172	3.2	59°20'N	0-24	NS	Lindelöf <i>et al.</i> ,2000

¹ Caucasians only

absorbing a major portion of UV radiation and preventing it from reaching the earth (National Institutes of Health,1991). The chemicals responsible for the depletion of the ozone layer include the hydroflourocarbons present in aerosol sprays and refrigerators. It is feared that the depletion of ozone over the next few years will rapidly increase the incidence of skin cancer (Brash,1997).

UV radiation and the immune system

UV light may influence the development and progression of skin cancers by affecting the host immune system. UV radiation is both mutagenic and in doses equivalent to recreational sun-exposure, can cause selective immunosuppression (Parrish,1983). Kripke and his colleagues showed that UV-induced cancers in mice are highly antigenic and that most are rejected by the host immune system after transplantation into a normal, genetically identical animal (Kripke,1974;Kripke,1986). However, the primary host in whom the cancer was induced by UV light becomes tolerant to the tumour and allows its rapid growth. This tolerance is due the induction of T suppressor lymphocytes that may persist for years after exposure to UVB (Fisher *et al.*,1982). Although not yet confirmed in humans, this work suggests that suppressor factors and cells develop that act to suppress the host immune system and prevent rejection of UV-induced skin cancer. This effect may be induced by the action of UV-light on Langerhans' cells in skin, which alters the immune system and allows the development and progression of skin cancer (Brash,1997). What has been shown in humans is that in patients with a history of skin cancer, 92% have immunosuppression following UVB, indicating that individual susceptibility to the immunosuppressive effects of UVB may be a risk factor for the development of skin cancer (Yoshikawa *et al.*,1990a). The effect of UVB on cutaneous immunity may be mediated by induction of the tumour necrosis factor- α (TNF- α), a proinflammatory cytokine. In support of this is the observation that UVB-susceptible mice are converted to contact hypersensitivity responders on receipt of systemic anti-TNF- α antibodies administered at the same time that hapten is applied to UVB-exposed skin (Yoshikawa *et al.*,1990b). Moreover, when hapten is painted on skin site that has been pretreated with a single injection of recombinant murine TNF- α contact hypersensitivity is avoided (Yoshikawa *et al.*,1990b).

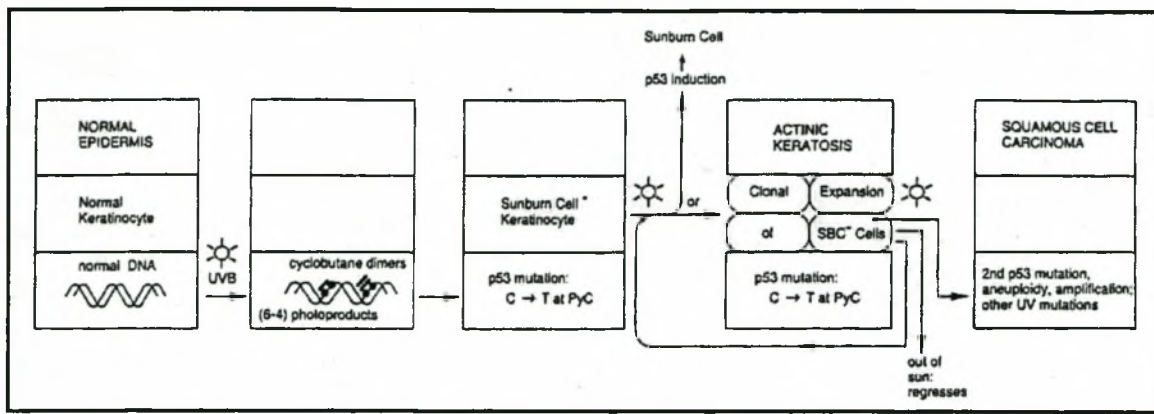


Fig. 12-1 A model for genetic and cellular events in the onset of human skin cancer. Mutation of the *p53* tumour suppressor gene and selection for *p53* mutated cells by sunlight exposure occur. See text for details. From Ziegler *et al.* (1994).

The mechanism whereby $\text{TNF-}\alpha$ interferes with cutaneous immunity appears to involve epidermal Langerhans cells and dermal antigen presenting cells. $\text{TNF-}\alpha$ induces cytoskeletal rearrangements in these cells that result in the transient inability of the cells to migrate from the skin. These cells are unable to reach the regional lymph nodes and the immunological response is therefore halted at this point (Vermeer *et al.*,1990). The molecular mechanism whereby UVB energy is transmuted to an increase in $\text{TNF-}\alpha$ is thought to be by *cis*-urocanic acid, the deaminated form of histidine that is produced when by the action of UVB radiation from the *trans*-isoform (De Fabo *et al.*,1983;Kurimoto *et al.*,1992;Scott *et al.*,1982). After conversion of *trans* - to *cis* - urocanic acid, this molecule directly or indirectly causes the local accumulation of $\text{TNF-}\alpha$ (Streilein *et al.*,1994). In addition, there is evidence that UVB induces tolerance of cutaneous antigens by giving rise to a novel dermal-cell population that can capture hapten and deliver it as a down regulatory signal to the immune system (Kurimoto *et al.*,1994b;Kurimoto *et al.*,1994a). This ability to impair induction of the immune system is genetically determined in mice, suggesting that the susceptibility to UVB-induced cancers may also be a genetically determined trait (Streilein *et al.*,1994). Recent studies on *p53* protein have elaborated the experimental work of Kripke (Kripke,1974;Kripke,1986) and Daynes (Daynes *et al.*,1981).

p 53 and skin cancer (Fig. 12-1)

The p53 protein is not required for normal development or physiology, but is elevated in cells with damaged DNA and cells with cell cycle abnormalities (Fisher,1994;White,1994). The elevated p53 protein has two effects on cells. DNA damage induces the p53 protein, which leads to the arrest of the cell cycle in the G₁ phase (Fisher,1994;Hartwell *et al.*,1994). This so-called "guardian of the genome" pathway allows additional time for DNA repair. The other p53 function termed "cellular proofreading" is the induction of apoptosis of aberrant cells by induction of the *bax* gene (Miyashita *et al.*,1995). In skin the cellular proofreading pathway appears to be operative after DNA damage. UV mutates the p53 gene (Campbell *et al.*,1993;Hall *et al.*,1993) and it is largely this gene that prevents UV-B and chemically-induced skin tumours in mice (Li *et al.*,1995). Long-lived mutants of p53, that have lost the tumour suppressant effect have been found not only in most skin cancers and precancers, but also in the sun-damaged cells adjacent to the malignant lesions (Shea *et al.*,1992). This suggests that UV damage to keratinocytes may result in mutation of p53 gene to an ineffective form allowing carcinogenesis to proceed.

UV radiation and azathioprine

In addition the two major metabolites of azathioprine (an agent widely used in renal transplant patients) 6-mercaptopurine and methylnitrothioimidazole have strong photo oxidative activities in the presence of UV light which may cause photosensitisation and photoallergy (Trush *et al.*,1982).

Chemical carcinogenesis

Extensive animal studies have shed some light on the pathogenesis of chemical carcinogenesis. Three stages of progression, based on studies on the mouse skin tumour model have been identified for chemical carcinogenesis: *initiation*, *promotion*, and *carcinogenesis* (Brash,1997). The initiated cells are terminally differentiated and retain their ability to multiply. For the promoter to be effective and cause tumours the cell has to be initiated previously (Marks *et al.*,1986). Animal studies have also shown that multiactivational events are required before progression to carcinoma occurs (Hennings *et al.*,1993).

Immunosuppressive drugs

Azathioprine enhances the speed of development of UV-induced skin cancer in murine models (Kelly *et al.*,1987b). Other effects of azathioprine include chromosomal breaks (Jensen,1967), and inhibition of repair of UV-induced damage (Kelly *et al.*,1986). Azathioprine may act as a tumour promoter and initiator through its active metabolite, 6-thioguanine (Lennard *et al.*,1985;Taylor *et al.*,1992). The development of tumours in immunosuppressed patients not receiving azathioprine suggests that chemical carcinogenesis is not the only factor involved. Animal studies have also failed to show either an increase in the incidence, or a reduction in latency, of tumours following the systemic use of cyclosporine unless the animal was administered a carcinogen, in which case they developed more squamous cell cancers (Berger,1991). In models of UV-induced carcinogenesis, however, systemic administration of cyclosporine or azathioprine increased the incidence and reduced the mean tumour latency (Berger,1991). *In vitro* studies have also shown cyclosporine has the ability to inhibit antigen presenting and accessory functions of Langerhans' cells in the skin of transplant recipients (Bergfelt,1993;Petzelbauer *et al.*,1992;Servitje *et al.*,1991;Sontheimer *et al.*,1984). This effect is detectable as early as 3 days after the initiation of treatment (Gabel *et al.*,1987). In addition, corticosteroids are known to deplete epidermal Langerhans' cells (Ashworth *et al.*,1988;Belsito *et al.*,1982;Berman *et al.*,1983) and impair their antigen-processing ability (Aberer *et al.*,1984;Ashworth *et al.*,1988;Belsito *et al.*,1982).

Viral Oncogenesis

Human papillomavirus (HPV) has long been recognised as the cause of common warts and condylomata acuminata but has also been identified in a variety of other skin lesions including verrucous carcinoma, bowenoid papulosis, epidermodysplasia verruciformis, and *in situ* epidermoid carcinoma (Ikenberg *et al.*,1983; Lutzner,1983; Obalek *et al.*,1985). The role of HPV in cutaneous squamous cell carcinoma in recipients of renal transplants is unclear. Many subtypes of HPV have been identified of which, especially HPV 5 and HPV 8 have been found in 90% cases of epidermodysplasia verruciformis patients that have progressed to squamous cell carcinoma (Orth,1987;Ostrow *et al.*,1982). It is likely that HPV may play a similar role in the development of posttransplant skin malignancies.

Oncogenic HPV

DNA of HPV 5 and 8 has been identified *in situ* in invasive squamous cell carcinomas and viral warts on sun-exposed skin of renal transplant patients (Lutzner *et al.*,1983;Lutzner *et al.*,1984). These findings were subsequently confirmed, and with the use of polymerase chain reactions and combinations of primers it is now possible to detect HPV DNA in 91% of transplant-associated squamous cell carcinomas (de Villiers *et al.*,1997) and 65% of basal cell carcinomas (Harwood *et al.*,2000). The molecular mechanisms of viral oncogenesis in cutaneous squamous cell carcinomas remain unexplained (Iftner *et al.*,1988;Steger *et al.*,1992) but what is evident is that the transformation strategies differ from those that give rise to genital cancers (Pfister,1992). It is likely that other factors are required to produce the malignant tumour from some of these oncogenic papillomaviruses (Ostrow *et al.*,1982). It has been suggested that in most renal allograft recipients the high rates of squamous cell carcinoma arise from synergism between the agents used for long-term immunosuppression, UV radiation and oncogenic types of HPV (Glover *et al.*,1994a). The relative importance of the different factors will tend to vary from patient to patient depending on the degree of exposure to sunlight, skin-type, degree of immunosuppression and genetic factors such as HLA type (Bouwes *et al.*,1991b).

Immunologic factors

The normal cell-mediated defense against skin cancer consists of a non-specific protection by natural killer cells, and a more specific HLA-restricted defense through cytotoxic T cells (Herberman,1984). In addition, the epidermal Langerhans' cells have a well established role in the local processing and presentation of antigens to lymphocytes as a critical step in the initiation of immune responses against skin cancer (Kelly *et al.*,1987a).

Immunological surveillance

The concept of immunological surveillance has been discussed above, but briefly it suggests that many potentially fatal tumour cells are continuously being detected and destroyed by the immune system of the host before they can form clinically detectable lesions (Klein *et al.*,1977). There is still controversy on the veracity of this concept because, although antibody-mediated and cell-mediated cytotoxic antitumour responses that destroy malignant cells have been detected in animal

tumours, these reactions have yet to be proven in human malignancies (Brash,1997). The increased incidence of skin cancers could be partly explained by this hypothesis but the disproportionate increase in squamous cell carcinomas suggests that there are factors other than decreased immunosurveillance influencing the development of skin cancer in renal transplant patients (Sheil,1994a).

Immune system and skin cancers

The work of Kripke and his colleagues indicate that a suppressor T cell and suppressor factor are produced in mice in response to UV radiation on the immune system (Kripke,1974;Kripke,1986). The interaction between UV radiation and the human immune system has not been well studied. Patients with both primary and secondary immunodeficiencies are susceptible to *de novo* skin malignancies (Walder *et al.*,1971). Renal transplant recipients are also more prone to skin cancers as demonstrated in this study and by other reports (Hoxtell *et al.*,1977;Koranda *et al.*,1974;Penn *et al.*,1971;Westburg *et al.*,1973). Patients with lymphoreticular malignancies are more prone to nonmelanoma skin cancers and as has been noted earlier, skin cancers behave more aggressively in patients who are immunocompromised (Berg,1967;Turner *et al.*,1981;Weimar *et al.*,1979;Westburg *et al.*,1973). There appears to be some association between the host immune system and the development of skin cancer but that relationship remains to be elucidated (Brash,1997). Possibly, long-term antigenic stimulation by a poorly matched graft may induce skin cancer either directly or indirectly, by necessitating a higher dose of immunosuppressive therapy (Kinlen,1985;Zimmerman *et al.*,1978).

Genetic Factors

The HLA antigens have an important role in the defense of the host against the development and spread of malignancies, especially viral-induced lesions (Dausset *et al.*,1982;Festenstein *et al.*,1986;Hors *et al.*,1983). The HLA-class II antigens are involved in recognition of foreign peptides by CD4 regulatory T lymphocytes (Neefjes *et al.*,1992), whereas the HLA class I antigen mainly serve as restriction elements for the CD8 cytotoxic T lymphocytes (Monaco,1992). In transplant recipients immune surveillance against skin cancer is impaired by depressed natural killer cell activity (Kelly *et al.*,1987a;Kelly *et al.*,1984;Legendre *et al.*,1986;ten Berge *et al.*,1981). Subsequently, more strain is placed upon the functioning of the cytotoxic T cells and

the role of the HLA class I antigens with respect to antigen presentation might be even more crucial (Bouwes *et al.*,1991a). HLA-associated susceptibility exists for several kinds of virus-related malignancies including Kaposi's sarcoma (HLA-DR5) and Burkitt's lymphoma (HLA-A1, -B12, -DR7) (Jones *et al.*,1980).

Importance of homozygosity

Homozygosity for HLA antigens has been reported to be a risk factor for the several kinds of cancers (Hors *et al.*,1983;von Fliedner *et al.*,1980). Homozygosity reduces the number of different polymorphic class I and class II products with the result that there are fewer possibilities of interaction between antigenic peptides and less recognition of foreign antigens (Dausset *et al.*,1982).

HLA antigens and skin cancer

There is increasing evidence that immunogenic factors may be relevant in the development of non-melanoma skin malignancies, with recent studies indicating that susceptibility to the immunosuppressive effects of UVB may be genetically determined (Yoshikawa *et al.*,1990a). Studies of non-immunosuppressed American (Myskowski *et al.*,1985) and Sardinian (Contu *et al.*,1987) patients have shown an association of non-melanoma skin cancer with HLA-DR 1, a finding confirmed in studies from Australia (Czarnecki *et al.*,1991a) and Britain (Glover *et al.*,1993), albeit at a lower relative risk. An absence of HLA-A11 in recipients with skin cancer has been reported (Bouwes-Bavinck *et al.*,1990;Bouwes *et al.*,1991a;Bouwes *et al.*,1991b), suggesting that this antigen is associated with resistance to skin cancer in these patients. Terasaki *et al.* have also found a negative association of HLA-A11 with virus-related carcinoma of the cervix in nonimmunocompromised patients (Terasaki *et al.*,1977). The protective effect of HLA-A11 against skin cancer could not be confirmed by a British group of investigators, who interestingly found a new association between HLA-DQw2 and non-melanoma skin cancer, a finding that has yet to be confirmed (Glover *et al.*,1993). Other antigens that have been associated with skin cancers include HLA-B27 and -DR 7 (Bavinck *et al.*,1993b;Coebergh *et al.*,1991;Czarnecki *et al.*,1992). The association of skin cancer with both class I and class II molecules suggests that both the effector and the induction phase of the cellular immune response play an aetiological role in cutaneous oncogenesis (Bavinck *et al.*,1993b).

HLA matching

HLA matching also appeared to influence patients' susceptibility to skin cancer. It has been shown that the risk of squamous cell carcinoma was increased in recipients mismatched for HLA-B antigens. Homozygosity for HLA-DR was more frequent among the patients with squamous cell carcinoma (Bouwes *et al.*,1991b). HLA-A and -DR mismatches did not have an effect nor was basal cell carcinoma associated with any HLA mismatches (Bouwes *et al.*,1991b). The small number of patients with skin cancer in our own cohort did not allow us to attempt a detailed HLA antigen analysis.

TIME TO SKIN CANCER DEVELOPMENT

In patients exposed to other carcinogens, the latent period between exposure and the development of the cancer is generally very long. In posttransplant patients however, skin cancers, most of which are *de novo*, are often diagnosed in the early months following renal transplantation. However, as the increased risk of cutaneous malignancies persists indefinitely, the average times of appearance of these cancers gradually lengthen in concert with the increasing mean follow-up period for transplant recipients. In the Australian experience, with follow-up periods averaging 6.3 years, the mean time of appearance of skin cancer is 6.3 years (Sheil,1994a). In our experience squamous cell carcinoma appeared at a mean period of 5.2 years and basal cell carcinoma 6.8 years after transplantation.

INFLUENCE OF CYCLOSPORINE

In our study the incidence of skin cancer did not increase significantly under cyclosporine compared with azathioprine (8.6% vs. 5.8%, respectively). This is in contrast to the findings of a study from Sweden in which it was found that the relative risk of nonmelanoma skin cancers decreased under cyclosporine (Lindelöf *et al.*,2000) but this applied only to males and not the female patients in whom there was no alteration in risk. The authors suggested that the decreased risk in males could be possibly be ascribed to a shorter follow-up period. Other investigators have found that skin cancer occurred significantly more frequently in patients treated with the combination of cyclosporine and azathioprine than with either drug alone (Disney *et al.*,1997). In the group treated with cyclosporine the incidence of cancers was

higher for the first six years after transplantation after which it reached levels comparable to the group on azathioprine alone (Disney *et al.*,1997). There is some evidence that the link between cancers and cyclosporine may be dose-related (Newstead,1998), and it has been shown in a randomised study of renal transplant patients that a low-dose regimen with cyclosporine was associated with fewer malignancies than a high-dose regimen (Dantal *et al.*,1998). This was confirmed in another report that also found a lower incidence of warts and premalignant skin lesions, although there were more rejection episodes in the group on the lower dose of cyclosporine (Dantal *et al.*,1998). The risk of various immunosuppressive regimens for cancer development remains controversial, with several studies finding no difference in the incidence of skin cancers under varying permutations of treatments that included azathioprine and/or cyclosporine with or without steroids (Bouwes *et al.*,1996;Liddington *et al.*,1989). The authors of one of these studies conclude " ...that it is likely that the increased risk of skin cancer associated with immunosuppression is independent of the agent(s) used and is the result of the immunosuppression *per se.*" (Bouwes *et al.*,1996).

MANAGEMENT

Prevention

Prevention of skin cancer is the key management strategy in patients who are recipients of renal allografts. All patients who are transplant candidates must be forewarned of the potential dangers of skin cancer and advised on strict sun avoidance, appropriate clothing and the use of high-factor UV-A and UV-B barrier creams on exposed skin surfaces and the lips (Lindelöf *et al.*,2000). However, despite verbal advice and written information at the time of hospital discharge for all newly diagnosed transplanted patients, only half recall receiving advice and compliance with sun protection measures is poor (Seukeran *et al.*,1998). On the other hand, it is uncertain how much difference active prevention actually makes (Liddington *et al.*,1989): much of posttransplantation skin cancer risk probably reflects sun-exposure prior to the transplantation, as alluded to earlier. All patients at risk should be examined annually and suspicious lesions should be biopsied (Glover *et al.*,1994b). Those patients who have had very high UV radiation exposure and

have extensive dysplastic lesions should be assessed more frequently especially with increasing time after transplantation (Lindelöf *et al.*,2000).

Treatment

Benign and premalignant conditions should be treated by cautery, freezing or excision. All malignant lesions require wide excision with reparative skin grafts if necessary. With squamous cell carcinoma or malignant melanoma draining lymph nodes may require block dissection, should metastatic involvement be present at the time of initial presentation.

Manipulation of immunosuppression

Reduction or withdrawal of immunosuppressive therapy must be considered in patients who have rapid, recurrent development of squamous cell carcinoma or those with generalised carcinomatous changes (Sheil,1994a). Substitution of agents such as chlorambucil or cyclophosphamide for azathioprine has occasionally resulted in regression of the skin changes but has usually resulted in graft loss due to rejection. When cyclosporine was substituted for azathioprine the results have been disappointing usually with progression of the squamous cell carcinoma lesions (Sheil,1994a). Of greater concern are the reports of *de novo* squamous cell carcinoma development in patients in whom azathioprine is replaced with cyclosporine for unrelated reasons (Thompson *et al.*,1985). As with Kaposi's sarcoma, the dramatic reduction or withdrawal of immunosuppressive therapy is associated with the rapid resolution of the skin lesions, although few patients accept this option (Sheil,1994a).

Retinoids

Recently, retinoids have been used in the treatment of squamous cell carcinoma both in the general population (Shuttleworth *et al.*,1988) and in renal transplant patients (Hong *et al.*,1990). A trial of systemic administration of retinoids in Australian transplant recipients has resulted in the amelioration of skin lesions without adverse effects on the renal allografts (Sheil *et al.*,1992). However, the side-effects, particularly hyperlipidaemia, may limit the use of retinoids in this group of patients who are already at risk of ischaemic heart disease (Glover *et al.*,1994a). Although retinoids may benefit some patients, skin cancers may continue to develop

during treatment (Bavinck *et al.*,1993a;Kelly *et al.*,1991;Shuttleworth *et al.*,1988) and lesions recur when treatment is stopped.

PROGNOSIS

It has been observed that squamous cell carcinomas are more aggressive in renal transplant recipients (Gupta *et al.*,1986;Hardie *et al.*,1980), with a higher risk of metastases than in the general population (Gupta *et al.*,1986). However, the outcome of skin cancers was very good in our cohort of patients with none of the patients having metastatic disease or dying directly as a result of their malignancies; nor was it necessary to significantly modify the immunosuppressive treatment in any of our patients. Others have also commented on geographical differences in the behaviour of skin cancers. None or very few of the patients in several reports from Europe developed metastases or died as a result of causes directly related to the skin cancer (Blohme *et al.*,1984;Hartevelt *et al.*,1990;Liddington *et al.*,1989). In contrast, the reports from Australia and New Zealand have noted that skin cancers in renal transplant patients may be unusually aggressive with deaths and nodal metastases (Sheil *et al.*,1985;Sheil,1994a;Sheil,1994b). The skin cancers in temperate Europe may be less of a threat than those occurring in Australasia.

Patient and graft survival

We have observed that in patients with Kaposi's sarcoma, and other authors have made the similar observations in patients with nonmelanoma skin cancers, that in the early posttransplant period both patient and graft survival are better in those who have developed skin malignancies compared with those who do not develop cancers (Sheil,1977;Sheil *et al.*,1979;Sloan *et al.*,1977). In the case of skin cancers, however, beyond 7 or 8 years following transplantation, graft and patient survivals rapidly worsen in those with malignancies because of death due to the cancer and the withdrawal of the immunosuppressive agents in an attempt to control the cancer (Sheil *et al.*,1979). This paradox of improved survival in the early posttransplant period in the patients who develop cancers could be the possibility that routine immunosuppressive treatment may produce more profound immunosuppression in some patients or that such patients may have reduced innate ability to mount immune responses (Sheil,1994a). In either case, while there is improved tolerance

of the renal allograft there could be reduced ability to withstand viral oncogenesis or to eliminate malignant clones. Also, recipients with well functioning grafts are also the ones to be exposed to both prolonged immunosuppressive therapy and chronic antigenic stimulation of the graft.

THE LIP

The lip is exposed to a great deal of sunlight but the current study did not address the lip as a separate site because of the low incidence of disease confined to this site in our cohort of patients. In a recent report, however, it was found that 13% of renal transplant patients had leukoplakia by 69 months after transplantation and 1.2% of the patients had squamous cell carcinoma in the leukoplakia. Exposure to sun and smoking were risk factors for malignant lip lesions in renal transplant recipients. Of note, is that only men developed malignant and dysplastic lesions of the lip, and it was suggested that the use of lipstick by the majority of the women may have played a protective role (King *et al.*, 1995). Other important observations made by the authors was that lip squamous cell carcinoma did not portend the development of malignant skin lesions on the face or elsewhere; and diagnosing serious skin lesions required biopsies to be done because clinically, lesions were indistinguishable (King *et al.*, 1995).

SUMMARY

Skin cancer is the most common malignancy both in the general Caucasian population and in Caucasian recipients of renal allografts. In our experience, lesions occurred exclusively in white patients and predominantly in males, another universal observation. Skin malignancies occurring in renal transplant recipients differed from the disease in the general population in several aspects:

- It occurred several decades earlier
- It was more aggressive, with greater likelihood of metastases
- The basal cell carcinoma to squamous cell carcinoma ratio was reversed, with the result that squamous cell carcinoma was more common than basal cell carcinoma (the lesion that is more common in the general population).

In patients on immunosuppression the aetiology of skin cancer is multifactorial with the degree and intensity of exposure to UV radiation, and the genetically determined skin type being the most important predisposing factors. The various mechanisms of UV radiation induced oncogenesis were briefly reviewed. There is increasing evidence of an aetiological role for oncogenic strains of HPV and future studies are recommended to elucidate the molecular mechanisms of viral oncogenesis. The role of the immunosuppressive agents in the development of skin malignancies has also been speculated on, but whether the occurrence of skin cancers is the result of the toxic effect of the drugs or the result of the concurrent immunosuppression is still uncertain. HLA antigens may also play a role with HLA-B 27 and -DR7 contributing to the development of skin cancer, while -A11 is possibly protective.

Solar keratosis and other premalignant skin conditions usually herald the onset of skin cancer. Management of skin cancer in renal transplant requires the aggressive treatment of these conditions and the biopsy of all suspicious lesions in renal transplant patients. Vigilance by both patient and caring physician is crucial to the successful management of posttransplant skin cancer. The mainstay of treatment, however, is sun-avoidance and the use of protective sunscreens. However, since it is the exposure to UV radiation earlier in life that predisposes to skin cancer, it remains to be proven whether this advice is appropriate.

LITERATURE CITED

- Aberer, W., Stingl, L., Pogantsch, S., and Stingl, G. (1984). Effect of glucocorticosteroids on epidermal cell-induced immune responses. *J Immunol.* **133**, 792.
- Ashworth, J., Booker, J., and Breathnach, S. M. (1988). Effects of topical corticosteroid therapy on Langerhans cell antigen presenting function in human skin. *Br J Dermatol.* **118**, 457.
- Aubry, F. and MacGibbon, B. (1985). Risk factors of squamous cell carcinoma of the skin. A case-control study in the Montreal region. *Cancer.* **55**, 907.
- Barr, B. B., Benton, E. C., McLaren, K., *et al.* (1989). Human papilloma virus infection and skin cancer in renal allograft recipients. *Lancet.* **1**, 124.

- Bavinck, J. N., De Boer, A., Vermeer, B. J., *et al.* (1993a). Sunlight, keratotic skin lesions and skin cancer in renal transplant recipients. *Br J Dermatol.* **129**, 242.
- Bavinck, J. N., Gissmann, L., Claas, F. H., *et al.* (1993b). Relation between skin cancer, humoral responses to human papillomaviruses, and HLA class II molecules in renal transplant recipients. *J.Immunol.* **151**, 1579.
- Beatty, M. E. and Habal, M. B. (1980). De novo cutaneous neoplasm: biologic behavior in an immunosuppressed patient. *Plast.Reconstr.Surg.* **66**, 623.
- Beirn, S. F., Judge, P., Urbach, F., MacCon, C. F., and Martin, F. (1970). Skin cancer in County Galway, Ireland. *Proc.Natl.Cancer Conf.* **6**, 489.
- Belsito, D. V., Flotte, T. J., Lim, H. W., Baer, R. L., Thorbecke, G. J., and Gigli, I. (1982). Effect of glucocorticosteroids on epidermal Langerhans cells. *J Exp.Med.* **155**, 291.
- Bencini, P. L., Montagnino, G., De Vecchi, A., *et al.* (1983). Cutaneous manifestations in renal transplant recipients. *Nephron.* **34**, 79.
- Berg, J. W. (1967). The incidence of multiple primary cancers. I. Development of further cancers in patients with lymphomas, leukemias, and myeloma. *J Natl.Cancer Inst.* **38**, 741 .
- Berger, M. R. (1991). Animal models of cancer caused by immunosuppression. *In* Cancer in Organ Transplant Recipients, (Schmähl, D. and Penn, I., eds.), p.3, Springer-Verlag, Berlin.
- Bergfelt, L. (1993). Langerhans cells, immunomodulation and skin lesions. A quantitative, morphological and clinical study. *Acta Derm.Venereol.Suppl (Stockh).* **180**, 1.
- Berman, B., France, D. S., Martinelli, G. P., and Hass, A. (1983). Modulation of expression of epidermal Langerhans cell properties following in situ exposure to glucocorticosteroids. *J Invest Dermatol.* **80**, 168.
- Birkeland, S. A. (1983). Malignant tumors in renal transplant patients. The Scandia transplant material. *Cancer.* **51**, 1571.
- Blohme, I. and Larko, O. (1984). Premalignant and malignant skin lesions in renal transplant patients. *Transplantation.* **37**, 165.
- Blohme, I. and Larko, O. (1990). Skin lesions in renal transplant patients after 10-23 years of immunosuppressive therapy. *Acta Derm.Venereol.* **70**, 491.
- Boring, C. C., Squires, T. S., and Tong, T. (1992). Cancer statistics, 1992. *CA Cancer J Clin.* **42**, 19.

- Bouwes-Bavinck, J. N., Kootte, A. M., van der Woude, F. J., Vandenbroucke, J. P., Vermeer, B. J., and Claas, F. H. (1990). HLA-A11-associated resistance to skin cancer in renal-transplant patients. *N Engl J Med.* **323**, 1350.
- Bouwes-Bavinck J.N., Hardie, D. R., Green, A., *et al.* (1996). The risk of skin cancer in renal transplant recipients in Queensland, Australia. A follow-up study. *Transplantation.* **61**, 715.
- Bouwes-Bavinck J.N., Kootte, A. M., van der Woude, F. J., Vandenbroucke, J. P., Vermeer, B. J., and Claas, F. H. (1991a). On a possible protective effect of HLA-A11 against skin cancer and keratotic skin lesions in renal transplant recipients [see comments]. *J.Invest.Dermatol.* **97**, 269.
- Bouwes-Bavinck J.N., Vermeer, B. J., van der Woude, F. J., *et al.* (1991b). Relation between skin cancer and HLA antigens in renal-transplant recipients [see comments]. *N.Engl.J.Med.* **325**, 843.
- Boyle, J., MacKie, R. M., Briggs, J. D., Junor, B. J., and Aitchison, T. C. (1984). Cancer, warts, and sunshine in renal transplant patients. A case- control study. *Lancet.* **1**, 702.
- Brash, D. E. (1997). Cancer of the skin. *In* Cancer: Principles and Practice of Oncology, 5 ed. (De Vita, V. T., Hellman, S., and Rosenberg, S. A., eds.), p.1879, Lippincott-Raven, Philadelphia.
- Brown, J. H., Hutchison, T., Kelly, A. M., and McGeown, M. G. (1988). Dermatologic lesions in a transplant population. *Transplantation.* **46**, 530.
- Campbell, C., Quinn, A. G., Angus, B., Farr, P. M., and Rees, J. L. (1993). Wavelength specific patterns of p53 induction in human skin following exposure to UV radiation. *Cancer Res.* **53**, 2697.
- Caterson, R. J., Furber, J., Murray, J., McCarthy, W., Mahony, J. F., and Sheil, A. G. (1984). Carcinoma of the vulva in two young renal allograft recipients. *Transplant Proc.* **16**, 559.
- Coebergh, J. W., Neumann, H. A., Vrints, L. W., van der, Heijden L., Meijer, W. J., and Verhagen-Teulings, M. T. (1991). Trends in the incidence of non-melanoma skin cancer in the SE Netherlands 1975-1988: a registry-based study. *Br J Dermatol.* **125**, 353.
- Contu, L., Cerimele, D., Carcassi, C. (1987). HLA markers in skin cancer. *Med.Sci.Res.* **15**, 1065.

- Czarnecki, D., Lewis, A., Nicholson, I., and Tait, B. (1991a). Multiple basal cell carcinomas and HLA frequencies in southern Australia. *J Am Acad.Dermatol.* **24**, 559.
- Czarnecki, D., Meehan, C., O'Brien, T., Leahy, S., and Nash, C. (1991b). The changing face of skin cancer in Australia. *Int.J Dermatol.* **30**, 715.
- Czarnecki, D., Watkins, F., Leahy, S., et al. (1992). Skin cancers and HLA frequencies in renal transplant recipients. *Dermatology.* **185**, 9.
- Dantal, J., Hourmant, M., Cantarovich, D., et al. (1998). Effect of long-term immunosuppression in kidney-graft recipients on cancer incidence: randomised comparison of two cyclosporin regimens. *Lancet.* **351**, 623.
- Dausset, J., Colombani, J., and Hors, J. (1982). Major histocompatibility complex and cancer, with special reference to human familial tumours (Hodgkin's disease and other malignancies). *Cancer Surv.* **16**, 119.
- Daynes, R. A., Bernhard, E. J., Gurish, M. F., and Lynch, D. H. (1981). Experimental photoimmunology: immunologic ramifications of UV-induced carcinogenesis. *J Invest Dermatol.* **77**, 77.
- De Fabo, E. C. and Noonan, F. P. (1983). Mechanism of immune suppression by ultraviolet irradiation in vivo. I. Evidence for the existence of a unique photoreceptor in skin and its role in photoimmunology. *J Exp.Med.* **158**, 84.
- de Villiers, E. M., Lavergne, D., McLaren, K., and Benton, E. C. (1997). Prevailing papillomavirus types in non-melanoma carcinomas of the skin in renal allograft recipients. *Int.J Cancer.* **73**, 356.
- Disler, P. B., MacPhail, A. P., and Myburg, J. A. (1981). Neoplasia after successful renal transplantation. *Nephron.* **29**, 119.
- Disney, A. P. S., Russ, G. R., Walker, R., and Sheil, A. G. R. Australia and New Zealand Transplant Registry Report 1997. Adelaide, South Australia. *Australia and New Zealand Transplant Registry.*
- Doll, J. R., Payne, P, and Hawke, J. Cancer in Five Continents.(1970). New York, Springer-Verlag.
- Festenstein, H. and Garrido, F. (1986). MHC antigens and malignancy. *Nature.* **322**, 502.
- Fisher, D. E. (1994). Apoptosis in cancer therapy: Crossing the threshold. *Cell.* **78**, 539.

- Fisher, M. S. and Kripke, M. L. (1982). Suppressor T lymphocytes control the development of primary skin cancers in ultraviolet-irradiated mice. *Science*. **216**, 1133.
- Fitzpatrick, T. (1975). Soleil et Peau. *J Medecine Esthetique*. **2**, 33.
- Gabel, H., Jontell, M., Ohman, C., and Brynger, H. (1987). Epidermal Langerhans cells in the early phase of immunosuppression. *Transplant Proc*. **19**, 1205.
- Gallagher, R. P., Ma, B., McLean, D. I., et al. (1990). Trends in basal cell carcinoma, squamous cell carcinoma, and melanoma of the skin from 1973 through 1987. *J Am Acad.Dermatol*. **23**, 413.
- Glover, M. T., Bodmer, J., Bodmer, W., et al. (1993). HLA antigen frequencies in renal transplant recipients and non-immunosuppressed patients with non-melanoma skin cancer. *Eur.J.Cancer*. **29A**, 520.
- Glover, M. T., Niranjana, N., Kwan, J. T., and Leigh, I. M. (1994b). Non-melanoma skin cancer in renal transplant recipients: the extent of the problem and a strategy for management. *Br J Plast.Surg*. **47**, 86.
- Glover, M. T., Niranjana, N., Kwan, J. T., and Leigh, I. M. (1994a). Non-melanoma skin cancer in renal transplant recipients: the extent of the problem and a strategy for management. *Br.J.Plant.Surg*. **47**, 86.
- Greene, M. H., Young, T. I., and Clark, W. H., Jr. (1981). Malignant melanoma in renal-transplant recipients. *Lancet*. **1**, 1196.
- Gupta, A. K., Cardella, C. J., and Haberman, H. F. (1986). Cutaneous malignant neoplasms in patients with renal transplants. *Arch.Dermatol*. **122**, 1288.
- Hall, P. A., McKee, P. H., Menage, H. D., Dover, R., and Lane, D. P. (1993). High levels of p53 protein in UV-irradiated normal human skin. *Oncogene*. **8**, 203.
- Hardie, I. R., Strong, R. W., Hartley, L. C., Woodruff, P. W., and Clunie, G. J. (1980). Skin cancer in Caucasian renal allograft recipients living in a subtropical climate. *Surgery*. **87**, 177.
- Hartvelt, M. M., Bavinck, J. N., Kootte, A. M., Vermeer, B. J., and Vandenbroucke, J. P. (1990). Incidence of skin cancer after renal transplantation in The Netherlands. *Transplantation*. **49**, 506.
- Hartwell, L. H. and Kastan, M. B. (1994). Cell cycle control and cancer. *Science*. **266**, 1821.

- Harwood, C. A., Suretheran, T., McGregor, J. M., *et al.* (2000). Human papillomavirus infection and non-melanoma skin cancer in immunosuppressed and immunocompetent individuals. *J Med Virol.* **61**, 289.
- Hennings, H., Glick, A. B., Greenhalgh, D. A., *et al.* (1993). Critical aspects of initiation, promotion, and progression in multistage epidermal carcinogenesis. *Proc.Soc.Exp.Biol.Med.* **202**, 1.
- Herberman, R. B. (1984). Possible role of natural killer cells and other effector cells in immune surveillance against cancer. *J Invest Dermatol.* **83**, 137s.
- Hong, W. K., Lippman, S. M., Itri, L. M., *et al.* (1990). Prevention of second primary tumors with isotretinoin in squamous-cell carcinoma of the head and neck. *N Engl J Med.* **323**, 795.
- Hoover, R. and Fraumeni-JF, Jr. (1973). Risk of cancer in renal-transplant recipients. *Lancet.* **2**, 55.
- Hors, J. and Dausset, J. (1983). HLA and susceptibility to Hodgkin's disease. *Immunol.Rev.* **70**, 167.
- Hoxtell, E. O., Mandel, J. S., Murray, S. S., Schuman, L. M., and Goltz, R. W. (1977). Incidence of skin carcinoma after renal transplantation. *Arch.Dermatol.* **113**, 436.
- Iftner, T., Bierfelder, S., Csapo, Z., and Pfister, H. (1988). Involvement of human papillomavirus type 8 genes E6 and E7 in transformation and replication. *J Virol.* **62**, 3655.
- Ikenberg, H., Gissmann, L., Gross, G., Grussendorf-Conen, E. I., and zur, Hausen H. (1983). Human papillomavirus type-16-related DNA in genital Bowen's disease and in Bowenoid papulosis. *Int.J Cancer.* **32**, 563.
- Jacobs, C., Brunner, F. P., Brynger, H., *et al.* (1981). Malignant diseases in patients treated by dialysis and transplantation in Europe. *Transplant Proc.* **13**, 729.
- Jensen, M. K. (1967). Chromosome studies in patients treated with azathioprine and amethopterin. *Acta Med Scand.* **182**, 445.
- Jones, E. H., Biggar, R. J., Nkrumah, F. K., and Lawler, S. D. (1980). Study of the HLA system in Burkitt's lymphoma. *Hum.Immunol.* **1**, 207.
- Kelly, G., Scheibner, A., Murray, E., Sheil, R., Tiller, D., and Horvath, J. (1987a). T6+ and HLA-DR+ cell numbers in epidermis of immunosuppressed renal transplant recipients. *J Cutan.Pathol.* **14**, 202.

- Kelly, G. E., Meikle, W., and Sheil, A. G. (1987b). Effects of immunosuppressive therapy on the induction of skin tumors by ultraviolet irradiation in hairless mice. *Transplantation*. **44**, 429.
- Kelly, G. E., Sheil, A. G., and Taylor, R. (1984). Nonspecific immunological studies in kidney transplant recipients with and without skin cancer. *Transplantation*. **37**, 368.
- Kelly, G. E., Sheil, A. G., Wass, J., and Zbroja, R. A. (1986). Effects of ultraviolet radiation and immunosuppressive therapy on mouse epidermal cell kinetics. *Br J Dermatol*. **114**, 197.
- Kelly, J. W., Sabto, J., Gurr, F. W., and Bruce, F. (1991). Retinoids to prevent skin cancer in organ transplant recipients. *Lancet*. **338**, 1407.
- King, G. N., Healy, C. M., Glover, M. T., *et al.* (1995). Increased prevalence of dysplastic and malignant lip lesions in renal-transplant recipients. *N.Engl.J.Med.* **332**, 1052.
- Kinlen, L. J. (1985). Incidence of cancer in rheumatoid arthritis and other disorders after immunosuppressive treatment. *Am J Med*. **78**, 44.
- Klein, G. and Klein, E. (1977). Immune surveillance against virus-induced tumors and nonrejectability of spontaneous tumors: contrasting consequences of host versus tumor evolution. *Proc.Natl.Acad.Sci.U.S.A.* **74**, 2121.
- Koranda, F. C., Dehmel, E. M., Kahn, G., and Penn, I. (1974). Cutaneous complications in immunosuppressed renal homograft recipients. *JAMA*. **229**, 419.
- Kricker, A., Armstrong, B. K., English, D. R., and Heenan, P. J. (1991). Pigmentary and cutaneous risk factors for non-melanocytic skin cancer-- a case-control study. *Int.J Cancer*. **48**, 650.
- Kripke, M. L. (1974). Antigenicity of murine skin tumors induced by ultraviolet light. *J Natl.Cancer Inst.* **53**, 1333.
- Kripke, M. L. (1986). Immunology and photocarcinogenesis. New light on an old problem. *J Am Acad.Dermatol*. **14**, 149.
- Kurimoto, I. and Streilein, J. W. (1992). *cis* - Urocanic acid suppression of contact hypersensitivity induction is mediated via tumor necrosis factor-alpha. *J Immunol*. **148**, 3072.

- Kurimoto, I. and Streilein, J. W. (1994a). Characterization of the immunogenetic basis of ultraviolet-B light effects on contact hypersensitivity induction. *Immunology*. **81**, 352.
- Kurimoto, I., van Rooijen, N., Dijkstra, C. D., and Streilein, J. W. (1994b). Role of phagocytic macrophages in induction of contact hypersensitivity and tolerance by hapten applied to normal and ultraviolet B-irradiated skin. *Immunology*. **83**, 281.
- Kwa, R. E., Campana, K., and Moy, R. L. (1992). Biology of cutaneous squamous cell carcinoma. *J Am Acad.Dermatol*. **26**, 1.
- Legendre, C. M., Guttman, R. D., and Yip, G. H. (1986). Natural killer cell subsets in long-term renal allograft recipients. A phenotypic and functional study. *Transplantation*. **42**, 347.
- Lennard, L., Thomas, S., Harrington, C. I., and Maddocks, J. L. (1985). Skin cancer in renal transplant recipients is associated with increased concentrations of 6-thioguanine nucleotide in red blood cells. *Br J Dermatol*. **113**, 723.
- Li, G., Ho, V. C., Berean, K., and Tron, V. A. (1995). Ultraviolet radiation induction of squamous cell carcinomas in p53 transgenic mice. *Cancer Res*. **55**, 2070.
- Liddington, M., Richardson, A. J., Higgins, R. M., *et al.* (1989). Skin cancer in renal transplant recipients. *Br.J.Surg*. **76**, 1002.
- Lindelöf, B., Sigurgeirsson, B., Gäbel, H., and Stern, R. S. (2000). Incidence of skin cancer in 5356 patients following organ transplantation. *Br J Dermatol*. **143**, 513.
- Luande, J., Henschke, C. I., and Mohammed, N. (1985). The Tanzanian human albino skin. Natural history. *Cancer*. **55**, 1823.
- Lutzner, M., Croissant, O., Ducasse, M. F., Kreis, H., Crosnier, J., and Orth, G. (1980). A potentially oncogenic human papillomavirus (HPV-5) found in two renal allograft recipients. *J Invest Dermatol*. **75**, 353.
- Lutzner, M. A. (1978). Epidermodysplasia verruciformis. An autosomal recessive disease characterized by viral warts and skin cancer. A model for viral oncogenesis. *Bull.Cancer*. **65**, 169.
- Lutzner, M. A. (1983). The human papillomaviruses. A review. *Arch.Dermatol*. **119**, 631.
- Lutzner, M. A., Blanchet-Bardon, C., and Orth, G. (1984). Clinical observations, virologic studies, and treatment trials in patients with epidermodysplasia

- verruciformis, a disease induced by specific human papillomaviruses. *J Invest Dermatol.* **83**, 18s.
- Lutzner, M. A., Orth, G., Dutronquay, V., Ducasse, M. F., Kreis, H., and Crosnier, J. (1983). Detection of human papillomavirus type 5 DNA in skin cancers of an immunosuppressed renal allograft recipient. *Lancet.* **2**, 422.
- Mackie, R. M., Elwood, J. M., and Hawk, J. L. M. (1987). Links between exposure to ultraviolet radiation and skin cancer. *J R Coll.Physicians.Lond.* **21**, 91.
- Marks, F. and Furstenberger, G. (1986). Experimental evidence that skin carcinogenesis is a multistep phenomenon. *Br J Dermatol.* **115 Suppl 31**, 1.
- Marks, R. (1995). An overview of skin cancers. Incidence and causation. *Cancer.* **75**, 607.
- Marks, R., Jolley, D., Lechtsas, S., and Foley, P. (1990). The role of childhood exposure to sunlight in the development of solar keratoses and non-melanocytic skin cancer. *Med J Aust.* **152**, 62.
- Marshall, V. (1974). Premalignant and malignant skin tumours in immunosuppressed patients. *Transplantation.* **17**, 272.
- Matas, A. J., Simmons, R. L., Kjellstrand, C. M., Buselmeier, T. J., and Najarian, J. S. (1975). Increased incidence of malignancy during chronic renal failure. *Lancet.* **1**, 883.
- McLelland, J., Rees, A., Williams, G., and Chu, T. (1988). The incidence of immunosuppression-related skin disease in long-term transplant patients. *Transplantation.* **46**, 871.
- Miyashita, T. and Reed, J. C. (1995). Tumor suppressor p53 is a direct transcriptional activator of the human bax gene. *Cell.* **80**, 293.
- Monaco, J. J. (1992). A molecular model of MHC class-I-restricted antigen processing. *Immunol.Today.* **13**, 173.
- Mullen, D. L., Silverberg, S. G., Penn, I., and Hammond, W. S. (1976). Squamous cell carcinoma of the skin and lip in renal homograft recipients. *Cancer.* **37**, 729.
- Myskowski, P. L., Pollack, M. S., Schorr, E., Dupont, B., and Safai, B. (1985). Human leukocyte antigen associations in basal cell carcinoma. *J Am Acad.Dermatol.* **12**, 997.
- National Institutes of Health. (1991). Summary of the Consensus Development Conference on Sunlight, Ultraviolet Radiation, and the Skin. *J Am Acad.Dermatol.* **24**, 608.

- Neefjes, J. J. and Ploegh, H. L. (1992). Intracellular transport of MHC class II molecules. *Immunol.Today.* **13**, 179.
- Newstead, C. G. (1998). Assessment of risk of cancer after renal transplantation. *Lancet.* **351**, 610.
- Obalek, S., Jablonska, S., and Orth, G. (1985). HPV-associated intraepithelial neoplasia of external genitalia. *Clin Dermatol.* **3**, 104.
- Orth, G. (1987). The papillomaviruses. In *The Papoviridae*, (Salzman, N. P. and Howley, P. M., eds.), p.199, Plenum Press, New York.
- Ostrow, R. S., Bender, M., Niimura, M., et al. (1982). Human papillomavirus DNA in cutaneous primary and metastasized squamous cell carcinomas from patients with epidermodysplasia verruciformis. *Proc.Natl.Acad.Sci.U.S.A.* **79**, 1634.
- Parrish, J. A. (1983). Ultraviolet radiation affects the immune system. *Pediatrics.* **71**, 129.
- Penn, I., Halgrimson, C. G., and Starzl, T. E. (1971). De novo malignant tumors in organ transplant recipients. *Transplant.Proc.* **3**, 773.
- Petzelbauer, P. and Wolff, K. (1992). Effects of cyclosporin A on resident and passenger immune cells of normal human skin and UV-induced erythema reactions. *Br J Dermatol.* **127**, 560.
- Pfister, H. (1992). Human papillomaviruses and skin cancer. *Semin.Cancer Biol.* **3**, 263.
- Roberts, D. L. (1990). Incidence of non-melanoma skin cancer in West Glamorgan, South Wales. *Br J Dermatol.* **122**, 399.
- Scott, I. R., Harding, C. R., and Barrett, J. G. (1982). Histidine-rich protein of the keratohyalin granules. Source of the free amino acids, urocanic acid and pyrrolidone carboxylic acid in the stratum corneum. *Biochim.Biophys.Acta.* **719**, 110.
- Sequeira, L. A. and Cutler, R. E. (1992). Occurrence of skin cancer in transplant recipients. *Dialy.Transplantation.* **21**, 143.
- Servitje, O., Seron, D., Ferrer, I., Carrera, M., Pagerols, X., and Peyri, J. (1991). Quantitative and morphometric analysis of Langerhans cells in non- exposed skin in renal transplant patients. *J Cutan.Pathol.* **18**, 106.
- Seukeran, D. C., Newstead, C. G., and Cunliffe, W. J. (1998). The compliance of renal transplant recipients with advice about sun protection measures. *Br J Dermatol.* **138**, 301.

- Shea, C. R., McNutt, N. S., Volkenandt, M., Lugo, J., Prioleau, P. G., and Albino, A. P. (1992). Overexpression of p53 protein in basal cell carcinomas of human skin. *Am J Pathol.* **141**, 25.
- Sheil, A. G. (1977). Cancer in renal allograft recipients in Australia and New Zealand. *Transplant.Proc.* **9**, 1133.
- Sheil, A. G. (1994a). Skin cancer in renal transplant recipients. *Transplant.Sci.* **4**, 42.
- Sheil, A. G., Disney, A. P., Mathew, T. G., Amiss, N., and Excell, L. (1992). Malignancy following renal transplantation. *Transplant.Proc.* **24**, 1946.
- Sheil, A. G., Disney, A. P., Mathew, T. H., and Amiss, N. (1993). De novo malignancy emerges as a major cause of morbidity and late failure in renal transplantation. *Transplant Proc.* **25**, 1383.
- Sheil, A. G., Flavel, S., Disney, A. P., and Mathew, T. H. (1985). Cancer development in patients progressing to dialysis and renal transplantation. *Transplant Proc.* **17**, 1685.
- Sheil, A. G., Mahoney, J. F., Horvath, J. S., *et al.* (1979). Cancer and survival after cadaveric donor renal transplantation. *Transplant Proc.* **11**, 1052.
- Sheil, A. G., May, J., Mahoney, J. F., *et al.* (1980). Incidence of cancer in renal transplant recipients. *Proc.Eur.Dial.Transplant.Assoc.* **17**, 502.
- Sheil, A. G. R. (1994b). Cancer in dialysis and transplant patients. *In* *Kidney Transplantation*, 4 ed. (Morris, P. J., eds.), p.390, W B Saunders, Philadelphia.
- Shuttleworth, D., Marks, R., Griffin, P. J., and Salaman, J. R. (1988). Treatment of cutaneous neoplasia with etretinate in renal transplant recipients. *Q.J Med.* **68**, 717.
- Sloan, G. M., Cole, P., and Wilson, R. E. (1977). Risk indicators of de novo malignancy in renal transplant recipients. *Transplant Proc.* **9**, 1129.
- Sontheimer, R. D., Bergstresser, P. R., Gailunas, P., Jr., Helderman, J. H., and Gilliam, J. N. (1984). Perturbation of epidermal Langerhans cells in immunosuppressed human renal allograft recipients. *Transplantation.* **37**, 168.
- Spencer, E. S. and Andersen, H. K. (1970). Clinically evident, non-terminal infections with herpesviruses and the wart virus in immunosuppressed renal allograft recipients. *Br Med J.* **1**, 251.
- Steger, G. and Pfister, H. (1992). In vitro expressed HPV 8 E6 protein does not bind p53. *Arch.Virol.* **125**, 355.

- Streilein, J. W., Taylor, J. R., Vincek, V., *et al.* (1994). Immune surveillance and sunlight-induced skin cancer. *Immunol.Today*. **15**, 174.
- Taylor, A. E. and Shuster, S. (1992). Skin cancer after renal transplantation: the causal role of azathioprine. *Acta Derm.Venereol*. **72**, 115.
- ten Berge, R. J., Schellekens, P. T., Surachno, S., The, T. H., ten Veen, J. H., and Wilmink, J. M. (1981). The influence of therapy with azathioprine and prednisone on the immune system of kidney transplant recipients. *Clin Immunol.Immunopathol*. **21**, 20 .
- Terasaki, P. I., Perdue, S. T., and Mickey, M. R. (1977). HLA frequencies in cancer: A second study. *In Genetics of Human Cancer*, (Mulvihill, J. J., Miller, R. W., and Fraumeni, J. F., Jr., eds.), p.321, Raven Press, New York.
- Thompson, J. F., Allen, R., Morris, P. J., and Wood, R. (1985). Skin cancer in renal transplant patients treated with cyclosporin. *Lancet*. **1**, 158.
- Trush, M. A., Mimnaugh, E. G., and Gram, T. E. (1982). Activation of pharmacologic agents to radical intermediates. Implications for the role of free radicals in drug action and toxicity. *Biochem.Pharmacol*. **31**, 3335.
- Turner, J. E. and Callen, J. P. (1981). Aggressive behavior of squamous cell carcinoma in a patient with preceding lymphocytic lymphoma. *J Am Acad.Dermatol*. **4**, 446.
- Urbach, F. (1984). Ultraviolet radiation and skin cancer. *In Topics in Photomedicine*,(Smith, K. C., eds.), p.67, Plenum, New York.
- Vermeer, M. and Streilein, J. W. (1990). Ultraviolet B light-induced alterations in epidermal Langerhans cells are mediated in part by tumor necrosis factor-alpha. *Photodermatol.Photoimmunol.Photomed*. **7**, 258.
- von Fliedner, V. E., Sultan-Khan, Z., and Jeannet, M. (1980). HLA-DRw antigens associated with acute leukemia. *Tissue Antigens*. **16**, 399.
- Walder, B. K., Robertson, M. R., and Jeremy, D. (1971). Skin cancer and immunosuppression. *Lancet*. **2**, 1282.
- Weimar, V. M., Ceilley, R. I., and Goeken, J. A. (1979). Aggressive biologic behavior of basal- and squamous-cell cancers in patients with chronic lymphocytic leukemia or chronic lymphocytic lymphoma. *J Dermatol Surg.Oncol*. **5**, 609.
- Westburg, S. P. and Stone, O. J. (1973). Multiple cutaneous squamous cell carcinomas during immunosuppressive therapy. *Arch.Dermatol*. **107**, 893.
- White, E. (1994). Tumour biology. p53, guardian of Rb. *Nature*. **371**, 21.

- Yiannias, J. A., Goldberg, L. H., Carter-Campbell, S., Reddick, M., and Chamberlain, R. M. (1988). The ratio of basal cell carcinoma to squamous cell carcinoma in Houston, Texas. *J Dermatol Surg.Oncol.* **14**, 886.
- Yoshikawa, T., Rae, V., Bruins-Slot, W., Van den Berg, J. W., Taylor, J. R., and Streilein, J. W. (1990a). Susceptibility to effects of UVB radiation on induction of contact hypersensitivity as a risk factor for skin cancer in humans. *J Invest Dermatol.* **95**, 530.
- Yoshikawa, T. and Streilein, J. W. (1990b). Genetic basis of the effects of ultraviolet light B on cutaneous immunity. Evidence that polymorphism at the Tnfa and Lps loci governs susceptibility. *Immunogenetics.* **32**, 398.
- Ziegler, A., Jonason, A. S., Leffell, D. J., *et al.* (1994). Sunburn and p53 in the onset of skin cancer. *Nature.* **372**, 773.
- Zimmerman, S. W. and Esch, J. (1978). Skin lesions treated with azathioprine and prednisone. Comparison of nontransplant patients and renal transplant recipients. *Arch.Intern.Med.* **138**, 912.

COLOUR PHOTOGRAPHIC PLATES

Figs. 13-2 to 13-4 Skin Cancer

The pathological features of the two most common forms of skin cancer are shown in the following sections.

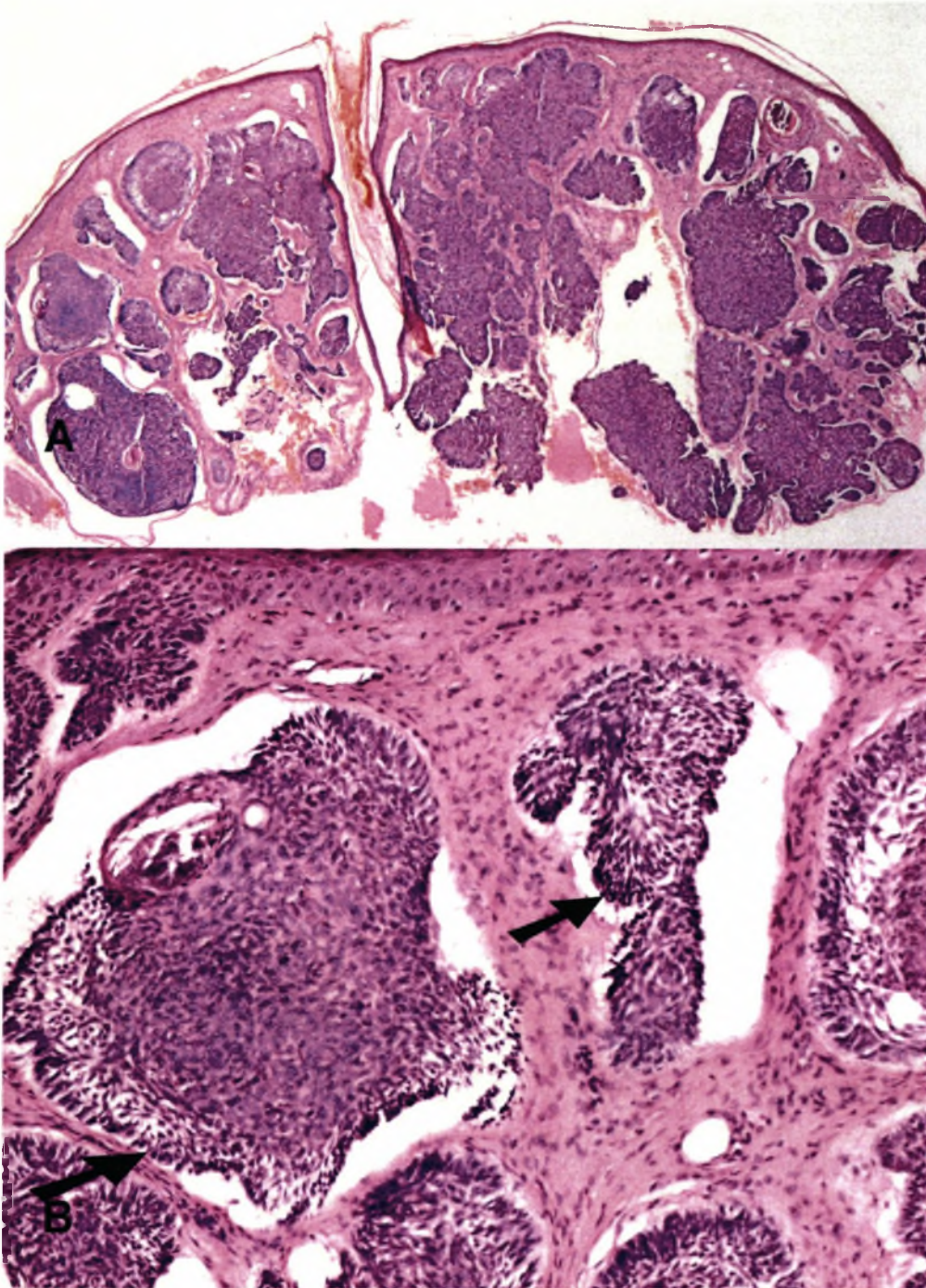


Fig. 12-2 Basal cell carcinoma

There is nodular arrangement of invasive basaloid tumour cells in the dermis and the very characteristic clefts between tumour cells and adjacent stroma can be seen. (B) At higher magnification the typical nests of hyperchromatic basaloid cells with peripheral palisading is revealed (arrows).

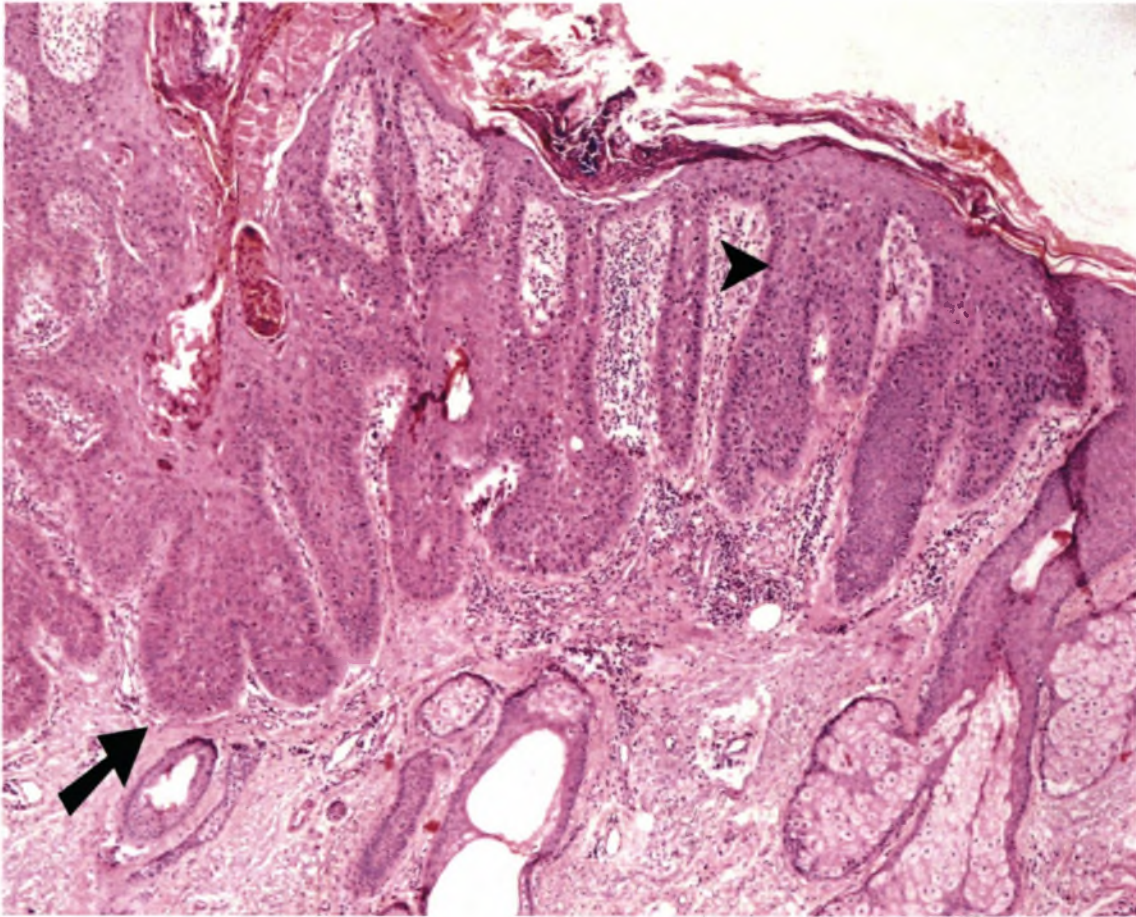


Fig. 12-3 *In situ squamous cell carcinoma*

In situ squamous cell carcinoma (arrow point) with adjacent infiltration of the dermis (arrow).

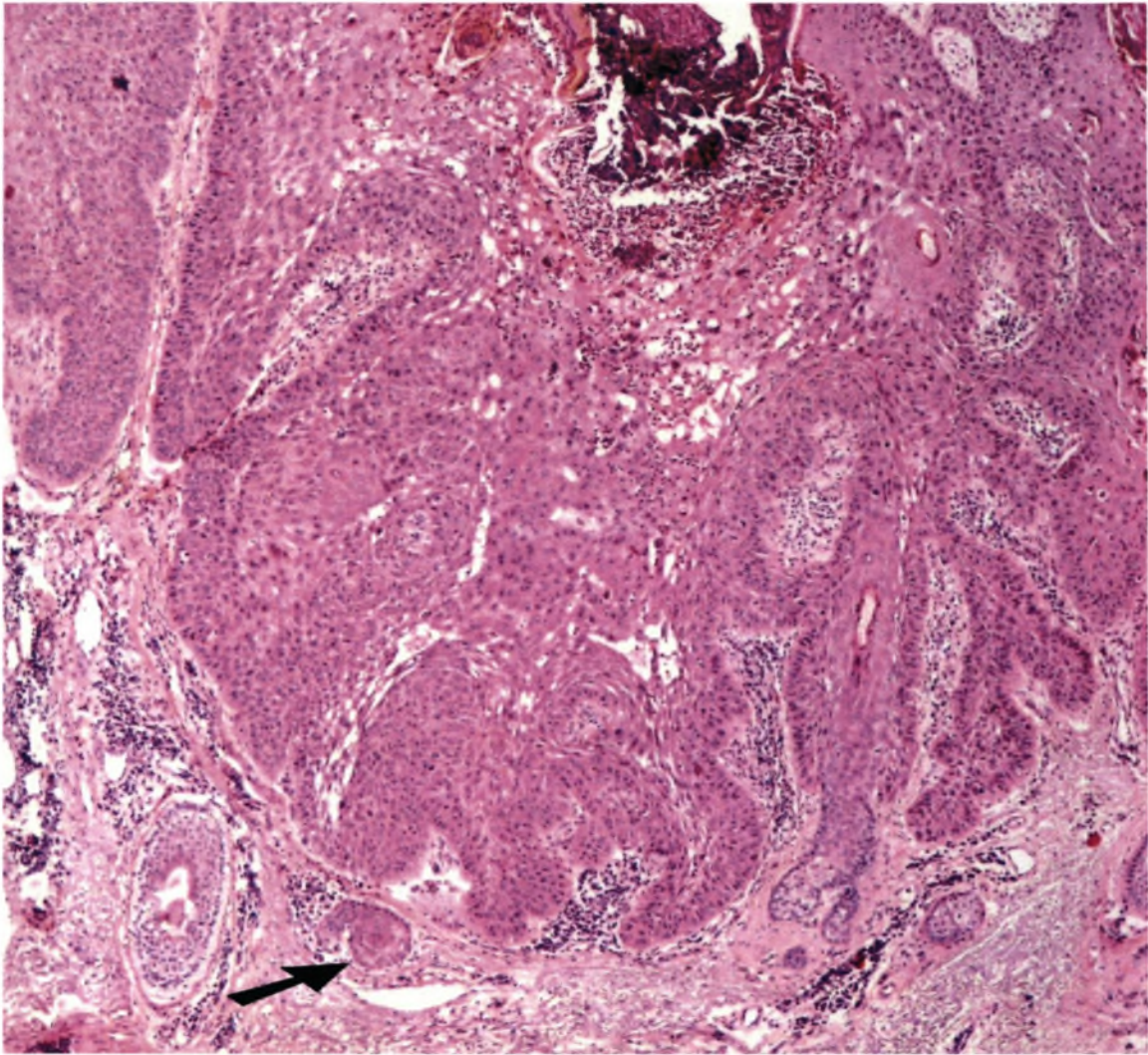


Fig. 12-4 *Invasive squamous cell carcinoma*

The invasion of the dermis shown (arrow).

Chapter 13

NON-SKIN CANCERS

Malignancies occurring in renal transplant recipients differ in distribution from that of the age- and sex-matched general population (Penn *et al.*,1969; Penn,1994c; Penn,1995a; Penn,1999b). The Cincinnati Transplant Tumor Registry (CTTR) found a 3- to 4- fold increase in the incidence of cancer compared with age-matched controls but observed no increase in the incidence of malignancies that commonly occur in the general population locally, which, in order of frequency are carcinomas of the lung, breast, prostate, colon and uterine cervix (Penn *et al.*,1969; Penn,1994c; Penn,1995a; Penn,1999b). The commonest malignancies in the different race groups of the general Western Cape population are listed in Table 13-1. Of note, in our experience also, was the absence, in our renal transplant patients of malignancies most commonly occurring in our general population. However, the small number of patients in our cohort makes it difficult to draw any firm statistical conclusions on the pattern of the non-skin and non-Kaposi's sarcoma malignancies in our renal transplant patients.

Table 13-1. Malignancies in order of frequency in the general population of the Western Cape by race for the age group 15-60 years.

White		Coloured		Black	
Male	Female	Male	Female	Male	Female
Prostate	Breast	Stomach	Cervix	Stomach	Cervix
Colorectal	Colorectal	Prostate	Breast	PSU	Stomach
Stomach	PSU	Lung	Stomach	Lung	Breast
Lung	Cervix	PSU	PSU	Prostate	PSU
PSU	Melanoma	Colorectal	Colorectal	Liver	Lung

Drawn from data supplied by the National Cancer Registry (1998)

PSU is primary site unknown

EPIDEMIOLOGY OF POSTTRANSPLANT CANCERS

Incidence

The incidence of various cancers has been discussed in detail in Chapter 6. In brief, in our experience 7.6% of patients developed malignancies following renal transplantation, of which 53.6% were Kaposi's sarcoma and 31.7% skin cancers. Only 4.9% of the lesions were lymphomas. The prevalence of *de novo* malignancies in renal transplant patients has been reported to be between 1% and 6% (Cockburn *et al.*, 1989; Penn, 1994b; Sheil *et al.*, 1993) and is similar to that reported in patients with genetically determined immunodeficiency disease (Spector *et al.*, 1978). In line with our experience, it has also been reported that certain malignancies that are common in the general population are *less* frequent in the renal transplant patients (Penn, 1994b; Penn, 1996b). These include carcinoma of the prostate, breast, lung, colon, rectum, bladder and uterus. *In situ* carcinoma of the uterine cervix occurs with the same frequency in renal transplant recipients (31%) as in the general public (37%). On the other hand (beside skin cancers and Kaposi's sarcoma that have been discussed above), non-Hodgkin's lymphomas, and carcinomas of the kidney, liver, skin, lip, vulva, and perineum are much more frequent among renal allograft recipients (*vide supra*), although there are some regional differences as seen in Table 13- 2.

Table 13-2 Comparison between the incidence of malignancies in renal allograft recipients compared to the general population in different regions (values are relative risks)

	European	Australasia	Current Study
Kaposi's sarcoma	400 - 1000	82.6	238.4
Skin Carcinoma	100	-	-
Non-Hodgkin's lymphoma	28-49	8.03	1.8
Liver carcinoma	20-38	7.3	1.8
Renal carcinoma	8.9	7.0	4.8
Thyroid	-	4.5	2.4
Breast carcinoma	↓ ¹	1.0	0.6
Prostate carcinoma	↓	0.6	-
Lung carcinoma	↓	2.3	1.7
Colon carcinoma	↓	2.3	-
Bladder carcinoma	↓	7.5	-
Uterus carcinoma	↓	1.4	-
Rectum	↓	1.4	-

From Montagnino, (2000); Sheil, (1999)

¹Incidence lower than in general population

Differences in the relative frequencies in the different regions may be due to differences in the population studied, differences in the criteria for cancer inclusion and differences in the average age of patients at transplantation (Penn,1999b). Skin and lip cancers generally account for 34% to 46% of total malignancies (Montagnino *et al.*,1996;Penn,1994b), and are particularly common in countries with greater sunlight exposure (Sheil *et al.*,1993). The racial distribution of certain cancers such as Kaposi's sarcoma in Jews, Arabs, Mediterranean and Coloured populations (Akhtar *et al.*,1984;Montagnino *et al.*,1994b), skin cancer in Caucasians (Sheil *et al.*,1993), and stomach carcinoma in Japanese patients (Gunji *et al.*,1990), has been discussed in detail in Chapter 6.

Posttransplant tumours affect a relatively young group of patients whose average age in data from the CTTR was 50 years (compared with 45 years in our patients) at diagnosis. Of these patients 67% were males, in keeping with the male to female ratio of 2:1 of patients who underwent renal and cardiac transplantation (Penn,1989; Penn,1994c; Penn,1994a; Penn,1995a).

The incidence of cancers increases with length of follow-up after transplantation. This is particularly well illustrated by an Australasian study of 6596 renal transplant patients (Sheil *et al.*,1993), in whom it was shown that there was linear increase in the number of cancers such that the percentage probability of developing cancer 24 years after cadaveric donor transplantation was 66% for skin tumours, 27% for non-skin tumours and 72% for any type of cancer. These figures, admittedly, are exceptional because of the very high incidence of skin cancers in Australia and the actual number of patients surviving 24 years is small. However, these data do serve to emphasise the point that all transplant patients should be followed-up indefinitely (Penn,1999a).

INTERVAL TO CANCER APPEARANCE

As length of follow-up of organ transplant recipients has increased, it has become clear that certain tumours appear at fairly distinct intervals after transplantation (Penn,1989; Penn,1994c; Penn,1994a; Penn,1995a) (Table 13- 3). In contrast to other known oncogenic stimuli, which often take several decades before they cause

Table 13-3 *Average time of appearance of cancers after transplantation.*

Tumour	Mean (mo.)	Range (mo.)	Median (mo.)
Kaposi's sarcoma	21 [22] ¹	1-226	13
PTLD	34	0.25-306	13
Skin cancer	75 [73]	1-362	60
Anogenital	115	1-289	114
All	63 [64]	0.25-362	47

Drawn from data obtained from Penn (1999a).

¹Our data are shown in square brackets. We only had two cases of PTLD and none of anogenital carcinomas.

Table 13-4 Factors contributing to cancers in renal allograft recipients

Immunosuppression

Chronic antigenic stimulation

Age

Environment

Duration of uraemia

Genetic predisposition

Duration of transplant

From Montagnino (2000)

clinical lesions, cancers in renal transplant patients on immunosuppression occurs relatively early after transplantation. The first one to appear is Kaposi's sarcoma that can occur as early as a few weeks after transplantation. Carcinomas of the anogenital region, on the contrary, take longest to appear. When all tumours are included the average time of their appearance is 63 months (Penn,1999a).

PATHOGENESIS OF POSTTRANSPLANT CANCERS

There are several factors in common with Kaposi's sarcoma and skin cancers that contribute to the development of other cancers (Table 13-4).

Immunosuppression

The role of immunosuppression in development of posttransplant malignancies has been discussed in Chapter 16. Our own experience, supported by the literature, is that use cyclosporine in renal transplant recipients is not associated with an increase in the incidence of malignancies (London *et al.*,1995;Montagnino *et al.*,1996;Penn,1990). This is despite the recent study suggesting that cyclosporine, independent of its effect on the host immune system, promotes cancer progression by a direct cell-autonomous effect *via* transforming growth factor β (TGF- β), (Hojo *et al.*,1999). Indeed, meta-analysis done in Chapter 16 suggests that cyclosporine may be associated with a lower incidence of posttransplant cancers. What we have found however, and this has been confirmed by others, is that the latent period to the development of the first cancer is reduced in patients treated with cyclosporine

(Montagnino *et al.*,1996;Penn,1986). In our cohort the latent period was reduced from 87 months under azathioprine to 41 months under cyclosporine, compared to the mean of 60-67 months under cyclosporine reported in other studies. The lesion with the shortest mean time of appearance is Kaposi's sarcoma (21 months) followed by lymphomas (33 months) (Penn,1996b). The predominance of Kaposi's sarcoma in our cohort, probably explains why the mean time to appearance of the first cancer is shorter than reported elsewhere. There is also some evidence that antilymphocyte antibodies enhance the risk of posttransplant lymphoproliferative disorders, an effect which is related more to the degree of immunosuppression rather than a specific oncogenic effect of these agents (Swinnen *et al.*,1990).

Environmental Factors

A well-recognised observation is that the incidence of malignancies increase the longer the patient survive with their functioning grafts; this has been particularly the case in Australasia (Disney *et al.*,1997), where the incidence of skin cancers increases inexorably and it has been predicted that all transplant patients will develop a malignancy if they survive long enough (Sheil,1999). This increasing risk of cancers can be explained by the length of continuous antigenic stimulation, by the natural aging process of the grafted population and the increased time of exposure to immunosuppressive agents and viral pathogens (Montagnino,2000). The cumulative risks to cancer vary in different regions. In a British series, the overall cumulative risk of cancer at 10 years was 18%, and at 20 years 50% (Gaya *et al.*,1995). In an Italian study, probabilities of developing cancer of whatever origin 20 years after transplantation was 32% (Montagnino *et al.*,1996). In the Australian study, at 24 years the overall risk of tumours was 72% with most of the lesions being skin cancers (Sheil *et al.*,1993). The development of skin cancers is highly dependent on exposure to sunlight and probably accounts for the overestimation in the Australian series.

Chronic Antigenic Stimulation and Viruses

Chronic antigenic stimulation from the renal allograft (Gleichmann *et al.*,1975) and viral infections (Klein *et al.*,1977) are recognised causes of malignant transformation. At least 15% of all malignancies are associated with viral infections (zur

Hausen,1991). The human papilloma virus (HPV) is associated with various skin (*vide supra*), oropharynx, oesophagus and bladder carcinomas (Arends *et al.*,1997;Bouwes-Bavinck *et al.*,1997). The Epstein-Barr virus (EBV) is considered the main aetiological agent of posttransplant lymphoproliferative diseases (see below for further discussion) (Ho *et al.*,1988). Hepatitis virus B and C are well-known to cause hepatocellular carcinoma. HPV-16 and -18 have been implicated in cervical cancer and HTLV-1 and -2 in human T-cell leukaemia. Finally, HHV-8 has been associated with all forms of Kaposi's sarcoma (*vide infra*) (Moore *et al.*,1995;Schalling *et al.*,1995).

Uraemia

Prolonged uraemia may be another pathogenetic factor in the development of cancers after renal transplantation. Certain tumours such as liver, thyroid, anogenital, and colon carcinomas are as frequent in dialysis patients as in transplant patients (Brunner *et al.*,1988;Brunner *et al.*,1995;Fairley *et al.*,1994). The factors contributing to development of cancers in uraemic patients include (Birkeland,1998):

1. Uraemia, which may be considered with a state of immune deficiency (Kramer *et al.*,1985)
2. Previous immunosuppression to treat underlying renal diseases such as glomerulonephritis, lupus nephritis, crescentic nephritis etc.
3. The prolonged use of potentially oncogenic drugs such as phenacetin and cyclophosphamide.
4. A link between the renal disease and the risk for cancer (*vide infra*)

Duration of Exposure and Genetic Factors

The risk of malignancies is related to the age of the patient with the older recipients having the greatest risk (Montagnino *et al.*,1996). Aging is characterised by reduced reparative cell proliferation and DNA repair capacity after the damaging effects of UV radiation (Moriwaki *et al.*,1996). In addition, the longer the exposure to the oncogenic factors the greater the risk of malignancies. Genetic and ethnic diversity characterise some lesions. HLA antigens such as -B27 and -DR7 are associated with a greater incidence of squamous cell carcinoma of the skin in transplant

recipients (*vide supra*) (Bouwes-Bavinck *et al.*,1991). Kaposi's sarcoma is particularly common in the Mediterranean region as mentioned earlier as well as the first generation immigrants from these countries (Montagnino *et al.*,1994a;Qunibi *et al.*,1988). At the same time, environmental factors may be equally important in the causation of Kaposi's sarcoma since its increased incidence among Mediterranean transplant recipients may be related to the higher incidence of HHV-8 infection in these populations (Parravicini *et al.*,1997).

Lymphomas (Posttransplant lymphoproliferative disorders - PTLD)

Since Penn *et al.* (1969) described the first case of posttransplant lymphoma a great deal of controversy has surrounded the nomenclature of these lesions. Consequently, the non-specific term posttransplant lymphoproliferative disease (PTLD) has been used widely (Hanto,1995;Nalesnik *et al.*,1994). PTLD therefore refers to a syndrome that includes a wide range of abnormal hyperplastic and neoplastic lymphocyte growths, ranging from a benign self-limited form of lymphoproliferation to an aggressive widely disseminated disease (Frizzera *et al.*,1981;Hanto *et al.*,1985;Harris *et al.*,1997;Knowles *et al.*,1995;Swerdlow,1992). Some 85% to 90% of these growths are of B-cell origin (Penn,1994c), and 90% to 95% contain the EBV. Patients with PTLD have different histological findings, a more aggressive clinical course, respond poorly to conventional treatment for lymphoma and have poorer prognosis when compared with immunocompetent individuals who develop lymphomas (Penn,1996a).

IMPORTANCE

On a worldwide basis non-Hodgkin's lymphoma is the second most common posttransplant malignancy following skin and lip cancers (Table 13-5). However PTLD is much more important because these lymphomas are *the* major cause of cancer-related mortality and morbidity and will therefore be discussed in some detail. In developing countries posttransplant lymphomas are relatively more common than in industrialised countries (see Chapter 6). For reasons that are not clear the

Table 13-5 *De novo cancers in renal allograft recipients - CTTR data*

Type of neoplasm	No. of Tumours	% of Tumours
Cancers of skin/lip	3987	41.2
<i>PTLD</i>	1108	11.4
Lung carcinoma	515	5.3
Uterine carcinoma	406	4.2
Renal carcinoma	393	4.1
Rectal and colon carcinoma	342	3.5
Breast carcinoma	330	3.4
Urogenital carcinoma	272	2.8
Head and neck carcinoma	269	2.8
Bladder carcinoma	236	2.4
Unknown primary carcinoma	217	2.2
Prostatic carcinoma	174	1.8
Leukaemias	174	1.8
Hepatobiliary	170	1.8
Thyroid carcinoma	129	1.3
Stomach carcinoma	125	1.3
Sarcoma (excl. Kaposi's sarcoma)	117	1.2
Testicular carcinoma	75	0.8
Ovarian carcinoma	68	0.7
Pancreatic carcinoma	67	0.7
Miscellaneous tumours	182	1.9
TOTAL	9 688¹	

Adapted from Penn (2000a)

¹These occurred in 9032 patients.

relative incidence of lymphomas in our experience is similar to that reported in developed rather than developing countries (*vide supra*). According to the CTTR, the main repository of data on posttransplant cancers, lymphoma accounts for 16% of cancers in transplant patients compared with 5% in the general population (Penn,1996a); in our cohort lymphomas accounted for 5% of all malignancies. In addition, the relative risk of developing lymphoma after transplantation has been

reported to be 28 to 49 times greater than in the general population (Boubenider *et al.*,1997), whereas the relative risk in our cohort was a mere 1.8. The reason for the lower incidence of this disorder among our recipients may be a lower prevalence of EBV infection in our general population and is an area that warrants further study. The incidence also varies according to the organ transplanted: it is 1.4% to 2.5% among adult renal transplant patients, 2.1% to 2.8% in liver transplant recipients, 1.8% to 6.3% in heart transplant recipients and 4.5% to 10% in lung transplant recipients (Leblond *et al.*,1995;Starzl *et al.*,1984;Swinnen,1997;Walker *et al.*,1995). The difference is related to the more intense immunosuppression that is used in heart and lung transplant recipients (Penn,1995a). Heavy immunosuppression is often used in this group of patients to reverse rejection to save their lives, whereas with severe rejection in renal transplant recipients physicians have the option to abandon immunosuppression and return the patient to dialysis therapy (Penn,2000a). Patients who received antilymphocyte globulin or OKT3 monoclonal antibodies had an increased risk of PTLD (Swinnen *et al.*,1990). Other factors that determine the frequency of PTLD are the presence of EBV infection before the transplantation, adult vs. paediatric population, underlying disease, intensity and duration of immunosuppression.

PATHOGENESIS

Role of Epstein-Barr Virus

The pathogenesis of PTLD is complex and multifactorial. Important general host factors such as impaired immune surveillance, chronic antigenic stimulation from the allograft, type, intensity, and duration of maintenance immunosuppression, have been alluded to above. Epstein-Barr virus (EBV) infection, whether primary or reactivation, however, is the main aetiological factor. Primary EBV disease in normal hosts occurs as a result of salivary contact with an infected individual and presents as self-limiting infectious mononucleosis. The host develops permanent antibodies but the virus remains dormant for life. EBV seroconversion occurs early in life and by adulthood 90% of persons are latently infected with EBV. Essentially all seronegative patients will seroconvert after transplantation (Swinnen,1997). Epstein-Barr virus has been demonstrated in biopsy specimens from patients with PTLD by DNA hybridisation techniques (Saemundsen *et al.*,1981). Most PTLD arise from B

cells that are infected by EBV. The EBV infects B cells by interaction of the viral surface glycoprotein gp350/200 with the cell surface protein CD21 of B cells (Kieff,1996). The virus is then endocytosed and brought into the cell nucleus, where it circularises and equilibrates into one of several forms of latent infection. Acutely infected B-cells express a large number of viral genes that serve as targets for the cellular immune system (Montagnino,2000). Acute infection is kept in check by natural killer cells and by EBV-specific CD4⁺ or CD8⁺ cytotoxic cells. By contrast, latently infected B cells express only a limited number of genes: EBV nuclear antigen-1 (EBNA-1) and latent membrane protein-2 (LMP-2). It is this restricted gene expression that is the mechanism whereby the EBV evades host responses. In addition, EBNA-1 is required for the viral DNA to maintain itself in actively dividing cells and it can reduce the surface expression of MHC class I and adhesion molecules, while LMP-2 allows the virus to limit its gene expression in the latency phase (Cohen,1997). Furthermore, these latently infected B lymphocytes are immortalised through the production of an EBV-encoded gene, BCRF-1 that has more than 80% amino-acid homology with interleukin-10 (IL-10) (Moore *et al.*,1990). IL-10 inhibits synthesis of interferon- γ by lymphocytes and natural killer cells, which protects B cells from apoptosis and favours the proliferation of EBV-transformed B-cells (Kieff,1996). Apoptosis is a protective host response to eliminate virally-infected cells. Epstein-Barr virus can modulate apoptosis by inhibition, allowing the virus to complete its replication before the cell dies (Montagnino,2000).

Other potential mechanisms that trigger cell proliferation may derive from oncogenes and tumour suppressor genes. *Bcl-2* protooncogene, which regulates the effector phase of apoptosis and promotes cellular proliferation is strongly expressed in PTLID (Chetty *et al.*,1996). Epstein-Barr virus upregulates *Bcl-2*, thereby promoting cell survival and thus viral replication (Nunez *et al.*,1989). Normally, such proliferation is inhibited by host immune responses, especially macrophages and T-cells (Birkeland and Bendtzen,1996; Birkeland *et al.*,1999). If T-cells are functionally compromised as is the case in patients on immunosuppression, infected B-cells may be able to escape immune control. All these factors impair the ability of the immune system to eliminate the virus and lead to the development of polyclonal polymorphic hyperplasia that may evolve into a more malignant monoclonal lesion.

Microchimerism

An important observation is that a substantial number of T-cells and macrophages are present within the PTLD lesions (Minervini *et al.*,1999). This may represent an abortive host response although contrary evidence suggests that there may, in fact, be an enhancing response. The intratumoural cytokine environment of PTLD is Th-2-like, which is associated with support of B-cell growth (Nalesnik *et al.*,1999). Finally it has been proposed that host-donor microchimerism, might favour PTLD development (Nalesnik *et al.*,1997) and may explain the preferential occurrence of malignancies in the transplanted graft itself, arising from the donor cells (Goldstein *et al.*,1996).

Other factors

The incidence of PTLD is increased 7- to 10-fold in patients who had symptomatic cytomegalovirus (CMV) infection. In addition EBV replication is regularly observed in patients with CMV infection (Tolkoff-Rubin *et al.*,1998). The incidence of PTLD is related to the dose of cyclosporine (Calne *et al.*,1981;Gaya *et al.*,1995) and the addition of azathioprine to full doses of cyclosporine enhances the risk of lymphoma (Wilkinson *et al.*,1989). The incidence of PTLD is higher in children, in whom this lesion represents 53% of malignancies compared with 15% of cancers in adults (Penn,1998b). The increased incidence in the paediatric population has been attributed to the higher rate of primary EBV infection following transplantation (Dror *et al.*,1999) and the greater mass of lymphoid tissue than in adults (Montagnino,2000).

CLINICAL ASPECTS

Distribution of Lesions

In PTLD the pattern of distribution of lesions is different to that seen in malignant lymphoma in the general population (Penn,1986), with 70% of PTLD lesions occurring in extranodal positions (Penn,1998a) - much higher than seen in the general population (Table 13-6). In patients with central nervous system involvement the brain is usually involved and the lesions are multicentric in distribution (Nalesnik *et al.*,1992;Penn,1989;Penn,1994c;Penn,1994a;Penn *et al.*,1995;Penn,1995a). Another notable feature is that in 54% of patients with

Table 13-6 Localisation of PTLD lesions.

Localisation	Percentage
Multiple organs	53
Extranodal	70
Liver	25
Allograft	23
Lungs	21
Brain	21
Bowel	19
Kidney	18
Spleen	12

Drawn from data derived from Penn (1999a)

central nervous system involvement the disease was limited to that site, compared to 1%-2% prevalence of isolated brain disease in the general population (Penn *et al.*,1995). Also noteworthy was the frequency of either macroscopic or microscopic involvement of the graft by PTLD (Penn,1994c;Penn,1995a;Penn,1996c). In 30% of cases the disease was localised to the allograft. PTLD involvement must be distinguished from allograft rejection, for which it is often mistaken. This may result in incorrect management as immunosuppressive therapy is intensified whereas an important treatment strategy in PTLD involves reduction of immunosuppression (Penn,1994c;Penn,1995a;Starzl *et al.*,1984).

Period to Onset

PTLD can occur as early as 3 weeks to as late as 25 years after transplantation (Penn,1994c). The disease is however remarkable for the short time interval between transplantation and development of the tumour. The period of onset is shorter under cyclosporine than under azathioprine (Mihalov *et al.*,1996). It has recently been reported that 47% of cases occur within six months of transplantation, 62% within 1 year and 90% within 5 years of renal transplantation (Nalesnik *et al.*,2000).

Clinical Manifestations

The two affected patients in our cohort presented with contrasting clinical pictures, illustrating the variability of clinical presentation of PTLD. Both patients were receiving cyclosporine but one received multiple courses of treatment for acute rejection including OKT3 monoclonal antibodies. In this patient the disease was an incidental finding at postmortem, performed after she died of fulminant CMV pneumonitis. There was extensive organ involvement including the renal allograft. The malignancy, that was undiagnosed antemortem, no doubt contributed to her terminal illness. The second patient was found to have diffuse B cell lymphoma when a non-healing leg ulcer was biopsied. The lesion improved when maintenance azathioprine treatment was withdrawn. Isolated skin involvement as seen in our patient is rare but has been reported (Gonthier *et al.*,1992;McGregor *et al.*,1993). The CMV and EBV status of this patient were unknown. The clinical features of PTLD tend to fall within several-defined, albeit overlapping forms (Malatack *et al.*,1991). These include:

1. An infectious mononucleosis-like syndrome with or without lymphadenopathy
2. One or more nodal or extranodal tumours
3. Fulminant and disseminated presentation with sepsis

The first mode of presentation is common in children occurring early after transplantation and is seen particularly with primary EBV infection. In children upper respiratory tract symptoms, which may be quite severe, are often the first manifestation of PTLD (Posey *et al.*,1999). It is not always possible to distinguish clinically between frank PTLD and infectious mononucleosis.

PTLD that occurs later is more likely to be anatomically circumscribed and to be associated with gastrointestinal, pulmonary, or central nervous system involvement. The allograft may also be involved as was our experience. The frequency of involvement depends on the specific type of allograft. PTLDs that arise in lung or intestinal transplants involve those organs in 80% of cases; lesions arising in liver and kidney allograft recipients involve one third of these organs (Cohen,1991). In contrast, the transplanted heart is seldom involved by these tumours (Hanasono *et*

al.,1995). The symptoms of PTLT will vary depending on the site of tumour involvement.

A fulminant form of PTLT is rare occurring in approximately 1% of cases. These patients present with a clinical picture of septicaemia and may also have lymphadenopathy or frank tumours (Nalesnik *et al.*,2000). Exudates in the pleural or peritoneal cavities from which malignant cells can be isolated may be present (Ohuri *et al.*,2001).

Since no formal staging of PTLT exists, it has been recommended that the Ann Arbor classification with Cotswold modification be used (Paya *et al.*,1999).

PATHOLOGY OF PTLT

See Fig. 13.1 (page 13-39) for details of some features of the disease.

CLASSIFICATION OF PTLT

The classification of PTLT has recently been reviewed by the Society of Haematopathology in a recent workshop (Harris *et al.*,1997) (Table 13-7).

MANAGEMENT

Diagnosis of PTLT requires biopsy of involved tissue. In addition, several laboratory tests serve to support or suggest the diagnosis of PTLT. A monoclonal gammopathy has been demonstrated in over 70% of transplant recipients compared with 27% of patients without PTLT (Ciancio *et al.*,1997). A separate study confirms that PTLT developed in 9% of patients who had monoclonal gammopathy (Pageaux *et al.*,1998). Epstein-Barr viral serologic testing may be used to evaluate recent or remote infection, but the diagnosis of EBV infection is not synonymous with a diagnosis of PTLT, since the number of patients who have the infection who go on to develop PTLT is small. In a recent study of EBV-negative paediatric liver transplant patients, 80% seroconverted within 3 months. Of these patients 85% remained asymptomatic, while only 15% developed PTLT (Smets *et al.*,2000). Quantitative estimation of

Table 13-7 Categories of posttransplant lymphoproliferative diseases, according to the Society of Haematopathology Workshop.

Early lesions

- Reactive plasmacytic hyperplasia
- Infectious mononucleosis-like

Polymorphic PTLD

- Polyclonal
- Monoclonal

Monomorphic PTLD**B cell lymphoma**

- (1) Diffuse large-cell lymphoma (immunoblastic, centroblastic, anaplastic)
- (2) Burkitt's / Burkitt's-like lymphoma
- (3) Other types (e.g. T-NK)

T-cell lymphoma

- (1) Peripheral T cell lymphoma, unspecified type (usually large-cell)
- (2) Anaplastic large-cell lymphoma (t or null)
- (3) Other types (e.g. T-NK)

Other

- T cell-rich/Hodgkin's disease-like B cell lymphoma
 - Plasmacytoma-like
 - Myeloma
-

From Harris *et al.* (1997)

the number of EBV genomes in the peripheral blood is useful because it has been shown that patients with PTLD have elevated numbers of circulating viral genomes (Hanasono *et al.*, 1995; Rooney *et al.*, 1995a; Rowe *et al.*, 1997). On the other hand, regression of PTLD is associated with decrease in the number of circulating viral genomes, suggesting that this may be a useful technique for monitoring the response of the disease to treatment (Rogers *et al.*, 1998).

It has been suggested that malignant tissue of all patients with PTLD should be subjected to clonality testing using cell typing of surface and cytoplasmic immunoglobulins (Whiting *et al.*,1998). Establishing clonality is of prognostic importance with polyclonal lesions responding better to treatment. In addition, clonal cytogenetic abnormalities revealed by metaphase examinations may disclose malignant transformation of benign polyclonal B cell proliferation into malignant lymphoma (Hanto *et al.*,1989).

TREATMENT

Early diagnosis and use of appropriate therapies are essential for the successful treatment of PTLD. There is however no universal approach. A graded treatment approach for PTLD has been proposed, according to the stage of the disease (Davis *et al.*,1998;Hanto *et al.*,1989) and the degree of acute illness of the patient (Dror *et al.*,1999;Praghakaran *et al.*,1999). Polymorphic diffuse B cell hyperplasia still seems to be dependent on viral replication and the use of high-dose systemic acyclovir or valacyclovir that inhibit EBV DNA replication may be sufficient to treat the disease. These antiviral agents have no effect on non-replicating latent EBV genome (Hanto *et al.*,1982). In these cases as well as those with cytogenetic abnormalities, reduction or withdrawal of immunosuppression is advocated as the first therapeutic step (Swinnen *et al.*,1995). This alone will result in the regression of PTLD in 25% to almost 50% of all cases (Benkerrou *et al.*,1993;Heslop *et al.*,1994a;Starzl *et al.*,1984). The obvious risk with this approach is that of acute allograft rejection. For this reason other therapeutic approaches have also been attempted. The routine use of prophylactic anti-CMV therapy with ganciclovir or acyclovir has become increasingly prevalent (Balfour, Jr. *et al.*,1989;Hibberd *et al.*,1992). Both agents are also potent inhibitors of EBV replication (Dorsky *et al.*,1987;Matthews *et al.*,1988). It has been suggested that this practice should have the beneficial effect of inhibiting EBV reactivation or prevention of primary EBV infection (First,1993;Stephanian *et al.*,1991), as a result of which the incidence of PTLD would diminish. There are no prospective randomised studies to test the efficacy of acyclovir or ganciclovir given prophylactically. However, a recent study showed that acyclovir or ganciclovir given preemptively during antilymphocyte treatment reduced the incidence of PTLD to 1 in 198 consecutive patients from 7 of 179 historical control patients (McDiarmid *et*

al.,1998). However, cases have been reported where a combination of acyclovir and ganciclovir used as anti-CMV prophylaxis failed to prevent the development of PTLD in high risk patients (Aris *et al.*,1996;Kuo *et al.*,1995b;Kuo *et al.*,1995a). The reason that these agents fail to be effective could be because they are virostatic rather than virocidal and act only on the linear form of the virus and not the latent form that is important in PTLD development (Penn,2000b).

Cytokine therapy

The next intervention may be the introduction of interferon- α 2b that is capable of enhancing the cytotoxic T-cell activity against EBV thus stimulating the immune system to reject the PTLD. A recent review of published reports concluded that interferon- α may succeed when there has been no response to reduction of immunosuppression (Faro,1998). This agent however, increases the risk of acute rejection. The response to interferon- α is rapid - usually within 3 weeks in 50% of the patients (Davis *et al.*,1998).

Radiotherapy and chemotherapy

If interferon- α therapy fails or the disease progresses rapidly, chemotherapy should be considered. Chemotherapy should be combined with radiotherapy or with local tumour resection (Penn *et al.*,1995). The results of treatment with conventional chemotherapeutic agents are conflicting (Boubenider *et al.*,1997;Morrison *et al.*,1994). Some centres reported complete regression of the disease, while others reported low success rates and high mortality rates with this form of treatment. Recently, regimens have been modified to both treat the malignancy and to maintain an immunosuppressed state, to preserve the allograft (Gross *et al.*,1998;Swinnen,1997).

Cell therapy

Cell therapy represents a recent innovation in the treatment of PTLD. Donor lymphocyte infusions, in a graft-vs-host type reaction, have been successfully used to treat PTLD in several bone marrow transplant recipients (Papadopoulos *et al.*,1994). An alternative approach to cell therapy for PTLD was used by other groups (Heslop *et al.*,1994b;Heslop *et al.*,1994a;Heslop *et al.*,1999;Rooney *et*

al.,1995b). Donor T-cells were stimulated with EBV-positive B cells and those cells with anti-EBV reactivity were collected and transfused into recipients. Anti-B cell antibodies such as anti-CD21 and anti-CD-24 antibodies are alternative forms of treatment that may be used in patients with polyclonal tumours who are unable to undergo a reduction in immunosuppression (Antoine *et al.*,1996;Fischer *et al.*,1991). Preliminary results are encouraging: in a recent report of PTLT treatment by means of monoclonal antibodies, there was a 58% response rate (Benkerrou *et al.*,1993).

PROGNOSIS

With this sequential approach, one series of adult patients has reported success in 76% of patients (Davis *et al.*,1998), while a paediatric series reports successful treatment in 80% of patients including those with monomorphic or monoclonal lesions (Dror *et al.*,1999). However, overall response and survival rates are difficult to compare because of the wide range of PTLT forms and therapies. A recent review of relevant literature shows responses that vary depending on the histology and stage of the disease. In two separate series, mortality from polymorphic and monomorphic PTLTs ranged from 0% to 20%, and 67% to 87% respectively. PTLTs with cytogenetic abnormalities, usually fall into the monomorphic category and have a poor prognosis (*vide supra*). In a separate series, it was observed that 44% of PTLT survivors had involvement of only one organ, and involvement of three or more organs occurred in 57% of fatal cases (Cohen,1991). In children, mortality is also closely related to the underlying transplant procedure. Bone marrow transplant and cardiac transplant recipients had higher mortality rates (100% and 55% respectively), than liver and kidney transplant recipients (both 0%) (Donnelly *et al.*,1998).

Miscellaneous Cancers

We have described a number of other malignancies in our cohort. The small numbers of these cases in the reported literature does not allow meaningful statistical evaluation. The incidence and epidemiology of these lesions as well as the geographic variation in the patterns of posttransplant malignancies has been discussed in Chapter 6. Carcinomas of the lung are the second most common solid

tumours in patients in the CTTR (Table 13-5) as well as in our study. In a report of malignancies in 785 transplant recipients, 8 cases of bronchogenic carcinoma were observed. The incidence according to organ transplanted was 2% for heart transplant patients and less than 0.5% for kidney transplant patients (Delcambre *et al.*,1996). The mean age of transplanted patients who developed bronchogenic carcinoma was 57 years, compared to the mean age of 63 years of the tumour in the general population (Delcambre *et al.*,1996). In a report on bronchogenic carcinoma in cardiac transplant patients, it was found that all were men and all were heavy smokers, as, indeed all our patients who had lung cancer, were. The tumour was irresectable in almost all the patients and they were treated with chemotherapy and/or radiotherapy. Median survival was only 3 months! (Goldstein *et al.*,1996). We were impressed by the number of occult thyroid cancers in the South African experience. In two of our patients thyroid cancer were incidental findings at postmortem examination. One patient died of PTLN complicated by CMV pneumonitis, while the other patient died postoperatively following complications of transplant surgery. A review of the literature indicates that thyroid cancer is a relatively low-grade malignancy that is often found incidentally at postmortem examinations of renal transplant recipients (Cassidy *et al.*,1982;Disler *et al.*,1981;Starzl *et al.*,1970). It is interesting to note that all the other South African centres who reported their experience of posttransplant malignancies reported occult thyroid cancers as well (Cassidy *et al.*,1982;Disler *et al.*,1981;Margolius,1996). In cases where the diagnosis is made antemortem, the patients can have extended survival after successful treatment of the malignant lesion (Yasumura *et al.*,1997).

Prevention of Posttransplant Cancers

Every effort should be made to prevent the development of posttransplant malignancies (Penn *et al.*,1969;Penn,1994c;Penn,1995a;Penn,1996d). Certain guidelines have been proposed to reduce the risk of posttransplant cancers and allow their early detection (Montagnino,2000). These are summarised in Table 13-8. Immunosuppression should be maintained at the minimum level compatible with good renal allograft function. If necessary heroic attempts to salvage failing renal

Table 13-8 Recommendations for the prevention and early detection of de novo cancers in renal transplant recipients.

Patient Responsibility - Life style modification

Stop smoking

Minimize sun exposure

Reduce fat intake

Minimise intake of salt-cured and smoked foods

Self-examination of breasts and testes

Take viral infections seriously

Physician Responsibility - Regular screening

Dermatological evaluation

Gynaecological evaluation

Prostatic evaluation (PSA¹, sonar)

Native kidney sonar

Occult blood in stools

¹Prostate specific antigen

allografts should be abandoned and patients returned to dialysis therapy. Viral infections should be prevented whenever possible (Penn,1996d). It has been suggested that hepatitis B vaccine be used to immunise seronegative potential renal transplant recipients to reduce the risk of hepatocellular carcinoma. In the prevention of PTLD the use of early markers has been advocated: the presence of monoclonal gammopathies may be a clue (Pham *et al.*,1998) (*vide supra*). However, the avoidance of overimmunosuppression especially the use of multiple agents over a short period of time and the use of prolonged or repeated course of antilymphocyte antibody preparations is perhaps more important. The use of acyclovir and ganciclovir in the prevention of PTLD has been discussed above. Currently there is no effective prophylaxis against other potentially oncogenic viruses such as human herpesvirus-8 and human papillomaviruses (HPV). As HPV infections are sexually transmitted, patients should be advised to use the barrier method of contraception (Penn,1996d; Sillman *et al.*,1984). All post adolescent females should undergo regular pelvic examinations and cervical smears. All premalignant lesions including

condylomata or cervical dysplasia should be treated early to prevent progression to cancer (Penn,1996d). Sunlight exposure is important in the causation of skin cancers and transplant patients, especially those with fair complexions, blonde or red hair and blue eyes should avoid excessive exposure (Euvrard *et al.*,1997; Penn,1994c; Penn,1995a; Penn,1996d; Sheil,1994). Patients venturing outside in the sun should be advised to wear wide-brimmed hats, sun visors and appropriate protective clothing. In addition use of protective sunscreens that filter out the harmful ultraviolet rays should be considered. The skin of patients at risk should be examined regularly and any premalignant skin lesions carefully observed or treated. The use of retinoids in the treatment of skin lesions is controversial and has been discussed further in Chapter 13. The routine screening of the diseased kidneys of transplant patients with regular ultrasound examinations to exclude acquired cystic disease related malignancies, is not cost effective (Penn,2000b). However, in patients who have analgesic nephropathy, regular screening including urine cytology and appropriate radiological screening procedures are advisable to detect early malignancies (Penn,1995b; Penn,1996d). Tumour markers do not appear to be useful screening tools. In a study involving 70 patients with no overt gastrointestinal malignant disease serial carcinoembryonic antigen (CEA) and a number of other tumour markers were serially monitored starting prior to transplantation. Of the 70 patients, 1% to 36% had persistent elevation of one or other of the markers with no evidence of malignant disease (Wood *et al.*,1993).

Pre-existing cancers

Although none of our patients who had been treated for malignancies before transplantation suffered a relapse of the original tumour, the question of the safety of transplantation in patients who have had a previous malignancy remains a vexing one. The predisposition of transplanted patients to development of malignancies is well known (*vide supra*). The recurrence of cancers in patients with pre-existing tumours was recently reviewed (Penn,1997). Among 1297 renal transplant recipients the recurrence rate was 21% for cancers treated before transplantation and 33% for those treated after the transplant. The rate of recurrence depended on the type of tumour. Incidental renal, uterine body, testicular, uterine cervical and

thyroid carcinomas showed low recurrence rates of between 1% and 7%. Hodgkin's lymphoma, Wilm's tumour, prostate carcinoma, and malignant melanoma showed intermediate recurrence rates of 11% to 21%. Breast, symptomatic renal cell, colorectal, and bladder carcinomas, as well as multiple myeloma and sarcomas had recurrence rates of 14% to 23% (Penn,1983; Penn,1993; Penn,1997). Other factors that were associated with a low rate of recurrence were a favourable histology, (*in-situ* or low grade malignancy) and a long time interval (more than 5 years) between treatment of malignancy and the transplantation (Montagnino,2000). In patients with skin cancer, the incidence of recurrence is high (58%) and there is no correlation between the time of treatment and the likelihood of recurrence (Penn,1983). In the tumours treated after transplantation, 39% of recurrences were from nonmelanoma skin cancers, followed by prostatic carcinoma (12%), incidental renal carcinoma (8%) and symptomatic renal carcinoma (5%).

Recommendations on delay before transplantation

In patients with low-grade cancers, including skin cancers and *in situ* cancer of the uterine cervix no waiting period is necessary and they can be offered transplantation after treatment of the lesions. Patients who have other cancers treated successfully should be observed for at least two years before transplantation is considered (Penn,1993). A waiting period of at least 5 years is recommended before transplantation for tumours with a high recurrence rate (*vide supra*), in order to minimise the risk of stimulating the growth of dormant metastases (Montagnino, 2000).

Cancers in Renal versus Non-Renal Recipients (Table 13-9)

INCIDENCE

A recent single-centre study of 674 solid organ transplant patients established that the overall frequency of posttransplant cancers was lower in renal transplant recipients compared to non-renal transplant recipients (9% vs. 16% respectively); also noted was a longer interval to malignancy (61 vs. 27 months) (Mihalov *et al.*,1996). In a report specifically on Kaposi's sarcoma, it was reported that the frequency of Kaposi's sarcoma was significantly higher in liver transplant recipients

Table 13-9 Pattern of cancers in renal transplant recipients versus non-renal transplant recipients.

Type of Tumour	Renal Recipients (n = 9508) ¹		Non-Renal Recipients (n = 2155) ²	
	Number	%	Number	%
Skin cancers	3819	40	587	27
PTLD	1080	11	873	41
Lung carcinoma	505	5	147	7
Kaposi's sarcoma	416	4	51	2
Cervix carcinoma	337	4	19	<1
Renal carcinoma	385	3	30	1
Anogenital carcinoma	265	3	20	<1

From Penn (1999a)

¹In 8868 patients

²In 2087 patients

(1.24%) than in either renal (0.45%) or heart transplant patients (0.41%) (Montagnino *et al.*, 1994a). The available data also suggests that lung malignancies are seen more commonly after heart transplantation than after renal transplantation, while survival data indicate a poorer prognosis in these patients compared to the general population with similar-stage lesions (Herr *et al.*, 1979; Kinlen *et al.*, 1979; Oberbauer *et al.*, 1996; Tan *et al.*, 1995).

DISTRIBUTION

Many differences in the pattern of tumours in renal allograft recipients compared to recipients of other organs have already been alluded to. The difference in the lesions in the two groups is indicated in Table 13-9. The most striking feature is the frequency with which PTLD occurs in non-renal recipients compared with renal recipients. This is most likely related to the difference in the intensity of immunosuppression in the two groups as discussed above. Many renal patients have been followed up for 10 to 30 years posttransplant, whereas few non-renal patients have been followed so long. This may account for the somewhat higher

frequency of late appearing tumours such as skin, uterine cervix, and urogenital lesions in renal recipients. The higher incidence of renal tumours may reflect the influence of analgesic nephropathy and acquired cystic kidney disease (Gonthier *et al.*, 1992; Penn, 1989; Penn, 1994c; Penn, 1994a).

BONE MARROW TRANSPLANT PATIENTS

In bone marrow transplant recipients the pattern of malignancies is somewhat different. PTLD and leukaemias are the main tumours encountered but other common lesions include malignant melanoma, and cancers of the buccal mucosa, brain, liver, thyroid, bone and connective tissue. The cancers that develop may be related to the treatment of the underlying disease (that necessitated the transplant). The treatments used include radiation therapy and chemotherapy, as well as conditioning regimens with total body irradiation or limited field irradiation and/or large doses of chemotherapy. To further aggravate the problem, patients are placed on immunosuppression posttransplantation to prevent or treat graft-versus-host reaction (Penn, 1999a). Radiation therapy is particularly important in the cancers of the thyroid, salivary glands, bone connective tissue and the brain. The mechanism of the association between malignant melanoma and high doses of radiation are unknown (Curtis *et al.*, 1997).

SUMMARY

There is a several-fold increase in cancers following renal transplantation. However, after skin cancer the most common malignancies are malignant lymphomas. The cancers that commonly threaten the general population are no more common in these patients. Indeed, in the case of breast and prostate carcinoma these are less common in transplanted patients. The exact aetiology of posttransplant cancers remains speculative but in PTLD the EBV plays a key aetiological role. PTLD manifests in several ways clinically but a high index of suspicion should always be maintained. PTLD is relatively more common in non-renal transplant recipients and remains difficult to treat. It accounts for significant posttransplant morbidity and mortality. The incidence of cancers increases the longer the patients survive with

their functioning grafts; it is essential that regular examinations be scheduled especially in high-risk groups. Prevention of cancers is of paramount importance and involves both the patient and his or her physician.

Despite the challenges, the late Dr Penn remained optimistic and gives some indication of future directions ". . . Nonetheless the future holds promise. Attempts are being made to modify the immune system . . . to induce states of immune unresponsiveness directed specifically . . . at the foreign antigens of the allograft. . . . these efforts should eliminate the need for long-term . . . immunosuppressive therapy and the problem of posttransplant malignancies will be relegated to a footnote in the history of organ transplantation." (Penn,1999a).

LITERATURE CITED

- Akhtar, M., Bunuan, H., Ali, M. A., and Godwin, J. T. (1984). Kaposi's sarcoma in renal transplant recipients. Ultrastructural and immunoperoxidase study of four cases. *Cancer*. **53**, 258.
- Antoine, C., Garnier, J. L., Duboust, A., Bariety, J., Stevenson, G., and Glotz, D. (1996). Successful treatment of posttransplant lymphoproliferative disorder with renal graft preservation by monoclonal antibody therapy. *Transplant Proc*. **28**, 2825.
- Arends, M. J., Benton, E. C., McLaren, K. M., Stark, L. A., Hunter, J. A., and Bird, C. C. (1997). Renal allograft recipients with high susceptibility to cutaneous malignancy have an increased prevalence of human papillomavirus DNA in skin tumours and a greater risk of anogenital malignancy. *Br J Cancer*. **75**, 722.
- Aris, R. M., Maia, D. M., Neuringer, I. P., *et al.* (1996). Posttransplantation lymphoproliferative disorder in the Epstein-Barr virus-naive lung transplant recipient. *Am J Respir.Crit Care Med*. **154**, 1712.
- Balfour, H. H., Jr., Chace, B. A., Stapleton, J. T., Simmons, R. L., and Fryd, D. S. (1989). A randomized, placebo-controlled trial of oral acyclovir for the prevention of cytomegalovirus disease in recipients of renal allografts. *N Engl J Med*. **320**, 1381.

- Benkerrou, M., Durandy, A., and Fischer, A. (1993). Therapy for transplant-related lymphoproliferative diseases. *Hematol.Oncol.Clin North Am.* **7**, 467.
- Birkeland, S. A. and Bendtzen, K. (1996). Interleukin-10 and Epstein-Barr virus-induced posttransplant lymphoproliferative disorder. *Transplantation.* **61**, 1425.
- Birkeland, S. A., Bendtzen, K., Moller, B., Hamilton-Dutoit, S., and Andersen, H. K. (1999). Interleukin-10 and posttransplant lymphoproliferative disorder after kidney transplantation. *Transplantation.* **67**, 876.
- Birkeland, S. A. (1998). Malignancies occurring de novo after transplantation. *Curr Opin Organ Transplant.* **3**, 82.
- Boubenider, S., Hiesse, C., Goupy, C., Kriaa, F., Marchand, S., and Charpentier, B. (1997). Incidence and consequences of posttransplantation lymphoproliferative disorders. *J Nephrol.* **10**, 136.
- Bouwes-Bavinck, J. N. and Berkhout, R. J. (1997). HPV infections and immunosuppression. *Clin Dermatol.* **15**, 427.
- Bouwes-Bavinck, J. N., Vermeer, B. J., Van-Der, Woude FJ., *et al.* (1991). Relation between skin cancer and HLA antigens in renal-transplant recipients [see comments]. *N.Engl.J.Med.* **325**, 843.
- Brunner, F. P., Fassbinder, W., Broyer, M., *et al.* (1988). Survival on renal replacement therapy: data from the EDTA Registry. *Nephrol.Dial.Transplant.* **3**, 109.
- Brunner, F. P., Landais, P., and Selwood, N. H. (1995). Malignancies after renal transplantation: the EDTA-ERA registry experience. European Dialysis and Transplantation Association-European Renal Association. *Nephrology Dialysis Transplantation.* **10 Suppl 1**, 74.
- Calne, R. Y., Rolles, K., White, D. J., *et al.* (1981). Cyclosporin-A in clinical organ grafting. *Transplant Proc.* **13**, 349.
- Cassidy, M. J., Disler, P. B., Swanepoel, C. R., Jacobson, J. E., and Pontin, A. R. (1982). De novo malignant tumours in renal transplant recipients. *S.Afr.Med J.* **62**, 58.
- Chetty, R., Biddolph, S., Kaklamanis, L., *et al.* (1996). bcl-2 protein is strongly expressed in posttransplant lymphoproliferative disorders. *J Pathol.* **180**, 254.
- Ciancio, G., Siquijor, A. P., Burke, G. W., *et al.* (1997). Posttransplant lymphoproliferative disease in kidney transplant patients in the new immunosuppressive era. *Clin Transplant.* **11**, 243.

- Cockburn, I. T. and Krupp, P. (1989). The risk of neoplasms in patients treated with cyclosporine A. *J Autoimmun.* **2**, 723.
- Cohen, J. I. (1991). Epstein-Barr virus lymphoproliferative disease associated with acquired immunodeficiency. *Medicine (Baltimore)*. **70**, 137.
- Cohen, J. I. (1997). Epstein-Barr virus and the immune system. Hide and seek. *JAMA*. **278**, 723.
- Curtis, R. E., Rowlings, P. A., Deeg, H. J. et al. (1997). Solid cancers after bone marrow transplantation. *N Engl J Med*. **336**, 897.
- Davis, C. L., Wood, B. L., Sabath, D. E., Joseph, J. S., Stehman-Breen, C., and Broudy, V. C. (1998). Interferon-alpha treatment of posttransplant lymphoproliferative disorder in recipients of solid organ transplants. *Transplantation*. **66**, 1770.
- Delcambre, F., Pruvot, F. R., Ramon, P., et al. (1996). Primary bronchogenic carcinoma in transplant recipients. *Transplant Proc*. **28**, 2884.
- Disler, P. B., MacPhail, A. P., and Myburgh, J. A. (1981). Neoplasia after successful renal transplantation. *Nephron*. **29**, 119.
- Disney, A. P. S., Russ, G. R., Walker, R., and Sheil, A. G. R. (1997) *Australia and New Zealand Transplant Registry Report (1997)*. Australia and New Zealand Transplant Registry Adelaide, South Australia.
- Donnelly, L. F., Frush, D. P., Marshall, K. W., and White, K. S. (1998). Lymphoproliferative disorders: CT findings in immunocompromised children. *AJR Am J Roentgenol*. **171**, 725.
- Dorsky, D. I. and Crumpacker, C. S. (1987). Drugs five years later: acyclovir. *Ann.Intern.Med*. **107**, 859.
- Dror, Y., Greenberg, M., Taylor, G., et al. (1999). Lymphoproliferative disorders after organ transplantation in children. *Transplantation*. **67**, 990.
- Euvrard, S., Kanitakis, J., Pouteil-Noble, C., Claudy, A., and Touraine, J. L. (1997). Skin cancers in organ transplant recipients. *Ann.Transplant*. **2**, 28.
- Fairley, C. K., Sheil, A. G., McNeil, J. J., et al. (1994). The risk of ano-genital malignancies in dialysis and transplant patients. *Clin.Nephrol*. **41**, 101.
- Faro, A. (1998). Interferon-alpha and its effects on posttransplant lymphoproliferative disorders. *Springer Semin.Immunopathol*. **20**, 425.
- First, M. R. (1993). Long-term complications after transplantation. *Am J Kidney Dis*. **22**, 477.

- Fischer, A., Blanche, S., Le Bidois, J., *et al* . (1991). Anti-B-cell monoclonal antibodies in the treatment of severe B-cell lymphoproliferative syndrome following bone marrow and organ transplantation. *N Engl J Med.* **324**, 1451.
- Frizzera, G., Hanto, D. W., Gajl-Peczalska, K. J., *et al.* (1981). Polymorphic diffuse B-cell hyperplasias and lymphomas in renal transplant recipients. *Cancer Res.* **41**, 4262.
- Gaya, S. B. M., Rees, A. J., Lechler, R. I., Williams, G., and Mason, P. D. (1995). Malignant disease in patients with long term renal transplants. *Transplantation.* **59**, 1705.
- Gleichmann, E., Gleichmann, H., Schwartz, R. S., Weinblatt, A., and Armstrong 7y. (1975). Immunologic induction of malignant lymphoma: identification of donor and host tumors in the graft-versus-host model. *J Natl.Cancer Inst.* **54**, 107.
- Goldstein, D. J., Austin, J. H., Zuech, N., *et al.* (1996). Carcinoma of the lung after heart transplantation. *Transplantation.* **62**, 772.
- Gonthier, D. M., Hartman, G., and Holley, J. L. (1992). Posttransplant lymphoproliferative disorder presenting as an isolated skin lesion. *Am J Kidney Dis.* **19**, 600.
- Gross, T. G., Hinrichs, S. H., Winner, J., *et al.* (1998). Treatment of posttransplant lymphoproliferative disease (PTLD) following solid organ transplantation with low-dose chemotherapy. *Ann.Oncol.* **9**, 339.
- Gunji, Y., Ochiai, T., Asano, T, *et al.* (1990). Development of malignant tumor in renal transplant recipients and their NK and LAK activity. *Jap.J.Clin.Immun.* **13**, 236.
- Hanasono, M. M., Kamel, O. W., Chang, P. P., Rizeq, M. N., Billingham, M. E., and van de, Rijn M. (1995). Detection of Epstein-Barr virus in cardiac biopsies of heart transplant patients with lymphoproliferative disorders. *Transplantation.* **60**, 471.
- Hanto, D. W. (1995). Classification of Epstein-Barr virus-associated posttransplant lymphoproliferative diseases: implications for understanding their pathogenesis and developing rational treatment strategies. *Annu.Rev.Med.* **46**, 381.
- Hanto, D. W., Birkenbach, M., Frizzera, G., Gajl-Peczalska, K. J., Simmons, R. L., and Schubach, W. H. (1989). Confirmation of the heterogeneity of posttransplant Epstein-Barr virus- associated B cell proliferations by immunoglobulin gene rearrangement analyses. *Transplantation.* **47**, 458.

- Hanto, D. W., Frizzera, G., Gajl-Peczalska, K. J., *et al.* (1982). Epstein-Barr virus-induced B-cell lymphoma after renal transplantation: acyclovir therapy and transition from polyclonal to monoclonal B-cell proliferation. *N Engl J Med.* **306**, 913.
- Hanto, D. W., Frizzera, G., Gajl-Peczalska, K. J., and Simmons, R. L. (1985). Epstein-Barr virus, immunodeficiency, and B cell lymphoproliferation. *Transplantation.* **39**, 461.
- Harris, N. L., Ferry, J. A., and Swerdlow, S. H. (1997). Posttransplant lymphoproliferative disorders: summary of Society for Hematopathology Workshop. *Semin.Diagn.Pathol.* **14**, 8.
- Herr, H. W., Engen, D. E., and Hostetler, J. (1979). Malignancy in uremia: dialysis versus transplantation. *J.Urol.* **121**, 584.
- Heslop, H. E., Brenner, M. K., Rooney, C., *et al.* (1994a). Administration of neomycin-resistance-gene-marked EBV-specific cytotoxic T lymphocytes to recipients of mismatched-related or phenotypically similar unrelated donor marrow grafts. *Hum.Gene Ther.* **5**, 381.
- Heslop, H. E., Brenner, M. K., and Rooney, C. M. (1994b). Donor T cells to treat EBV-associated lymphoma. *N Engl J Med.* **331**, 679.
- Heslop, H. E., Perez, M., Benaim, E., Rochester, R., Brenner, M. K., and Rooney, C. M. (1999). Transfer of EBV-specific CTL to prevent EBV lymphoma post bone marrow transplant. *J Clin Apheresis.* **14**, 154.
- Hibberd, P. L., Tolkoff-Rubin, N. E., Cosimi, A. B., *et al.* (1992). Symptomatic cytomegalovirus disease in the cytomegalovirus antibody seropositive renal transplant recipient treated with OKT3. *Transplantation.* **53**, 68.
- Ho, M., Jaffe, R., Miller, G., *et al.* (1988). The frequency of Epstein-Barr virus infection and associated lymphoproliferative syndrome after transplantation and its manifestations in children. *Transplantation.* **45**, 719.
- Hojo, M., Morimoto, T., Maluccio, M., *et al.* (1999). Cyclosporine induces cancer progression by a cell-autonomous mechanism [see comments]. *Nature.* **397**, 530.
- Kieff, E. (1996). Epstein-Barr virus and its replication. *In* Fields Virology, (Fields, B. N., Knipe, D. M., Chanock, R., and Howley, P. M., eds.), p.2343, Lippincott-Raven, Philadelphia.

- Kinlen, L. J., Sheil, A. G., Peto, J., and Doll, R. (1979). Collaborative United Kingdom-Australasian study of cancer in patients treated with immunosuppressive drugs. *Br.Med.J.* **2**, 1461.
- Klein, G. and Klein, E. (1977). Immune surveillance against virus-induced tumors and nonrejectability of spontaneous tumors: contrasting consequences of host versus tumor evolution. *Proc.Natl.Acad.Sci.U.S.A.* **74**, 2121.
- Knowles, D. M., Cesarman, E., Chadburn, A., *et al.* (1995). Correlative morphologic and molecular genetic analysis demonstrates three distinct categories of posttransplantation lymphoproliferative disorders. *Blood.* **85**, 552.
- Kramer, P., Broyer, M., Brunner, F. P., *et al.* (1985). Combined report on regular dialysis and transplantation in Europe, XIV, 1983. *Proc.Eur.Dial.Transplant Assoc.Eur.Ren Assoc.* **21**, 2.
- Kuo, P. C., Dafoe, D. C., Alfrey, E. J., *et al.* (1995a). Posttransplant lymphoproliferative disorders and Epstein-Barr virus prophylaxis. *Transplantation.* **59**, 135.
- Kuo, P. C., Dafoe, D. C., Alfrey, E. J., Sibley, R. K., and Scandling, J. D. (1995b). Posttransplant lymphoproliferative disorders and Epstein-Barr virus prophylaxis. *Transplantation.* **59**, 135.
- Leblond, V., Sutton, L., Dorent, R., *et al.* (1995). Lymphoproliferative disorders after organ transplantation: a report of 24 cases observed in a single center. *J Clin Oncol.* **13**, 961.
- London, N. J., Farmery, S. M., Will, E. J., Davison, A. M., and Lodge, J. P. (1995). Risk of neoplasia in renal transplant patients. *Lancet.* **346**, 403.
- Malatack, J. F., Gartner, J. C., Jr., Urbach, A. H., and Zitelli, B. J. (1991). Orthotopic liver transplantation, Epstein-Barr virus, cyclosporine, and lymphoproliferative disease: a growing concern. *J Pediatr.* **118**, 667.
- Margolius, L. P. (1996). Kaposi's sarcoma and other malignancies in renal transplant recipients. *Transplant.Rev.* **10**, 129.
- Matthews, T. and Boehme, R. (1988). Antiviral activity and mechanism of action of ganciclovir. *Rev.Infect.Dis.* **10 Suppl 3**, S490.
- McDiarmid, S. V., Jordan, S., Kim, G. S., *et al.* (1998). Prevention and preemptive therapy of posttransplant lymphoproliferative disease in pediatric liver recipients. *Transplantation.* **66**, 1604.

- McGregor, J. M., Yu, C. C., Lu, Q. L., Cotter, F. E., Levison, D. A., and MacDonald, D. M. (1993). Posttransplant cutaneous lymphoma. *J Am Acad.Dermatol.* **29**, 549.
- Mihalov, M. L., Gattuso, P., Abraham, K., Holmes, E. W., and Reddy, V. (1996). Incidence of posttransplant malignancy among 674 solid-organ-transplant recipients at a single center. *Clin.Transplant.* **10**, 248.
- Minervini, M. I., Swerdlow, S. H., and Nalesnik, M. A. (1999). Polymorphism and T-cell infiltration in posttransplant lymphoproliferative disorders. *Transplant Proc.* **31**, 1270.
- Montagnino, G. (2000). Malignancy. *In Principles and Practice of Renal Transplantation*,(Ponticelli, C. and Kahan, B. D., eds.), p.617, Martin Dunitz, London.
- Montagnino, G., Bencini, P. L., Tarantino, A., Caputo, R, and Ponticelli, C. (1994a). Clinical features and course of Kaposi's sarcoma in kidney transplant recipients:report of 13 cases. *Am.J.Nephrol.* **14**, 121.
- Montagnino, G., Bencini, P. L., Tarantino, A., Caputo, R., and Ponticelli, C. (1994b). Clinical features and course of Kaposi's sarcoma in kidney transplant patients: report of 13 cases. *Am J Nephrol.* **14**, 121.
- Montagnino, G., Lorca, E., Tarantino, A., *et al.* (1996). Cancer incidence in 854 kidney transplant recipients from a single institution: comparison with normal population and with patients under dialytic treatment. *Clin Transplant.* **10**, 461.
- Moore, K. W., Vieira, P., Fiorentino, D. F., Trounstein, M. L., Khan, T. A., and Mosmann, T. R. (1990). Homology of cytokine synthesis inhibitory factor (IL-10) to the Epstein- Barr virus gene BCRF1. *Science.* **248**, 1230.
- Moore, P. S. and Chang, Y. (1995). Detection of herpesvirus-like DNA sequences in Kaposi's sarcoma in patients with and those without HIV infection. *N.Engl.J.Med.* **332**, 1181.
- Moriwaki, S., Ray, S., Tarone, R. E., Kraemer, K. H., and Grossman, L. (1996). The effect of donor age on the processing of UV-damaged DNA by cultured human cells: reduced DNA repair capacity and increased DNA mutability. *Mutat.Res.* **364**, 117.
- Morrison, V. A., Dunn, D. L., Manivel, J. C., Gajl-Peczalska, K. J., and Peterson, B. A. (1994). Clinical characteristics of posttransplant lymphoproliferative disorders. *Am J Med.* **97**, 14.

- Nalesnik, M. A., Demetris, A. J., Fung, J., Randhawa, P., and Zeevi, A. Posttransplantation lymphoproliferative disorders. *Medscape*, 1-24. 2000. www.medscape.com/Medscape/transplantation/ClinicalMgmt/CM.v04/public/index-CM.v04.html. Accessed 4 October 2000.
- Nalesnik, M. A., Locker, J., Jaffe, H., *et al.* (1992). Experience with posttransplant lymphoproliferative disorder in solid organ recipients. *Clin Transplant*. **6**, 249.
- Nalesnik, M. A. and Starzl, T. E. (1994). Epstein-Barr virus, infectious mononucleosis, and posttransplant lymphoproliferative disorders. *Transplant Sci*. **4**, 61.
- Nalesnik, M. A. and Starzl, T. E. (1997). On the crossroad between tolerance and posttransplant lymphoma. *Curr Opin Organ Transplant*. **2**, 30.
- Nalesnik, M. A., Zeevi, A., Randhawa, P. S., *et al.* (1999). Cytokine mRNA profiles in Epstein-Barr virus-associated posttransplant lymphoproliferative disorders. *Clin Transplant*. **13**, 39.
- Nunez, G., Seto, M., Seremetis, S., *et al.* (1989). Growth- and tumor-promoting effects of deregulated BCL2 in human B- lymphoblastoid cells. *Proc.Natl.Acad.Sci.U.S.A.* **86**, 4589.
- Oberbauer, R., Banyai, S., Schmidt, A., Kornek, G., Scheithauer, W., and Mayer, G. (1996). Serum tumor markers after renal transplantation. *Transplantation*. **62**, 1506.
- Ohori, N. P., Whisnant, R. E., Nalesnik, M. A., and Swerdlow, S. H. (2001). Primary pleural effusion posttransplant lymphoproliferative disorder: Distinction from secondary involvement and effusion lymphoma. *Diagn.Cytopathol*. **25**, 50.
- Pageaux, G. P., Bonnardet, A., Picot, M. C., *et al.* (1998). Prevalence of monoclonal immunoglobulins after liver transplantation: relationship with posttransplant lymphoproliferative disorders. *Transplantation*. **65**, 397.
- Papadopoulos, E. B., Ladanyi, M., Emanuel, D., *et al.* (1994). Infusions of donor leukocytes to treat Epstein-Barr virus-associated lymphoproliferative disorders after allogeneic bone marrow transplantation. *N Engl J Med*. **330**, 1185.
- Parravicini, C., Olsen, S. J., Capra, M., *et al.* (1997). Risk of Kaposi's sarcoma-associated herpes virus transmission from donor allografts among Italian posttransplant Kaposi's sarcoma patients. *Blood*. **90**, 2826.
- Paya, C. V., Fung, J. J., Nalesnik, M. A., *et al.* (1999). Epstein-Barr virus-induced posttransplant lymphoproliferative disorders. ASTS/ASTP EBV-PTLD Task

- Force and The Mayo Clinic Organized International Consensus Development Meeting. *Transplantation*. **68**, 1517.
- Penn, I. (1983). Kaposi's sarcoma in immunosuppressed patients. *J Clin.Lab.Immunol.* **12**, 1.
- Penn, I. (1986). Cancers of the anogenital region in renal transplant recipients. Analysis of 65 cases. *Cancer*. **58**, 611.
- Penn, I. (1989). Why do immunosuppressed patients develop cancer? In CRC Critical reviews in oncogenesis, Vol 1,(Pimental, E., eds.), CRC Press Inc, Boca Raton.
- Penn, I. (1990). Cancers complicating organ transplantation. *N.Engl.J Med.* **323**, 1767.
- Penn, I. (1993). The effect of immunosuppression on pre-existing cancers. *Transplantation*. **55**, 742.
- Penn, I. (1994a). Depressed immunity and the development of cancer. *Cancer Detect.Prev.* **18**, 241.
- Penn, I. (1994b). Occurrence of cancers in immunosuppressed organ transplant recipients. *Clin.Transpl.* **99**.
- Penn, I. (1994c). The problem of cancer in organ transplant recipients: an overview. *Transplant.Sci.* **4**, 23.
- Penn, I. (1995a). Malignancy after immunosuppressive therapy: how can the risk be reduced? *Clin Immunother.* **9**, 207.
- Penn, I. (1995b). Primary kidney tumors before and after renal transplantation. *Transplantation*. **59**, 480.
- Penn, I. (1996a). Cancers in cyclosporine-treated vs azathioprine-treated patients. *Transplant Proc.* **28**, 876.
- Penn, I. (1996b). Epidemiology of cancer in transplant patients. In *Cancer in Transplantation. Prevention and Treatment*,(Touraine, J. L., Traeger, J., Bétuel, H., Dubernard, J. M., and Revill, J. P., eds.), p.3, Kluwer Academic, London.
- Penn, I. (1996c). Immunosuppressive agents, immunodeficiency states and malignancy. In *Principles of drug development in transplant and autoimmunity*, (Lieberman, R. and Muckerjee, A., eds.), p.93, RG Landes, Austin(Texas).
- Penn, I. (1996d). Posttransplant malignancies: clinical preventative measures. In *Cancers in Organ Transplant Recipients*,(Schmahl, D. and Penn, I., eds.), p.157, Spronger-Verslag, Berlin.

- Penn, I. (1997). Evaluation of transplant candidates with pre-existing malignancies. *Ann.Transplant.* **2**, 14.
- Penn, I. (1998a). De novo cancers in organ allograft recipients. *Curr Opin Organ Transplant.* **3**, 188.
- Penn, I. (1998b). The role of immunosuppression in lymphoma formation. *Springer Semin.Immunopathol.* **20**, 343.
- Penn, I. (1999a). Occurrence of cancers in immunosuppressed organ transplant recipients. In *Clinical Transplants 1998*,(Cecka, J. M. and Terasaki, P. I., eds.), p.147, UCLA Tissue Typing Laboratory, Los Angeles.
- Penn, I. (1999b). Posttransplant malignancies. *Transplant Proc.* **31**, 1260.
- Penn, I. (2000a). Cancers in renal transplant recipients. *Adv.Ren Replace.Ther.* **7**, 147.
- Penn, I. (2000b). Posttransplant malignancy: the role of immunosuppression [In Process Citation]. *Drug Saf.* **23**, 101.
- Penn, I., Hammond, W., Brettschneider, L., and Starzl, T. E. (1969). Malignant lymphomas in transplantation patients. *Transplant.Proc.* **1**, 106.
- Penn, I. and Porat, G. (1995). Central nervous system lymphomas in organ allograft recipients. *Transplantation.* **59**, 240.
- Pham, H., Lemoine, A., Salvucci, M., et al. (1998). Occurrence of gammopathies and lymphoproliferative disorders in liver transplant recipients randomized to tacrolimus (FK506)- or cyclosporine- based immunosuppression. *Liver Transpl.Surg.* **4**, 146.
- Posey, L. A., Kerschner, J. E., and Conley, S. F. (1999). Posttransplantation lymphoproliferative disease in children: otolaryngologic manifestations and management. *South.Med J.* **92**, 1079.
- Praghakaran, K., Wise, B., Chen, A., Schwarz, K., and Colombani, P. (1999). Rational management of posttransplant lymphoproliferative disorder in pediatric recipients. *J Pediatr.Surg.* **34**, 112.
- Qunibi, W., Akhtar, M., Sheth, K., et al. (1988). Kaposi's sarcoma: The most common tumor after renal transplantation in Saudi Arabia. *Am.J.Med.* **84**, 225 .
- Rogers, B. B., Sommerauer, J., Quan, A., et al . (1998). Epstein-Barr virus polymerase chain reaction and serology in pediatric posttransplant lymphoproliferative disorder: three-year experience. *Pediatr.Dev.Pathol.* **1**, 480.

- Rooney, C. M., Loftin, S. K., Holladay, M. S., Brenner, M. K., Krance, R. A., and Heslop, H. E. (1995a). Early identification of Epstein-Barr virus-associated post-transplantation lymphoproliferative disease. *Br J Haematol.* **89**, 98.
- Rooney, C. M., Smith, C. A., Ng, C. Y., *et al.* (1995b). Use of gene-modified virus-specific T lymphocytes to control Epstein-Barr-virus-related lymphoproliferation. *Lancet.* **345**, 9.
- Rowe, D. T., Qu, L., Reyes, J., *et al.* (1997). Use of quantitative competitive PCR to measure Epstein-Barr virus genome load in the peripheral blood of pediatric transplant patients with lymphoproliferative disorders. *J Clin Microbiol.* **35**, 1612.
- Saemundsen, A. K., Purtilo, D. T., Sakamoto, K., *et al.* (1981). Documentation of Epstein-Barr virus infection in immunodeficient patients with life-threatening lymphoproliferative diseases by Epstein-Barr virus complementary RNA/DNA and viral DNA/DNA hybridization. *Cancer Res.* **41**, 4237.
- Schalling, M., Ekman, M., Kaaya, E. E., Linde, A., and Biberfeld, P. (1995). A role for a new herpes virus (KSHV) in different forms of Kaposi's sarcoma. *Nat.Med.* **1**, 707.
- Sheil, A. G. (1994). Skin cancer in renal transplant recipients. *Transplant Sci.* **4**, 42.
- Sheil, A. G. (1999). Patterns of malignancies following renal transplantation. *Transplant.Proc.* **31**, 1263.
- Sheil, A. G., Disney, A. P., Mathew, T. H., and Amiss, N. (1993). De novo malignancy emerges as a major cause of morbidity and late failure in renal transplantation. *Transplant Proc.* **25**, 1383.
- Sillman, F., Stanek, A., Sedlis, A., *et al.* (1984). The relationship between human papillomavirus and lower genital intraepithelial neoplasia in immunosuppressed women. *Am J Obstet.Gynecol.* **150**, 300.
- Smets, F., Bodeus, M., Goubau, P., *et al.* (2000). Characteristics of Epstein-Barr virus primary infection in pediatric liver transplant recipients. *J Hepatol.* **32**, 100.
- Spector, B. D., Perry, G. S., III, and Kersey, J. H. (1978). Genetically determined immunodeficiency diseases (GDID) and malignancy: report from the immunodeficiency--cancer registry. *Clin Immunol.Immunopathol.* **11**, 12.
- Starzl, T. E., Nalesnik, M. A., Porter, K. A., *et al.* (1984). Reversibility of lymphomas and lymphoproliferative lesions developing under cyclosporin-steroid therapy. *Lancet.* **1**, 583.

- Starzl, T. E., Porter, K. A., Andres, G., *et al.* (1970). Long-term survival after renal transplantation in humans: (with special reference to histocompatibility matching, thymectomy, homograft glomerulonephritis, heterologous ALG, and recipient malignancy). *Ann.Surg.* **172**, 437.
- Stephanian, E., Gruber, S. A., Dunn, D. L., and Matas, A. J. (1991). Posttransplant lymphoproliferative disorders. *Transplant Rev.* **5**, 120.
- Swerdlow, S. H. (1992). Posttransplant lymphoproliferative disorders: a morphologic, phenotypic and genotypic spectrum of disease. *Histopathology.* **20**, 373.
- Swinnen, L. J. (1997). Treatment of organ transplant-related lymphoma. *Hematol.Oncol.Clin North Am.* **11**, 963.
- Swinnen, L. J., Costanzo-Nordin, M. R., Fisher, S. G., *et al* (1990). Increased incidence of lymphoproliferative disorder after immunosuppression with the monoclonal antibody OKT3 in cardiac- transplant recipients. *N Engl J Med.* **323**, 1723.
- Swinnen, L. J., Mullen, G. M., Carr, T. J., Costanzo, M. R., and Fisher, R. I. (1995). Aggressive treatment for postcardiac transplant lymphoproliferation. *Blood.* **86**, 3333.
- Tan, Shalaby J. and Tempero, M. (1995). Malignancies after liver transplantation: a comparative review. *Semin.Liver Dis.* **15**, 156.
- Tolkoff-Rubin, N. E. and Rubin, R. H. (1998). Viral infections in organ transplantation. *Transplant Proc.* **30**, 2060.
- Walker, R. C., Marshall, W. F., Strickler, J. G., *et al* (1995). Pretransplantation assessment of the risk of lymphoproliferative disorder. *Clin Infect.Dis.* **20**, 1346.
- Whiting, J. F. and Hanto, D. W. (1998). Cancer in recipients of organ allografts. *In* Kidney Transplant Rejection,(Racusen, L. C. and Solez, K., eds.), p.577, Marcel Dekker, New York.
- Wilkinson, A. H., Smith, J. L., Hunsicker, L. G., *et al.* (1989). Increased frequency of posttransplant lymphomas in patients treated with cyclosporine, azathioprine, and prednisone. *Transplantation.* **47**, 293.
- Wood, W. G., Steinhoff, J., and Kessler, A. C. (1993). Anomalous tumour marker concentrations in renal transplant patients. *Eur.J Clin Chem.Clin Biochem.* **31**, 75.

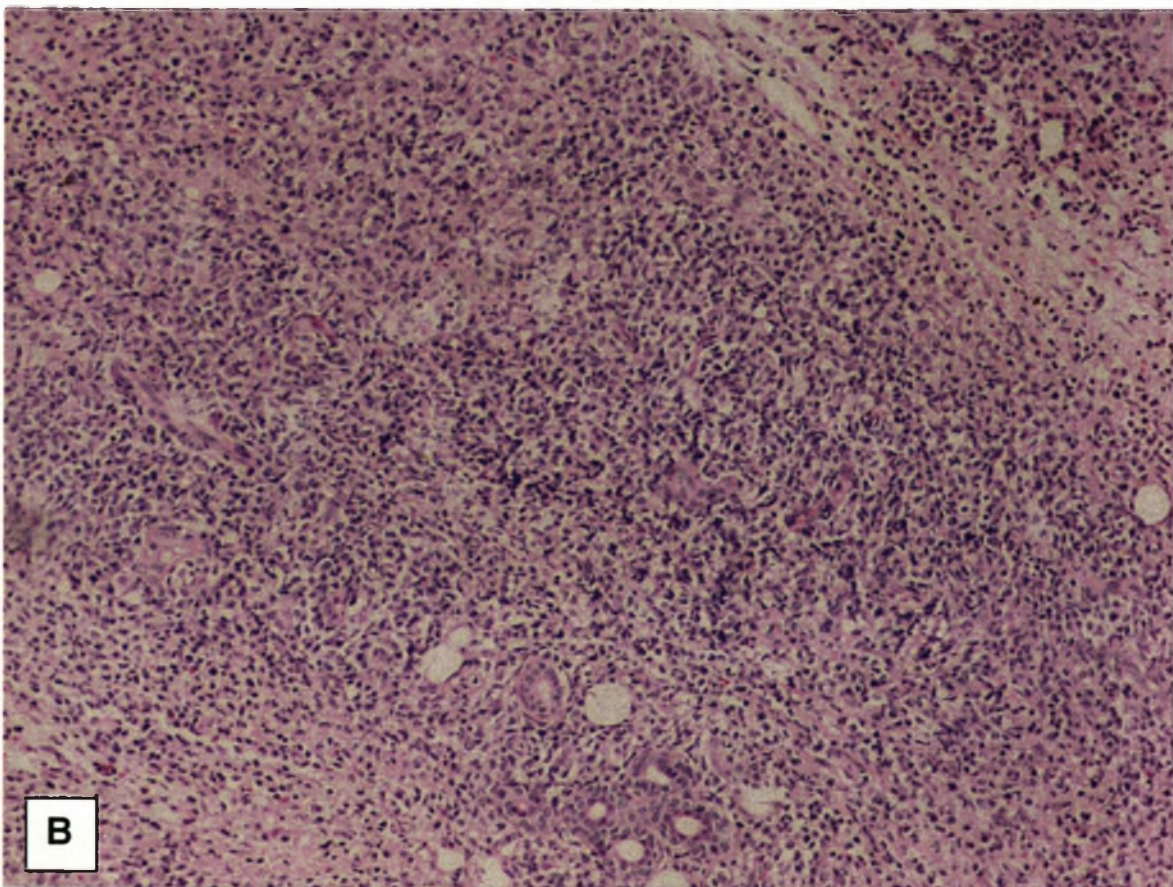
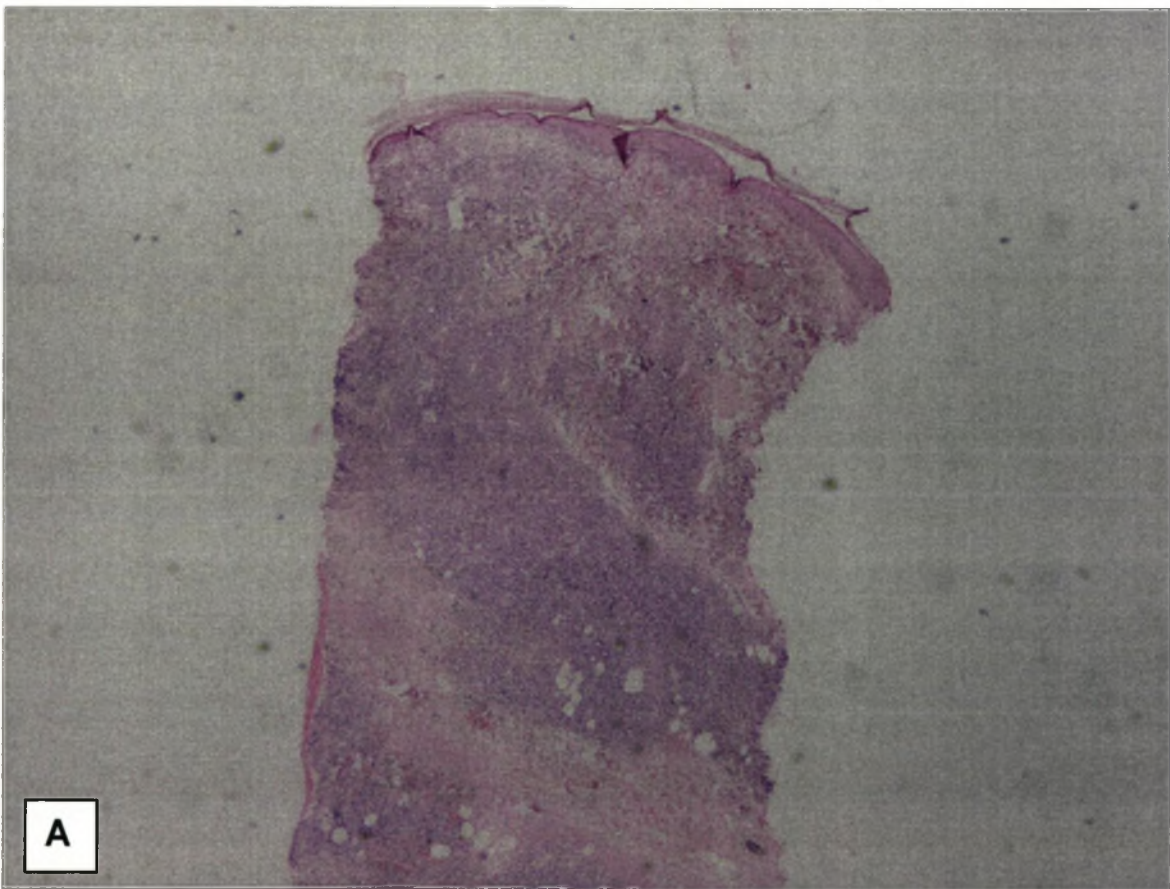
Yasumura, T., Oka, T., Nakane, Y., *et al* (1997). Long-term prognosis of renal transplant surviving for over 10 yr, and clinical, renal and rehabilitation features of 20-yr successes. *Clin. Transplant.* **11**, 387.

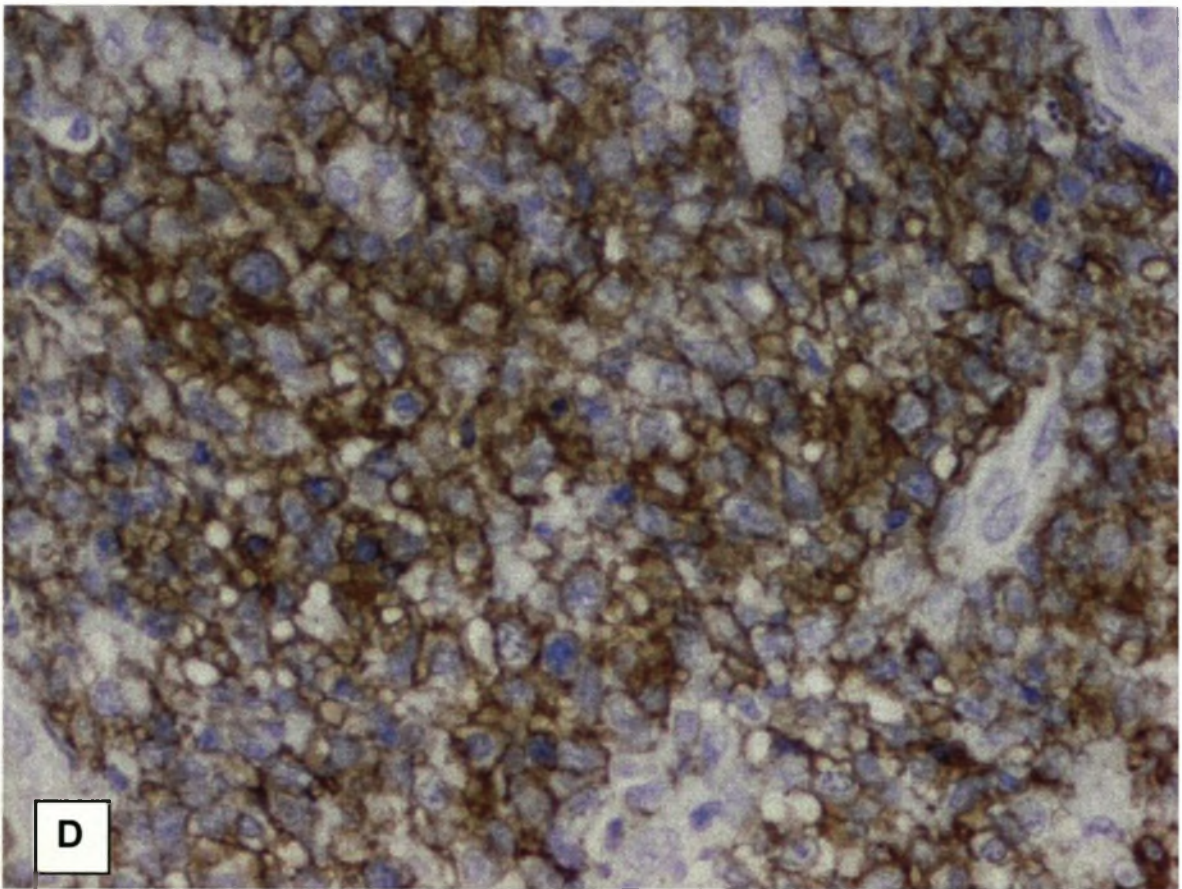
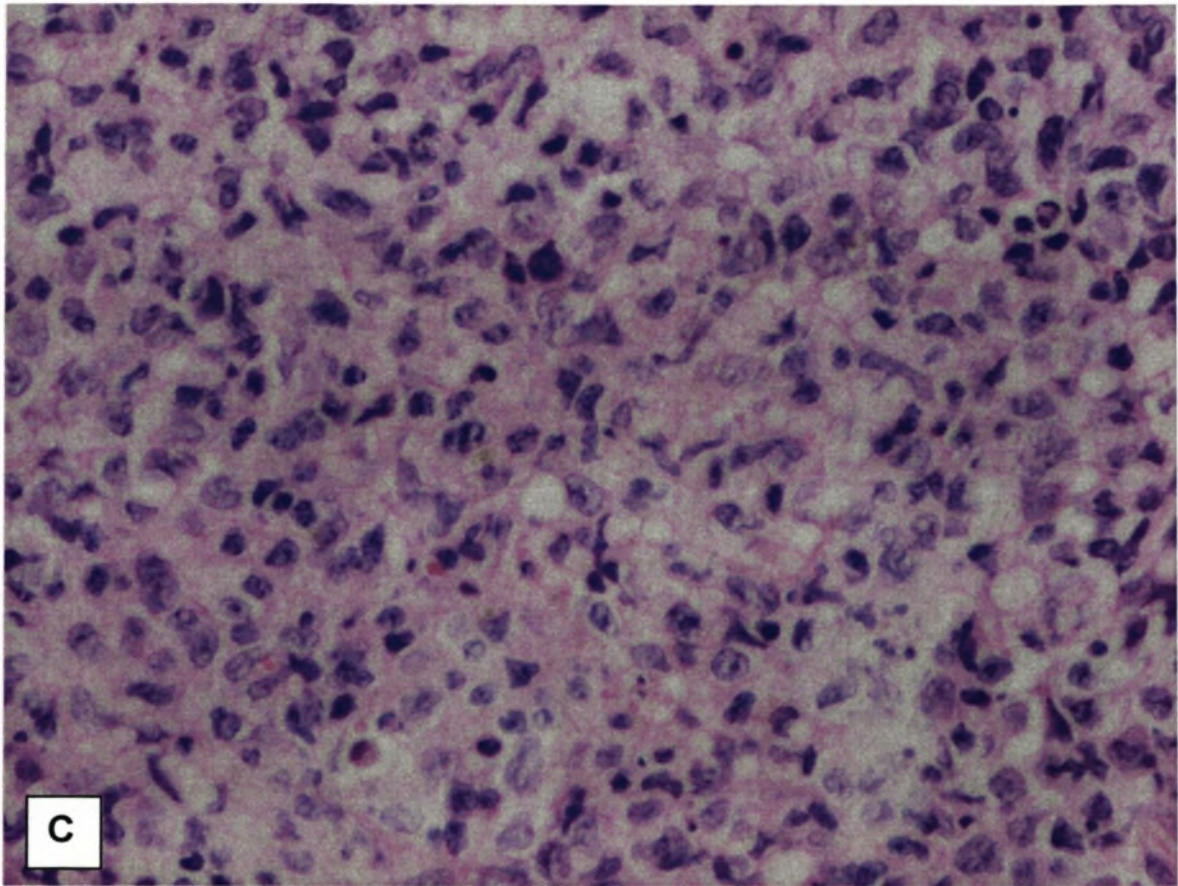
zur Hausen, H. (1991). Viruses in human cancers. *Science.* **254**, 1167.

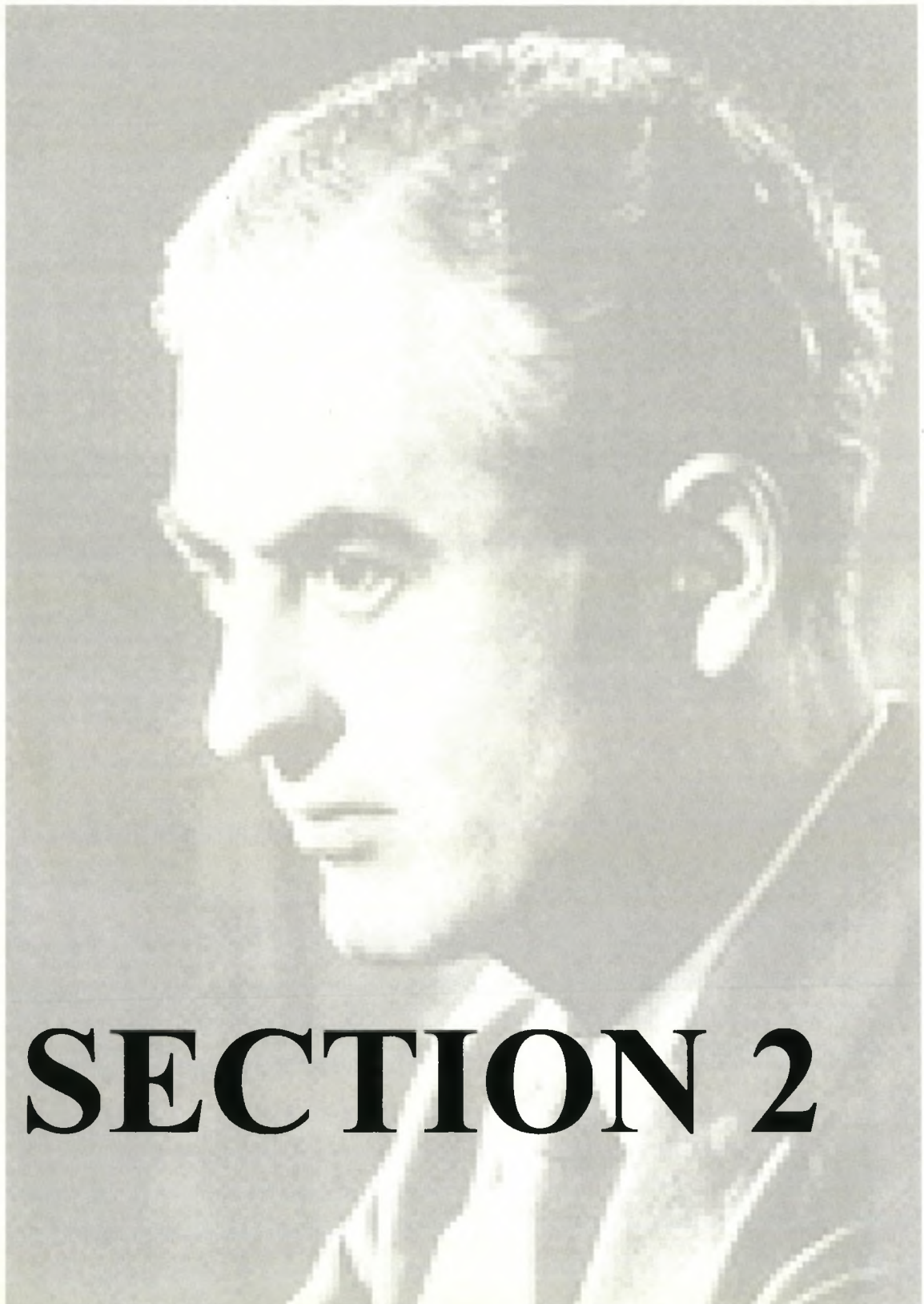
COLOUR PHOTOGRAPHIC PLATES

Fig. 13-1 Pathology of Posttransplant Lymphoproliferative Disease

A and B are low power images of a skin biopsy from one of our renal transplant patients showing an infiltrate of mononuclear cells. The high power image (C) clearly shows the presence of abnormal lymphocytes, which on immunohistochemistry (D) are B-lymphocytes. (*Sections courtesy of Dr W.B. Bates, Senior Consultant, Department of Anatomical Pathology, University of Stellenbosch*).







SECTION 2

Sir Peter Medawar (1880-1966)

Chapter 14

THE AETIOLOGY OF KAPOSI'S SARCOMA

Many aspects of Kaposi's sarcoma remain enigmatic and the aetiology of the disease is perhaps most so. Beside immunosuppression and genetic predisposition, epidemiological and clinical observation has long indicated that an infective agent could be associated with Kaposi's sarcoma.

EVIDENCE IN FAVOUR OF AN INFECTIVE AETIOLOGY FOR KAPOSI'S SARCOMA

1. An increased incidence of Kaposi's sarcoma in elderly patients who were immunosuppressed, had congestive cardiac failure or were recipients of blood transfusions (Bendsoe *et al.*, 1990).
2. An upsurge in the cases of classical Kaposi's sarcoma in women after 1950 but before the acquired immunodeficiency syndrome (AIDS) pandemic (Bendsoe *et al.*, 1990; Beral *et al.*, 1990).

3. The more malignant progression of Kaposi's sarcoma lesions in 15-20% of patients with "classical Kaposi's sarcoma" (Root-Bernstein,1990).
4. The increased incidence of Kaposi's sarcoma in renal allograft recipients, especially in developing countries, following the use of routine pre-transplant blood transfusions (Dictor *et al.*,1988;Penn,1979a).
5. Development of Kaposi's sarcoma after blood transfusions in patients who remained human immunodeficiency virus (HIV)-negative (Mannucci *et al.*,1986).
6. The higher incidence of Kaposi's sarcoma in HIV-negative gay men (Friedman-Kien *et al.*,1990;Goriano *et al.*,1991).
7. Geographic distribution of African Kaposi's sarcoma resembling Burkitt's lymphoma associated with Epstein-Barr virus (EBV) (Safai,1983;Safai *et al.*,1985) and corresponding with that of malaria (Schatz *et al.*,1997).
8. A higher incidence of epidemic Kaposi's sarcoma among sexually promiscuous homosexual and bisexual men as compared to the incidence in other groups at risk for HIV infection (Archibald *et al.*,1992;Beral *et al.*,1992;Lifson *et al.*,1990;Martin *et al.*,1993)
9. An observed decrease in epidemic Kaposi's sarcoma among HIV infected persons practising "safer sex" (Roth,1991).
10. The frequent association of a second primary malignancy in patients with iatrogenic immunosuppression (Safai,1983).
11. Women with AIDS are 4 times more likely to develop Kaposi's sarcoma if they acquired the HIV infection from a bisexual partner rather than from an intravenous drug abuser or a blood product recipient (Beral *et al.*,1990;Franceschi *et al.*,1995;Franceschi *et al.*,1998;Serraino *et al.*,1995).

The range of organisms that have been implicated in the pathogenesis of Kaposi's sarcoma is wide and include parasites and bacteria but viruses have been considered with the greatest suspicion. Alleged culprits have included onchocerciasis (Taylor *et al.*,1972), mycoplasma penetrans (Wang *et al.*,1993), hepatitis B virus (Siddiqui,1983), human T lymphotropic virus type-1 (HTLV-1) (Siegal *et al.*,1990), a retrovirus (Gyorkey *et al.*,1984;Rappersberger *et al.*,1990), human papilloma virus (Huang *et al.*,1992), avian leukosis virus (Dictor *et al.*,1988)

and human immunodeficiency virus (HIV) (Scinicariello *et al.*,1991). However it is cytomegalovirus (CMV) with or without a second virus that has been always considered the top contender (Andersen *et al.*,1991;Giraldo *et al.*,1975;Giraldo *et al.*,1989;Hashimoto *et al.*,1987;Qunibi *et al.*,1988;Siegal *et al.*,1990). However no causative role for any of these agents has ever been confirmed (Kempf *et al.*,1995;O'Leary *et al.*,1997).

In an in-depth review, Martin *et al.* (1993) stated that "... the occurrence of Kaposi's sarcoma in HIV-1 seronegative homosexual men suggested an infective "Kaposi's sarcoma agent" with a preferred transmission route (probably sexual) among homosexual men – as a cause independent of the HIV". The viral cause was

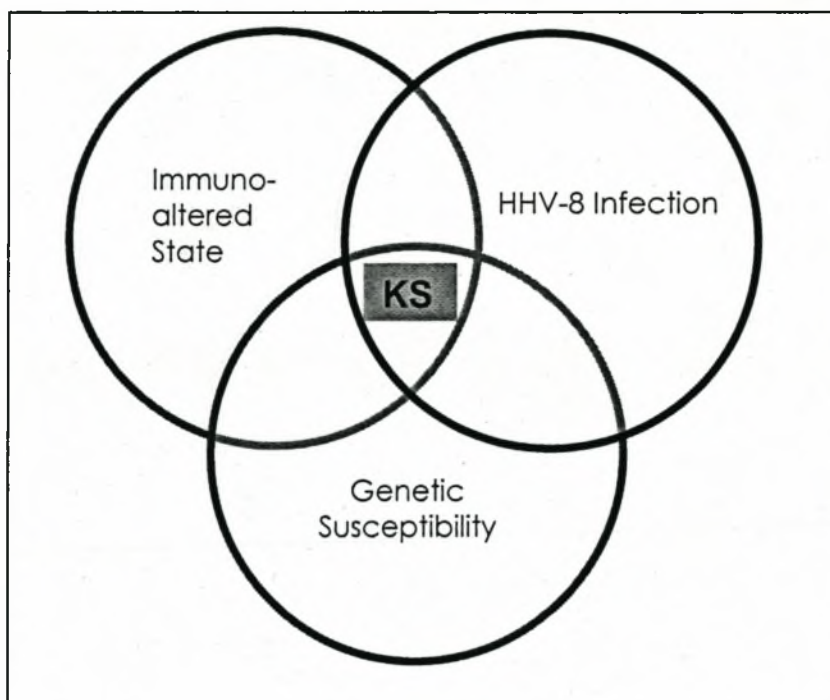


Fig. 14-1. *The aetiology of Kaposi's sarcoma.* Current evidence suggests that Kaposi's sarcoma occurs in the genetically susceptible, immunologically comprised host who is infected with the HHV-8 virus. A certain degree of immunoactivation is also an important factor.

advanced by the studies of Giraldo *et al.* (1972). This group established a number of cell-lines in continuous culture. Although considerable pleomorphism was found in culture, they were able to demonstrate herpesvirus particles in several of the cell-lines. Although the complete herpesvirus was not identified, the particles were demonstrated to have several antigens in common with EBV (Editorial,1973). Walters *et al.* (1984) also later demonstrated herpesvirus-type particles in Kaposi's sarcoma but were unaware of the importance of their findings. Although a Lancet editorial accurately predicted that the agent would be an oncogenic herpesvirus (Editorial,1973) it was to take another 2 decades for the putative herpesvirus to be identified (Chang *et al.*,1994). The development of Kaposi's sarcoma would appear to require the interaction of several host and environmental factors (Fig. 14-1).

IMMUNO-DYSFUNCTIONAL STATES

Immunodeficiency has been described to a greater or lesser degree in all forms of Kaposi's sarcoma (Editorial,1973). Whether it affects the growth of Kaposi's sarcoma directly by impairing immune surveillance or indirectly by allowing the proliferation of the oncogenic virus by as yet unknown mechanisms remains uncertain (Harwood *et al.*,1979a;Qunibi *et al.*,1988;Roth,1991). Kaposi's sarcoma however progresses irrespective of the degree of immunosuppression (Spornraft *et al.*,1988). Paradoxically, a certain degree of immune activation seems to be essential for the development of Kaposi's sarcoma (Mitsuyasu *et al.*,1986; Safai *et al.*,1992; Ziegler,1990). Older individuals with the classic and endemic forms of Kaposi's sarcoma often present with signs of immunoactivation as evidenced by increased inflammatory cytokine production and expansion of CD8⁺ T cells (Fagiolo *et al.*,1993;Kestens *et al.*,1985;Rizzardini *et al.*,1996). In AIDS-associated Kaposi's sarcoma the growth of the lesion is dramatically increased during times of opportunistic infections (Miles,1994). Although major increases in the expression of certain cytokines such as interleukin - 1 (IL-1) and tumour necrosis factor (TNF)- α occur during opportunistic infections, whether this accounts for the accelerated growth of the AIDS-Kaposi's sarcoma lesion has not been clearly demonstrated (Miles,1994).

The concern for solid organ transplant recipients is the observation that steroids have a direct stimulatory effect on the proliferation of AIDS - Kaposi's sarcoma cells that are rich in glucocorticoid receptors upregulated by the steroid treatment (Gill *et al.*,1989;Schulhafer *et al.*,1987;Trattner *et al.*,1993). In addition, steroids also acts synergistically with oncostatin M, a potent Kaposi's sarcoma cell growth factor to promote the proliferation of the Kaposi's sarcoma cells (Miles *et al.*,1992;Nair *et al.*,1992). The current evidence suggests that immunodeficiency may be responsible for tumour aggressiveness while immunoactivation, mainly the secretion of cytokines, play a major role in the initiation and maintenance of the disease (Ensoli *et al.*,1998a). Immunological aspects of Kaposi's sarcoma are discussed further in Chapter 15 of this thesis.

GENETIC SUSCEPTIBILITY

The geographic clustering of cases (Central Africa in endemic Kaposi's sarcoma, developing countries in iatrogenic Kaposi's sarcoma), ethnicity, increased frequency of HLA-DR5 and HLA-DW 19 in classical Kaposi's sarcoma, HLA-A2, HLA-A19, HLA-A23, HLA-B49, HLA-B18, HLA-DR5 and decreased frequency of HLA-DR3 and HLA-B8 in iatrogenic Kaposi's sarcoma (Brunson *et al.*,1990) suggest a genetic predisposition to Kaposi's sarcoma (Bayley,1984;Garcia *et al.*,1989;Qunibi *et al.*,1988). This is further supported to some extent by the gender ratios with marked male predominance in classical Kaposi's sarcoma and the association with lymphoma (Moertel,1966). Clear genotype patterns are, however, not seen in endemic Kaposi's sarcoma and familial cases of Kaposi's sarcoma are extremely unusual (Melbye *et al.*,1987;Myskowski *et al.*,1997). Some (Friedman-Kien *et al.*,1982;Goedert *et al.*,1987) but not all (Rubinstein *et al.*,1983) studies of HIV - associated Kaposi's sarcoma have reported an association with HLA-DR 5. A few studies (Klein *et al.*,1994;Mann *et al.*,1988) including one in homosexual males (Klein *et al.*,1994) have reported an association between HLA-DR 1 and Kaposi's sarcoma. The evidence therefore seems to suggest that genetic factors and specific combinations of HLA alleles may influence the risk of Kaposi's sarcoma (Strathdee *et al.*,1996).

VIRAL AETIOLOGY

Discovery of human herpesvirus 8 (HHV-8)

The understanding of the aetiopathogenesis of Kaposi's sarcoma was greatly advanced with the elegant description of HHV-8 by Chang *et al.* (1994) using a novel technique, "representational differential analysis" (RDA) (Lisitsyn *et al.*, 1993). Chang and his colleagues identified two polymorphic DNA sequences by comparing AIDS – Kaposi's sarcoma DNA to DNA extracted from clinically normal tissue from the same patient. Of 27 AIDS-Kaposi's sarcoma lesions examined, 93% contained the Kaposi's sarcoma DNA fragment KS330₂₃₃. Examination of non-Kaposi's sarcoma tissues from four additional AIDS–Kaposi's sarcoma patients demonstrated variable detection of DNA sequences consistent with dissemination of an infectious agent. All control specimens, including samples from AIDS patients without Kaposi's sarcoma were negative (Chang *et al.*, 1994). Extended sequence analysis confirms that these sequences belong to a new human herpesvirus and has been designated HHV-8 or Kaposi's sarcoma-associated herpesvirus (KSHV) (Moore *et al.*, 1996a).

Diseases associated with HHV-8

The virus has now been demonstrated in all epidemiological forms of Kaposi's sarcoma (Boshoff *et al.*, 1995a; Boshoff *et al.*, 1997; Buonaguro *et al.*, 1996; Engelbrecht *et al.*, 1997; Huang *et al.*, 1995b; Noel *et al.*, 1996; Weiss *et al.*, 1998). HHV-8 is also consistently associated with primary effusion B-cell lymphoma (Cesarman *et al.*, 1995a; Cesarman *et al.*, 1995b; Renne *et al.*, 1996a) and multicentric Castleman's disease (MCD), both AIDS-related lymphoproliferative diseases (Table 14-1) (Soulier *et al.*, 1995). There is a strong association between MCD and Kaposi's sarcoma with 75% of patients with MCD subsequently developing Kaposi's sarcoma (O'Leary *et al.*, 1997). Primary effusion B-cell lymphomas lack *c-myc* gene rearrangements and usually but not always contain EBV as well as HHV-8 (Weiss, 1996), a finding supported by Nador *et al.* (Nador *et al.*, 1996). Rady *et al.* (1995) have also reported the presence of HHV-8 in other non-Kaposi's sarcoma lesions in renal transplant recipients. However, these findings could not be confirmed by other groups who consistently failed to demonstrate herpes-like

Table 14-1. Detection of HHV-8 in Kaposi's sarcoma, lymphoproliferative diseases and peripheral blood mononuclear cells.

Patient Group	HHV-8 Detected	Percentage
AIDS-Kaposi's sarcoma	125/128	98
Classical Kaposi's sarcoma	49/52	94
Endemic Kaposi's sarcoma	24/27	89
Iatrogenic Kaposi's sarcoma	9/9	100
HIV-negative homosexual	5/5	100
Uninvolved skin, Kaposi's sarcoma patient	21/57	37
Control:HIV negative	3/95	3
PEL: AIDS	23/26	89
MCD: AIDS	14/14	100
Lymphoma: HIV positive	9/110	8
Lymphoma: HIV negative	18/365	5
PBMC: Kaposi's sarcoma	37/70	53
PBMC: no Kaposi's sarcoma, HIV positive	11/173	6
PBMC: no Kaposi's sarcoma, HIV negative	0/211	0

PEL; Primary effusion B-cell lymphoma; MCD; multicentric Castleman's disease; %; Peripheral blood mononuclear cells. Pooled data from Ambroziak *et al.*, 1995; Boshoff *et al.*, 1995a; Cesarman *et al.*, 1995a; Chang *et al.*, 1994; Chatlynne *et al.*, 1998; Collandre *et al.*, 1995; Dupin *et al.*, 1995; Huang *et al.*, 1995a; Lebbe *et al.*, 1995; Moore *et al.*, 1995; Schalling *et al.*, 1995; Su *et al.*, 1995.

sequences in transplant patients without Kaposi's sarcoma (Boshoff *et al.*, 1995a; Boshoff *et al.*, 1996; Noel *et al.*, 1996).

Oncogenicity of HHV-8

Having demonstrated the presence of HHV-8 in Kaposi's sarcoma tissue, the question of whether the virus is the cause of the lesions or whether it is a "passenger" remained unanswered (Roizman,1995; Schulz *et al.*,1995; Gallo,1995). In AIDS and organ transplantation the presence of HHV-8 may merely reflect a decreased capacity of the host to destroy cells harbouring latent HHV-8 because of immunosuppression (Roizman,1995). It could also represent an opportunistic pathogen that preferentially infects immuno-incompetent patients at risk for Kaposi's sarcoma (Ganem,1995). The absence of HHV-8 from cell lines derived from these cancers (Ambroziak *et al.*,1995) has also called into question the role of this virus in this malignancy (Levy,1997). However, parallels may be drawn between HHV-8, and its cousins Epstein-Barr virus (EBV) and herpesvirus saimiri that are also γ -herpesviridae. EBV can transform B-lymphocytes and herpesvirus saimiri T-lymphocytes to produce lymphoproliferative lesions in the appropriate host (Albrecht *et al.*,1992). HHV-8 is similarly found in B cells and is present in large nuclear episomes (Cesarman *et al.*,1995b). EBV is unable to induce malignant transformation on its own and rearrangement of the *c-myc* oncogene is invariably present. Concomitant malaria is thought to expand the polyclonal B-cell population increasing the number of number of cells at risk for transformation leading to a high incidence of Burkitt's lymphoma. It is interesting that the geographical distribution of endemic Kaposi's sarcoma and Burkitt's lymphoma are similar and parallels that of malaria (Fife *et al.*,1996).

HHV-8: Pathogen or passenger?

Whitby *et al.* (1995) addressed this problem by establishing the presence of HHV-8 DNA by nested PCR in the peripheral blood mononuclear cells (PBMC) of 24 out of 46 (52%) of HIV-positive Kaposi's sarcoma patients. This, compared to only 11 out of 143 (8%) of HIV-infected patients without Kaposi's sarcoma. The latter group was followed up for a median of 30 months; 11 (55%) of patients with detectable HHV-8 DNA who did not have Kaposi's sarcoma subsequently developed the disease, as compared with only 12 out of 132 (9%) of patients who initially tested HHV-8 negative. Moore *et al.* (1996b) obtained similar results comparing AIDS – Kaposi's patients with two control groups – a high risk control group of homo/bisexual males

with AIDS and a low risk group of HIV-infected haemophiliac patients. These studies suggested that the presence of HHV-8 in peripheral blood predicted the development of Kaposi's sarcoma. Whitby *et al.* (1995) also report that the appearance of overt Kaposi's sarcoma was delayed with 50% of the patients being Kaposi's sarcoma-free at 3.5 years. This suggests that factors and co-factors other than immunosuppression are required for the promotion of the development of Kaposi's sarcoma lesions. The easier detection of HHV-8 in patients with low CD4⁺ cell counts suggest that its replication is under immunological control (Whitby *et al.*, 1995).

Miller *et al.* (1996) using immunoblot and immunofluorescence assays detected antibodies to the p40 antigen of HHV-8 in 67% of HIV-positive patients with Kaposi's sarcoma compared with 13% of HIV-positive patients without Kaposi's sarcoma. Gao *et al.* (1996a) using immunoblot assays for two latent nuclear antigens found that 80% of patients with Kaposi's sarcoma expressed anti-HHV-8 antibodies compared with 18% of homosexual men without Kaposi's sarcoma. They also found that patients seroconverted 33 months before the onset of clinical Kaposi's sarcoma. These findings support those of Whitby and his colleagues in suggesting an important role for HHV-8 infection in the development of Kaposi's sarcoma. Gao *et al.* (1996a) also report that the 20% of patients with Kaposi's sarcoma who had no antibodies to HHV-8 had significantly higher CD4⁺ cell counts than the seropositive patients and had developed Kaposi's sarcoma more rapidly than the seropositive patients. They postulated that the failure to develop protective antibodies was responsible for the higher CD4⁺ cell counts and more aggressive disease. Miller *et al.* (1996) also report that patients with AIDS-related Kaposi's sarcoma had lower CD4⁺ cell counts whereas homosexual patients with HIV-negative Kaposi's sarcoma and patients with classical Kaposi's sarcoma had normal CD4⁺ cell counts. The findings of Gao's and Miller's groups support those of Whitby's in implicating an important role for the immune system in the development of Kaposi's sarcoma.

KAPOSI'S SARCOMA IN AIDS PATIENTS

AIDS-Kaposi's sarcoma has been the best studied form of Kaposi's sarcoma and it is likely that all forms of Kaposi's sarcoma may be initiated by signals inducing the

activation and growth of a particular type of mesenchymal cell that expresses autocrine, paracrine and growth properties. An understanding of this form of Kaposi's sarcoma may provide valuable clues to the pathogenesis of posttransplant Kaposi's sarcoma. AIDS has now reached pandemic proportions but it is interesting to recall that the original description of the disease were of three observations of an aggressive form of Kaposi's sarcoma in homosexual men (Borkovic *et al.*,1981;Gottlieb *et al.*,1981;Hymes *et al.*,1981).

Although the incidence of Kaposi's sarcoma as the presenting manifestation of AIDS has diminished, its prevalence has not (Northfelt,1994). In addition, with the availability of effective anti-retroviral agents and better control of opportunistic infections, AIDS patients are now surviving long enough to succumb to Kaposi's sarcoma (Schwartz,1996). Epidemiological evidence strongly suggests that Kaposi's sarcoma occurring in AIDS patients is caused by an agent other than HIV (Martin *et al.*,1993). In certain cohorts of homosexual men with AIDS, the lifetime risk of Kaposi's sarcoma approaches 50% (Katz *et al.*,1994) whereas only 1% of haemophiliacs and 3% of blood product transfusion recipients with AIDS developed Kaposi's sarcoma (Beral *et al.*,1990). Children who have acquired AIDS vertically from infected mothers have even lower risks of Kaposi's sarcoma (Ganem,1995). The indications are therefore that the agent responsible for Kaposi's sarcoma is sexually transmitted (Beral *et al.*,1990). AIDS patients have a 20 000 fold increased risk of developing Kaposi's sarcoma (Beral *et al.*,1990) but the incidence of Kaposi's sarcoma is decreasing in the USA (Beral *et al.*,1990) with a 4-fold decline among a cohort of homosexual men between 1983 and 1990 (Katz *et al.*,1994). This could represent a genuine decrease due to "safer sex" practices resulting in reduction in the transmission rate of the Kaposi's sarcoma infective agent although under-reporting cannot be excluded.

Clinically, Kaposi's sarcoma developing in AIDS patients follows a more aggressive course than other forms of Kaposi's sarcoma (Ensoli *et al.*,1991). The disease is more likely to be complicated by visceral and lymph node involvement (Friedman-Kien,1981;Gottlieb *et al.*,1982) and has more extensive cutaneous distribution with lesions on the trunk, neck and arms compared with the predominant distribution on

the lower limbs in the other forms of the disease. HIV-associated Kaposi's sarcoma is also more resistant to treatment (Buchbinder *et al.*,1992; Friedman-Kien *et al.*,1982). The suggestion therefore is that additional factors may be operative in AIDS patients that do not occur in other Kaposi's sarcoma patients.

HIV-Tat: A progression factor in AIDS-Kaposi's sarcoma

The aggressive course of AIDS-Kaposi's sarcoma has been ascribed at least in part to the HIV-*tat* gene. The product of this gene is a small intranuclear polypeptide that activates viral gene expression early after infection via interaction with structures on viral RNA (Arya *et al.*,1985;Chang *et al.*,1995;Ensoli *et al.*,1993). Small amounts of Tat are released from infected cells (Ensoli *et al.*,1993). At high extracellular concentration, small amounts of Tat can enter cells where it induces the nuclei to undergo transactivation. At lower concentrations, the Tat binds to AIDS-Kaposi's sarcoma cells, and promotes cell growth (Buonaguro *et al.*,1992) and adhesion to solid surfaces (Barillari *et al.*,1993). AIDS - Kaposi's sarcoma cell proliferation induced by the supernatant of HIV culture media was specifically blocked by anti-Tat antibodies (Ensoli *et al.*,1990). The cell culture supernatant is rich in inflammatory cytokines that both induce the expression of $\alpha 5\beta 1$ and $\alpha v\beta 3$ integrins that function as receptors for Tat, and induce basic fibroblast growth factor (bFGF) expression that in turn induces the same integrins (Barillari *et al.*,1993;Barillari *et al.*,1999b;Barillari *et al.*,1999a;Stromblad *et al.*,1996). *In vitro* studies have shown that Tat acts synergistically with bFGF to promote the formation of angiogenic lesions in nude mice following subcutaneous inoculation with AIDS – Kaposi's cells (Salahuddin *et al.*,1988; Ensoli *et al.*,1990; Ensoli *et al.*, 1994). Supporting the observation is that some transgenic mice expressing *tat* develop proliferative multifocal dermal lesions containing spindle-shaped cells (Vogel *et al.*,1988). bFGF would appear to be essential for the development of Kaposi's sarcoma lesions and Tat, in turn, enhances bFGF activity (Fife *et al.*,1996). Extracellular Tat is detectable in AIDS-Kaposi's sarcoma lesions (Ensoli *et al.*,1994a). In addition, endothelial and spindle cells of Kaposi's sarcoma lesions express both bFGF as well as $\alpha 5\beta 1$ and $\alpha v\beta 3$ Tat receptors to which Tat has been shown to be bound (Ensoli *et al.*,1994a). The suggestion is therefore that the mechanisms described *in vitro* are operative *in vivo* as well.

More recent observations have established that Tat protein in addition to promoting spindle cell growth also promotes AIDS-Kaposi's sarcoma and normal vascular cells to migrate, to degrade the basement membrane and to stimulate endothelial cell morphogenesis (Albini *et al.*, 1995b; Albini *et al.*, 1995a; Barillari *et al.*, 1993). Tat has also been shown to promote adhesion of monocytes-macrophages to damaged vasculature increasing their migration and invasion into tissues (Lafrenie *et al.*, 1996). Another mechanism whereby Tat may influence Kaposi's sarcoma development is through activation of cellular gene expression, especially cytokine genes involved in the pathogenesis of Kaposi's sarcoma (Chang *et al.*, 1995). Cytokines induced include $\text{TNF}\alpha$, $\text{TNF}\beta$ (Buonaguro *et al.*, 1994) and IL-6 (Scala *et al.*, 1994). However, much higher concentrations of Tat are required for the activation of cytokines than for integrins (Chang *et al.*, 1997; Chang *et al.*, 1995; Ensoli *et al.*, 1993). Finally, Tat has also been shown to increase HHV-8 viral load (Harrington, Jr. *et al.*, 1997) and to activate the expression of oncogene bcl-2 (Zauli *et al.*, 1995). The evidence presented therefore supports the hypothesis that Tat may represent the factor in AIDS-Kaposi's sarcoma which accounts for the frequency and aggressiveness of Kaposi's sarcoma in AIDS patients compared to the milder forms of Kaposi's sarcoma in which only bFBF is present (Ensoli *et al.*, 1994a).

Cytokines (Table 14-2)

The study of AIDS-Kaposi's sarcoma was severely hampered by the inability to maintain Kaposi's sarcoma cells in culture until the discovery by Nakamura *et al.* (1998) that supernatant from retrovirus-infected cell lines could ensure the long-term maintenance of Kaposi's sarcoma cell cultures. They found that these cells produced a variety of factors that induced their own growth, and the growth of normal and other cell types (Ensoli *et al.*, 1989; Salahuddin *et al.*, 1988a). In addition, when the chorioallantoic membrane (CAM) of 9-day-old chicken eggs was exposed to AIDS-Kaposi's sarcoma cells extensive vascularisation was observed in 3 days. In a landmark experiment, it was established that when Kaposi's sarcoma-AIDS cells were injected subcutaneously into the lower back of nude mice, this resulted in an angiogenic response resembling Kaposi's sarcoma (Fig. 14-2) (Salahuddin *et al.*, 1988b). These observations therefore indicate that AIDS-Kaposi's sarcoma cells release factors capable of inducing lesions resembling Kaposi's sarcoma in humans.

Table 14-2. Contribution of identified cytokines to biologic activities released or induced by AIDS-Kaposi's sarcoma cells.

Biologic Activities	Response/Cytokine Expression
A. Effect of Inflammatory cytokines on normal endothelial cells	
Vessel activation	Expression of ELAM-1, ICAM-1, V-CAM-1, HLA-DR, CD40; upregulation of $\alpha 5\beta 1$ and $\alpha v\beta 3$ integrins (receptors for Tat)
Acquisition of Kaposi's sarcoma spindle-cell phenotype	Spindle morphology, expression of the above markers, downregulation of factor VIII-related antigen, production of bFGF and other activating factors
Induction of Kaposi's sarcoma-like lesions	Angiogenic after inoculation in nude mice
Induction of the response to HIV-1 Tat protein	Upregulation of Tat receptors; response to the adhesive, mitogenic, and invasive effects of Tat and <i>in vivo</i> angiogenesis
B. Effect of Inflammatory cytokines on cells derived from Kaposi's sarcoma lesions	
Kaposi's sarcoma cells with endothelial cell markers	Long-term growth, detection of markers of vessel activation, downregulation of factor VIII-related antigen, production of activating factor, expression of MCP-1
Kaposi's sarcoma cells with macrophagic markers	Support of their growth, increased vascular adhesion, MCP-1 production
Tumour infiltrating lymphocytes	Survival and phenotype maintenance in T-Cell derived media cultured lesions
C. <i>In vivo</i> effects of inflammatory cytokines	
Angiogenic and Kaposi's sarcoma-forming activity	Induction of hyperplastic Kaposi's sarcoma-like lesions in nude mice
D. Role of inflammatory cytokines in Kaposi's sarcoma progression	
Activation of Tat transcription and production, upregulation of Tat receptors on endothelial cells	HIV-1 Tat (target)
Increase of viral replication and load	HHV-8 (target)

Modified from Ensoli *et al.* (1998a)

Ensoli and her group (1989) studied specific cytokines and growth factors extensively using messenger ribonucleic acid (mRNA) expression of AIDS-Kaposi's sarcoma cells and comparing expression of cytokines and growth factors capable of inducing similar biological effects. AIDS-Kaposi's sarcoma cells constitutively

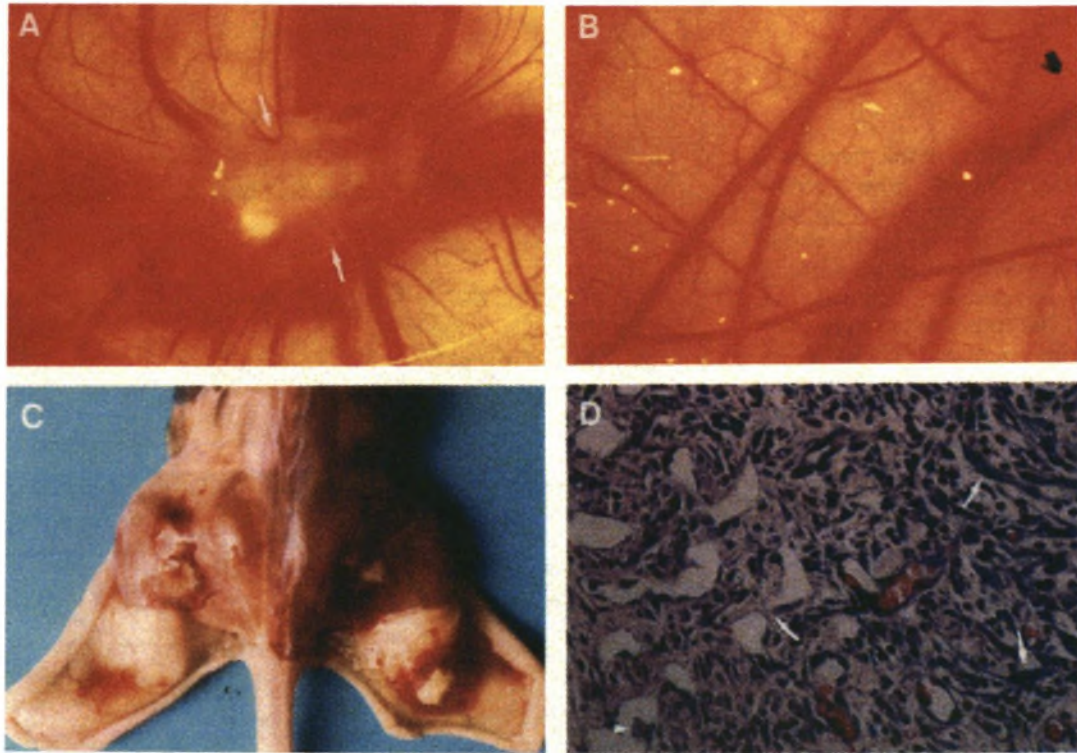


Fig. 14-2. (A) Induction of angiogenic response in a chorioallantoic membrane fertilized for 12 days by AIDS-Kaposi's sarcoma cells. Newly formed vessels are indicated by the arrows. (B) In contrast the control CAM shows no neovascularisation. (C) Nude mice injected with AIDS-Kaposi's sarcoma cells show angiogenesis at the site of injection of the live AIDS-Kaposi's sarcoma cells (right) with the absence of reaction where fixed cells (left) were injected. (D) The histology of the subcutaneous tissue that was injected with AIDS-Kaposi's sarcoma cells reveals marked angiogenic response after 5 days. The lesions show numerous small slits and vessels some with blood, and spindle cells. The lesion closely resembles the changes seen in Kaposi's sarcoma. From Salahuddin et al. (1988a).

expressed very high levels of m-RNA for bFGF, vascular endothelial growth factor (VEGF) and IL1- β ; moderate amounts of mRNA for granulocyte-monocyte-colony stimulating factor (GM-CSF), transforming growth factor (TGF)- β , platelet derived growth factor (PDGF) -B and oncostatin-M. The levels of mRNA for aFGF and IL-1 α were low (Ensoli *et al.*,1989). In addition, mRNA for PDGF-A and IL-6 were also expressed (Ensoli *et al.*,1991).

Preliminary data have suggested that TGF- β , IFN- γ , oncostatin-M, IL-1 β , among others, all stimulate growth of Kaposi's sarcoma cells by induction of IL-6 (Miles,1994). It has been suggested that IL-6 may be the key cytokine modulating the growth of Kaposi's sarcoma-derived cells (Miles,1994). However other reports have failed to corroborate its proliferative effect and it has been demonstrated that the Kaposi's sarcoma cells with endothelial markers lack IL-6 receptors both *in vivo* and *in vitro* (Murakami-Mori *et al.*,1995;Sturzl *et al.*,1995). In addition IL-6 fails to induce angiogenesis or endothelial cell growth in nude mice (Mantovani *et al.*,1997). Among the angiogenic factors present in Kaposi's sarcoma bFGF plays a major role in the development of the lesion. Ensoli and her group have shown in some elegant studies that the inoculation of bFGF in nude mice (Fig. 14-2) also results in formation of Kaposi's sarcoma-type lesions (Ensoli *et al.*,1994a;Ensoli *et al.*,1994b). Furthermore, they performed inhibition studies with specific neutralising antibodies directed against bFGF mRNA and proved that bFGF was required for formation of Kaposi's sarcoma-type lesions induced by inoculation of Kaposi's sarcoma with endothelial cells markers in nude mice (Ensoli *et al.*,1994b). IL-1 is produced by several Kaposi's sarcoma cell types and induces autocrine proliferation of Kaposi's sarcoma endothelial cells. Its actions are mediated by induction of bFGF which appears to be the final mediator of Kaposi's sarcoma cell growth (Ensoli *et al.*,1994b;Samaniego *et al.*,1995;Samaniego *et al.*,1997). IL-1 also acts synergistically with TNF and IFN- γ to induce endothelial cell proliferation and spindle cell formation (Fiorelli *et al.*,21995;Mantovani *et al.*,1997;Memar *et al.*,1995). Current data indicate that the interplay between cytokines and growth factors is a ". . . key event in the neoangiogenesis characteristic of (Kaposi's sarcoma) and may

trigger a cascade of events leading to the appearance and maintenance of the disease" (Ensoli *et al.*,1998a).

SUMMARY AND HYPOTHESIS

The aetiology of Kaposi's sarcoma has been disputed but there is growing evidence that an infectious agent spreads the disease. Oncogenic viruses have been implicated in the pathogenesis of Kaposi's sarcoma. The herpes group of viruses, especially cytomegalovirus (CMV) have long been the main suspects. The involvement of the herpesvirus group in the pathogenesis of Kaposi's sarcoma was confirmed by the description in Kaposi's sarcoma tissue of new herpes-like DNA sequences. These sequences were found to be highly homologous to capsid and tegumen protein coding genes of herpesvirus saimiri and Epstein-Barr virus. The exact role of the newly discovered HHV-8 in the development of Kaposi's sarcoma remains uncertain but there is now compelling evidence to suggest that HHV-8 is important in the pathogenesis of Kaposi's sarcoma. The unique viral DNA sequence detected in all forms of Kaposi's sarcoma which bears homology to known oncogenic herpesviruses (Bencini *et al.*,1993;Boshoff *et al.*,1995a;Huang *et al.*,1995b;Moore *et al.*,1996a) argues strongly in favour of an aetiological role for the virus as does development of antibodies to HHV-8 related antigens before the appearance of clinical features of Kaposi's sarcoma (Levy *et al.*,1983;Whitby *et al.*,1995). In AIDS-Kaposi's sarcoma Tat and cytokines/integrins contribute to the aggressiveness of the disease. Various studies evaluated the incidence of HHV-8 DNA sequences in Kaposi's sarcoma, non-Kaposi's sarcoma tumours and normal tissue from immunosuppressed patients, but none included skin biopsies from the same anatomical site after remission of the skin lesions.

We postulated that if posttransplant Kaposi's sarcoma is caused by HHV-8 infection:

1. The viral infection should be present in all Kaposi's sarcoma tissue
2. The viral infection should clear when Kaposi's sarcoma remits
3. Renal transplant patients with non-Kaposi's sarcoma skin lesions should not express the virus.

In this study we demonstrate this phenomenon in a group of renal allograft recipients who had remitted Kaposi's sarcoma and note the absence of the virus in a control group of renal transplant subjects.

MATERIALS AND METHODS

PATIENTS AND SAMPLES (Table 14-3)

In the 20-year period 1976-1995, a total of 444 patients received 509 renal allografts. Of the 27 malignancies documented, 16 (59%) were Kaposi's sarcoma. Pathological material for the confirmation of the diagnosis of Kaposi's sarcoma was available on all but two patients who were excluded from further analysis. The remaining 14 patients presented with cutaneous Kaposi's sarcoma at diagnosis. Autopsy material of 2 patients who also presented with visceral organ involvement was available. Cutaneous Kaposi's sarcoma biopsy samples were available from 13 patients, but not on patient 14 who had a diagnostic lymph node biopsy. The mean age of the 14 patients at the time of diagnosis of Kaposi's sarcoma was 41.5 years (range: 27-55 years). Caucasians made up 36% of our total transplant population but only 1 (7%) developed Kaposi's sarcoma ($P < 0.03$, Fisher's exact test). All the patients received triple immunosuppressive therapy including cyclosporine, except patient 7 who was on azathioprine. None of the patients received anti-lymphocyte globulin therapy. The latent period following transplantation and the diagnosis of Kaposi's sarcoma was 21 months (range: 3-64 months). The 11 patients without visceral involvement had complete remission of the Kaposi's sarcoma skin lesions after reduction or withdrawal of immunosuppressive therapy.

A follow-up biopsy of clinically normal skin was taken from the same anatomical region as the first biopsy, after remission of Kaposi's sarcoma in the 11 patients. The follow-up biopsies were performed at a mean interval of 44 months (range 5-125 months) after the initial biopsy. The follow-up punch biopsies of skin were divided in two and the one section was fixed in buffers while the other half was snap frozen and stored at -70°C . Unclothed peripheral blood was collected in EDTA tubes at the time

Table 14-3. Demographic and clinical data on Kaposi's sarcoma in our renal transplant patients.

Patient	Age (Yrs)	Sex	Race ¹	Latency (Mo)	Tissue Sampled	Immunotherapy Discontinued ²	Biopsy Interval (Mo)	Graft Outcome ³
1	27	Male	Coloured	5	skin	CSA	37	Functioning
2	44	Female	Coloured	64	skin	CSA	6	Functioning
3	50	Male	Black	27	skin	CSA	42	Functioning
4	48	Female	Coloured	14	skin	CSA	5	Infarction
5	56	Male	Black	56	skin	CSA	21	Functioning
6	50	Female	Black	9	skin	CSA	16	Chronic rejection
7 ⁴	49	Male	Coloured	21	skin	IS	126	Acute rejection
8	36	Female	Coloured	22	skin	CSA	32	Functioning
9	29	Female	Coloured	3	skin	IS	125	Acute rejection
10	41	Male	Coloured	18	skin	CSA	18	Functioning
11	30	Male	Coloured	34	skin	CSA	33	Functioning
12 ⁵	39	Male	Coloured	11	skin	IS	-	Patient died
13	43	Female	Caucasian	5	skin liver lung	IS	-	Patient died
14	40	Female	Coloured	9	lung stomach kidney lymph node	IS	-	Patient died

¹P<0.03, Fisher's exact test, Caucasian compared with non-Caucasian (coloured and black) patients who develop Kaposi's sarcoma.

²CSA is cyclosporine alone, IS is all immunosuppression.

³Graft outcome refers to status at repeat skin biopsy.

⁴Patient on azathioprine

⁵Patient with clinical visceral Kaposi's sarcoma organ involvement. Postmortem examination not obtained.

of the second skin biopsy. Sections from a renal graft that was removed following severe rejection (patient 4), at the time of the second skin biopsy were also included. All patients tested negative for HIV (ELISA, Abbot Laboratories, Chicago, IL). The 24 control subjects were all renal transplant recipients transplanted at the same institution and receiving similar immunosuppressive therapy, who had pathological material sent for the diagnosis of a range of inflammatory and dysplastic skin lesions.

The specimens, collected over a 3-year period, included both non-Kaposi's sarcoma malignancies and other benign skin lesions (Table 14-4). Formalin-fixed paraffin embedded blocks of Kaposi's sarcoma and non-Kaposi's sarcoma tissue specimens from the 14 Kaposi's sarcoma patients and 24 control subjects were retrieved from the files of the Department of Anatomical Pathology, University of Stellenbosch and Tygerberg Hospital. Hematoxylin and eosin stained sections were examined histopathologically in all cases. Using established criteria all histopathological variants of Kaposi's sarcoma were found to be represented in the cohort (Friedman-Birnbaum *et al.*,1993;Harawi,1989). Venesection and repeat biopsies were not performed on the control subjects.

PREPARATION OF CELL LYSATES AND DNA FROM TISSUE SECTIONS AND PBMC SAMPLES

Cell lysates were prepared from paraffin embedded tissue sections and frozen tissue by a method previously described (Van Rensburg *et al.*,1996). Sections of formalin-fixed and paraffin embedded normal foetal skin tissue were included as negative controls and to evaluate the possibility of contamination. Non-Kaposi's sarcoma skin tissue from the control subjects was prepared using the same technique, but sections of affected tissue from 2 patients diagnosed with the Kaposi's sarcoma served as positive controls.

Peripheral blood mononuclear cells (PBMC) were prepared by separation on ficoll-hypaque (Sigma, St. Louis, MO USA). The buffy coat fraction of each specimen was collected and washed with phosphate buffered saline (PBS). Each cell pellet was resuspended in 300ul lysis buffer containing 300 ug/ml proteinase K and

Table 14-4. Details of control subjects (n=24)

Mean age (yrs)	42
Sex (male/female)	15:8
Race (black/white/coloured)	1/12/10
Latency period (mo.)	86.6
Pathological specimens	35 ¹
<i>Diagnosis:</i>	
Dermatitis	4
Squamous CA	10
Basal cell CA	3
Solar keratosis	3
Infections	3
Calcinosis cutis	2
Miscellaneous	10

¹ Several patients had more than a single skin biopsy

was incubated at 55°C for 60 minutes. The lysates were then incubated at 95°C for 15 minutes to inactivate enzymes and proteinase K (Albert *et al.*, 1990). The lysates prepared from the blocked and fresh tissue samples, as well as the PBMC samples were then put through QIAamp columns (QIAamp blood kit, 05/95, QIAGEN GmbH, Germany) for DNA isolation and the manufacturer's protocol were followed from step 4.

DNA AMPLIFICATION TO DETECT HHV-8 SPECIFIC SEQUENCES

General procedures were followed to avoid contamination during sample preparation and PCR (Kwok *et al.*, 1989). All samples were first amplified with β -globin primers to evaluate their suitability for PCR (Saiki *et al.*, 1986). The KS330₂₃₃ primers were

used to amplify an HHV-8 specific 233 bp sequence of open reading frame 26 (ORF 26) (Chang *et al.*,1994) under the same conditions as previously described (Engelbrecht *et al.*,1997). Nested PCR to amplify a 172 bp was done using the primers GTG CTC GAA TCC AAC GGA TT and ATG ACA CAT TGG TGG TAT AT as described (Engelbrecht *et al.*,1997;Whitby *et al.*,1995). Dilutions of the plasmid KS330Bam (Chang *et al.*,1994) were included as positive controls and to determine the number of HHV-8 target molecules present (Engelbrecht *et al.*,1995). PCR products were analysed by UV transillumination after electrophoresis through 3% agarose gels stained with ethidium bromide.

DETECTION OF PCR PRODUCTS BY SPOT BLOT HYBRIDISATION

A total of 8ul denatured nested PCR products were spotted onto nylon membranes (Hybond-N, Amersham International plc, Buckinghamshire, England). The KS330Bam fragment, cleaved and purified from the plasmid, was labeled as probe to detect HHV-8 DNA sequences (DIG DNA labeling kit; Boehringer Mannheim, Mannheim, Germany). DNA hybridisation was done overnight at 50°C according to the manufacturer's instructions. The membranes were washed twice in 2x SSC and 0.1% SDS for 5 minutes at room temperature, followed by 2x 15 minutes at 55°C in 0.1x SSC and 0.1% SDS. The DNA hybridisation was detected using the DIG detection kit (Boehringer Mannheim, Mannheim, Germany).

DIRECT SEQUENCING

PCR products were analysed for sequence variation by direct sequencing. The nested PCR primers (Whitby *et al.*,1995) were used for sequencing with the Sequenase PCR product sequencing kit (USB Catalogue US70170, supplied by Amersham Life Science Inc). Standard denaturing gel electrophoresis was conducted according to the kit's manufacturers.

SEQUENCE ANALYSIS

Nucleotide changes were identified in the HHV-8 DNA from our patients with the Genepro V5.0 software program (Riverside Scientific Enterprises, Bainbridge Island

WA,USA) by aligning the sequences to the reference sequence of KS330 (Chang *et al.*,1994).

RESULTS

HISTOPATHOLOGICAL FINDINGS

Follow-up skin biopsies done during periods of clinical remission revealed no evidence of Kaposi's sarcoma except in patients 5 and 11 where histopathological signs of perivascular inflammation and subtle vascular proliferation were suggestive of early Kaposi's sarcoma. The histopathology of sections from the graft nephrectomy (patient 4) was compatible with acute infarction.

DETECTION OF HHV-8 IN BIOPSY SAMPLES AND PBMC (Figs. 14-3 and 14- 4)

HHV-8 specific DNA sequences were detected in all the initial cutaneous Kaposi's sarcoma biopsy samples. Patients 5 and 9 showed very weak hybridisation signals. All formalin fixed follow-up skin biopsies were negative for HHV-8 DNA sequences by PCR and DNA hybridisation. However in the equivalent frozen skin biopsies viral DNA was detectable in 5 patients (patients 2,5,6,8,10). HHV-8 sequences were detected in only two (patients 4 and 10) of the eleven PBMC samples collected at the same time as the follow-up skin biopsies. One of these patients (patient 4) was on immunosuppressive therapy for the treatment of acute rejection. In patient 10 viral DNA was also detected in the repeat skin biopsy. The non-Kaposi's sarcoma tissue sample from the graft kidney of patient 4 was negative for HHV-8 DNA. Although HHV-8 DNA was detected in the frozen biopsies of patients 2,6 and 8 the PBMC samples tested negative. Patient 5 whose frozen biopsy tested positive had histopathological features of early Kaposi's sarcoma. In the two postmortem cases all the visceral Kaposi's sarcoma tissue (patient 13: spleen, liver, lung and patient 14: spleen, lung, stomach, kidney) and almost all non-Kaposi's sarcoma tissue (patient 13: brain, thyroid, salivary gland, myocardium, aorta and patient 14: brain, thyroid, ovary, myocardium) tested positive for HHV-8 DNA sequences (Table 14-5). Only the non-Kaposi's sarcoma specimen of the ovary of patient 13 was negative.

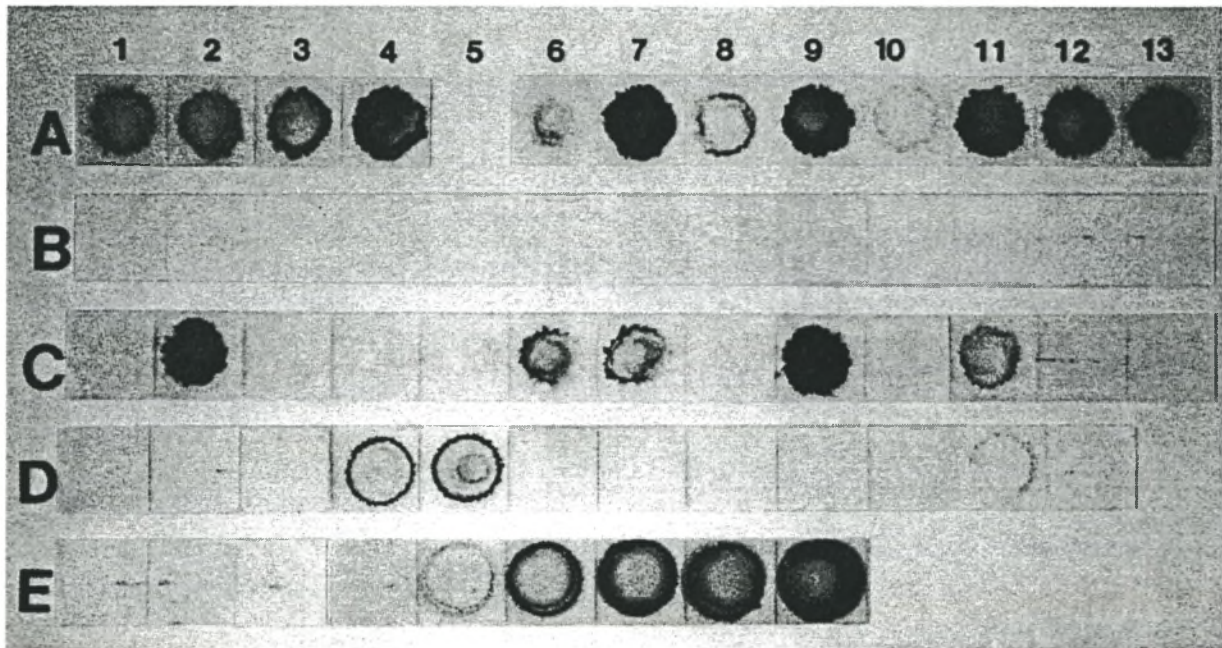


Fig. 14-3. HHV-8 DNA in skin and PBMC samples of transplant patients. **A**, formalin-fixed Kaposi's sarcoma skin biopsies. **B**, formalin-fixed follow-up skin biopsies. **C**, equivalent frozen follow-up biopsies. **D**, PBMC samples at time of the follow-up skin biopsies. Lanes 1-4: patients 1-4; lanes 6-12: patients 5-11. Lane A13: patient 12; lane A5: space, B5 and C5: graft kidney of patient 4, D5: second PBMC sample of patient 4. Lanes B13 and C13: foetal skin. **E**, 1-3: foetal skin, 4: reagent control, 5-9: 1, 10^2 , 10^3 and 10^4 copies of KS330Bam plasmid DNA.

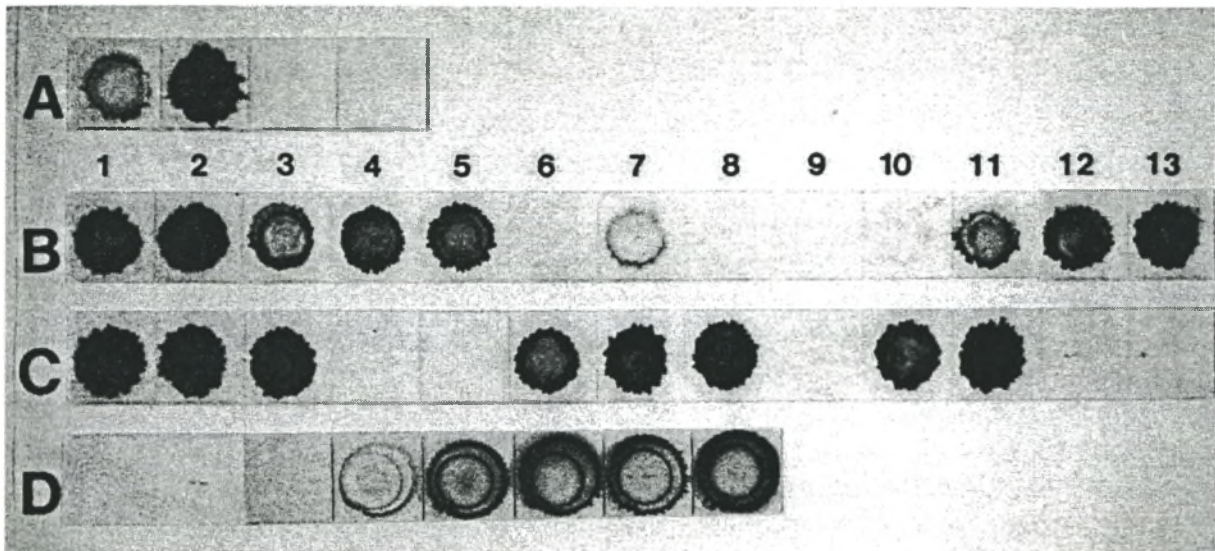


Fig. 14-4. HHV-8 DNA hybridisation signal of initial Kaposi's sarcoma biopsy samples and postmortem (PM) samples from patient 13 and 14. **A**, initial biopsy Kaposi's sarcoma: 1: skin, patient 13, 2: lymph node, patient 14; 3 and 4: foetal skin. **B**, PM samples: patient 13: 1: liver, 2: lung, 3 and 4: myocardium, 5: spleen, 6: ovary, 7: cerebellum, 8: cerebral grey cortex, 9: deep grey matter (brain), 10: brain, 11: aorta, 12: thyroid, 13: salivary gland. **C**, PM samples: patient 14: 1: lung, 2: stomach, 3: kidney, 4: cerebral cortex, 6: deep grey matter (brain), 7: spleen, 8: and 9: myocardium, 10: ovary, 11: thyroid, 12 and 13: foetal skin. **D**, 1 and 2: foetal skin, 3: reagent control, 4-8: 1, 10, 10², 10³, and 10⁴ copies of KS330Bam plasmid DNA.

Table 14-5. HHV-8 in 2 autopsy cases with Kaposi's sarcoma. The virus was detected extensively in tissue not phenotypically Kaposi's sarcoma.

Patient	Kaposi's sarcoma Tissue	HHV-8	Non-Kaposi's sarcoma Tissue	HHV-8
13	skin	+	brain	-
	liver	+	thyroid	+
	lung	+	salivary gland	+
			myocardium	+
			aorta	-
			spleen	+
			ovary	+
14	lung	+	brain	+
	stomach	+	thyroid	+
	kidney	+	ovary	+
	lymph node	+	myocardium	-
			spleen	+

The foetal skin samples tested negative for HHV-8 by PCR and hybridisation. All specimens obtained from the control patients including all malignant skin lesions tested negative for HHV-8 DNA. The control samples were tested together with tissue from two patients known to have Kaposi's sarcoma and only these tested positive for HHV-8 DNA by PCR and hybridisation. A control patient with a herpesvirus simplex skin lesion also tested negative.

DIRECT DNA SEQUENCING AND SEQUENCE ANALYSIS (Table 14-6)

Mutations in HHV-8 DNA from 12/14 patients were identified. The HHV-8 DNA of all the patients except patient 13 contained 3-5 mutations each and the nucleotide positions involved were as follows: position 1032 (C>A), 1033 (C>T), 1055 (G>T),

Table 14-6. Mutations in HHV-8 DNA from South African renal transplant patients.

Patient Number	Nucleotide Position	Nucleotide Change	Codon Change
1, 2, 5, 8, 10, 12, 14	1033	C → T	Pro → Leu
	1055	G → T	silent
	1132	A → G	Asp → Gly
	1139	A → C	silent
3	1033	C → T	Pro → Leu
	1055	G → T	silent
	1077	C → T	silent
	1132	A → G	Asp → Gly
	1139	A → C	silent
4	1032	C → A	Pro → Thr
	1033	C → T	Pro → Leu
	1132	A → G	Asp → Gly
	1139	A → C	silent
6	1033	C → T	Pro → Leu
	1086	C → T	silent
	1139	A → C	silent
11	1033	C → T	Pro → Leu
	1132	A → G	Asp → Gly
	1139	A → C	silent
13	1033	C → T	Pro → Leu

1077 (C>T), 1086 (C>T), 1132 (A>G), 1139 (A>C). Only one mutation at position 1033 was identified in the HHV-8 DNA of patient 13. Similar mutations were found in 7/12 (58,3%) patients and were as follows: position 1033 (C>T), 1055 (G>T), 1132 (A>G) and 1139 (A>C). The HHV-8 DNA from all the patients sequenced contained the C>T nucleotide change at position 1033. The nucleotide changes at positions 1032, 1033 and 1132 result in a proline to threonine, proline to leucine and aspartine to glycine amino-acid changes.

DISCUSSION

Kaposi's sarcoma is the single most common posttransplant malignancy in our cohort accounting for 64% of all malignancies in this group and is second only to the reported Saudi Arabian experience where Kaposi's sarcoma causes 85% of all malignancies (Qunibi *et al.*,1988). The clustering of our cases in the middle of the last two decades when the number of transplants had remained relatively constant was perhaps suggestive of an outbreak of an infectious agent.

HHV-8 – DESCRIPTION OF THE HERPESVIRUS FAMILY (Fig. 14-5)

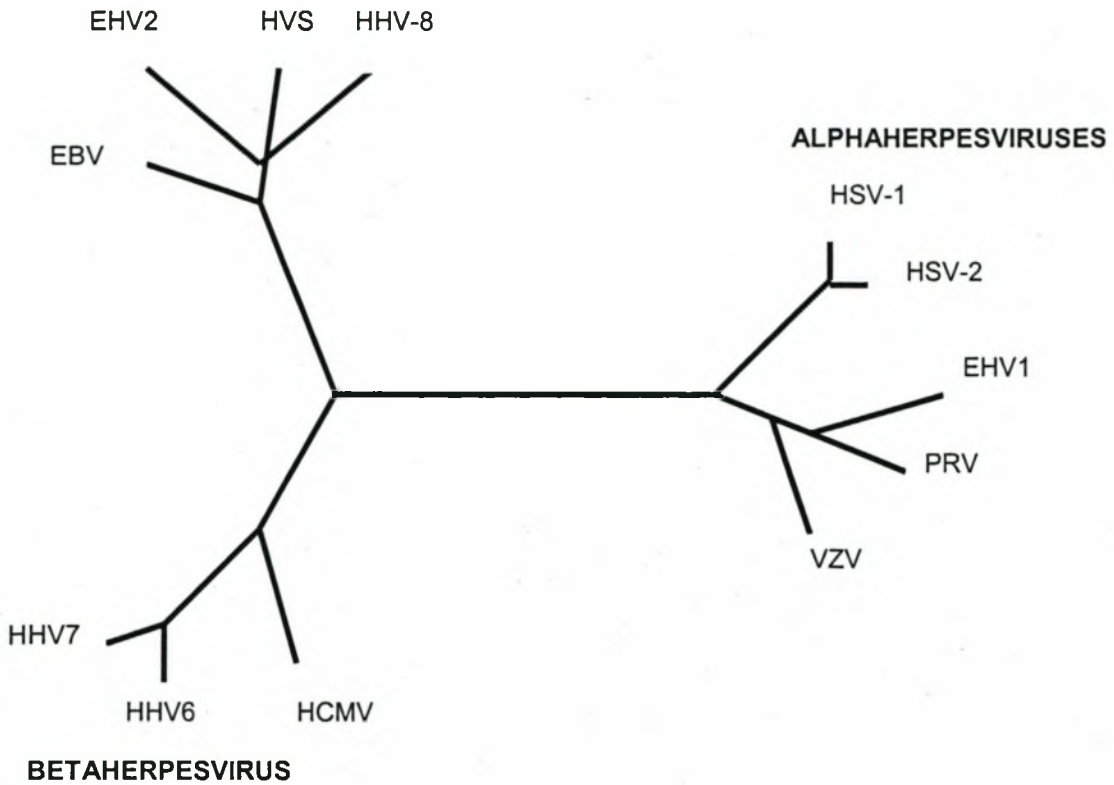
The description by Chang *et al.* (1994) of the new oncogenic herpesvirus HHV-8 represented a major advance not only in the understanding of Kaposi's sarcoma but also of virally-mediated malignancies. The newly described virus bears similarity to two other γ -herpesviruses in the genus Rhadinovirus and is the first member of the genus to infect humans (Moore *et al.*,1996a). HHV-8 shows sequence homology at the DNA level to EBV and herpesvirus saimiri (Moore *et al.*,1996a). These viruses infect lymphocytes and are associated with immortalisation and transformation. The prototype of this genus is herpesvirus saimiri that is non-pathogenic in its squirrel monkey host but is the cause of T-cell lymphoma in other primates (Levy,1997).

HHV-8 – DESCRIPTION OF THE VIRUS

The HHV-8 genome is about 170kb in size (Renne *et al.*,1996b;Russo *et al.*,1996) and contains sequences resembling those of cyclin D, a cell cycle inducer (Chang *et al.*,1996a), cytokines, and other human regulatory and DNA metabolism genes (Moore *et al.*,1996c;Russo *et al.*,1996). Of note is the presence of the bcl-2-like

GAMMAHERPESVIRUSES

Rhadinovirus



Members of the family Herpesviridae

Alphaherpesviruses

- Herpesvirus simplex 1 (HSV1)
- Herpesvirus simplex 2 (HSV2)
- Equine herpesvirus 1 (EHV1)
- Varicella-zoster virus (VZV)
- Pseudorabies virus (PRV)

Betaherpesviruses

- Human cytomegalovirus (CMV)
- Human herpesvirus 6 (HHV6)
- Human herpes 7 (HHV7)

Gammaherpesviruses

- Herpesvirus saimiri (HSV)
 - Epstein-Barr virus (EBV)
 - Equine herpesvirus 2 (EHV2)
 - Human herpesvirus 8 (HHV8)
-

Fig. 14-5. *The phylogenetic tree of the herpesvirus family based on amino acid sequences of the major capsid protein of HHV-8 with table listing the members of the family (Moore et al., 1996a)*

sequence that, by inhibiting apoptosis, could confer transforming properties also attributed to Epstein-Barr virus (Moore et al.,1996c;Russo et al.,1996). Although the exact mechanism whereby the virus triggers the lesion remains to be established the detection of the virus in virtually all Kaposi's sarcoma lesions (Boshoff et al.,1995a;Chang et al.,1996b;Huang et al.,1995a;Schalling et al.,1995) and its presence preceding development of Kaposi's sarcoma suggest that the virus plays a key aetiological role (Whitby et al.,1995). In this study HHV-8 DNA sequences were detected in all cutaneous Kaposi's sarcoma biopsy samples as well as in all Kaposi's sarcoma tissue examined at autopsy. Our observation that the virus is cleared on remission of the Kaposi's sarcoma lesions further corroborates the importance of the virus.

HHV-8 – TISSUE LOCALISATION

At the Kaposi's sarcoma lesional level, HHV-8 infects spindle and endothelial cells (Boshoff et al.,1995b) as demonstrated by PCR *in situ* hybridisation (Boshoff et al.,1995b;Li et al.,1996;Staskus et al.,1997) with the majority of these cells latently infected (Boshoff et al.,1995b;Li et al.,1996). By contrast, the mononuclear cells including the monocytes-macrophages are lytically infected and may support viral replication and spread to other cell types (Blasig et al.,1997;Orenstein et al.,1997). This is suggested by recent observations of HHV-8 transmission to peripheral blood mononuclear cells, B-cells, monocytes-macrophages, dendritic cells and endothelial cells (Monini et al.,1999). Other supporting evidence is the *in situ* hybridisation result demonstrating recruitment of HHV-8 infected monocytes into Kaposi's sarcoma tissue (Blasig et al.,1997). An important observation is that B-cells are virtually absent from Kaposi's sarcoma lesions. However, viral DNA can be found in circulating B cells in some 50% of AIDS patients and 7% of AIDS patients without Kaposi's sarcoma (Whitby et al.,1995). Circulating B-cells therefore represent one of the major reservoirs of the virus. HHV-8 has recently been detected in monocytes-macrophages (Blasig et al.,1997;Sirianni et al.,1998), dendritic cells (Rettig et al.,1997) and in T-cells (but only rarely and only in patients with advanced AIDS (Monini et al.,1999). HHV-8 has also been detected in the circulating monocytes and spindle cell precursors of Kaposi's sarcoma patients (Monini et

al.,1999;Sirianni *et al.*,1997) suggesting that these cells may play a role in virus recruitment into tissues (Ensoli *et al.*,1998b).

HHV-8 – ROLE IN KAPOSÍ'S SARCOMA PATHOGENESIS

O'Leary *et al.* (1997) have proposed 4 possible mechanisms whereby the virus could be involved in Kaposi's sarcoma. (i) HHV-8 may be an opportunistic infection targeting specific B-cells that respond to malignancy. In this case HHV-8 should be detected in serological tests as shown by Kedes *et al.* (1996) and Gao *et al.* (1996b). However the limitation of HHV-8 to Kaposi's sarcoma (and primary effusion lymphoma and MCD) makes this hypothesis unlikely. (ii) HHV-8 infected B-cells may indirectly enhance the initial transforming event, in much the same fashion as has been suggested for EBV in Burkitt's lymphoma. This effect is specific and tumour restrictive. (iii) HHV-8 infected B-cells may produce cytokines that have a proliferative effect on endothelial cells, which subsequently proceed to transformation/differentiation into the spindle cell phenotype of Kaposi's sarcoma. HHV-8 may act directly on endothelial cells resulting in activation of the cells and their transformation to spindle cells. (iv) Action of HHV-8 may be mediated by a variety of cytokines and proteins involved in cell regulation and division. HHV-8 may also interact with undefined cellular factors.

The question of whether extravasation of HHV-8 infected mononuclear cells into the tissue may be the initiating event of the development of Kaposi's sarcoma or whether these cells are secondarily recruited into an early reactive Kaposi's sarcoma focus has not been resolved. Ensoli *et al.* (1998b) support the latter hypothesis because recent data have shown that in the advanced stage of Kaposi's sarcoma both the latency associated nuclear antigen (LANA) and the kaposin gene (expressed in lytic lesions as well) are detected whereas in early lesions only a relatively small number of cells express kaposin and LANA is not expressed at all (Rainbow *et al.*,1997;Sturzl *et al.*,1997). In addition viral load is much higher in advanced lesions compared to early lesions, where the virus may be undetectable (Fiorelli *et al.*,1998;Maiorana *et al.*,1997;Noel,1995). Inflammatory cytokines have also been shown to activate HHV-8 and increase viral load (see above). Ensoli *et al.* (1998b)

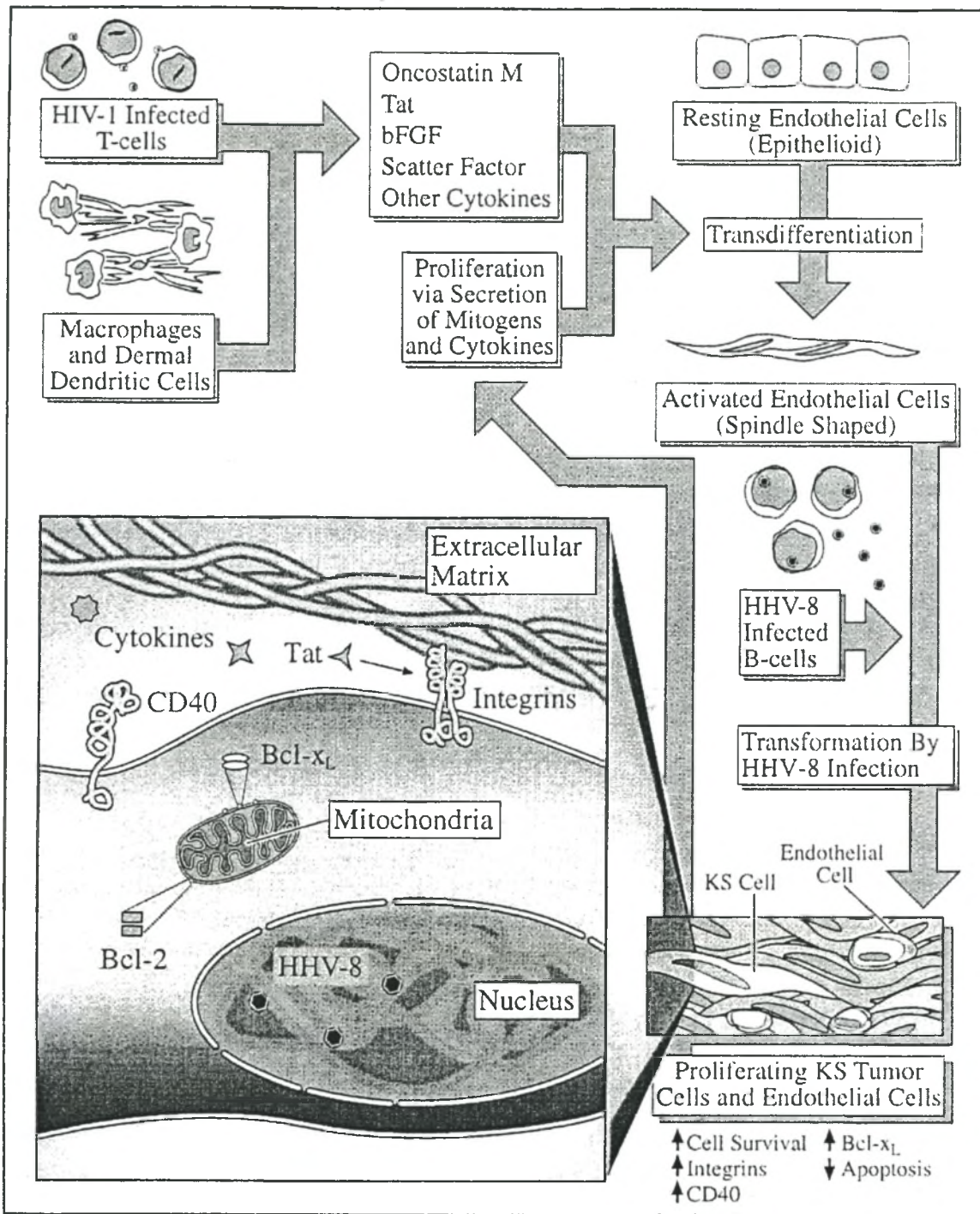


Fig. 14-6. The pathogenesis of Kaposi's sarcoma. Multiple pathways leading to the formation of Kaposi's sarcoma involve HHV-8, integrins and other proteins that regulate apoptosis are involved. The possible role of HIV is portrayed. The exact role played by the immune system is uncertain at this time and is not illustrated here (Nickoloff et al., 1996).

therefore speculate that HHV-8 plays a predominant role after the initiation of Kaposi's sarcoma.

The possible role of HHV-8 in the pathogenesis of Kaposi's sarcoma is illustrated (Fig. 14-6). We have however demonstrated the extensive presence of the virus in non-Kaposi's sarcoma tissue of patients dying with widespread Kaposi's sarcoma. This observation therefore suggests that HHV-8 is not restricted to Kaposi's sarcoma or transformed tissue and makes it difficult to accept the Ensoli hypothesis. The presence of HHV-8 in non-Kaposi's sarcoma tissue does however imply additional factors are required for induction of Kaposi's sarcoma.

OTHER FACTORS IN THE DEVELOPMENT OF KAPOSI'S SARCOMA

Other factors essential for development of angioproliferative Kaposi's lesions are extracellular matrix molecules, integrins and cytokines. Extracellular matrix molecules such as fibronectin and vitronectin are key factors in endothelial cell survival, adhesion, growth, invasion and angiogenesis (Stromblad *et al.*,1996). Integrins are known to modulate angiogenesis directly by influencing apoptosis. This complex process involves the potentially transforming genes *bcl-2* and *bcl-x_L* that prolong cell survival, and *bcl-x_S* and *bax* genes that promote apoptosis (O'Leary *et al.*,1997). In Kaposi's sarcoma it is known that *bcl-x_L* is present in endothelial and spindle cells and its expression can be directly influenced by certain cytokines. *Bcl-2* is detectable in Kaposi's sarcoma lesions but at lower concentrations than *bcl-x_L* (Nickoloff *et al.*,1996).

Increased expression of CD40, a member of the tumor necrosis factor receptor/nerve growth receptor family, occurs in Kaposi's sarcoma tumour cells and in vessels adjacent to Kaposi's sarcoma lesions (Pammer *et al.*,1996). CD40 is a signalling molecule that is involved in inhibition of apoptosis, induction of cell surface antigen presentation and B-cell proliferation adhesion and differentiation. In B-cells, CD40 expression can induce production of cell survival products such as *bcl-x_L*. The stimulus for inducing expression of CD40 in Kaposi's sarcoma cells and endothelial cells are not known. Cytokines reported to upregulate CD40 include interferon (IFN)-

γ (Stamenkovic *et al.*,1989) and interleukin (IL)-4 (Bouwes *et al.*,1995) for lymphoid cells and IFN- γ , IL-1 α and tumour necrosis factor (TNF) for epithelial cells (Galy *et al.*,1992;Stamenkovic *et al.*,1989). Recently it was demonstrated that IFN- γ and - β , and TNF increase CD40 on endothelial cells *in vitro* (Hollenbaugh *et al.*,1995;Karmann *et al.*,1995). Combinations of cytokines implicated in the pathogenesis of Kaposi's sarcoma appear to act synergistically to upregulate CD40 expression on Kaposi's sarcoma tumor cells and on regular endothelial cells in Kaposi's sarcoma lesions (Ensoli *et al.*,1992;Fiorelli *et al.*,1995;Karmann *et al.*,1995;Roth *et al.*,1992). It has also been speculated that HHV-8 may be the responsible for inducing CD40 expression (O'Leary *et al.*,1997;Pammer *et al.*,1996). In support of this hypothesis is the observation that the closely related EBV produces latent membrane protein-1 (LMP-1) that can increase CD40 expression (Wang *et al.*,1990). In addition, EBV – LMP-1, that induces Bcl -2 expression in B-cells, and another EBV product bhrf-1, an anti-apoptotic protein, are known to protect virally infected cells from apoptosis (O'Leary *et al.*,1997). The role of HHV-8 in the pathogenesis of Kaposi's sarcoma remains speculative.

HHV-8 – GENETIC STRUCTURE (Fig. 14-7)

A number of HHV-8 genes, which are homologous to genes encoding cell cyclins and some G-protein coupled receptors have now been identified (Motokura *et al.*,1993b;Motokura *et al.*,1993a). These genes among others may confer direct oncogenic ability on HHV-8. Surprisingly, almost 10% of all genes encoded by HHV-8 have been suggested to promote Kaposi's sarcoma development due either to mitogenic, anti-apoptotic, chemoattractant, angiogenic or transforming properties (Neipel *et al.*,1997; Russo *et al.*,1996). HHV-8 genes implicated include ORFK2 (v-IL-6), ORFs K4,K6 (v-MIP-II), ORF16 (bcl-2), ORFK13 (v-FLIP), ORF72 (v-CYC D), ORF73 (LANA) and ORF74 (G-coupled receptor). Using *in situ* hybridisation techniques Strürzl and Ensoli (1999) found that of all the HHV-8 genes only v-Cyclin D was highly expressed in Kaposi's sarcoma lesions during viral latency. v-Cyclin D can mimic the effect of cellular D-type cyclins and induces the progression of the cell from G₁ to S-phase of the cell cycle (Chang *et al.*,1996a). Expression of v-bcl-2, v-MIP-I and v-IL6 were undetectable or limited to a few lytically infected cells in

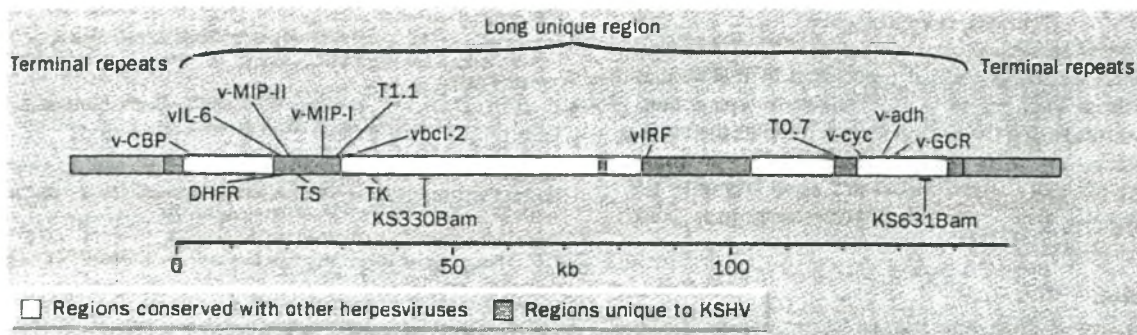


Fig. 14-7: Schematic representation of the HHV-8 genome showing the 140.5-kb long unique coding region (LUR) containing all identified genes.

LUR is flanked by multiple G+C-rich 801 base-pair terminal repeat sequences (about 35 kb) at either end which probably ligate together to circularise the genome during cellular portion of the viral replicative cycle. LUR is divided into portions that have genes conserved among other herpesviruses (thymidine kinase –TK and thymidylate synthetase – TS), and regions unique to the HHV-8 containing regulatory, cytokine, and DNA metabolism genes homologous to cellular genes. The virus encodes homologues to complement-binding protein – v-CBP, three cytokines (two macrophage inflammatory proteins– vMIP, and interleukin-6 – vIL-6), dihydrofolate reductase – DHFR, bcl-2, interferon regulatory protein – vIRF, interleukin 8 receptor – vGCR, neural cell adhesion molecule-like adhesin – vadh and D-type cyclin – v-Cyc. Also shown are T1.1 and T0.7, two highly conserved mRNA transcripts and KS 330Bam and KS631Bam sequences that were originally described in AIDS-Kaposi's sarcoma lesions. Modified from Levy (1997).

Kaposi's sarcoma lesions suggesting that these genes had minimal impact on the pathogenesis of Kaposi's sarcoma (Stürzl *et al.*,1999). Another important observation made by Strürzl and Ensoli (1999), and one that supports the observations of other groups is the low copy numbers of the HHV-8 genome in Kaposi's sarcoma lesions. In B-cell primary effusion lymphomas 40-80 HHV-8 genome equivalents can be found per lymphoma cell (Renne *et al.*,1996a). In Kaposi's sarcoma tumours, in contrast, the frequency is approximately one HHV-8 genome per cell (Rainbow *et al.*,1997;Staskus *et al.*,1997). This suggests that HHV-8 may be more important in the progression of Kaposi's sarcoma than in the initial transformation although it is still possible that a few HHV-8 infected cells can trigger early Kaposi's sarcoma development (Sturzl *et al.*,1999).

HHV-8 AND THE IMMUNE SYSTEM

The aetiology of Kaposi's sarcoma, perhaps like other malignancies, would appear to be multifactorial with the complex interplay between immunological, genetic and environmental factors. Central to the development of both AIDS-associated and posttransplant Kaposi's sarcoma, is immunosuppression. In immunocompromised patients with AIDS development of Kaposi's sarcoma is related to the degree of immunosuppression as evidenced by CD4⁺ T-cell levels (Gao *et al.*,1996a). In renal transplant patients the use of azathioprine increased the prevalence of Kaposi's sarcoma 4-500 times (Harwood *et al.*,1979b) and 1000-fold with the introduction of the more potent cyclosporine (Cockburn,1987;Cockburn *et al.*,1989). The drugs suppress the immune response at various levels including cell-mediated immunity, which in particular is required for both tumour surveillance and suppressing viral replication. Impairment of cell-mediated immunity has also been demonstrated in classical and endemic Kaposi's sarcoma (Dobozy *et al.*,1973;Harwood *et al.*,1979b;Master *et al.*,1970).

The immune system responds to the development of oncogenic-virus induced tumours in the same way that it does to foreign transplant antigens and specific cytotoxic T-cells, cytokines and cytotoxic natural killer cells act in concert to eliminate these mutations (Goust *et al.*,1993;Roitt,1994). We postulate that in the immunocompromised, there is unchecked HHV-8 replication and vascular proliferation that may result in neoplastic transformation of endothelial cells and subsequent progression to clinically overt Kaposi's sarcoma; this may be maintained because of lack of immune surveillance. The susceptibility of renal allograft recipients in particular to Kaposi's sarcoma may also be due to the chronic antigenic stimulation which occur in allograft recipients which may promote the production of angiogenic cytokines by activated T-lymphocytes (Ziegler,1990). This immune activation is seen in other forms of Kaposi's sarcoma and seems to be important to the development of Kaposi's sarcoma as alluded to above (Mitsuyasu *et al.*,1986;Safai *et al.*,1992).

REMISSION OF KAPOSI'S SARCOMA

We have observed and other groups have confirmed that complete remission of Kaposi's sarcoma can be achieved solely with reduction or withdrawal of immunosuppression (Bencini *et al.*, 1993; Montagnino *et al.*, 1994; Pedagogos *et al.*, 1994; Penn, 1979b). The absence of HHV-8 DNA sequences in the second skin biopsy and PBMCs shows that HHV-8 disappears from the skin and the PBMCs when immunosuppressive therapy is discontinued or stopped and remission of Kaposi's sarcoma lesions is complete (the one PBMC sample that still contained HHV-8 was from a patient who was on immunosuppressive therapy for graft rejection). We postulate that this allows the immune response to be reconstituted sufficiently for normal anti-viral mechanisms to eliminate the HHV-8. At the same time malignant Kaposi's sarcoma cells are also removed by the patients' reconstituted immune system.

HHV-8 IN RENAL TRANSPLANT PATIENTS WITHOUT KAPOSI'S SARCOMA

Our experience confirms that HHV-8 is not associated with either benign or malignant non-Kaposi's sarcoma skin lesions in immunocompromised renal transplant patients. The extent of HHV-8 infection in non-Kaposi's sarcoma patients is uncertain, but is probably low in low-risk populations contrary to the findings of Rady *et al.* (1995) and Monini *et al.* (1996). Rady and colleagues reported the detection of HHV-8 DNA in 82% of samples tested using PCR in 33 skin lesions derived from 4 renal transplant patients. In squamous cell carcinomas of the skin the prevalence was 93%. The authors suggested that HHV-8 is a widespread latent virus that undergoes activation in immunosuppressed patients and is associated with proliferating lesions in these patients (Rady *et al.*, 1995). In another report Monini *et al.* (1996) evaluated the presence of HHV-8 in semen, urogenital and prostatic tissue of immunocompetent subjects without evidence of Kaposi's sarcoma. They found evidence of the virus in all the biological samples tested. The highest prevalences were in normal semen (91%), prostate tissue (44%) and foreskin/glans specimens (10%). However, other groups have consistently been unable to corroborate the findings of Rady and Monini. Boshoff *et al.* (1996) investigated the presence of the

virus in 37 squamous cell carcinoma specimens from a group of both immunocompetent and immunosuppressed patients. This group used nested primers to detect the presence of HHV-8. Although they initially found that 38% of squamous cell carcinoma specimens were positive they established that contamination had occurred. On re-testing, all the samples both from the immunocompetent and bone marrow transplant recipients were negative. An earlier study by the same group failed to reveal HHV-8 in non-Kaposi's sarcoma tissue (Boshoff *et al.*,1995a). These findings concur with those of other groups (Noel *et al.*,1996) and argue against the suggestion of Rady *et al.* (1995) of HHV-8 being widespread and being reactivated by immunosuppression.

It has been suggested that use of PCR for detection of HHV-8 DNA leads to overestimation of infection rate largely due to laboratory contamination despite appropriate control measures (Kwok *et al.*,1989). Serological assays specific for HHV-8 have been used now to establish whether the virus is more common in individuals at risk for Kaposi's sarcoma. The recent development of a serological test for HHV-8 lytic-phase antigens may allow epidemiological investigations to be conducted (Miller *et al.*,1996).

HHV-8 IN NON-KAPOSİ'S SARCOMA LESIONS OF PATIENTS WITH VISCERAL KAPOSİ'S SARCOMA

In our study nearly 67% of non-Kaposi's sarcoma tissue from various organs of the 2 postmortem cases contained HHV-8 DNA. Both these two patients died within a few days of the initial diagnosis of Kaposi's sarcoma being made. We detected HHV-8 in a number of Kaposi's sarcoma-free organs including thyroid, salivary gland, myocardium, which have not been described before as well as in Kaposi's sarcoma-affected liver, lung, lymph nodes, stomach and kidney. In other studies, HHV-8 DNA was found in Kaposi's sarcoma-free lymph nodes, female and male urogenital tract tissue (especially prostatic tissue), bone marrow, paravertebral ganglia, hyperplastic tonsils, Kaposi's sarcoma-unaffected skin and Kaposi's

sarcoma-affected lung and spleen (Corbellino *et al.*,1996a;Corbellino *et al.*,1996b;Monini *et al.*,1996).

The significance of HHV-8 in the sensory ganglia and brain tissue is not clear. HHV-8 is expected to remain latent in B cells and therefore in lymphoid tissue such as the spleen, tonsils and lymph nodes like other γ -herpesviruses, but not in the neuronal cells like α -herpesviruses (Bigoni *et al.*,1996;Sears,1990). HHV-8 DNA sequences have been described in sensory ganglia of Kaposi's sarcoma patients and it has been suggested that this may explain the symmetrical cutaneous distribution often seen in Kaposi's sarcoma (Corbellino *et al.*,1996a). The detection of HHV-8 in non-lymphoid tissue could be the result of a viraemia secondary to immunosuppression, and not due to a primary infection of neuronal cells.

HHV-8 DNA POLYMORPHISM

Polymorphism of HHV-8 DNA sequences was detected and nucleotide changes were identified in 12/14 of our patient samples. There was a high degree of similarity in the mutation profile in most of the 12 patients, and a novel mutation was found at position 1077 in patient 3. The patterns of DNA from different postmortem tissue samples of patients 13 and 14 were the same for each individual patient and these similarities were confirmed by sequence analysis. The HHV-8 DNA identified in the PBMCs and cutaneous Kaposi's sarcoma sample of patient 4 also had the same nucleotide sequences.

The nucleotide change at position 1033 (C>T) that resulted in a proline to leucine amino acid change was present in the HHV-8 sequences of all 12 patients. The nucleotide change at position 1033 is described in 85.7% of HHV-8 DNA from classical Kaposi's sarcoma cases, and in 58.3% of AIDS-Kaposi's sarcoma cases (Dictor *et al.*,1996). This mutation at position 1033 was the only mutation present in patient 13. The sequences of all other patients contained 3 to 5 mutations, and were related more to the profile of mutations found in AIDS-Kaposi's sarcoma cases than in those found in African endemic Kaposi's sarcoma cases (Huang *et al.*,1995b).

Sequence variation in HHV-8 is therefore found in different clinical presentations of Kaposi's sarcoma as well as in different geographical regions.

CONCLUDING REMARKS

The results of our study suggest that viral replication occurs during immunosuppression, with viral dissemination to infect nearly every organ in the body and further, that HHV-8 is cleared from the blood and skin of renal transplant patients after cessation of immunosuppressive therapy and remission of the Kaposi's sarcoma lesions. Advances in the understanding of the aetiology and pathogenesis of Kaposi's sarcoma should lead to novel forms of therapeutic intervention based on eliminating the infective agent rather than using chemotherapeutic agents that further suppress the immunity.

LITERATURE CITED

- Albert, J. and Fenyo, E. M. (1990). Simple, sensitive, and specific detection of human immunodeficiency virus type 1 in clinical specimens by polymerase chain reaction with nested primers. *J.Clin.Microbiol.* **28**, 1560.
- Albini, A., Barillari, G., Benelli, R., Gallo, R. C., and Ensoli, B. (1995b). Angiogenic properties of human immunodeficiency virus type 1 Tat protein. *Proc.Natl.Acad.Sci.U.S.A.* **92**, 4838.
- Albini, A., Barillari, G., Benelli, R., Gallo, R. C., and Ensoli, B. (1995a). Angiogenic properties of human immunodeficiency virus type 1 Tat protein. *Proc.Natl.Acad.Sci.U.S.A.* **92**, 4838.
- Albrecht, J. C., Nicholas, J., Biller, D., *et al.* (1992). Primary structure of the herpesvirus saimiri genome. *J.Virol.* **66**, 5047.
- Ambroziak, J. A., Blackbourn, D. J., Herndier, B. G., *et al.* (1995). Herpes-like sequences in HIV-infected and uninfected Kaposi's sarcoma patients [letter; comment]. *Science.* **268**, 582.

- Andersen, C. B., Karkov, J., Bjerregaard, B., and Visfeldt, J. (1991). Cytomegalovirus infection in classic, endemic and epidemic Kaposi's sarcoma analyzed by in situ hybridization. *APMIS*. **99**, 893.
- Archibald, C. P., Schechter, M. T., Le, T. N., Craib, K. J., Montaner, J. S., and O'Shaughnessy, M. V. (1992). Evidence for a sexually transmitted cofactor for AIDS-related Kaposi's sarcoma in a cohort of homosexual men [see comments]. *Epidemiology*. **3**, 203 .
- Arya, S. K., Guo, C., Josephs, S. F., and Wong-Staal, F. (1985). Trans-activator gene of human T-lymphotropic virus type III (HTLV-III). *Science*. **229**, 69.
- Barillari, G., Gendelman, R., Gallo, R. C., and Ensoli, B. (1993). The Tat protein of human immunodeficiency virus type 1, a growth factor for AIDS Kaposi sarcoma and cytokine-activated vascular cells, induces adhesion of the same cell types by using integrin receptors recognizing the RGD amino acid sequence. *Proc.Natl Acad.Sci.U.S.A.* **90**, 7941.
- Barillari, G., Sgadari, C., Fiorelli, V., et al. (1999b). The Tat protein of human immunodeficiency virus type-1 promotes vascular cell growth and locomotion by engaging the alpha5beta1 and alphavbeta3 integrins and by mobilizing sequestered basic fibroblast growth factor. *Blood*. **94**, 663.
- Barillari, G., Sgadari, C., Palladino, C., et al. (1999a). Inflammatory cytokines synergize with the HIV-1 Tat protein to promote angiogenesis and Kaposi's sarcoma via induction of basic fibroblast growth factor and the alpha v beta 3 integrin. *J.Immunol.* **163**, 1929.
- Bayley, A. C. (1984). Aggressive Kaposi's sarcoma in Zambia, 1983. *Lancet*. **1**, 1318.
- Bencini, P. L., Montagnino, G., Tarantino, A., Alessi, E., Ponticelli, C., and Caputo, R. (1993). Kaposi's sarcoma in kidney transplant recipients. *Arch.Dermatol.* **129**, 248.
- Bendsoe, N., Dictor, M., Blomberg, J., Agren, S., and Merk, K. (1990). Increased incidence of Kaposi sarcoma in Sweden before the AIDS epidemic. *Eur.J.Cancer.* **26**, 699.
- Beral, V., Bull, D., Darby, S., et al. (1992). Risk of Kaposi's sarcoma and sexual practices associated with faecal contact in homosexual or bisexual men with AIDS [see comments]. *Lancet*. **339**, 632.

- Beral, V., Peterman, T. A., Berkelman, R. L., and Jaffe, H. W. (1990). Kaposi's sarcoma among persons with AIDS: a sexually transmitted infection? *Lancet*. **335**, 123.
- Bigoni, B., Dolcetti, R., de Lellis, L., *et al.* (1996). Human herpesvirus 8 is present in the lymphoid system of healthy persons and can reactivate in the course of AIDS. *J.Infect.Dis.* **173**, 542.
- Blasig, C., Zietz, C., Haar, B., *et al.* (1997). Monocytes in Kaposi's sarcoma lesions are productively infected by human herpesvirus 8. *J.Virol.* **71**, 7963.
- Borkovic, S. P. and Schwartz, R. A. (1981). Kaposi's sarcoma presenting in the homosexual man -- a new and striking phenomenon! *Ariz.Med.* **38**, 902.
- Boshoff, C., Schulz, T. F., Kennedy, M. M., *et al.* (1995b). Kaposi's sarcoma-associated herpesvirus infects endothelial and spindle cells. *Nat.Med.* **1**, 1274.
- Boshoff, C., Talbot, S., Kennedy, M., O'Leary, J, Schulz, T. F., and Chang, Y. (1996). HHV8 and skin cancers in immunosuppressed patients [letter]. *Lancet*. **347**, 338.
- Boshoff, C., Whitby, D., Hatzioannou, T., *et al.* (1995a). Kaposi's sarcoma associated herpesvirus in HIV-negative Kaposi's sarcoma [letter]. *Lancet*. **345**, 1043.
- Boshoff, C., Whitby, D., Talbot, S., and Weiss, R. A. (1997). Etiology of AIDS-related Kaposi's sarcoma and lymphoma. *Oral Dis.* **3 Suppl 1**, S129.
- Bouwes, Bavinck JN, Robertson, I., Wainwright, R. W., and Green, A. (1995). Excessive numbers of skin cancers and pre-malignant skin lesions in an Australian heart transplant recipient. *Br.Heart J.* **74**, 468.
- Brunson, M. E., Balakrishnan, K., and Penn, I. (1990). HLA and Kaposi's sarcoma in solid organ transplantation. *Hum.Immunol.* **29**, 56.
- Buchbinder, A. and Friedman, Kien AE. (1992). Clinical aspects of Kaposi's sarcoma. *Curr.Opin.Oncol.* **4**, 867.
- Buonaguro, F. M., Tornesello, M. L., Beth, Giraldo E., *et al.* (1996). Herpesvirus-like DNA sequences detected in endemic, classic, iatrogenic and epidemic Kaposi's sarcoma (Kaposi's sarcoma) biopsies. *Int.J.Cancer.* **65**, 25.
- Buonaguro, L., Barillari, G., Chang, H. K., *et al.* (1992). Effects of the human immunodeficiency virus type 1 Tat protein on the expression of inflammatory cytokines. *J.Virol.* **66**, 7159.

- Buonaguro, L., Buonaguro, F. M., Giraldo, G., and Ensoli, B. (1994). The human immunodeficiency virus type 1 Tat protein transactivates tumor necrosis factor beta gene expression through a TAR-like structure. *J.Virol.* **68**, 2677.
- Cesarman, E., Chang, Y., Moore, P. S., Said, J. W., and Knowles, D. M. (1995a). Kaposi's sarcoma-associated herpesvirus-like DNA sequences in AIDS-related body-cavity-based lymphomas [see comments]. *N.Engl.J.Med.* **332**, 1186.
- Cesarman, E., Moore, P. S., Rao, P. H., Inghirami, G., Knowles, D. M., and Chang, Y. (1995b). In vitro establishment and characterization of two acquired immunodeficiency syndrome-related lymphoma cell lines (BC-1 and BC-2) containing Kaposi's sarcoma-associated herpesvirus-like (Kaposi's sarcomaHV) DNA sequences. *Blood.* **86**, 2708.
- Chang, H. C., Samaniego, F., Nair, B. C., Buonaguro, L., and Ensoli, B. (1997). HIV-1 Tat protein exits from cells via a leaderless secretory pathway and binds to extracellular matrix-associated heparan sulfate proteoglycans through its basic region. *AIDS.* **11**, 1421.
- Chang, H. K., Gallo, R. C., and Ensoli, B. (1995). Regulation of cellular gene expression and function by the human immunodeficiency virus type 1 Tat protein. *J.Biomed.Sci.* **2**, 189.
- Chang, Y., Cesarman, E., Pessin, S., *et al.* (1994). Identification of herpes-like DNA sequences in AIDS-associated Kaposi's sarcoma. *Science.* **266**, 1865.
- Chang, Y., Moore, P. S., Talbot, S. J., *et al.* (1996a). Cyclin encoded by Kaposi's sarcoma herpesvirus [letter]. *Nature.* **382**, 410.
- Chang, Y., Ziegler, J., Wabinga, H., *et al.* (1996b). Kaposi's sarcoma-associated herpesvirus and Kaposi's sarcoma in Africa. Uganda Kaposi's Sarcoma Study Group. *Arch.Intern.Med.* **156**, 202.
- Chatlynne, L. G., Lapps, W., Handy, M., *et al.* (1998). Detection and titration of human herpesvirus-8-specific antibodies in sera from blood donors, acquired immunodeficiency syndrome patients, and Kaposi's sarcoma patients using a whole virus enzyme-linked immunosorbent assay. *Blood.* **92**, 53.
- Cockburn, I. (1987). Assessment of the risks of malignancy and lymphomas developing in patients using Sandimmune. *Transplant.Proc.* **19**, 1804.
- Cockburn, I. T. and Krupp, P. (1989). The risk of neoplasms in patients treated with cyclosporine A. *J.Autoimmun.* **2**, 723.

- Collandre, H., Ferris, S., Grau, O., Montagnier, L., and Blanchard, A. (1995). Kaposi's sarcoma and new herpesvirus [letter]. *Lancet*. **345**, 1043.
- Corbellino, M., Parravicini, C., Aubin, J. T., and Berti, E. (1996a). Kaposi's sarcoma and herpesvirus-like DNA sequences in sensory ganglia [letter]. *N.Engl.J.Med.* **334**, 1341.
- Corbellino, M., Poirel, L., Bestetti, G., et al. (1996b). Restricted tissue distribution of extralesional Kaposi's sarcoma-associated herpesvirus-like DNA sequences in AIDS patients with Kaposi's sarcoma. *AIDS Res Hum.Retroviruses*. **12**, 651.
- Dictor, M. and Jarplid, B. (1988). The cause of Kaposi's sarcoma: an avian retroviral analog. *J.Am.Acad.Dermatol.* **18**, 398.
- Dictor, M., Rambech, E., Way, D., Witte, M., and Bendsoe, N. (1996). Human herpesvirus 8 (Kaposi's sarcoma-associated herpesvirus) DNA in Kaposi's sarcoma lesions, AIDS Kaposi's sarcoma cell lines, endothelial Kaposi's sarcoma simulators, and the skin of immunosuppressed patients. *Am.J.Pathol.* **148**, 2009.
- Dobozy, A., Husz, S., Hunyadi, J., Berko, G., and Simon, N. (1973). Immune deficiencies and Kaposi's sarcoma. *Lancet*. **2**, 625.
- Dupin, N., Grandadam, M., Calvez, V., et al. (1995). Herpesvirus-like DNA sequences in patients with Mediterranean Kaposi's sarcoma [see comments]. *Lancet*. **345**, 761.
- Editorial. (1973). Kaposi's sarcoma. *Lancet*. 300.
- Engelbrecht, S., Treurnicht, F., Schneider, J., et al. (1997). Detection of human herpes virus 8 DNA and sequence polymorphism in classical, epidemic, and iatrogenic Kaposi's sarcoma in South Africa. *J.Med.Virol.* **52**, 168.
- Engelbrecht, S. and Van Rensburg, E. J. (1995). Detection of southern African human immunodeficiency virus type 1 subtypes by polymerase chain reaction: evaluation of different primer pairs and conditions. *J.Virol.Methods*. **55**, 391.
- Ensoli, B., Barillari, G., and Gallo, R. C. (1991). Pathogenesis of AIDS-associated Kaposi's sarcoma. *Haem.Onco.Clin.No.Am.* **5**, 281.
- Ensoli, B., Barillari, G., and Gallo, R. C. (1992). Cytokines and growth factors in the pathogenesis of AIDS-associated Kaposi's sarcoma. *Immunol.Rev.* **127**, 147.
- Ensoli, B., Barillari, G., Salahuddin, S. Z., Gallo, R. C., and Wong-Staal, F. (1990). Tat protein of HIV-1 stimulates growth of cells derived from Kaposi's sarcoma lesions of AIDS patients. *Nature*. **345**, 84.

- Ensoli, B., Buonaguro, L., Barillari, G., *et al.* (1993). Release, uptake, and effects of extracellular human immunodeficiency virus type 1 Tat protein on cell growth and viral transactivation. *J.Virol.* **67**, 277.
- Ensoli, B., Gendelman, R., Markham, P., *et al.* (1994a). Synergy between basic fibroblast growth factor and HIV-1 Tat protein in induction of Kaposi's sarcoma. *Nature.* **371**, 674.
- Ensoli, B., Markham, P., Kao, V., *et al.* (1994b). Block of AIDS-Kaposi's sarcoma (Kaposi's sarcoma) cell growth, angiogenesis, and lesion formation in nude mice by antisense oligonucleotide targeting basic fibroblast growth factor. A novel strategy for the therapy of Kaposi's sarcoma. *J.Clin.Invest.* **94**, 1736.
- Ensoli, B., Nakamura, S., Salahuddin, S. Z., *et al.* (1989). AIDS-Kaposi's sarcoma-derived cells express cytokines with autocrine and paracrine growth effects. *Science.* **243**, 223.
- Ensoli, B. and Sirianni, M. C. (1998a). Kaposi's sarcoma pathogenesis: a link between immunology and tumor biology. *Crit Rev Oncog.* **9**, 107.
- Ensoli, B. and Stürzl, M. (1998b). Kaposi's sarcoma: a result of the interplay among inflammatory cytokines, angiogenic factors and viral agents. *Cytokine Growth Factor Rev.* **9**, 63.
- Fagiolo, U., Cossarizza, A., Scala, E., *et al.* (1993). Increased cytokine production in mononuclear cells of healthy elderly people. *Eur.J.Immunol.* **23**, 2375.
- Fife, K. and Bower, M. (1996). Recent insights into the pathogenesis of Kaposi's sarcoma. *Br.J Cancer.* **73**, 1317.
- Fiorelli, V., Gendelman, R., Samaniego, F., Markham, P. D., and Ensoli, B. (1995). Cytokines from activated T cells induce normal endothelial cells to acquire the phenotypic and functional features of AIDS-Kaposi's sarcoma spindle cells. *J.Clin.Invest.* **95**, 1723.
- Fiorelli, V., Gendelman, R., Sirianni, M. C., *et al.* (1998). γ -Interferon produced by CD8+ T cells infiltrating Kaposi's sarcoma induces spindle cells with angiogenic phenotype and synergy with human immunodeficiency virus-1 Tat protein: an immune response to human herpesvirus-8 infection? *Blood.* **91**, 956.
- Fiorelli, V., Markham, P., Gendelman, R., and Ensoli, B. (21995). Cytokines from activated T cells induce normal endothelial cells to acquire the phenotypic and

- functional features of AIDS-Kaposi's sarcoma spindle cells. *J.Clin.Invest.* **95**, 1723.
- Franceschi, S., Dal Maso, L., Serraino, D., Lo, Re A., and La Vecchia, C. (1998). Increasing incidence of AIDS among women [letter]. *JAMA.* **279**, 354.
- Franceschi, S., Rezza, G., Serraino, D., Cozzi, Lepri A., Geddes, M., and Cote, T. (1995). Risk for Kaposi's sarcoma among Italian women with AIDS [letter]. *J.Acquir.Immune.Defic.Syndr.Hum.Retrovirol.* **9**, 313.
- Friedman-Birnbaum, R., Bergman, R., Bitterman-Deutsch, O., Weltfriend, S., and Lichtig, C. (1993). Classic and iatrogenic Kaposi's sarcoma. Histopathological patterns as related to clinical course. *Am.J.Dermatopathol.* **15**, 523.
- Friedman-Kien, A. E. (1981). Disseminated Kaposi's sarcoma syndrome in young homosexual men. *J.Am.Acad.Dermatol.* **5**, 468.
- Friedman-Kien, A. E., Laubenstein, L. J., Rubinstein, P. , *et al.* (1982). Disseminated Kaposi's sarcoma in homosexual men. *Ann.Intern.Med.* **96**, 693.
- Friedman-Kien, A. E., Saltzman, B. R., Cao, Y. Z., *et al.* (1990). Kaposi's sarcoma in HIV-negative homosexual men [letter] [see comments]. *Lancet.* **335**, 168.
- Gallo, R. C. (1995). Human retroviruses in the second decade: a personal perspective. *Nat.Med.* **1**, 753.
- Galy, A. H. and Spits, H. (1992). CD40 is functionally expressed on human thymic epithelial cells. *J.Immunol.* **149**, 775.
- Ganem, Don. (1995). Viruses, cytokines and Kaposi's sarcoma. *Curr.Biol.* **5**, 469.
- Gao, S-J., Kingsley, L., Hoover, D. R., *et al.* (1996a). Seroconversion to antibodies against Kaposi's sarcoma-associated herpesvirus-related latent nuclear antigens before the development of Kaposi's sarcoma. *N.Engl.J.Med.* **335**, 233.
- Gao, S. J., Kingsley, L., Li, M., *et al.* (1996b). Kaposi's sarcomaHV antibodies among Americans, Italians and Ugandans with and without Kaposi's sarcoma [see comments]. *Nat.Med.* **2**, 925.
- Garcia, A., Olivella, F., Valderrama, S., and Rodriguez, G. (1989). Kaposi's sarcoma in Colombia. *Cancer.* **64**, 2393.
- Gill, P. S., Loureiro, C., Bernstein, Singer M., Rarick, M. U., Sattler, F., and Levine, A. M. (1989). Clinical effect of glucocorticoids on Kaposi sarcoma related to the acquired immunodeficiency syndrome (AIDS). *Ann.Intern.Med.* **110**, 937.

- Giraldo, G., Beth, E., Coeur, P., Vogel, C. L., and Dhru, D. S. (1972b). Kaposi's sarcoma: a new model in the search for viruses associated with human malignancies. *J.Natl Cancer Inst.* **49**, 1495.
- Giraldo, G., Beth, E., and Haguenu, F. (1972a). Herpes-type virus particles in tissue culture of Kaposi's sarcoma from different geographic regions. *J.Natl Cancer Inst.* **49**, 1509.
- Giraldo, G., Beth, E., Kourilsky, F. M., *et al.* (1975). Antibody patterns to herpesviruses in Kaposi's sarcoma: serological association of european kaposi's sarcoma with cytomegalovirus. *Int.J.Cancer.* **15**, 839.
- Giraldo, G., Buonaguro, F. M., and Beth, Giraldo E. (1989). The role of opportunistic viruses in Kaposi's sarcoma (Kaposi's sarcoma) evolution. *APMIS Suppl.* **8**, 62.
- Goedert, J. J., Biggar, R. J., Melbye, M., *et al.* (1987). Effect of T4 count and cofactors on the incidence of AIDS in homosexual men infected with human immunodeficiency virus. *JAMA.* **257**, 331.
- Goriano, V., Hewlett, I., Friedman-Kien, A. E., Tor, J., Huang, Y., and Epstein, J. (1991). Definitve exclusion of HIV infection in a Kaposi's sarcoma bisexual man: Suggestions on a pathogenic model of Kaposi's sarcoma. *Int.Conf.AIDS.* **96**, 78.
- Gottlieb, G. J. and Ackerman, A. B. (1982). Kaposi's sarcoma: an extensively disseminated form in young homosexual men. *Hum.Pathol.* **13**, 882.
- Gottlieb, G. J., Ragaz, A., Vogel, J. V., *et al.* (1981). A preliminary communication on extensively disseminated Kaposi's sarcoma in young homosexual men. *Am.J.Dermatopathol.* **3**, 111.
- Goust, J-M. and Bierer, B. (1993). Cell-mediated immunity. *In* Introduction to medical immunology, 3rd ed. (Virella, G., eds.), p.187, Marcel Dekker, New York.
- Gyorkey, F., Sinkovics, J. G., Melnick, J. L., and Gyorkey, P. (1984). Retroviruses in Kaposi-sarcoma cells in AIDS [letter]. *N.Engl.J.Med.* **311**, 1183.
- Harawi, S. J. (1989). Kaposi's sarcoma. *In* Pathology and pathophysiology of AIDS and HIV-related disease, (Harawi, S. J. and O'Hara, C. J., eds.), p.83, CV Mosby, St Louis.
- Harrington, W., Jr., Sieczkowski, L., Sosa, C., *et al.* (1997). Activation of HHV-8 by HIV-1 tat [letter]. *Lancet.* **349**, 774.
- Harwood, A. R., Osoba, D, Hofstader, Sophie. L, *et al.* (1979b). Kaposi's sarcoma in recipients of renal transplants. *Am.J.Med.* **67**, 759.

- Harwood, A. R., Osoba, D., Hofstader, S. L., *et al.* (1979a). Kaposi's sarcoma in recipients of renal transplants. *Am.J.Med.* **67**, 759.
- Hashimoto, H., Muller, H., Muller, F., Schmidts, H. L., and Stutte, H. J. (1987). In situ hybridization analysis of cytomegalovirus lytic infection in Kaposi's sarcoma associated with AIDS. A study of 14 autopsy cases. *Virchows Arch.A Pathol.Anat.Histopathol.* **411**, 441.
- Hollenbaugh, D., Mischel-Petty, N., Edwards, C. P., *et al.* (1995). Expression of functional CD40 by vascular endothelial cells. *J.Exp.Med.* **182**, 33.
- Huang, Y. Q., Li, J. J., Kaplan, M. H., *et al.* (1995b). Human herpes-like nucleic acid in various forms of Kaposi's sarcoma. *Lancet.* **345**, 759.
- Huang, Y. Q., Li, J. J., Kaplan, M. H., *et al.* (1995a). Human herpesvirus-like nucleic acid in various forms of Kaposi's sarcoma [see comments]. *Lancet.* **345**, 759.
- Huang, Y. Q., Li, J. J., Rush, M. G., *et al.* (1992). HPV-16-related DNA sequences in Kaposi's sarcoma. *Lancet.* **339**, 515.
- Hymes, K. B., Cheung, T., Greene, J. B., *et al.* (1981). Kaposi's sarcoma in homosexual men-a report of eight cases. *Lancet.* **2**, 598.
- Karmann, K., Hughes, C. C., Schechner, J., Fanslow, W. C., and Pober, J. S. (1995). CD40 on human endothelial cells: inducibility by cytokines and functional regulation of adhesion molecule expression. *Proc.Natl.Acad.Sci.U.S.A.* **92**, 4342.
- Katz, M. H., Hessel, N. A., Buchbinder, S. P., Hirozawa, A., O'Malley, P., and Holmberg, S. D. (1994). Temporal trends of opportunistic infections and malignancies in homosexual men with AIDS. *J.Infect.Dis.* **170**, 198.
- Kedes, D. H., Operskalski, E., Busch, M., Kohn, R., Flood, J., and Ganem, D. (1996). The seroepidemiology of human herpesvirus 8 (Kaposi's sarcoma-associated herpesvirus): distribution of infection in Kaposi's sarcoma risk groups and evidence for sexual transmission [published erratum appears in Nat Med 1996 Sep;2(9):1041]. *Nat.Med.* **2**, 918.
- Kempf, W., Adams, V., Pfaltz, M., *et al.* (1995). Human herpesvirus type 6 and cytomegalovirus in AIDS-associated Kaposi's sarcoma: no evidence for an etiological association. *Hum.Pathol.* **26**, 914.
- Kestens, L., Melbye, M., Biggar, R. J., *et al.* (1985). Endemic African Kaposi's sarcoma is not associated with immunodeficiency. *Int.J.Cancer.* **36**, 49.

- Klein, M. R., Keet, I. P., D'Amaro, J., *et al.* (1994). Associations between HLA frequencies and pathogenic features of human immunodeficiency virus type 1 infection in seroconverters from the Amsterdam cohort of homosexual men. *J.Infect.Dis.* **169**, 1244.
- Kwok, S. and Higuchi, R. (1989). Avoiding false positives with PCR [published erratum appears in Nature 1989 Jun 8;339(6224):490]. *Nature.* **339**, 237.
- Lafrenie, R. M., Wahl, L. M., Epstein, J. S., Hewlett, I. K., Yamada, K. M., and Dhawan, S. (1996). HIV-1-Tat protein promotes chemotaxis and invasive behavior by monocytes. *J.Immunol.* **157**, 974.
- Lebbe, C., de Cremoux, P., Ryobjad, M., Costa da Cunha, C., Morel, P., and Calvo, F. (1995). Kaposi's sarcoma and new herpesvirus [letter]. *Lancet.* **345**, 1180.
- Levy, J. A. (1997). Three new human herpesviruses (HHV6, 7, and 8). *Lancet.* **349**, 558.
- Levy, J. A. and Ziegler, J. L. (1983). Acquired immunodeficiency syndrome is an opportunistic infection and Kaposi's sarcoma results from secondary immune stimulation. *Lancet.* **2**, 78.
- Li, J. J., Huang, Y. Q., Cockerell, C. J., and Friedman-Kien, A. E. (1996). Localization of human herpes-like virus type 8 in vascular endothelial cells and perivascular spindle-shaped cells of Kaposi's sarcoma lesions by in situ hybridization. *Am.J.Pathol.* **148**, 1741.
- Lifson, A. R., Darrow, W. W., Hessel, N. A., *et al.* (1990). Kaposi's sarcoma in a cohort of homosexual and bisexual men. Epidemiology and analysis for cofactors. *Am.J.Epidemiol.* **131**, 221.
- Lisitsyn, N., Lisitsyn, N., and Wigler, M. (1993). Cloning the differences between two complex genomes. *Science.* **259**, 946.
- Maiorana, A., Luppi, M., Barozzi, P., Collina, G., Fano, R. A., and Torelli, G. (1997). Detection of human herpes virus type 8 DNA sequences as a valuable aid in the differential diagnosis of Kaposi's sarcoma. *Mod.Pathol.* **10**, 182.
- Mann, D. L., Murray, C., Yarchoan, R., Blattner, W. A., and Goedert, J. J. (1988). HLA antigen frequencies in HIV-1 seropositive disease-free individuals and patients with AIDS. *J.Acquir.Immune.Defic.Syndr.* **1**, 13.

- Mannucci, P. M., Quattrone, P., and Maturri, L. (1986). Kaposi's sarcoma without human immunodeficiency virus antibody in a hemophiliac [letter]. *Ann.Intern.Med.* **105**, 466.
- Mantovani, A., Bussolino, F., and Introna, M. (1997). Cytokine regulation of endothelial cell function: from molecular level to the bedside. *Immunol.Today.* **18**, 231.
- Martin, R. W. III, Hood, A., and Farmer, E. R. (1993). Kaposi's sarcoma. *Medicine Baltimore.* **72**, 245.
- Master, S. P., Taylor, J. F., Kyalwazi, S. K., and Ziegler, J. L. (1970). Immunological studies in Kaposi's sarcoma in Uganda. *Br.Med.J.* **1**, 600.
- Melbye, M., Kestens, L., Biggar, R. J., Schreuder, G. M., and Gigase, P. L. (1987). HLA studies of endemic African Kaposi's sarcoma patients and matched controls: no association with HLA-DR5. *Int.J.Cancer.* **39**, 182.
- Memar, O. M., Rady, P. L., and Tying, S. K. (1995). Human herpesvirus-8: detection of novel herpesvirus-like DNA sequences in Kaposi's sarcoma and other lesions. *J.Mol.Med.* **73**, 603.
- Miles, S. A. (1994). Pathogenesis of HIV-related Kaposi's sarcoma. *Curr.Opin.Oncol.* **6**, 497.
- Miles, S. A., Martinez, Maza O., Rezai, A., *et al.* (1992). Oncostatin M as a potent mitogen for AIDS-Kaposi's sarcoma-derived cells. *Science.* **255**, 1432.
- Miller, G., Rigsby, M. O., Heston, L., *et al.* (1996). Antibodies to butyrate-inducible antigens of Kaposi's sarcoma-associated herpesvirus in patients with HIV-1 infection. *N.Engl.J.Med.* **334**, 1292.
- Mitsuyasu, R. T., Taylor, J. M., Glaspy, J., and Fahey, J. L. (1986). Heterogeneity of epidemic Kaposi's sarcoma. Implications for therapy. *Cancer.* **57**, 1657.
- Moertel, C. G. (1966). Multiple primary malignant neoplasia: Their incidence and significance. Springer-Verlag, New York.
- Monini, P., Colombini, S., Stürzl, M., *et al.* (1999). Reactivation and persistence of human herpesvirus-8 infection in B cells and monocytes by Th-1 cytokines increased in Kaposi's sarcoma. *Blood.* **93**, 4044.
- Monini, P., de Lellis, L., Fabris, M., Rigolin, F., and Cassai, E. (1996). Kaposi's sarcoma-associated herpesvirus DNA sequences in prostate tissue and human semen. *N.Engl.J.Med.* **334**, 1168.

- Montagnino, G., Bencini, P. L., Tarantino, A., Caputo, R., and Ponticelli, C. (1994). Clinical features and course of Kaposi's sarcoma in kidney transplant recipients: report of 13 cases. *Am.J.Nephrol.* **14**, 121.
- Moore, P. S., Boshoff, C., Weiss, R. A., and Chang, Y. (1996c). Molecular mimicry of human cytokine and cytokine response pathway genes by Kaposi's sarcomaHV. *Science.* **274**, 1739.
- Moore, P. S. and Chang, Y. (1995). Detection of herpesvirus-like DNA sequences in Kaposi's sarcoma in patients with and those without HIV infection. *N.Engl.J.Med.* **332**, 1181.
- Moore, P. S., Gao, S-J., Dominguez, D., *et al.* (1996a). Primary characterisation of a herpes agent associated with Kaposi's sarcoma. *J.Virol.* **70**, 549.
- Moore, P. S., Kingsley, L. A., Holmberg, S. D., *et al.* (1996b). Kaposi's sarcoma-associated herpesvirus infection prior to onset of Kaposi's sarcoma. *AIDS.* **10**, 175.
- Motokura, T. and Arnold, A. (1993b). Cyclin D and oncogenesis. *Curr.Opin.Genet.Dev.* **3**, 5.
- Motokura, T. and Arnold, A. (1993a). Cyclins and oncogenesis. *Biochim.Biophys.Acta.* **1155**, 63.
- Murakami-Mori, K., Taga, T., Kishimoto, T., and Nakamura, S. (1995). AIDS-associated Kaposi's sarcoma (Kaposi's sarcoma) cells express oncostatin M (OM)- specific receptor but not leukemia inhibitory factor/OM receptor or interleukin-6 receptor. Complete block of OM-induced Kaposi's sarcoma cell growth and OM binding by anti-gp130 antibodies. *J.Clin.Invest.* **96**, 1319.
- Myskowski, P. L. and Ahkami, R. (1997). Advances in Kaposi's sarcoma. *Dermatol.Clin.* **15**, 177.
- Nador, R. G., Cesarman, E., Chadburn, A., *et al.* (1996). Primary effusion lymphoma: a distinct clinicopathologic entity associated with the Kaposi's sarcoma-associated herpes virus. *Blood.* **88**, 645.
- Nair, B. C., DeVico, A. L., Nakamura, S., *et al.* (1992). Identification of a major growth factor for AIDS-Kaposi's sarcoma cells as oncostatin M. *Science.* **255**, 1430.

- Nakamura, S., Salahuddin, S. Z., Biberfeld, P., *et al.* (1988). Kaposi's sarcoma cells: long-term culture with growth factor from retrovirus-infected CD4+ T cells. *Science*. **242**, 426.
- Neipel, F., Albrecht, J. C., and Fleckenstein, B. (1997). Cell-homologous genes in the Kaposi's sarcoma-associated rhadinovirus human herpesvirus 8: determinants of its pathogenicity? *J. Virol.* **71**, 4187.
- Nickoloff, B. J. and Foreman, K. E. (1996). Charting a new course through the chaos of Kaposi's sarcoma. *Am.J.Pathol.* **148**, 1323.
- Noel, J-C., Hermans, P., Andre, J., *et al.* (1996). Herpes-like DNA sequences and Kaposi's sarcoma. *Cancer*. **77**, 2132.
- Noel, J-C. (1995). Kaposi's sarcoma and Kaposi's sarcomaHV [letter; comment]. *Lancet*. **346**, 1359.
- Northfelt, D. W. (1994). AIDS-related Kaposi's sarcoma: still a problem, still an opportunity [editorial]. *J.Clin.Oncol.* **12**, 1109.
- O'Leary, J. J., Kennedy, M. M., and McGee, J. O'D. (1997). Kaposi's sarcoma associated herpes virus (Kaposi's sarcomaHV/HHV 8):epidemiology,molecular biology and tissue distribution. *J.Clin.Pathol:Mol.Pathol.* **50**, 4.
- Orenstein, J. M., Alkan, S., Blauvelt, A., *et al.* (1997). Visualization of human herpesvirus type 8 in Kaposi's sarcoma by light and transmission electron microscopy. *AIDS*. **11**, F35.
- Pammer, J, Plettenberg, A., Weninger, W., *et al.* (1996). CD40 antigen is expressed by endothelial cells and tumor cells in Kaposi's sarcoma. *Am.J.Pathol.* **148**, 1387.
- Pedagagos, E., Nicholls, K., Dowling, J., and Becker, G. (1994). Kaposi's sarcoma post renal transplant. *Aust.NZ.J.Med.* **24**, 722.
- Penn, I. (1979b). Kaposi's sarcoma in organ transplant recipients. *Transplantation*. **27**, 8.
- Penn, I. (1979a). Kaposi's sarcoma in organ transplant recipients: report of 20 cases. *Transplantation*. **27**, 8.
- Qunibi, W., Akhtar, M., Sheth, K., *et al.* (1988). Kaposi's sarcoma: The most common tumor after renal transplantation in Saudi Arabia. *Am.J.Med.* **84**, 225 .
- Rady, P. L., Yen, A., Rollefson, J. L., *et al.* (1995). Herpesvirus-like DNA sequences in non-Kaposi's sarcoma skin lesions of transplant patients. *Lancet*. **345**, 1339.


- Rainbow, L., Platt, G. M., Simpson, G. R., *et al.* (1997). The 222- to 234-kilodalton latent nuclear protein (LNA) of Kaposi's sarcoma-associated herpesvirus (human herpesvirus 8) is encoded by orf73 and is a component of the latency-associated nuclear antigen. *J.Virol.* **71**, 5915.
- Rappersberger, K., Tschachler, E., Zonzits, E., *et al.* (1990). Endemic Kaposi's sarcoma in human immunodeficiency virus type 1-seronegative persons: demonstration of retrovirus-like particles in cutaneous lesions. *J.Invest Dermatol.* **95**, 371.
- Renne, R., Lagunoff, M., Zhong, W., and Ganem, D. (1996b). The size and conformation of Kaposi's sarcoma-associated herpesvirus (human herpesvirus 8) DNA in infected cells and virions. *J.Virol.* **70**, 8151.
- Renne, R., Zhong, W., Herndier, B., *et al.* (1996a). Lytic growth of Kaposi's sarcoma-associated herpesvirus (human herpesvirus 8) in culture. *Nat.Med.* **2**, 342.
- Rettig, M. B., Ma, H. J., Vescio, R. A., *et al.* (1997). Kaposi's sarcoma-associated herpesvirus infection of bone marrow dendritic cells from multiple myeloma patients [see comments]. *Science.* **276**, 1851.
- Rizzardini, G., Piconi, S., Ruzzante, S., *et al.* (1996). Immunological activation markers in the serum of African and European HIV-seropositive and seronegative individuals. *AIDS.* **10**, 1535.
- Roitt, I. M. (1991). *Essential Immunology*, 7th Ed, Blackwell, Oxford.
- Roizman, B. (1995). New viral footprints in Kaposi's sarcoma [editorial]. *N.Engl.J.Med.* **332**, 1227.
- Root-Bernstein, R. S. (1990). AIDS and Kaposi sarcoma pre-1979 [letter; comment]. *Lancet.* **335**, 969.
- Roth, W. K. (1991). HIV-associated Kaposi's sarcoma: new developments in epidemiology and molecular pathology [editorial]. *J.Cancer Res Clin.Oncol.* **117**, 186.
- Roth, W. K., Brandstetter, H., and Sturzl, M. (1992). Cellular and molecular features of HIV-associated Kaposi's sarcoma [editorial] [published erratum appears in *AIDS* 1992 Nov;6(11):following 1410]. *AIDS.* **6**, 895.
- Rubinstein, P., Rothman, W. M., and Friedman, Kien A. (1983). Immunologic and immunogenetic findings in patients with epidemic Kaposi's sarcoma. *Antibiot.Chemother.* **32**, 87.

- Russo, J. J., Bohenzky, R. A., Chien, M. C., *et al.* (1996). Nucleotide sequence of the Kaposi sarcoma-associated herpesvirus (HHV8). *Proc.Natl.Acad.Sci.U.S.A.* **93**, 14862.
- Safai, B. (1983). Clinical features of Kaposi's sarcoma/acquired immune deficiency syndrome and its management. *Antibiot.Chemother.* **32**, 54.
- Safai, B., Diaz, B., and Schwartz, J. (1992). Malignant neoplasms associated with human immunodeficiency virus infection [published erratum appears in *CA Cancer J Clin* 1992 Jul-Aug;42(4):254]. *CA Cancer J.Clin.* **42**, 74.
- Safai, B., Mike, V., Giraldo, G., Beth, E., and Good, R. A. (1980). Association of Kaposi's sarcoma with second primary malignancies: possible etiopathogenic implications. *Cancer.* **45**, 1472.
- Safai, B., Sarngadharan, M. G., Koziner, B., *et al.* (1985). Spectrum of Kaposi's sarcoma in the epidemic of AIDS. *Cancer Res.* **45**, 4646s.
- Saiki, R. K., Bugawan, T. L., Horn, G. T., Mullis, K. B., and Erlich, H. A. (1986). Analysis of enzymatically amplified beta-globin and HLA-DQ alpha DNA with allele-specific oligonucleotide probes. *Nature.* **324**, 163.
- Salahuddin, S. Z., Nakamura, S., Biberfeld, P., *et al.* (1988a). Angiogenic properties of Kaposi's sarcoma-derived cells after long-term culture in vitro. *Science.* **242**, 430.
- Salahuddin, S. Z., Nakamura, S., Biberfeld, P., *et al.* (1988b). Angiogenic properties of Kaposi's sarcoma-derived cells after long-term culture in vitro. *Science.* **242**, 430.
- Samaniego, F., Markham, P. D., Gallo, R. C., and Ensoli, B. (1995). Inflammatory cytokines induce AIDS-Kaposi's sarcoma-derived spindle cells to produce and release basic fibroblast growth factor and enhance Kaposi's sarcoma-like lesion formation in nude mice. *J.Immunol.* **154**, 3582.
- Samaniego, F., Markham, P. D., Gendelman, R., Gallo, R. C., and Ensoli, B. (1997). Inflammatory cytokines induce endothelial cells to produce and release basic fibroblast growth factor and to promote Kaposi's sarcoma-like lesions in nude mice. *J.Immunol.* **158**, 1887.
- Scala, G., Ruocco, M. R., Ambrosino, C., *et al.* (1994). The expression of the interleukin 6 gene is induced by the human immunodeficiency virus 1 TAT protein. *J.Exp.Med.* **179**, 961.

- Schalling, M., Ekman, M., Kaaya, E. E., Linde, A., and Biberfeld, P. (1995). A role for a new herpes virus (Kaposi's sarcomaHV) in different forms of Kaposi's sarcoma. *Nat.Med.* **1**, 707.
- Schatz, O., Bogner, J. R., and Goebel, F. D. (1997). Kaposi's sarcoma: is the hunt for the culprit over now? *J Mol.Med.* **75**, 28.
- Schulhafer, E. P., Grossman, M. E., Fagin, G., and Bell, K. E. (1987). Steroid-induced Kaposi's sarcoma in a patient with pre-AIDS. *Am.J.Med.* **82**, 313.
- Schulz, T. F. and Weiss, R. A. (1995). Kaposi's sarcoma. A finger on the culprit [news]. *Nature.* **373**, 17.
- Schwartz, R. A. (1996). Kaposi's sarcoma: advances and perspectives. *J Am Acad.Dermatol.* **34**, 804 .
- Scinicariello, F., Rady, P., Cloyd, M. W., and Tyring, S. K. (1991). HPV 18 in HIV-associated Kaposi's sarcoma [letter]. *Lancet.* **337**, 501.
- Sears, A. E. (1990). Mechanisms of restriction of viral gene expression during herpes simplex virus latency. *Adv.Exp Med.Biol.* **278**, 211.
- Serraino, D., Franceschi, S., Dal Maso, L., and La Vecchia, C. (1995). HIV transmission and Kaposi's sarcoma among European women. *AIDS.* **9**, 971.
- Siddiqui, A. (1983). Hepatitis B virus DNA in Kaposi sarcoma. *Proc.Natl Acad.Sci.U.S.A.* **80**, 4861.
- Siegal, B., Levinton, Kriss S., Schiffer, A., et al. (1990). Kaposi's sarcoma in immunosuppression. Possibly the result of a dual viral infection. *Cancer.* **65**, 492.
- Sirianni, M. C., Uccini, S., Angeloni, A., Faggioni, A., Cottoni, F., and Ensoli, B. (1997). Circulating spindle cells: correlation with human herpesvirus-8 (HHV-8) infection and Kaposi's sarcoma [letter]. *Lancet.* **349**, 255.
- Sirianni, M. C., Vincenzi, L., Fiorelli, V., et al. (1998). γ -Interferon production in peripheral blood mononuclear cells and tumor infiltrating lymphocytes from Kaposi's sarcoma patients: correlation with the presence of human herpesvirus-8 in peripheral blood mononuclear cells and lesional macrophages. *Blood.* **91**, 968.
- Soulier, J., Grollet, L., Oksenhendler, E., et al. (1995). Kaposi's sarcoma-associated herpesvirus-like DNA sequences in multicentric Castleman's disease [see comments]. *Blood.* **86**, 1276.

- Spornraft, P., Froschl, M., Ring, J., *et al.* (1988). T4/T8 ratio and absolute T4 cell numbers in different clinical stages of Kaposi's sarcoma in AIDS. *Br.J.Dermatol.* **119**, 1.
- Stamenkovic, I., Clark, E. A., and Seed, B. (1989). A B-lymphocyte activation molecule related to the nerve growth factor receptor and induced by cytokines in carcinomas. *EMBO J.* **8**, 1403.
- Staskus, K. A., Zhong, W., Gebhard, K., *et al.* (1997). Kaposi's sarcoma-associated herpesvirus gene expression in endothelial (spindle) tumor cells. *J.Virol.* **71**, 715.
- Strathdee, S. A., Veugeliers, P. J., and Moore, P. S. (1996). The epidemiology of HIV-associated Kaposi's sarcoma: the unraveling mystery. *AIDS.* **10** Suppl A, S51.
- Strömblad, S. and Cheresh, D. A. (1996). Integrins, angiogenesis and vascular cell survival. *Chem.Biol.* **3**, 881.
- Stürzl, M., Blasig, C., Schreier, A., *et al.* (1997). Expression of HHV-8 latency-associated T0.7 RNA in spindle cells and endothelial cells of AIDS-associated, classical and African Kaposi's sarcoma. *Int.J.Cancer.* **72**, 68.
- Stürzl, M., Brandstetter, H., Zietz, C., *et al.* (1995). Identification of interleukin-1 and platelet-derived growth factor-B as major mitogens for the spindle cells of Kaposi's sarcoma: a combined in vitro and in vivo analysis. *Oncogene.* **10**, 2007.
- Stürzl, M. and Ensoli, B. (1999). Big but weak: how many pathogenic genes does human herpesvirus-8 need to cause Kaposi's sarcoma? (Review). *Int.J.Oncol.* **14**, 287.
- Su, I. J., Hsu, Y. S., Chang, Y. C., and Wang, I. W. (1995). Herpesvirus-like DNA sequence in Kaposi's sarcoma from AIDS and non-AIDS patients in Taiwan [letter]. *Lancet.* **345**, 722.
- Taylor, J. F., Smith, P. G., Bull, D., and Pike, M. C. (1972). Kaposi's sarcoma in Uganda: geographic and ethnic distribution. *Br.J.Cancer.* **26**, 483.
- Trattner, A., Hodak, E., David, M., and Sandbank, M. (1993). The appearance of Kaposi's sarcoma during corticosteroid therapy. *Cancer.* **72**, 1779.
- Van Rensburg, E. J., Engelbrecht, S., Van Heerden, W. F., Raubennheimer, E. J., and Schoub, B. D. (1996). Human papillomavirus DNA in oral squamous cell carcinomas from an African population sample. *Anticancer Res.* **16**, 969.

- Vogel, J., Hinrichs, S. H., Reynolds, R. K., Luciw, P. A., and Jay, G. (1988). The HIV *tat* gene induces dermal lesions resembling Kaposi's sarcoma in transgenic mice. *Nature*. **335**, 606.
- Walter, P. R., Philippe, E., Nguemby, Mbina C., and Chamlian, A. (1984). Kaposi's sarcoma: presence of herpes-type virus particles in a tumor specimen. *Hum.Pathol.* **15**, 1145.
- Wang, F., Gregory, C., Sample, C., *et al.* (1990). Epstein-Barr virus latent membrane protein (LMP1) and nuclear proteins 2 and 3C are effectors of phenotypic changes in B lymphocytes: EBNA-2 and LMP1 cooperatively induce CD23. *J.Virol.* **64**, 2309.
- Wang, R. Y., Shih, J. W., Weiss, S. H., *et al.* (1993). Mycoplasma penetrans infection in male homosexuals with AIDS: high seroprevalence and association with Kaposi's sarcoma. *Clin.Infect.Dis.* **17**, 724.
- Weiss, R. A. (1996). Human herpesvirus 8 in lymphoma and Kaposi's sarcoma: now the virus can be propagated. *Nat.Med.* **2**, 277.
- Weiss, R. A., Whitby, D., Talbot, S., Kellam, P., and Boshoff, C. (1998). Human herpesvirus type 8 and Kaposi's sarcoma. *J Natl.Cancer Inst.Monogr.* **51**.
- Whitby, D., Howard, M. R., Tenant-Flowers, M., *et al.* (1995). Detection of Kaposi's sarcoma associated herpesvirus in peripheral blood of HIV-infected individuals and progression to Kaposi's sarcoma. *Lancet.* **346**, 799.
- Zauli, G., Gibellini, D., Caputo, A., *et al.* (1995). The human immunodeficiency virus type-1 Tat protein upregulates Bcl-2 gene expression in Jurkat T-cell lines and primary peripheral blood mononuclear cells. *Blood.* **86**, 3823.
- Ziegler, J. L. (1990). Kaposi's sarcoma: Introduction and overview. *J.Acquir.Immun.Defic.Dis.* **3**, S1.



SECTION 3

J E Murray (1919-)

Chapter 15

THE IMMUNE SYSTEM IN KAPOSI'S SARCOMA

Tumour immunology is the grandfather of transplant immunology but is also its grandchild.

George Klein

The immune system plays an integral role in the development of malignancies. The exact role however remains the subject of debate. The first person to implicate the immune system in malignancies was Paul Ehrlich who stated, “. . . in the enormously complicated course of foetal and post-foetal development aberrant cells become unusually common. Fortunately in the majority of people, they remain latent thanks to the organism's positive mechanisms” (Ehrlich, 1957). Ehrlich implied that the latter was immunity and went on to predict that a depressed immune response “allows the rapid, parasitic growth of malignant cells”. This led Thomas (1959) to formulate a concept that was elaborated by Burnet (1970) into the theory of immunological surveillance. The basic tenet of the theory is that tumour cells are destroyed by the immune system in the early stages of tumour formation. Tumour cells present unique antigenic material to the immune system

and are therefore targeted by the same response that destroys grafts of foreign cells (Prehn *et al.*,1971). Both laboratory and clinical data support this concept:

- Mice treated with anti-lymphocytic serum and infected with an oncogenic virus develop a marked propensity for malignancies (Hirsch *et al.*,1968;Schwartz,1975).
- The polyoma virus failed to induce neoplasms in healthy mice, but thymectomised animals readily developed malignancies. Restoration of immunologic competence by the addition of lymphocytes resulted in the elimination of the neoplastic lesions (Law,1969;Schwartz,1975).
- The marked increase in the incidence of malignancies in allograft recipients especially renal transplant patients is perhaps the strongest clinical evidence in favour of this theory (Penn,1990;Penn,1993a;Sheil *et al.*,1992;Sheil,1996).
- Postmortem studies indicated that a number of malignancies go undetected clinically (Shaheen *et al.*,1997) and a significant number of cadaveric organ donors are found to have undiagnosed malignancies (Stanta *et al.*,1997).
- Lymphoid infiltrates are a feature of many tumours, indicating a favourable prognosis (Wahl *et al.*,1974).
- Spontaneous regression of tumours may occur (Bodey *et al.*,1998;Castleberry,1997).
- Tumours occur more frequently when age, drugs or disease compromise the immune system (Beverley, 1998).

The immune surveillance theory however fails in several situations. According to the theory of immune surveillance, decreased immunity should be associated with an increased incidence of malignancy. This however is not a consistent occurrence. The cheek pouch of the Syrian hamster is used normally by the animal to store food, but is used in experimental situations to store allografts and even xenografts. Because this is an immunologically privileged site, grafts are retained indefinitely. The lack of any connection to the lymphatic system may play a role in inducing this immunologic privilege. According to the theory of immune surveillance this site

should be prone to many neoplasms of the mucous membrane and connective tissue lining, but this does not appear to be the case (Billingham *et al.*,1971). Other immunologically privileged sites, such as the cornea, the subcutaneous fat pad, and the matrix of new hair follicles are similarly not compromised by an increased tendency to develop neoplasms (Schwartz,1975).

The theory of immune surveillance also predicts an overall increased incidence of malignancies when the general immunity is depressed. This indeed is not always the case in either experimental or clinical situations. Nude mice fail to develop a thymus and are severely immunocompromised because of the absence of T-lymphocytes. Because of susceptibility to infections the lifespan of these mice is limited (Wortis,1971). When Outzen *et al.* (1975) were able to extend the life-expectancy of the nude mice by maintaining a germ-free environment, they found an increase exclusively of lymphoreticular malignancies. From a clinical aspect, Metlief and Schwartz (1975) reviewed the occurrence of cancers in patients suffering from primary immunodeficiency diseases. The incidence of cancers was 10%, which is considerably higher than expected. However, of the 58 cases of cancers in immunodeficient patients reported 93% were patients with defective cellular immunity. Lymphoreticular malignancies developed in 81% of the patients. In other reports, almost 70% of patients with primary immunodeficiency states suffered from a lymphoproliferative disorder (Mueller,1999;Penn,1994a). In renal transplant patients there is an increased incidence of certain malignancies, particularly epithelial lesions of the skin and lip but more importantly of non-Hodgkin's lymphomas (Hoover *et al.*,1973;Mueller,1999). In acquired immunodeficiency syndrome (AIDS) patients non-Hodgkin's lymphomas and Kaposi's sarcoma are the commonest malignancies (Hermans, 1998; Scandinavian Study Group, 1997). The lesions that occur most commonly in the general population, carcinoma of the breast and lung do not appear to be any more common in immunosuppressed patients as would be predicted by the immune surveillance theory (Penn,1993b; Sheil,1992; Sheil,1996). There are experimental situations where depressed immunity may actually inhibit the development of certain neoplasms. Thymectomy at birth resulted in the reduction in the incidence of mammary carcinoma in a strain of mice that was prone to the lesion (Martinez,1964). The propensity for the malignancy was restored

when the immunity of mice was restored by the implantation of thymic tissue (Yunis *et al.*, 1969).

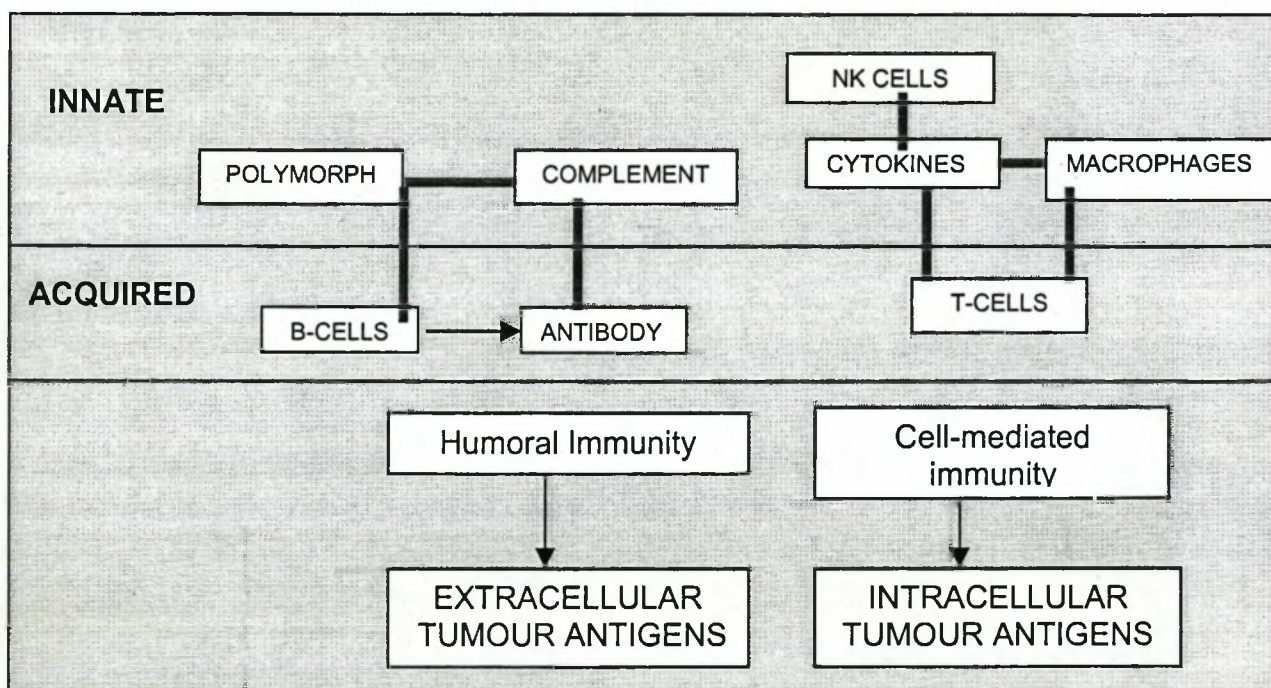
Common to both experimental and clinical examples of decreased immunity and spontaneous neoplasms is the development of lymphoreticular neoplasms. These lesions can arise because they are highly immunogenic and only when there is immunosuppression can they manifest: a prediction that would fit in with the immunosurveillance theory (Schwartz, 1975). Other factors that need to be taken into consideration are the effect of the continuous antigenic stimulation. In partially immunodeficient mice continuous antigenic stimulation triggers the development of lymphoreticular malignancies (Gleichmann *et al.*, 1975; Krueger, 1972; Prehn *et al.*, 1971). The renal transplant patient and the patient with acquired immunodeficiency syndrome (AIDS) represent the clinical equivalent of this experimental model with chronic immunosuppression associated with prolonged exposure to antigenic stimuli presented by the allograft and recurrent infections respectively (Bencini *et al.*, 1993; Penn, 1994a). In these circumstances defective immunoregulation could allow lymphocytes to proliferate unchecked following antigenic stimulation (Gil *et al.*, 1998).

The immune surveillance theory, although exciting, fails to explain the high incidence of all malignancies in renal transplant patients. The malignancies, which do occur more frequently, all have a putative viral aetiology (Mueller, 1999; Penn, 1981; Penn, 1994b). The surveillance of the immune system could therefore be more important in preventing the spread of potentially oncogenic viruses and it would seem that surveillance against malignant cells are relatively less effective (Purtilo *et al.*, 1984). Experimental data from animal studies support this view. Athymic nude mice or mice immunosuppressed with anti-lymphocyte serum did not show an increase in tumour frequency until they were infected with polyoma virus (Sinkovics, 1991).

IMMUNOLOGICAL RESPONSE TO MALIGNANT TRANSFORMATION

Our understanding of the nature of the malignant process is incomplete, as is the mechanism of human immune responses to malignant cells. Beside the immunosurveillance system postulated there are other mechanisms whereby the immune system protects the body against malignant antigens (Stevenson *et al.*,1993). The presence of tumour antigens activates a series of immunological defence reactions - both humoral and cellular, which entails the involvement of several components of the immune system (Fig. 15-1). Most of the responses in specific tumour immunity closely resemble the immunological responses to allograft rejection phenomena (Kniker and Bellanti, 1978; Shurin,1996). The responses are both innate and acquired. These include T-lymphocytes, B-lymphocytes, monocyte-macrophages, natural killer (NK) cells and a variety of soluble products that regulate the interaction of different components of the immune response (Roitt,1994; Delves *et al.*,2000). However, for the different components of the immune system to function efficiently the tumour cell has to be identified before it is eliminated. This recognition is achieved by expression on the surface of malignant cells of unique antigens that do not appear on normal cells (Urban *et al.*,1992).

Fig. 15-1. Immunological response to tumour antigens



Modified from Roitt (1991).

Tumour Antigens

Although the existence of these antigens have been known since the turn of the last century, there have been two recent discoveries which have advanced the understanding of the processes considerably (Roitt,1994). The first discovery is that of the role played by genes that code for predictable tumour-specific mutations. Both regulatory and structural genes are implicated (Urban *et al.*,1992). The second discovery, pertinent to this discussion is the demonstration that cytotoxic T-lymphocytes are able to recognise intracellular mutant proteins by virtue of the expression of peptides derived from these proteins being presented by major histocompatibility complex (MHC) molecules on the cell surface, (reviewed in Rowland-Jones *et al.*,1997). A variety of antigens have been identified which are expressed on surfaces of malignant cells.

Viral Antigens

Malignancies developing spontaneously in humans are induced by exposure to carcinogens, radiation injury or oncogenic viruses (Hall,1997;Poeschla *et al.*,1997;Yuspa *et al.*,1997). Viruses are increasingly being recognised to play a role in the aetiology of malignancies such that up to 20% of all human malignancies may result from viral infections (Dawson *et al.*,1989) (Table 15-1). The infecting viruses interact with and disrupt the structure and/or the function of normal DNA including

Table 15-1. *Known virus-associated malignancies.*

Virus	Cancer
Hepatitis B (HBV)	Hepatocellular carcinoma
Epstein Barr virus (EBV)	Non-Hodgkin's lymphoma Nasopharyngeal carcinoma Burkitt's lymphoma
Human papilloma virus (HPV16, HPV18)	Carcinoma of the cervix
Human T-cell lymphotropic virus (HTLV-1)	T-cell leukaemia
Human herpes virus-8 (HHV-8)	Kaposi's sarcoma

proto-oncogenes and tumour suppressor genes that play an important role in cellular proliferation and differentiation of normal cells (Stevenson *et al.*,1993). Experimental studies in animals have shown that malignant transformation can result from the integration of retroviral sequences that act as promoter for the transcription of normal cellular proto-oncogenes. In addition, viral integration into the host genome can produce structural mutations that result in the formation of tumour-specific antigens (Ashall *et al.*,1982;Fung *et al.*,1983;Milligan *et al.*,1991). These altered molecules do not contain any viral material, but viral peptides are expressed on the surface of the tumour cell. Here they are associated with MHC class I antigens (Townsend *et al.*,1989;Townsend *et al.*,1986) where they ultimately elicit a powerful rejection response from CD8⁺ cytotoxic cells (Doherty *et al.*,1974;Doherty *et al.*,1975;Zinkernagel *et al.*,1974). All tumours produced by an oncogenic virus share a common surface antigen (Roitt,1994). In this respect they differ from chemically induced cancers which induce immune responses to themselves but to no other tumour produced by the same carcinogen (Prehn *et al.*,1957;Roitt,1994). Beside the virally controlled antigens, there is a range of other antigens that can be expressed on the surface of tumour cells. These antigens may be classified into 3 categories:

1. Tumour Specific Antigens.

Recent evidence has indicated that structural mutations on oncogenes and suppressor genes can occur that result in the formation of mutant proteins that are tumour specific. Proto-oncogenes and suppressor genes play important roles in normal cellular proliferation and differentiation. When structural mutations occur they result in the formation of mutant proteins and thus contribute to the formation of a variety of human malignancies (Urban *et al.*,1992).

1.1 Point mutations

Both the activation of proto-oncogenes and the inactivation of suppressor genes may be caused by point mutations involving one or more nucleotides. Single point mutations in oncogenes can account for the large diversity of antigens found in cancer cells (Urban *et al.*,1992). The *ras* genes are an example of normal cellular genes that

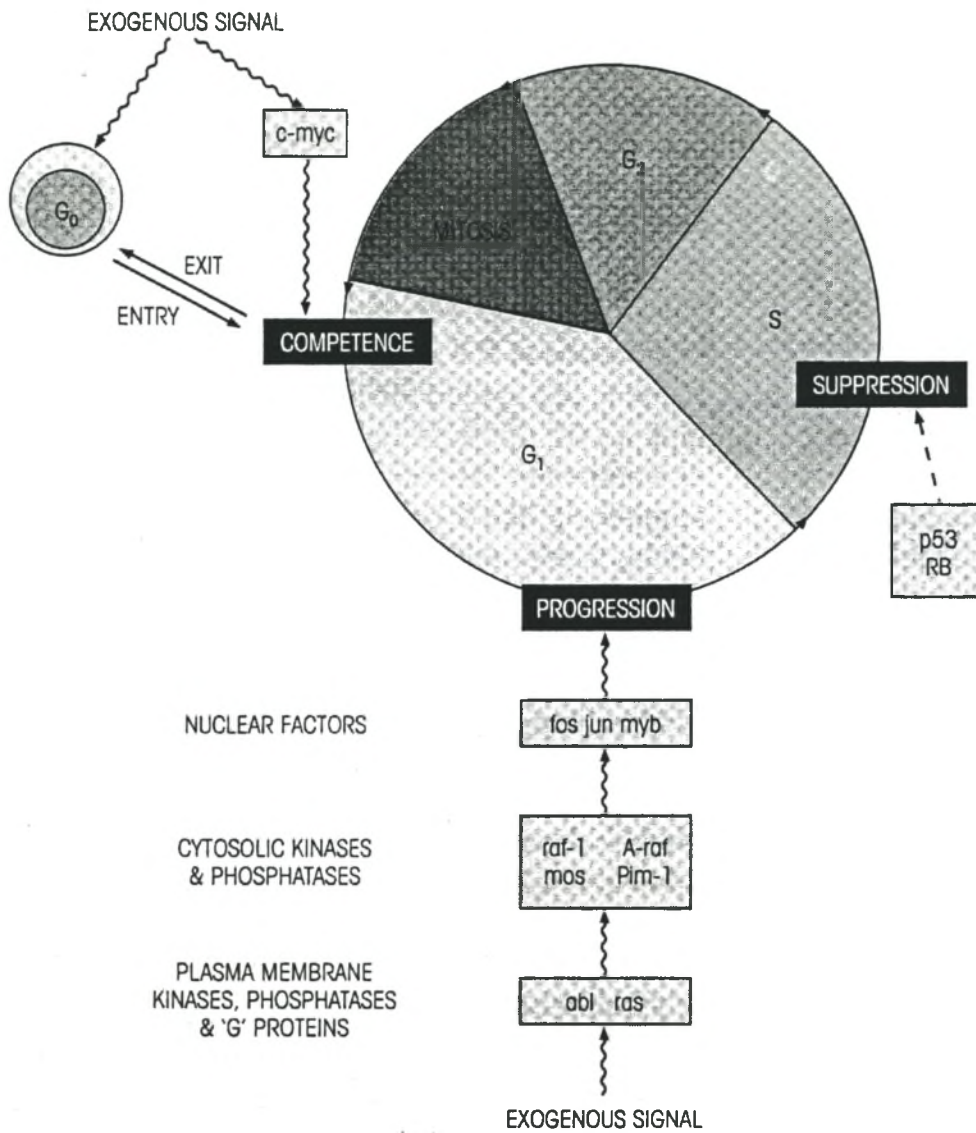


Fig. 15-2. Relationships of proto-oncogene products to control points for cell division. It is hypothesised that at least two major control points must be influenced by proto- or anti-oncogenes for mitosis to occur: the cell must be subject to factors affecting its competence to move through G₁ and a second set of factors which either enhance or suppress its ability to progress through the DNA synthetic phase. From Roitt (1994).

become transforming as a result of single nucleotide substitutions. The *ras* proto-oncogene codes for a family of proteins (p21 ras) on the inner membrane that play an essential role in the cell cycle (Appleman *et al.*,1996). Uncontrolled growth results because the transforming *ras* protein is locked in the biologically active form (Santos *et al.*,1989). *ras* oncogenes are the most frequently expressed activated oncogenes in human malignancies (Barbacid,1990). However mutations in the *p53* human suppressor gene is one of the most common genetic alterations in human malignancies (Levine *et al.*,1991). The *p53* gene normally arrests cells in the late G₁ phase of the cell cycle (Martinez *et al.*,1991). It is induced in response to ionising radiation and carcinogens, thus preventing a cell that has undergone genomic damage, from replicating (Kastan *et al.*,1991;Kastan *et al.*,1992) (Fig. 15-2).

1.2 Chromosomal Translocations (Fig. 15-3)

Chronic myelogenous leukaemia is a prime example of a chromosomal

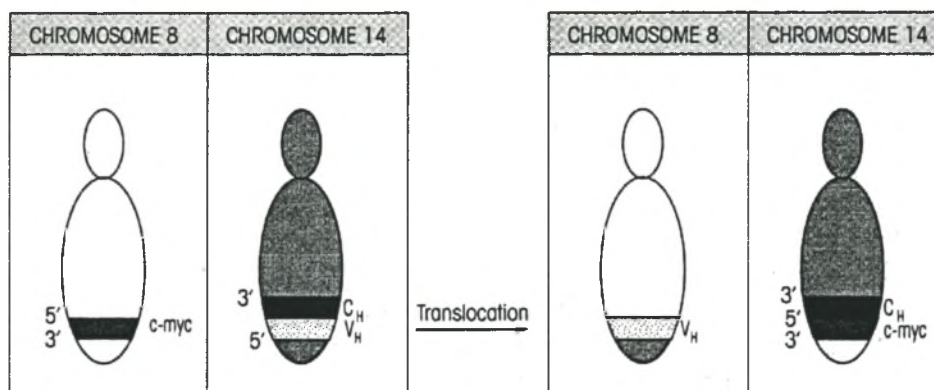


Fig. 15-3. Burkitt's lymphoma is a lymphoproliferative disorder that involves translocation of the *c-myc* gene to the μ -chain locus in Burkitt's lymphoma. Most lymphomas and leukaemias have chromosomal abnormalities involving translocation to B-cell immunoglobulin or T-cell receptor gene loci although *c-myc* is not always involved. From Roitt (1994).

translocation that results in the formation of chimeric fusion proteins (Ben Neriah *et al.*, 1986; de Klein *et al.*, 1982; Rowley, 1973; Shtivelman *et al.*, 1985). The leukaemic cells of over 90% of patients exhibit the Philadelphia chromosome in which the 5' end of the *c-abl* proto-oncogene on chromosome 9 is replaced with the *bcr* gene sequences of a chromosome 22 (Nowell *et al.*, 1966; Rowley, 1973). The resultant chimeric gene encodes a fusion protein with tumourigenic properties (Hariharan *et al.*, 1989; McLaughlin *et al.*, 1987; McLaughlin *et al.*, 1989).

1.3 Internal Deletion Mutations

Fusion type proteins can result from deletion mutations within a single gene. In malignant glioblastoma, a prime example of this type of mutation, the epidermal growth factor gene is structurally rearranged resulting in the deletion mutants of this gene (Urban *et al.*, 1992).

1.4 Viral Insertional Mutagenesis

Malignant transformation can occur as a result of the integration of retroviral sequences that serve as a promoter activator for the transcriptions of normal cellular proto-oncogenes. Viral integration may also precipitate structural mutational alterations consequently resulting in the expression of tumour specific antigens (*vide supra*).

2. *Aberrantly Glycosylated Molecules*

The surface carbohydrate structures of malignant cells display abnormalities which may involve blocked synthesis (Hakomori, 1989a; Hakomori, 1989b; Lloyd, 1990; Singhal *et al.*, 1990; Thurin, 1989), e.g. deletion of blood group A (Roitt, 1994). Other changes result in the increased expression of intact molecules that are absent in the progenitor cells, e.g. (Appleman *et al.*, 1996), some gastrointestinal tumours express the Lewis Le^a antigen in subjects who are Le (a⁻, b⁻) (Roitt, 1994).

3. *Amplified Normal Self-Molecules*

Under certain conditions there may be a significant immune response to normal self-molecules that are over-expressed in cancer. These would include growth factors,

their receptors, and other differentiation molecules (Urban *et al.*,1992). The oncofoetal antigens α -foetoprotein and carcino-embryonic antigen (CEA) are not expressed by fully differentiated cells. They are produced by undifferentiated cells and are useful in the diagnosis of certain forms of cancer and for the monitoring of remission (Roitt,1994;Urban *et al.*,1992).

Several oncogenic proteins expressed on the surface of the cancerous cells represent tumour-specific antigens although whether any of them represent rejection antigens is uncertain (Urban *et al.*,1992). Some virally encoded proteins are strong tumour rejection antigens that are causally related to the malignant phenotypes. Cancers induced by oncogenic viruses are likely to generate stronger resistance to growth than those caused by genetic perturbations. The number of novel epitopes on the surface of tumours arising from oncogenic viruses is likely to be considerably more than those arising from genetic mutations from single point mutations. Tumours arising spontaneously therefore produce little or no response (Appleman *et al.*,1996;Roitt,1994). This may be one explanation for the excess of virally-mediated tumours after renal transplantation.

CELLS INVOLVED IN THE IMMUNOLOGICAL RESPONSE

All components of the immune system play a role in the response to malignant transformation (Fig. 15-4). *T-lymphocytes* however represent the cornerstone of the response to the malignant process. They have a dual function as cytotoxic effector cells and as the key modulating cells, which control specific cell-mediated anti-tumour immune responses. Indications are that T-cells play the major role in the response to tumour cells compared with *B cells*, although anti-tumour antibody responses undoubtedly occur. The presence of natural antibodies in the serum of human cancer patients specific for the autologous tumour cells have been demonstrated (Carey *et al.*,1976;Old,1981;Shiku *et al.*,1976). Most of these auto-antibodies were reactive with antigens also found on certain normal tissues and less than 10% detected, shared an unique tumour antigen (Lloyd,1990). Most of the antibodies were directed to surface carbohydrates on glycolipids. The B cells are able to respond only to antigens expressed on the surface of tumour cells whereas

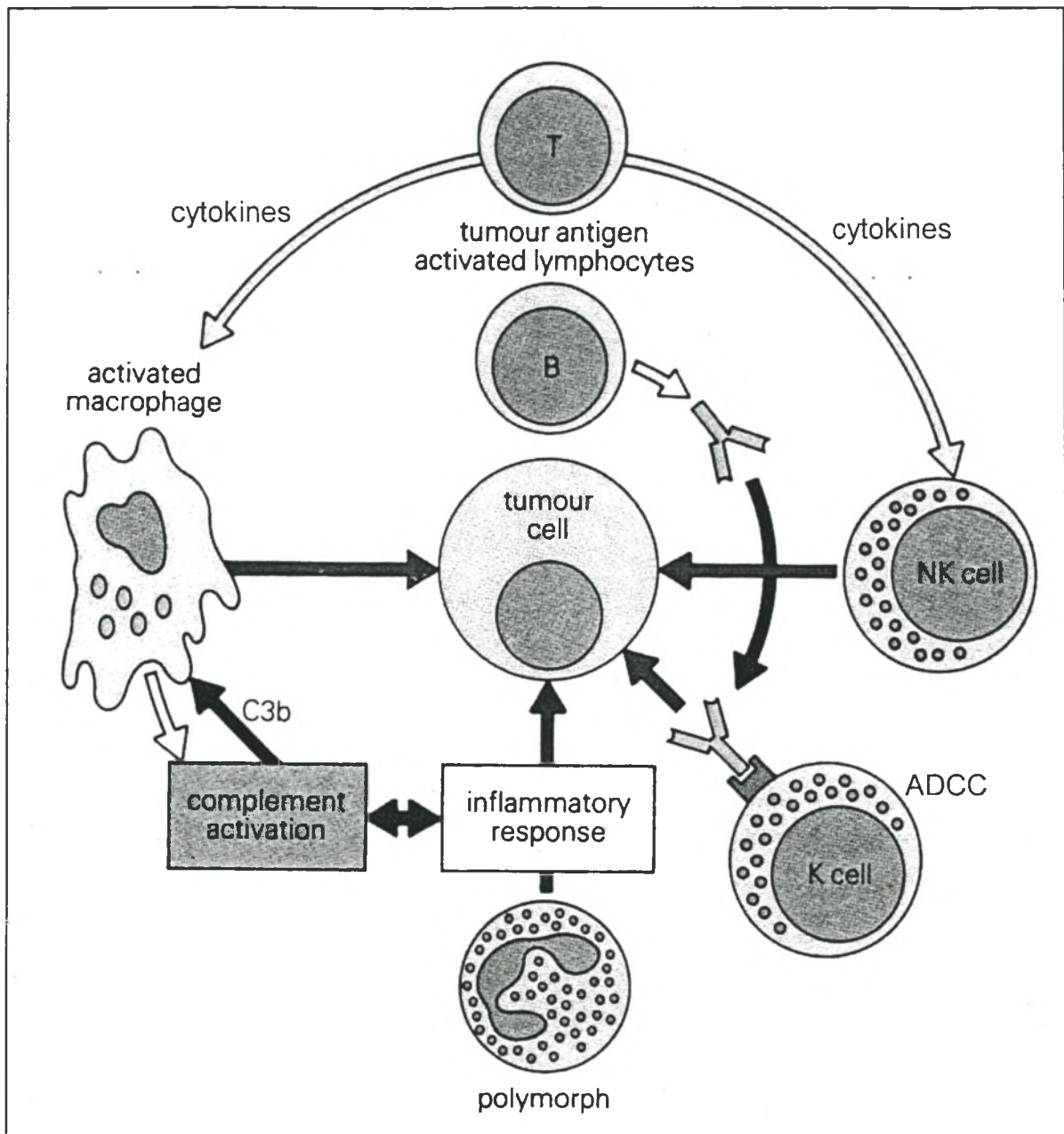


Fig. 15-4. Summary of the interaction between natural and adaptive immunity. Cytokines activate macrophages and NK cells. Activated macrophages produce complement components locally which are involved in the development of the inflammatory response. C5a is chemotactic for neutrophils while C3b induces macrophage enzymes release. K cells are armed by antibody from tumour-specific B cells. This is a simplified interpretation and is based on data derived from *in vitro* studies. ADCC, antibody-dependent cell-mediated cytotoxicity. Modified from Dawson et al. (1989).

the T cells are able to respond to intracellular antigens, provided a peptide chain is expressed on the surface in association with MHC (Dawson *et al.*, 1989). The B-cells may also induce a humoral response with the production of tumour specific antibodies which may result in complement-dependent cytotoxicity of tumour cells or may mediate antibody-dependent cell-mediated cytotoxicity (ADCC) in the presence of mononuclear cells possessing Fc γ receptors (Stevenson *et al.*, 1993) (*vide infra*). Some of the antibody effects may however be detrimental: blocking antibodies may prevent the recognition of antigenic determinants by cytotoxic T-cells. In addition soluble immune complexes formed when anti-tumour antibodies and tumour antigens combine, can suppress cytotoxic T-lymphocyte and natural killer cell functions.

Natural killer (NK) cells play a vital role in the initial defence against neoplastic cells (Pross *et al.*, 1993). The NK activity can be augmented by interferon- γ , interleukin-2 and adjuvants such as BCG (Whiteside *et al.*, 1990). The *monocyte/macrophage* system is triggered when T-lymphocyte products are released as a consequence of antigen recognition. Non-specific cytotoxic mononuclear phagocytes, natural killer cells and granulocytes all bear Fc γ receptors and thus readily interact with and destroy IgG-coated target cells as part of ADCC. In addition, these three cell types have the capacity to kill tumour targets in the absence of antibody coating: this is termed natural killing in the case of natural killer cells and spontaneous killing in the case of mononuclear cells and granulocytes. These 3 non-specific effector cell types recognise a common membrane marker of malignant cells that appears to be shared by many different types of malignant cells. If a tumour target is first encountered by a T-lymphocyte, its specific activation may result in the secretion of non-specific immunoregulatory factors that are capable of up-regulating the tumour killing function of mononuclear phagocytes, natural killer cells and granulocytes (Coulie, 1997; Searle *et al.*, 1996).

ESCAPE FROM IMMUNITY

The postulated host defence mechanisms against cancer have clearly failed when tumour growth becomes established. Several mechanisms have been postulated to explain how tumour cells evade the immune system and grow unrestrained. The

most credible of the mechanisms are immunoselection and enhancement. In immunoselection the subclones with decreased antigenicity that occur in most tumour cell populations have an advantage under the selective pressure exerted on the tumour cells by the host immunity; the proliferation of these cells will increase the general immunoresistance of the tumour. In addition, mutation of MHC class I antigens of antigen presenting cells or β_2 -microglobulin which effectively renders the cell incapable of recognition by CD8⁺ T cells (Browning *et al.*,1992;Smith *et al.*,1989;Uyttenhove *et al.*,1980;Wortzel *et al.*,1983a;Wortzel *et al.*,1983b).

Immunological enhancement has been observed in experimental situations where animals are immunised with inactivated tumour cells before they are infected with live cells. The enhancement is mediated by the production of blocking antibodies that bind inconsequentially to antigenic sites of the tumour and yet prevent the recognition of the same sites by potentially effective cytotoxic T-lymphocytes. The tumour antigen-antibody complexes are serum-blocking factors that have a similar effect. The shedding of free tumour antigen may block receptors of cytotoxic immune cells and induce the formation of immune complexes that in turn may participate in stimulation of suppressor cells. Additionally, activated monocytes can also promote malignant cell proliferation by release of growth factors such as IL-2 and epidermal growth factor (EGF) that are active on transformed cells.

Tumours may dampen the immune response by the secretion of immunosuppressive cytokines. Transforming growth factor (TGF) β -1 and IL-10 are potent immunosuppressive factors that downregulate the immune response. Tumour cells may either secrete these factors themselves or recruit a class of lymphocytes to the tumour that do (Pisa *et al.*,1992;Smith *et al.*,1994). Downregulation of the immune response may also occur because the tumour antigens closely resemble self-antigens. Anergy or clonal deletion may therefore occur. The mechanisms whereby this may occur remain to be elucidated, although preferential tumour antigen expression by the thymus may be a factor (Boussiotis *et al.*,1996; Pardoll,1994; Parmiani,1993).

IMMUNOSTIMULATION

Despite its limitations, the immune surveillance theory currently holds sway despite its many limitations. It has undergone many modifications over the years. Prehn who has revolutionised thinking in oncological immunoreaction has proposed an alternative postulate. He has suggested that all tumours evoke some degree of immune reaction and that this is fundamental to the growth of the lesion (Prehn *et al.*,1971). The increased incidence of skin malignancies in immunosuppressed allograft recipients compared to the general population suggests that the normal immune response usually inhibits the growth of these tumours. The increased incidence in renal and cardiac transplant patients is due to a lowering of a tumour stimulating immune reaction to a level that is even more stimulatory (Prehn *et al.*,1996). It also explains why the incidence of other common malignancies such as breast cancer have a lower than expected incidence in immunosuppressed patients. Breast malignancies according to Prehn, are of low immunogenicity and thus stimulate an immune reaction that is equal to or less than that required for optimal tumour growth. Prehn predicts that in renal and cardiac transplant recipients, the incidence of breast cancer would therefore be reduced. The use of immunostimulating adjuvants or vaccines may lead to acceleration of tumour growth (Prehn *et al.*,1971;1996).

OTHER CAUSES OF MALIGNANCIES

Neoplastic transformation requires the influence of several additional factors including loss of tumour suppressing genes and over-expression of normal or mutated proto-oncogenes. Cellular insults by certain viruses, chemicals and ionising radiation injury are capable of causing the sequential changes necessary for transformation (Fig. 15-2) (Roitt,1994).

EVALUATION OF IMMUNOLOGIC FUNCTIONS IN PATIENTS WITH KAPOSI'S SARCOMA

Two major developments of the latter half of the 20th century have emphasised the role of the immune system in the development of Kaposi's sarcoma. Firstly, transplantation of replacement organs or tissue to treat disease has become a

clinical reality. However, the success of transplantation is dependent on the use of immunomodulating agents whose mandatory chronic use predisposes patients to the development of malignancies of which Kaposi's sarcoma is one of the most common (Rossini *et al.*,1999). Secondly, the outbreak of Kaposi's sarcoma in young homosexual males represented one of the first descriptions of acquired immunodeficiency syndrome (AIDS) (Friedman-Kien,1981). In both clinical situations it has been postulated that immune dysfunction is responsible for the development of Kaposi's sarcoma with the patients who suffer this complication being relatively more immunosuppressed (Bencini *et al.*,1993;Lane *et al.*,1985a).

Renal Transplant Patients

The findings of Lane *et al.* (1985a) in one of the first studies of its kind suggested that AIDS patients who developed Kaposi's sarcoma represented a subgroup that had more severe immunologic derangement. They measured lymphocyte CD4 and CD8 phenotypes and undertook stimulation tests with pokeweed mitogen (PWM), phytohaemagglutinin (PHA) and tetanus toxoid. Harwood *et al.* (1979) undertook the immunologic evaluation of renal allograft recipients whose clinical course was complicated by the development of Kaposi's sarcoma. They performed mitogenic stimulation tests using PWM, PHA and concanavalin A (Con A) and were able to demonstrate that the responses in the 3 patients tested were diminished. However, beside the small number of patients, no comparisons were made to either normal subjects or case controls. Master *et al.* (1970) were among the first to undertake immunologic studies in Kaposi's sarcoma patients when they evaluated the humoral and cellular immunity of African patients with endemic Kaposi's sarcoma. Although immunoglobulin levels were normal, they were able to demonstrate a "striking impairment in the delayed hypersensitivity response". The evidence available suggests therefore that patients who have defects of cell-mediated immunity may be predisposed to the development of Kaposi's sarcoma. Because of defective immunity of immuno-compromised patients the immune-surveillance fails to respond to virus-specific antigens (Purtilo *et al.*,1984). Although failure of immunosurveillance does account for the increased incidence of certain malignancies in renal transplant patients, the failure of the incidence of other common malignancies such as breast cancer to increase, has led to suggestions of

other mechanisms whereby the immune system is involved in the development of malignancies (*vide supra*).

AIDS Patients

The immune system has been studied more extensively in patients infected with the human immunodeficiency virus (HIV) (Table 15-2) and this may shed some light on the alterations that predispose to posttransplantation Kaposi's sarcoma. Much of the early immunological work on AIDS emanated from the laboratory of Anthony Fauci. Well before the aetiology and pathogenesis of AIDS were understood the devastating effect of the disease on the immune system was recognised. The varied clinical manifestations that included increased susceptibility to opportunistic infections and neoplasms were indicative of a defective cellular immune response (Fauci *et al.*,1984a; Friedman-Kien,1981; Gottlieb *et al.*,1981; Gottlieb *et al.*,1983; Masur *et al.*,1981; Mildvan *et al.*,1982; Siegal *et al.*,1981). It is now known that the HIV targets the CD4⁺ cell, which itself plays the central role in "orchestrating the immune reactivity in humans" (Fauci *et al.*,1983; Lane *et al.*,1985c; Lane *et al.*,1985a; Reinherz *et al.*,1979). The earliest observations made in patients who become infected with the HIV is a reduction in the CD4⁺ lymphocyte subpopulation with a rise in the CD8⁺ cell number resulting in reversal of the CD4/CD8 ratio among peripheral blood lymphocytes (Bowen *et al.*,1986;Gottlieb *et al.*,1981;Masur *et al.*,1981;Tsoukas *et al.*,1994). The typical HIV-infected patient has a gradual fall in the CD4⁺ cell count over several years (McGrath,1996). Of greater importance is the switch from a Th-1 to a Th-2 CD4 genotype. This manifests clinically with a decline in the ability to ward off chronic viral infections and cancers, that require Th-1-type response, to developing hypergammaglobulinaemia, which characterises the type 2 response (Levy,1993). This is associated *in vitro* with decreased mitogen responsiveness and *in vivo* with decreased delayed type hypersensitivity reactions (Fauci,1982;Fauci *et al.*,1984b;Fauci *et al.*,1984a). Although the primary abnormality is at the CD4⁺ T-cell level, abnormalities have been described at virtually all levels of the immune system including B-cell function, macrophage/monocyte function and NK cell function (Bowen *et al.*,1986;Lane *et al.*,1985d). The abnormalities are summarised in Table 15-2 (Bowen *et al.*,1986; Lane *et al.*,1985b).

Table 15-2. Immunologic abnormalities in AIDS.

Quantitative abnormalities of T lymphocytes

Decreased numbers of CD4+ cells

Elevated, normal or decreased numbers of CD8+ cells

Functional abnormalities of T lymphocytes *in vivo*

Host susceptibility to infection

Host susceptibility to neoplasms

Decreased delayed-type hypersensitivity responses

Functional abnormalities of T lymphocytes *in vitro*

Decreased mitogenic and antigenic responsiveness

Decreased virus-specific cytotoxic lymphocyte function

Decreased ability to help B cells

Functional abnormalities of B lymphocytes *in vivo*

Elevated serum immunoglobulin and CIC levels

Poor serological response to immunisation

Functional abnormalities of B lymphocytes *in vitro*

Elevated spontaneous proliferation

Elevated response to B cell growth factors

Refractory response to normal B cell signals

Abnormalities of other cell types

Decreased macrophage/monocyte chemotaxis

Decreased natural killer cell activity

From Bowen *et al.* (1986) and Lane *et al.* (1985b)

Kaposi's Sarcoma

In studies specifically looking at Kaposi's sarcoma, Lane *et al.* (1985a; 1985b) studied lymphocyte profiles and function in groups of HIV-infected patients, healthy homosexual males and control subjects. They demonstrated that the more advanced the HIV infection the lower the CD4⁺ count was. The patients with AIDS had lower mean values of all measured immunological variables with the exception of the CD8⁺ count. There was no difference in the CD8⁺ counts in the 3 patient groups compared with controls. The CD4⁺ counts of patients who had opportunistic infections were significantly lower than in those patients who had Kaposi's sarcoma (Fig. 15-5). This suggested that the former had more profoundly depressed immunological function. This was confirmed by the improved overall long-term survival of Kaposi's sarcoma patients (79%) compared with patients with opportunistic infections (44%) (Lane *et al.*, 1985b; Lane *et al.*, 1985a).

KAPOSI'S SARCOMA AND THE IMMUNE SYSTEM

Levy and Ziegler observed in 1983 that Kaposi's sarcoma was more common in immunosuppressed transplant patients (Levy *et al.*, 1983). They discounted the immunosurveillance theory because it failed to explain why the common cancers (lung, breast, colon, leukaemia) were not observed in these patients. The endothelial cell, which they felt was the cell of origin in Kaposi's sarcoma, was closely linked to the functional components of the immune system (Ashida *et al.*, 1981; Baldwin, 1982; Levy *et al.*, 1983). The endothelial cell participates as an accessory cell in lymphocyte activation (Ashida *et al.*, 1981; Levy *et al.*, 1983) and contains surface Fc and C3 receptors that may modulate interaction between the immune system and the vascular endothelium (Baldwin, 1982; Levy *et al.*, 1983). The immune cells secrete a variety of cytokines that have angiogenic properties (Jones *et al.*, 1978; Nishioka *et al.*, 1978; Taylor *et al.*, 1982; Warner *et al.*, 1975; Ziche *et al.*, 1982). They proposed that in AIDS patients, Kaposi's sarcoma develops as a result of "the enhanced secretion of immunomodulating factors with angiogenesis-promoting activity by cells attempting to correct or compensate for the disorder". The Kaposi's sarcoma cells themselves also produce angiogenesis factors (Salahuddin *et al.*, 1988). They further suggested that the immunodepression could enhance the

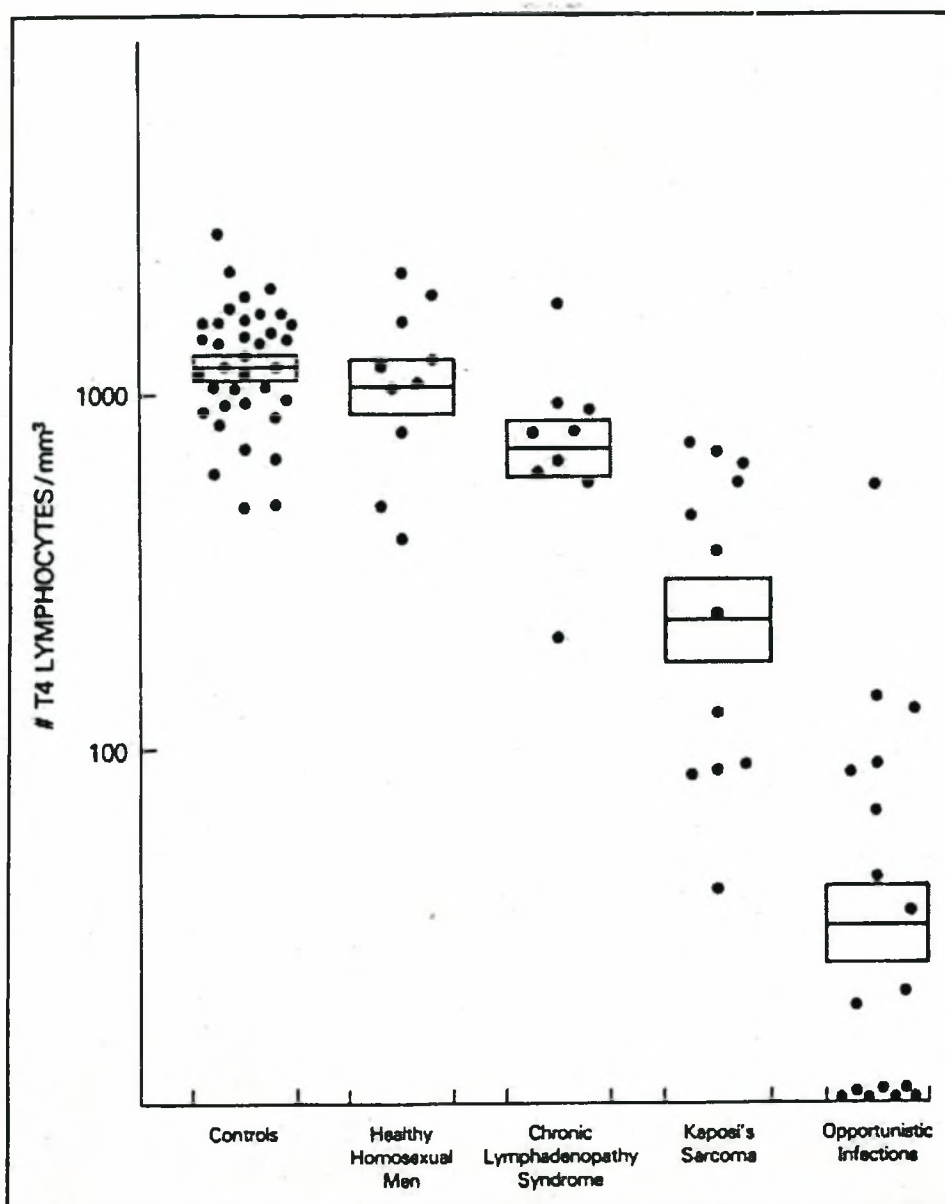


Fig 15-5. The CD4⁺ count of patients with AIDS. The counts were reduced in Kaposi's sarcoma patients but the more severely immunocompromised patients had the lowest counts. From Lane *et al.* (1985a).

activation of latent herpes viruses that could promote transformation. Bencini *et al.* (1993) suggested that Kaposi's sarcoma in renal transplant patients was also contributed to by immunostimulation, this resulting from low grade persistent antigenic stimulation occurring in the allograft (Bencini *et al.*, 1993). Other factors that they postulated played a role was the "low immune response" of their patients: 60% of their patients failed to reject their grafts even months after reduction or withdrawal of immunosuppression therapy. They further suggest that cyclosporine

impairs the immune surveillance and allows abnormal endothelial cells to proliferate. Alternatively, immunosuppression disturbed the balance between cytokines favouring the promotive effect of viral infections on vascular proliferation (Bencini *et al.*,1993).

Recent studies have concentrated on the human herpesvirus 8 (HHV-8), the putative agent causing Kaposi's sarcoma (Brander *et al.*,2000). While herpesviruses are renowned for their complex strategies for evading the immune response (Ploegh,1998), the HHV-8 has evolved an unprecedented approach. Intracellular viruses are detected by the immune system by virtue of the MHC class I molecules that deliver fragments of the viral proteins to the surface to be detected and destroyed by cytotoxic T-cells. Whereas some herpesviruses downregulate MHC class I expression by interfering with the synthesis, translocation or assembly of class I chains, the K3 and K5 proteins of HHV-8 accelerate the endocytosis of MHC-I molecules expressed on the surface of infected cells (Coscoy *et al.*,2000; Ishido *et al.*,2000b). There is also evidence from both these groups that other signaling molecules are also targeted. The exact mechanism whereby HHV-8 infection predisposes to Kaposi's sarcoma is unclear but these observations “ . . . underline the fact that the immune system is very important in the control of (HHV-8) and that the virus has equipped itself with the devices to evade it” (Habeck,2000).

Summary and Hypothesis

There is little doubt that the immune system plays a vital role in modulating malignant transformation. All aspects of the immune system, but especially cellular immunity play an important role here. Whether recirculating T-lymphocytes which patrol all somatic tissue as part of immune surveillance proceed to recognise and destroy the transformed and proliferating malignant cells, or whether Levy and Prehn's suggestion that immunostimulation was the main causative factor will have to be tested over time.

Our own observation, that patients with Kaposi's sarcoma seldom rejected their kidneys following therapeutic reduction of immunosuppressive agents, led us postulate that these patients had reduced immune-responsiveness and we proceeded to investigate aspects of cellular and humoral immunity to test this hypothesis.

Materials and Method

SELECTION OF CASES

Kaposi's Sarcoma Patients

The patients studied were those who were diagnosed previously with Kaposi's sarcoma and who were alive at the time of study. A total of 13 patients were available for some form of immunological evaluation. Demographic and other details are shown (Table 15-3): the male to female ratio was 7:6 and racial distribution was 10 coloured and 3 black patients, but no white patients. Eleven patients underwent initial lymphocyte phenotyping and subsequent typing and transformation testing. Cyclosporine had been discontinued in all patients, but one. The tests were conducted between 11-143 months following discontinuation of cyclosporine. This was the main therapeutic modality for the treatment of Kaposi's sarcoma. In one patient the tests were conducted when he was initially diagnosed with Kaposi's sarcoma (patient 6). The patients had been on immunotherapy, including cyclosporine for 65.6 months (range: 24.1 – 225.1 months). All the patients with

functioning grafts were receiving methylprednisolone 8mg daily and azathioprine 50 mg daily. The two patients (patients 9, 11) on haemodialysis had had all immunotherapy discontinued when Kaposi's sarcoma was diagnosed. They were restarted on haemodialysis after the grafts failed within 4-6 weeks of discontinuation of immunosuppressive treatment. HIV infection was excluded in all patients.

Transplant Controls

For comparison of the immunological status of the Kaposi's sarcoma patients, a group of renal transplant patients who were also only receiving azathioprine and methylprednisolone at the time of the study were used. Patients who were transplanted in the pre-cyclosporine period were therefore selected. Only 9 patients were available for study and their details are shown (Table 15-3). The control group was 10 years younger at transplantation, but age at the time of the study in the Kaposi's sarcoma and control group were 45 and 46 years respectively. The male to female ratio was 3:6 and the racial breakdown revealed 7 white patients, 2 coloured patients, but no black patients. The duration under immunotherapy, not surprisingly, was more than 3 fold greater in the control group. Renal function was also much better preserved in the control group by a factor of almost 3. All controls were negative for the HIV.

Normal Controls

For lymphocyte phenotype studies 47 healthy laboratory staff, and for transformation studies 18 healthy laboratory staff, served as normal controls. The controls were age-matched, but no attempt was made to match for race. For the immunoglobulin studies, normal ranges supplied by the local laboratory were used. Results outside the normal range were considered abnormal. For delayed type hypersensitivity reactions, consecutive nursing trainees were recruited over a 2-year period. This test is a pre-employment requirement at our institution for all new recruits.

Table 15-3. Demographic and other details of Kaposi's sarcoma survivors and control renal allograft recipients not receiving cyclosporine.

	Age ¹	Sex	Race	Primary renal disease	Immuno-therapy (mo.)	Serum creatinine ($\mu\text{mol/l}$) ²	Interval off cyclosporine (mo.)
Kaposi's Sarcoma patients (n=13)							
1	26.4	Male	Coloured	Hypertension	55.1	131	50.0
2	35.1	Female	Coloured	Polycystic kidneys	24.1	113	11.0
3	38.6	Female	Coloured	Pyelonephritis	82.1	110	18.0
4	47.2	Male	Black	Glomerulonephritis	88.0	358	61.1
5	46.4	Female	Coloured	Hypertension	37.1	987	23.0
6	26.0	Male	Coloured	Pyelonephritis	225.1	376	0.0
7	49.5	Male	Black	Hypertension	90.1	66	34.0
8	49.3	Female	Black	Glomerulonephritis	38.0	747	29.1
9	47.5	Male	Coloured	Polycystic kidneys	22.2	HD	141.1
10	33.4	Female	Coloured	Scleroderma	67.1	315	45.0
11	28.6	Female	Coloured	Pyelonephritis	4.5	HD	143.1
12	39.1	Male	Coloured	Glomerulonephritis	49.0	112	31.1
13	28.0	Male	Coloured	Glomerulonephritis	70.0	76	36.0
Mean	38.1				65.6	308	47.9
Renal transplant controls (n=9)							
1	24.9	Female	White	Pyelonephritis	191.9	69	
2	40.6	Female	White	Analgesic nephropathy	163.6	98	
3	14.7	Male	White	Alport's	238.2	113	
4	13.3	Female	White	Alport's	225.2	75	
5	28.9	Female	White	Pyelonephritis	213.1	HD	
6	37.7	Male	Coloured	Pyelonephritis	237.2	122	
7	38.9	Female	White	Pyelonephritis	214.8	147	
8	40.1	Female	White	Pyelonephritis	223.1	81	
9	20.1	Male	Coloured	Pyelonephritis	209.9	153	
Mean	28.8				213.0	107	

Notes:

¹The age is that at initial transplantation²Mean creatinine value excludes those patients on haemodialysis (HD)

T-CELL FUNCTION

Phenotypic Analysis of T-Lymphocytes by Flow Cytometry

Whole blood was assayed to determine the T-lymphocyte subpopulations by use of three-coloured immunofluorescence. In this technique 100 μl of whole blood was incubated with 20 μl of each of the appropriate antibodies for 20 minutes at room temperature. The aliquots were lysed with 2 ml of lysing solution (Becton-Dickinson,

Johannesburg) incubated for a further 10 minutes and then washed in phosphate buffered saline (PBS) (Diagnostic and Technical Services, Johannesburg). The cell deposits were fixed in 0.5% paraformaldehyde. The following panel of monoclonal antibodies (Becton-Dickinson, Johannesburg) conjugated with either fluorescein isothiocyanate (FITC) or peridinin chlorophyll protein (PERCP) was used: CD3-PERCP, CD4-FITC, CD8-FITC, CD19-PERCP, CD16-PERCP and CD56-PERCP. The lymphocytes were analysed on a flow cytometer (FAC scan, Becton-Dickinson, Johannesburg) using Cell Quest software programs. Lymphocytes were gated on forward and side scatter. A second gate of CD3⁺ cells was used to determine the T-cell subpopulations. The percentage of lymphocytes expressing the respective antigens was recorded and the absolute lymphocyte numbers were calculated using the full blood count conducted in parallel.

Skin Tests

The volar aspect of the left arm was used to inject 0.1ml (2TU/0.1 ml) of tuberculin purified protein derivative (PPD) (Vaccinia, Johannesburg) intradermally. The wheal raised was marked and read 48 hours later. An induration of 10mm or more in maximum diameter was considered a positive reaction. The same volume (1000 PNU/ml) of *Candida albicans* antigen was injected intradermally in the opposite arm and read in the same fashion as the tuberculin reaction.

Lymphocyte Transformation Assays

Antigens are presented to lymphocytes by macrophages which release interleukin 1 (IL-1). This, together with the MHC class II antigen – foreign antigen complex activates the T-lymphocytes and initiates an immune response. The method used to measure the activation and proliferation of lymphocytes is a cell culture technique whereby mononuclear cells and mitogens are incubated together under specific conditions. Antigens induce differentiation and division of cells. The mitogens used in this study were phytohaemagglutinin (PHA) (Wellcome, Scientific Group, Cape Town) and concanavalin A (Con A) (Sigma, Sigma-Aldrich, Cape Town), both strict T-cell mitogens, and pokeweed mitogens (PWM) (Sigma, Sigma-Aldrich, Cape Town), a T-dependent B-cell mitogen. An optimum response is achieved with PHA and Con A after 3 days of incubation compared with 5 days for PWM. After

incubation, lymphocyte proliferation is measured by the uptake of radio-labelled metabolites required for DNA synthesis. In this study ^3H -thymidine (Amersham, AEC Amersham, Cape Town) uptake was measured by harvesting the cells and counting the incorporated radio-activity.

The method used for lymphocyte transformation commenced with the isolation of mononuclear cells from whole, heparinised blood on a Hypaque-Ficoll density gradient (Sigma, Sigma-Aldrich, Cape Town). The mononuclear cells were washed in TRIS (Sigma, Sigma-Aldrich, Cape Town) and then resuspended in 1ml of complete medium. Cell counts were adjusted to a concentration of 1×10^6 ml. Using a 96 well cell culture plate (Sterilab Services, Cape Town), 1×10^5 cells were mixed with 100 μl of mitogen (PHA, Con A, or PWM). The tests were conducted in triplicate. Trays were incubated at 37°C in a CO_2 incubator. After $2\frac{1}{2}$ and $4\frac{1}{2}$ days, 20 μl of ^3H -thymidine were added to 3 day and 5 day trays respectively. The trays were then incubated for a further 18 hours before harvesting. Counting was done on the Beta counter (Beckman, Beckman-Coulter, Cape Town) after the addition of 3ml scintillation fluid (Beckman, Beckman-Coulter, Cape Town) to the vials. The mean counts for each mitogen reaction and the background control were established. The stimulatory index (SI) was calculated by dividing the mean mitogen count by the mean count of the control. Results were expressed as the stimulatory index of the patient to a particular antigen divided by the stimulatory index of the control multiplied by 100.

VENEPUNCTURE

Venesection was performed at approximately the same time of the day (7am to 10am). All tests were conducted on the same day that blood was collected. Blood samples were transported to the laboratory within 4 hours of being drawn. Blood was not collected from patients if there was recent evidence of acute or chronic infection. The lymphocyte phenotypes were repeated in 9 Kaposi's sarcoma patients between 1 and 12 months later.

IMMUNOGLOBULIN AND OTHER BIOCHEMICAL TESTS

Serum immunoglobulin levels were assayed by immuno-electrophoresis using a Beckman Array analyser (Galway, Ireland) and other proteins by electrophoresis on a Beckman Coulter Paragon analyser (Fullerton, OA). Serum immunoglobulin levels were correlated with age, sex, and race. Other proteins were correlated with age and sex.

STATISTICAL ANALYSIS

The data were analysed by non-parametric techniques because of the non-normality of the results. Where patients were compared with a normal control or case control, the Mann-Whitney U test was used. The χ^2 - test was used for other comparisons. Significance was set at the 5% level. Data was analysed using software from Stat Soft, Inc (1999), Statistica for Windows (release 5.2), Tulsa, Oklahoma, USA.

Results

HUMORAL IMMUNITY

Humoral immunity was evaluated in the Kaposi's sarcoma patients and renal transplant control patients, by measurement of serum immunoglobulin levels, quantitative assessment of B cell phenotypes was established by flow cytometry, while B cell function was assessed using pokeweed mitogen (PWM). Natural killer cell phenotype analysis as a measure of innate immunity was also performed.

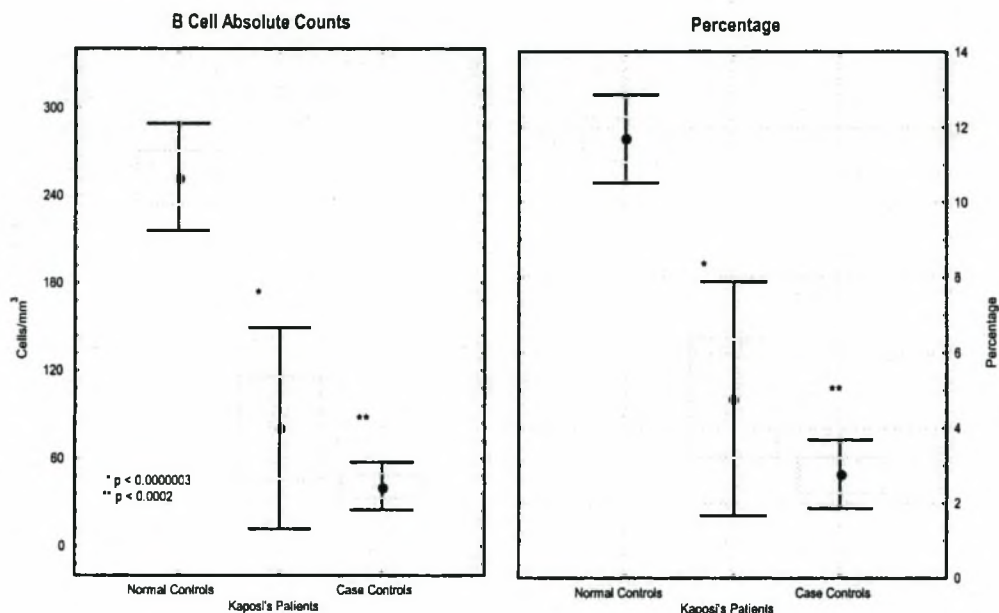
Serum Immunoglobulin Levels (Table 15-4)

Comparisons of study patients and both Kaposi's sarcoma and renal transplant controls were made with the normal laboratory ranges for race, age and gender. Values below the normal range were considered abnormal. Of the 13 Kaposi's sarcoma patients 8 (62%) had normal serum immunoglobulin levels while 5 (38%) had abnormal levels. Only one patient (patient 12) had more than one abnormal serum immunoglobulin level. There were 2 abnormalities each of immunoglobulin A (IgA),

Table 15-4. Serum immunoglobulin levels and skin tests in immunosuppressed renal transplant patients

	Albumin (g/l)	γ -globulin (g/l)	IgA (g/l)	IgG (g/l)	IgM (g/l)	Tuberculin Reaction	Candida Reaction
Kaposi's sarcoma patients							
1	42.9	11.9	3.26	14.2	1.34	+	0
2	45.2	8.7	1.87	11.1	1.59		
3	40.7	13.1	3.39	12.7	1.59	+	0
4	23.0↓	9.3	3.6	10.2	0.55↓	0	0
5	39.0↓	12.9	1.16↓	14.8	0.84	0	0
6	26.8↓	3.9	1.89	5.53↓	1.5	0	0
7	38.9↓	14.2	2.96	16.1	1.08	0	0
8	44.8	15.3	4.84	17.9	1.27	+	0
9	32.5↓	12.2	3.31	14	0.63	0	0
10	41	10.8	3.55	13.4	0.73	0	0
11	37.2↓	12.2	1.54	12.9	1.21	+	0
12	38.4↓	6.7	2.57	5.09↓	0.39↓	0	0
13	39.9↓	7.9	0.8↓	10.1	0.82	0	0
Renal transplant control patients							
1	49.5	7.7	1.74	8.42	1.04		
2	45.4	4.4↓	1.1	7.7	1.8	0	0
3	50.8	9.5	2.82	10.8	0.84	0	0
4	49.1	9.8	1.57	10.6	1.72	0	0
5	39.0↓	6.6	1.3	10.6	0.8	0	0
6	34.3↓	5.8	3.09	8.31	1.17	0	0
7	40.2	10.95	1.82	13.6	0.69	0	0
8	39.0↓	3.3↓	2.19	4.38↓	1.23	0	0
9	38.5↓	7.5	1.82	9.7	0.87	0	0

immunoglobulin G (IgG) and immunoglobulin M (IgM). No patient had abnormal serum levels of all 3 immunoglobulins. Only one of the 9 (11%) case control patients had an abnormal serum immunoglobulin level (IgG). No patient in either group had increased serum levels of immunoglobulins. More abnormalities were observed in the Kaposi's sarcoma patient group, but the differences were not significant ($p = 0.16$, Fisher's exact, 2-tailed). Of note is that all patients who had decreased serum immunoglobulin levels, also had reduced serum albumin levels ($p = 0.0152$, Fisher's exact, 2-tailed). Serum α -globulin levels were preserved in all Kaposi's sarcoma patients and were marginally reduced in 2 controls, one of who had decreased serum IgA as well. Serum α_1 , α_2 and β -globulin estimations (not shown) were also

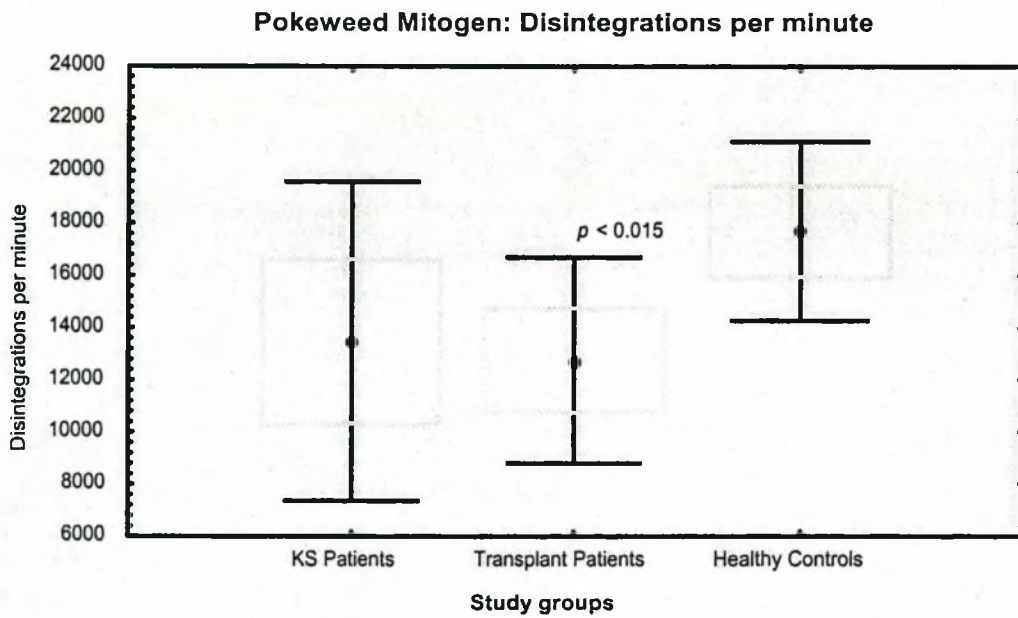
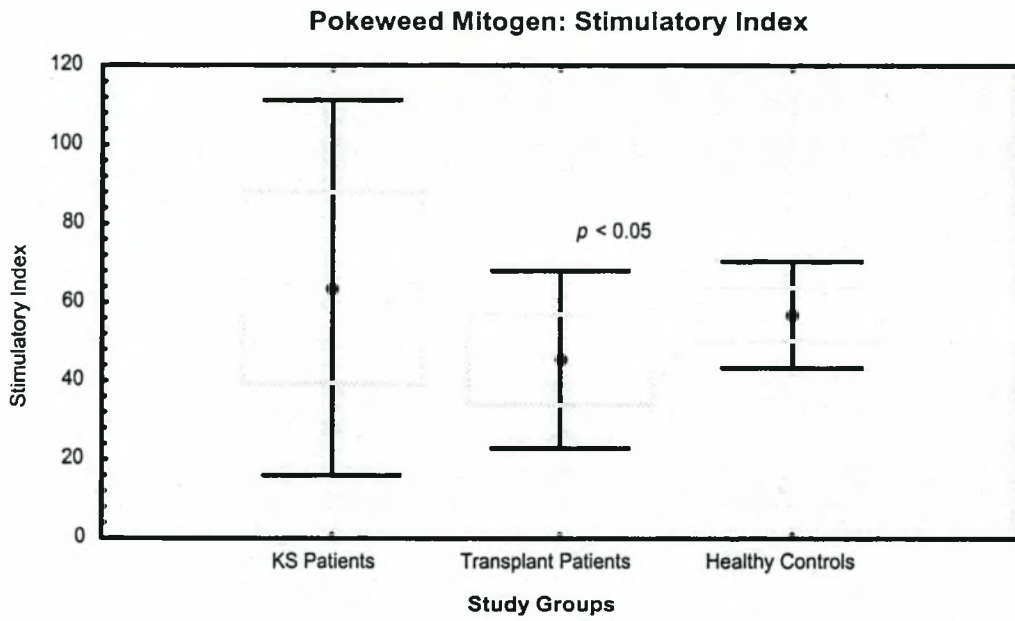
Fig. 15-6. B Cell Phenotypes

performed but all values were either normal or slightly increased. Also of note is that no patients with a positive tuberculin skin test had any immunoglobulin abnormalities. In Kaposi's sarcoma patients 8/13 (62%) and in the control group 4/9 (57%) had low serum albumin, perhaps reflecting the poor nutritional state of our transplant patients in general. Of the white patients 2/7 (29%) and of the nonwhite patients 10/12 (71%) had low serum albumin levels ($p = 0.15$, Fisher's exact, 2-tailed).

B-Cell Phenotypes (Fig. 15-6)

The most striking abnormality was marked reduction in B cells in all transplant patients, both Kaposi's sarcoma and controls. The B cell count was less than 100 cells/mm³ in all patients receiving immunosuppressive therapy. The relative B cell count was 5% or less in all patients on treatment. The only patient in whom B cell counts were normal, was on haemodialysis after discontinuation of immunosuppression following the development of Kaposi's sarcoma more than 12 years ago. The mean number of B cells in Kaposi's sarcoma patients and controls did not differ significantly although the former showed much greater scatter.

Fig 15-7. B Cell Stimulation Studies



Relative to the other lymphocytes, the percentage of B cells was also comparable in the two groups studied.

B Cell Lymphocyte Transformation Assay (Fig. 15-7)

Pokeweed mitogen, which is a polyclonal B cell mitogen was used to induce blastic transformation. Compared to healthy controls, control renal transplant patients had reduced responsiveness to PWM, but Kaposi's sarcoma patients did not have an altered response compared to either normal or case controls. Although B cells are quantitatively significantly reduced, and there are moderate reductions of immunoglobulins, B cell function would appear to be comparable in Kaposi's sarcoma patients and controls.

CELLULAR IMMUNITY

The screening tests for T-cell functions are less definitive than those for the evaluation of B cell function. Additional tests are therefore required to complete the assessment of cellular immunity. Immunophenotyping of T cells and T cell subsets has gained prominence over the past few years and provide useful insight into the quantitative status of T cells and their subpopulations. The tests however do not establish the functional capabilities of the T cells identified by flow cytometry; for this lymphocyte transformation tests using T cell mitogens, Con A and PHA were used.

Lymphocyte Phenotypes (Fig. 15-8)

The absolute number of T cells and CD4⁺ cells were significantly reduced in Kaposi's sarcoma patients compared to healthy controls. Although renal transplant patients also had reduced T and CD4 cells, the differences compared to healthy controls failed to achieve significance. The difference in counts between Kaposi's sarcoma and case control patients was also not significant. Because of the marked reduction in B and NK cells, the relative numbers of T cells were increased, but no differences were found between Kaposi's sarcoma and transplant patients.

Fig. 15-8. T Cell Phenotypes

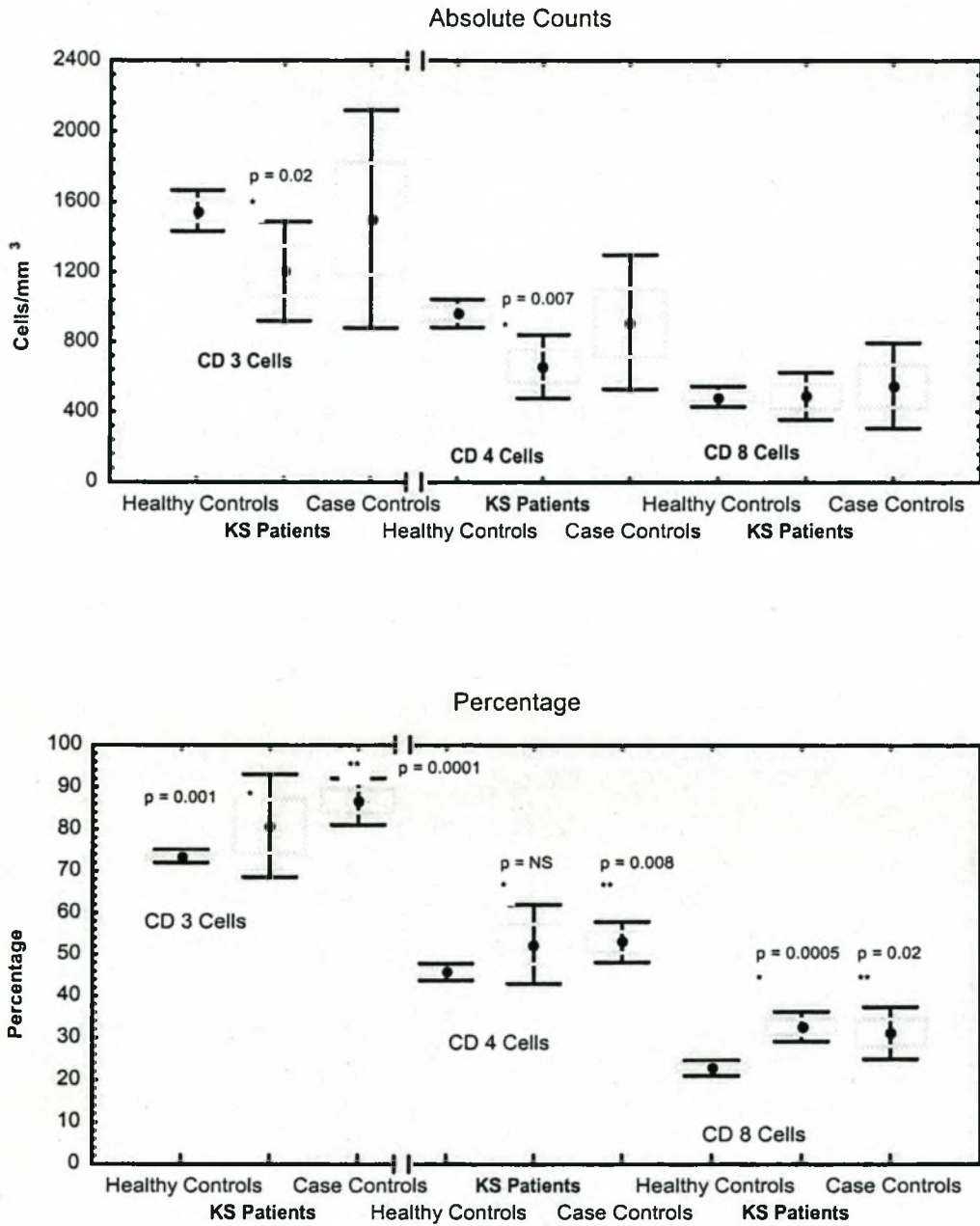
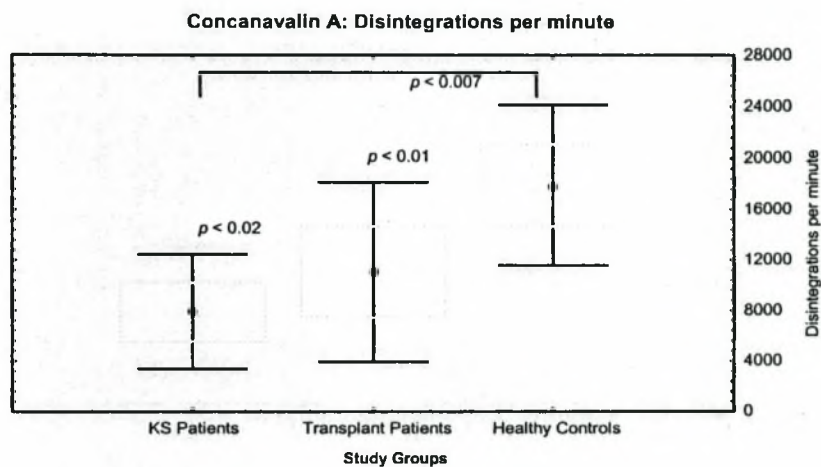
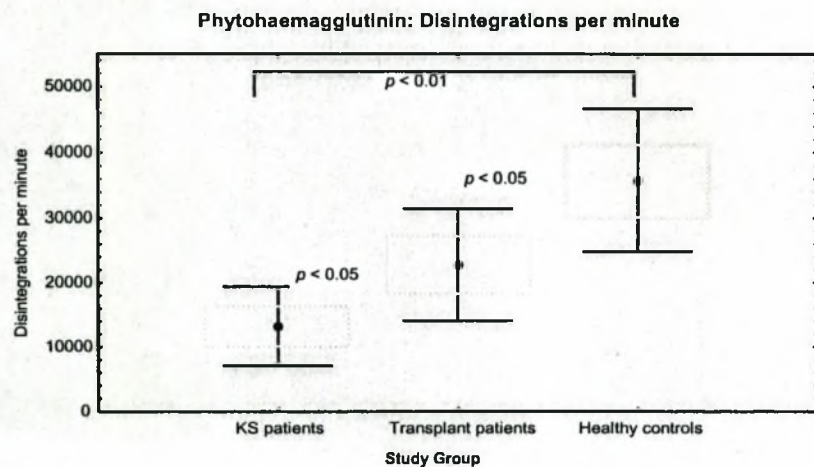
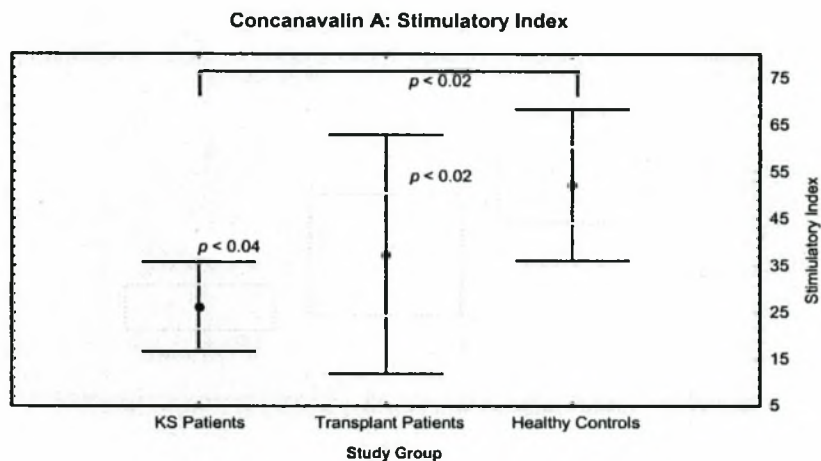
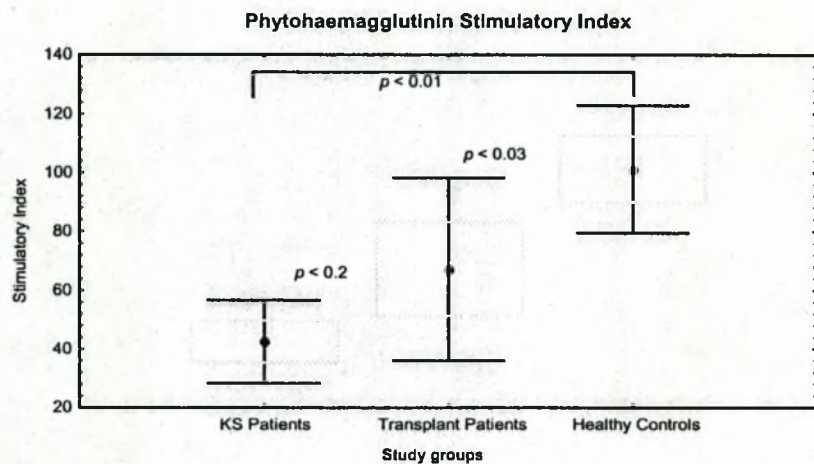


Fig. 15-9. Lymphocyte Transformation Assays



Lymphocyte Stimulation Assays (Fig. 15-9)

Functional assessment of T cells has traditionally been performed by evaluating the T cell proliferative response to polyclonal stimulants. The two mitogens used in this study to test T cell function, were Con A and PHA. The blastogenic responses of all transplanted patients were reduced compared to normal controls. More importantly were the significantly reduced responses of the Kaposi's sarcoma patients compared to the other renal transplant patients.

Delayed Type Hypersensitivity (DTH) Reactions

None of the patients reacted to *Candida albicans* antigen administered intradermally, nor did any of the control patients react to the intradermal tuberculin antigen. Of the 10 Kaposi's sarcoma patients tested, 4/12 (25%) had a positive tuberculin reaction (Table 15-4). This suggests that more Kaposi's sarcoma patients had been exposed to tuberculosis. All patients who tested tuberculin-positive were nonwhite. Among controls, a clear racial pattern was demonstrated. Of the 59 white nursing recruits tested 11 (18.6%) reacted to tuberculin, compared to 45 (64.2%) of the 70 nonwhite recruits tested ($P = 0.000$, χ^2 -test).

NATURAL KILLER CELLS (NK) (Fig. 15-10)

Beside T and B cell mediated responses, the NK cells form another important arm of immunity. The phenotypic analysis of lymphocytes revealed a marked reduction in the number of these cells. Functional tests of NK cell activity were not performed.

INTERVAL ANALYSIS (Fig. 15-11)

Initial evaluation of lymphocyte subpopulations was available in 11 patients and repeated in 9 patients. The data show that there were some variations in interim measurement. The percentages of cells varied the least. The maximum inter-assay variation was in that of CD4 cells that varied by maximum of 17%. The absolute counts varied by between 13-30%. There was however no significant difference in the results of the two analyses, confirming the general reliability of the laboratory assays. The CD4/CD8 ratio was preserved in all, but one patient.

Fig. 15-10. Natural Killer Cells: Phenotypes

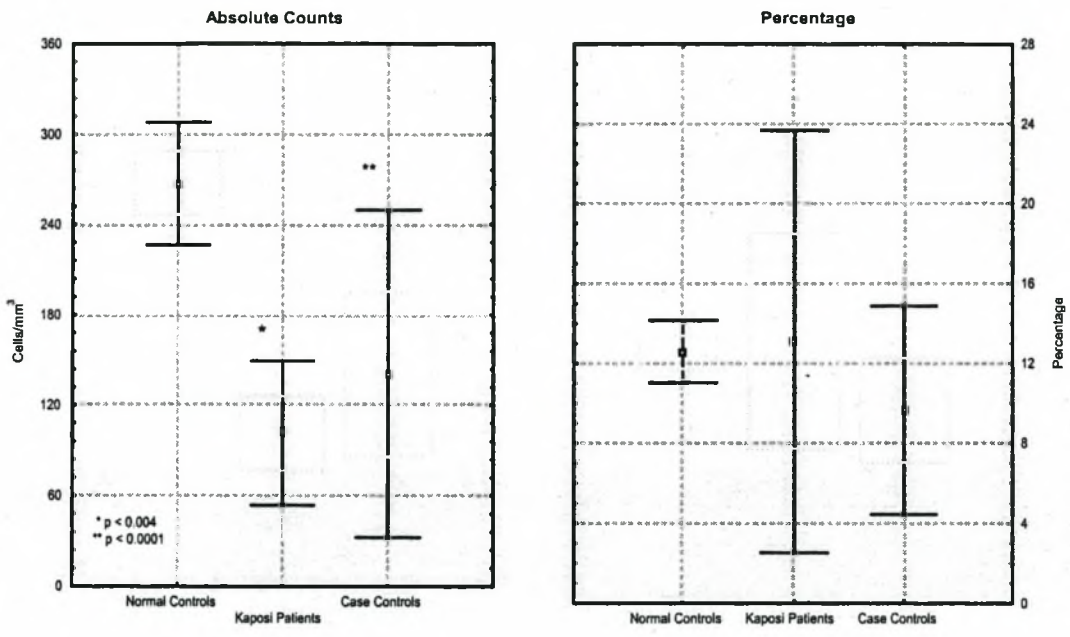
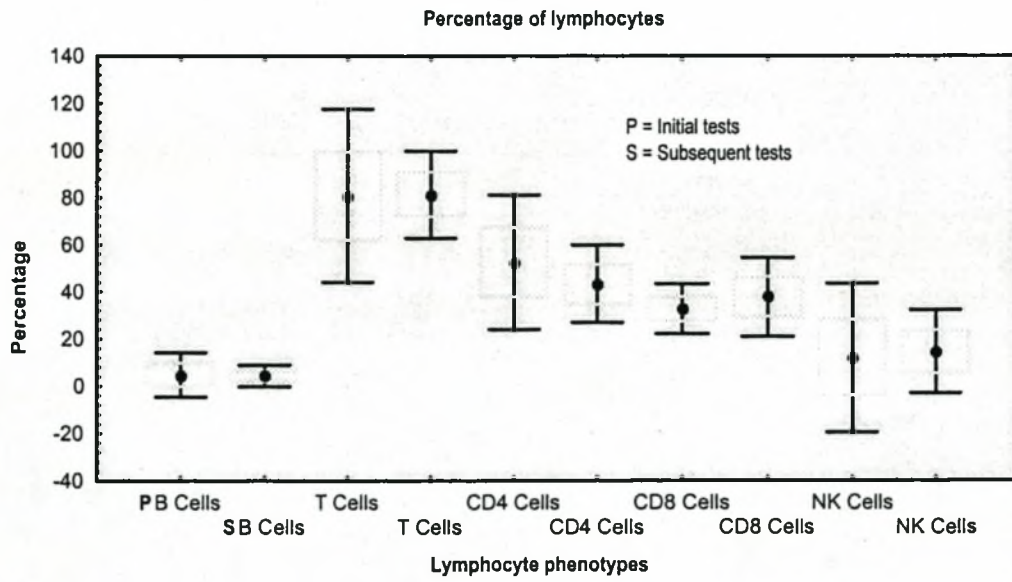
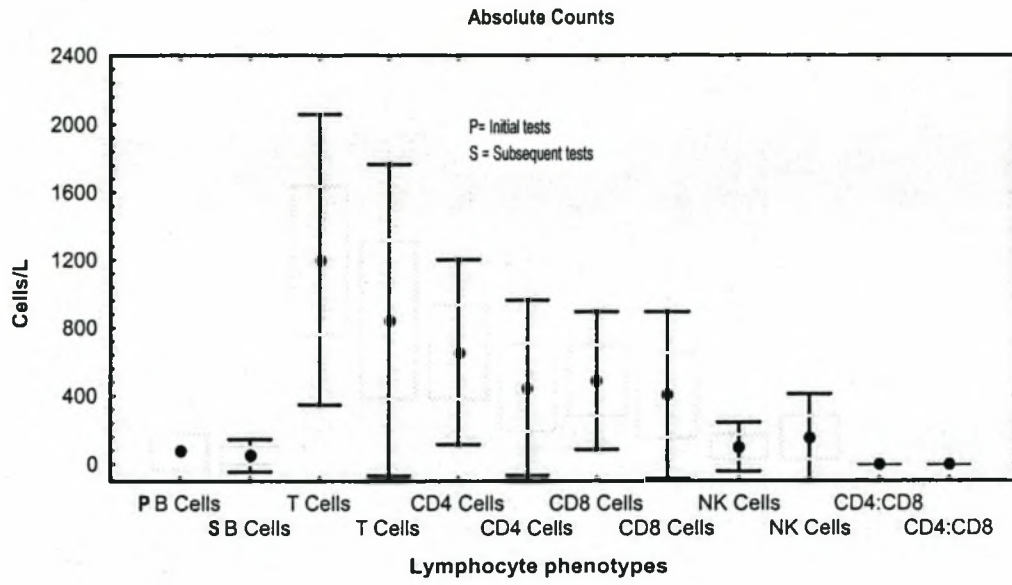


Fig. 15-11. Interval Analysis of Lymphocyte Sub-populations



Discussion

The immune system plays a crucial role in the development of Kaposi's sarcoma. This is evidenced firstly by the association of Kaposi's sarcoma with both pathological and iatrogenic immunosuppression. Kaposi's sarcoma is the most common malignancy in AIDS developing in 20% to 30% of patients. (Ensoli *et al.*,1998;Friedman-Kien,1981;Haverkos *et al.*,1985;Hymes *et al.*,1981;Longo *et al.*,1984;Maurice *et al.*,1982;Safai *et al.*,1985). It occurs particularly but not exclusively in homosexual and bisexual males but the incidence is decreasing as a result of safer sex practices and the availability of effective anti-retroviral agents Myskowski *et al.*,1997;Schatz *et al.*,1997). Kaposi's sarcoma is also one of the most frequent malignancies following organ transplantation (Penn,1986; Penn,1990; Penn,1993c; Penn,1993b). Of greater importance is the observation that decreasing immunosuppression and allowing patients to regain immunological competence results in disappearance of Kaposi's sarcoma lesions (Levy *et al.*,1983;Longo *et al.*,1984;Margolius,1996). The putative cause of Kaposi's sarcoma is HHV-8 and it is likely that the cellular insult caused by the virus leads to the multiple sequential changes necessary for malignant transformation (Ensoli *et al.*,1998;Stevenson *et al.*,1993). The exact role of the immune system in the development of Kaposi's sarcoma is speculative and has not been fully investigated (Levy *et al.*,1983). There was speculation that the use of immunosuppression results in the compromise of the immunosurveillance mechanisms (Bencini *et al.*,1993). On the other hand Levy and Ziegler (1983) suggested that selective immunostimulation in AIDS patients and Bencini *et al.* (1993) proposed that persistent antigenic stimulation in allograft recipients resulted in the production of factors with angiogenic properties (Bencini *et al.*,1993). Another important observation made by Bencini (1993) which we have been able to confirm, is that a large number of Kaposi's sarcoma patients did not suffer rejection of their grafts despite reduction of immunosuppression. These observations therefore suggest the development of Kaposi's sarcoma in a renal transplant recipient is the result of a depressed immune response that provides "relative" tolerance of the graft even with minimal immunosuppression therapy.

Our study was designed to address some of the immunological aspects of Kaposi's sarcoma, especially the question of whether patients who developed Kaposi's sarcoma, were immunologically different from their other transplanted counterparts. Both humoral and cellular immunity were investigated as well as aspects of the NK cell function.

HUMORAL IMMUNITY

Our data show that B cell numbers are markedly depressed in renal transplant patients on immunosuppression. Kaposi's sarcoma patients are affected as severely as control patients. Despite the reduction in B cell numbers, immunoglobulin production seems to be relatively well maintained with no specific pattern of abnormality being noted. Pollock *et al.* (1989) reported that 35% of 110 renal transplant patients had low levels of one or more of the serum immunoglobulin phenotypes. Our experience in the combined Kaposi's sarcoma and case controls was similar with 27% of transplanted patients having one or more serum immunoglobulin level that was low. Although more Kaposi's sarcoma patients had lower immunoglobulin levels (38%) the difference was not significant compared to the control group (11%). None of the patients was however prone to recurrent infections. Pollock observed an increased incidence of skin cancer in those of his patients with abnormal immunoglobulin levels (Pollock *et al.*, 1989).

An important observation in our group of patients, however, was the strong association between low serum immunoglobulin levels and low serum albumin. All the patients with low serum immunoglobulin levels also had reduced serum albumin levels suggesting that malnutrition may well have contributed to the patients' immunodepression. Hypoalbuminaemia is a well-recognised feature of protein calorie malnutrition (Rossing, 1978). Of the patients with normal serum immunoglobulin levels only 13% had low serum albumin levels. Since our control group was mainly of a higher social class compared to the Kaposi's sarcoma study patients, the difference in the immunoglobulin abnormalities could be explained by the differences in the nutritional status of the patients. However the influence of protein energy malnutrition on serum immunoglobulin levels seems to be very contradictory (Sall *et al.*, 1994). Various studies *in vitro* and in malnourished children and adults (Chang, 1990) have failed to show significant reductions in serum

immunoglobulin levels (Revillard *et al.*,1990;Schopper *et al.*,1976;Stiehm,1980). The exception is serum and (McMurray *et al.*,1981) secretory IgA which is diminished in lung and intestinal secretions of malnourished children (Chandra *et al.*,1994;Revillard *et al.*,1990;Stiehm,1980) in a finding confirmed by laboratory studies (Ha *et al.*,1996;Ha *et al.*,1997). Hypogammaglobulinaemia seems to develop mainly in the very young very severely malnourished patients (McMurray *et al.*,1981;Schopper *et al.*,1976;Stiehm,1980). The abnormalities in immunoglobulin experienced by our patients are therefore unlikely to have been related to malnutrition. Uraemia is also unlikely to have depressed immunoglobulin levels. The serum creatinine levels were almost 3 times greater in the transplant patients, but minor immunoglobulin abnormalities have only been described in renal patients who have been treated with continuous ambulatory peritoneal dialysis for prolonged periods of time (Palop *et al.*,1997). The alteration of B cell numbers and functions can therefore only be ascribed to a depressed immune response, associated with the use of immunosuppressive agents. Our functional test, using PWM to stimulate B-lymphocyte transformation, however failed to reveal significant abnormality of B cell function.

Master and Kyalwazi (1970) evaluated humoral immunity in patients with endemic Kaposi's sarcoma and found normal antibody responses to *Escherichia coli* (Vi) antigen and normal serum immunoglobulin levels. Despite marked quantitative deficiencies in B cells, humoral immunity is preserved in renal transplant patients whose Kaposi's sarcoma is in remission. This contrasts with the findings in AIDS patients. The initial observations that AIDS patients had normal or elevated immunoglobulin levels was interpreted to mean that humoral immunity was spared in this syndrome (Friedman-Kien,1981;Gottlieb *et al.*,1981;Masur *et al.*,1981;Siegal *et al.*,1981;Stahl *et al.*,1982). However, further investigation revealed that these patients had intense polyclonal B-cell activation characterised by increased levels of immunoglobulins and circulating immune complexes (Lane *et al.*,1983;Lane *et al.*,1985b;Lightfoot *et al.*,1984) and inability to mount an antigen-specific antibody response following immunisation (Ammann *et al.*,1984;Lane *et al.*,1983), enhanced responsiveness to B cell growth factors and impaired response to normal *in vitro* signals for B-cell activation. Unfractionated T-cells from AIDS patients are a poor source of help with regard to PWM-induced B-cell differentiation (Benveniste *et*

al.,1983;Lane *et al.*,1983;Mildvan *et al.*,1982). This decreased ability to provide help to B-cells was shown to be due the decreased activity of CD4⁺ cells rather than the increased suppressor activity of CD8⁺ cells (Benveniste *et al.*,1983;Lane *et al.*,1983). Oligoclonal and monoclonal immunoglobulins were detected in 89% of patients with AIDS who developed Kaposi's sarcoma as opposed to only 13% of patients with AIDS who had opportunistic infections (Papadopoulos *et al.*,1985). This almost certainly was a function of the switch of the CD4⁺ cell from Th-1 genotype to Th-2 genotype (McGrath,1996). Monoclonal bands are frequently found in the sera of patients with B-lymphocyte malignancies such as lymphomas and chronic lymphocytic leukaemia. Paraproteinemias and lymphocytic malignancies have been described in patients with classical Kaposi's sarcoma while lymphomas are more common in AIDS patients (Ciobanu *et al.*,1983). The authors suggested that similar mechanisms might be operative in the malignant proliferation of B-cells and endothelial cells in patients with AIDS (Papadopoulos *et al.*,1985). However, a new theory has been proposed for the development of Kaposi's sarcoma in HIV-patients based on the impact of HIV infected macrophages (Ensoli *et al.*,1998). Our study of posttransplant Kaposi's sarcoma did not analyse CD4⁺ subclasses. In view of the importance of the Th-1 and Th-2 subpopulations in the progression of AIDS, it would be an useful area for future investigation in our patients.

CELLULAR IMMUNITY

T Cell Phenotypes and Function

The T cells are the main role-players of cell mediated immunity and have functions that are far ranging. T cells are both immunoregulatory (the Th and Ts cells) as well as effector cells (primarily cytotoxic T cells) (Fleisher,1996). In our patients immunosuppression was characterised by reductions in CD3⁺, CD4⁺ and CD8⁺ cell lines as well as a reduction (but not reversal) of the CD4/CD8 ratio with Kaposi's sarcoma patients generally being more affected than the case controls. Although T cell phenotypes were depressed in our immunosuppressed patients, the reduction was less pronounced than the B cell count. T cell function as evidenced by the mitogen stimulation tests, however was significantly impaired. Not only were the Con A and PHA responsiveness less than in controls, but Kaposi's sarcoma patients

had significantly reduced mitogenic responsiveness compared to the case control patients. The decreased blast transformation of unfractionated T-cells *in vitro* to the mitogens may be due to the reduced CD4⁺ cell numbers. Further studies using purified T-cell subsets would be required to elucidate the cause of the impaired mitogenic responses.

In the case of AIDS patients reversal of the CD4⁺/CD8⁺ ratio was a characteristic manifestation of the immunological profile (Gottlieb *et al.*,1981;Lane *et al.*,1985b;Siegal *et al.*,1981). This was found to be due to a marked decrease in CD4⁺ T-cell numbers and either elevated/normal (usually early) and decreased numbers of CD8⁺ T-cells (late in the course of the disease) (Ammann *et al.*,1983;Fahey *et al.*,1984;Lane *et al.*,1985a;Schroff *et al.*,1983;Stahl *et al.*,1982;Tsoukas *et al.*,1994). Of note is that the depletion of CD4⁺ cells occurred not only in the peripheral blood but also in the lymphoid tissue (Margolick *et al.*,1997). Despite the phenotypic evidence of enhanced activation of the CD8⁺ cells *in vitro* Lane *et al.* (1983; 1985b) found little *in vivo* evidence of functional suppressor activity on the rest of the immune system. In AIDS patients with Kaposi's sarcoma only, the CD8⁺ count was elevated (Lane *et al.*,1985a), in contrast to our experience in posttransplant patients in whom the numbers were reduced. In AIDS patients there are reports that CD8⁺ T cells are able to suppress HIV replication in CD4⁺ T cells both *in vivo* and *in vitro*, the latter even with low numbers of CD8⁺ T-cells (Walker *et al.*,1986;Walker *et al.*,1989;Wiviott *et al.*,1990). It has also been observed that in AIDS patients the T-cell defect can be corrected by purification of cells before testing for proliferation and CD4⁺ cell function suggesting that this restoration of function could be due to the elimination of CD8⁺ suppressor cells (Margolick *et al.*,1985). On the basis of these and other relevant observations Aranda-Anzaldo (1991) has postulated that an active CD8⁺ T lymphocyte population causes down-regulation of the persistently activated CD4⁺ cells in an antigen-stimulated host leading to a state of immune over-suppression (Aranda-Anzaldo,1991). CD4⁺ cell counts therefore decline with consequent decrease in cytokines essential for the activation of macrophages and NK cells. The patient with a renal allograft is also subjected to chronic antigenic stimulation (Bencini *et al.*,1993) and the role of CD8⁺ suppressor T-cell in the development of the opportunistic infections and neoplasms such as Kaposi's sarcoma needs to be investigated despite the findings of reduced

CD8⁺ T cells. An alternative proposal for the T-cell abnormalities seen in AIDS patients was proposed by Margolick and Donnenberg (1997) and independently by Adleman and Wofsy (1996) who coined the term "blind T-cell homeostasis". This hypothesis proposes that as the number of CD4⁺ cells decline in HIV infection they are gradually replaced by CD8⁺ cells maintaining the T-cells counts unchanged. In our immunosuppressed patients this phenomenon has not been observed presumably because of the influence of the immunosuppressive agents.

Harwood *et al.* (1979) were the first to postulate and test the role of immunosuppression in the aetiology of Kaposi's sarcoma in renal transplant recipients. They found that on mitogenic stimulation, the responses of the patients were reduced compared to controls. However, these responses normalised once the patients were in remission. They therefore concluded that the immunological deficiency was secondary to the presence of the tumour. Our studies were performed when the Kaposi's sarcoma patients had been in remission for several months to years. The patients demonstrated a depressed response when compared to controls on the same immunosuppressive regimen. Our observation therefore refutes the postulate that Kaposi's sarcoma was causing the immunosuppression. We contend that patients who developed Kaposi's sarcoma were relatively more immunocompromised as suggested by Bencini *et al.* (1993). Friedman-Birnbaum *et al.* (1991) studied T lymphocyte subsets, CD4/CD8 ratio and natural killer cell activity in 28 patients with classic Kaposi's sarcoma. The CD4⁺ and CD8⁺ lymphocytes as well as the CD4⁺/CD8⁺ ratio were normal in virtually all their patients. Indeed, in some of the patients with more extensive disease, the CD8 T-cell count was at the upper ranges of normal. It would seem that depression of cellular immunity might play a role in the development of iatrogenic Kaposi's sarcoma, but not necessarily in classic Kaposi's sarcoma. This observation is supported by some earlier studies in patients with classic Kaposi's sarcoma that cellular immunity was not significantly impaired (Kamal *et al.*, 1995; Meneghini *et al.*, 1975). These studies were however, small and uncontrolled.

Delayed Type Hypersensitivity (DTH)

Delayed type hypersensitivity (DTH) response is a complex immune function that can be used to determine *in vivo* T-cell function. It is a complex response requiring

antigen processing, antigen specific T-cells and the recruitment of monocytes and macrophages (Lane *et al.*,1985b). In all our patients the delayed type hypersensitivity was impaired in that not a single patient responded to *Candida albicans* antigen and only 4 responded to tuberculin. The lack of response to *Candida* antigen could be lack of exposure to the antigen (unlikely) or it could reflect T cell anergy. Fleischer (1996) recommends the use of more than one antigen for DTH skin testing. A combination of 2 or 3 antigens should elicit at least one positive reaction in a normal adult (Birx *et al.*,1993;Phillips *et al.*,1991). Master and Taylor (1970) found impairment of DTH reaction in patients with endemic Kaposi's sarcoma. Delayed type hypersensitivity impairment in our patients was related to the use of immunosuppression and Kaposi's sarcoma patients were not unduly compromised. In fact, all 4 positive tuberculin reactions occurred in the Kaposi's sarcoma patients and all were nonwhite, a group particularly prone to tuberculosis in the Western Cape (Szende *et al.*,1997). On the other hand, the ability of Kaposi's sarcoma patients to mount a DTH response to tuberculin, may indicate selective immunostimulation as suggested by Prehn (1996) and Levy (1983), which may have made them more prone to Kaposi's sarcoma.

NATURAL KILLER (NK) CELLS

Natural killer cells represent the third arm of the lymphocyte system, distinct from the B and T cells. The natural killer cells are large granular lymphocytes that mediate non-human leucocyte antigen (HLA) restricted cytotoxicity. They are able to kill a wide range of target cells including malignant cells and cells infected with bacteria and viruses (Spits *et al.*,1995). In addition, NK cells produce an array of cytokines such as interferon- γ that are involved in the elimination of intracellular pathogens as well as in the generation of antigen specific immune responses.

Deficiency in natural killer cell function has been observed in a patient with recurrent herpesvirus infections emphasising the importance of natural killer cells in host defences against this group of DNA viruses (Biron *et al.*,1989). There is evidence that natural killer cells also mediate allograft rejections (Fleisher,1996). Abnormalities of natural killer cells may well represent the primary defect

predisposing patients to the development of malignancies. Our study has clearly shown a marked reduction in the number of natural killer cells in all transplant patients enhancing susceptibility firstly, to herpesvirus infection and secondly, to the development of neoplastic transformation. Experimental evidence has established that natural killer cells play a significant role in the first line of defence against neoplastic cells (Stevenson *et al.*,1993). Although we quantified natural killer cells by fluorescence-activated cell sorter (FACS) analysis (of CD16 and CD56 bearing lymphocytes) future avenues of investigation should include *in vitro* functional testing of natural killer cells by evaluating activity in a standard cytotoxic assay with labelled cell lines as targets (Whiteside *et al.*,1992). Alternatively, antibody dependent cellular cytotoxicity (ADCC) should be assessed (Whiteside *et al.*,1992). Lymphocyte-activated killer (LAK) cells are natural killer cells that have been exposed to IL-2 which increases the level of cytotoxicity and range of susceptible target cells (Grimm *et al.*,1982). This, together with interferon enhancement of standard natural killer cell activity represent additional tests which can be performed to complete the study of this population of cells (Grimm *et al.*,1982;Weigent *et al.*,1983;Whiteside *et al.*,1990).

Cyclosporine inhibits IL-2 production via the calcineurin pathway (Kahan,1989; Schreiber *et al.*,1992). The influence of cyclosporine on natural killer cells may well result in depression of LAK formation thus accounting for the increased incidence of both viral infections and malignancies in cyclosporine treated patients. Patients with AIDS typically have normal numbers of NK cells in the peripheral circulation but defective NK cell activity. However, *in vitro* cultivation of the lymphocytes of these patients with IL-2 results in marked enhancement of NK cell activity suggesting that in AIDS patients there is defective induction that is normally provided by the CD4⁺ cell (Rook *et al.*,1985). There appear to be no studies that specifically address the issue of NK cell numbers and function in Kaposi's sarcoma patients.

Recent studies have demonstrated that interaction with the MHC class I molecules on target cells can turn off NK cell mediated cytotoxicity (Blery *et al.*,2000; Lanier,1998; Long,1999). In the absence of appropriate interaction between NK cell receptors and MHC class I molecules, NK cells can exert their cytolytic function. Therefore, NK cells eliminate autologous cells that present quantitative or qualitative

alterations of MHC class I (Garrido *et al.*,1997). On the other hand, activating signals for NK cells may be initiated by many different adhesion or costimulatory molecules (Bakker *et al.*,2000;Bottino *et al.*,2000). The B7 family and intercellular adhesion molecule -1 (ICAM-1) can function as ligands for NK cell mediated cytotoxicity-activating receptors (Azuma *et al.*,1992;Dang *et al.*,1990;Galea-Lauri *et al.*,1999;Wilson *et al.*,1999). The strength of this response has been shown to override the negative signaling between NK cell receptors and the MHC class I molecules (Chambers *et al.*,1996). A novel effect of HHV-8 has recently been demonstrated on the NK cell. The K5 molecule of HHV-8 has been shown to downregulate the MHC class I receptor (*vide supra*). However, although MHC class I downregulation may protect KSHV-infected cells from cytotoxic T lymphocyte recognition, these cells still become potential targets for natural killer (NK) cell-mediated lysis: Ishido *et al.* (2000a) have elegantly demonstrated that K5 downregulates ICAM-I and B7, which are ligands for NK cell-mediated cytotoxicity receptors. This is a novel viral immune evasion strategy where KSHV K5 achieves immune avoidance by downregulation of cellular ligands for NK cell-mediated cytotoxicity receptors. Consequently, virus-infected cells are protected from destruction by innate effector cells.

MONOCYTE-MACROPHAGE FUNCTION

Monocyte-macrophage function was not addressed in this study but there is mounting evidence of the important role played by this group of cells in the development of Kaposi's sarcoma (Ensoli *et al.*,1998;McGrath,1996). Macrophages are critical for antigen processing and phagocytosis of particulate matter including organisms with antibody attached to them (Delves *et al.*,2000). These are efficiently ingested through Fc receptor-mediated phagocytosis (McGrath,1996). Macrophages express the CD4 cell surface marker (Rook *et al.*,1985) and the cell can be infected by HIV both through this marker and the Fc receptor (Takeda *et al.*,1990). Unlike the infected CD4⁺ T-cell which dies when the HIV replicates the macrophage survives for prolonged periods (Crowe *et al.*,1987). The numbers of these cells are maintained until HIV disease is far advanced although this cell population is functionally impaired. There is reduced ability to phagocytose (Crowe

et al.,1994), to present antigen (Ennen *et al.*,1990), to respond to chemoattractants (Poli *et al.*,1985; Smith *et al.*,1984) and to disrupt normal cytokine expression (Roy *et al.*,1988). Some of these abnormalities may be related to the blockade of the Fc receptor by excess immune complexes (McGrath,1996). In AIDS patients a number of diseases are associated with HIV-infected macrophages including dementia and large cell lymphoma. Both these conditions are associated with the production and release of cytokines that have a detrimental effect on the host tissue. In a clonal form of HIV associated with early stages of Kaposi's sarcoma, macrophages that express HIV also expressed basic fibroblast growth factor, IL-6 and HIV tat (McGrath *et al.*,1995). The macrophages that expressed HIV also co-expressed basic fibroblast growth factor, IL-6 and HIV tat. These cytokines are all associated with spindle-cell proliferation, the malignant cell found in Kaposi's sarcoma (Ensoli *et al.*,1998). A new model of tumourigenesis termed sequential neoplasia has been suggested (McGrath *et al.*,1995). In this model HIV integration would cause malignant transformation of the infected macrophage to occur. The type of secondary neoplasia that the individual patient would be at risk of developing would depend on where the HIV is integrated within the macrophage population (Shiramizu *et al.*,1994). No studies on the role of the macrophage in posttransplant patients have been undertaken but the exciting developments in epidemic Kaposi's sarcoma promises to enhance understanding of the underlying pathophysiology of Kaposi's sarcoma. This is another potentially fruitful area of research.

SUMMARY

- T cell function and (possibly NK cell activity) may be more severely impaired in patients who are prone to develop Kaposi's sarcoma following renal transplantation. This may explain the failure of these patients to develop acute rejection following reduction of immunosuppression. It is unlikely that Kaposi's sarcoma causes immunosuppression *per se*.
- B cell and NK cell counts are the most profoundly depressed.

- Serum immunoglobulin level abnormalities are common, but invariably associated with hypo-albuminaemia.
- The tuberculin skin test may possibly be an early clue to identify patients who may be at risk of developing Kaposi's sarcoma.

Recommendations

- Immunosuppressive protocols should allow for the reduction of immunosuppression as early as possible.
- Since it is impractical to monitor the T cell function in allograft recipients, clinical suspicion of neoplasms should be high.

LITERATURE CITED

- Adleman, L. M. and Wofsy, D. (1996). Blind T-cell homeostasis in CD4-deficient mice. *J.Acquir.Immune.Defic.Syndr.Hum.Retrovirol.* **11**, 334.
- Ammann, A. J., Abrams, D., Conant, M., et al. (1983). Acquired immune dysfunction in homosexual men: immunologic profiles. *Clin.Immunol.Immunopathol.* **27**, 315.
- Ammann, A. J., Schiffman, G., Abrams, D., Volberding, P., Ziegler, J., and Conant, M. (1984). B-cell immunodeficiency in acquired immune deficiency syndrome. *JAMA.* **251**, 1447.
- Appleman, L. J. and Frey, A. B. (1996). Tumors antigens encoded by oncogenes and the impact of oncogenes upon the immune responses. *Cell Immunol.* **170**, 1.
- Aranda, Anzaldo A. (1991). A role for CD8+ T lymphocytes in the pathogenesis of AIDS. *Res Immunol.* **142**, 541.
- Ashall, F., Bramwell, M. E., and Harris, H. (1982). A new marker for human cancer cells. 1 The Ca antigen and the Ca1 antibody. *Lancet.* **2**, 1.
- Ashida, E. R., Johnson, A. R., and Lipsky, P. E. (1981). Human endothelial cell-lymphocyte interaction. Endothelial cells function as accessory cells necessary for mitogen-induced human T lymphocyte activation *in vitro*. *J.Clin.Invest.* **67**, 1490.

- Azuma, M., Cayabyab, M., Buck, D., Phillips, J. H., and Lanier, L. L. (1992). Involvement of CD28 in MHC-unrestricted cytotoxicity mediated by a human natural killer leukemia cell line. *J.Immunol.* **149**, 1115.
- Bakker, A. B., Wu, J., Phillips, J. H., and Lanier, L. L. (2000). NK cell activation: distinct stimulatory pathways counterbalancing inhibitory signals. *Hum.Immunol.* **61**, 18.
- Baldwin, W. M. III. (1982). The symbiosis of immunocompetent and endothelial cells. *Immunol.Today.* **3**, 267.
- Barbacid, M. (1990). *ras* oncogenes: their role in neoplasia. *Eur.J.Clin.Invest.* **20**, 225.
- Ben Neriah, Y., Daley, G. Q., Mes-Masson, A. M., Witte, O. N., and Baltimore, D. (1986). The chronic myelogenous leukemia-specific P210 protein is the product of the *bcr/abl* hybrid gene. *Science.* **233**, 212.
- Bencini, P. L., Montagnino, G., Tarantino, A., Alessi, E., Ponticelli, C., and Caputo, R. (1993). Kaposi's sarcoma in kidney transplant recipients. *Arch.Dermatol.* **129**, 248.
- Benveniste, E., Schroff, R., Stevens, R. H., and Gottlieb, M. S. (1983). Immunoregulatory T cells in men with a new acquired immunodeficiency syndrome. *J.Clin.Immunol.* **3**, 359.
- Beverley, P. C. L. (1998). Tumour Immunology. In *Immunology*, 5th ed. (Roitt, I. M., Brostoff, J., and Male, D., eds.), p.273, Mosby, London.
- Billingham, R. E. and Silvers, W. K. (1971). *The immunobiology of transplantation.* Prentice-Hall, New Jersey.
- Biron, C. A., Byron, K. S., and Sullivan, J. L. (1989). Severe herpesvirus infections in an adolescent without natural killer cells. *N.Engl.J.Med.* **320**, 1731.
- Birx, D. L., Brundage, J., Larson, K., *et al.* (1993). The prognostic utility of delayed-type hypersensitivity skin testing in the evaluation of HIV-infected patients. Military Medical Consortium for Applied Retroviral Research. *J.Acquir.Immune.Defic.Syndr.* **6**, 1248.
- Blery, M., Olcese, L., and Vivier, E. (2000). Early signaling via inhibitory and activating NK receptors. *Hum.Immunol.* **61**, 51.
- Bodey, B., Bodey, B., Siegel, S. E., and Kaiser, H. E. (1998). The spontaneous regression of neoplasms in mammals: possible mechanisms and their application in immunotherapy. *In vivo.* **12**, 107.

- Bottino, C., Biassoni, R., Millo, R., Moretta, L., and Moretta, A. (2000). The human natural cytotoxicity receptors (NCR) that induce HLA class I- independent NK cell triggering. *Hum.Immunol.* **61**, 1.
- Boussiotis, V. A., Pardo, N. A., Collins, H., et al. (1996). R24 anti-GD3 ganglioside antibody can induce costimulation and prevent the induction of alloantigen-specific T cell clonal anergy. *Eur.J.Immunol.* **26**, 2149.
- Bowen, D. L., Lane, H. C., and Fauci, A. S. (1986). Immunologic abnormalities in the acquired immunodeficiency syndrome. *Prog Allergy.* **37**, 207.
- Brander, C., Suscovich, T., Lee, Y., et al. (2000). Impaired CTL recognition of cells latently infected with Kaposi's sarcoma-associated herpes virus. *J.Immunol.* **165**, 2077.
- Browning, M. J. and Bodmer, W. F. (1992). MHC antigens and cancer: implications for T-cell surveillance. *Curr.Opin.Immunol.* **4**, 613.
- Burnet, F. M. (1970a). Immunological surveillance. Pergamon, Oxford.
- Burnet, F. M. (1970b). The concept of immunologic surveillance. *Prog.Exp.Tumor Res.* **13**, 1.
- Carey, T. E., Takahashi, T., Resnick, L. A., Oettgen, H. F., and Old, L. J. (1976). Cell surface antigens of human malignant melanoma: mixed hemadsorption assays for humoral immunity to cultured autologous melanoma cells. *Proc.Natl Acad.Sci.U.S.A.* **73**, 3278.
- Castleberry, R. P. (1997). Neuroblastoma. *Eur.J.Cancer.* **33**, 1430.
- Chambers, B. J., Salcedo, M., and Ljunggren, H. G. (1996). Triggering of natural killer cells by the costimulatory molecule CD80 (B7-1). *Immunity.* **5**, 311.
- Chandra, R. K. and Kumari, S. (1994). Nutrition and immunity: an overview. *J Nutr.* **124**, 1433S.
- Chang, S. J. (1990). Antimicrobial proteins of maternal and cord sera and human milk in relation to maternal nutritional status. *Am J Clin Nutr.* **51**, 183.
- Ciobanu, N., Andreeff, M., Safai, B., Koziner, B., and Mertelsmann, R. (1983). Lymphoblastic neoplasia in a homosexual patient with Kaposi's sarcoma. *Ann.Intern.Med.* **98**, 151.
- Coscoy, L. and Ganem, D. (2000). Kaposi's sarcoma-associated herpesvirus encodes two proteins that block cell surface display of MHC class I chains by enhancing their endocytosis. *Proc.Natl.Acad.Sci.U.S.A.* **97**, 8051.

- Coulie, P. G. (1997). Human tumour antigens recognized by T cells: new perspectives for anti-cancer vaccines? *Mol.Med.Today*. **3**, 261.
- Crowe, S., Mills, J., and McGrath, M. S. (1987). Quantitative immunocytofluorographic analysis of CD4 surface antigen expression and HIV infection of human peripheral blood monocyte/macrophages. *AIDS Res Hum.Retroviruses*. **3**, 135.
- Crowe, S. M., Vardaxis, N. J., Kent, S. J., et al. (1994). HIV infection of monocyte-derived macrophages *in vitro* reduces phagocytosis of *Candida albicans*. *J.Leukoc.Biol*. **56**, 318.
- Dang, L. H., Michalek, M. T., Takei, F., Benaceraff, B., and Rock, K. L. (1990). Role of ICAM-1 in antigen presentation demonstrated by ICAM-1 defective mutants. *J.Immunol*. **144**, 4082.
- Dawson, M. and Moore, M. (1989). Immunology. *In Immunology*, 2nd edition ed. (Roitt, I. M., Brostoff, J., and Male, D., eds.), p.18.1, Gower, London.
- de Klein, A., van Kessel, A. G., Grosveld, G., et al. (1982). A cellular oncogene is translocated to the Philadelphia chromosome in chronic myelocytic leukaemia. *Nature*. **300**, 765.
- Delves, P. J. and Roitt, I. M. (2000). The immune system. First of two parts. *N.Engl.J.Med*. **343**, 37.
- Doherty, P. C. and Zinkernagel, R. M. (1974). T-cell-mediated immunopathology in viral infections. *Transplant.Rev*. **19**, 89.
- Doherty, P. C. and Zinkernagel, R. M. (1975). H-2 compatibility is required for T-cell-mediated lysis of target cells infected with lymphocytic choriomeningitis virus. *J.Exp Med*. **141**, 502.
- Ehrlich, P. (1957). Über den jetzigen Stand der Karzinomforschung. In *The Collected Papers of Paul Ehrlich*. Vol II,(Himmelweit, F., eds.), p.550, Pergamon Press, London.
- Ennen, J., Seipp, I., Norley, S. G., and Kurth, R. (1990). Decreased accessory cell function of macrophages after infection with human immunodeficiency virus type 1 *in vitro*. *Eur.J.Immunol*. **20**, 2451.
- Ensoli, B. and Sirianni, M. C. (1998). Kaposi's sarcoma pathogenesis: a link between immunology and tumor biology. *Crit Rev Oncog*. **9**, 107.

- Fahey, J. L., Prince, H., Weaver, M., *et al.* (1984). Quantitative changes in T helper or T suppressor/cytotoxic lymphocyte subsets that distinguish acquired immune deficiency syndrome from other immune subset disorders. *Am.J.Med.* **76**, 95.
- Fauci, A. S. (1982). The syndrome of Kaposi's sarcoma and opportunistic infections: an epidemiologically restricted disorder of immunoregulation [editorial]. *Ann.Intern.Med.* **96**, 777.
- Fauci, A. S. and Lane, H. C. (1984b). Overview of clinical syndromes and immunology of AIDS. *Top.Clin.Nurs.* **6**, 12.
- Fauci, A. S., Lane, H. C., and Volkman, D. J. (1983). Activation and regulation of human immune responses: implications in normal and disease states. *Ann.Intern.Med.* **99**, 61.
- Fauci, A. S., Macher, A. M., Longo, D. L., *et al.* (1984a). NIH conference. Acquired immunodeficiency syndrome: epidemiologic, clinical, immunologic, and therapeutic considerations. *Ann.Intern.Med.* **100**, 92.
- Fleisher, T. A. (1996). Evaluation of the potentially immunodeficient patient. *Adv.Intern.Med.* **41**, 1.
- Friedman-Birnbaum, R, Weltfriend, S, and Pollack, S. (1991). Classical Kaposi's sarcoma: T-lymphocyte subsets, T4/T8 ratio, and NK cell activity. *J.Am.Acad.Dermatol.* **24**, 937.
- Friedman-Kien, A. E. (1981). Disseminated Kaposi's sarcoma syndrome in young homosexual men. *J.Am.Acad.Dermatol.* **5**, 468.
- Fung, Y. K., Lewis, W. G., Crittenden, L. B., and Kung, H. J. (1983). Activation of the cellular oncogene c-erbB by LTR insertion: molecular basis for induction of erythroblastosis by avian leukosis virus. *Cell.* **33**, 357.
- Galea-Lauri, J., Darling, D., Gan, S. U., *et al.* (1999). Expression of a variant of CD28 on a subpopulation of human NK cells: implications for B7-mediated stimulation of NK cells. *J.Immunol.* **163**, 62.
- Garrido, F., Ruiz-Cabello, F., Cabrera, T., *et al.* (1997). Implications for immunosurveillance of altered HLA class I phenotypes in human tumours. *Immunol.Today.* **18**, 89.
- Gil Mateo MP, Miquel, F. J., Ledesma, E., Febrer, M. I., Tusset, C., and Aliaga, A. (1998). The absence of HHV-8 DNA sequences in skin tumours other than Kaposi's sarcoma from AIDS patients and transplant recipients [letter]. *Br J Dermatol.* **139**, 918.

- Gleichmann, E., Gleichmann, H., Schwartz, R. S., Weinblatt, A., and Armstrong 7y. (1975). Immunologic induction of malignant lymphoma: identification of donor and host tumors in the graft-versus-host model. *J.Natl.Cancer Inst.* **54**, 107.
- Gottlieb, M. S., Groopman, J. E., Weinstein, W. M., Fahey, J. L., and Detels, R. (1983). The acquired immunodeficiency syndrome. *Ann.Intern.Med.* **99**, 208.
- Gottlieb, M. S., Schroff, R., Schanker, H. M., *et al.* (1981). Pneumocystis carinii pneumonia and mucosal candidiasis in previously healthy homosexual men: evidence of a new acquired cellular immunodeficiency. *N.Engl.J.Med.* **305**, 1425.
- Grimm, E. A., Mazumder, A., Zhang, H. Z., and Rosenberg, S. A. (1982). Lymphokine-activated killer cell phenomenon. Lysis of natural killer-resistant fresh solid tumor cells by interleukin 2-activated autologous human peripheral blood lymphocytes. *J.Exp Med.* **155**, 1823.
- Ha, C. L., Paullno, Racine LE, and Woodward, B. D. (1996). Expansion of the humoral effector cell compartment of both systemic and mucosal immune systems in a weanling murine model which duplicates critical features of human protein-energy malnutrition. *Br J Nutr.* **75**, 445.
- Ha, C. L. and Woodward, B. (1997). Reduction in the quantity of the polymeric immunoglobulin receptor is sufficient to account for the low concentration of intestinal secretory immunoglobulin A in a weanling mouse model of wasting protein-energy malnutrition. *J Nutr.* **127**, 427.
- Habeck, M. (2000). Kaposi's sarcoma-associated virus mounts novel attack on immune system. *Mol.Med.Today.* **6**, 377.
- Hakomori, S. (1989a). Aberrant glycosylation in tumors and tumor-associated carbohydrate antigens. *Adv.Cancer Res.* **52**, 257.
- Hakomori, S. (1989b). Biochemical basis and clinical application of tumor-associated carbohydrate antigens: current trends and future perspectives. *Gan To Kagaku Ryoho.* **16**, 715 .
- Hall, E. (1997). Etiology of cancer: physical factors. *In Cancer: Principles and practice of oncology*, 5th ed. (De Vita, V. T. and Hellman, S., eds.), p.203, Lippincott-Raven, Philadelphia.
- Hariharan, I. K., Harris, A. W., Crawford, M., *et al.* (1989). A *bcr-v-abl* oncogene induces lymphomas in transgenic mice. *Mol.Cell Biol.* **9**, 2798.
- Harwood, A. R., Osoba, D, Hofstader, Sophie. L., *et al.* (1979). Kaposi's sarcoma in recipients of renal transplants. *Am.J.Med.* **67**, 759.

- Haverkos, H. W. and Drotman, D. P. (1985). Prevalence of Kaposi's sarcoma among patients with AIDS [letter]. *N.Engl.J.Med.* **312**, 1518.
- Hermans, P. (1998). Epidemiology, etiology and pathogenesis, clinical presentations and therapeutic approaches in Kaposi's sarcoma: 15-year lessons from AIDS. *Biomed.Pharmacother.* **52**, 440.
- Hirsch, M. S. and Murphy, F. A. (1968). Effects of anti-thymocyte serum on Rauscher virus infection of mice. *Nature.* **218**, 478.
- Hoover, R. and Fraumeni-JF, Jr. (1973). Risk of cancer in renal-transplant recipients. *Lancet.* **2**, 55.
- Hymes, K. B., Cheung, T., Greene, J. B., *et al* . (1981). Kaposi's sarcoma in homosexual men-a report of eight cases. *Lancet.* **2**, 598.
- Ishido, S., Choi, J. K., Lee, B. S., *et al.* (2000a). Inhibition of natural killer cell-mediated cytotoxicity by Kaposi's sarcoma-associated herpesvirus K5 protein. *Immunity.* **13**, 365.
- Ishido, S., Wang, C., Lee, B. S., Cohen, G. B., and Jung, J. U. (2000b). Downregulation of major histocompatibility complex class I molecules by Kaposi's sarcoma-associated herpesvirus K3 and K5 proteins. *J.Virol.* **74**, 5300.
- Jones, D. B., Castleden, M., Smith, J. L., Mepham, B. L., and Wright, D. H. (1978). Immunopathology of angioimmunoblastic lymphadenopathy. *Br.J.Cancer.* **37**, 1053.
- Kahan, B. D. (1989). Cyclosporine. *N.Engl.J.Med.* **321**, 1725.
- Kamal, Adel M. and Rashid, A. (1995). Kaposi's sarcoma in kidney transplant recipients -- immunological studies. *Journal of the European Academy of Dermatology and Venereology.* **5**, S112.
- Kastan, M. B., Onyekwere, O., Sidransky, D., Vogelstein, B., and Craig, R. W. (1991). Participation of p53 protein in the cellular response to DNA damage. *Cancer Res.* **51**, 6304.
- Kastan, M. B., Zhan, Q., el Deiry, W. S., *et al.* (1992). A mammalian cell cycle checkpoint pathway utilizing p53 and GADD45 is defective in ataxia-telangiectasia. *Cell.* **71**, 587.
- Kniker, W.T. and Bellanti, J.A. (1978). Immune defence mechanisms in tumor immunity. In *Immunology II*, (Bellanti, J.A., *ed.*), p.448, W.B. Saunders, Philadelphia.

- Krueger, G. R. F. (1972). Chronic immunopression and lymphomagenesis in man and mice. *Natl Cancer Inst Monogr.* **35**, 183.
- Lane, H. C., Depper, J. M., Greene, W. C., Whalen, G., Waldmann, T. A., and Fauci, A. S. (1985c). Qualitative analysis of immune function in patients with the acquired immunodeficiency syndrome. Evidence for a selective defect in soluble antigen recognition. *N.Engl.J.Med.* **313**, 79.
- Lane, H. C. and Fauci, A. S. (1985b). Immunologic abnormalities in the acquired immunodeficiency syndrome. *Annu.Rev Immunol.* **3**, 477.
- Lane, H. C., Masur, H., Edgar, L. C., Whalen, G., Rook, A. H., and Fauci, A. S. (1983). Abnormalities of B-cell activation and immunoregulation in patients with the acquired immunodeficiency syndrome. *N.Engl.J.Med.* **309**, 453.
- Lane, H. C., Masur, H., Gelmann, E. P., *et al.* (1985d). Correlation between immunologic function and clinical subpopulations of patients with the acquired immune deficiency syndrome. *Am.J.Med.* **78**, 417.
- Lane, H. F., Masur, H., Gelman, E. D., *et al.* (1985a). Correlation between immunologic function and clinical subpopulations of patients with the acquired immunodeficiency syndrome. *Am.J.Med.* **78**, 417.
- Lanier, L. L. (1998). Follow the leader: NK cell receptors for classical and nonclassical MHC class I. *Cell.* **92**, 705.
- Law, L. W. (1969). Studies of the significance of tumor antigens in induction and repression of neoplastic diseases: presidential address. *Cancer Res.* **29**, 1.
- Levine, A. J., Momand, J., and Finlay, C. A. (1991). The p53 tumour suppressor gene. *Nature.* **351**, 453.
- Levy, J. A. (1993). HIV pathogenesis and long-term survival [editorial]. *AIDS.* **7**, 1401.
- Levy, J. A. and Ziegler, J. L. (1983). Acquired immunodeficiency syndrome is an opportunistic infection and Kaposi's sarcoma results from secondary immune stimulation. *Lancet.* **2**, 78.
- Lightfoot, M. M., Folks, T. M., and Sell, K. W. (1984). Analysis of immune complex components isolated from serum of AIDS patients. *Fed.Proc.* **43**, 1921.
- Lloyd, K. O. (1990). Molecular characterisation of tumour antigens. *Immunol.Allergy Clinics N.Am.* **10**, 765.
- Long, E. O. (1999). Regulation of immune responses through inhibitory receptors. *Annu.Rev.Immunol.* **17**, 875.

- Longo, D. L., Steis, R. G., Lane, H. C., *et al* . (1984). Malignancies in the AIDS patient: natural history, treatment strategies, and preliminary results. *Ann.N.Y.Acad.Sci.* **437**, 421.
- Margolick, J. B. and Donnenberg, A. D. (1997). T-cell homeostasis in HIV-1 infection. *Semin.Immunol.* **9**, 381.
- Margolick, J. B., Volkman, D. J., Lane, H. C., and Fauci, A. S. (1985). Clonal analysis of T lymphocytes in the acquired immunodeficiency syndrome. Evidence for an abnormality affecting individual helper and suppressor T cells. *J.Clin.Invest.* **76**, 709.
- Margolius, L. P. (1996). Kaposi's sarcoma and other malignancies in renal transplant recipients. *Transplant.Rev.* **10**, 129.
- Martinez, C. (1964). Effect of early thymectomy on development of mammary tumours in mice. *Nature.* **203**, 1188.
- Martinez, J., Georgoff, I., Martinez, J., and Levine, A. J. (1991). Cellular localization and cell cycle regulation by a temperature- sensitive p53 protein. *Genes Dev.* **5**, 151.
- Master, S. P., Taylor, J. F., Kyalwazi, S. K., and Ziegler, J. L. (1970). Immunological studies in Kaposi's sarcoma in Uganda. *Br.Med.J.* **1**, 600.
- Masur, H., Michelis, M. A., Greene, J. B., *et al*. (1981). An outbreak of community-acquired *Pneumocystis carinii* pneumonia: initial manifestation of cellular immune dysfunction. *N.Engl.J.Med.* **305**, 1431.
- Maurice, P. D., Smith, N. P., and Pinching, A. J. (1982). Kaposi's sarcoma with benign course in a homosexual [letter]. *Lancet.* **1**, 571.
- McGrath, M. S. (1996). T-cells and macrophages in HIV disease. *Clin.Rev Allergy Immunol.* **14**, 359 .
- McGrath, M. S., Shiramizu, B. T., and Herndier, B. G. (1995). Identification of a clonal form of HIV in early Kaposi's sarcoma: evidence for a novel model of oncogenesis, "sequential neoplasia". *J. Acquir. Immune. Defic. Syndr. Hum. Retrovirol.* **8**, 379.
- McLaughlin, J., Chianese, E., and Witte, O. N. (1987). *In vitro* transformation of immature hematopoietic cells by the P210 BCR/ABL oncogene product of the Philadelphia chromosome. *Proc.Natl Acad.Sci.U.S.A.* **84**, 6558.

- McLaughlin, J., Chianese, E., and Witte, O. N. (1989). Alternative forms of the BCR-ABL oncogene have quantitatively different potencies for stimulation of immature lymphoid cells. *Mol. Cell Biol.* **9**, 1866.
- McMurray, D. N., Watson, R. R., and Reyes, M. A. (1981). Effect of renutrition on humoral and cell-mediated immunity in severely malnourished children. *Am J Clin Nutr.* **34**, 2117 .
- Meneghini, C. L., Angelini, G., and Bonifazi, E. (1975). Immunity in tumours of the skin. Studies on cell-mediated immune reactions. *Arch.Dermatol.Forsch.* **252**, 203.
- Melief, C. J. M. and Schwartz, R. S. (1975). Immunocompetence and malignancy. In *Cancer: A comprehensive treatise*. Vol 1.,(Becker, F. F., eds.), p.121, Plenum Press, New York.
- Mildvan, D., Mathur, U., Enlow, R. W., *et al.* (1982). Opportunistic infections and immune deficiency in homosexual men. *Ann.Intern.Med.* **96**, 700.
- Milligan, G. N., Flaherty, L., Braciale, V. L., and Braciale, T. J. (1991). Nonconventional (TL-encoded) major histocompatibility complex molecules present processed viral antigen to cytotoxic T lymphocytes. *J.Exp Med.* **174**, 133.
- Mueller, N. (1999). Overview of the epidemiology of malignancy in immune deficiency. *J.Acquir.Immune.Defic.Syndr.* **21 Suppl 1**, S5.
- Myskowski, P. L. and Ahkami, R. (1997). Advances in Kaposi's sarcoma. *Dermatol.Clin.* **15**, 177.
- Nishioka, K. and Katayama, I. (1978). Angiogenic activity in culture supernatant of antigen-stimulated lymph node cells. *J.Pathol.* **126**, 63.
- Nowell, P. C. and Hungerford, D. A. (1966). The etiology of leukemia: some comments on current studies. *Semin.Hematol.* **3**, 114.
- Old, L. J. (1981). Cancer immunology: the search for specificity--G. H. A. Clowes Memorial lecture. *Cancer Res.* **41**, 361.
- Outzen, H. C., Custer, R. P., Eaton, G. J., and Prehn, R. T. (1975). Spontaneous and induced tumor incidence in germfree "nude" mice. *J.Reticuloendothel.Soc.* **17**, 1.
- Palop, L. and Martinez, J. A. (1997). Cross-sectional assessment of nutritional and immune status in renal patients undergoing continuous ambulatory peritoneal dialysis. *Am J Clin Nutr.* **66**, 498S.

- Papadopoulos, N. M., Lane, H. C., Costello, R., *et al.* (1985). Oligoclonal immunoglobulins in patients with the acquired immunodeficiency syndrome. *Clin.Immunol.Immunopathol.* **35**, 43.
- Pardoll, D. M. (1994). Tumour antigens. A new look for the 1990s. *Nature.* **369**, 357.
- Parmiani, G. (1993). Tumor immunity as autoimmunity: tumor antigens include normal self proteins which stimulate anergic peripheral T cells. *Immunol.Today.* **14**, 536.
- Penn, I. (1981). Depressed immunity and the development of cancer. *Clin.Exp Immunol.* **46**, 459.
- Penn, I. (1986). Cancer is a complication of severe immunosuppression. *Surg.Gynecol.Obstet.* **162**, 603.
- Penn, I. (1990). Cancers complicating organ transplantation. *N.Engl.J Med.* **323**, 1767.
- Penn, I. (1993c). Incidence and treatment of neoplasia after transplantation. *J Heart Lung Transplant.* **12**, S328.
- Penn, I. (1993a). Neoplastic complications of transplantation. *Semin.Respir.Infect.* **8**, 233.
- Penn, I. (1993b). Tumors after renal and cardiac transplantation. *Hematol.Oncol.Clin.North Am.* **7**, 431.
- Penn, I. (1994a). Depressed immunity and the development of cancer. *Cancer Detect.Prev.* **18**, 241.
- Penn, I. (1994b). Occurrence of cancers in immunosuppressed organ transplant recipients. *Clin.Transpl.* **99**.
- Phillips, A. N., Lee, C. A., Elford, J., *et al.* (1991). Serial CD4 lymphocyte counts and development of AIDS [see comments]. *Lancet.* **337**, 389.
- Pisa, P., Halapi, E., Pisa, E. K., *et al.* (1992). Selective expression of interleukin 10, interferon gamma, and granulocyte-macrophage colony-stimulating factor in ovarian cancer biopsies. *Proc.Natl Acad.Sci.U.S.A.* **89**, 7708.
- Ploegh, H. L. (1998). Viral strategies of immune evasion. *Science.* **280**, 248.
- Poeschla, E. M. and Wong-Staal, F. (1997). Etiology of cancer: Viruses. In *Cancer: Principles and practice of oncology*, 5th ed. (De Vita, V. T. and Hellman, S., eds.), p.153, Lippincott-Raven, Philadelphia.
- Poli, G., Bottazzi, B., Acero, R., *et al.* (1985). Monocyte function in intravenous drug abusers with lymphadenopathy syndrome and in patients with acquired

- immunodeficiency syndrome: selective impairment of chemotaxis. *Clin.Exp Immunol.* **62**, 136.
- Pollock, C. A., Mahony, J. F., Ibels, L. S., *et al.* (1989). Immunoglobulin abnormalities in renal transplant recipients. *Transplantation.* **47**, 952.
- Prehn, R. T. and Lappé, M. A. (1971). An immunostimulation theory of tumour development. *Transplant.Rev.* **7**, 26.
- Prehn, R. T. and Prehn, L. M. (1996). Immunostimulation of cancer versus immunosurveillance. *Medicina.B.Aires.* **56 Suppl 1**, 65.
- Prehn, T. T. and Main, J. M. (1957). Immunity to methylcholanthrene-induced sarcomas. *J.Natl.Cancer Inst.* **18**, 769.
- Pross, H. F. and Lotzova, E. (1993). Role of natural killer cells in cancer. *Nat.Immun.* **12**, 279.
- Purtilo, D. T., Manolov, G., Manolova, Y., Harada, S., and Lipscomb, H. (1984). Squamous-cell carcinoma, Kaposi's sarcoma and Burkitt's lymphoma are consequences of impaired immune surveillance of ubiquitous viruses in acquired immune deficiency syndrome, allograft recipients and tropical African patients. *IARC.Sci.Publ.* 749.
- Reinherz, E. L., Kung, P. C., Goldstein, G., and Schlossman, S. F. (1979). Further characterization of the human inducer T cell subset defined by monoclonal antibody. *J.Immunol.* **123**, 2894.
- Revillard, J. P. and Cozon, G. (1990). Experimental models and mechanisms of immune deficiencies of nutritional origin. *Food Addit.Contam.* **7 Suppl 1**, S82.
- Roitt, I. M. Essential immunology. (1991). 7th ed., Blackwell, Oxford.
- Roitt, I. M. Essential immunology. (1994). 8th ed., Blackwell, Oxford.
- Rook, A. H., Hooks, J. J., Quinnan, G. V., *et al.* (1985). Interleukin 2 enhances the natural killer cell activity of acquired immunodeficiency syndrome patients through a gamma-interferon-independent mechanism. *J.Immunol.* **134**, 1503.
- Rossing, N. (1978). Intra- and extravascular distribution of albumin and immunoglobulin in man. *Lymphology.* **11**, 138.
- Rossini, A. A., Greiner, D. L., and Mordes, J. P. (1999). Induction of immunologic tolerance for transplantation. *Physiol Rev.* **79**, 99.
- Rowland-Jones, S., Tan, R., and McMichael, A. (1997). Role of cellular immunity in protection against HIV infection. *Adv.Immunol.* **65**, 277.

- Rowley, J. D. (1973). Letter: A new consistent chromosomal abnormality in chronic myelogenous leukaemia identified by quinacrine fluorescence and Giemsa staining. *Nature*. **243**, 290.
- Roy, S., Fitz, Gibbon L., Poulin, L., and Wainberg, M. A. (1988). Infection of human monocytes/macrophages by HIV-1: effect on secretion of IL-1 activity. *Immunology*. **64**, 233.
- Safai, B., Johnson, K. G., Myskowski, P. L., *et al.* (1985). The natural history of Kaposi's sarcoma in the acquired immunodeficiency syndrome. *Ann.Intern.Med.* **103**, 744.
- Salahuddin, S. Z., Nakamura, S., Biberfeld, P., *et al.* (1988). Angiogenic properties of Kaposi's sarcoma-derived cells after long-term culture *in vitro*. *Science*. **242**, 430.
- Sall, M. G., Toure, M., Vol, S., *et al.* (1994). [Effects of refeeding on serum immunoglobulin (IgA, IgG, IgM) concentrations in children with severe protein-energy malnutrition] Effects de la renutrition sur les concentrations seriques des immunoglobulines (IgA, IgG, IgM) d'enfants atteints de malnutrition proteinoenergetique severe. *Arch Pediatr*. **1**, 132.
- Santos, E. and Nebreda, A. R. (1989). Structural and functional properties of ras proteins. *FASEB J*. **3**, 2151.
- Scandinavian Study Group (1997). Kaposi's sarcoma and its management in AIDS patients [Recommendations]. *Scand.J.Infect.Dis.* **29**, 3.
- Schatz, O., Bogner, J. R., and Goebel, F. D. (1997). Kaposi's sarcoma: is the hunt for the culprit over now? *J Mol.Med.* **75**, 28.
- Schopper, K. and Douglas, S. D. (1976). Immunological aspects of infantile protein-calorie malnutrition. *Bull Schweiz.Akad.Med Wiss.* **31**, 327.
- Schreiber, S. L. and Crabtree, G. R. (1992). The mechanism of action of cyclosporine A and FK506. *Immunol.Today*. **13**, 136.
- Schroff, R. W., Gottlieb, M. S., Prince, H. E., Chai, L. L., and Fahey, J. L. (1983). Immunological studies of homosexual men with immunodeficiency and Kaposi's sarcoma. *Clin.Immunol.Immunopathol.* **27**, 300.
- Schwartz, R. S. (1975). Another look at immunological surveillance. *N.Engl.J Med.* **181**.
- Searle, P. F. and Young, L. S. (1996). Immunotherapy II: Antigens, receptors and costimulation. *Cancer Metastasis Rev.* **15**, 329.

- Shaheen, F. A., al Sulaiman, M. H., Ramprasad, K. S., and al Khader, A. A. (1997). Kaposi's sarcoma in renal transplant recipients. *Ann. Transplant.* **2**, 49.
- Sheil, A. G. (1992). Development of malignancy following renal transplantation in Australia and New Zealand. *Transplant.Proc.* **24**, 1275.
- Sheil, A. G. (1996). Malignancy in organ transplantation recipients. *Transplant.Proc.* **28**, 1162.
- Sheil, A. G., Disney, A. P., Mathew, T. G., Amiss, N., and Excell, L. (1992). Malignancy following renal transplantation. *Transplant.Proc.* **24**, 1946.
- Shiku, H., Takahashi, T., and Oettgen, H. F. (1976). Cell surface antigens of human malignant melanoma. II. Serological typing with immune adherence assays and definition of two new surface antigens. *J.Exp Med.* **144**, 873.
- Shiramizu, B., Herndier, B. G., and McGrath, M. S. (1994). Identification of a common clonal human immunodeficiency virus integration site in human immunodeficiency virus-associated lymphomas. *Cancer Res.* **54**, 2069.
- Shtivelman, E., Lifshitz, B., Gale, R. P., and Canaani, E. (1985). Fused transcript of *abl* and *bcr* genes in chronic myelogenous leukaemia. *Nature.* **315**, 550.
- Shurin, M. R. (1996). Dendritic cells presenting tumor antigen. *Cancer Immunol.Immunother.* **43**, 158.
- Siegal, F. P., Lopez, C., Hammer, G. S., *et al* . (1981). Severe acquired immunodeficiency in male homosexuals, manifested by chronic perianal ulcerative herpes simplex lesions. *N.Engl.J.Med.* **305**, 1439.
- Singhal, A. and Hakomori, S. (1990). Molecular changes in carbohydrate antigens associated with cancer. *Bioessays.* **12**, 223.
- Sinkovics, J. G. (1991). Kaposi's sarcoma: its 'oncogenes' and growth factors. *Crit.Rev Oncol.Hematol.* **11**, 87.
- Smith, D. R., Kunkel, S. L., Burdick, M. D., *et al.* (1994). Production of interleukin-10 by human bronchogenic carcinoma. *Am.J.Pathol.* **145**, 18.
- Smith, M. E., Bodmer, J. G., Kelly, A. P., Trowsdale, J., Kirkland, S. C., and Bodmer, W. F. (1989). Variation in HLA expression on tumors: an escape from immune response. *Cold Spring Harb.Symp.Quant.Biol.* **54.1**, 581.
- Smith, P. D., Ohura, K., Masur, H., Lane, H. C., Fauci, A. S., and Wahl, S. M. (1984). Monocyte function in the acquired immune deficiency syndrome. Defective chemotaxis. *J.Clin.Invest.* **74**, 2121.

- Spits, H., Lanier, L. L., and Phillips, J. H. (1995). Development of human T and natural killer cells. *Blood*. **85**, 2654.
- Stahl, R. E., Friedman-Kien, A., Dubin, R., Marmor, M., and Zolla-Pazner, S. (1982). Immunologic abnormalities in homosexual men. Relationship to Kaposi's sarcoma. *Am.J.Med.* **73**, 171.
- Stanta, G., Campagner, L., Cavallieri, F., and Giarelli, L. (1997). Cancer of the oldest old. What we have learned from autopsy studies. *Clin.Geriatr.Med.* **13**, 55.
- Stevenson, H. and Tsang, K-Y. (1993). Tumor immunology. In Introduction to medical immunology, 3rd ed. (Virella, G., eds.), p.497, Marcel Dekker, New York.
- Stiehm, E. R. (1980). Humoral immunity in malnutrition. *Fed.Proc.* **39**, 3093.
- Szende, B., Toth, A., Perner, F., Nagy, K., and Takacs, K. (1997). Clinicopathologic aspects of 8 Kaposi's sarcomas among 1009 renal transplant patients. *Gen.Diagn.Pathol.* **143**, 209.
- Takeda, A., Sweet, R. W., and Ennis, F. A. (1990). Two receptors are required for antibody-dependent enhancement of human immunodeficiency virus type 1 infection: CD4 and Fc gamma R. *J.Virol.* **64**, 5605.
- Taylor, S. and Folkman, J. (1982). Protamine is an inhibitor of angiogenesis. *Nature*. **297**, 307.
- Thomas, L. (1959). Reactions to homologous tissue antigens in relation to hypersensitivity. In Cellular and Humoral Aspects of the Hypersensitive States,(Lawrence, H. S., eds.), p.529, Hoeber-Harper, New York.
- Thurin, J. (1989). Characterization and molecular biology of tumor-associated antigens. *Curr.Opin.Immunol.* **2**, 702.
- Townsend, A., Bastin, J., Bodmer, H., et al. (1989). Recognition of influenza virus proteins by cytotoxic T lymphocytes. *Philos.Trans.R.Soc.Lond B Biol.Sci.* **323**, 527.
- Townsend, A. R., Rothbard, J., Gotch, F. M., Bahadur, G., Wraith, D., and McMichael, A. J. (1986). The epitopes of influenza nucleoprotein recognized by cytotoxic T lymphocytes can be defined with short synthetic peptides. *Cell*. **44**, 959.
- Tsoukas, C. M. and Bernard, N. F. (1994). Markers predicting progression of human immunodeficiency virus-related disease. *Clin.Microbiol.Rev.* **7**, 14.
- Urban, J. L. and Schreiber, H. (1992). Tumor antigens. *Ann.Rev.Immunol.* **10**, 617.

- Uytenhove, C., Van Snick, J., and Boon, T. (1980). Immunogenic variants obtained by mutagenesis of mouse mastocytoma P815. I. Rejection by syngeneic mice. *J.Exp Med.* **152**, 1175 .
- Wahl, D. V., Chapman, W. H., Hellstrom, I., and Hellstrom, K. E. (1974). Transplantation immunity to individually unique antigens of chemically induced bladder tumors in mice. *Int.J.Cancer.* **14**, 114.
- Walker, C. M., Moody, D. J., Stites, D. P., and Levy, J. A. (1986). CD8⁺ lymphocytes can control HIV infection *in vitro* by suppressing virus replication. *Science.* **234**, 1563.
- Walker, C. M., Moody, D. J., Stites, D. P., and Levy, J. A. (1989). CD8⁺ T lymphocyte control of HIV replication in cultured CD4⁺ cells varies among infected individuals. *Cell Immunol.* **119**, 470.
- Warner, T. F. and O'Loughlin, S. (1975). Kaposi's sarcoma: a byproduct of tumour rejection. *Lancet.* **2**, 687.
- Weigent, D. A., Stanton, G. J., and Johnson, H. M. (1983). Recombinant gamma interferon enhances natural killer cell activity similar to natural gamma interferon. *Biochem.Biophys.Res Commun.* **111**, 525.
- Whiteside, T. L. and Herberman, R. B. (1990). The biology of human natural killer cells. *Ann.Ist.Super.Sanita.* **26**, 335.
- Whiteside, T. L., Rinaldo, R. R., and Herberman, R. B. (1992). Cytolytic cell functions. *In Manual of clinical Laboratory Immunology*, 4 ed. (Rose, N. R., de Macario, E. C., and Fahey, J. L., eds.), p.220, American Society of Microbiology, Washington.
- Wilson, J. L., Charo, J., Martin-Fontecha, A., *et al.* (1999). NK cell triggering by the human costimulatory molecules CD80 and CD86. *J.Immunol.* **163**, 4207.
- Wiviott, L. D., Walker, C. M., and Levy, J. A. (1990). CD8⁺ lymphocytes suppress HIV production by autologous CD4⁺ cells without eliminating the infected cells from culture. *Cell Immunol.* **128**, 628.
- Wortis, H. H. (1971). Immunological responses of 'nude' mice. *Clin.Exp Immunol.* **8**, 305.
- Wortzel, R. D., Philipps, C., and Schreiber, H. (1983b). Multiple tumour-specific antigens expressed on a single tumour cell. *Nature.* **304**, 165.
- Wortzel, R. D., Urban, J. L., Philipps, C., Fitch, F. W., and Schreiber, H. (1983a). Independent immunodominant and immunorecessive tumor-specific antigens on

- a malignant tumor: antigenic dissection with cytolytic T cell clones. *J.Immunol.* **130**, 2461.
- Yunis, E. J., Martinez, C., Smith, J., Stutman, O., and Good, R. A. (1969). Spontaneous mammary adenocarcinoma in mice: influence of thymectomy and reconstitution with thymus grafts or spleen cells. *Cancer Res.* **29**, 174.
- Yuspa, S. H. and Shields, P. G. (1997). Etiology of cancer: chemical factors. In *Cancer: Principles and practice of oncology*, 5th ed. (De Vita, V. T. and Heilman, S., eds.), p.185, Lippincott-Raven, Philadelphia.
- Ziche, M., Jones, J., and Gullino, P. M. (1982). Role of prostaglandin E1 and copper in angiogenesis. *J.Natl Cancer Inst.* **69**, 475.
- Zinkernagel, R. M. and Doherty, P. C. (1974). Immunological surveillance against altered self components by sensitised T lymphocytes in lymphocytic choriomeningitis. *Nature.* **251**, 547.

Chapter 16

THE ROLE OF IMMUNOSUPPRESSIVE AGENTS

Sustained immunosuppression is associated with an increased propensity for malignancy; this remains the price that the renal transplant patient is obliged to pay for the privilege of a functioning allograft (London *et al.*, 1995; Penn, 1987b; Suthanthiran *et al.*, 1994; Yokoyama *et al.*, 1991). The risk of cancer after renal transplantation was recognised soon after the establishment of renal transplantation as a routine therapeutic option (see Chapter 5). The agents used initially were azathioprine and/or cyclophosphamide, prednisone or prednisolone, and occasionally antilymphocyte globulin (ALG) (Beveridge *et al.*, 1984; Cockburn, 1987; Penn, 1987b). The introduction of cyclosporine into routine clinical practice in the early 1980s revolutionised solid organ transplantation but also raised fears of its oncogenic potential (Penn, 1987b; Penn, 1987a; Penn *et al.*, 1988). However, subsequent experience with the drug has allayed these fears as the incidence of malignancies with this agent was comparable to conventional treatment with azathioprine (Cockburn, 1987; Penn, 1982; Penn, 1986a; Penn, 1987a). The

immunosuppressive armamentarium was further broadened by the introduction of various monoclonal antibodies (of which OKT3 was the most widely used) and mycophenolate mofetil. The introduction of these agents meant that patients were often receiving up to 5 different agents in different combinations over short periods of time (Penn,2000). However, current evidence suggests the newer agents were not associated with any significant change in posttransplant malignancies. A recent study compared the malignancies observed in patients treated with tacrolimus and with cyclosporine (Jonas *et al.*,1997;Wiesner,1998). There was little difference in the type of tumours or rates of tumor development. Indeed they differed little from those reported previously when azathioprine-based regimens were compared to cyclosporine-based regimens (Penn,1996a). However, with the recently introduced agents care needs to be exercised in the interpretation of the data. Posttransplant cancers appear an average of 5 years after transplantation and the length of follow-up of many patients on mycophenolate mofetil falls well short of this figure (Penn,2000).

MECHANISMS OF ONCOGENICITY

It is likely that a number of aetiological factors contribute to the development of malignancies in renal transplant patients who are immunosuppressed; lesions are likely the result of a complex interplay between these factors rather than due to single factor.

Immunological surveillance

The reason for the increased oncogenicity associated with the use of immunosuppressive has defied explanation. In the early 1960s the "immunologic surveillance" theory gained popular following (Burnet,1970;Thomas,1959). This theory contended that neoplastic cells arise repeatedly throughout the life of an individual but that these clones of cells are detected and destroyed by the host cellular immune response. The logical corollary to this theory is that any suppression of the cellular immune system would be accompanied by an increase in clinically overt malignancies. Based on this reasoning it was hypothesized that patients on immunosuppressive drugs would experience an extremely high rate of almost all forms of cancer (Hoover,1977). However, although our own observations and those

of others have confirmed the increased incidence of malignancies in immunosuppressed patients, the increase has only been in certain types of tumours, that are rare in the general population; the incidence of tumours that occur commonly has remained unchanged, thus placing some doubt on the veracity of the "immunologic surveillance" theory (Flattery,1998; Kehinde *et al.*,1994; Min *et al.*,2000; Penn,1981; Penn,1984; Penn,1986b; Penn,1989b; Schmidt *et al.*,1996). An additional factor that involves the immune system, is the chronic antigenic stimulation that results in a constant immunological battle between the host and the allograft (Penn,1982), which may also activate oncogenic viruses (Hoover,1977; Swift,1996).

Chronic glomerulonephritis

Several other hypotheses can be offered to explain the excess of malignancies in renal allograft recipients. One is that most of the recipients of renal allografts were victims of chronic glomerulonephritis and that chronic glomerulonephritis is an autoimmune disease, with the latter condition known to be associated with an increase in cancers. However, the current evidence fails to show an excess of cancer risk according to the recipients' renal disease (Hoover,1977).

Uraemia

Chronic uraemia is a state of immunosuppression in itself (Birkeland,1976), and this has been suggested as a possible reason for the excess of tumours. However, studies comparing the risk of malignancies in patients on dialysis have been contradictory with some showing an increased incidence (Herr *et al.*,1979; Kinlen *et al.*,1980; Lindner *et al.*,1981; Matas *et al.*,1975a; Miach *et al.*,1976; Pecchini *et al.*,1983; Sutherland *et al.*,1977) and others little or no increase (Bush *et al.*,1984; Kramer *et al.*,1984; Slifkin *et al.*,1977). Most of the former group of studies indicate that in contrast to the experience in renal transplant recipients, the types of malignancies encountered in dialysis patients are the same as those encountered in the general population, but with a high incidence of genitourinary tumours (Kramer *et al.*,1984;Sheil *et al.*,1985). This plethora of conflicting findings means that "no scientifically justified conclusions can be drawn from such heterogeneous data derived from such diverse and unrelated groups of patients . . .To clarify this issue a well conducted study is needed, and indeed is long overdue." (Pateras,1985).

Oncogenic viruses

There is convincing laboratory evidence that the immunosuppressive drugs facilitate infections with oncogenic viruses (Lopez *et al.*,1974). In addition it is relatively easy to obtain oncogenic viruses from the serum and urine of renal transplant patients (Matas *et al.*,1975b). This is in keeping with the observation that the cancers that are particularly prevalent in our own patients (Kaposi's sarcoma and skin carcinoma) are ones that putatively are caused by oncogenic viruses. The short latent period of malignancies such as Kaposi's sarcoma and lymphoma is in keeping with a viral aetiology. There are two possible sources of oncogenic viruses in immunosuppressed patients: firstly, an immunological reaction may activate latent endogenous oncornaviruses (Armstrong *et al.*,1973) and secondly, exogenous oncogenic viruses may become established in individuals with impaired immune defenses (Centres for Disease Control,1982; Gottlieb *et al.*,1983; Penn,1982; Penn,1986a; Selik *et al.*,1987).

Direct oncogenicity

Immunosuppressive agents may be directly oncogenic. It has been demonstrated that these agents cause chromosomal breaks, nuclear abnormalities, cytologic dysplasia, and are teratogenic in man and animals but a direct oncogenic effect of these compounds remains to be proven (Penn,1977;Penn *et al.*,1988). These agents may operate through another mechanism (Penn,1977). Extensive *in vitro* studies have demonstrated that the agents commonly used to obtain immunosuppression in clinical transplantation enhance the oncogenic potential of physical or chemical carcinogens and of oncogenic viruses (Penn,1989b;Penn,1991a;Penn,1993) as well as accelerating metastatic growth (Albert *et al.*,1962; Allison *et al.*,1968; Baserga *et al.*,1954; Casey,1968; Penn,1980; Schwartz *et al.*,1966). In experiments with hairless mice, chronic azathioprine administration enhanced the oncogenic effects of ultraviolet light in causing skin cancers (Koranda *et al.*,1975). At the same time, the prevailing state of immunosuppression also decreases the ability of the immune system to reject the cancers (Penn,1980;Starzl *et al.*,1971). Virtually all cytotoxic drugs are immunosuppressive which raises the question whether they are carcinogenic through their immunosuppressive properties or by direct effect on susceptible cells (Harris *et al.*,1976; Penn,1974; Penn,1978; Penn,1982; Penn,1986a; Rosner *et al.*,1982). *In vitro* studies have, unfortunately, produced

conflicting results and the matter remains unresolved (Gleichmann *et al.*,1973;Grundmann *et al.*,1973;Schmähl,1977). As regards direct carcinogenicity of the commonly used agents, most experimental evidence showed that carcinogenicity occurred in the presence of physical or chemical agents, foreign proteins, viral infections or in animals such as the NZB mice that suffer from autoimmune diseases. However, most agents did not cause spontaneous malignancies when administered singly (Hattan *et al.*,1971;Koranda *et al.*,1975).

State of immunosuppression

There is some evidence that instead of being related to any individual immunosuppressive agent or cocktail of agents, cancer development is linked to the immunosuppressed state *per se* which, among other factors enhances the susceptibility of transplant recipients to a variety of virus-related tumours (Penn,2000). This contention is supported by the observation of malignancies in two other conditions associated with immunosuppression. In naturally occurring immunosuppressive states, there is a 100-fold increase risk of lymphomas, which have similar characteristics to posttransplant lymphoproliferative disease (Penn,1996b). In AIDS, the risk of certain cancers, especially Kaposi's sarcoma, non-Hodgkin's lymphoma and uterine cervical cancer is greatly increased (Penn,1996b).

The rest of this chapter is a review of the immunosuppressive agents routinely used in our patients with special attention to the mechanism of oncogenesis; it will also specifically review the impact of the conventional treatment with that of cyclosporine on the development of cancer in renal allograft recipients.

CYCLOSPORINE

Historical background

The history of cyclosporine dates back to the summer of 1970 when a fungus classified as *Tolypocladium inflatum* Gams a member of the *Fungi imperfecti* family was discovered on the inhospitable plains of Hardanger Vidda, in Southern Norway (Kahan,1999). It was found that the fungus produced a cyclic undecapeptide that had unique immunosuppressive properties (Borel *et al.*,1976). The first clinical trials

by Sir Roy Calne (1978) with the new agent, named cyclosporine A, yielded encouraging results. However, the nephrotoxic potential of the new drug and its narrow therapeutic window became apparent very early.

Mechanism of Action (Fig. 16-1)

Cyclosporine selectively inhibits the synthesis of interleukin-2, interferon- γ and other lymphokines (Yoshimura *et al.*,1986), and to a lesser extent the proto-oncogenes *c-myc* and *c-fos* and cytokine receptors (Granelli-Piperno *et al.*,1986;Granelli-Piperno,1990). The site of action of cyclosporine within the cell has been localised to the cytoplasm with no effect on membrane-associated signaling or events that occur after gene activation (Kahan,1989).

Intracellular action The cytosolic protein cyclophilin has been identified as the cellular receptor for cyclosporine (Harding *et al.*,1986;Ryffel *et al.*,1992). Upon binding to cyclophilin, the cyclosporine undergoes a marked conformational change resulting in a polar exterior surface. The cyclophilin-cyclosporine complex then binds to and inhibits calcineurin, a calcium- and calmodulin-dependent serine-threonine phosphatase (Liu *et al.*,1991) that has been shown to participate in signal transduction (Clipstone *et al.*,1992;O'Keefe *et al.*,1992). Inhibition of the phosphatase activity of calcineurin is central to the immunosuppressive activity of cyclosporine (Fruman *et al.*,1992;Liu *et al.*,1991). Inhibition of the phosphatase activity of calcineurin prevents the activation of nuclear factors involved in the regulation of transcription of genes encoding interleukin-2 and other cytokines (Faulds *et al.*,1993;Schumacher *et al.*,1992). Cyclosporine potently inhibits the activation and DNA binding of nuclear factor in activated cells (NF-AT), activator protein 3 (AP-3) as well as nuclear factor κ B (NF- κ B). These proteins bind to regulatory sites on the human interleukin-2 enhancer allowing the genes to be transcribed by upregulation of m-RNA (Emmel *et al.*,1989;Mattila *et al.*,1990). Calcineurin has also been shown to be a component in the signal transduction pathway leading to activation of the interleukin-2 enhancer (O'Keefe *et al.*,1992). Inhibition of these nuclear factors blocks the activation of the interleukin-2 gene thus inhibiting interleukin-2 production.

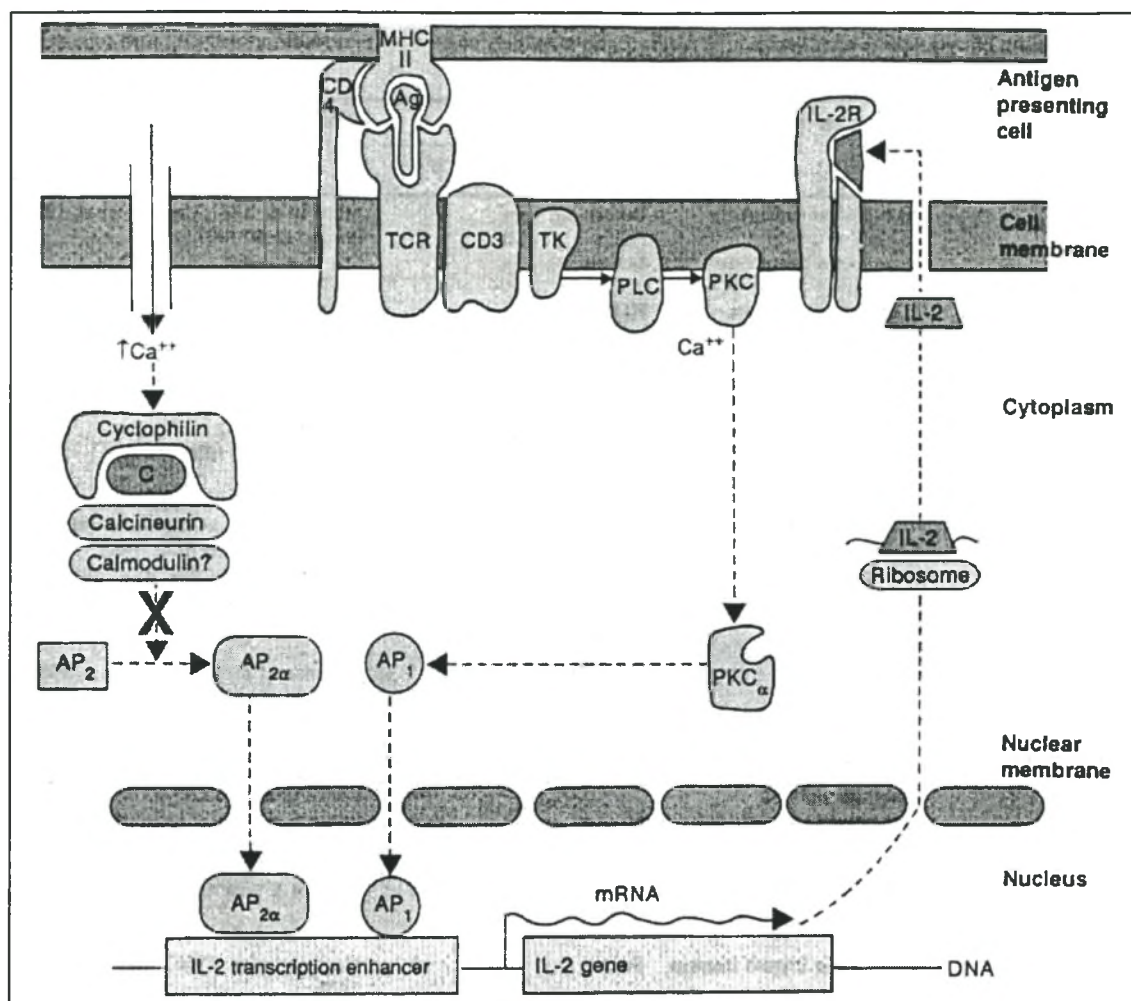


Fig. 16-1 Schematic representation of the biochemical events associated with T-cell activation and the possible site of action of cyclosporine. See text for details. Modified from Faulds *et al.* (1993).

α = activated; AP = activation protein; Ag = antigen; C = cyclosporine; CD = cluster designation; IL-2 = interleukin-2; IL-2R = interleukin-2 receptor; MHC II = major histocompatibility complex II; mRNA = messenger RNA; PKC = protein kinase C; PLC = phospholipase C; TCR = T-cell receptor; TK = tyrosine kinase; $\uparrow Ca^{++}$ = increased calcium.

New evidence The conventional explanation of the mechanism of action of cyclosporine and that of cyclosporine-associated cancer development has recently been challenged by Hojo *et al.* (1999). The conventional mechanism of action of cyclosporine has been discussed above and has been extensively reviewed (Rao, 1995; Schreiber *et al.*, 1992) (Fig. 16-2). There are some limitations to this explanation of the mechanism of action of cyclosporine. *In vitro* studies have

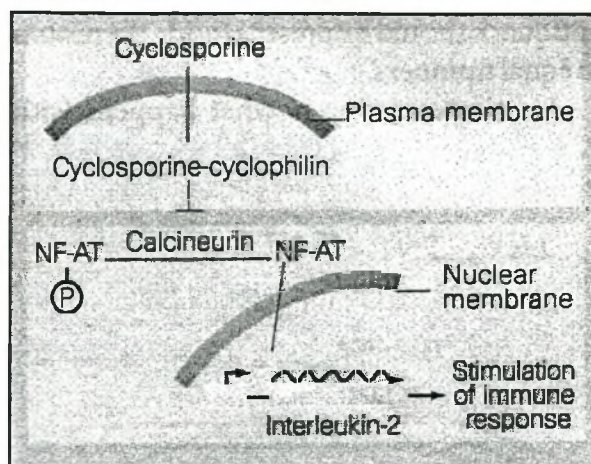


Fig. 16-2 Summary of cyclosporine action at the cellular level. From Nabel (1999).

demonstrated that when the key cytokine, interleukin-2 is disrupted in transgenic animals, the effect on immune function is not the same as treatment with cyclosporine (Contractor *et al.*, 1998; Horak *et al.*, 1995; Kundig *et al.*, 1993; Schorle *et al.*, 1991). A second important observation is that when another molecule in the proposed pathway, NF-AT, is knocked out, the effects do not match those of treatment with cyclosporine (Xanthoudakis *et al.*, 1996). It has also been held that cyclosporine-associated cancers result from the failure of the host immune system to eliminate cancerous cells because the use of cyclosporine impairs the ability of the immune system to detect and respond to protein associated with the malignancy (Kahan, 1989; Masuhara *et al.*, 1993; Shimizu *et al.*, 1989; Van de Vrie *et al.*, 1997; Van der Elst *et al.*, 1986).

Hojo *et al.* (1999) performed some very elegant experiments that showed that cyclosporine induces phenotypic changes, including invasiveness of non-transformed cells, by cell autonomous mechanisms (Figs 16-3 to 16-6). Their studies showed that cyclosporine treatment of adenocarcinoma cells causes striking morphological changes. These alterations include membrane ruffling, increased pseudopodial protrusions, increased cell motility, and anchorage-independent (invasive) growth. Even more striking, was their demonstration that these alterations could be prevented by antibodies directed against transforming growth factor- β (TGF- β). In addition, *in vivo* studies performed in immunodeficient SCID-beige rats,

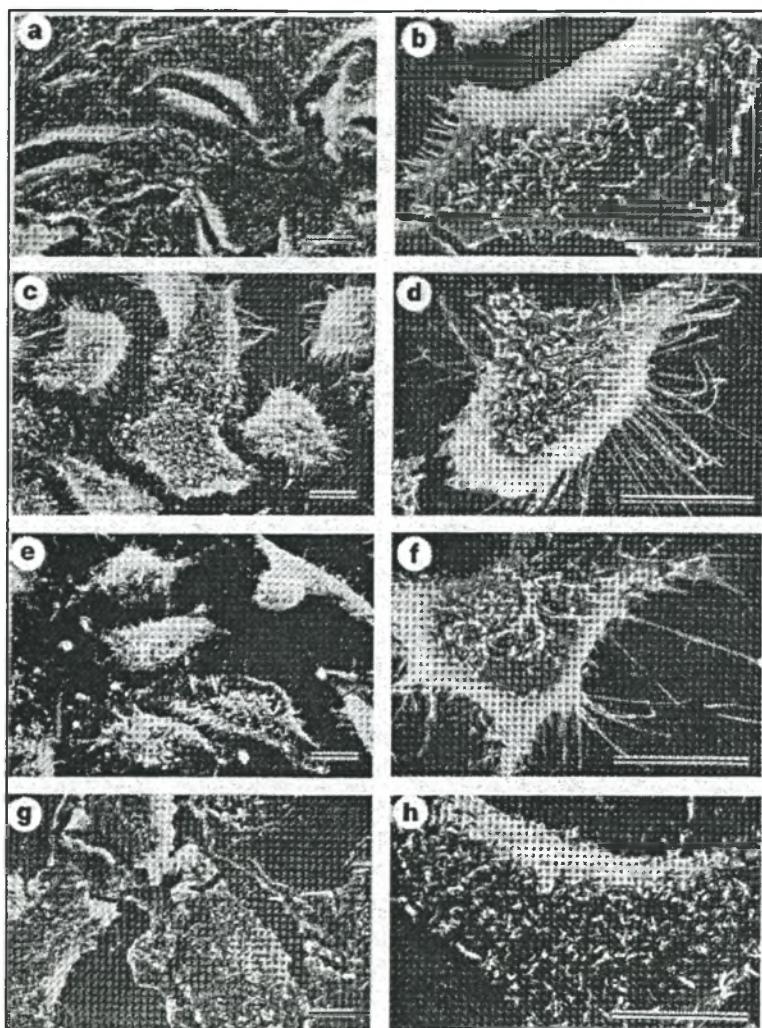


Fig. 16-3 Scanning electron microscopy shows the striking morphological changes observed following treatment in cells of non-transformed pulmonary adenocarcinoma cell line (A-549) with cyclosporine. Untreated A-549 cells have a cuboidal epithelium and non-invasive appearance (a, b), whereas cells that are treated with cyclosporine show invasive characteristics, which include marked membrane ruffling and the formation of pseudopodia (c, d). The use of anti-TGF- β antibodies prevented the cyclosporine-induced phenotypic changes (e, f), while TGF- β_1 induced morphological changes that were similar to those caused by cyclosporine (g, h). From Hojo et al. (1999)




Fig. 16-4 Cells capable of invasiveness display exploratory pseudopodia. These scanning electron micrographs show A-549 cells grown on two different sized polycarbonate membrane filters (0.4 μm and 3.0 μm) in the absence (a, c) and presence of cyclosporine (b, d). Those grown with cyclosporine showed increased motility. From Hojo et al. (1999).

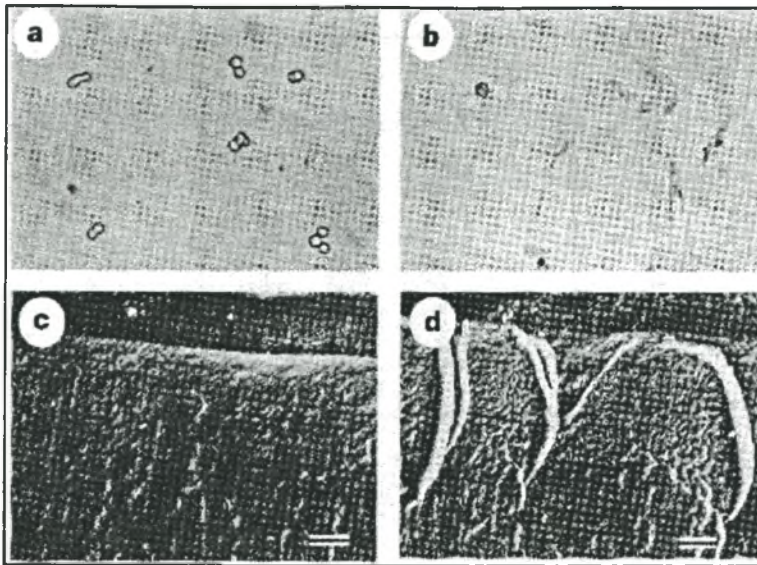


Fig. 16-5 Anchorage-independent growth *in vitro* is a marker of invasive tumour growth. In this experiment phase-contrast microscopy showed that untreated A-549 cells retained their shape and remained suspended in the culture medium whereas cyclosporine-treated cells spread and proliferated strongly on the gel (a, b). To show the behaviour of the pseudopodia better, vertical sections of the gel were done, which showed that fully grown pseudopodia of the cyclosporine-treated cells penetrated the gel-layer and extended vertically into the gel plate (d) in contrast to control A-549 cells that had no pseudopodial extensions (c). From Hojo et al. (1999).

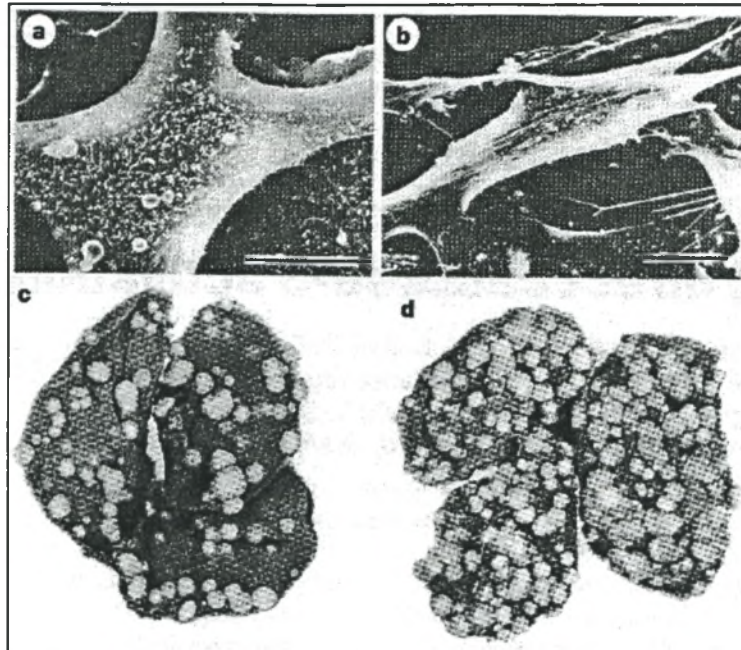


Fig. 16-6 Cyclosporine was demonstrated to promote the invasive behaviour of renal cancer cells and promote tumour growth *in vivo*. This scanning electron micrographs show renal adenocarcinoma cells incubated without (a) and with cyclosporine (b). The lungs retrieved from untreated SCID-beige mice (c) and from mice treated with cyclosporine showing cyclosporine-associated increase in renal cell cancer in pulmonary metastases (d). From Hojo et al.(1999).

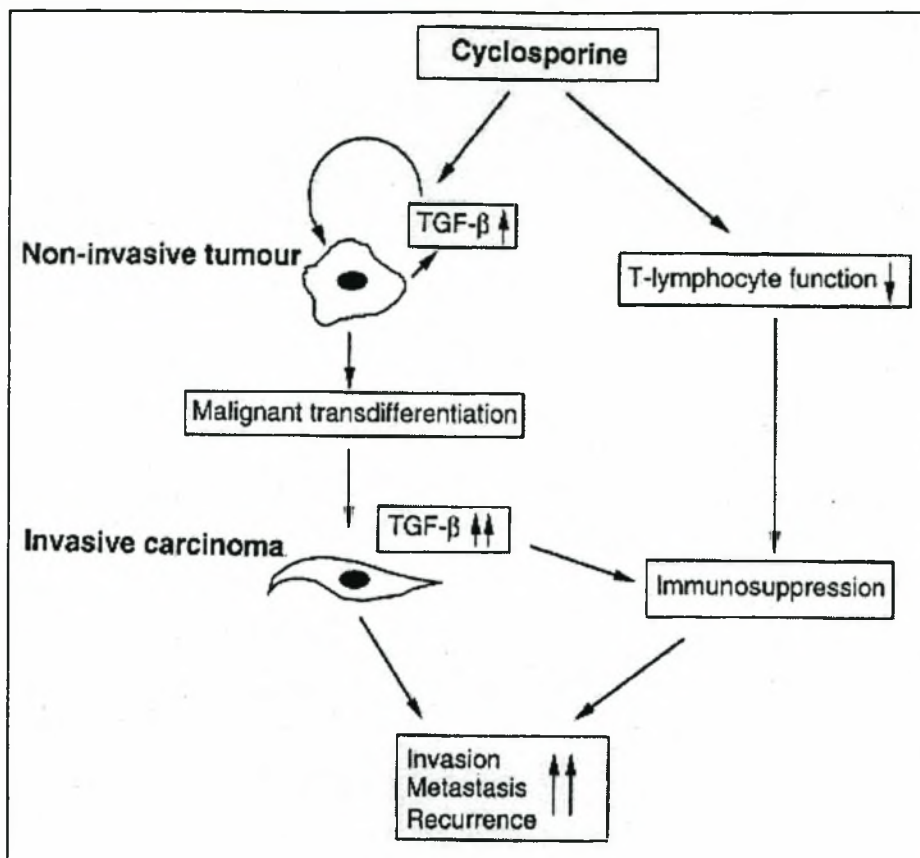


Fig. 16-7 A summary of the potential mechanisms for cyclosporine-associated tumour progression in transformed cells. See text for details. From Hojo *et al.*(1999).

showed that cyclosporine enhanced the growth of tumours. Anti-TGF- β monoclonal antibodies, but not control antibodies, prevented the cyclosporine-induced spread of metastases. This contribution of Hojo *et al.* (1999), suggests that TGF- β not only has an effect on the immune system but also alters the behaviour of malignant cells as indicated above. These observations indicate that treatment with cyclosporine does not increase tumour growth indirectly by failure of the immune system but rather directly through a non-immune mechanism that acts on the tumour itself *via* TGF- β receptors (Nabel,1999) (Fig. 16-7). These provocative findings challenge the views of others that cancers in immunosuppressed patients is a function of the degree of immune suppression rather than that of a particular compound or combination of agents (Penn,2000).

Following the work of Hojo *et al.* (1999)(Figs. 16-3 to 16-7), and other groups an alternative explanation for the action of cyclosporine has been proposed (Nabel,1999). It is known that cyclosporine stimulates the production of TGF- β by an as yet unknown mechanism(s) (Khanna *et al.*,1994;Li *et al.*,1991). This observation explains some of the mysterious side-effects of cyclosporine, for example, the hepatotoxicity, and the thickening and scarring of the kidneys and skin — an effect seen also with increased TGF- β (Border *et al.*,1994). TGF- β is a well-known and potent immunosuppressive and the cyclosporine action may well be mediated through increased production of this cytokine (and perhaps the inhibition of others) (Kehrl *et al.*,1986;Roberts *et al.*,1993).

Caveats There are some caveats that need to be borne in mind in the interpretation of the data presented by Hojo *et al.* (1999). The studies of the group involved cells that were already transformed and whether cyclosporine has a similar effect on pre-cancerous cells is uncertain. It was also never proven that cyclosporine can induce the transformation of cells from a normal to a malignant state. The data does however very strongly suggest that the cyclosporine can potentially exacerbate tumour growth if used in patients with an underlying malignancy (Hojo *et al.*,1999).

Other in vitro studies of oncogenicity of cyclosporine There are also a variety of animal experiments that have demonstrated the oncogenic potential of cyclosporine. In syngeneic rats the administration of cyclosporine promoted the development of liver metastases after the intraportal injection of colon cancer cells (Van der Elst *et al.*,1986). Cyclosporine potentiated ultraviolet radiation-induced malignancies to proliferate following their transplantation into syngeneic mouse recipients probably via its capacity to enhance the dominance of suppressor T-cell controlled immune responses (Servilla *et al.*,1987). It has been demonstrated that the administration of cyclosporine to immunocompetent rodents permits the growth of xenografts of human cancers (Bennett *et al.*,1985;Goodman *et al.*,1987;Lockshin,1987;Otto *et al.*,1987). In other studies cyclosporine has caused an eight-fold increase in the incidence of thymic lymphomas in mice (that normally have a low spontaneous rate of lymphomas) when pretreated with a small dose of N-methyl nitrosurea (MNU), a known carcinogen (Shinozuka *et al.*,1986). Other

studies have shown that cyclosporine markedly accelerates the induction of thymic lymphomas in AKR mice, that naturally have a high incidence of this tumour and this may be due its acting as a tumour promoter (Hattori *et al.*,1986). Rats fed cyclosporine develop lymphoproliferative lesions that closely resemble that seen in man both in their affinity for gut-associated lymphoid tissues and their morphological appearance (Demetris *et al.*,1984). When these experiments were extended by adding MNU to the oral cyclosporine then adenocarcinomas of the bowel occurred in 60% of treated patients compared to 8% of control animals (Perera *et al.*,1986). Some 12% of non-human primates treated with varying doses of cyclosporine developed lymphomas after transplantation of heart and lungs, with the presence of a herpes-like virus in the malignant cells (Penn *et al.*,1988). In summary, animal studies also suggest that cyclosporine promotes the development of tumours whether spontaneous, transplanted, chemically, or virally induced.

Humans, cyclosporine and cancer The carcinogenic effect of cyclosporine on humans however is poorly understood. *In vitro* studies of human cells have shown that cyclosporine induced sister chromatid exchanges (Yuzawa *et al.*,1986). However, the doses of cyclosporine used were much higher than those used clinically (Penn,1987b). In studies of peripheral blood lymphocytes of patients treated with azathioprine or cyclosporine for more than 1 year, 62% of patients under azathioprine showed chromosomal aberrations compared to 68% under cyclosporine, suggesting that both agents can be regarded as potentially carcinogenic (Goodman *et al.*,1987).

STEROIDS

Mechanism of actions

Corticosteroids exert a variety of actions but those most important to transplantation include generalised anti-inflammatory effects, as well as the disruption of antigen presenting cell (APC) functions that are necessary for the initial recognition functions of the immune response (Kahan and Ponticelli, 2000). The main anti-inflammatory effect of steroids is to dampen the interleukin-1 and interleukin-6 costimulatory activity; to dampen the synthesis of pro-inflammatory molecules — platelet activating factor (PAF), prostaglandins, leukotrienes — as well as the release of tumour

necrosis factor α (TNF- α); to dampen the chemotactic, oxygen burst and cytotoxic activities of elements of non-specific resistance; and to stabilize the membranes of cells regarded as targets of immune responses (Kahan and Ponticelli, 2000). A generally recognised mechanism of action of steroids in all tissues is the stabilisation of the inhibitory factor I κ B, thereby blocking generation of nuclear factor (NF- κ B), a proinflammatory regulatory factor for cytokine gene transcription. Cortisone binds to cytosolic receptors that are present in variable amounts in all cells type, producing complexes that migrate into the nucleus. Here it interacts with specific DNA sequences in a glucocorticoid receptor element (GRE), a promoter region of specific target genes, thereby modulating their transcription (Ashwell *et al.*,2000). Dimers of steroid-receptor complexes joined head-to-head form a loop binding to the DNA sequence at the one end and another copy of the receptor at the other (Torchia *et al.*,1997). DNA and receptor complexes interactions can have one of three consequences: upregulation of gene expression; downregulation of gene expression; or interference with the binding of specific regulatory molecules such as Jun-Fos, that form the activator protein-1 (AP-1) transcription element. The last mechanism explains the inhibitory effect of steroids on genes that have no obvious regulatory GRE. Following binding of the steroid to the receptor, the complex enters the nucleus where it interacts with transcription factor AP-1, and prevents its association with the nuclear factor of activated T-cells (NF-AT), thereby inhibiting the promoter functions for proinflammatory cytokines (Kahan and Ponticelli, 2000). Steroids also inhibit NF- κ B production by promoting the induction and stability of I κ B. During T-cell activation I κ B kinase phosphorylates I κ B, which is ubiquitinated and then degraded, releasing NF- κ B to migrate into the nucleus (Auphan *et al.*,1995;Scheinman *et al.*,1995). Little is known of specific mechanism(s) if any, of oncogenesis of corticosteroids beside the ones discussed above.

AZATHIOPRINE

The use of azathioprine as an immunosuppressive for solid organ transplants was a watershed in the development of clinical transplantation. In the New York laboratories of Burroughs Wellcome, Hitchings and Elion started a program to deliberately substitute purines and pyrimidines to produce molecules that would be falsely incorporated in vital biological processes but then poison the cells and

prevent their division (Hitchings *et al.*,1954). One of these agents was 6-mercaptopurine, which was used by Schwartz and Dameshek (1959) (Schwartz *et al.*,1959) in experiments to inhibit the clonal proliferation of lymphocytes that occurs in response to antigenic stimulation. Calne tested the drug in dogs and found that it improved renal allograft survival (Calne *et al.*,1962). Hitchings and Elion subsequently provided Calne with a new variation of the drug, a derivative of 6-mercaptopurine later called azathioprine which he found to be a little more effective and safer at preventing kidney graft rejection than 6-mercaptopurine itself (Calne *et al.*,1968). Azathioprine in addition displayed more consistent bioavailability than the parent drug.

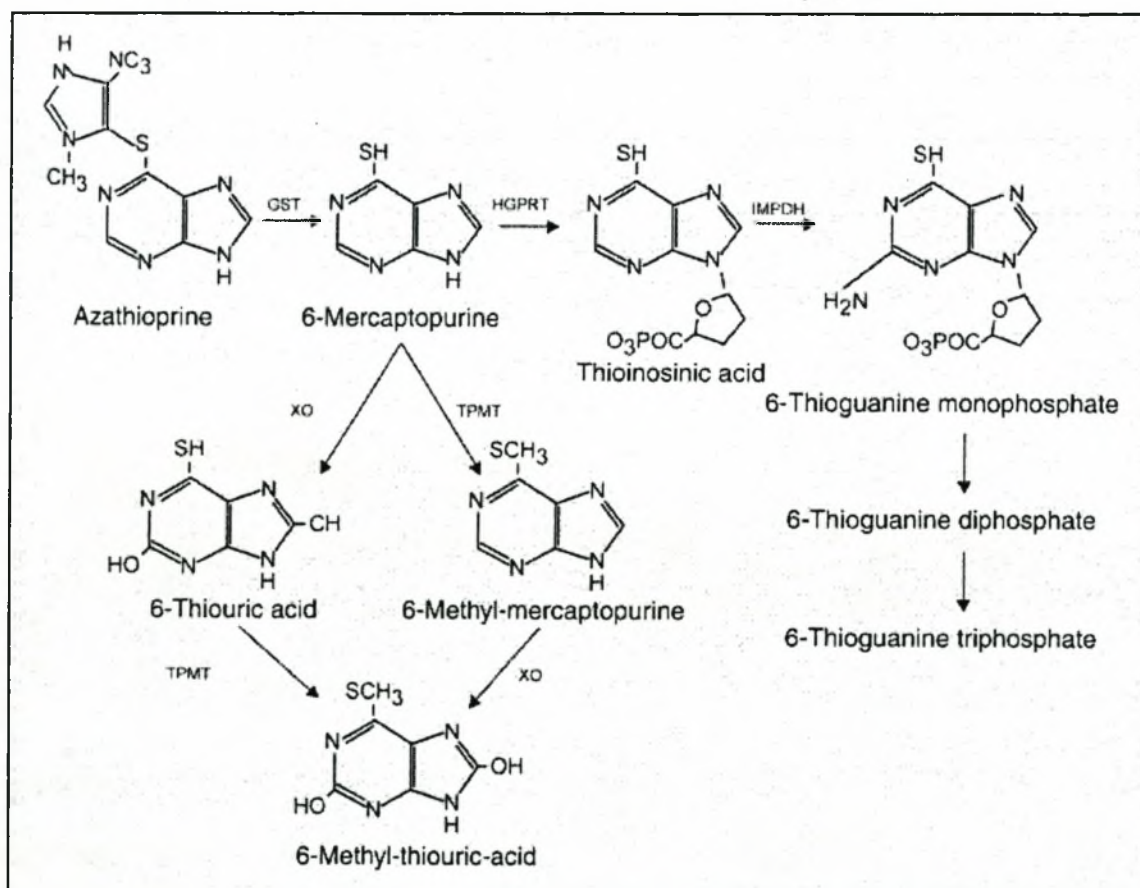


Fig. 16-8 The metabolism of azathioprine showing the alternative pathway of thiopurine methyl transferase (TPMT) vs. 6-thioguanine nucleotides. GST = glutathione S-transferase, HGPRT = hypoxanthine-guanine phosphoribosyltransferase, XO = xanthine oxidase, IMPDH = inosine monophosphate dehydrogenase. Modified from Kahan and Ponticelli (2000).

Mechanism of action (Fig. 16-8)

Azathioprine, the nitroimidazole derivative of 6-mercaptopurine, acts as a competitive inhibitor of both *de novo* and salvage pathways of nucleoside synthesis. The metabolism of azathioprine is complex and still incompletely understood. The drug is either converted to 6-mercaptopurine, which is further metabolised to 6-thiouracil, or alternatively to 6-thioinosic acid and 6-thioguanic acid (Kahan and Ponticelli, 2000). These intracellular metabolites are thought to be largely responsible for the immunosuppressive effects of azathioprine (Brockman, 1963; Tidd *et al.*, 1974a). In common with other purines, the thiopurine intermediates are converted by xanthine oxidase to 6-thiouric acid which is eliminated in the urine. Xanthine oxidase is present in many tissues but especially the liver. Methylation of 6-mercaptopurine or 6-thioinosic acid by thiopurine methyl transferase (TPMT) produces 6-methyl-mercaptopurine as well as 6-thioguanine, the primary active metabolite of azathioprine (Lennard *et al.*, 1983). Both of these products are incorporated directly into nucleic acids as fraudulent bases (Chan *et al.*, 1987), leading to chromosomal breakage, nucleic acid distortion, interference with DNA repair (Elion, 1967; Tidd *et al.*, 1974b), and an increased proclivity to malignant cell transformation.

Immunosuppression Azathioprine is useful for inhibiting the primary responses but has little effect on secondary responses or on the reversal of acute allograft rejections. It blocks T-cell activation at the most distal point compared with steroids and cyclosporine. It does not prevent initial gene activation but instead powerfully inhibits gene replication and T-cell activation. Azathioprine also decreases the number of migratory mononuclear cells and polymorphonuclear cells whilst inhibiting the proliferation of promyelocytes within bone marrow. As a result the number of circulating mononuclear cells capable of differentiating into macrophages is decreased. An increased risk of neoplasia is a recognised adverse effect of azathioprine administration (Bach *et al.*, 1986).

CELLULAR SITES OF ACTION OF IMMUNOSUPPRESSIVE AGENTS (Fig. 16-9, Table 16-1)

The immunosuppressive agents have different sites of action in the cell cycle (Fig. 16-9, Table 16-1). *Corticosteroids* inhibit T-cell proliferation, T-cell dependent immunity, and the expression of cytokine genes (*i.e.* interleukin-1, interleukin-2, interleukin-6, interferon- γ , and TNF- α) (Arya *et al.*, 1984; Knudsen *et al.*, 1987; Zanker *et al.*, 1990). The actions most important to transplantation include the generalised anti-inflammatory effects as well as the disruption of the antigen presenting cell functions that are necessary for the initial recognition functions of the immune system. After antigen signalling, transduction of the message to produce cellular activation during the G₀ to the G₁ phase of the cell cycle is disrupted by the binding of OKT3 antibodies. Thereafter *cyclosporine* disrupts the progression of the activation cascade by dampening T-cell production of proinflammatory cytokines (Suthanthiran *et al.*, 1994).

Azathioprine is an anti-proliferative agent that disrupts the S-phase of the cell cycle (Elion, 1967). It disrupts nucleoside synthesis required for proliferation, clonal expansion as well as the generation of memory cells. The entire army of T-cells may be reduced by monoclonal or polyclonal reagents directed toward surface markers that are relatively restricted to elements of the immune system.

IMPACT OF IMMUNOSUPPRESSIVE TREATMENT

Our findings were that the overall incidence of malignancies did not increase under cyclosporine. Regarding Kaposi's sarcoma under conventional treatment 2.4% of patients had the disease compared with 4.3% under cyclosporine. The difference

Table 16-1. *Site of action of immunosuppressive agents*

Site	Immunosuppressive Agent
Antigen presentation	Steroids
G ₀ to G ₁	Cyclosporine
S	Azathioprine

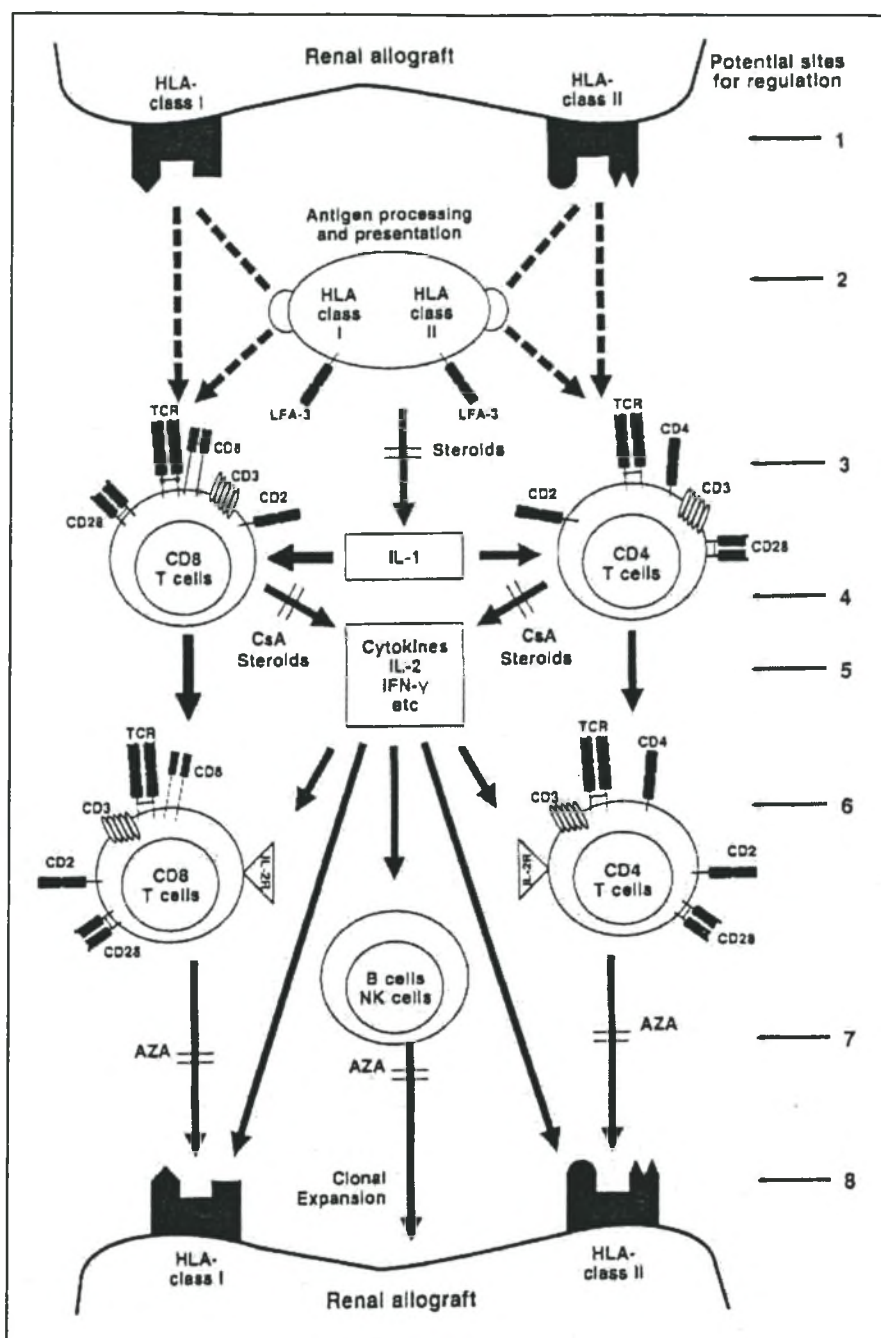


Fig. 16- 9. Mechanism of acute rejection and the cellular site of action of the immunosuppressive agents. HLA is the main stimulus for the acute rejection episode; cell surface proteins participate in the antigenic recognition and signal transduction; the contribution of cytokines and various cell types are illustrated. The possible sites of intervention are also illustrated. The main sites of action of steroids are prevention of cytokine production by antigen presenting cells (site 2) and inhibition of T-cell cytokine production (site 4). Cyclosporine inhibit IL-2 production by T-cells (site 4). Azathioprine inhibits clonal expansion (site 7). APC = antigen presenting cell, CsA = cyclosporine , aza = Azathioprine, IL-2 = interleukin-2, IFN γ = interferon- γ , NK cells = natural killer cells. Modified from Suthanthiran et al. (1994).

however was not significant. Penn has stated that the use of cyclosporine is not associated with an increase in the incidence of malignancies (Penn,2000). However, the evidence for this premise is very tentative and based largely on the data reported to the Cincinnati Transplant Tumor Registry (CTTR). Since the data is dependent on reporting by various centres and the number of patients transplanted is not known the actual frequency of malignancies cannot be calculated although the relative frequencies can.

Cyclosporine reduces risk of cancer!

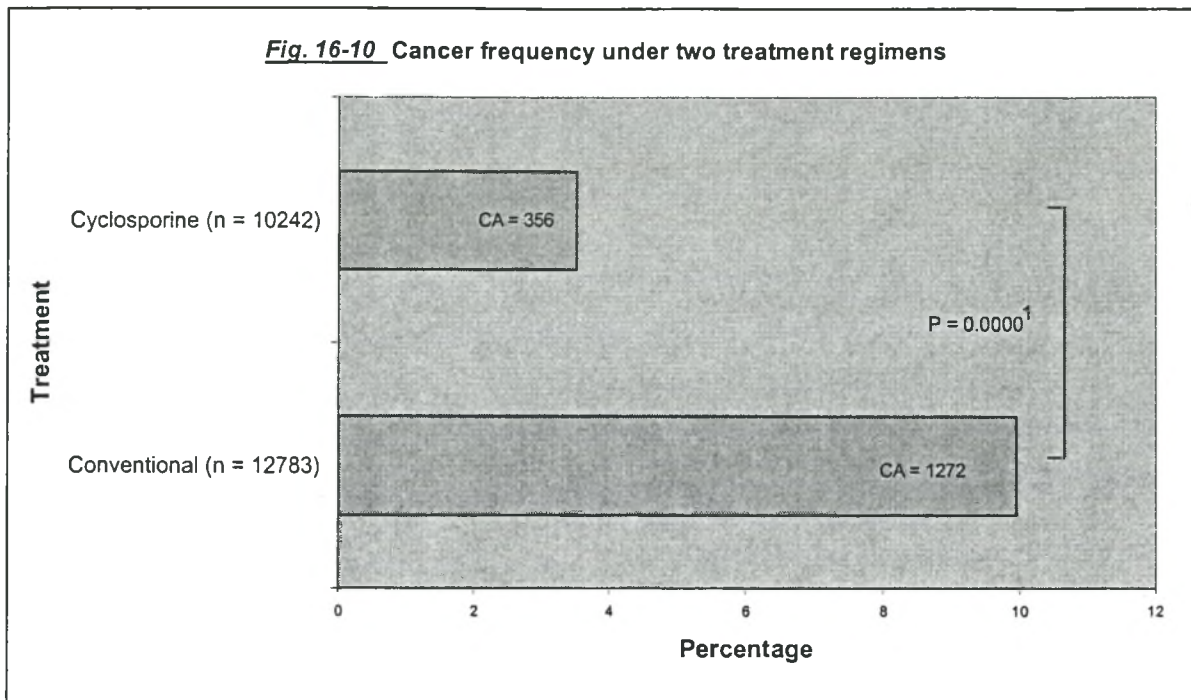
For the purposes of this discussion, we reviewed studies from around the world comparing conventional treatment with cyclosporine in renal allograft recipients, as well as others from which we could calculate the frequency of malignancies and identify clearly the treatment received by transplant recipients (Table 16-2). In the meta-analysis of the 22 reports, the number of malignancies identified in the 12 783 patients receiving conventional treatment was 1272 (10%); under cyclosporine of the 10 242 recipients 356 (3.5%) developed malignancies. This difference is highly significant ($p = 0.0000$, χ^2 -test) and is graphically represented (Fig. 16-10). This type of meta-analysis has never been undertaken before and shows convincingly that the overall malignancies are significantly less common under cyclosporine than conventional treatment. The implications of this observation are quite profound if confirmed to be correct.

Kaposi's sarcoma increases under cyclosporine

Using the data reported to the CTTR, Penn has demonstrated a dramatic increase in the number of cases of Kaposi's sarcoma with cyclosporine (Penn *et al.*,1988; Penn,2000), accounting for 11% of all cancer cases compared with 3% under azathioprine. We analysed the number of Kaposi's sarcoma cases in the available literature diagnosed before and after the introduction of cyclosporine. However, only those reports were considered where the absolute frequency of Kaposi's sarcoma could be calculated. The number of studies suitable for our analysis was limited. Our meta-analysis, which included 7 studies (Fig. 16-11), clearly indicated an absolute increase in the frequency of Kaposi's sarcoma from 1.8% under conventional treatment to 4.9% under cyclosporine.

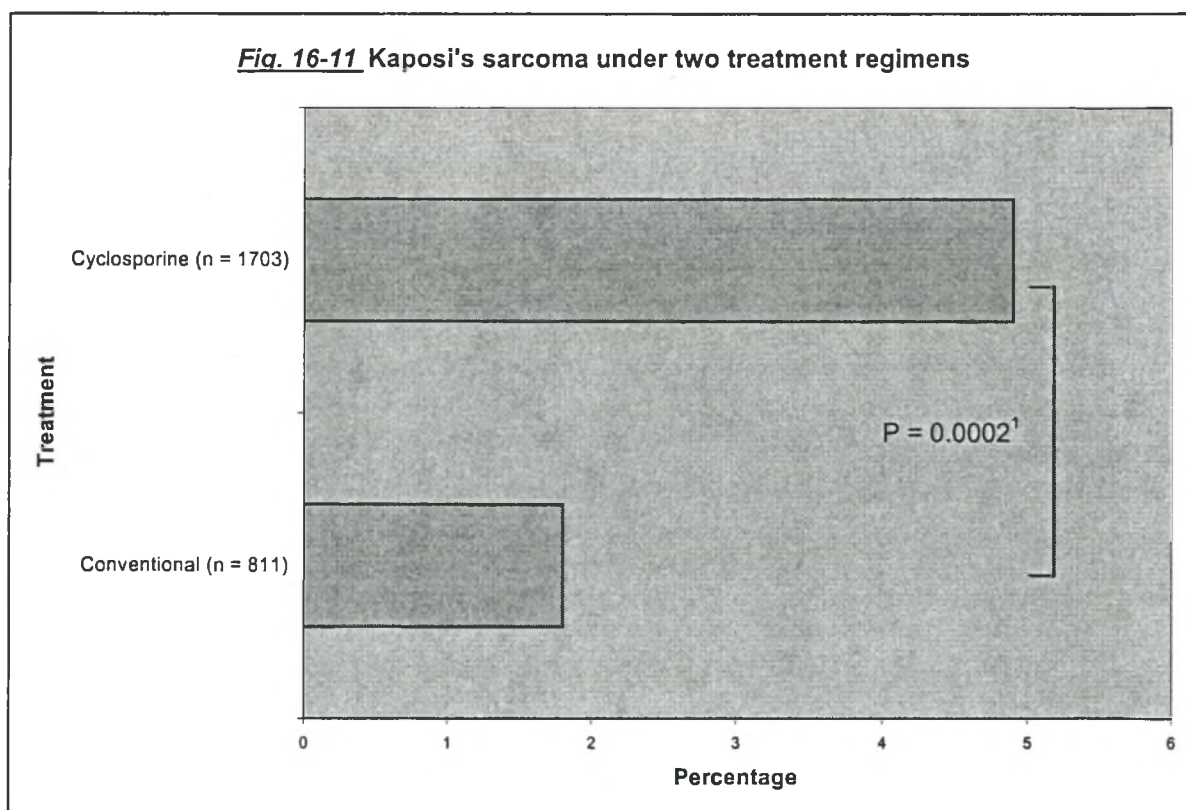
Table 16-2 The influence of treatment on the frequency and latency of posttransplant malignancies.

Treatment	No. of patients	No. of CA cases	Incidence (%)	Latency (mo.)	Reference
Conventional	281	35	12.4	67.4	Montagnino <i>et al.</i> , 1996
Cyclosporine	573	41	7.1		Italy
Conventional	305	28	9.2	61	Mihalov <i>et al.</i> , 1996
Cyclosporine					Illinois
Conventional	2672	39	1.5	29.5	Birkeland, 1983
					Scandinavia
Conventional	4241	794	18	66	Sheil <i>et al.</i> , 1987
					ANZ
Conventional	133	6	4.5	48	Kehinde <i>et al.</i> , 1994
Cyclosporine	359	21	5.8		UK
Conventional	927	35	3.8	67	Villardell <i>et al.</i> , 1992
Cyclosporine	1295	31	2.4	22	Spain
Conventional	396	15	3.8	98.6	Yokota <i>et al.</i> , 1994
Cyclosporine	359	6	1.7	45.5	Japan
Conventional	1165	124	10.6	90	Gruber <i>et al.</i> , 1994
Cyclosporine	722	34	4.7	37	Minnesota
Conventional	1317	129	9.8	p = NS	Gruber <i>et al.</i> , 1991
Cyclosporine	713	15	2.1		Minnesota
Conventional	340	5	1.5	75.6	Bakr <i>et al.</i> , 1997
Cyclosporine	610	17	2.8	49.3	Egypt
Conventional	597	49	8.2	91.9	Glover <i>et al.</i> , 1994
Cyclosporine	1113	84	7.5	52	France
Conventional	123	8	6.5	86.9	Present Study
Cyclosporine	419	33	7.9	41.3	Stellenbosch
Conventional	80	8	10.0	95	Ritters <i>et al.</i> , 1994
Cyclosporine	466	22	4.7	36	Germany
Conventional	380	13		110	Bordes-Aznar <i>et al.</i> , 1992
		3		25	Mexico
Cyclosporine	630	12	1.9	52.6	Askari <i>et al.</i> , 1999
					Pakistan
Conventional	100	14	0.75	90.3	(Thiagarajan <i>et al.</i> , 1998
					India
Cyclosporine	1464			38.5	
Cyclosporine	1600	5	0.3	36.4	Kim <i>et al.</i> , 1998
					Korea
Conventional	193	14	7.3	32.6	Disler <i>et al.</i> , 1981
					Johannesburg
Conventional	209	8	3.8	35	Cassidy <i>et al.</i> , 1982
					Cape Town
Cyclosporine	867	21	2.4	42.8	Ghods <i>et al.</i> , 2000
					Iran
Conventional	109	3	2.8		Min <i>et al.</i> , 2000
Cyclosporine	516	14	2.7		Korea



Drawn from data obtained from references in Table 16-2.

¹ χ^2 -test



Drawn from data obtained from the present study, as well as from Al-Sulaiman MH *et al.*,1994;Ecdar *et al.*,1998;Harwood *et al.*,1979;Margolius,1996;Qunibi *et al.*,1988;Qunibi *et al.*,1993.

¹ χ^2 test

The apparent increase in the number of cases of Kaposi's sarcoma experienced by Penn, could be due to the decrease in the relative numbers of lesions such as lymphomas and skin carcinomas. The cumulative number of patients receiving cyclosporine is progressively increasing and since Kaposi's sarcoma is a lesion that develops the earliest it is liable to be diagnosed before other lesions have developed. We concur with Penn that longer follow-up will be necessary to obtain a clearer impression of the frequency of post-cyclosporine malignancies (Penn *et al.*, 1988). That both the absolute and relative frequencies of Kaposi's sarcoma are increasing, however, is cause for grave concern.

Pattern of malignancies

The type of immunosuppression used has been associated with an alteration in the pattern of tumours (Table 16-3). Conventional treatment was associated with a higher incidence of skin malignancies including anorectal, genital, and lip cancers, whereas cyclosporine is associated with a higher incidence of Kaposi's sarcoma and lymphomas (Penn *et al.*, 1988; Rao, 1998). In our experience skin cancers predominated under azathioprine and Kaposi's sarcoma under cyclosporine. Both lymphoma cases that we diagnosed in our study occurred under cyclosporine.

Table 16-3 *Difference in pattern of malignancies under different treatment regimens. Our own experience compared with that of the CTTR.*

	Penn (1988)% ¹	Moosa (Present Study) ² %
Skin cancer:		
Conventional	40	55
Cyclosporine	22	28
Kaposi's sarcoma:		
Conventional	3	33
Cyclosporine	11	51
Lymphoma:		
Conventional	12	0
Cyclosporine	29	6

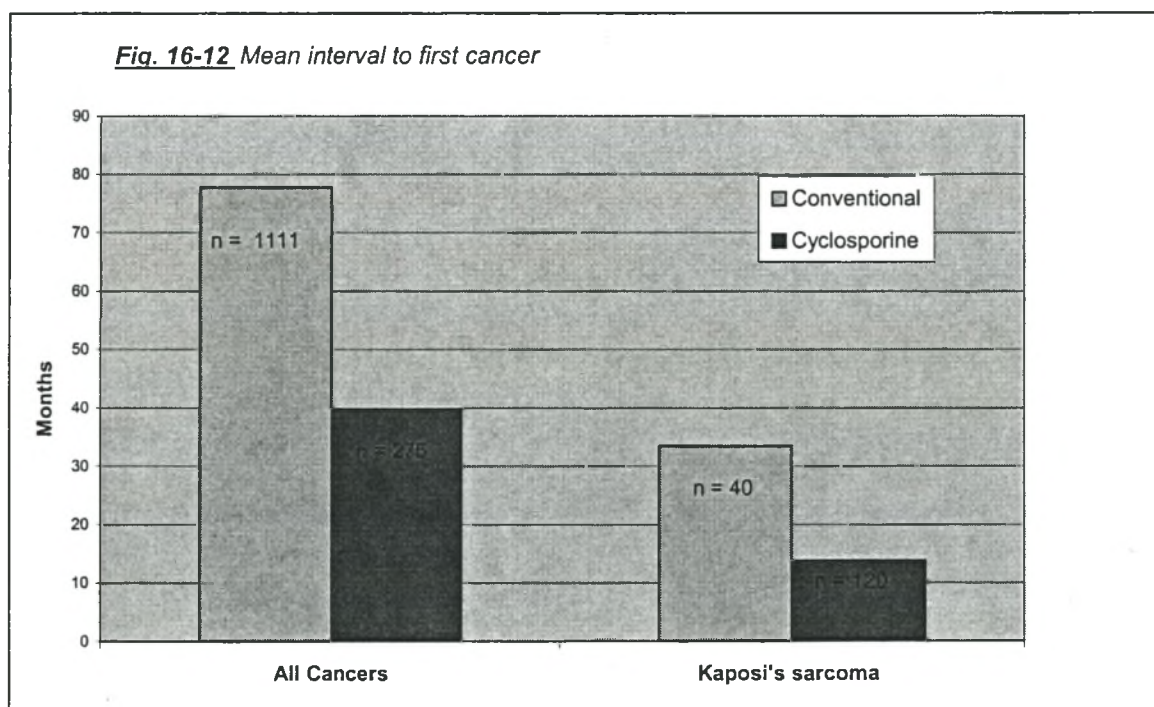
¹ Based on 3139 tumours

² Based on 44 tumours

However, it should be recalled that lymphomas were the most frequent initially in patients on conventional treatment but the incidence had been decreasing steadily (Penn *et al.*,1969; Penn *et al.*,1971; Penn,1984; Penn,1991b). It would be interesting to follow the pattern of lymphomas under cyclosporine over time.

Latency period under cyclosporine

One area where there has been little controversy is the impact of cyclosporine on the average time of appearance of malignancies (Fig. 16-12). For reasons that are as yet unclear the use of cyclosporine reduces the time by almost 50%. The latency period was calculated using data available from studies around the world and showed an overall reduction from a mean of 77 months to 39 months. In the case of Kaposi's sarcoma the reduction was even more dramatic from 33 months to 14 months.



Drawn from data obtained from this study as well Bakr *et al.*,1997;Birkeland,1983;Bordes-Aznar *et al.*,1992;Ghods *et al.*,2000;Glover *et al.*,1994;Gruber *et al.*,1994;Kim *et al.*,1998;Noel *et al.*,1996;Ritters *et al.*,1994;Sheil *et al.*,1987;Thiagarajan *et al.*,1998;Vilardell *et al.*,1992;Yokota *et al.*,1994 for all cancers latency, and Al-Sulaiman MH *et al.*,1994;Ecder *et al.*,1998;Farge,1993;Harwood *et al.*,1979;Qunibi *et al.*,1988;Qunibi *et al.*,1993 for Kaposi's sarcoma latency periods.

LATENCY PERIOD OF TUMOURS

It has become evident that as the length of follow-up of organ transplant recipients has increased that certain tumours occur at particular intervals after transplantation (Penn,1989a;Penn,1994a;Penn,1994b). In contrast to other oncogenic stimuli in man, that may take 15-20 years or more to manifest clinically, cancers were diagnosed a relatively short time after renal transplantation in our patients. In our experience and that of others Kaposi's sarcoma is the first to appear. In Penn's experience this occurred at a mean of 22 months with the shortest time being 1 month (Penn,1999). Lymphomas followed, appearing at an average of 34 months after transplantation, while skin cancers appeared at 75 months (Penn,1999). Another observation made by this study was that the latent period to the development of visceral Kaposi's sarcoma was shorter than Kaposi's sarcoma confined to the skin. This observation has never been made before, and may imply a more aggressive form of the disease or more severe infection with the putative causative virus. It is of note that all these tumours have a putative viral aetiology (Kuper *et al.*,2000) and this may explain their early manifestation in patients who are severely immunosuppressed. The mechanisms whereby viruses cause cancers will be discussed elsewhere.

SUMMARY

The nature of the immunosuppressive drugs has been discussed together with their cellular and molecular mechanisms of action. The oncogenic potential of the agents remains to be proven conclusively although convincing data for cyclosporine is starting to accumulate. We have speculated on the possible mechanisms whereby these agents may contribute to carcinogenesis.

The clinical application of cyclosporine has manifested in the following ways as regards posttransplant malignancies:

- Reduction in the overall frequency of cancers
- Increase in the absolute and relative frequency of Kaposi's sarcoma
- Change in the pattern of malignancies with less skin cancers and more Kaposi's sarcoma and lymphomas
- Reduction in the time to the appearance of cancers by almost 50%.

LITERATURE CITED

- Anonymous (2000). Immunosuppressive drugs: Molecular and cellular mechanisms of action. *In Principles and Practice of Renal Transplantation*, (Kahan, B. D. and Ponticelli, C., eds.), p.315, Martin Dunitz, London.
- Al-Sulaiman MH and Al-Kader, A. A. (1994). Kaposi's sarcoma in renal transplant recipients. *Transplant.Sci.* **4**, 46.
- Albert, D. and Ziedman, I. (1962). Relation of glucocorticoid activity of steroids to number of metastases. *Cancer Res.* **22**, 1297.
- Allison, A. C. and Law, L. W. (1968). Effects of antilymphocyte serum on virus oncogenesis. *Proc.Soc.Exp.Biol.Med.* **127**, 207.
- Armstrong, M. Y., Ruddle, N. H., Lipman, M. B., and Richards, F. F. (1973). Tumor induction by immunologically activated murine leukemia virus. *J Exp.Med.* **137**, 1163.
- Arya, S. K., Wong-Staal, F., and Gallo, R. C. (1984). Dexamethasone-mediated inhibition of human T cell growth factor and gamma-interferon messenger RNA. *J Immunol.* **133**, 273.
- Ashwell, J. D., Lu, F. W., and Vacchio, M. S. (2000). Glucocorticoids in T cell development and function. *Annu.Rev.Immunol.* **18**, 309.
- Askari, H., Hashmi, A., Lal, M. *et al.* (1999). Postrenal transplant malignancies in a living-related donor program: 13-year experience--an update. *Transplant.Proc.* **31**, 3236.
- Auphan, N., DiDonato, J. A., Rosette, C., Helmberg, A., and Karin, M. (1995). Immunosuppression by glucocorticoids: inhibition of NF-kappa B activity through induction of I kappa B synthesis. *Science.* **270**, 286.
- Bach, J. W. and Strom, T. B. (1986). The mode of action of immunosuppressive agents. p105. Elsevier, Amsterdam.
- Bakr, M. A., Sobh, M., el, Agroudy A., *et al.* (1997). Study of malignancy among Egyptian kidney transplant recipients. *Transplant.Proc.* **29**, 3067.
- Baserga, R. and Shubik, P. (1954). Action of cortisone on disseminated tumor cells after removal of the primary growth. *Science.* **121**, 100.
- Bennett, J. A., Pilon, V. A., Briggs, D. R., and McKneally, M. F. (1985). Evaluation of cyclosporine-treated mice as hosts for growing and testing the chemosensitivity

- of first-transplant-generation human tumor xenografts implanted under the kidney capsule. *J Natl.Cancer Inst.* **75**, 925.
- Beveridge, T., Krupp, P., and McKibbin, C. (1984). Lymphomas and lymphoproliferative lesions developing under cyclosporin therapy. *Lancet.* **1**, 788.
- Birkeland, S. A. (1976). Uremia as a state of immune deficiency. *Scand.J Immunol.* **5**, 107.
- Birkeland, S. A. (1983). Malignant tumors in renal transplant patients. The Scandia transplant material. *Cancer.* **51**, 1571.
- Border, W. A. and Noble, N. A. (1994). Transforming growth factor beta in tissue fibrosis. *N Engl J Med.* **331**, 1286.
- Bordes-Aznar, J., Mancilla, E., Rosenblum, M., *et al.* (1992). Malignant neoplasms in renal transplant patients: a 24-year experience. *Transplant.Proc.* **24**, 1802.
- Borel, J. F., Feurer, C., Gubler, H. U., and Stahelin, H. (1976). Biological effects of cyclosporin A: a new antilymphocytic agent. *Agents Actions.* **6**, 468.
- Brockman, R. W. (1963). Biochemical aspects of mercaptopurine inhibition and resistance. *Cancer.* **23**, 1191.
- Burnet, F. M. (1970). The concept of immunologic surveillance. *Prog.Exp.Tumor Res.* **13**, 1.
- Bush, A. and Gabriel, R. (1984). Cancer in uremic patients. *Clin.Nephrol.* **22**, 77.
- Calne, R. Y., Alexandre, G. P., and Murray, J. E. (1962). A study of the effects of drugs in prolonged survival of homologous renal transplantation in dogs. *Ann.N.Y.Acad.Sci.* **99**, 743.
- Calne, R. Y., Evans, D. B., Herbertson, B. M., *et al.* (1968). Survival after renal transplantation in man: an interim report on 54 consecutive transplants. *Br.Med.J.* **2**, 404.
- Calne, R. Y., White, D. J., Thiru, S., *et al.* (1978). Cyclosporin A in patients receiving renal allografts from cadaver donors. *Lancet.* **2**, 1323.
- Casey, T. P. (1968). Azathioprine (Imuran) administration and the development of malignant lymphomas in NZB mice. *Clin.Exp.Immunol.* **3**, 305.
- Cassidy, M. J., Disler, P. B., Swanepoel, C. R., Jacobson, J. E., and Pontin, A. R. (1982). De novo malignant tumours in renal transplant recipients. *S.Afr.Med J.* **62**, 58.
- Centres for Disease Control. (1982). Epidemiologic aspects of the current outbreak of Kaposi's sarcoma and opportunistic infections. *N Engl J Med.* **306**, 248.

- Chan, G. L., Canafax, D. M., and Johnson, C. A. (1987). The therapeutic use of azathioprine in renal transplantation. *Pharmacotherapy*. **7**, 165.
- Clipstone, N. A. and Crabtree, G. R. (1992). Identification of calcineurin as a key signalling enzyme in T- lymphocyte activation. *Nature*. **357**, 695.
- Cockburn, I. (1987). Assessment of the risks of malignancy and lymphomas developing in patients using Sandimmune. *Transplant.Proc.* **19**, 1804.
- Contractor, N. V., Bassiri, H., Reya, T., et al. (1998). Lymphoid hyperplasia, autoimmunity, and compromised intestinal intraepithelial lymphocyte development in colitis-free gnotobiotic IL-2- deficient mice. *J Immunol.* **160**, 385 .
- Demetris, A. J., Nalesnik, M. A., Kunz, H. W., Gill, T. J., III, and Shinozuka, H. (1984). Sequential analyses of the development of lymphoproliferative disorders in rats receiving cyclosporine. *Transplantation.* **38**, 239.
- Disler, P. B., MacPhail, A. P., and Myburg, J. A. (1981). Neoplasia after successful renal transplantation. *Nephron.* **29**, 119.
- Ecdar, S. T., Sever, M. S., Yildiz, A., et al. (1998). Kaposi's sarcoma after renal transplantation in Turkey. *Clin Transplant.* **12**, 472.
- Elion, G. B. (1967). Symposium on immunosuppressive drugs. Biochemistry and pharmacology of purine analogues. *Fed.Proc.* **26**, 898.
- Emmel, E. A., Verweij, C. L., Durand, D. B., Higgins, K. M., Lacy, E., and Crabtree, G. R. (1989). Cyclosporin A specifically inhibits function of nuclear proteins involved in T cell activation. *Science.* **246**, 1617.
- Farge, D. (1993). Kaposi's sarcoma in organ transplant recipients. The Collaborative Transplantation Research Group of Ile de France. *Eur.J Med.* **2**, 339.
- Faulds, D., Goa, K. L., and Benfield, P. (1993). Cyclosporin. A review of its pharmacodynamic and pharmacokinetic properties, and therapeutic use in immunoregulatory disorders [published erratum appears in *Drugs* 1993 Sep;46(3):377]. *Drugs.* **45**, 953.
- Flattery, M. P. (1998). Incidence and treatment of cancer in transplant recipients. *J Transpl.Coord.* **8**, 105.
- Fruman, D. A., Klee, C. B., Bierer, B. E., and Burakoff, S. J. (1992). Calcineurin phosphatase activity in T lymphocytes is inhibited by FK 506 and cyclosporin A. *Proc.Natl.Acad.Sci.U.S.A.* **89**, 3686.
- Ghods, A. J. and Ossareh, S. (2000). Lymphoma-the most common neoplasia in renal transplant recipients. *Transplant.Proc.* **32**, 585.

- Gleichmann, H. and Gleichmann, E. (1973). Immunosuppression and neoplasia. I. A critical review of experimental carcinogenesis and the immunosurveillance theory. *Klin.Wochenschr.* **51**, 255.
- Glover, M. T., Niranjani, N., Kwan, J. T., and Leigh, I. M. (1994). Non-melanoma skin cancer in renal transplant recipients: the extent of the problem and a strategy for management. *Br.J.Plast.Surg.* **47**, 86.
- Goodman, M. M., McCullough, J. L., Biren, C. A., and Barr, R. J. (1987). A model of human melanoma in cyclosporine-immunosuppressed rats. *J Invest Dermatol.* **88**, 141.
- Gottlieb, M. S., Groopman, J. E., Weinstein, W. M., Fahey, J. L., and Detels, R. (1983). The acquired immunodeficiency syndrome. *Ann.Intern.Med.* **99**, 208.
- Granelli-Piperno, A. (1990). Lymphokine gene expression in vivo is inhibited by cyclosporin A. *J Exp.Med.* **171**, 533.
- Granelli-Piperno, A., Andrus, L., and Steinman, R. M. (1986). Lymphokine and nonlymphokine mRNA levels in stimulated human T cells. Kinetics, mitogen requirements, and effects of cyclosporin A. *J Exp.Med.* **163**, 922.
- Gruber, S. A., Gillingham, K. J., Sothorn, R. B., Stephanian, E., Matas, A. J., and Dunn, D. L. (1994). De novo cancer in cyclosporin-treated and non-cyclosporin-treated adult primary renal allograft recipients. *Clin.Transpl.* **8**, 388.
- Gruber, S. A., Skjei, K. L., Sothorn, R. B., et al. (1991). Cancer development in renal allograft recipients treated with conventional and cyclosporin immunosuppression. *Transplant.Proc.* **23**, 1104.
- Grundmann, E. and Hobik, H. P. (1973). [Lymphoreticular sarcomas in immunodeficient mice]. *Z.Krebsforsch.Klin.Onkol.Cancer Res.Clin.Oncol.* **79**, 298.
- Harding, M. W., Handschumacher, R. E., and Speicher, D. W. (1986). Isolation and amino acid sequence of cyclophilin. *J Biol.Chem.* **261**, 8547.
- Harris, J., Sengar, D., Stewart, T., and Hyslop, D. (1976). The effect of immunosuppressive chemotherapy on immune function in patients with malignant disease. *Cancer.* **37**, 1058.
- Harwood, A. R., Osoba, D., Hofstader, S.L., et al. (1979). Kaposi's sarcoma in recipients of renal transplants. *Am.J.Med.* **67**, 759.
- Hattan, D. and Cerilli, G. J. (1971). Spontaneous reticulum cell sarcomas developing in C3H-HeJ mice on prolonged immunosuppressive therapy. *Transplantation.* **11**, 580.

- Hattori, A., Perera, M. I., Witkowski, L. A., Kunz, H. W., Gill, T. J., III, and Shinozuka, H. (1986). Accelerated development of spontaneous thymic lymphomas in male AKR mice receiving cyclosporine. *Transplantation*. **41**, 784.
- Herr, H. W., Engen, D. E., and Hostetler, J. (1979). Malignancy in uremia: dialysis versus transplantation. *J.Urol.* **121**, 584.
- Hitchings, G. H. and Elion, G. B. (1954). The chemistry and biochemistry of purine analogs. *Ann.N.Y.Acad.Sci.* **60**, 195.
- Hojo, M., Morimoto, T., Maluccio, M., *et al.* (1999). Cyclosporine induces cancer progression by a cell-autonomous mechanism. *Nature*. **397**, 530.
- Hoover, R. (1977). Effect of drugs - Immunosuppression. *In* Origins of Human Cancer, (Haitt, H. H., Watson, J. D. , and Winsten, J. A., eds.), p.369 , Cold Spring Harbor Laboratory, Cold Spring Harbor.
- Horak, I., Lohler, J., Ma, A., and Smith, K. A. (1995). Interleukin-2 deficient mice: a new model to study autoimmunity and self-tolerance. *Immunol.Rev.* **148**, 35.
- Jonas, S., Rayes, N., Neumann, U., *et al.* (1997). De novo malignancies after liver transplantation using tacrolimus-based protocols or cyclosporine-based quadruple immunosuppression with an interleukin-2 receptor antibody or antithymocyte globulin. *Cancer*. **80**, 1141.
- Kahan, B. D. (1989). Cyclosporine [see comments]. *N.Engl.J.Med.* **321**, 1725.
- Kahan, B. D. (1999). Cyclosporine: a revolution in transplantation. *Transplant.Proc.* **31**, 14S.
- Kehinde, E. O., Petermann, A., Morgan, J. D., *et al.* (1994). Triple therapy and incidence of de novo cancer in renal transplant recipients. *Br J Surg.* **81**, 985.
- Kehrl, J. H., Wakefield, L. M., Roberts, A. B., *et al.* (1986). Production of transforming growth factor beta by human T lymphocytes and its potential role in the regulation of T cell growth. *J Exp.Med.* **163**, 1037.
- Khanna, A., Li, B., Stenzel, K. H., and Suthanthiran, M. (1994). Regulation of new DNA synthesis in mammalian cells by cyclosporine. Demonstration of a transforming growth factor beta-dependent mechanism of inhibition of cell growth. *Transplantation*. **57**, 577.
- Kim, S., Kang, S. H., Moon, J., Kim, M. S., Kim, Y. S., and Park, K. (1998). Kaposi sarcoma in renal transplant recipients. *Transplant.Proc.* **30**, 3165.
- Kinlen, L. J., Eastwood, J. B., Kerr, D. N., *et al.* (1980). Cancer in patients receiving dialysis. *Br Med J.* **280**, 1401.

- Knudsen, P. J., Dinarello, C. A., and Strom, T. B. (1987). Glucocorticoids inhibit transcriptional and post-transcriptional expression of interleukin 1 in U937 cells. *J Immunol.* **139**, 4129.
- Koranda, F. C., Loeffler, R. T., Koranda, D. M., and Penn, I. (1975). Accelerated induction of skin cancers by ultraviolet radiation in hairless mice treated with immunosuppressive agents. *Surg.Forum.* **26**, 145.
- Kramer, P., Broyer, M., Brunner, F. P., et al. (1984). Combined report on regular dialysis and transplantation in Europe. *Proc.EDTA-ERA.* **21**, 5.
- Kundig, T. M., Schorle, H., Bachmann, M. F., Hengartner, H., Zinkernagel, R. M., and Horak, I. (1993). Immune responses in interleukin-2-deficient mice. *Science.* **262**, 1059.
- Kuper, H., Adami, H. O., and Trichopoulos, D. (2000). Infections as a major preventable cause of human cancer. *J Intern.Med.* **248**, 171.
- Lennard, L. and Maddocks, J. L. (1983). Assay of 6-thioguanine nucleotide, a major metabolite of azathioprine, 6-mercaptopurine and 6-thioguanine, in human red blood cells. *J Pharm.Pharmacol.* **35**, 15.
- Li, B., Sehajpal, P. K., Khanna, A., et al. (1991). Differential regulation of transforming growth factor beta and interleukin 2 genes in human T cells: demonstration by usage of novel competitor DNA constructs in the quantitative polymerase chain reaction. *J Exp.Med.* **174**, 1259.
- Lindner, A., Farewell, V. T., and Sherrard, D. J. (1981). High incidence of neoplasia in uremic patients receiving long-term dialysis. Cancer and long-term dialysis. *Nephron.* **27**, 292.
- Liu, J., Farmer, J. D., Jr., Lane, W. S., Friedman, J., Weissman, I., and Schreiber, S. L. (1991). Calcineurin is a common target of cyclophilin-cyclosporin A and FKBP-FK506 complexes. *Cell.* **66**, 807.
- Lockshin, A. (1987). Lethality of human melanoma cells for normal mice immunosuppressed with cyclosporin A. *Cancer Lett.* **35**, 159.
- London, N. J., Farmery, S. M., Will, E. J., Davison, A. M., and Lodge, J. P. (1995). Risk of neoplasia in renal transplant patients. *Lancet.* **346**, 403.
- Lopez, C., Simmons, R. L., Mauer, S. M., Najarian, J. S., Good, R. A., and Gentry, S. (1974). Association of renal allograft rejection with virus infections. *Am J Med.* **56**, 280.

- Margolius, L. P. (1996). Kaposi's sarcoma and other malignancies in renal transplant recipients. *Transplant.Rev.* **10**, 129.
- Masuhara, M., Ogasawara, H., Katyal, S. L., Nakamura, T., and Shinozuka, H. (1993). Cyclosporine stimulates hepatocyte proliferation and accelerates development of hepatocellular carcinomas in rats. *Carcinogenesis.* **14**, 1579.
- Matas, A. J., Simmons, R. L., Kjellstrand, C. M., Buselmeier, T. J., and Najarian, J. S. (1975a). Increased incidence of malignancy during chronic renal failure. *Lancet.* **1**, 883 .
- Matas, A. J., Simmons, R. L., and Najarian, J. S. (1975b). Chronic antigenic stimulation, herpesvirus infection, and cancer in transplant recipients. *Lancet.* **1**, 1277.
- Mattila, P. S., Ullman, K. S., Fiering, S., *et al.* (1990). The actions of cyclosporin A and FK506 suggest a novel step in the activation of T lymphocytes. *EMBO J.* **9**, 4425.
- Miach, P. J., Dawborn, J. K., and Xipell, J. (1976). Neoplasia in patients with chronic renal failure on long-term dialysis. *Clin.Nephrol.* **5**, 101.
- Mihalov, M. L., Gattuso, P., Abraham, K., Holmes, E. W., and Reddy, V. (1996). Incidence of posttransplant malignancy among 674 solid-organ-transplant recipients at a single center. *Clin.Transplant.* **10**, 248.
- Min, S. K., Huh, S., Ahn, M. S., *et al.* (2000). Malignancy in renal transplant recipients. *Transplantation Proceedings.* **32**, 1980.
- Montagnino, G., Lorca, E., Tarantino, A., *et al.* (1996). Cancer incidence in 854 kidney transplant recipients from a single institution: comparison with normal population and with patients under dialytic treatment. *Clin.Transplant.* **10**, 461.
- Nabel, G. J. (1999). A transformed view of cyclosporine. *Nature.* **397**, 471.
- Noel, J.-C., Hermans, P., Andre, J., *et al.* (1996). Herpes-like DNA sequences and Kaposi's sarcoma. *Cancer.* **77**, 2132.
- O'Keefe, S. J., Tamura, J., Kincaid, R. L., Tocci, M. J., and O'Neill, E. A. (1992). FK-506- and CsA-sensitive activation of the interleukin-2 promoter by calcineurin. *Nature.* **357**, 692.
- Otto, U., Huland, H., Kloppel, G., and Baisch, H. (1987). Xenogenic transplantation of human bladder- and renal-cell carcinoma into NMRI mice treated with cyclosporin A and into NMRI nu/nu mice. Introduction of a new experimental cancer model. *Urol.Int.* **42**, 1.

- Pateras, V. R. (1985). Malignancy in chronic dialysis patients. *Int.J Artif.Organs.* **8**, 301.
- Pecchini, F. and Vagelli, G. (1983). [Clinical aspects of tumors in the course of dialysis]. *Minerva Nefrol.* **30**, 41.
- Penn, I. (1974). Chemical immunosuppression and human cancer. *Cancer.* **34**, suppl.
- Penn, I. (1977). Development of cancer as a complication of clinical transplantation. *Transplant.Proc.* **9**, 1121.
- Penn, I. (1978). Malignancies associated with immunosuppressive or cytotoxic therapy. *Surgery.* **83**, 492.
- Penn, I. (1980). Some contribution of transplantation to our understanding of cancer. *Transplant.Proc.* **12**, 676.
- Penn, I. (1981). Depressed immunity and the development of cancer. *Clin.Exp Immunol.* **46**, 459.
- Penn, I. (1982). The occurrence of cancer in immune deficiencies. *Curr.Probl.Cancer.* **6**, 1.
- Penn, I. (1984). Cancer in immunosuppressed patients. *Transplant.Proc.* **16**, 492.
- Penn, I. (1986a). Cancer is a complication of severe immunosuppression. *Surg.Gynecol.Obstet.* **162**, 603.
- Penn, I. (1986b). The occurrence of malignant tumors in immunosuppressed states. *Prog.Allergy.* **37**, 259.
- Penn, I. (1987a). Cancers following cyclosporine therapy. *Transplant.Proc.* **19**, 2211.
- Penn, I. (1987b). Cancers following cyclosporine therapy. *Transplantation.* **43**, 32.
- Penn, I. (1989a). Why do immunosuppressed patients develop cancer? In CRC Critical reviews in oncogenesis, Vol 1, (Pimental, E., eds.), CRC Press Inc, Boca Raton.
- Penn, I. (1989b). Why do immunosuppressed patients develop cancer? *Crit Rev.Oncog.* **1**, 27.
- Penn, I. (1991a). Immunosuppression and opportunistic tumors. In Advances in Tumor Immunology and Allergic Disorders, (Dammacco, F., eds.), p.139, Edi Ermes, Milan,Italy.
- Penn, I. (1991b). The changing pattern of posttransplant malignancies. *Transplant.Proc.* **23**, 1101 .

- Penn, I. (1993). Tumors after renal and cardiac transplantation. *Hematol.Oncol.Clin.North Am.* **7**, 431.
- Penn, I. (1994a). Depressed immunity and the development of cancer. *Cancer Detect.Prev.* **18**, 241.
- Penn, I. (1994b). The problem of cancer in organ transplant recipients: an overview. *Transplant.Sci.* **4**, 23.
- Penn, I. (1996a). Cancers in cyclosporine-treated vs azathioprine-treated patients. *Transplant.Proc.* **28**, 876.
- Penn, I. (1996b). Immunosuppressive agents, immunodeficiency states and malignancy. *In Principles of drug development in transplant and autoimmunity*, (Lieberman, R. and Muckerjee, A., eds.), p.93, RG Landes, Austin(Texas).
- Penn, I. (1999). Occurrence of cancers in immunosuppressed organ transplant recipients. *In Clinical Transplants 1998*, (Cecka, J. M. and Terasaki, P. I., eds.), p.147, UCLA Tissue Typing Laboratory, Los Angeles.
- Penn, I. (2000). Posttransplant malignancy: the role of immunosuppression [In Process Citation]. *Drug Saf.* **23**, 101.
- Penn, I. and Brunson, M. E. (1988). Cancers after cyclosporine therapy. *Transplant.Proc.* **20**, 885 .
- Penn, I., Halgrimson, C. G., and Starzl, T. E. (1971). De novo malignant tumors in organ transplant recipients. *Transplant.Proc.* **3**, 773.
- Penn, I., Hammond, W., Brettschneider, L., and Starzl, T. E. (1969). Malignant lymphomas in transplantation patients. *Transplant.Proc.* **1**, 106.
- Perera, M. I., Kunz, H. W., Gill, T. J., III, and Shinozuka, H. (1986). Enhancement of induction of intestinal adenocarcinomas by cyclosporine in rats given a single dose of N-methyl N-nitrosourea. *Transplantation.* **42**, 297.
- Qunibi, W., Akhtar, M., Sheth, K., *et al.* (1988). Kaposi's sarcoma: The most common tumor after renal transplantation in Saudi Arabia. *Am.J.Med.* **84**, 225.
- Qunibi, W., Barri, Y., Alfurayh, O., *et al.* (1993). Kaposi's sarcoma in renal transplant recipients: a report on 26 cases from a single institution. *Transplant.Proc.* **25**, 1402.
- Rao, A. (1995). NFATp, a cyclosporin-sensitive transcription factor implicated in cytokine gene induction. *J Leukoc.Biol.* **57**, 536.
- Rao, V. K. (1998). Posttransplant medical complications. *Surg.Clin.North Am.* **78**, 113.

- Ritters, B., Grabensee, B., and Heering, P. (1994). Malignancy under immunosuppressive therapy including cyclosporine. *Transplant.Proc.* **26**, 2656.
- Roberts, A. B. and Sporn, M. B. (1993). Physiological actions and clinical applications of transforming growth factor-beta (TGF-beta). *Growth Factors.* **8**, 1.
- Rosner, F., Grünewald, H. W., and Zarrabi, H. M. (1982). Cancer after the use of alkylating agents and non-alkylating cytotoxic agents. *Cancer Surv.* **1**,
- Ryffel, B., Woerly, G., Quesniaux, V. F., Husi, H., and Foxwell, B. M. (1992). Covalent binding of cyclosporine inhibits irreversibly T-lymphocyte activation. *Biochem.Pharmacol.* **43**, 953.
- Scheinman, R. I., Cogswell, P. C., Lofquist, A. K., and Baldwin, A. S., Jr. (1995). Role of transcriptional activation of I kappa B alpha in mediation of immunosuppression by glucocorticoids. *Science.* **270**, 283.
- Schmähl, D. (1977). Carcinogenic action of anticancer drugs with special reference to immunosuppression. *Cancer.* **40**, 1927.
- Schmidt, R., Stippel, D., Schmitz, Rixen T., and Pollok, M. (1996). Tumors after renal transplantation. *Urol.Int.* **57**, 21.
- Schorle, H., Holtschke, T., Hunig, T., Schimpl, A., and Horak, I. (1991). Development and function of T cells in mice rendered interleukin-2 deficient by gene targeting. *Nature.* **352**, 621.
- Schreiber, S. L. and Crabtree, G. R. (1992). The mechanism of action of cyclosporin A and FK506. *Immunol.Today.* **13**, 136.
- Schumacher, A. and Nordheim, A. (1992). Progress towards a molecular understanding of cyclosporin A-mediated immunosuppression. *Clin.Investig.* **70**, 773.
- Schwartz, R., Andre-Schwartz, J., Armstrong, M. Y. K., and Beldotti, L. (1966). Neoplastic sequelae of allogenic disease. *Ann.N.York.Acad.Sc.* **129**, 804.
- Schwartz, R. S. and Dameshek, W. (1959). Drug-induced immunological tolerance. *Nature.* **183**, 1682 .
- Selik, R. M., Starcher, E. T., and Curran, J. W. (1987). Opportunistic diseases reported in AIDS patients: frequencies, associations, and trends. *AIDS.* **1**, 175.
- Servilla, K. S., Burnham, D. K., and Daynes, R. A. (1987). Ability of cyclosporine to promote the growth of transplanted ultraviolet radiation-induced tumors in mice. *Transplantation.* **44**, 291.

- Sheil, A. G., Flavel, S., Disney, A. P., and Mathew, T. H. (1985). Cancer development in patients progressing to dialysis and renal transplantation. *Transplant.Proc.* **17**, 1685.
- Sheil, A. G., Flavel, S., Disney, A. P., Mathew, T. H., and Hall, B. M. (1987). Cancer incidence in renal transplant patients treated with azathioprine or cyclosporine. *Transplant.Proc.* **19**, 2214.
- Shimizu, T., Martin, M. S., Pelletier, H., Lagadec, P., and Martin, F. (1989). Effects of cyclosporin A on progressive and regressive tumors induced by two cancer lines derived from a single colon carcinoma chemically induced in the rat. *Immunobiology.* **178**, 401.
- Shinozuka, H., Gill, T. J., III, Kunz, H. W., Witkowski, L. A., Demetris, A. J., and Perera, M. I. (1986). Enhancement of the induction of murine thymic lymphomas by cyclosporine. *Transplantation.* **41**, 377.
- Slifkin, R. F., Goldberg, J., Neff, M. S., Baez, A., Mattoo, N., and Gupta, S. (1977). Malignancy in end-stage renal disease. *Trans.Am Soc.Artif.Intern.Organs.* **23**, 34.
- Starzl, T. E., Penn, I., Putnam, C. W., Groth, C. G., and Halgrimson, C. G. (1971). Iatrogenic alterations of immunologic surveillance in man and their influence on malignancy. *Transplant.Rev.* **7**, 112.
- Suthanthiran, M. and Strom, T. B. (1994). Renal transplantation. *N Engl J Med.* **331**, 365.
- Sutherland, G. A., Glass, J., and Gabriel, R. (1977). Increased incidence of malignancy in chronic renal failure. *Nephron.* **18**, 182.
- Swift, P. S. (1996). The role of radiation therapy in the management of HIV-related Kaposi's sarcoma. *Hematol.Oncol.Clin.North Am.* **10**, 1069.
- Thiagarajan, C. M., Divakar, D., and Thomas, S. J. (1998). Malignancies in renal transplant recipients. *Transplant.Proc.* **30**, 3154.
- Thomas, L. (1959). Reactions to homologous tissue antigens in relation to hypersensitivity. In *Cellular and Humoral Aspects of the Hypersensitive States*, (Lawrence, H. S., eds.), p.529, Hoeber-Harper, New York.
- Tidd, D. M. and Paterson, A. R. (1974a). A biochemical mechanism for the delayed cytotoxic reaction of 6- mercaptopurine. *Cancer Res.* **34**, 738.
- Tidd, D. M. and Paterson, A. R. (1974b). Distinction between inhibition of purine nucleotide synthesis and the delayed cytotoxic reaction of 6-mercaptopurine. *Cancer Res.* **34**, 733.

- Torchia, J., Rose, D. W., Inostroza, J., *et al.* (1997). The transcriptional co-activator p/CIP binds CBP and mediates nuclear-receptor function. *Nature*. **387**, 677.
- Van de Vrie, W, Marquet, R. L., and Eggermont, A. M. (1997). Cyclosporin A enhances locoregional metastasis of the CC531 rat colon tumour. *J Cancer Res.Clin.Oncol.* **123**, 21.
- Van der Elst, J., De Greve, J., Geerts, F., De Neve, W., Storme, G., and Willems, G. (1986). Quantitative study of liver metastases from colon cancer in rats after treatment with cyclosporine A. *J Natl.Cancer Inst.* **77**, 227.
- Vilardell, J., Oppenheimer, F., Castelao, A. M., *et al.* (1992). Cancer after transplantation in Catalonia. *Transplant.Proc.* **24**, 124.
- Wiesner, R. H. (1998). A long-term comparison of tacrolimus (FK506) versus cyclosporine in liver transplantation: a report of the United States FK506 Study Group. *Transplantation.* **66**, 493.
- Xanthoudakis, S., Viola, J. P., Shaw, K. T., *et al.* (1996). An enhanced immune response in mice lacking the transcription factor NFAT1. *Science*. **272**, 892.
- Yokota, K., Fukumitsu, K, Kuzuhara, K., *et al.* (1994). Development of cancer in renal allograft recipients. *Transplant.Proc.* **26**, 1977.
- Yokoyama, I., Carr, B., Saito, H., Iwatsuki, S., and Starzl, T. E. (1991). Accelerated growth rates of recurrent hepatocellular carcinoma after liver transplantation. *Cancer*. **68**, 2095.
- Yoshimura, N. and Kahan, B. D. (1986). The requirement for the renal transplant to induce allograft unresponsiveness by the combination of extracted histocompatibility antigen and cyclosporine. *Transplantation.* **42**, 642.
- Yuzawa, K., Kondo, I., Fukao, K., Iwasaki, Y., and Hamaguchi, H. (1986). Mutagenicity of cyclosporine. Induction of sister chromatid exchange in human cells. *Transplantation.* **42**, 61.
- Zanker, B., Walz, G., Wieder, K. J., and Strom, T. B. (1990). Evidence that glucocorticosteroids block expression of the human interleukin-6 gene by accessory cells. *Transplantation.* **49**, 183.



SECTION 4

Sir Roy Calne (1930-)

Chapter 17

SERO-EPIDEMIOLOGY OF HHV-8

Overwhelming evidence suggests a key role for the human herpesvirus-8 (HHV-8) in the aetiopathogenesis of all epidemiological forms of Kaposi's sarcoma (see Chapter 14) (Schulz, 1998; Weiss *et al.*, 1998). We have also shown in the preceding chapters of this thesis that Kaposi's sarcoma is by far the most common malignancy in our renal transplant population, as well as that of many other developing countries. The question of why this is so, arises. Could it be that the high prevalence of Kaposi's sarcoma in our renal transplant patients is due to the high prevalence of HHV-8 infection in the general population? There are several cross-sectional epidemiological studies supporting the hypothesis that HHV-8 infection is more prevalent in regions where there is a higher prevalence of Kaposi's sarcoma (Cattani *et al.*, 1999; Cottoni *et al.*, 1996; Gao *et al.*, 1996b; Kedes *et al.*, 1996; Kedes *et al.*, 1997; Lennette *et al.*, 1996; Lospalluti *et al.*, 1995; Simpson *et al.*, 1996; Viviano *et al.*, 1997) and that when other factors are also present this can contribute to the development of Kaposi's sarcoma. Longitudinal studies, which are

critical in the evaluation of causality, have shown that HHV-8 infection precedes the development of Kaposi's sarcoma (Gao *et al.*,1996a;Lefrère *et al.*,1996;Whitby *et al.*,1995). The other question that arises that is equally important is how is the virus transmitted to transplant recipients? Sexual routes of spread have been implicated in epidemic Kaposi's sarcoma (Blackbourn *et al.*,1999;Caterino-de-Araujo *et al.*,1999;Howard *et al.*,1997;Kedes *et al.*,1997;Martin *et al.*,1998b;Monini *et al.*,1996;Simpson *et al.*,1996;Sosa *et al.*,1998;Zhang *et al.*,1998). The strongest evidence for sexual transmission of the virus is from studies that show that the prevalence of anti-HHV-8 antibodies is highest in homosexual men living in the hot spots of the acquired immunodeficiency syndrome (AIDS) epidemic and that human immunodeficiency virus (HIV)-negative homosexual males have a higher seroprevalence than heterosexual males (Beral *et al.*,1990;Rutherford *et al.*,1989;Wang *et al.*,1995). In contrast, in endemic Kaposi's sarcoma nonsexual routes appear to be the main manner of spread of HHV-8 (Cattani *et al.*,1999;Enbom *et al.*,1999). Little is known about the spread of the virus in renal transplant recipients but the donor graft has been suggested as a possible route (Frances *et al.*,2000;Regamey *et al.*,1998a).

HHV-8 SEROPREVALENCE

Europe and USA

Epidemiological studies have shown that the incidence of Kaposi's sarcoma differs in various parts of the world and in different categories of patients with AIDS (Fig. 17-1) (Beral *et al.*,1990), with serology of HHV-8 antibodies generally fitting a similar pattern (Weiss *et al.*,1998). Among all the different categories of AIDS patients from North America and Europe, HHV-8 infection occurs most commonly among homosexual men and least among haemophiliacs (Lennette *et al.*,1996;Simpson *et al.*,1996). Heterosexual acquisition of HIV in Africa is also associated with Kaposi's sarcoma. Geographically as well, the detection of HHV-8 antibodies is associated with areas such as Greece, Italy and Uganda, which have a high incidence of Kaposi's sarcoma (Whitby *et al.*,1998b). However, areas such as the Western Cape, Saudi Arabia and other developing countries, which have a very high incidence of posttransplant Kaposi's sarcoma are not traditionally known to be associated with a high incidence of Kaposi's sarcoma in the general population (Qunibi *et al.*,1988).

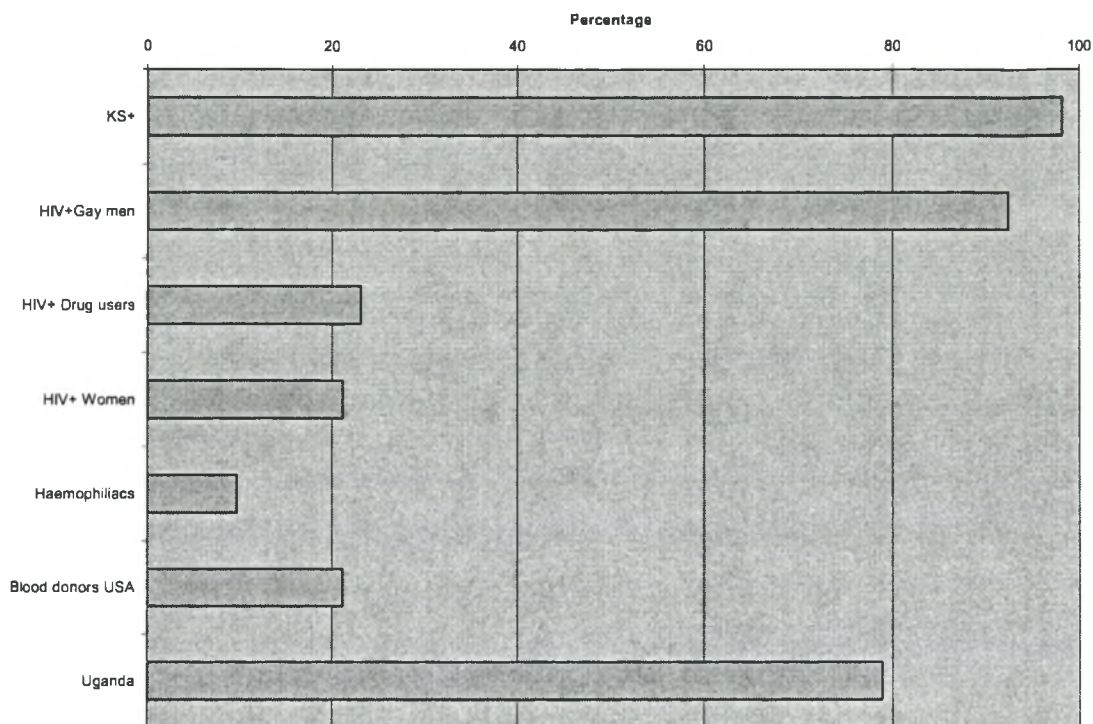
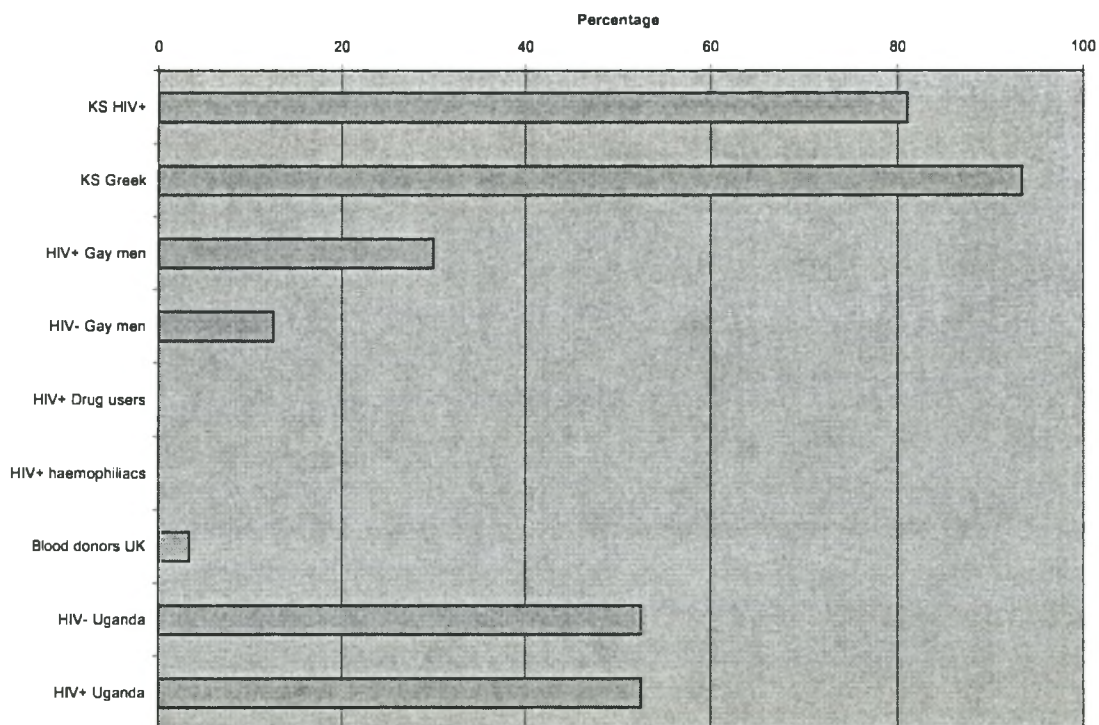


Fig. 17-1 The prevalence of antibodies to HHV-8 in various risk groups. The upper figure was drawn from data obtained from Simpson et al. (1996) and the lower figure from Lennette et al. (1996).



In a cross-sectional study, Qunibi and his colleagues established that among renal transplant patients with Kaposi's sarcoma the prevalence of HHV-8 antibodies was 93%, compared to 28% among renal transplant patients who did not develop Kaposi's sarcoma (Qunibi *et al.*,1998). The seroreactivity of 28% among renal patients, in whom sexual transmission of the virus is considered less likely, is vastly greater than the 7% among healthy control subjects and alludes to the possibility of acquiring the infection from sources other than the renal allograft. The 7% seroprevalence in normal Saudi subjects is similar to that reported in Western countries (Davis *et al.*,1997;Kedes *et al.*,1996;Lefrère *et al.*,1996;Lennette *et al.*,1996;Regamey *et al.*,1998a;Simpson *et al.*,1996;Whitby *et al.*,1995).

Sub-Saharan Africa

In developing countries the seroprevalence of HHV-8 antibodies is much higher than in the general population of Europe and the United States (Davis *et al.*,1997;Kedes *et al.*,1996;Lefrère *et al.*,1996;Lennette *et al.*,1996;Simpson *et al.*,1996;Whitby *et al.*,1995). In sub-Saharan Africa especially, where the prevalence of Kaposi's sarcoma is high, the seroprevalence of HHV-8 has been shown to be particularly high. In a study from Johannesburg, it was again confirmed that Kaposi's sarcoma was associated with the presence of HHV-8 antibodies but not with any other cancer (Sitas *et al.*,1999). In addition, higher titres of HHV-8 antibodies correlated with the risk of the disease as is the case with Epstein-Barr virus (EBV), and Burkitt's lymphoma and nasopharyngeal carcinoma (de-Thé *et al.*,1978a;de-Thé *et al.*,1978b). The prevalence of antibodies to HHV-8 in the general population of the Western Cape where our Transplant Unit is located is unknown.

ROUTE OF TRANSMISSION

Although there is strong evidence supporting the sexual route of transmission of the virus (Blackbourn *et al.*,1997;Kedes *et al.*,1996;Martin *et al.*,1998a;Regamey *et al.*,1998b), it is also becoming increasingly evident that nonsexual modes of spread also exist especially in areas where Kaposi's sarcoma is endemic (Enbom *et al.*,1999). The high seroprevalence of HHV-8 and its detection in young people in areas where Kaposi's sarcoma is endemic (Mayama *et al.*,1998;Olsen *et al.*,1998) suggests that multiple modes of transmission are possible. *Parenteral* transmission

almost certainly occurs as suggested by data from an Eritrean tribe, the Rashaidas, among whom prostitution and extramarital liaisons do not occur but skin piercing under non-sterile conditions is widely practiced. Among this tribe the prevalence of anti-HHV-8 antibodies is 26% compared to 5% among subjects from neighbouring regions (Enbom *et al.*,1999). As with other herpesviruses horizontal transmission possibly via nongenital fluids may in fact play an important role in the spread of HHV-8 (Bigoni *et al.*,1996;Blackbourn *et al.*,1998; Boldogh *et al.*,1996; Chang *et al.*,1996b; Koelle *et al.*,1997; Lennette *et al.*,1996). There is epidemiological evidence that the virus may be spread by the *faecal-oral* route (DePond *et al.*,1997), and the gastrointestinal tract is a potential reservoir for HHV-8 (Thomas *et al.*,1996). If these nonsexual routes of transmission are indeed important it places the renal transplant patient potentially at risk from infected Renal Unit staff and family members. Of relevance, not to the transplant patient but from an epidemiological viewpoint, is the recent report from South Africa that *mother-to-child* transmission was an important route for acquiring HHV-8 in Africa (Bourboullia *et al.*,1998), although another serologic study from Haiti where Kaposi's sarcoma is not endemic showed, contrariwise, no HHV-8 transmission from mother to child (Rabkin *et al.*,1998).

Donor Organ-Recipient Transmission

In an important study, Regamey and colleagues (1998) studied the transmission of HHV-8 infection from renal transplant donors to organ recipients (Regamey *et al.*,1998a). Using an enzyme-linked immunosorbent assay (ELISA) with the recombinant HHV-8 protein open reading frame (ORF) 65.2 they analysed the serum samples of 220 renal transplant recipients for the presence of antibody at the time of transplantation and also a year later. The seroprevalence of HHV-8 increased from 6.4% at transplantation to 17.7% at one year after transplantation. Of the patients who seroconverted, 83% had received organs from donors who were seropositive. Kaposi's sarcoma developed in 2 (8%) of the 25 patients who had seroconverted. None of the patients who received an organ from a seronegative donor seroconverted; also Kaposi's sarcoma did not occur in any of the patients who had remained seronegative or were already seropositive at the time of renal transplantation. The latter observation is an important one because it suggests, as is the case with cytomegalovirus (CMV), that among renal transplant recipients

primary HHV-8 infection, transmitted through the graft, poses a much greater threat of complications than the reactivation of the latent disease (Ho *et al.*, 1975).

Shortcomings

A major defect of this study was that, although the number of blood transfusions received within the first year was documented, the HHV-8 antibody status of the blood donors was not determined. The possibility that HHV-8 could have been transmitted by blood transfusions could not be excluded with certainty. This is supported by the following observation: the seroprevalence of HHV-8 antibody was 6.4% in Regamey's population of renal transplant patients, which is close to that of blood donors (5%) and of the HIV-negative, heterosexual population of Switzerland (7%) where the study was done. Following transplantation the increase of seropositivity to 17% within a year is greater than the number that could be accounted for by transmission through infected grafts. This assumes that the rate of transmission of the virus through the infected donor organ is 100%, that the seroprevalence in the donor population was the same as that in the recipient population and that the presence of HHV-8 antibodies implies both past and present infection (Ho, 1998). Another problem with the study was that serum samples from donor-recipient pairs were not available so that it was not possible to establish more precisely the probability of the transmission of infection through an infected organ to a seronegative subject and perhaps rule out infection from other sources. One would also have been able to determine with greater certainty whether seropositivity always indicated the presence of latent, transmissible infection in the donor graft. In our study we sought to address some of these issues and bring a developing country perspective to the problem. Our findings, interestingly differed from those of Regamey *et al.* (1998) in that we found that reactivation of HHV-8 posed a greater threat for Kaposi's sarcoma development than primary infection from infected donor organs.

Aims

The aims of this investigation were:

1. To establish the HHV-8 antibody serostatus of kidney donor-recipient pairs and determine whether seropositive donor status was associated with seroconversion and subsequent Kaposi's sarcoma development in recipients.
2. To establish the seroprevalence HHV-8 antibodies in various groups of healthy individuals in the Western Cape.
3. To establish the seroprevalence of HHV-8 antibodies in the sexual partners and family members of transplant patients with Kaposi's sarcoma.
4. To establish the role of blood transfusions in HHV-8 seroconversions.

Subjects and Method

SUBJECTS

All consecutive patients receiving renal allografts in our Unit over a three-year period and their donors were tested for the presence of HHV-8 antibodies. Blood was drawn from recipients at the time of transplantation and after six months in all patients transplanted in the first year of the study. The recipients who had received any blood products were identified and every attempt was made to identify the blood donors. Stored blood samples from these donors were then tested. Several categories of control subjects were tested. Healthy blood donors served as the main controls. Specimens were obtained from the Western Province Blood Transfusion Service. The samples were randomly chosen from donors who presented for venesection over the study period. The second control group was the staff members of the Renal Transplant and Dialysis Units of the Tygerberg Hospital. All staff members, both medical and non-medical, who had contact with patients and who were in the employ of the Hospital over the period of the study were included. Family members, residing with renal transplant patients who were previously diagnosed with Kaposi's sarcoma, were also invited to be tested. This part of the investigation was not limited to the current cohort of patients but included all patients who had been diagnosed with Kaposi's sarcoma and whose next-of-kin were still

willing to participate. Transplant patients whose Kaposi's sarcoma had remitted served as positive controls.

SPECIMEN COLLECTION

Aseptically collected patient and control plasma were separated from the red blood cells (within 24 hours of collection) and stored frozen at -40°C until ready for testing. Repeated freezing and thawing was avoided. The seroevidence of HHV-8 was established by determining the presence of antibodies to the virus. Commercial kits, from Advanced Biotechnologies (Columbia, Maryland), were used to screen blood for the antibodies and confirm the results. The HHV-8 IgG antibody enzyme-linked immunosorbant assay (ELISA) was used as the screening test. All positive results were then confirmed by using ELISA for the detection of IgG antibody to HHV-8 latent protein ORF 73.

PRINCIPLE OF THE HHV-8 IgG ANTIBODY ELISA

Primary herpesviral infection generally results in antibody responses, which, although insufficient to prevent establishment of a latent infection, typically remains detectable for the life of the host (Strauss,1995). These antibodies persist during viral latency, when infection is clinically quiescent and viral DNA is confined to a small subpopulation of cells. Thus, the presence of antibodies to herpesvirus sensitively denotes past exposure to the virus and is generally accepted to indicate ongoing latent infection (Kedes *et al.*,1996). Accordingly, several assays for antibodies to viral antigen specific to cells latently infected with HHV-8 have been developed. A HHV-8 whole virus extract has been prepared by Advanced Biotechnologies (Columbia, Maryland), from sucrose gradient purified virus that was isolated from the KS-1 cell line. The virus antigen from the KS-1 cell line was then used for the development of the ELISA kit that measures antibody to the majority of HHV-8 structural proteins. At present the diagnosis of HHV-8 infection can be confirmed by polymerase chain reaction (PCR) analysis and by immunological assays such as immunofluorescence assay (IFA) and ELISA. Even though PCR is sensitive it is expensive and less practical in a clinical setting because there are more chances of contamination. In addition, a low viral load in latency is characteristic of the γ -herpesviridae subfamily and excludes easy detection by PCR

(Verbeek *et al.*,1998). Such difficulties may account for the conflicting results from a number of different laboratories employing PCR-based assays to detect HHV-8 in semen (Ambroziak *et al.*,1995;Lin *et al.*,1995;Monini *et al.*,1996) or skin carcinomas (Adams *et al.*,1995;Boshoff *et al.*,1996;Rady *et al.*,1995). Serological assays for viral antibodies are much better suited to the task of addressing epidemiological problems (Kedes *et al.*,1996). ELISA and IFA immunoassay kits are also useful to follow the course of HHV-8 infection.

ELISA has certain advantages over IFA since it can be automated and a large number of samples can be tested simultaneously. The ELISA for HHV-8 IgG antibody detection is intended for the detection of HHV-8 antibody in human serum or plasma. Plastic microwell strips are sensitized by absorption of optimal amounts of solubilized HHV-8 whole virus extract. The test procedure involves three incubation steps:

1. Test samples at one or multiple dilutions are incubated in the antigen-coated microtitre wells. Any antibody present will bind to the immobilized antigen. The wells are washed to remove unbound sample components.
2. Peroxidase conjugated anti-human IgG (Fc specific) is added to the wells and incubated. The conjugate will bind to the antibody immobilized on the solid phase microtitre wells in Step 1. The wells are washed to remove unreacted conjugate.
3. The microtitre wells containing immobilized peroxidase conjugate are incubated with peroxidase substrate. Enzyme mediated cleavage of the substrate results in a colour change. After a period of time, the reaction is stopped, and the colour intensity of the solution is measured spectrophotometrically. The colour intensity of the solution is proportional to the antibody concentration in the test sample.

Excessively lipaemic or otherwise contaminated samples may give spurious results. Paired serum or plasma samples to demonstrate seroconversion or significant titre increase were collected several months apart, stored, then tested simultaneously.

General Procedure

The kit components were removed from storage and allowed to warm to room temperature (20-25°C). The total number of samples and controls to be tested was determined. The reagent blank occupied one well, the positive control was run in duplicate wells, and the negative control was run in triplicate wells. Samples were run in duplicate. Each blank, control, and sample occupied a separate antigen-coated microwell. After the strips and strip frame had warmed to room temperature, the protective pouch was opened and the antigen-coated assay plate removed. The wash buffer was prepared by diluting one vial of 20X (25 ml) concentrate to 500 ml by adding 475 ml distilled or deionized water and mixing well. The 4X specimen diluent was prepared by diluting the vial of 4X (25 ml) concentrate to 100ml by adding 75 ml distilled or deionized water and mixing well.

All samples and controls were prediluted in 1.0 ml microtitre microtubes before addition to the antigen-coated plate. The tubes were held in a rack that had the configuration and dimensions of the microtitre plate to facilitate compatibility with a multichannel transfer pipette. The rack of dilution tubes was loaded in the same sample pattern that was used in the antigen-coated plate. Volumes of 10 μ l of positive control (in duplicate), negative control (in triplicate), and samples to be tested were added to separate tubes of the dilution tray. Sample diluent (1000 μ l) were added to each well containing a control or sample to give a 1:101 dilution. The same volume (1000 μ l) of sample diluent was added to the reagent blank well.

Using a multichannel pipette, 100 μ l of each diluted blank, control, or sample was transferred to the antigen-coated plate. To ensure proper mixing the samples were withdrawn and expelled ten times before the final transfer. A different tip was used for each sample. The strips were sealed with the adhesive plate sealer and incubated at 37°C for 30 minutes.

The samples were shaken out into a container appropriate for decontamination. Using a squirt bottle, each well was gently filled with wash buffer. Care was taken to ensure that no air bubbles were trapped in the wells. This process was repeated twice more. The well contents were then shaken out and firmly tapped on a paper

towel to remove residual wash buffer. The plate was visually inspected and tapped again if necessary.

One hundred microlitres of the anti-human IgG (γ)-horseradish peroxidase (HRP) conjugate was added to each well. The strips were sealed with the adhesive plate sealer and incubated at 37°C for 30 minutes. The plate was washed as before. One hundred microlitres of the HRP substrate (TMB) solution were added to each well and incubated at room temperature (20-25°C) for thirty minutes (± 5 minutes) in the dark. One hundred microlitres of stop reagent was then added to each well. Positive samples turned from blue to yellow. Optical densities were measured within thirty minutes. The microplate reader was set to read at a wavelength of 450 nm. The instrument was blanked on the reagent blank well and the optical density of all wells measured.

Measurement of Optical Densities for HHV-8 IgG Antibody ELISA

As per manufacturer's recommendation, the readings of the three negative control wells were averaged and the result multiplied by 3.0 to obtain the cutoff value. The optical density (OD) ratios were calculated by dividing the reading of each sample well by the cutoff value. Each OD ratio was interpreted as follows:

	OD Ratio
Negative Samples	≤ 0.75
Positive Samples	≥ 1.00
Equivocal (borderline)	0.76 – 0.99

All positive results were confirmed using the ELISA for the detection of IgG antibody to HHV-8 latent protein ORF 73.

PRINCIPLE OF THE HHV-8 LATENT PROTEIN ORF 73 ELISA

Advanced Biotechnologies Incorporation's ELISA for human herpesvirus 8 (HHV-8) ORF 73 IgG Antibody detection is intended for the detection of HHV-8 latent IgG antibody in human serum or plasma. ORF 73, also known as Latent Nuclear Antigen-1 (LANA-1), is a latent nuclear protein that is analogous to the nuclear antigen EBNA in EBV (Antman *et al.*,2000; Boshoff *et al.*,1998; Schulz,1998; Schulz,1998c; Whitby *et al.*,1998a). Although the function of the protein is unknown,

a role has been suggested in cellular transformation and eliciting humoral and cellular immunity (Boshoff *et al.*,1998; Schulz,1998c; Whitby *et al.*,1998a). ORF 73 is immunogenic and is expressed during latency together with viral cyclin and viral FLICE¹ inhibitory protein (FLIP). It is expressed in almost all spindle cells in Kaposi's sarcoma lesions and in cell lines from primary effusion lymphoma (Antman *et al.*,2000; Boshoff *et al.*,1998; Dupin *et al.*,1999; Kellam *et al.*,1999; Schulz,1998; Schulz,1998c; Whitby *et al.*,1998a). Antibody to HHV-8 encoded ORF 73 latent antigen is detectable in plasma and can be used to assess individuals at risk for developing HHV-8 associated malignancies (Antman *et al.*,2000; Boshoff *et al.*,1998; Schulz,1998; Schulz,1998c; Whitby *et al.*,1998a). The IFA has been widely used by researchers throughout the world to assess latent infection in patients. Although informative, the present LANA-IFA for latent HHV-8 antibody detection requires a trained technologist to perform and interpret the results. It is also a subjective test. Moreover, auto-antibody and non-specific reactivity may also hinder the interpretation of the results. The LANA-IFA is amenable to small numbers of samples but for large samples that are required for epidemiological studies the LANA-IFA is impractical. The ELISA-based test was developed using purified full-length recombinant HHV-8 ORF 73 protein for the detection of HHV-8 latent IgG antibodies as an indicator of latent infection. When used with the HHV-8 whole virus lytic ELISA the manufacturers expect that all HHV-8 positive samples will be detected (Advanced Biotechnologies Inc., 2001). Wells of plastic microwell strips are coated with optimal amounts of purified HHV-8 ORF 73 recombinant protein. The test procedure involves the same steps as described above for the HHV-8 IgG Antibody ELISA.

Measurement of Optical Densities for HHV-8 Latent Protein ORF 73 ELISA

The microplate reader was set to read at a wavelength of 450 nm. The instrument was blanked on the reagent blank well and the optical density (O.D.) of all wells was measured. The results were interpreted as follows (O.D. cut-off was 0.17):

	O.D. Value
Negative Samples	< 0.17
Positive Samples	≥ 0.17

¹ FLICE is Fas-associated death domain protein (FADD) interleukin-1beta-converting enzyme.

Table 17-1. The prevalence of antibodies against HHV-8 in healthy control subjects and dialysis patients at the time of renal transplantation.

Subjects	Total No.	HHV-8 Antibody Positive (%)
Organ Donors ¹	94	6 (6.4)
Transplant Recipients (Pretransplant)	113	10 (8.8)
Blood Donors	66	4 (6.1)
Renal Unit Staff	45	2 (4.4)
Transplant Recipients (Interval) ²	32	7 (21.9)
Blood Donors of HHV-8 ⁺ patients	118	0
Kaposi's sarcoma patients (Remitted)	11	11 (100)

¹ All these donors had recipients who were matched for the presence of anti-HHV-8 antibodies.

² Tested at least 6 months after transplantation.

Limitations

False positive results may be obtained if samples are excessively lipaemic or heavily contaminated with bacteria. Lipaemic samples may be extracted with silica or freon without affecting antibody reactivity. *False positive results* may also be obtained through improper washing. *False negative results* may be obtained if samples are not stored properly after collection. High levels of circulating antigen in the patient sample can neutralize antibodies that may be present and cause false negative results.

STATISTICAL ANALYSIS

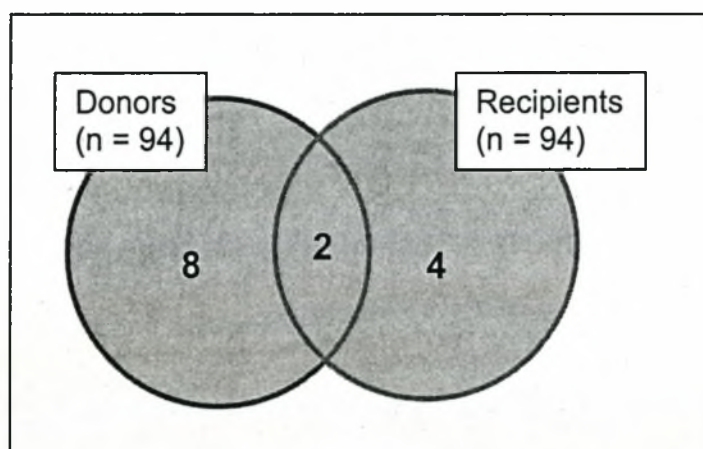
Differences were analysed using Fisher's exact test (2-tailed). Significance was set at 5%. Statistical analysis was performed using the software package Statistica for Windows, (Release 5.5, 2000; Stat Soft Inc, Tulsa, OK).

Results

CONTROLS AND DIALYSIS PATIENTS

The results of the serological studies are summarised in Table 17-1. The HHV-8 ORF 73 ELISA confirmed the screening results. The prevalence of HHV-8 in our healthy population is low and comparable to that reported from the USA and UK, but considerably lower than that reported from elsewhere in Africa and Italy, which are areas associated with high prevalence of Kaposi's sarcoma albeit of different forms of the disease.

Fig. 17-2 *The seropositive HHV-8 antibody status of donor-recipient pairs.*



Two seropositive recipients received organs from seropositive donors. One of these patients developed Kaposi's sarcoma.

In the study period 113 patients with end-stage renal failure received allografts. Of these 10 had antibodies to HHV-8. There were 94 donor-recipient pairs of whom the HHV-8 serostatus was known (Fig. 17-2). In 19 patients the serostatus of the donor could not be established because the organ had been imported from elsewhere but none of the patients receiving organs from this group of donors were seropositive or seroconverted. All 10 seropositive recipients were from the donor-matched group. A total of 3 patients in this cohort of 94 matched pairs developed Kaposi's sarcoma (Table 17-2). Of these 2 received organs from HHV-8 positive donors while in one

Table 17-2. Details of the Kaposi's sarcoma patients according to HHV-8 antibody status of donor - recipient pairs (n = 94).

	Patient	Donor	Latency (mo.)
Patient RB	+	+	13.3
Patient DI	+	-	10.6
Patient ML	-	-	31.5

the donor was negative. However, the one patient who received a graft from a positive donor also had HHV-8 antibodies at the time of the transplant. Of the 94 donor-recipient pairs, in whom the HHV-8 antibody status was known at transplantation 2 (20%) of the 10 HHV-8 positive patients developed Kaposi's sarcoma, compared to only one of the 84 (1.2%) who were negative. This difference was statistically significant ($P = 0.02$, Fisher's exact, 2-tailed). Three patients developed Kaposi's sarcoma (Table 17-3). The patient who was HHV-8 antibody negative and whose donor also tested negative, seroconverted 4 months after transplantation and developed Kaposi's sarcoma 32 months after the transplant. The last HHV-8 positive patient to be diagnosed has been followed-up for almost 3 years and remains free of Kaposi's sarcoma. All patients have been followed-up for a minimum of two years. The second patient who had HHV-8 antibodies and received a graft from a HHV-8 positive donor, remains free of Kaposi's sarcoma, more than 3 years after transplantation (Table 17-4).

Table 17-3. Summary of the HHV-8 status of donor-recipient pairs.

Pairs (n=94)	No. (%)	Kaposi's sarcoma
Donor+ Recipient +	2 (2.1)	1
Donor- Recipient +	8 (8.5)	1
Donor+ Recipient -	4 (4.2)	0
Donor- Recipient -	80 (85)	1

Table 17-4. *The outcome of patients who received renal allografts from HHV-8 seropositive donors.*

Patient	Outcome	Period (mo.)
RB ¹	Kaposi's sarcoma	32
AF	Death	16
JP	Death	2
ES	HHV-8 neg.	7
CM	HHV-8 neg	23
CW ¹	HHV-8 neg	13

¹Patients also had HHV-8 antibodies at transplantation

Blood donors (For HHV-8 seropositive recipients) (Table 17-1)

The blood samples of 118 subjects who had donated blood that was used in one form or another in any of the HHV-8 seropositive patients, including those with Kaposi's sarcoma, were traced and tested for HHV-8 antibodies. Twenty donor-samples of which 13 were donations to one patient, could not be traced. All the recent blood samples could be traced and the only ones that were missing were from the early part of the last decade. None of the blood donors tested positive.

Relatives and Household Members (Table 17-5)

The response to our request for consorts and family members, resident in the same household as patients diagnosed with Kaposi's sarcoma, to present themselves for testing, resulted in a response from only 14 households. Despite the small response some interesting patterns were revealed that should be confirmed with follow-up studies. From Table 17-5 it is evident that 4 of 14 (28.6%) Kaposi's sarcoma patients had at least one family member/spouse who had anti-HHV-8 antibodies. Of 23 family members tested 4 (16.6%) had anti-HHV-8 antibodies. Of 9 sexual partners tested only one had anti-HHV-8 antibodies (11%). As controls, the family members of other transplant patients free of Kaposi's sarcoma were requested to submit for anti-HHV-8 serotesting and 13 families responded. A total of 22 healthy subjects with a similar spectrum of family members as the study group were tested. None had anti-HHV-8 antibodies. The difference in the seroprevalence between the

Table 17-5. Anti-HHV-8 seroprevalence in family members of patients with Kaposi's sarcoma.

Patient	Spouse	Offspring	Other
WB	0	0	+ ²
WC	-	+	0
LJ	0	+/-	0
IM	-	0	0
KM	-	-	0
GN	0	-/-	0
MO	+	0	0
GO	-	-	0
RT	-	-	0
RB	0	-	- ³
JM	-	0	0
SG	-	0	0
DI	-	-	- ²
ML	0	-/-	0

¹ P= 0.1 compared to controls (Fisher's exact, 2-tailed)

² Mother; ³ Brother

Kaposi's sarcoma and non-Kaposi's sarcoma families, however, was not significant (P = 0.1, Fisher's exact, 2-tailed).

Racial and gender differences

Of the 66 random blood donors supplied by the blood bank, 4 had antibodies to HHV-8. All the subjects were black and all were male. None of the 19 white or coloured blood donors were seropositive. With regard to the renal patients there was no gender difference in the distribution of the viral antibodies, although one other study has reported that women have a higher incidence of HHV-8 antibodies (Sheldon *et al.*,2000). However, none of the 24 white patients in our transplant

cohort had anti-HHV-8 antibodies compared to 10 (11%) of the 90 non-white patients. The difference was however, not statistically significant.

Discussion

The herpesviruses are the largest group of viruses than can be transmitted through transplanted organs. All herpesviruses remain latent in some tissue after infection. The herpes simplex viruses, HHV-1 and HHV-2, are latent in trigeminal ganglia and lumbosacral dorsal-root ganglia. Therefore, transmission through transplanted kidneys is unusual and occurs only if the graft is inapparently infected (Ho *et al.*,1995). Varicella-zoster virus (HHV-3) is latent in neural ganglia and hence is not transmitted through transplantation of other tissues and organs. Cytomegalovirus (CMV) (HHV-5) on the other hand is readily transmitted by the transplanted organ and is one of the main viral infections to affect recipients (Ho *et al.*,1975). The case of CMV is paralleled by that of EBV, (HHV-4), which is essential for the development of posttransplantation lymphoproliferative disorder. Children are at greatest risk of posttransplantation lymphoproliferative disorder because primary infection is the most important risk factor (see Chapter 13). The situation with regards to the transmission of HHV-6 and HHV-7 through transplantation still has to be clarified. There is currently no proof of transmission by this means and the specific effects of infection in transplant recipients are difficult to assess (Herbein *et al.*,1996). Although there is overwhelming support for its aetiological role in Kaposi's sarcoma of all types, there is still uncertainty as to the epidemiology of HHV-8 and the manner in which is transmitted. There are no studies of the epidemiology of the virus in renal transplant recipients in South Africa, or in the Western Cape population that we serve. More importantly, this is one of the first studies to compare donor-recipient pairs with regard to the HHV-8. This was one of the major defects of the study reported by Regamey *et al.* (1998) (*vide supra*).

DONOR-RECIPIENT RENAL TRANSPLANTS

Organ unlikely source of infection

Our results show that the prevalence of HHV-8 antibodies in renal patients before transplantation is 8.8%, which is very close to the 6.4% in the organ donor

population. Three patients in our cohort developed Kaposi's sarcoma. Although all 3 patients had HHV-8 antibodies at the time that Kaposi's sarcoma developed, the donor was the potential source of the virus in one case only. In the other two cases the patients had previously been exposed to the virus. Also important, was our finding of one patient who had no antibodies to HHV-8 at the time of the transplant, and whose donor was also seronegative, who subsequently seroconverted and developed Kaposi's sarcoma. This finding contradicts that of Regamaney *et al.* (1998) and Francès *et al.* (2000) who both found that no patients who were initially negative and whose donors were also negative, seroconverted. In fact, we tested the serostatus of 30 seronegative control patients at least 6 months after transplantation. Of these 5 (20%) developed HHV-8 antibodies but none had received a graft from a seropositive donor. Regamaney *et al.* (1998) also found, in contrast to our own findings that, the only two patients who developed Kaposi's sarcoma had been seronegative and had received grafts from seropositive patients. In our cohort, 2 patients in whom Kaposi's sarcoma developed were seropositive *before* transplantation.

The other evidence that Regamey *et al.* (1998) quote for suggesting that the donor kidney is the source of the virus is the fact that of the six patients who seroconverted, five of the donors were positive although it does not appear that the donors and recipients were paired as was the case in our patients. Another observation that is used to support their argument is that the number of seropositive patients increased from 6.4% to 17.7%. In our own cohort there was also an increase in HHV-8 seropositivity from 8.8% to 22%, but none of four seroconversions (the serostatus of one donor could not be established) occurred in patients who had received grafts from seropositive patients. This implies that the virus was acquired from sources other than the graft. Alternatively, false negative results could have been obtained if the HHV-8 seroassay had inadequate sensitivity to detect persistent but low-level antibodies in certain patients. The use of immunosuppression may allow the latent virus to become reactivated and for antibodies to develop as has been suggested previously (Francès *et al.*, 1999). Further studies are clearly necessary to clarify these issues. Admittedly, although we confirmed all our positive results using a second generation ELISA to detect antibodies to the latent nuclear antigen of HHV-8, the negative results were not. However, the fact that all our remitted Kaposi's

sarcoma patients tested positive suggests that the tests had to have sensitivity in excess of 90%. Of the 4 seronegative recipients of grafts from seropositive donors, neither of the 2 survivors seroconverted (Table 17-5). This confirms the observation of others that infection is not an inescapable result of transplantation from a positive donor. This is similar to the observation in HIV-positive patients who also do not all develop Kaposi's sarcoma after infection by the HHV-8 (Verbeek *et al.*,1998).

The other possible source of infection could have been blood transfusions administered perioperatively. However, of all the blood donors whose blood products had been used in the treatment of seropositive patients none had anti-HHV-8 antibodies. Part of the explanation for the low infectivity of the blood is that we used predominantly white-cell poor red cell concentrate to transfuse patients.

Nonsexual Transmission

In the absence of sexual or parenteral transmission, other nonsexual modes of spread of the virus have to be considered. Cattani *et al.* (1999) used viral DNA amplification to investigate the possibility that a nonsexual transmission route was involved in the spread of infection and found HHV-8 DNA in almost one-half of the saliva and tonsillar swabs of Kaposi's sarcoma patients (Cattani *et al.*,1999). They suggested that HHV-8 replicates in tonsils and then sheds into saliva, which could contribute to HHV-8 transmission. This is supported by the earlier findings of LaDuca *et al.* (1998) who detected HHV-8 DNA sequences in several body fluids of patients with Kaposi's sarcoma but concluded that the saliva was more important than semen or stool in transmission of the virus (LaDuca *et al.*,1998). HHV-8 DNA has also been detected in saliva of patients without Kaposi's sarcoma but who are HIV positive, but not from healthy controls (Blackbourn *et al.*,1998;Koelle *et al.*,1997;Lucht *et al.*,1998). It is possible that immunosuppression due to HIV, malnutrition or other severe illness, increases shedding of HHV-8 in saliva and thus makes viral transmission via saliva more common in Africa (Schatz *et al.*,1997). Our study was not designed to test salivary spread, but in view of our finding that neither the graft nor the transfusion of blood / blood products appear to contribute to HHV-8 infection in renal transplant patients; this is an avenue for future investigation. The immunosuppressed status of these patients may enhance their susceptibility to infection from persons shedding the virus.

We have shown a higher prevalence of anti-HHV-8 antibodies in the family members of patients with Kaposi's sarcoma. In a survey from Sardinia, data were presented that also showed a high prevalence of HHV-8 infection in relatives of patients with Kaposi's sarcoma, suggesting intrafamilial person-to-person or vertical transmission of the virus (Angeloni *et al.*,1998).

HHV-8 in children

The situation of anti-HHV-8 antibodies in children is interesting and holds clues to establishing the spread of the virus. It has been shown that the prevalence of anti-HHV-8 antibodies increases progressively with age (Enbom *et al.*,1999;Gessain *et al.*,1999;Huang *et al.*,2000). In Taiwan the prevalence of anti-HHV-8 antibodies peaks at between 10 and 40 years of age. This suggests that the infection, at least in Taiwan, is sexually spread (Huang *et al.*,2000). However, in reports from Egypt and Uganda, the seroprevalence peaked in children aged 1 to 3 years old, suggesting that in developing countries HHV-8 infection may be acquired early in life through routes other than sexual transmission (Andreoni *et al.*,1999).

Reactivation vs. Primary infection

Our data suggest that Kaposi's sarcoma in immunosuppressed renal transplant patients is associated with reactivation of latent HHV-8 rather than primary HHV-8 infection. Similar results were reported by Parravicini *et al.* (1997b) who found that 10 of 11 Italian renal-transplant recipients with Kaposi's sarcoma had had a positive serologic test for HHV-8 before transplantation. A French group came to a similar conclusion. They found that 4 of 12 (33.3%) patients who were seropositive before transplantation developed Kaposi's sarcoma but Kaposi's sarcoma did not occur in any of the patients who were seronegative (Frances *et al.*,1999). Combined with our own results, there is mounting evidence that in HHV-8 endemic areas posttransplant Kaposi's sarcoma occurs in individuals who are HHV-8 infected before transplantation (Farge *et al.*,1999;Parravicini *et al.*,1997b;Sheldon *et al.*,2000). Since the seropositive patients showed no clinical manifestations of Kaposi's sarcoma until after receiving immunosuppressive treatment, our hypothesis that immunosuppression is another important factor in the pathogenesis of the disease, is further strengthened.

Table 17-6. The seroprevalence of HHV-8 in different normal subjects from a range of regions.

Country/ Region	Subjects	No.	HHV-8 ⁺ (%)	Test	Reference
<i>Europe</i>					
Belgium	Blood donors	210	7(3.3)	ELISA	Sheldon <i>et al.</i> ,2000
UK	Blood donors	150	4 (3%)	IFA ¹	Simpson <i>et al.</i> ,1996
Italy	Blood donors	107	4 (4)	Immunoblot	Gao <i>et al.</i> ,1996b
Italy	Blood donors	747	103 (14)	IFA	Whitby <i>et al.</i> ,1998b
France	Pregnant women	50	1 (2)	IFA	Couty <i>et al.</i> ,1999
France	Blood donors	50	1 (2)	IFA	Couty <i>et al.</i> ,1999
France	HIVKS ⁻	45	1 (2.2)	PCR	Belec <i>et al.</i> ,1998
<i>North America</i>					
USA	Blood donors	117	0	IFA	Simpson <i>et al.</i> ,1996
USA	Gen. public	437	0	IFA	Lennette <i>et al.</i> ,1996
N. America	Blood donors	122	0	Immunoblot	Gao <i>et al.</i> ,1996b
<i>Africa</i>					
RSA	Blood donors	66	4 (6.3)	ELISA	Present study
RSA	Black Blood Donors	85	17 (20)	IFA	Sitas <i>et al.</i> ,1999
Uganda	HIVKS ⁻	47	29 (62)	Immunoblot	Gao <i>et al.</i> ,1996b
Central	Blood donors	49	11 (23)	PCR	Belec <i>et al.</i> ,1998
<i>Africa</i>					
Eritrea	Pregnant women	112	6 (5)	IFA	Enbom <i>et al.</i> ,1999
Cameroon	Children	258	71 (28)	IFA	Gessain <i>et al.</i> ,1999
Cameroon	Pregnant	189	103 (54)	IFA	Gessain <i>et al.</i> ,1999
Nigeria	HIVKS ⁻	52	3 (6)	IFA	Lennette <i>et al.</i> ,1996
Zaire	HIVKS ⁻	16	13 (82)	IFA	Lennette <i>et al.</i> ,1996
Egypt	Children	246	21 (9)	IFA	Andreoni <i>et al.</i> ,1999
<i>Latin America/Asia</i>					
Haiti	HIVKS ⁻	52	15 (29)	IFA	Lennette <i>et al.</i> ,1996
Dominican	HIVKS ⁻	40	5 (13)	IFA	Lennette <i>et al.</i> ,1996
Guatemala	HIVKS ⁻	20	2 (10)	IFA	Lennette <i>et al.</i> ,1996
Brazil	Blood donors	81	6 (7.4)	IFA	Caterino-de-Araujo <i>et al.</i> ,1999
Honduras	Blood donors	96	10(10.4)	IFA	Sosa <i>et al.</i> ,1998
Taiwan	Spectrum	1201	141 (11)	IFA	Huang <i>et al.</i> ,2000

¹ Antibodies to HHV-8 latent antigen.

HUMAN HERPESVIRUS 8 IN HEALTHY SUBJECTS

The prevalence of HHV-8 infection differs in different geographical settings (Table 17-6). Comparisons of different methods for the detection of anti-HHV-8 antibodies show relatively good, though incomplete agreement, regarding anti-latent antibodies but poor agreement for antibodies to lytic antigen (Rabkin *et al.*, 1998); there is also evidence that anti-latent antibodies represent a better predictor of Kaposi's sarcoma development (Rezza *et al.*, 1998). Therefore, only the antibodies to latent antigen are reported here. The most striking difference seems to be between developed countries and developing countries, with a low prevalence in the former (Gao *et al.*, 1996b; Lennette *et al.*, 1996; Simpson *et al.*, 1996) and higher prevalence in countries such as Central Africa and Uganda (Gao *et al.*, 1996b). It has been suggested that the mode of transmission of the virus differs. In industrialised countries, HHV-8 infection is likely to be acquired after adolescence, during the sexually active phase of life (Kedes *et al.*, 1996; Lennette *et al.*, 1996; Martin *et al.*, 1998a). In developing countries the infection appears to be acquired early in life as a possible consequence of transmission in the family and in community settings (Andreoni *et al.*, 1999; Gessain *et al.*, 1999). Such differences in the age at primary infection suggest a different route of HHV-8 acquisition for individuals in different geographic and/or socioeconomic conditions. This recalls the EBV situation (de-Thé *et al.*, 1978a; Niederman *et al.*, 1997), although in Africa it appears that children acquire EBV at a much earlier age than HHV-8. In Ghana, for example 80% of children have acquired EBV antibodies by the age of 21 months (Niederman *et al.*, 1997) and in Uganda 100% by the age of six years (de-Thé *et al.*, 1978a). However, nonsexual transmission of HHV-8 may play an important role only when particular environmental factors prevail; these would include the presence of overcrowding and poor hygiene and primarily in areas where the background HHV-8 prevalence is high (Andreoni *et al.*, 1999; Gessain *et al.*, 1999). It is therefore possible that the impact of specific transmission modalities may vary across different geocultural and socioeconomic contexts. This is supported to some extent by our own observation that in both our blood donor and renal recipient populations anti-HHV-8 antibodies occurred exclusively in non-white patients. In our white and non-white subjects from the same geographical region, the prevalence of the anti-HHV-8

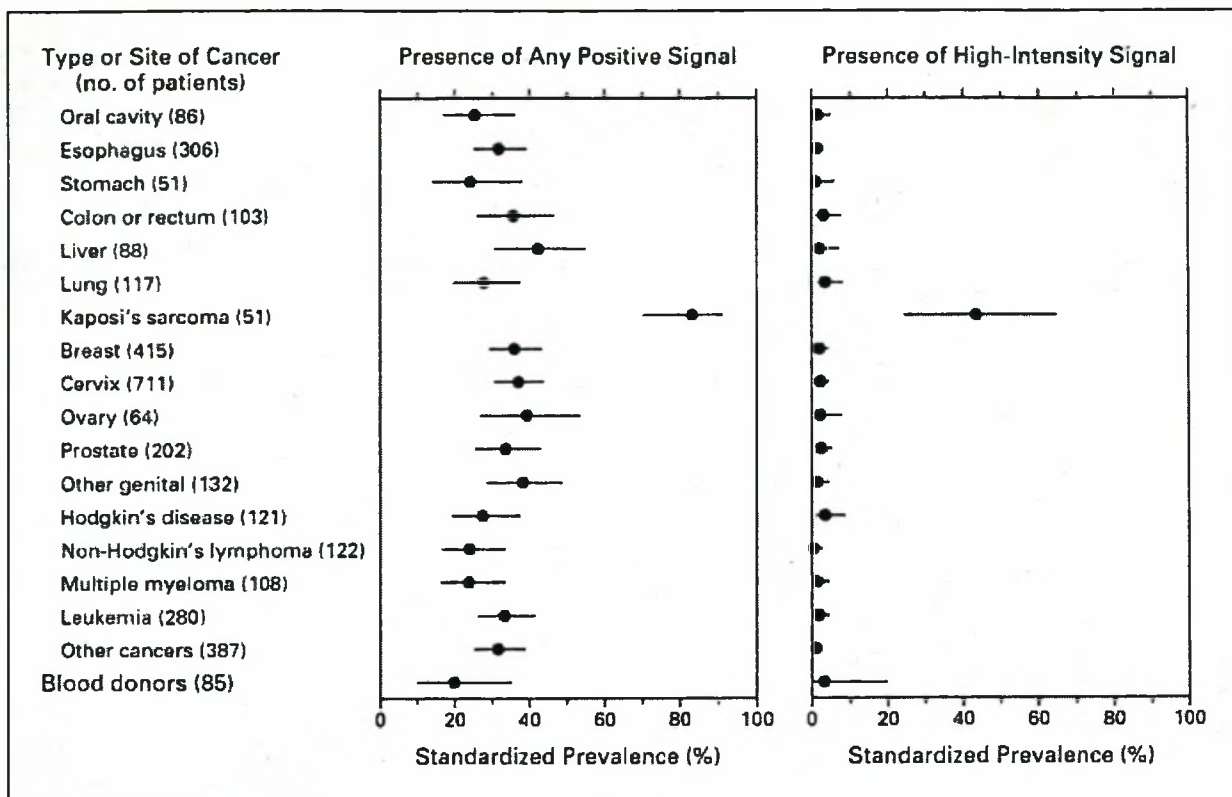


Fig. 17-3 The prevalence of HHV-8 antibodies among 3344 Black South African cancer patients and Black blood donors. Only patients with Kaposi's sarcoma had a significantly higher seroprevalence. From Sitas *et al.* (1999).

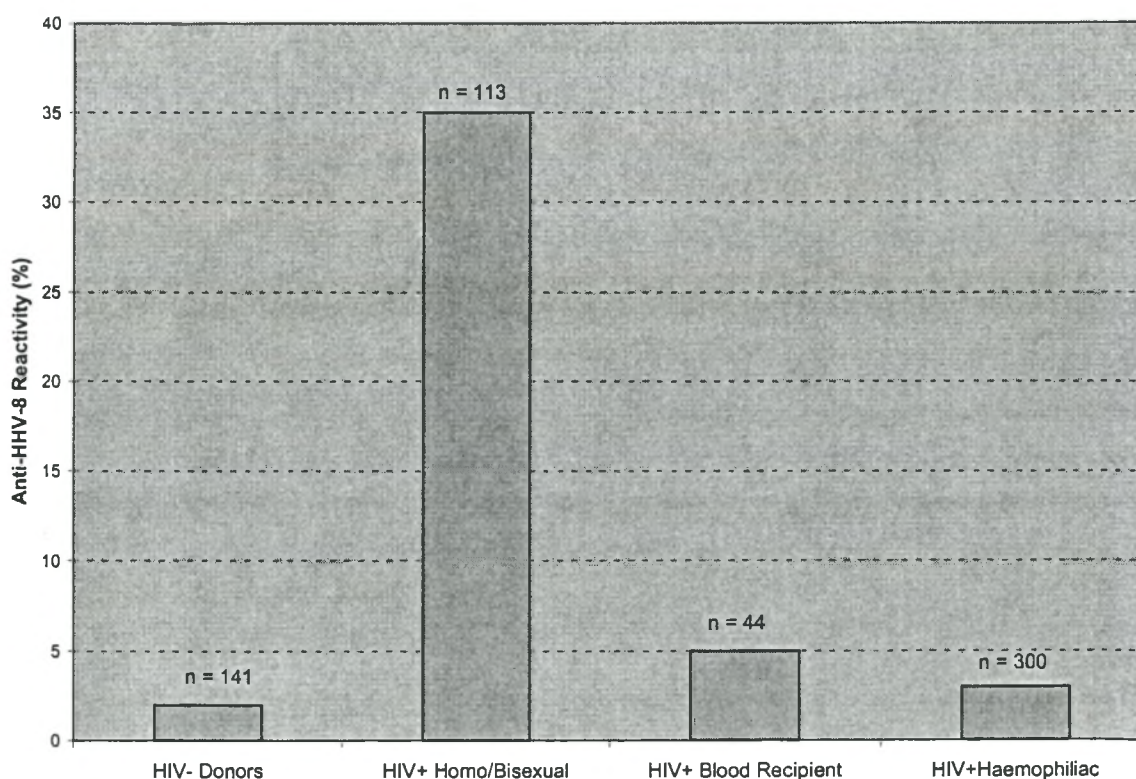
antibodies varies and corresponds with the incidence of Kaposi's sarcoma in our transplant population.

South African Situation

Our own experience with HHV-8 in healthy individuals is comparable to that of developed countries which report prevalence rates ranging from less than 5% (Sheldon *et al.*,2000) to 28% (Chang *et al.*,1996a;Gao *et al.*,1996b;Kedes *et al.*,1997;Lennette *et al.*,1996;Levy,1997;Luppi *et al.*,1996;Miller *et al.*,1996;Simpson *et al.*,1996). Sitas *et al.* (1999) in an extensive survey of black South African cancer patients, found that 32% had anti-HHV-8 antibodies; this was similar to the standardised prevalence among black blood donors (Fig. 17-3) (Sitas *et al.*,1999). The seroprevalence increased progressively with age and the number of sexual partners. Anti-HHV-8 antibodies were more prevalent in black than white blood donors and this corresponds to our own experience with seropositivity occurring

exclusively in non-white patients. The high seroprevalence of anti-HHV-8 antibodies in the black patients was associated with a high prevalence of endemic Kaposi's sarcoma in the Johannesburg experience (Sitas *et al.*,1999). Although HHV-8 has been implicated in multiple myeloma (Rettig *et al.*,1997), and prostate cancer (Staskus *et al.*,1997) these reports have not been confirmed (Masood *et al.*,1997;Munker *et al.*,1997;Parravicini *et al.*,1997a;Whitby *et al.*,1997). The South African study found an association only with Kaposi's sarcoma and no other tumour occurring in black patients. In our study, the prevalence of HHV-8 was considerably lower than that reported among patients from Gauteng. If we combine all our healthy controls subjects the overall seroprevalence is 5.2% (8% if we exclude the donor-specific blood donors). The main explanation for this is the difference in the racial mix of the population in the Western Cape compared to Gauteng. In the white blood donors the prevalence was also 5% in the north. None of our white blood donors tested positive but the number was too small to allow comparison between the races.

Fig. 17-4 HHV-8 antibodies in selected Kaposi's sarcoma risk groups



Modified from Kedes *et al.* (1996)

Our serological data therefore indicate that, unlike most herpesvirus infections, HHV-8 infection is not ubiquitous in man, a finding supported by others (Gao *et al.*,1996b;Strauss,1995). Indeed, HHV-8 seropositivity is limited to a rather small proportion of the population. Populations at risk of HHV-8 infection are those exposed to sexually transmitted diseases like syphilis and HIV (Kedes *et al.*,1996).

HIV and HHV-8 (Fig. 17-4)

A strong association exists between HHV-8 seropositivity and HIV infection. The most important observation however, is that not all HIV-positive patients are equally at risk. Homosexual patients are much more likely to have HHV-8 antibodies than patients who acquired HIV infection parenterally through the use of clotting factor concentrates or other blood products (Kedes *et al.*,1996). Thus, HIV infection *per se* is not always associated with a high risk of developing HHV-8; this suggests that the higher rates of HHV-8 infection in other HIV-positive cohorts is not simply due to the immunodeficiency produced by HIV but also reflects their sexual activity (Kedes *et al.*,1996). The low rate of HHV-8 infection in HIV positive haemophiliacs and transfusion recipients correlates strikingly with the low risk of Kaposi's sarcoma that has been documented in these groups. The estimates of Kaposi's sarcoma in haemophiliacs and transfusion recipients is 1-3% (Beral,1991), a range strikingly close to the prevalence of HHV-8 antibodies that have been observed in these patients (Fig. 17-4). Similarly, the risk of Kaposi's sarcoma in homosexual men with AIDS is 15-30% (Beral *et al.*,1990;Beral,1991), a number in the same general range as the 35% seroprevalence that has been observed (Kedes *et al.*,1996). Infection rates among homosexual men have remained relatively constant and unlike other viral cancers (such as hepatocellular cancer) the risk of getting Kaposi's sarcoma after HHV-8 infection may be less dependent on duration of infection (Gao *et al.*,1996b;Verbeek *et al.*,1998). One explanation for this is that the expression of Kaposi's sarcoma is tightly regulated by host immunity among persons infected with HHV-8. Thus the risk of developing Kaposi's sarcoma is largely dependent on immunologic integrity in those who are infected with the virus regardless of the length of time of their infection.

Racial/Geographic variations in the distribution of anti-HHV-8 antibodies.

The South African experience including our own seems to indicate that there is a racial discrepancy in the distribution of HHV-8 serologically in normal subjects in the same geographical region with white subjects having a much lower prevalence of the virus compared to black donors (Sitas *et al.*,1999). A recent Belgian study found a higher incidence in patients from endemic areas (Sheldon *et al.*,2000). Sheldon *et al.* (2000) reported that renal transplant patients who originated from the Mediterranean region of the European Community had a significantly higher rate of anti-HHV-8 antibodies than local patients (15% vs. 5%). In a comparison between Americans, Italians, and Ugandans it was found that the latter had the highest prevalence of anti-HHV-8 antibodies (62%) among HIV-negative patients without Kaposi's sarcoma (Gao *et al.*,1996b). None of the American blood donors and only 4% of the Italian donors had anti-HHV-8 antibodies. A recent study from Italy, a region known for endemic Kaposi's sarcoma, observed that most patients with posttransplant Kaposi's sarcoma were already infected with HHV-8 before the engraftment (Parravicini *et al.*,1997b). Further studies have confirmed racial/geographic differences.

SUMMARY

The development of Kaposi's sarcoma appears to be the result of reactivation of latent HHV-8 virus rather than primary infection from a donor graft or peri-operative blood transfusion. The transplant of a graft from a seropositive donor does not invariably result in primary infection in the recipient. The high number of seroconversions after transplantation, in the absence of evidence of parenteral or graft organ spread, suggests that nonsexual spread of the virus occurs. Candidate routes in adults are most likely salivary and faecal-oral.

All the patients who developed Kaposi's sarcoma were known to have HHV-8 antibodies *prior* to the development of the disease. The important corollary to this observation is that HHV-8 is not a consequence of Kaposi's sarcoma as has been suggested by Roizman (1995), and it almost certainly is a vital aetiological factor.

There is a great deal of variation in the prevalence of HHV-8 geographically and/or along socioeconomic lines. The higher prevalence in poorer communities including our own, and in developing countries suggests that conditions prevailing in these circumstances facilitate the spread of the virus. However, the variation in the prevalence of anti-HHV-8 antibodies may be influenced by technical factors such as the poor sampling methods, different levels of test sensitivity and the lack of a standard HHV-8 antibody assay. However, the unique epidemiology of Kaposi's sarcoma seems to support the hypothesis that the cause of Kaposi's sarcoma is multifactorial and that one of the cofactors (essential or at least enhancing) is HHV-8 which predisposes immunosuppressed renal transplant patients to Kaposi's sarcoma.

LITERATURE CITED

- Adams, V., Kempf, W., Schmid, M., Muller, B., Briner, J., and Burg, G. (1995). Absence of herpesvirus-like DNA sequences in skin cancers of non-immunosuppressed patients. *Lancet*. **346**, 1715.
- Ambroziak, J. A., Blackburn, D. J., Herndier, B. G., *et al.* (1995). Herpes-like sequences in HIV-infected and uninfected Kaposi's sarcoma patients [letter; comment]. *Science*. **268**, 582.
- Andreoni, M., El Sawaf, G., Rezza, G., *et al.* (1999). High seroprevalence of antibodies to human herpesvirus-8 in Egyptian children: evidence of nonsexual transmission. *J.Natl.Cancer Inst.* **91**, 465.
- Angeloni, A., Heston, L., Uccini, S., *et al.* (1998). High prevalence of antibodies to human herpesvirus 8 in relatives of patients with classic Kaposi's sarcoma from Sardinia. *J.Infect.Dis.* **177**, 1715.
- Antman, K. and Chang, Y. (2000). Kaposi's sarcoma. *N Engl J Med.* **342**, 1027.
- Belec, L., Cancre, N., Hallouin, M. C., Morvan, J., Si, Mohamed A., and Gresenguet, G. (1998). High prevalence in Central Africa of blood donors who are potentially infectious for human herpesvirus 8. *Transfusion.* **38**, 771.
- Beral, V. (1991). Epidemiology of Kaposi's sarcoma [published erratum appears in *Cancer Surv* 1992;**12**: 225]. *Cancer Surv.* **10**, 5.

- Beral, V., Peterman, T. A., Berkelman, R. L., and Jaffe, H. W. (1990). Kaposi's sarcoma among persons with AIDS: a sexually transmitted infection? *Lancet*. **335**, 123.
- Bigoni, B., Dolcetti, R., de Lellis, L., *et al.* (1996). Human herpesvirus 8 is present in the lymphoid system of healthy persons and can reactivate in the course of AIDS. *J.Infect.Dis.* **173**, 542.
- Blackbourn, D. J., Lennette, E. T., Ambroziak, J., Mourich, D. V., and Levy, J. A. (1998). Human herpesvirus 8 detection in nasal secretions and saliva. *J.Infect.Dis.* **177**, 213.
- Blackbourn, D. J. and Levy, J. A. (1997). Human herpesvirus 8 in semen and prostate. *AIDS*. **11**, 249.
- Blackbourn, D. J., Osmond, D., Levy, J. A., and Lennette, E. T. (1999). Increased human herpesvirus 8 seroprevalence in young homosexual men who have multiple sex contacts with different partners. *J.Infect.Dis.* **179**, 237.
- Boldogh, I., Szaniszlo, P., Bresnahan, W. A., Flaitz, C. M., Nichols, M. C., and Albrecht, T. (1996). Kaposi's sarcoma herpesvirus-like DNA sequences in the saliva of individuals infected with human immunodeficiency virus. *Clin.Infect.Dis.* **23**, 406.
- Boshoff, C., Talbot, S., Kennedy, M., O'Leary, J., Schulz, T. F., and Chang, Y. (1996). HHV8 and skin cancers in immunosuppressed patients [letter]. *Lancet*. **347**, 338.
- Boshoff, C. and Weiss, R. A. (1998). Kaposi's sarcoma-associated herpesvirus. *Adv.Cancer Res.* **75**, 57.
- Bourboulia, D., Whitby, D., Boshoff, C., *et al.* (1998). Serologic evidence for mother-to-child transmission of Kaposi sarcoma-associated herpesvirus infection in healthy South African children. *JAMA*. **280**, 31.
- Caterino-de-Araujo, A., Calabro, M. L., los Santos-Fortuna, E., Suleiman, J., and Chieco-Bianchi, L. (1999). Searching for human herpesvirus 8 antibodies in serum samples from patients infected with human immunodeficiency virus type 1 and blood donors from Sao Paulo, Brazil. *J.Infect.Dis.* **179**, 1591.
- Cattani, P., Capuano, M., Cerimele, F., *et al.* (1999). Human herpesvirus 8 seroprevalence and evaluation of nonsexual transmission routes by detection of DNA in clinical specimens from human immunodeficiency virus-seronegative patients from central and southern Italy, with and without Kaposi's sarcoma. *J.Clin.Microbiol.* **37**, 1150.

- Chang, Y. and Moore, P. S. (1996a). Kaposi's Sarcoma (KS)-associated herpesvirus and its role in KS. *Infect.Agents Dis.* **5**, 215.
- Chang, Y., Ziegler, J., Wabinga, H., *et al.* (1996b). Kaposi's sarcoma-associated herpesvirus and Kaposi's sarcoma in Africa. Uganda Kaposi's Sarcoma Study Group. *Arch.Intern.Med.* **156**, 202.
- Cottoni, F., De Marco, R., and Montesu, M. A. (1996). Classical Kaposi's sarcoma in north-east Sardinia: an overview from 1977 to 1991. *Br.J.Cancer.* **73**, 1132.
- Couty, J. P., Ranger-Rogez, S., Venot, C., *et al.* (1999). Evaluation of BC-3 and BCP-1 cell lines in immunofluorescence assay to detect HHV-8 antibodies in Kaposi's sarcoma, multiple myeloma and other groups. *J.Clin.Virol.* **12**, 221.
- Davis, D. A., Humphrey, R. W., Newcomb, F. M., *et al.* (1997). Detection of serum antibodies to a Kaposi's sarcoma-associated herpesvirus-specific peptide. *J.Infect.Dis.* **175**, 1071.
- de-Thé, G., Geser, A., Day, N. E., *et al.* (1978a). Epidemiological evidence for causal relationship between Epstein-Barr virus and Burkitt's lymphoma from Ugandan prospective study. *Nature.* **274**, 756.
- de-Thé, G., Lavoue, M. F., and Muenz, L. (1978b). Differences in EBV antibody titres of patients with nasopharyngeal carcinoma originating from high intermediate and low incidence areas. *In* Nasopharyngeal Carcinoma: Etiology and Control,(de-Thé, G. and Ito, Y., eds.), International Agency for Research on Cancer (IARC publication, no. 20), Lyons, France.
- DePond, W., Said, J. W., Tasaka, T., *et al.* (1997). Kaposi's sarcoma-associated herpesvirus and human herpesvirus 8 (KSHV/HHV8)-associated lymphoma of the bowel. Report of two cases in HIV-positive men with secondary effusion lymphomas. *Am.J.Surg.Pathol.* **21**, 719.
- Dupin, N., Fisher, C., Kellam, P., *et al.* (1999). Distribution of human herpesvirus-8 latently infected cells in Kaposi's sarcoma, multicentric Castleman's disease, and primary effusion lymphoma. *Proc.Natl.Acad.Sci.U.S.A.* **96**, 4546.
- Enbom, M., Tolfvenstam, T., Ghebrekidan, H., *et al.* (1999). Seroprevalence of human herpes virus 8 in different Eritrean population groups. *J.Clin.Virol.* **14**, 167.
- Farge, D., Lebbe, C., Marjanovic, Z., *et al.* (1999). Human herpes virus-8 and other risk factors for Kaposi's sarcoma in kidney transplant recipients. Groupe

- Cooperatif de Transplantation d' Ile de France (GCIF). *Transplantation*. **67**, 1236.
- Frances, C., Mouquet, C., and Calvez, V. (1999). Human herpesvirus 8 and renal transplantation [letter]. *N Engl J Med*. **340**, 1045.
- Frances, C., Mouquet, C., Marcelin, A. G., *et al.* (2000). Outcome of kidney transplant recipients with previous human herpesvirus- 8 infection. *Transplantation*. **69**, 1776.
- Gao, S-J., Kingsley, L., Hoover, D. R., *et al.* (1996a). Seroconversion to antibodies against Kaposi's sarcoma-associated herpesvirus-related latent nuclear antigens before the development of Kaposi's sarcoma. *N.Engl.J.Med*. **335**, 233.
- Gao, S. J., Kingsley, L., Li, M., *et al.* (1996b). KSHV antibodies among Americans, Italians and Ugandans with and without Kaposi's sarcoma. *Nat.Med*. **2**, 925.
- Gessain, A., Maucleere, P., van Beveren, M., *et al.* (1999). Human herpesvirus 8 primary infection occurs during childhood in Cameroon, Central Africa. *Int.J.Cancer*. **81**, 189.
- Herbein, G., Strasswimmer, J., Altieri, M., Woehl-Jaegle, M. L., Wolf, P., and Obert, G. (1996). Longitudinal study of human herpesvirus 6 infection in organ transplant recipients. *Clin.Infect.Dis*. **22**, 171.
- Ho, M. (1998). Human herpesvirus 8--let the transplantation physician beware [editorial]. *N Engl J Med*. **339**, 1391.
- Ho, M. and Dummer, J. S. (1995). Infections in transplant recipients. *In* Mandell, Douglas and Bennett's Principles and Practice of Infectious Diseases, 4th ed. Vol. 2. ed. (Mandell, G. L., Bennett, J. E., and Dolin, R., eds.), p.2709, Churchill-Livingstone, New York.
- Ho, M., Suwansirikul, S., Dowling, J. N., Youngblood, L. A., and Armstrong, J. A. (1975). The transplanted kidney as a source of cytomegalovirus infection. *N.Engl.J.Med*. **293**, 1109.
- Howard, M. R., Whitby, D., Bahadur, G., *et al.* (1997). Detection of human herpesvirus 8 DNA in semen from HIV-infected individuals but not healthy semen donors. *AIDS*. **11**, F15.
- Huang, L. M., Huang, S. Y., Chen, M., *et al.* (2000). Geographical differences in human herpesvirus 8 seroepidemiology: a survey of 1,201 individuals in Asia. *J.Med.Virol*. **60**, 290.

- Kedes, D. H., Ganem, D., Ameli, N., Bacchetti, P., and Greenblatt, R. (1997). The prevalence of serum antibody to human herpesvirus 8 (Kaposi sarcoma-associated herpesvirus) among HIV-seropositive and high-risk HIV- seronegative women. *JAMA*. **277**, 478.
- Kedes, D. H., Operskalski, E., Busch, M., Kohn, R., Flood, J., and Ganem, D. (1996). The seroepidemiology of human herpesvirus 8 (Kaposi's sarcoma-associated herpesvirus): distribution of infection in KS risk groups and evidence for sexual transmission [published erratum appears in *Nat Med* 1996 Sep;2(9):1041]. *Nat.Med.* **2**, 918.
- Kellam, P., Bourboulia, D., Dupin, N., *et al.* (1999). Characterization of monoclonal antibodies raised against the latent nuclear antigen of human herpesvirus 8. *J.Virol.* **73**, 5149.
- Koelle, D. M., Huang, M. L., Chandran, B., Vieira, J., Piepkorn, M., and Corey, L. (1997). Frequent detection of Kaposi's sarcoma-associated herpesvirus (human herpesvirus 8) DNA in saliva of human immunodeficiency virus-infected men: clinical and immunologic correlates. *J.Infect.Dis.* **176**, 94.
- LaDuca, J. R., Love, J. L., Abbott, L. Z., Dube, S., Freidman-Kien, A. E., and Poiesz, B. J. (1998). Detection of human herpesvirus 8 DNA sequences in tissues and bodily fluids. *J.Infect.Dis.* **178**, 1610.
- Lefrère, J. J., Meyohas, M. C., Mariotti, M., Meynard, J. L., Thauvin, M., and Frottier, J. (1996). Detection of human herpesvirus 8 DNA sequences before the appearance of Kaposi's sarcoma in human immunodeficiency virus (HIV)-positive subjects with a known date of HIV seroconversion. *J.Infect.Dis.* **174**, 283.
- Lennette, E. T., Blackbourn, D. J., and Levy, J. A. (1996). Antibodies to human herpesvirus type 8 in the general population and in Kaposi's sarcoma patients. *Lancet.* **348**, 858.
- Levy, J. A. (1997). Three new human herpesviruses (HHV6, 7, and 8). *Lancet.* **349**, 558.
- Lin, J. C., Lin, S. C., Mar, E. C., *et al.* (1995). Is Kaposi's-sarcoma-associated herpesvirus detectable in semen of HIV- infected homosexual men? *Lancet.* **346**, 1601.

- Lospalluti, M., Mastroiuliano, M., Loconsole, F., Conte, A., and Rantuccio, F. (1995). Classical Kaposi's sarcoma: a survey of 163 cases observed in Bari, south Italy. *Dermatology*. **191**, 104.
- Lucht, E., Brytting, M., Bjerregaard, L., Julander, I., and Linde, A. (1998). Shedding of cytomegalovirus and herpesviruses 6, 7, and 8 in saliva of human immunodeficiency virus type 1-infected patients and healthy controls. *Clin.Infect.Dis.* **27**, 137.
- Luppi, M. and Torelli, G. (1996). The new lymphotropic herpesviruses (HHV-6, HHV-7, HHV-8) and hepatitis C virus (HCV) in human lymphoproliferative diseases: an overview. *Haematologica*. **81**, 265.
- Martin, J. N., Ganem, D. E., Osmond, D. H., Page-Shafer, K. A., Macrae, D., and Kedes, D. H. (1998a). Sexual transmission and the natural history of human herpesvirus 8 infection. *N.Engl.J.Med.* **338**, 948.
- Martin, N. Jeffrey, Ganem, Donald. E, Osmond, Dennis. H, Page-Shafer, Kimberley. A, Macrae, Don, and Kedes, Dean. H. (1998b). Sexual transmission and the natural history of human herpesvirus 8 infection. *N.Engl.J.Med.* **338**, 948.
- Masood, R., Zheng, T., Tupule, A., *et al.* (1997). Kaposi's sarcoma-associated herpesvirus infection and multiple myeloma. *Science*. **278**, 1970.
- Mayama, S., Cuevas, L. E., Sheldon, J., *et al.* (1998). Prevalence and transmission of Kaposi's sarcoma-associated herpesvirus (human herpesvirus 8) in Ugandan children and adolescents. *Int.J Cancer*. **77**, 817.
- Miller, G., Rigsby, M. O., Heston, L., *et al.* (1996). Antibodies to butyrate-inducible antigens of Kaposi's sarcoma-associated herpesvirus in patients with HIV-1 infection. *N.Engl.J.Med.* **334**, 1292.
- Monini, P., de Lellis, L., Fabris, M., Rigolin, F., and Cassai, E. (1996). Kaposi's sarcoma-associated herpesvirus DNA sequences in prostate tissue and human semen. *N.Engl.J.Med.* **334**, 1168.
- Munker, R., Tasaka, T., Park, D., Miller, C. W., and Koeffler, H. P. (1997). HHV-8 (KSHV) does not establish latency in prostate cancer cell lines. *Prostate*. **33**, 286.
- Niederman, J. C. and Evans, A. S. (1997). Epstein Barr virus. *In* Viral Infections of Humans, Epidemiology and Control, (Evans, A. S. and Niederman, J. C., eds.), p.253, Plenum, New York.

- Olsen, S. J., Chang, Y., Moore, P. S., Biggar, R. J., and Melbye, M. (1998). Increasing Kaposi's sarcoma-associated herpesvirus seroprevalence with age in a highly Kaposi's sarcoma endemic region, Zambia in 1985. *AIDS*. **12**, 1921.
- Parravicini, C., Lauri, E., Baldini, L., *et al.* (1997a). Kaposi's sarcoma-associated herpesvirus infection and multiple myeloma. *Science*. **278**, 1969.
- Parravicini, C., Olsen, S. J., Capra, M., *et al.* (1997b). Risk of Kaposi's sarcoma-associated herpes virus transmission from donor allografts among Italian posttransplant Kaposi's sarcoma patients. *Blood*. **90**, 2826.
- Qunibi, W., Akhtar, M., Sheth, K., *et al.* (1988). Kaposi's sarcoma: The most common tumor after renal transplantation in Saudi Arabia. *Am.J.Med.* **84**, 225 .
- Qunibi, W., Al, Furayh O., Almeshari, K., *et al.* (1998). Serologic association of human herpesvirus eight with posttransplant Kaposi's sarcoma in Saudi Arabia. *Transplantation*. **65**, 583.
- Rabkin, C. S., Schulz, T. F., Whitby, D., *et al.* (1998). Interassay correlation of human herpesvirus 8 serologic tests. HHV-8 Interlaboratory Collaborative Group. *J Infect.Dis.* **178**, 304.
- Rady, P. L., Yen, A., Rollefson, J. L., *et al.* (1995). Herpesvirus-like DNA sequences in non-Kaposi's sarcoma skin lesions of transplant patients. *Lancet*. **345**, 1339.
- Regamey, N, Tamm, M, Wernli, M, *et al.* (1998a). Transmission of human herpesvirus 8 infection from renal-transplant donors to recipients. *N.Engl.J.Med.* **339**, 1358.
- Regamey, N., Cathomas, G., Schwager, M., Wernli, M., Harr, T., and Erb, P. (1998b). High human herpesvirus 8 seroprevalence in the homosexual population in Switzerland. *J.Clin.Microbiol.* **36**, 1784.
- Rettig, M. B., Ma, H. J., Vescio, R. A., *et al.* (1997). Kaposi's sarcoma-associated herpesvirus infection of bone marrow. Schulz, T. F. (1998b). Kaposi's sarcoma-associated herpesvirus (human herpesvirus-8). *J.Gen.Virol.* **79 (Pt 7)**, 1573.
- dendritic cells from multiple myeloma patients [see comments]. *Science*. **276**, 1851.
- Rezza, G., Lennette, E. T., Giuliani, M., *et al.* (1998). Prevalence and determinants of anti-lytic and anti-latent antibodies to human herpesvirus-8 among Italian individuals at risk of sexually and parenterally transmitted infections. *Int.J.Cancer.* **77**, 361.
- Roizman, B. (1995). New viral footprints in Kaposi's sarcoma [editorial]. *N.Engl.J.Med.* **332**, 1227.

- Rutherford, G. W., Schwarcz, S. K., Lemp, G. F., *et al.* (1989). The epidemiology of AIDS-related Kaposi's sarcoma in San Francisco. *J.Infect.Dis.* **159**, 569.
- Schatz, O., Bogner, J. R., and Goebel, F. D. (1997). Kaposi's sarcoma: is the hunt for the culprit over now? *J Mol.Med.* **75**, 28.
- Schulz, T. F. (1998). Kaposi's sarcoma-associated herpesvirus (human herpesvirus-8). *J.Gen.Virol.* **79**, 1573.
- Schulz, T. J. (1998c). Human Herpesvirus-8. *In Human Tumor Viruses*,(McCance, D. J., eds.), p.87, ASM Press, Washington,D.C.
- Sheldon, J., Henry, S., Mourad, M., *et al.* (2000). Human herpes virus 8 infection in kidney transplant patients in Belgium. *Nephrol Dial Transplant.* **15**, 1443.
- Simpson, G. R., Schulz, T. F., Whitby, D., *et al.* (1996). Prevalence of Kaposi's sarcoma associated infection measured by antibodies to recombinant capsid protein and latent immunofluorescence antigen. *Lancet.* **349**, 1133.
- Sitas, F., Carrara, H., Beral, V., *et al.* (1999). Antibodies against human herpesvirus 8 in black South African patients with cancer [see comments]. *N.Engl.J.Med.* **340**, 1863.
- Sosa, C., Klaskala, W., Chandran, B., *et al.* (1998). Human herpesvirus 8 as a potential sexually transmitted agent in Honduras. *J.Infect.Dis.* **178**, 547.
- Staskus, K. A., Zhong, W., Gebhard, K., *et al.* (1997). Kaposi's sarcoma-associated herpesvirus gene expression in endothelial (spindle) tumor cells. *J.Virol.* **71**, 715.
- Strauss, S. (1995). Introduction to herpesviridae. *In Principles and Practice of Infection*,(Mandel, G., Bennett, W., and Dolin, R., eds.), p.1330, Churchill-Livingstone, New York.
- Thomas, J. A., Brookes, L. A., McGowan, I., Weller, I., and Crawford, D. H. (1996). HHV8 DNA in normal gastrointestinal mucosa from HIV seropositive people. *Lancet.* **347**, 1337.
- Verbeek, W., Frankel, M., Miles, S., Said, J., and Koeffler, H. P. (1998). Seroprevalence of HHV-8 antibodies in HIV-positive homosexual men without Kaposi's sarcoma and their clinical follow-up. *Am.J.Clin.Pathol.* **109**, 778.
- Viviano, E., Vitale, F., Ajello, F., *et al.* (1997). Human herpesvirus type 8 DNA sequences in biological samples of HIV- positive and negative individuals in Sicily. *AIDS.* **11**, 607.
- Wang, C. Y., Schroeter, A. L., and Su, W. P. (1995). Acquired immunodeficiency syndrome-related Kaposi's sarcoma. *Mayo Clin.Proc.* **70**, 869.

- Weiss, R. A., Whitby, D., Talbot, S., Kellam, P., and Boshoff, C. (1998). Human herpesvirus type 8 and Kaposi's sarcoma. *J Natl.Cancer Inst.Monogr.* 51.
- Whitby, D. and Boshoff, C. (1998a). Kaposi's sarcoma herpesvirus as a new paradigm for virus-induced oncogenesis. *Curr.Opin.Oncol.* 10, 405.
- Whitby, D., Boshoff, C., Luppi, M., and Torelli, G. (1997). Kaposi's sarcoma-associated herpesvirus infection and multiple myeloma. *Science.* 278, 1971.
- Whitby, D., Howard, M. R., Tenant-Flowers, M., et al. (1995). Detection of Kaposi's sarcoma associated herpesvirus in peripheral blood of HIV-infected individuals and progression to Kaposi's sarcoma. *Lancet.* 346, 799.
- Whitby, D., Luppi, M., Barozzi, P., Boshoff, C., Weiss, R. A., and Torelli, G. (1998b). Human herpesvirus 8 seroprevalence in blood donors and lymphoma patients from different regions of Italy. *J Natl.Cancer Inst.* 90, 395.
- Zhang, X, Fitzpatrick, L., Campbell, T. B., et al. (1998). Comparison of the prevalence of antibodies to human herpesvirus 8 (Kaposi's sarcoma-associated herpesvirus) in Brazil and Colorado. *J.Infect.Dis.* 178, 1488.

Chapter 18

CONCLUSIONS AND RECOMMENDATIONS

Some of the main findings of this dissertation are listed here with appropriate recommendations. Transplant patients should be observed and screened for the presence of malignancies on a regular basis. Perhaps the most important aspect of the management of this issue is the education and cooperation of the patient. What is clearly evident is that there are still many uncertainties with regard to this complication after transplantation. It is also abundantly clear that there are regional differences in the behaviour of posttransplant malignancies. Whether these are based on environmental, genetic or socioeconomic factors remains unknown. What is evident is that information from one area cannot automatically be extrapolated to other areas.

- Renal transplantation is the treatment of choice for patients with end-stage renal failure.
 1. Results of renal transplantation are comparable in white and nonwhite patients.

2. Cyclosporine markedly improves renal allograft survival in the first year. Long-term graft survival under cyclosporine, however, is not superior to conventional treatment and consideration should be given to discontinuing cyclosporine after a period of time; one year seems to be an appropriate interval. Further studies are needed to address this issue.
 3. Graft salvage at all costs carries a significant mortality and should be abandoned. With the option of dialysis a failed renal allograft is not necessarily a death sentence for a uraemic patient but aggressive immunosuppression may well be.
 4. Patients with hypertension as the primary disease resulting in renal failure have a poorer outcome when transplanted. Reasons for this are not clear but deserve further study. Optimal control of blood pressure after renal transplantation is advisable.
- Our patients have a similar incidence of posttransplant malignancies as that generally reported.
 1. The pattern of malignancies however is different from that reported in developing countries but is similar to that reported in other third world countries.
 2. Kaposi's sarcoma is the commonest malignancy in our patients compared to skin cancers reported by the world's largest registries.
 3. The pattern of malignancies differs in white and nonwhite patients who come from the same geographical region, making it a unique report of this type of racial difference in posttransplant cancers. The white and nonwhite patients epitomise the difference between developed and developing countries.
 4. Skin cancer is the commonest cancer to occur in, and is in fact limited to, white patients. The disease occurs almost exclusively in males.
 5. Cyclosporine-based immunosuppression reduces the time interval to the development of the first cancer but does not increase the risk of its development.
 - Kaposi's sarcoma is the commonest malignancy in our patients.

1. The relative risk for the development of Kaposi's sarcoma after renal transplantation was 235 in our patients.
2. The incidence of Kaposi's sarcoma was similar in males and females although the relative risk was higher in the males.
3. All 21 patients who developed Kaposi's sarcoma had skin involvement. Almost 30% of patients had extracutaneous involvement. The lower limbs were most commonly affected.
4. Visceral organ involvement was associated with a universally fatal outcome. Disease limited to peripheral lymph nodes, in contrast, had a good prognosis.
5. Kaposi's sarcoma develops within 2 years of transplantation with the earliest diagnosis being made at 3 months after transplantation.
6. Withdrawal or reduction of immunosuppression result in improvement of the skin and peripheral nodal lesions, with adjunctive radiotherapy being required only in a minority of patients.
7. Reduction of immunosuppression is all that is required as primary treatment of Kaposi's sarcoma limited to the skin and/or peripheral lymph nodes. Complete withdrawal of therapy with consequent graft loss is not necessary. Although in practice the reduction or withdrawal has been recommended, ours is the first study to prove that reduction should be the first line of treatment.
8. Reduction of immunosuppression is not associated with acute rejection; renal function remains preserved in well functioning grafts.
9. Kaposi's sarcoma lesions (skin/ peripheral lymph nodes) may take several months to heal and improvement is best monitored by serial photographs.
10. Disseminated Kaposi's sarcoma can affect any organ system in the body (including the renal allograft) with the exception of the nervous system.
11. The majority of lesions of Kaposi's sarcoma are either mixed type or spindle cell pathological variants corresponding to the more advanced plaque and nodule clinical stages.
12. The cell of origin of Kaposi's sarcoma remains a mystery.
13. Posttransplant Kaposi's sarcoma shares the same histopathological profile with all the other epidemiological forms.

- Skin cancer is the commonest cancer in white patients.
 1. Skin cancer occurs exclusively in white patients.
 2. Skin cancer occurs predominantly in males.
 3. Squamous cell carcinoma is more common than basal cell carcinoma in reversal of the ratio that occurs in immunocompetent patients.
 4. The mean time interval to the development of skin cancer is 6 years.
 5. Sun-exposed areas are at much greater risk of cancer development.
 6. The disease is usually treated with excision biopsy and has a good prognosis.
 7. Prevention should be encouraged using sun-avoidance techniques, although whether this makes a difference remains to be proven, as the bulk of damage is already done earlier in life.

- Cancers that commonly occur in the population do not occur with increased frequency after transplantation.

- Cellular immunity is impaired and natural killer cells are reduced in patients with Kaposi's sarcoma.
 1. Kaposi's sarcoma patients have evidence of both immunosuppression and immunostimulation.
 2. Immunosuppression should be tapered to lowest levels commensurate with good graft survival as soon as possible
 3. A high index of suspicion for malignancies, especially Kaposi's sarcoma should be maintained and especially in patients who are treated for acute rejection.

- The role of the immunosuppressive agents in the development of Kaposi's sarcoma and other malignancies remains uncertain.
 1. Withdrawal of immunosuppression results in the improvement of Kaposi's sarcoma and localised lymphoma.
 2. A meta-analysis undertaken for the first time in this study reveals that the use of cyclosporine is not associated with an increase risk of malignancies.

3. Cyclosporine is however associated with a reduced time to the development of the first posttransplant cancer.
- HHV-8 is important in the development of Kaposi's sarcoma.
 1. The virus is present in all Kaposi's sarcoma tissue and disappears after resolution of the lesion.
 2. The virus is present in the spindle cells, endothelial cells and leucocytes of Kaposi's sarcoma lesions.
 - Seroepidemiological studies show that HHV-8 is not ubiquitous.
 1. The seroprevalence of HHV-8 is less than 6% in our general population.
 2. Although the transplanted organ and to a lesser extent blood transfusions may be the source of the virus in renal transplant patients, the majority of patients who acquire the virus after renal transplantation do so from sources that are yet to be identified.
 3. Seropositivity is a prerequisite to the development of Kaposi's sarcoma.
 4. Routine testing for HHV-8 in allograft recipients may alert one to the patients at risk of Kaposi's sarcoma but in practice education of the patients and a high index of suspicion are the most vital tools to early detection.

To deny the hope of progress is the ultimate fatuity, the last word in poverty of spirit and meanness of mind. There is no need to be dismayed because we have not discovered the final solution to any of the problems that confront us: political, economic, social or moral, that is, having to do with the conduct of life. We are still beginners, and for that reason may hope to improve . . . there can be no contentment in proceeding.

Sir Peter Medawar

ADDENDUM

PUBLICATIONS AND CONGRESS PRESENTATIONS



XVII
CONGRESS
OF THE
SOUTHERN AFRICAN
TRANSPLANTATION SOCIETY

FINAL PROGRAMME
AND ABSTRACT BOOK

17-20 MARCH 1997

SPIER ESTATE, STELLENBOSCH

THE DEVELOPMENT OF MALIGNANCIES IN RENAL ALLOGRAFT RECIPIENTS: THE TYGERBERG HOSPITAL EXPERIENCE.

M R Moosa, McBryne A.

Department of Internal Medicine, University of Stellenbosch and Renal Transplant Unit, Tygerberg Hospital, Parow, Cape Town.

The immunosuppressed recipient of a renal allograft is at increased risk of developing a malignancy compared to the general population. The risk of malignancy increases progressively with the increasing duration of immunosuppression. There have been conflicting reports on the change in the pattern of malignancies following the introduction of ciclosporin. The purpose of our study was to establish the frequency and type of malignancies that occur after renal transplantation and determine if the application of ciclosporin influenced the disease process.

A retrospective analysis of all patients transplanted between 1976 and the end of 1995, and who had a minimum of eighteen months follow-up post-transplant were included in the study. Over the 20 year period 444 patients received 509 kidney transplants. Conventional treatment was given to 112 while the rest received ciclosporin as part of triple immunosuppressive therapy. Overall 27 patients developed malignancies to give an incidence of 6.1% over the 20 years. Kaposi's sarcoma (KS) accounted for 16/27(59%) of the malignant lesions. Under ciclosporin the incidence of KS was 70% compared to 28% in the conventional group ($p < 0.03$). Skin cancer accounted for the majority of the rest of the neoplastic lesions, occurring in 7/27(22%) patients all of whom were white.

Malignancies are an important complication in patients on prolonged immunosuppression, with KS being a particularly serious problem in our cohort of patients, especially under ciclosporin. Skin malignancies affects white patients exclusively.

Transplantation

THE OFFICIAL JOURNAL OF THE TRANSPLANTATION SOCIETY

2

Volume 66, Number 2, July 1998

DETECTION AND SUBTYPING OF HUMAN HERPESVIRUS-8 IN RENAL TRANSPLANT PATIENTS BEFORE AND AFTER REMISSION OF KAPOSII'S SARCOMA

M. Rafique Moosa, Florette K. Treurnicht, Estrelita J. van Rensburg, Johann W. Schneider, H. Francois Jordaan, and Susan Engelbrecht


Departments of Internal Medicine, Medical Virology, Anatomical Pathology, and Dermatology, University of Stellenbosch and Tygerberg Hospital, Tygerberg, Cape Town 7505, South Africa

Background. Kaposi's sarcoma (KS) is a complication of renal transplantation. If the human herpesvirus-8 (HHV-8) causes KS, the virus should be present in all KS lesions and be drastically reduced or cleared from involved tissue on remission of the KS.

Methods. Fourteen renal transplant patients with cutaneous KS, including autopsy material from two cases, were investigated for the presence of HHV-8. A second skin biopsy was taken from 11 survivors, after remission of KS, from normal skin in the same anatomical region as the first biopsy. Remission was induced by reduction or cessation of immunosuppression. A peripheral blood sample was collected simultaneously with the repeat biopsy. A nested polymerase chain reaction assay was used to detect HHV-8 DNA in the biopsy tissue and peripheral blood mononuclear cells followed by direct sequencing of polymerase chain reaction product to detect any nucleotide changes.

Results. HHV-8 DNA was detected in all the cutaneous KS and all the visceral KS samples, as well as a number of KS-free organs including the thyroid, salivary gland, and myocardium that have not been described before. Mutations in the viral DNA could be demonstrated in all patients. The mutations found were related more to that seen in AIDS-KS cases than that found in African endemic KS cases. HHV-8 sequences could be detected in follow-up frozen skin biopsies of five patients but were negative in the equivalent formalin-fixed specimens. Viral DNA was also detected in 2 of 11 peripheral blood mononuclear cell samples collected at the time of the follow-up skin biopsies.

Conclusion. Reduction or withdrawal of immunosuppression allows the immune system to recover sufficiently to reduce viral replication with subsequent viral persistence and low grade viral replication that coincides with clinical remission of the KS lesions. This provides further evidence for the important etiological role played by HHV-8 in the pathogenesis of posttransplant KS.



FACTORS INFLUENCING PATIENT AND RENAL ALLOGRAFT SURVIVAL : THE TYGERBERG HOSPITAL EXPERIENCE

MR Moosa

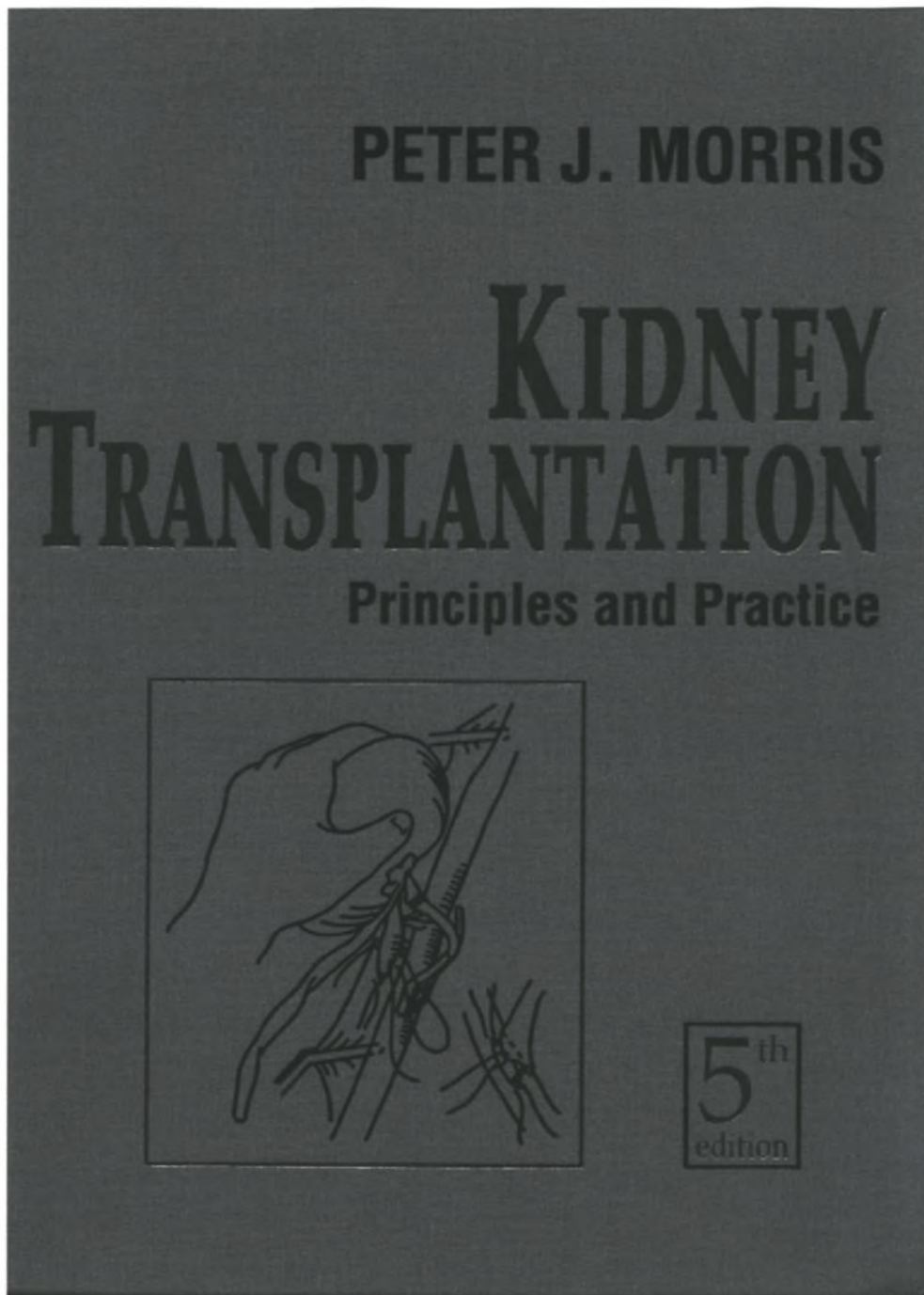
Department of Internal Medicine and Renal Unit, Tygerberg Hospital, Parow, Western Cape.

The survival of renal allografts and of recipients is influenced by a number of factors, demographic, clinical and therapeutic. Some of these factors have been better studied than others, and we sought to establish the influence of particular factors on our own patients and allografts.

All patients transplanted in our unit between April 1, 1976 and March 31, 1999 were included in the study. Demographic details were analysed. Patient and graft outcomes were assessed using Kaplan-Meier survival analysis. The survival curves were compared using univariate analysis; results that were significant were subjected to multivariate analysis. The influence of a number of factors on graft and patient survival were assessed and compared.

In the study period, 623 renal allografts were transplanted in 542 patients. Patient survival was superior in recipients who were aged less than 40 years, retained their allografts in the first year and received living-related donor kidneys. Patient survival was similar on cyclosporine compared to conventional treatment early, but was worse after 6 years. Graft survival was also better in younger patients and those under cyclosporine; race and sex did not have an influence on graft survival.

Failure to retain a renal allograft in the first year was a poor prognostic indicator. Cyclosporine improved graft survival, but not patient survival. Patient and graft survival were better in younger patients. Contrary to the experience elsewhere, black and white patients had similar outcomes after renal transplantation.



W.B. Saunders (2001), Philadelphia.

Renal Transplantation in Developing Countries

M. Rafique Moosa • Abdul Aziz Walele • Abdallah S. Daar

Introduction

Renal transplantation is the only viable therapeutic option for most patients with irreversible renal failure in developing countries. The high cost of dialysis limits this form of treatment to a privileged few, making a successful renal transplant a greater necessity than elsewhere. The struggling economies of most developing countries have many other priorities, and the question of whether dialysis and transplantation are justified at all has been raised but remains largely rhetorical. If transplants are to be done, the timing of transplantation must be optimized, graft function must be maximized and costs and complications must be minimized. Many developing countries are beset by problems, including political and military violence, economic upheavals, corruption and unstable governments. There are major demands on available resources, and generally less than 5% of gross national product (GNP) is spent on health. In the United States, 14.3% of GNP is spent on health care, whereas Pakistan spends 1.1% (Rizvi *et al.*, 1990), and India spends 1.5% (Chugh and Jha, 1995; Weening *et al.*, 1998). Many health problems in developing countries are related to poverty, malnutrition, lack of potable water and infections.

Malaria and human immunodeficiency virus (HIV) infection, especially in sub-Saharan Africa, put enormous strains on limited health care budgets. Within these limitations, nephrologists have to manage patients with irreversible renal failure. Proponents of renal transplantation argue that transplantation should be encouraged because it is the most cost-effective form of renal replacement therapy, with the best promise of improved quality of life and an excellent chance of rehabilitation. Rizvi and Naqvi (1995) argued that curbing transplantation until other health issues are addressed should be avoided because the delivery of health services is notoriously poor. It has been estimated that 80% of the world's population live in developing countries and consume 15% of world resources (Fig. 38-1). The World Bank classification of countries by economic groupings, based on GNP per capita (World Bank, 1997), is (1) *low income*, less than \$785 (U.S. dollars); (2) *lower middle income*, \$786 to \$3,125; (3) *upper middle income*, \$3,126 to \$9,655 and (4) *high income*, greater than \$9,656. The countries with low-income and middle-income economies are referred to as *developing countries*. The disparity between *emerging market economies* of developing countries and established market economies of developed countries continues to widen (Grunberg, 1996). Nowhere is this disparity more striking than in the differential resources spent on health.

The availability and rate of transplant activity vary considerably; however, demand exists even in the poorest nations. Kidney transplants were performed in 95% of 44 countries surveyed by Kazim *et al.* (1992)—most were performed in the more developed countries.

Most uremic patients are unlikely to receive treatment because with poverty there is a struggle to provide the most basic medical care. With many developing countries having virtually no dialysis activity or cadaver donor programs, the only hope for patients with irreversible renal failure is a living related donor transplant. On a worldwide basis, the number of patients with end-stage renal disease (ESRD) starting dialysis increased by more than 33-fold in the years 1975-1989, but the number of transplants increased only 5-fold in the same period. Of all the transplants worldwide, less than 10% are performed in developing countries, which rely heavily, and in some cases exclusively, on living related donors. The marked discrepancy between the number of patients with ESRD and the number of patients who receive transplants continues to grow at an alarming rate. In developing countries, the discrepancy between what is technically possible and what is economically viable is striking with regard to renal replacement treatment; in Pakistan, 400 kid-

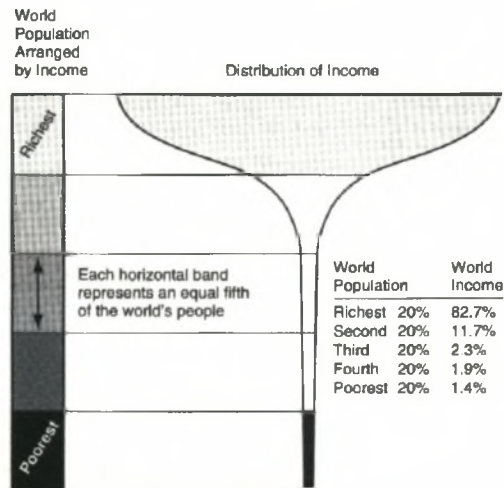


FIGURE 38-1

The champagne glass of world poverty. The discrepancy in the wealth of the rich and poor countries of the world is extremely large and continues to grow, largely as a result of the indebtedness of the poorest countries, resulting in the stem of the glass becoming thinner. The poorest 60% of the world's population are almost equally poor. (Anonymous, 1999b; reproduced with permission from the *British Medical Journal*.)