


# **Human Gamete Micromanipulation and Intracytoplasmic Sperm Injection (ICSI): Its impact on severe male infertility**

**Marie-Lena Windt MSc**

Dissertation submitted in fulfillment of the requirements for the degree of Doctor of  
Philosophy (Medical Sciences)

University of Stellenbosch, Department of Obstetrics and Gynaecology, Tygerberg  
Hospital, Tygerberg, South Africa



**Promotor: Prof TF Kruger MD**

December 2000

### **Declaration**

I, the undersigned, hereby declare that the work contained in this dissertation is my own original work and that I have not previously in its entirety or in part submitted it at any university for a degree.

25 November 2000

## SUMMARY

---

Intracytoplasmic sperm injection (ICSI) introduced a revolutionary way of treatment for male factor infertility. With the exception of some cases of non-obstructive azoospermia, all other male factor infertility cases have the potential to be successfully treated with ICSI. The only prerequisite seems to be the presence of a motile or viable immotile sperm cell for each oocyte.

In this study we report on our own experience with the development and implementation of the ICSI method in the Reproductive Biology Unit at Tygerberg Hospital. An analysis of 5 years of ICSI experience showed that semen parameters, sperm morphology, motility and concentration did not influence fertilization and pregnancy rates adversely. In most cases, patients who could not be treated with in vitro fertilization (IVF) and gamete intrafallopian transfer (GIFT), due to poor semen parameters or fertilization failure, were treated successfully with ICSI. Even a case of globozoospermia was treated successfully with ICSI.

Testicular spermatozoa, fresh or frozen-thawed, also resulted in excellent fertilization and pregnancy rates. Cryopreservation of testicular samples facilitated the management of the infertile couple, aiding the coordination of the recovery of vital gametes from both partners and also limiting the repetition of testicular biopsies. Incubation (maturation) of testicular spermatozoa also induced an enhancement in pregnancy rates.

It can be concluded that ICSI proved to be a treatment method with success similar to that of in vitro fertilization (IVF) and gamete intrafallopian transfer (GIFT), in spite of a severe male factor.

The study also indicated transfer route and embryo quality (viability) to be very important factors in the success of ICSI. The tubal transfer route was shown to be a significant contributor to the pregnancy success (compared to uterine transfer) as was the transfer of embryos that showed early division to the 2-cell stage, 26 hours post injection. The transfer of early dividing embryos into the fallopian tube resulted in a pregnancy rate of almost 40%, a result similar to that of GIFT with a mild male factor.

The role of the oocyte in fertilization and pregnancy success was also revealed indirectly by the introduction of ICSI. Visual observation of denuded oocytes was possible and many morphological features, normal and abnormal, can be observed. Immature oocytes can also be identified and it was shown that they could be successfully matured in vitro before injection.

In this study transmission electron microscopy (TEM) was used to study abnormalities in oocyte morphology. The standard method was adapted and modified for single cell TEM. The abnormalities observed included lysosomal and non-lysosomal degeneration (yellowish or darkly coloured oocytes), degeneration and vacuole formation (vacuolated oocytes), large secondary lysosomes filled with multiple small lipid droplets - lipofuscin body (refractile body) and a fragmented oocyte. It was also possible to study at ultrastructural level, possible reasons for fertilization failure in ICSI. Different stages of oocyte activation failure, cytoplasmic immaturity, sperm cell extrusion, abnormal sperm cell decondensation, female spindle abnormalities and technique related factors were observed.

TEM was also successfully implemented to elucidate the reason for infertility in a patient with a longstanding, unexplained history of infertility. TEM evaluation of two of the patient's unfertilized oocytes revealed a spindle abnormality with contributing cytoskeletal anomalies at ultrastructural level. The modified TEM technique offers a valuable tool to study this small, but important group of patients with unexplained infertility. This TEM study opened up a new, valuable and interesting avenue of research with both diagnostic and prognostic value for patients with unexplained infertility.

ICSI is therefore a valuable method in the treatment of especially male factor infertility. It is the most advanced fertilization technique developed in the last decade in this field. Not only can almost all male factor patients be treated, but unexplained female infertility can also be exposed, studied and hopefully in future also be treated with micromanipulation methods.

## OPSOMMING

---

Die ontwikkeling van die mikromanipulasie tegniek "Intracytoplasmic sperm injection" (ICSI) het die behandeling van die manlike faktor in infertiliteit, revolusionêr verander. Met die uitsondering van sommige gevalle van nie-obstruktiwiese asoospermia, kan potensieel alle ander manlike infertiliteits faktore suksesvol met ICSI behandel word. Die enigste voorvereiste blyk 'n bewegende of 'n nie-bewegende, maar bewese lewende spermiesel te wees.

In hierdie studie word verslag gedoen oor die ontwikkeling en toepassing van die ICSI metode in die Eenheid vir Reproductiewe Biologie by Tygerberg Hospitaal. 'n Analise van 5 jaar se resultate na die implementering van die ICSI metode het gewys dat die semen parameters, sperm morfologie, motiliteit en konsentrasie, nie 'n effek op bevrugting- en swangerskapsyfers gehad het nie. Pasiënte wat, as gevolg van ontoereikende semen parameters, nie met die klassieke metodes, in vitro bevrugting (IVB) of gameet intrafallopiumsbuis terugplasing (GIFT) behandel kon word nie, kon suksesvol met ICSI behandel word. Daar was selfs 'n geval van manlike infertiliteit as gevolg van globosospermie, wat suksesvol met ICS behandel is.

Die ICSI metode het dit ook moontlik gemaak om uitstekende bevrugting- en swangerskap resultate met testikulêre spermatozoa (vars en gevries) te bereik. Die bevriesing van testisweefsel het ook bygedra tot beter hantering van sulke pasiënte. Herhaalde testisbiopsies word uitgeskakel en die koördinasie van die verkryging van die manlike en vroulike gamete, word ook vergemaklik wanneer testisweefsel in gevriesde vorm beskikbaar is. Die studie het verder getoon dat wanneer testikulêre weefsel geïnkubeer word (om spermatozoa te laat matureer), die swangerskapsyfers verhoog was.

Dit is dus duidelik dat die ICSI metode net so suksesvol soos die IVB en GIFT metodes toegepas kan word, selfs en veral in gevalle van erge manlike faktor infertiliteit.

Die studie het ook verder getoon dat die plek waar embrios teruggeplaas word, asook die embriokwaliteit van teruggeplaasde embrios, belangrike bydraende faktore in die ICSI swangerskapsukses was. Embrioterugplasing in die buis van fallopium en terugplasing van embrios wat vroeë 2-sel deling, 26 uur na ICSI getoon het, is uitgewys as faktore wat ICSI swangerskap betekenisvol verbeter het. Dit was moontlik om 'n swangerskapsyfer van ongeveer 40%, sootgelyk aan die van GIFT sonder 'n erge manlike faktor, te bereik met die terugplasing van ten minste een vroeë deler embrio in die fallopiese buis.

Die ICSI tegniek het ook indirek bygedra tot nuwe insigte met betrekking tot die rol wat die vroulike eiersel (oösiet) in ICSI bevrugting speel. Oösiete word gestroop van hul omringende selle vir die ICSI proses en kan dan maklik vir hul normale en abnormale morfologiese eienskappe evalueer word. Oösiete wat immatuur is kan ook so geïdentifiseer word en dit is moontlik om hulle suksesvol te matureer voor mikro-inspuiting.

Transmissie-elektronmikroskopie (TEM) is in die studie gebruik om die ultrastruktuur van onbevrugde en abnormale oösiete te bestudeer. Hiervoor is 'n bestaande tegniek gemodifiseer vir die hantering van 'n enkele sel, in hierdie geval die oösiet. Lisosomale en nie-lisosomale

degenerasie (oösiete wat geel of donker van kleur voorkom), degeneratiewe tekens en vakuole (oösiete met vakuole), groot sekondêre lisosome gevul met klein lipieddruppels ('refractile body') en 'n gefragmenteerde oösiet was van die morfologies abnormale eienskappe wat ultrastruktureel geïdentifiseer is. Moontlike faktore wat 'n rol kan speel in nie-bevrugting na ICSI kon ook op ultrastrukturele vlak met die tegniek geïdentifiseer word. Hierdie faktore het die volgende ingesluit: die onvermoë van verskillende stadiums van oösiet aktivering, sitoplasmatiese immaturiteit, uitwerping van die spermsel na die periviteliene spasie, abnormale spermsel decondensasie, vroulike spoelvormings abnormaliteite en tegniekgekoppelde faktore.

Die TEM tegniek is ook suksesvol aangewend om die infertiliteitsprobleem van 'n pasiënt wat vir etlike jare aan onverklaarbare infertiliteit gely het, te identifiseer. TEM het op die ultrastrukturele vlak gewys dat daar 'n spoel abnormaliteit in twee van haar onbevrugde oösiete was. TEM kan dus baie vrugbaar gebruik word in hierdie groep pasiënte om onverklaarbare infertiliteit, wat andersins ongeïdentifiseerd sou bly, te verklaar.

Die ICSI metode is die mees revolusionêre tegniek wat die afgelope dekade vir die behandeling van veral manlike infertiliteit ontwikkel en baie suksesvol toegepas is. Die metode ook kan 'n bydraende rol speel in die hantering van onverklaarbare infertiliteit veral ten opsigte van die vroulike gameet. In die toekoms is dit moontlik dat selfs hierdie probleem met nuwe mikromanipulasietegnieke opgelos sal kan word.

**Dedicated to my father**

'To manage the instrument successfully, delicacy of touch and a great deal of patience are required; but it is only the latter combined with perseverance, energy and close observations that scientific facts have or ever will be established'.

HD Schmidt - 1859



## CONTENTS

---

<i>Summary</i>	<i>iii</i>
<i>Opsomming</i>	<i>v</i>
<i>Dedication</i>	<i>vii</i>
<i>Acknowledgements</i>	<i>xi</i>
<i>Chapter highlights</i>	<i>xiv</i>

### **Chapter 1**

#### **Introduction 1**

Protocol and development of the study 1

Intracytoplasmic sperm injection (ICSI) - a historical overview 5

Fertilization failure in intracytoplasmic sperm injection (ICSI) - a literature review 9

### **Chapter 2**

#### **Materials and Methods 46**

Intracytoplasmic sperm injection (ICSI): 46

Stimulation protocols

Semen preparation

Testicular Sperm Cryopreservation

ICSI Technique

Embryo Culture and Transfer

### **Chapter 3**

#### **Results of a 5 year ICSI program 62**

Intracytoplasmic sperm injection (ICSI) - five years of experience 62

Intracytoplasmic sperm injection (ICSI) with testicular spermatozoa - five years of experience 82

## **Chapter 4**

### **Results of the influence of transfer method and embryo quality/viability on ICSI pregnancy rates 93**

Intracytoplasmic sperm injection (ICSI): Comparison of laparoscopic tubal versus transvaginal uterine embryo transfer  
Phase 1 (Tom Cat uterine embryo transfer) 93

Intracytoplasmic sperm injection (ICSI): Comparison of laparoscopic tubal versus transvaginal uterine embryo transfer  
Phase 2 (Edwards-Wallace uterine embryo transfer) 101

Intracytoplasmic sperm injection (ICSI): Comparative analysis of pregnancy rates after the transfer of early dividing embryos versus late dividing embryos  
Phase 3 (Uterine and tubal transfer of early dividing embryos) 107

## **Chapter 5**

### **Short communications: interesting case studies from an ICSI programme 121**

Pregnancy with metaphase I oocytes after in vitro maturation and ICSI 121

Twin pregnancy after ICSI with a globozoospermic male patient 130

Pregnancies after ICSI with frozen-thawed testicular spermatozoa 135

## **Chapter 6**

### **Transmission electron microscopic (TEM) images of human oocytes 142**

Materials and methods: Transmission electron microscopy (TEM) for a single cell: TEM of the human oocyte  
 Transmission electron microscopy (TEM) for spermatozoa 142

Ultrastructure of normal, abnormal and unfertilized (ICSI) human oocytes to explain possible reasons for fertilization failure 151

Transmission electron microscopic (TEM) evaluation of oocytes arrested at metaphase I. A case study 171

## CHAPTER HIGHLIGHTS

---

### Chapter 1

In this chapter the development, hypothesis and objectives of the study is put forward. This section is followed by a short historical review of the evolution of the intracytoplasmic sperm injection (ICSI) technique. Further emphasis is then put on the problem of fertilization failure in general, but specifically after ICSI. The mechanism of oocyte activation, especially in ICSI is discussed. The possible reasons for fertilization failure are reviewed and it was concluded that the major cause for fertilization failure is failure of oocyte activation. Contributing factors are cytogenetic abnormalities in the oocyte and spermatozoon; female age; laboratory conditions; oocyte morphology; ICSI technique and specific spermatozoal and oocyte defects. When normal gametes are available and culture conditions are optimal, the ICSI injection technique seems to be the most important factor in fertilization success.

*This review was published in "An Atlas of the Ultrastructure of Human Oocytes - A Guide for Assisted Reproduction" (2000) edited by M. El. Shafie, M. Sousa, M.-L.- Windt and T.F. Kruger (Parthenon Publishing).*

### Chapter 2

In this chapter the methods used in the clinical studies are explained in detail. This includes the Intracytoplasmic Sperm Injection (ICSI) method, hyperstimulation protocols, semen preparation methods, testicular sperm cryopreservation methods, embryo culture methods and embryo transfer methods.

### Chapter 3

In this chapter the cumulative results of the first 5 years of ICSI experience in the Reproductive Biology Unit, Department of Obstetrics and Gynecology, Tygerberg Hospital, South Africa are presented. The technique was shown to be very successful, comparing very well with results from other international institutions. It was also shown to be especially successful in severe male factor patients, patients who before the introduction of ICSI had little other option but that of donor spermatozoa or adoption. ICSI also gave new hope to many azoospermic couples, assisting them to have a child, genetically their own. The results indicated a positive growth curve regarding fertilization and pregnancy rates and ICSI is now a routine assisted reproductive technique at Tygerberg Hospital.

*The results from this chapter were submitted for publication to "Journal of Assisted Reproduction and Genetics", (2000).*

## Chapter 4

In this chapter the effect of transfer route, transfer catheter and embryo selection on ICSI embryo transfer success is investigated. It was shown that the use of the rigid Tom Cat transfer catheter was less successful compared to the soft Edward- Wallace catheter. Our experience was also that the tubal transfer route of ICSI embryos was more successful. Finally it was shown that the selection of early dividing (26 hours post injection) embryos for transfer, was more successful than that of slower embryos. The combination of early dividing embryos via the tubal route resulted in significantly higher pregnancy rate compared to transfer of slower embryos in the uterus. Success after transfer of early dividing embryos into the uterus compared however favourably with transfer of similar embryos in the tube. When one or more early dividing embryo is therefore available, both tubal and uterine transfer of ICSI embryos can be considered. When no early dividing embryos are available, the tubal transfer route is the preferred one. The results also indicate that prolonged culture to the blastocyst stage is not necessary except in the case where early division is not present and more than 6 good quality embryos are available. In such cases, blastocyst culture can give additional information on embryo viability and selection of embryos for transfer.

*The results of this chapter were submitted for publication to "Human Reproduction", (2000).*

## Chapter 5

In this chapter a few interesting case studies with ICSI are presented.

Case study I: In this study the use of matured metaphase I oocytes in an ICSI program is discussed. A case study where only metaphase I oocytes were aspirated and then treated with ICSI after maturation in vitro to the metaphase II stage, is also discussed. Embryo transfer resulted in a pregnancy and a healthy boy was subsequently born.

*Results from this study were published in J. Assisted Reprod. Gen. (1996) 13(10), 775-778.*

Case study II: In another case study, an ongoing, twin pregnancy resulted after transfer of embryos fertilized in ICSI with spermatozoa from a globozoospermic male. Globozoospermia was confirmed with TEM.

*This case study was submitted for publication to "Journal of Assisted Reproduction and Genetics", (2000).*

Case study III: We also report on two clinical pregnancies (to our knowledge the first in Southern Africa) following intracytoplasmic sperm injection (ICSI) of spermatozoa from frozen-thawed testicular biopsies from two azoospermic men. In one case a healthy girl was delivered and in the other case an initial triplet pregnancy resulted in the birth of two healthy girls.

*These two case studies were published in "The South African Medical Journal, (1998) 88 (10), 348 (letter to the Editor) by Windt et al. and also in "Andrologia" (1999) 31(3), 169-172 by Windt et al.*

## Chapter 6

In this descriptive chapter the transmission electron microscopy (TEM) technique was implemented to evaluate human oocytes at ultrastructural level.

The materials and method for transmission electron microscopy (TEM) for a single cell (in this case the human oocyte) are described in detail.

In the preparation of oocytes for ICSI, certain morphological oocyte features become more apparent, revealing certain gross abnormalities. Investigation of such oocytes at ultrastructural level revealed specific deviations from the normal appearing oocyte. Some of these features were indicative of poor fertilization rates with ICSI and also of degeneration taking place in the oocyte. Investigation of unfertilized oocytes (after ICSI) at ultrastructural level revealed several possible reasons for the fertilization failure, reasons not apparent with inverted light microscopy. Unexplained fertilization failure can and is now investigated at the oocyte ultrastructural level and can assist in prognosis and treatment of the patients.

One such a case of unexplained female infertility is described and discussed. The inability of oocytes to reach the metaphase II stage was shown to be due to a possible cytoplasmic (specifically microtubule) abnormality at ultrastructural level. Treatment options for this patient are oocyte donation, cytoplasmic transfer or germinal vesicle transfer.

*This Chapter was published in "An Atlas of the Ultrastructure of Human Oocytes - A Guide for Assisted Reproduction" (2000) edited by M. El. Shafie, M. Sousa, M.-L.- Windt and T.F. Kruger (Parhenon Publishing) and the results are also in preparation for submission for publication to "Human Reproduction", 2000 and Fertility and Sterility, 2000.*

## ACKNOWLEDGEMENTS

---

I wish to thank the following people and institutions:

- Professor TF Kruger, my promoter and Head of the Reproductive Biology Unit, Tygerberg Hospital, Tygerberg, South Africa.
- Professor HJ Odendaal, Head of Department, Department of Obstetrics and Gynaecology, Tygerberg Hospital, Tygerberg, South Africa.
- Dr Roelof Menkveld, my internal examiner, Reproductive Biology Unit, Tygerberg Hospital, Tygerberg, South Africa.
- Prof. Anibal Acosta, my external examiner, emeritus professor of Obstetrics and Gynaecology, Eastern Virginia Medical School, Norfolk, VA. U.S.A.
- Everyone at the Reproductive Biology Unit, Tygerberg Hospital, Tygerberg, South Africa, especially Kevin Coetzee who assisted me in most of the studies in this work.
- Dr CJ Lombard, Division of Epidemiology and Biostatistics, CERSA, Medical Research Council, Tygerberg, South Africa.
- Prof PAB Wranz and the personnel, Diagnostic Electron Microscopy Division, Department of Anatomical Pathology, University of Stellenbosch, Tygerberg Hospital, South Africa.
- The University of Stellenbosch, Medical School, Tygerberg, South Africa.
- The Harry and Doris Crossley Fund, University of Stellenbosch, Tygerberg, South Africa.

Special thanks to:

- Professor Mário Sousa, Laboratory of Cell Biology, Institute of Biomedical Sciences, University of Oporto, Porto, Portugal for his invaluable assistance with the evaluation of TEM micrographs.
- Dr Mahmoud El. Shafie, El. Gallaa Maternity Hospital, Cairo, Egypt for his enthusiasm and introduction of the TEM method for the human oocyte to us.
- Marsia Kitshoff, Department of Anatomical Pathology, University of Stellenbosch, Tygerberg Hospital, South Africa for her meticulous performance of the TEM method.

Finally I wish to thank Pieter for his understanding, support and love.

# CHAPTER 1

## INTRODUCTION

---

- **Protocol and development of the study**
- **Intracytoplasmic sperm injection (ICSI) - a historical overview**
- **Fertilization failure in intracytoplasmic sperm injection (ICSI) – a literature review**

## PROTOCOL AND DEVELOPMENT OF THE STUDY

The design of the study that led to this thesis was developed around the intracytoplasmic sperm injection (ICSI) method at a time when the method was introduced into our laboratory for the first time. The proposed protocol follows below:

### Introduction

Although conventional in vitro fertilization (IVF) has been the cornerstone in trying to achieve pregnancies in infertile couples, some patients cannot even be helped by this method. Unexplained fertilization failure can be caused by the inability of spermatozoa to interact with the zona, fuse with the oolemma or decondense inside the oocyte. In some cases, the number of motile spermatozoa does not allow conventional IVF or gamete intrafallopian tube transfer (GIFT) and poor sperm morphology may also result in very low fertilization rates. It was therefore understandable that other methods would evolve and should be developed, aimed at overcoming these barriers to successful fertilization and pregnancy. These methods have become known as microsurgical fertilization. It includes partial zona dissection (PZD) (Cohen *et al.*, 1989) and subzonal sperm insertion (SUZI) (Fishel *et al.*, 1991) - methods that have in recent years been abandoned in most laboratories due to much higher success rates achieved with intracytoplasmic sperm injection (ICSI) (Palermo *et al.*, 1992; Van Steirteghem *et al.*, 1993a). In this method, a single live, but immobilized spermatozoon is injected with a micropipette into the ooplasm of a metaphase II oocyte to facilitate fertilization.

ICSI is now used worldwide to treat severe male infertility and with great success (Van Steirteghem *et al.*, 1993b; Payne *et al.*, 1994; Sousa and Tesarik, 1994). Fertilization and pregnancy rates equal to and sometimes even surpassing conventional IVF rates have been reported. The most recent advances even allow clinicians and embryologists to use spermatozoa from the epididymus (Silber *et al.*, 1994) and testis (Schoysman *et al.*, 1994) to facilitate fertilization and pregnancy.

Since the method is time consuming, labour intensive and involve initially high financial input, patients must be selected carefully for ICSI. In South Africa, ICSI is in its initial stages of development and establishment as a viable means to assist human reproduction.

Much can be learned from the gametes manipulated by ICSI, especially reasons for fertilization failure, since these oocytes can be studied, knowing that the majority of prerequisites for fertilization have been met.

There is consensus in most prominent IVF units that the ICSI method will become a prominent and permanent tool in the treatment of male infertility and that methods to increase it's success will be developed.

The aims of the study were therefore:

1. To develop and use the ICSI method to improve the fertilization and pregnancy rates in patients with severe male infertility.



Hypothesis: Severe male factor patients can achieve similar fertilization and pregnancy rates as patients treated with IVF and GIFT when ICSI is used. Improved technique, culture conditions and optimization of microtools will facilitate successful pregnancy rates **(Chapter 3)**.

2. To correlate semen parameters (motility, morphology and concentration) with ICSI success.  
Hypothesis: Fertilization and pregnancy rates in ICSI treated patients are not significantly influenced by traditional semen parameters **(Chapter 3 and Chapter 5)**.
3. To evaluate the use and success of epididymal and testicular spermatozoa in the ICSI method.  
Hypothesis: Epididymal and testicular spermatozoa can be used successfully in ICSI to achieve pregnancies **(Chapter 3 and 5)**.
4. To evaluate the most successful transfer method for patients treated with ICSI (patients with patent fallopian tubes).  
Hypothesis: Patients with patent fallopian tubes have a better prognosis for pregnancy success with tubal embryo transfer compared to uterine embryo transfer **(Chapter 4)**.
5. To evaluate the effect of ICSI embryo quality and viability on pregnancy rates after their selective transfer.  
Hypothesis: Embryo transfer by means of a specific embryo selection method (i.e. early division) will show an increased pregnancy rate **(Chapter 4)**.
6. To evaluate the influence of oocyte maturity, quality and morphology on ICSI success.  
Hypothesis: ICSI success is influenced by certain oocyte qualities determined at light microscopic level **(Chapter 5 and Chapter 6)**.
7. To determine the possible reasons for ICSI fertilization failure under optimal culture conditions.  
Hypothesis: Fertilization failure in ICSI is most often caused by:
  - a) Oocyte abnormalities at ultrastructural level
  - b) Spermatozoal abnormalities at ultrastructural level
  - c) Microinjection technique **(Chapter 6)**.

## References

- Cohen, J., Malter, H.E., Wright, G. *et al.* (1989) Partial zona dissection of human oocytes, when failure of zona pellucida penetration is anticipated. *Hum. Reprod.*, **4**, 435-442.
- Fischel, S., Antinori, S., Jackson, P. (1991) Presentation of six pregnancies established by sub-zonal insemination (SUZI). *Hum. Reprod.*, **6**, 124-130.
- Palermo, G., Joris, H., Devroey, P. *et al.* (1992) Pregnancy after intracytoplasmic injection of a single spermatozoon into an oocyte. *Lancet*, **2**, 17-18.
- Payne, D., Flaherty, S.P., Jeffrey, R. *et al.* (1994) Successful treatment of severe male factor infertility in 100 consecutive cycles using intracytoplasmic sperm injection. *Hum. Reprod.*, **11**, 2051- 2057.
- Schoysman, R., Vanderzwalmen, P., Nijs, M. *et al.* (1994) Pregnancy obtained with human testicular spermatozoa in an in vitro fertilization program. *J. Androl.*, **15**, 10S-13S.
- Silber, S.J., Nagy, Z.P., Liu, J. *et al.* (1994) Conventional in-vitro fertilization versus intracytoplasmic sperm injection for patients requiring microsurgical sperm aspiration. *Hum. Reprod.*, **9**, 1705-1709.
- Sousa, M. and Tesarik, J. (1994) Ultrastructural analysis of fertilization failure after intracytoplasmic sperm injection. *Hum. Reprod.*, **9**, 2374-2380.
- Van Steirteghem, A.C., Liu, J., Joris, H. *et al.* (1993a). Higher success rate by intracytoplasmic sperm injection than by subzonal insemination. Report on a second series of 300 consecutive treatment cycles. *Hum. Reprod.*, **8**, 1055-1060.
- Van Steirteghem, A.C., Nagy, Z., Joris, H. *et al.* (1993b). High fertilization and implantation rates after intracytoplasmic sperm injection. *Hum. Reprod.*, **8**, 1061-1066.

## INTRACYTOPLASMIC SPERM INJECTION (ICSI) - A HISTORICAL OVERVIEW

Intracytoplasmic Sperm Injection (ICSI) is an in vitro fertilization technique that stands the most prominent of all in the last decade of assisted reproduction. ICSI was an important breakthrough especially in the case of severe male factor infertility and failure of fertilization. It also enabled the embryologist to come into very close contact with the human gamete and opened up new fields of research on the oocyte and on human fertilization.

Cell micromanipulation is not a new technique and as early as 1911 micromanipulation techniques were described by Kite (Mansour, 1998). Micromanipulation techniques similar to ICSI were first used in non-mammalian studies (Harimoto, 1966) and eventually also used in rabbits to result in healthy offspring (Hosoi *et al.*, 1988; Iritani, 1998).

The technique has developed gradually since then and in the human, partial zona dissection (PZD) (Cohen *et al.*, 1988) and subzonal sperm injection (SUZI) (Palermo *et al.*, 1991, 1992a) techniques were developed and implemented, but resulted in limited success.

The first ICSI on human oocytes (Lanzendorf *et al.*, 1988) resulted in fertilization, but a high percentage of damage to the oocyte. In 1992, Palermo *et al.* (1992b) finally reported the first human pregnancies after ICSI. Since then ICSI dominated the field of assisted reproduction. Nagy *et al.* (1995) reported that severe cases of oligoasthenoteratozoospermia (OAT) treated with ICSI gave similar fertilization and pregnancy results than conventional in vitro fertilization (IVF) with normal spermatozoa. Semen parameters (Nagy *et al.*, 1995) and pre-treatment of spermatozoa (Liu *et al.*, 1994a) had no apparent effect on ICSI success. Fertilization and pregnancy were further enhanced by the introduction of sperm immobilization and cytoplasmic aspiration (Joris *et al.*, 1998) to the technique.

In 1994 Silber *et al.* and Tournaye *et al.* reported success with ICSI using epididymal sperm after applying microsurgical epididymal sperm aspiration (MESA) in men suffering from congenital absence of the vas deference (CAVD).

Reports of similar success with testicular spermatozoa in ICSI (Schoysman *et al.*, 1993; Craft *et al.*, 1993; Devroey *et al.*, 1995; Silber *et al.*, 1995a) were also published. The technique was called testicular sperm extraction (TESE) and is a relatively simple procedure without the need for microsurgical expertise. It was also subsequently shown that frozen-thawed epididymal and testicular spermatozoa could be used very successfully in ICSI (Devroey *et al.*, 1994; Gil-Salom *et al.*, 1996; Friedler *et al.*, 1997). Another breakthrough came when it was shown that even in men with testicular failure (maturation arrest, Sertoli cell-only syndrome, testicular atrophy, and even Klinefelter's syndrome), small numbers of spermatozoa or spermatids could be found and be used successfully in ICSI (Devroey *et al.*, 1995; Silber *et al.*, 1995b, 1996). This brought with it however, the risk of transmitting the possible underlying cause of the azoospermia to the resultant offspring (De Wert, 1998). Pre-implantation diagnosis techniques (Liebaers *et al.*, 1998) and genetic counselling became relevant especially in pregnancies from CAVD and non-obstructive azoospermic men (Liu *et al.*, 1994b; Silber *et al.*, 1998; De Wert, 1998; Liebaers *et al.*, 1998)

ICSI with haploid "round cells" (spermatids) from non-obstructive azoospermic men have been done with limited success (Sofikitis *et al.*, 1998) and are currently less successful than ICSI with testicular spermatozoa.

One of the concerns of ICSI fertilization, especially with testicular spermatozoa and spermatids, was the normality of the children born. Several studies concluded that so far, no increase in the incidence of major congenital abnormalities have been found (Bonduelle *et al.*, 1998; Tarlatzis *et al.*, 1998; Silber *et al.*, 1998), which is very reassuring. There is however a slightly increased risk reported in sex chromosomal abnormalities (1%) in fetuses from ICSI.

In the early nineties, at the Reproductive Biology Unit, Tygerberg Hospital, PZD and SUZI were also the first techniques implemented for patients with a severe male factor. But similar to the rest of the world, results were not very promising. Fertilization rates of 20 - 30% were achieved, but embryo transfers did not result in any pregnancies. In 1994, ICSI was started and initial fertilization rates were low (30%) and no pregnancies resulted. It was only after the implementation of sperm immobilization, cytoplasmic aspiration and good quality microtools that the fertilization rate increased to 60%. The first pregnancy was reported in January 1995 after ICSI with testicular spermatozoa.

Five years later in the year 2000, more than 600 ICSI stimulation cycles have been performed (including more than 150 cycles with testicular spermatozoa) and the fertilization rate has increased to more than 70%. One hundred and twenty eight (128) pregnancies have been reported; 74 pregnancies resulted in the birth of 93 healthy babies and 15 pregnancies are still ongoing. No increase in congenital abnormalities (minor or major) has been experienced and ICSI is implemented with great success for severe male factor infertility at the Reproductive Biology Unit at Tygerberg Hospital.

## References

- Bonduelle, M., Wilikens, A., Buysse, A. *et al.* (1998) A follow-up study of children born after intracytoplasmic sperm injection (ICSI) with epididymal and testicular spermatozoa and after replacement of cryopreserved embryos obtained after ICSI. *Hum. Reprod.*, **13**, (Suppl. 1) 196-207.
- Cohen, J., Malter, H., Fehilly, C. *et al.* (1988) Implantation of embryos after partial opening of oocyte zona pellucida to facilitate sperm penetration. *Lancet*, **2**, 162.
- Craft, I., Bennett, V. and Nicholsson, N. (1993) Fertilizing ability of testicular spermatozoa. *Lancet*, **349**, 846.
- De Wert, G.M.W.R. (1998) Ethics of intracytoplasmic sperm injection: proceed with care. *Hum. Reprod.*, **13**, (Suppl. 1) 219-227.
- Devroey, P., Silber, S., Nagy, Z., *et al.* (1994) Ongoing pregnancies and birth after intracytoplasmic sperm injection (ICSI) with frozen-thawed epididymal spermatozoa. *Hum. Reprod.*, **10**, 903-906.
- Devroey, P., Liu, J., Nagy, Z., *et al.* (1995) Pregnancies after testicular extraction (TESE) and intracytoplasmic sperm injection (ICSI) in non-obstructive azoospermia. *Hum. Reprod.*, **10**, 1457-1460.
- Friedler, S., Raziell, A., Soffer, Y. *et al.* (1997) Intracytoplasmic injection of fresh and cryopreserved testicular spermatozoa in patients with non-obstructive azoospermia – a comparative study. *Fertil. Steril.*, **68**, 892-897.
- Gil-Salom, M., Romera, J., Minguez, Y. *et al.* (1996) Pregnancies after intracytoplasmic sperm injection with cryopreserved testicular spermatozoa. *Hum. Reprod.*, **11**, 1309-1313.
- Harimoto, Y. (1966) Microinjection of the live spermatozoa into sea urchin eggs. *Exp. Cell Res.*, **27**, 416-426.
- Hosoi, Y., Miyake, M., Utsumi, K. *et al.* (1988) Development of rabbit oocytes after microinjection of spermatozoa. In: *Proceedings of the 11<sup>th</sup> International Congress on Animal Reproduction and Artificial Insemination*. Abstr. 331.
- Iritani, A. (1998) Micromanipulation of oocytes and embryos. In: *Proceedings of 13th World Congress on Fertility and Sterility*, Marrakech, Marocco. Oct 1989. Parthenon Publishing, Carnforth, UK.
- Joris, H., Nagy, Z., Van de Velde, H. *et al.* (1998) Intracytoplasmic sperm injection: laboratory set-up and injection procedure. *Hum. Reprod.*, **13**, (Suppl. 1) 76-86.
- Lanzendorf, S.M., Slusser, J., Maloney, M.K. *et al.* (1988) A preclinical evaluation of pronuclear formation by microinjection of human spermatozoa into human oocytes. *Hum. Reprod.*, *Update*, **4**, 43-56.
- Liebaers, I., Sermon, K., Staessen, C. *et al.* (1998) Clinical experience with pre-implantation genetic diagnosis and intracytoplasmic sperm injection. *Hum. Reprod.*, **13**, (Suppl. 1) 186-195.
- Liu, J., Nagy, Z., Joris, H. *et al.* (1994a) Intracytoplasmic sperm injection does not require a special treatment of spermatozoa. *Hum. Reprod.*, **9**, 1127-1130.
- Liu, J., Lissens, W., Silber, S.J., *et al.* (1994b) Birth after pre-implantation diagnosis of the cystic fibrosis  $\Delta F508$  mutation by polymerase chain reaction in human embryos resulting from intracytoplasmic sperm injection with epididymal sperm. *J. Am. Med. Assoc.*, **23**, 1858-1860.
- Mansour, R. (1998) Intracytoplasmic sperm injection: state of the art technique. *Hum. Reprod. Update*, **4**, 43-56.
- Nagy, Z.P., Liu, J., Joris, H. *et al.* (1995) The result of intracytoplasmic sperm injection is not related to any of the three basic sperm parameters. *Hum. Reprod.*, **10**, 1123-1129.
- Palermo, G., and Van Steirteghem, A.C. (1991) Enhancement of acrosome reaction and subzonal insemination of a single spermatozoon. *Mol. Reprod. Dev.*, **30**, 339-345.

- Palermo, G., Joris, H., Devroey, P. *et al.* (1992a) Induction of acrosome reaction in human spermatozoa used for subzonal insemination. *Hum. Reprod.*, **7**, 248-254.
- Palermo, G., Joris, H., Devroey, P. *et al.* (1992b) Pregnancies after intracytoplasmic sperm injection of single spermatozoon into the oocyte. *Lancet*, **340**, 17-18.
- Schoysman, R., Vanderzwalmen, P., Nijs, M. *et al.* (1993) Pregnancy after fertilization with testicular sperm (letter). *Lancet*, **342**, 1237.
- Silber, S.J., Nagy, Z.P., Liu, J. *et al.* (1994) Conventional in-vitro fertilization versus intracytoplasmic sperm injection for patients requiring microsurgical sperm aspiration. *Hum. Reprod.*, **9**, 1705-1709.
- Silber, S.J., Van Steirteghem, A.C., Liu, J. *et al.* (1995a) High fertilization and pregnancy rate after intracytoplasmic sperm injection with spermatozoa obtained from testicle biopsy. *Hum. Reprod.*, **10**, 148-152.
- Silber, S.J., Van Steirteghem, A.C., and Devroey, P. (1995b) Sertoli cell only revisited. *Hum. Reprod.*, **10**, 1031-1032.
- Silber, S.J., Van Steirteghem, A.C., Nagy, Z.P. *et al.* (1996) Normal pregnancies resulting from testicular sperm extraction and intracytoplasmic sperm injection for azoospermia due to maturation arrest. *Fertil. Steril.*, **55**, 110- 117.
- Silber, S.J. (1998) Intracytoplasmic sperm injection today: a personal review. *Hum. Reprod.*, **13**, (Suppl. 1) 208-218.
- Sofikitis, N., Miyagawa, I., Yamamoto, Y. *et al.* (1998) Micro-and macro-consequences of ooplasmic injections of early haploid male gametes. *Hum. Reprod. Update*, **4**, 197-212.
- Tarlatzis, B.C. and Bili, H. (1998) Survey on intracytoplasmic sperm injection: report from the EHSRE ICSI Task Force. *Hum. Reprod.*, **13**, (Suppl. 1) 165-117.
- Tournaye, H., Devroey, P., Liu, J. *et al.* (1994) Microsurgical epididymal sperm aspiration and intracytoplasmic sperm injection: a new effective approach to infertility as a result of congenital bilateral absence of the vas deferens. *Fertil. Steril.*, **61**, 1045 - 1051.

## FERTILIZATION FAILURE IN INTRACYTOPLASMIC SPERM INJECTION (ICSI) – A LITERATURE REVIEW.

**Windt M-L**

Reproductive Biology Unit, Department of Obstetrics and Gynaecology, University of Stellenbosch, Tygerberg Hospital, TYGERBERG, South Africa.

### **Abstract**

**T**his review focusses on the possible reasons for fertilization failure in intracytoplasmic sperm injection (ICSI). The literature survey concluded that the major cause for fertilization failure is failure of oocyte activation. Contributing factors are cytogenetic abnormalities in the oocyte and spermatozoon; female age; laboratory conditions; oocyte morphology; ICSI technique and specific spermatozoal and oocyte defects. When normal gametes are available and culture conditions are optimal, the ICSI injection technique seems to be the most important factor in fertilization success.

- 1. Introduction**
- 2. Principles of normal oocyte activation**
- 3. Intracytoplasmic sperm injection (ICSI): Mechanism of oocyte activation and fertilization in ICSI**
- 4. Fertilization failure in ICSI**
  - 4.1 Oocyte Activation Failure in ICSI
  - 4.2 Cytogenetic and Cytological Abnormalities in the Oocyte and Sperm cell
  - 4.3 Female / Male age
  - 4.4 Laboratory Conditions
  - 4.5 Oocyte Morphology
  - 4.6 Technique
  - 4.7 Spermatozoa defects
  - 4.8 Testicular and Epididymal Spermatozoa
  - 4.9 Round sperm/Spermatids
- 5. Concluding Remarks**



## 1. Introduction

Human fertilization begins when a haploid, acrosome-intact spermatozoon binds to the zona pellucida of a metaphase II oocyte. The acrosome reaction takes place and the spermatozoon penetrates the zona. The sperm head now attaches to the oolemma at the site of its equatorial segment. Fusion of the two membranes takes place and initiates a series of membrane and ooplasmic reactions. Cortical granules are extruded and the cytoskeleton of the oocyte cortex is activated to incorporate the sperm cell in a process similar to phagocytosis. During the cortical reaction, intracellular  $\text{Ca}^{2+}$  is also released and the oocyte is now regarded as "activated". Under the influence of factors in the oocyte the sperm nucleus decondenses. The decondensed nucleus develops into a membrane-surrounded pronucleus. This co-incides with decondensation of maternal chromatin and formation of the female pronucleus. The two pronuclei enlarge and move towards each other, the pronuclear membranes disappear and the sperm centriole divides to form the centrosomes of the first cleavage spindle. The male and female chromosomes condense, associate with the microtubules and form the spindle of the first cleavage division (Küpker *et al.*, 1998a).

Any defect in any of these events will result in failed or abnormal fertilization.

In human IVF, fertilization failure can be attributed to failure or dysfunction of certain prerequisite factors and events, especially concerning sperm-oocyte interaction. Functional events include sperm capacitation (hyperactivation); acrosome reaction; sperm-zona binding; sperm-zona penetration; sperm-oolemma fusion and sperm decondensation. Semen parameters such as sperm concentration, motility, morphology and acrosomal enzymes can influence the functional events of fertilization (Coetzee *et al.*, 1998; Oehninger *et al.*, 1997). These prerequisite factors and events have to be met before the sperm cell can participate in the process of oocyte activation, fertilization and cell division (Gearon *et al.*, 1995).

In general, fertilization failure in IVF that involves normal semen parameters, can be attributed to oocyte defects or abnormalities (Van Wissen *et al.*, 1992). In cases of partial fertilization failure, oocyte immaturity is the most likely cause for non-fertilization (Van Wissen *et al.*, 1992, 1994). Stimulation protocols often fail to achieve perfect oocyte synchrony and both mature and immature oocytes are aspirated. Therefore immature or recently matured oocytes are not able to form pronuclei because of their meiotic or cytoplasmic immaturity (Van Wissen *et al.*, 1992, 1994). On the other hand, fertilization failure in male factor cases can be caused by inherent sperm dysfunction and poor semen parameters resulting in poor zona binding and penetration (Van Wissen *et al.*, 1992, 1994; Van Blerkom *et al.*, 1994). A study by Van Blerkom *et al.* (1994) using confocal laser microscopy, showed however that a certain percentage of unfertilized oocytes are indeed penetrated by spermatozoa, irrespective of the semen parameters. Penetrating spermatozoa were condensed or only partially decondensed. This observation could be explained by a subtle sperm abnormality (structural, biochemical, genetic) not determined by conventional semen analysis, or also by an oocyte deficiency resulting in its inability to promote sperm decondensation (Van Blerkom *et al.*, 1994). The study also suggested that the oocyte's cytoplasmic capacity to decondense sperm DNA may decline more rapidly than the ability of the oocyte to be penetrated (Van Blerkom *et al.*, 1994).

For the male with severe male factor infertility, these barriers to normal sperm-oocyte interaction and fertilization posed a real problem. But with the introduction of intracytoplasmic sperm injection (ICSI), treatment for these individuals became a reality (Van Steirteghem *et al.*, 1993 a,b).

In this review, reasons for fertilization failure will be highlighted. Special emphasis will be placed on the principles of oocyte activation, the ICSI technique and factors affecting fertilization outcome in ICSI.

## 2. Principles of normal oocyte activation

### 2.1 Characterization

Oocyte activation in the mature human oocyte, is characterized by cortical granule exocytosis, release from metaphase II arrest and the subsequent extrusion of the second polar body, followed by pronuclear formation and cytoskeletal changes (Homa *et al.*, 1993; Meng and Wolf, 1997; Palermo *et al.*, 1997). In IVF, the fusion of the sperm and oocyte membranes acts as the physiological trigger of oocyte activation (Homa *et al.*, 1993; Tesarik *et al.*, 1994), resulting in a series of  $\text{Ca}^{+2}$  oscillations or repetitive waves recurring for several hours (Homa *et al.*, 1993; Tesarik *et al.*, 1994).

Activation is therefore controlled and regulated by changes in the intracellular, free  $\text{Ca}^{+2}$ . It has also been shown that parthenogenetic development of oocytes is associated with only monotonic increases in  $\text{Ca}^{+2}$ , whereas normal fertilization always shows repetitive wavelike  $\text{Ca}^{+2}$  oscillations (Homa *et al.*, 1993). Calcium oscillations are therefore vital components in normal mammalian fertilization. It can be measured using a calcium sensitive photo-protein and in a study by Taylor *et al.* (1993), it was shown for the first time that in oocytes inseminated with spermatozoa, typical calcium oscillations, associated with normal fertilization, started 20-35 minutes after insemination. Control oocytes (no spermatozoa added) failed to show any oscillation (Taylor *et al.*, 1993). The exact mechanism of all the processes in oocyte activation, is however, still controversial and different mechanisms have been proposed (Sousa *et al.*, 1997).

### 2.2 Mechanism

#### 2.2.1 Hormone-like mechanism

One hypothesis proposes that the sperm cell act like a hormone molecule and bind to specific receptors on the oocyte plasma membrane. G-proteins are stimulated and in turn stimulate phospholipase C, subsequently yielding inositol (1,4,5)-triphosphate ( $\text{InsP}_3$ ).  $\text{InsP}_3$  acts as an intracellular  $\text{Ca}^{2+}$ -releasing, second messenger. This hypothesis still poses many unanswered questions (Homa *et al.*, 1993; Taylor *et al.*, 1993; Tesarik, 1994; Swann *et al.*, 1994; Taylor, 1994; Homa and Swann, 1994; Dozortsev *et al.*, 1995; Parrington *et al.*, 1996; Gearon *et al.*, 1995; Meng and Wolf, 1997; K pker *et al.*, 1998a).

#### 2.2.2 Cytosolic sperm factor mechanism

An alternative hypothesis is that the sperm cell first fuses with the oocyte and then release a soluble factor directly into the ooplasm, initiating the  $\text{Ca}^{+2}$  oscillations and the oocyte activating cascade (Homa *et al.*, 1993; Taylor *et al.*, 1993; Tesarik *et al.*, 1994; Swann *et al.*, 1994; Homa and Swann, 1994; Dozortsev *et al.*, 1995; Meng and Wolf, 1997; K pker *et al.*, 1998a).

The injection of cytosolic extracts from human spermatozoa triggered  $Ca^{+2}$  oscillations accompanied with hyper-polarization in human oocytes (Homa and Swann, 1994) and indicated an active soluble sperm factor. In this and other similar studies it was also shown that cytosolic extracts from hamster spermatozoa had the same effect indicating that the sperm factor is not species specific (Homa and Swann, 1994; Dozortsev *et al.*, 1995; Palermo *et al.*, 1997). The data showed that the oscillations seen after injection of a sperm extract were not caused by the procedure itself (Homa and Swann, 1994; Palermo *et al.*, 1997) and also not by the injection of  $Ca^{+2}$  containing solutions (Tesarik and Sousa, 1995b). Human spermatozoa contain therefore a factor that is sperm specific and trigger  $Ca^{+2}$  oscillations by releasing  $Ca^{+2}$  directly from intracellular stores. The data support the view that human oocytes are activated at fertilization by the diffusion of a protein from spermatozoa into the ooplasm after membrane fusion (Homa and Swann, 1994). Flaherty *et al.*, (1995b), however, commented on the fact that they observed that the process of injection and especially the breakage of the oolemma, might initiate activation.

Meng and Wolf, (1997) used the rhesus monkey model to study sperm-induced oocyte activation. The rhesus monkey's reproductive physiology is very similar to that of the human. Their conclusions were similar to the work done on the human. They used the distribution and behavior of microtubules as a marker for oocyte activation (activated oocytes had long, radiating microtubule bundles throughout the cytoplasm compared to tubulin staining restricted to the spindle region in unactivated oocytes). Their results showed that oocyte activation is accompanied by an extensive rearrangement of the cytoplasmic microtubule network; that at least a sperm head is needed for activation (tail and sham injections were ineffective); and that sperm extract (equivalent to 2-5 sperm cells) also induced oocyte activation.

It was also reported recently that a cytosolic 33-kDa protein isolated from hamster spermatozoa was able to induce calcium oscillations when injected into mouse oocytes. The protein was named oscillin. This protein apparently exists in the equatorial segment of the sperm head and it was postulated that a protein similar in structure and function might be present in human spermatozoa (Parrington *et al.*, 1996).

### **3. Intracytoplasmic sperm injection (ICSI): Mechanism of oocyte activation and fertilization in ICSI**

#### **3.1 Introduction**

In ICSI a single spermatozoon is injected directly into the cytoplasm of the oocyte. Sperm binding and oolemma fusion became redundant and to a certain extent so did many of the events of fertilization as we understood them for IVF. ICSI therefore bypasses both requirements for normal fertilization: the binding and penetration of the zona pellucida and also binding and fusion with the oolemma (Gearon *et al.*, 1995; Dozortsev *et al.*, 1997). The events inside the oocyte, however, still have to take place. ICSI has provided a research opportunity into the mechanisms involved in sperm-induced oocyte activation and cell cycle control. An understanding of how fertilization takes place after ICSI is essential to understand why fertilization failure still take place in this technique that has changed and revolutionized the treatment of severe male infertility, forever (Mansour, 1998; Silber, 1998).

The success of ICSI treatment in severe male infertility indicates that the injection of a spermatozoon into the ooplasm seems to be sufficient for oocyte activation. The injection process has to initiate a calcium discharge in some or other way. The proposed possibility that increased calcium concentrations present in the injection medium and injected together with the sperm cell, can initiate activation, was shown to be not true (Edwards, 1993; Tesarik *et al.*, 1994). This poses the question as to the possible mechanism of oocyte activation following ICSI. Understanding thereof will also elucidate the possible reasons for fertilization failure despite the insertion of a sperm cell inside the oocyte cytoplasm.

### 3.2 Mechanism and sperm associated oocyte activating factor (SAOAF)

Oocyte activation in ICSI, associated with  $\text{Ca}^{+2}$  changes was studied by Tesarik *et al.* (1994) using confocal laser scanning microscopy. An increase in intracellular calcium was observed at the time of needle penetration. This increase was not associated with oocyte activation and was probably due to leakage of calcium ions from the surrounding medium at the site of injection (Taylor, 1994; Tesarik *et al.*, 1994). The same reaction was observed when only a needle was inserted into the oocyte and also when oocytes were injected with calcium-free medium. Oocytes injected with spermatozoa, however, showed a second  $\text{Ca}^{+2}$  change after a lag period of 4-12 hours, post injection. The change was sperm dependent and was either oscillatory (similar to normal fertilization) or non-oscillatory (similar to parthenogenetic activation). It was concluded that the presence of the sperm cell was necessary for oocyte activation and findings supported the view that a factor from the spermatozoon released into the cytoplasm, initiated oocyte activation (Tesarik *et al.*, 1994). Calcium oscillations and therefore oocyte activation in ICSI, occurs only after a long time (Taylor, 1994; Tesarik *et al.*, 1994; Tesarik and Sousa, 1995a; Dozortsev *et al.*, 1997). The delay can be explained since the sperm plasma membrane has to be removed before the sperm activating factor can be released (Swann *et al.*, 1994). Dozortsev *et al.* (1997) also noted that the necessity for sperm nuclear swelling to take place before sperm associated oocyte activating factor (SAOAF) can be released from the sperm cell, can explain the delay in calcium oscillations after ICSI.

### 3.3 G protein/ phospholipase C pathway

Although oocyte activation in ICSI favours the hypothesis of a soluble sperm factor, Tesarik, (1994) reported that interaction between the sperm and oocyte membranes and therefore the involvement of the G protein/ phospholipase C pathway, should not be eliminated (Taylor, 1994). According to the authors, part of the sperm tail remains outside the oocyte and is in contact with the oolemma. There is also a type of fusion between gamete membranes (though physically different from normal fertilization) at the time when the puncture canal is sealed (Ng *et al.*, 1993; Tesarik, 1994).

### 3.4 Soluble sperm factor

In the majority of studies it is however concluded that the success of ICSI favours the soluble sperm factor hypothesis, where the bypassing of membrane binding and fusion events, still results in oocyte activation (Swann *et al.*, 1994). This sperm factor is thought to be a soluble protein, located in the head of the sperm cell, but not in the acrosome. Dozortsev *et al.* (1995) investigated the role of the human spermatozoon in oocyte activation after ICSI, and also its probable mechanism. Pronuclear formation after injection of: a) initially motile spermatozoa, b)

immotile (dead) spermatozoa, c) human sperm cytosolic factor (SCF) and d) sham ICSI were 61%, 0%, 70% and 13% respectively (Dozortsev *et al.*, 1995). Their conclusion was that initially motile (and therefore vital) spermatozoa contribute to oocyte activation and that the sperm releases a factor into the oocyte that is heat-sensitive, intra-cellularly active and not species specific. The question remains whether this factor is sperm specific. Palermo *et al.* (1997) stated that a cell lysate from other tissues (Wu *et al.*, 1997), failed to induce calcium oscillations.

In ICSI, sperm cytosolic factor (SCF) release is facilitated from the permeabilization of the spermatozoal membrane performed during immobilization (Palermo *et al.*, 1997). Dozortsev *et al.* (1997) investigated the possibility of the passive release of the so-called sperm associated oocyte activating factor (SAOAF) after immobilization of the spermatozoon. Spermatozoa were immobilized 4 hours prior to the ICSI in one group and immediately prior to ICSI in a second group. Oocyte activation in the two groups was the same (72% and 73% respectively). This finding indicated that SAOAF was retained in the spermatozoon after immobilization and the release thereof was not a passive process, but dependent on sperm-oocyte interaction (Dozortsev *et al.*, 1997). They also speculated that release of SAOAF might be affected by a sperm nuclear decondensing factor (SNDF) in the oocyte. This decondensing factor can possibly be a low molecular weight, non-peptide molecule such as reduced glutathione, which can indeed cross the sperm plasma membrane (Dozortsev *et al.*, 1997). The removal of injected spermatozoa from the oocyte after 30 minutes did not prevent oocyte activation. This result indicated that SAOAF is released from the sperm cell within 30 minutes after injection (Dozortsev *et al.*, 1997).

The exact way of oocyte activation in ICSI is therefore not totally understood. It is conceivable that membrane interaction may be required to augment the calcium reaction initiated by a soluble sperm factor released inside the ooplasm by the immobilized spermatozoon (Taylor, 1994).

#### **4. Fertilization Failure in ICSI**

##### **4.1 Oocyte Activation Failure in ICSI**

Many studies focused on the possible reasons for fertilization failure in ICSI and concluded that the major cause is failure of oocyte activation. The individual roles of the sperm cell and the oocyte in this kind of fertilization failure are not always clear.

In an ultra-structural transmission electron microscopic study by Sousa and Tesarik (1994) fertilization failure in ICSI was associated with complete failure of oocyte activation. Cortical granules were intact, none of the oocytes showed any signs of resumption of second meiotic division and pronuclei development was arrested. Sperm chromatin was condensed but entirely free of a sperm membrane and therefore accessible to oocyte cytoplasmic factors involved in the chromatin decondensation of sperm cells (Sousa and Tesarik, 1994). The specific role of the spermatozoon or oocyte was not indicated in the study.

#### 4.1.1 Oocyte

A study by Tesarik and Sousa (1995a) also concluded that failure of oocyte activation is the major cause of fertilization failure in ICSI, in this case probably due to an oocyte factor. They treated unfertilized ICSI oocytes with calcium ionophore, an agent well known for its ability to activate oocytes. Their results pointed out that most (91%) of the unfertilized oocytes, were activated after treatment and showed subsequent pronuclear formation and at least one normal cell division. The majority of control oocytes (treated with only diluent) did not become activated (Tesarik and Sousa, 1995a). Other contributing factors, such as the failure of the injected spermatozoon to shed its membrane and failure of sperm chromatin to change into the male pronucleus, can also contribute to fertilization failure. In this study however, this seems unlikely, since such oocytes would probably not react to calcium ionophore.

Flaherty *et al.* (1995a,b; 1998), conducted a study on unfertilized oocytes after ICSI using a fluorescent stain to determine why oocytes remain unfertilized. In this study it was also concluded that the major cause for fertilization failure after ICSI is activation failure (83% of unfertilized oocytes). In most unfertilized oocytes a swollen sperm head was seen at different stages of decondensation, indicating that the injection technique was done correctly, but that oocytes failed to become activated and complete second meiotic division (Flaherty *et al.*, 1995a,b; 1998). Similar results were obtained in a study by Gook *et al.*, (1998). A high percentage of unfertilized oocytes showed decondensed sperm heads, but oocytes remained at metaphase II. The study suggests that for the male pronucleus to form, cytoplasmic conditions, permitting resumption of meiosis, are essential.

#### 4.1.2 Premature chromosome condensation (PCC)

In the normal mature oocyte, arrested at metaphase II, certain chromosome condensing factors are present (i.e. maturation promoting factor [MPF]). A decrease in MPF activity enables the oocyte to complete meiosis after oocyte activation due to sperm entry (Schmiady, *et al.*, 1996; Küpker *et al.*, 1998a). If the oocyte fails to be activated after injection, these condensing factors are still present and can cause premature chromosome condensation (PCC) of the injected spermatozoon. In this condition sperm chromosomes prematurely condense into elongated chromatids in response to the condensing factors. PCC is therefore associated with non-activation of the oocyte and also with oocyte immaturity. (Flaherty *et al.*, 1995b; Van Wissen and Bomsell-Helmreich, 1994). Studies concluded that reasons for activation failure could be the following: Cytoplasmic immaturity despite being at metaphase II (nuclear maturity); deficiencies or absence of the cytosolic sperm factor in the injected spermatozoon; abnormal calcium oscillations in some oocytes (Flaherty *et al.*, 1995a,b; Sousa *et al.*, 1996a). The final conclusion was that in some human oocytes there is an asynchrony between the maturation processes which result in cytoplasmic competence (ability to decondense the sperm head) and physiological competence (ability to activate) (Flaherty *et al.*, 1995a; Greco *et al.*, 1996).

Premature condensation of male chromatin (PCC) in ICSI is very low and the selection of only MFII oocytes for ICSI can explain this since PCC is associated with oocyte immaturity (Bergère *et al.*, 1995).

### 4.1.3 Sperm cell

A study by Dozortsev *et al.* (1995) indicated that failure of activation and therefore fertilization, might be due to the absence or deficiency of a factor from the injected spermatozoon or the inability of the sperm cell to release this factor. It is also possible that different spermatozoa contain different amounts of active oocyte activating sperm factor. This can then lead to either failure of activation, or to a non-oscillatory (single  $\text{Ca}^{+2}$  increase) pattern associated with parthenogenetic fertilization (Swann *et al.*, 1994). Taylor (1994), put forward the hypothesis that not all sperm cells are designed to achieve oocyte activation and therefore fertilization, and that is why 100% fertilization with ICSI is not probable. Sperm selection with this in mind is therefore of importance.

In a study by Palermo *et al.* (1997) it was concluded that oocytes that stayed unfertilized after ICSI was due to lack of an oocyte activator or a failure of its release. They also stated that the only limit to ICSI (from the sperm) is the use of spermatozoa that do not release a sperm cytosolic factor (SCF). This can be caused either by insufficient permeabilization (immobilization) or an absence of SCF in the selected, injected spermatozoon. They propose the use of this factor together with spermatozoa lacking it and also with immotile spermatozoa and round spermatids (Palermo *et al.*, 1997). A study by Schmiady *et al.* (1996) also suggested that the incidence of PCC in unfertilized ICSI oocytes can be due to non-activation of the oocyte caused by an absence of sperm cytosolic factor (SCF) for the same reasons mentioned above.

## 4.2 **Cytogenetic and cytological abnormalities in the oocyte and sperm cell**

The steps that occur within the cytoplasm of the oocyte after the physical incorporation of the spermatozoon can be arrested at different stages and will ultimately lead to fertilization failure. In a study by Asch *et al.* (1995) these different stages of fertilization arrest were investigated. They suggested that some fertilization failures arise due to specific defects within either the spermatozoon or the oocyte after sperm penetration. In this study 48% of "unfertilized" oocytes were shown to have initiated some aspects of the fertilization process, but were arrested at different stages. These include: metaphase II arrest, arrest after successful incorporation of the spermatozoon, arrest after the formation of the sperm aster (inability to organize the sperm aster microtubules), inability to form the male and female pronuclei and arrest during mitotic and meiotic cell progression. Many of these abnormalities may of course also be true of fertilization failure after ICSI (Asch *et al.*, 1995) (see Table 2 & 3).

A number of studies have focused on the DNA status of the unfertilized oocyte in an attempt to explain the aetiology of partial and total fertilization failure. A DNA fluorescent dye (Hoechst 33342), Giemsa DNA staining, immuno-chemical detection and FISH were used in these studies.

### 4.2.1 Oocytes

The incidence of cytogenetic abnormalities in unfertilized IVF and ICSI oocytes is summarized in Table 1 and varied between 20 and 58% (Van Wissen *et al.*, 1994; Almeida and Bolton, 1994; Bergère *et al.*, 1995; Wall *et al.*, 1996; Martini *et al.*, 1997; Lopes *et al.*, 1998b).

These abnormalities included clumped chromatin or a nucleus instead of metaphase II chromosomes; aneuploidy; hyper- and hypohaploidy; diploidy; disomy; euploidy; chromosome breakage or fragmentation; metaphase II arrest; PCC and a non functional spindle (Van Wissen *et al.*, 1992,1994; Almeida and Bolton, 1994; Asch *et al.*, 1995; Bergère *et al.*, 1995; Schmaidy *et al.*, 1996; Wall *et al.*, 1996; Martini *et al.*, 1997; Frydman *et al.*, 1998; Lopes *et al.*, 1998b; Vatev and Toncheva, 1998 (See Table 2).

Chromosome anomalies have been associated with maternal age, stimulation protocols, oocyte aging, increasing follicular recruitment and the disruption of the spindle and subsequent loss or scattering of chromosomes (Wall *et al.*, 1996; Martini *et al.*, 1997).

**Table 1**  
**Incidence of cytogenetic abnormalities in *unfertilized* IVF and ICSI oocytes**

Incidence of abnormalities (%)	cytogenetic	Reference
20-35 %		Van Wissen <i>et al.</i> (1994)
38.4%		Martini <i>et al.</i> (1997)
45%		Bergère <i>et al.</i> (1995)
37%		Wall <i>et al.</i> (1996)
47-58%		Almeida and Bolton (1994)
24.4%		Lopes <i>et al.</i> (1998b)
22.2%		Vatev and Toncheva (1998)



**Table 2**  
**Specific cytogenetic and cytological abnormalities in unfertilized IVF and ICSI oocytes**

Abnormality	Reference
Abnormal female chromatin (nucleus/clumped chromatin)	Van Wissen <i>et al.</i> (1992,1994)
Aneuploidy	Almeida and Bolton (1994); Wall <i>et al.</i> (1996); Martini <i>et al.</i> (1997)
Hyper- and hypohaploidy	Bergère <i>et al.</i> (1995); Wall <i>et al.</i> (1996); Martini <i>et al.</i> (1997); Frydman <i>et al.</i> (1998); Vatev and Toncheva (1998)
Diploidy	Almeida and Bolton (1994); Bergère <i>et al.</i> (1995); Frydman <i>et al.</i> (1998)
Chromosome breakage/fragmentation	Bergère <i>et al.</i> (1995); Wall <i>et al.</i> (1996); Lopes <i>et al.</i> (1998b)
Metaphase II arrest	Asch <i>et al.</i> (1995); Bergère <i>et al.</i> (1995)
PCC/immature cytoplasm	Bergère <i>et al.</i> (1995); Schmaidy <i>et al.</i> (1996); Wall <i>et al.</i> (1996); Frydman <i>et al.</i> (1998)
Non-functional spindle	Lopes <i>et al.</i> (1998b)
Disomy	Vatev and Toncheva (1998)
Euploidy	Frydman <i>et al.</i> (1998)

#### 4.2.2 Spermatozoa

ICSI offers treatment in male factor infertility, regardless of the severity of the sperm defect. Since sperm-oocyte membrane interaction became irrelevant in ICSI and physiological selection is bypassed, the selection of the injected spermatozoon is very important.

It has been shown that spermatozoa from oligoastheno-teratozoospermia (OAT) patients (usually treated with ICSI), have increased frequencies of diploidy, autosomal disomy and sex chromosome aneuploidy when compared to fertile control patients (Pang *et al.*, 1998). The data suggests that increased meiotic errors occur in the germ cells of this group of male patients. In another study patients with abnormal semen parameters were shown to have a significantly higher incidence of spermatozoal chromosome abnormalities (diploidy and disomy) when compared to fertile men (Hariprashad *et al.*, 1998). Fertilization and pregnancy rates as well as pregnancy loss in the abnormal semen group and fertile control group were however not affected and were similar (Table 3).

The rate of chromosomal aneuploidy in testicular spermatozoa was shown to be significantly higher than that from fertile donor spermatozoa (Levron *et al.*, 1998). In testicular spermatozoa, the non-obstructive group showed a higher aneuploidy incidence than the obstructive group. A linkage between gonadal failure (increased FSH levels) and gamete aneuploidy was implied in this study (Levron *et al.*, 1998).

In a study by Lopes *et al.* (1998a), the "terminal transferase-mediated deoxyuridine triphosphat-biotin end labeling assay" was used to show DNA fragmentation in spermatozoa used in ICSI. Their results showed that an increased incidence of DNA fragmentation correlated negatively with ICSI fertilization rates, sperm morphology and motility. The study suggests that ICSI selected spermatozoa may come from a sample with a high incidence of fragmented DNA, which may influence sperm decondensation and therefore fertilization. In another study by Lopes *et al.* (1998b), DNA fragmentation in both spermatozoa and oocytes were shown to be associated with fertilization failure in ICSI. It was shown that 50% of unfertilized oocytes contained chromatin with damaged DNA (25.8% from the spermatozoon and 24.4% from the oocyte). The incidence of damaged DNA was higher in condensed compared to decondensed spermatozoa. DNA fragmentation in spermatozoa may possibly contribute to fertilization failure in ICSI because DNA damage may prevent decondensation, and fragmentation may be associated with the loss of the oocyte activating factor (see Table 3).

**Table 3**  
**Effect of spermatozoal abnormalities (cytogenetic, cytological and structural) on fertilization**

Abnormality	Effect	Reference
DNA fragmentation/damaged DNA	↓ sperm morphology ↓ sperm motility ↓ sperm decondensation ↓ oocyte activating factor ↓ fertilization	Lopes <i>et al.</i> (1998a,b)
Abnormal sperm centrosome, aster microtubule growth and positioning.	Metaphase II arrest	Asch <i>et al.</i> (1995)
Diploidy, autosomal disomy, sex chromosome aneuploidy	OAT- ↓ sperm morphology ↓ sperm motility ↓ sperm concentration	Pang <i>et al.</i> (1998)
Diploidy, disomy	No effect on fertilization and pregnancy rates.	Hariprashad <i>et al.</i> (1998)

### 4.3 Female / male age

#### 4.3.1 Female

It is well known that maternal age plays an important role in the outcome (fertilization, embryo quality and pregnancy) of IVF and also of ICSI (Oehninger *et al.*, 1995; Abdelmassih *et al.*, 1996; Devroey *et al.*, 1996; Van de Velde *et al.*, 1997; Silber *et al.*, 1997; Spandorfer *et al.*, 1998).

From the study by Abdelmassih *et al.* (1996), it was clear that in ICSI, the ongoing pregnancy rate dropped significantly after the age of 35 years, indicating possibly oocyte and endometrial aging. In this specific study (Abdelmassih *et al.*, 1996) however, fertilization rates in the four age groups analysed, were not different. Oocyte quality, if age related, did therefore not reflect in the fertilization and cleavage rates after ICSI, but possibly in embryo viability and therefore in pregnancy results. A study by Yie *et al.* (1996) with IVF showed different results. A significant increase in failed IVF fertilization for patients over 37 years of age was found. This was, according to the authors, indicative of loss of competence due to a higher incidence of chromosome abnormalities in oocytes from older women, possibly explaining the lower fertilization rates in older women in their study.

The effect of female age and ovarian reserve in ICSI cycles was also investigated by Silber *et al.* (1997). The male partners in the study were all azoospermic. Maternal age and ovarian reserve (number of eggs) had no influence on fertilization rates, but did dramatically affect the implantation, pregnancy and delivery rates (Silber *et al.*, 1997). In a study by Alrayyes *et al.* (1997), it was shown those women older than 37 years yielded fewer embryos than younger women, when treated with ICSI. Cycles that yielded fewer than four embryos came from older patients with a lower number of oocytes retrieved and their fertilization rate was low. This can possibly be because the older ovary is less responsive and oocytes may have cytoskeletal defects that can impair fertilization. However, older women with a good ovarian response, can achieve fertilization and pregnancy rates similar to those of younger patients (Alrayyes *et al.*, 1997).

#### 4.3.2 Female and male

In a retrospective study Spandorfer *et al.* (1998) investigated the influence of maternal and paternal age on ICSI outcome. An increase in digyny (triploidy with an extra haploid set of female origin) was noted with an increase in paternal age, but none of the other outcomes were affected. Normal fertilization did not vary with maternal age, but younger women had a higher incidence of 1 PN formation whereas older women had more 3 PN oocytes (Ergun *et al.*, 1998; Spandorfer *et al.*, 1998). This can be explained by the increased resistance to oocyte activation and decreased ability to extrude the second polar body in oocytes of older women. Ergun *et al.* (1998) also reported that female age impairs ICSI outcome by reducing the ovarian response, producing fewer oocytes and thus fewer embryos.

A study on unfertilized oocytes showed that maternal age did not influence the incidence of aneuploidy (Wall *et al.*, 1996), but Lopes *et al.* (1998b) reported that oocytes from women older than 35 years, had a significantly higher incidence of DNA fragmentation compared to women younger than 35 years.

## 4.4 Laboratory Conditions

### 4.4.1 General laboratory conditions

Mansour (1998) highlights all the important factors influencing the effect of laboratory conditions in a review on the ICSI procedure.

The influence of sub-optimal culture conditions in the *in vitro* culture of human oocytes is well known to have a negative influence on fertilization (Matson, 1998). When ICSI is performed, additional handling and exposure (cumulus removal, washing, micromanipulation), is unavoidable. In ICSI, oocytes are exposed to factors such as hyaluronidase treatment, intense light and the creation of an artificial breach in the zona and oolemma (Palermo *et al.*, 1996a). These procedures can potentially introduce toxins and debris and compromise fertilization and normal embryo development.

Extra care and precaution should also be taken with regards to temperature, pH and osmolarity changes in the handling of ICSI oocytes. Sub-optimal culture conditions such as a pH shift in the medium might block the oocytes from further development and can also be the cause of PCC and fertilization failure (Schmiady *et al.*, 1996). Micro-droplets used in the injection and incubation processes must be covered very quickly with pre-equilibrated mineral oil to avoid the extremely fast evaporation (Svalander *et al.*, 1995) of the medium.

### 4.4.2 Polyvinylpyrrolidone (PVP)

The use of PVP also raised concerns with regards to abnormal embryos and also possibly abnormal fertilization (Palermo *et al.*, 1996a; Mansour, 1998). It is therefore important to be aware of these unique conditions in the ICSI laboratory. In assisted reproduction, especially in ICSI, PVP is used to increase the viscosity of the sperm sample, thus facilitating the handling of the sperm cells. It reduces the sperm motility, prevent sticking to the inner surface of the injection pipette and gives better control of the volume injected with the spermatozoon into the ooplasm (Liu *et al.*, 1995). There are however also certain negative effects of PVP. It has also been shown to stabilize the sperm plasma membrane (Dozortsev *et al.*, 1997; Strehler *et al.*, 1998), delay calcium oscillations, prevent nuclear decondensation and DNA lesions. Strehler *et al.* (1998) investigated the effect of PVP on the ultrastructure of the sperm membrane and concluded that it has a detrimental action on the plasma membrane as well as the acrosomal and mitochondrial membrane. Other possible negative effects of PVP are deterioration of chromatin, axonemal tubules and the fibrous sheath. Incubation time to exert these effects was 30 minutes. It is therefore important to expose spermatozoa to PVP for a short period of time and to inject as little as possible PVP into the oocyte (Strehler *et al.*, 1998). Injection of excessive amounts of PVP can compromise ICSI fertilization (Dozortsev *et al.*, 1997). PVP can also change the behaviour of other substances in its vicinity, and therefore interfere with sperm nucleus decondensation and fertilization.

### 4.4.3 Hyaluronidase

The effect of hyaluronidase, used to remove the cumulus cells from oocytes destined for ICSI, was investigated in a study by Van de Velde *et al.* (1997). Although their results showed no statistical difference in fertilization rates and other outcomes for the different conditions tested, (enzyme concentration and time exposed to the enzyme), they advise to use the lowest

concentration and shortest exposure possible. It is not known how hyaluronidase affects the outcome with regards to the development of the fetus and hyaluronidase can also be instrumental in the development of one and three pronuclear oocytes (Van de Velde *et al.*, 1997).

#### 4.4.4 Pre-incubation time

The effect of pre-incubation time on ICSI success was recently addressed in two reports. Culture of oocytes before injection is thought to be beneficial for the completion of oocyte maturation and is usually standardized at 5-5.5h. Yanagida *et al.* (1998) showed that incubation times of 1-9 hours gave the same results in ICSI. Pre-incubation times more than 9 hours resulted in a decrease of good quality embryos. In a similar study by Rienzi *et al.* (1998), both fertilization rates and number of good quality embryos were improved if preincubation times were more than 3 hours. These studies suggest the oocytes should be incubated (in their cumulus mass) for at least 3 hours to achieve full cytoplasmic maturation before ICSI is performed.

Total fertilization failure in ICSI is rare, but does occur. Moomjy *et al.* (1998) investigated this occurrence and the results of follow-up cycles. In most cases it was possible to do a transfer in subsequent cycles. Sub-optimal laboratory conditions can give a possible explanation for this phenomenon. It was however concluded that although unexplained, inter-cycle fluctuations in gamete quality are contributory.

### 4.5 Oocyte morphology

Fertilization failure in IVF is most often associated with sperm-related problems. This is especially true for total fertilization failure or where only a minority of oocytes is fertilized. In the case of partial fertilization failure, where the majority of oocytes are fertilized, unfertilized oocytes are usually associated with an egg factor. The effect of the oocyte morphology on fertilization is summarized in Table 4.

Bedford and Kim (1993) concluded that fertilization failure can be interpreted largely on the basis of gamete dysfunction. Although the absence of penetration of the zona pellucida by normal spermatozoa is a major cause for total fertilization failure, the study also suggested that the resistant zona often reflect some underlying abnormality in the oocyte. The zona is a secretory product of the oocyte and its impenetrability is often associated with a number of ooplasmic abnormalities. These anomalies (79,4% of all unfertilized oocytes without a sperm factor), include refractile bodies, extra chromosomes, chromatin rings or masses, 'gaint' eggs, degenerate and vacuolated cytoplasm (Bedford and Kim, 1993).

Defects in oocytes from controlled ovarian hyperstimulation cycles can influence their developmental potential. Metaphase II oocytes are frequently heterogeneous with respect to cytoplasmic organization and appearance. Dysmorphic phenotypes can indicate specific defects in the structure and organization of the ooplasm and are sometimes associated with biochemical and cellular abnormalities. In a study by Van Blerkom (1993), common cytoplasmic dysmorphisms were described and discussed. Some of them are associated with very low developmental potential and aneuploidy. These dysmorphic phenotypes include: granularity, central aggregation of organelles and vesicles ("bull's eye"), vacuoles, intracellular degeneration

(refractile bodies), large, smooth disc-like structure (van Wissen *et al.*, 1992; Van Blerkom, 1993; Veeck, 1991,1999).

When ICSI is performed, cleaning of the oocytes from their surrounding cumulus cells creates the opportunity to study the oocyte morphology in detail. It is also possible to note the type of membrane breakage and correlate that with fertilization outcome (Palermo *et al.*, 1996b).

◆ Granularity

The texture (granularity) of the cytoplasm was not predictive of fertilization failure, with the exception of extremely dark and dense cytoplasm.

◆ Central aggregation of organelles and vesicles ("bull's eye")

Oocytes with a central aggregation of organelles and vesicles ("bull's eye") are usually meiotically mature, but rarely fertilizes successfully and are often aneuploid (Van Blerkom, 1993). This feature appears to be related to an extensive breakdown of the cytoskeletal system and a reduced metabolic rate. It is also usually associated with hMG cycles.

◆ Vacuoles

Multiple vacuoles of varying size can also compromise development. Although vacuolated oocytes sometimes fertilize, they rarely divide. This endocytotic activity is probably associated with cortical cytoskeletal defects (Van Blerkom, 1993) and atresia (Van Wissen *et al.*, 1992).

◆ Intracellular degeneration (refractile bodies)

Intracellular degeneration appears to be membrane bound and has a pit-like appearance similar to the "refractile bodies" described by Veeck (1991,1999). These structures consist of electron-dense lipid-like bodies and can fertilize, but resulting embryos do not implant.

◆ Large smooth disc-like structure

Another type of dysmorphism described by Van Blerkom (1993), is a large smooth disc-like structure in the centre of a MFI oocyte. It is composed of a massive aggregation of saccules of smooth endoplasmic reticulum (SER). These oocytes are not developmentally viable and are often aneuploid. The study conclude that 60% of all unfertilized IVF oocytes will display one of the above dysmorphisms (Van Blerkom, 1993).

◆ Patterns of membrane breakage

Three patterns of membrane breakage in ICSI were investigated and correlated with fertilization and embryo development by Palermo *et al.* (1996b) and Joris *et al.* (1998). Sudden, normal and difficult breakage patterns were identified. The sudden breakage pattern was associated with an increased rate of damage and a decrease in fertilization. In cases where fertilization did take place, extrusion of the second polar body was reduced, resulting in increased numbers of 3PN oocytes. In the other two patterns, results were uneventful and similar. The protective funnel formed in the normal and difficult breakage patterns is characteristic of the membrane structure of the human oolemma. The elasticity of the oolemma lies in its lipoproteic structure and oocytes with a sudden breakage pattern, probably lack this specific structure and resemble the immature (GV) human oocyte and the mouse oocyte- their membranes are very fragile and damage very easily (Palermo *et al.*, 1996b; Moon *et al.*, 1998). Rattanachaiyront *et al.* (1998), however found that oocytes with difficult membrane breakage (increased oolemma elasticity), had significantly lower fertilization rates and higher degeneration rates.

#### 4.5.1 Other anomalies

Although gross morphological oocyte anomalies are associated with fertilization failure, "smaller" anomalies were shown to have no effect on fertilization rate and embryo quality score in a study reported by De Sutter *et al.* (1996). These anomalies included colour, granularity, homogeneity, perivitelline space (PVS) size, dark inclusions, vacuoles, zona colour and irregular shaped oocytes (De Sutter *et al.*, 1996). Only in the case of vacuoles, a sign of degeneration, were fertilization rates decreased. As discussed previously (Van Blerkom, 1993), refractile bodies and the so-called "bull's eye" oocytes are associated with fertilization failure, but the authors conclude that ICSI can overcome this problem since their study resulted in similar fertilization rates in these oocytes and so-called 'ideal' oocytes (De Sutter *et al.*, 1996). Ballesteros *et al.* (1998) also found no correlation between ICSI fertilization rates/embryo quality and the morphological features of oocytes (status of first polar body, size of PVS, vacuoles, cytoplasmic inclusions and cytoplasmic shape). Some of these morphotypes have been associated with IVF fertilization failure, which indicate that ICSI may be the appropriate method of treatment for such oocytes (Ballesteros *et al.*, 1998).

A study by Gabrielsen *et al.* (1996), however indicated that patients with a suspected oocyte factor (poor fertilization in spite of normal spermatozoa from a fertile male) treated with IVF, do not perform better in subsequent ICSI cycles. They concluded that these patients suffer from oocyte defects that can not be alleviated by ICSI. Similar results were found by Tomas *et al.* (1998), indicating that poor outcome in ICSI after previous IVF failure, reflects an intrinsic oocyte defect, not bypassed by ICSI.

Several other authors reported on the correlation of ICSI success and oocyte morphology. Serhal *et al.* (1997) reported that ICSI fertilization was not influenced by abnormal oocyte morphology (granularity, cytoplasmic inclusions like vacuoles, dark centers, refractile bodies), but implantation was significantly reduced. Oocyte morphology (irregular shape, 1PB fragmentation and maturity, PVS size, debris in PVS, vacuoles, granular cytoplasm and zona thickness and inclusions) were not associated with decreased ICSI fertilization rates in several other studies. (Guthauser *et al.*, 1998a,b; Moon *et al.*, 1998; Rattanachaiyanont *et al.*, 1998). Similarly, Balaban *et al.* (1998) also concluded that oocyte morphology (dark zona, large PVS, dark and granular cytoplasm, refractile body, abnormal shape) were not correlated to decreased fertilization or unfavourable embryo quality in ICSI. They stress however that the effect of vacuolated oocytes were not recorded. Guthauser *et al.* (1998b) found that embryos from oocytes with vacuoles had a significantly reduced quality.

Xia (1997) however, found that an immature polar body, enlarged PVS and cytoplasmic inclusions, were significantly related to lower ICSI fertilization rates and embryo quality.

The initial oocyte maturity at aspiration also has an influence on fertilization. De Vos *et al.* (1999) found that the fertilization rate of in vitro matured oocytes (from MF I to MF II within 4 hours of aspiration) was significantly lower when compared with that of aspirated MF II oocytes. This might reflect the in vitro matured oocyte's cytoplasmic immaturity despite their nuclear maturity. Matured oocytes that do fertilize however, have the same potential as aspirated MF II oocytes (De Vos *et al.*, 1999).

**Table 4**  
**Effect of Oocyte morphology on ICSI fertilization rates.**

Oocyte abnormality	Effect on ICSI fertilization (yes/ no)	Reference
Granularity/homogeneity	No	Van Blerkom <i>et al.</i> (1993); De Sutter <i>et al.</i> (1996); Serhal <i>et al.</i> (1997); Balaban <i>et al.</i> (1998); Guthauser <i>et al.</i> (1998a,b); Rattanachaiyanont <i>et al.</i> (1998); Moon <i>et al.</i> (1998); Veeck (1999)
	Yes	-
"Bull's eye (dark centre)	No	De Sutter <i>et al.</i> (1996); Serhal <i>et al.</i> (1997)
	Yes	Van Blerkom <i>et al.</i> (1993); Veeck (1999)
Vacuoles	No	Serhal <i>et al.</i> (1997); Ballesteros <i>et al.</i> (1998); Guthauser <i>et al.</i> (1998a,b); Moon <i>et al.</i> (1998); Rattanachaiyanont <i>et al.</i> (1998)
	Yes	Van Wissen <i>et al.</i> (1992); Bedford and Kim (1993); Van Blerkom <i>et al.</i> (1993); De Sutter <i>et al.</i> (1996); Veeck (1999)
Refractile body	No	Serhal <i>et al.</i> (1997); Balaban <i>et al.</i> (1998)
	Yes	Bedford and Kim (1993); Van Blerkom <i>et al.</i> (1993); Xia (1997); Veeck (1991,1999)
Central disc-like structure	No	Van Blerkom <i>et al.</i> (1993)
	Yes	-
Oocyte colour	No	De Sutter <i>et al.</i> (1996)
	Yes	-
Enlarged PVS	No	De Sutter <i>et al.</i> , (1996); Balaban <i>et al.</i> (1998); Ballesteros <i>et al.</i> (1998)
	Yes	Xia (1997)
Irregular oocyte shape	No	De Sutter <i>et al.</i> (1996); Balaban <i>et al.</i> (1998); Ballesteros <i>et al.</i> (1998); Guthauser <i>et al.</i> (1998a,b); Moon <i>et al.</i> (1998); Rattanachaiyanont <i>et al.</i> (1998); Veeck (1999)
	Yes	-
Dark zona pellucida	No	De Sutter <i>et al.</i> (1996); Balaban <i>et al.</i> (1998)
	Yes	-
Immature, small or large polar body	No	Ballesteros <i>et al.</i> (1998); Guthauser <i>et al.</i> (1998a,b); Moon <i>et al.</i> (1998); Rattanachaiyanont <i>et al.</i> (1998)
	Yes	Xia (1997); Veeck (1999)
Membrane breakage patterns	No	-
	Yes	Palermo <i>et al.</i> (1996b); Joris <i>et al.</i> (1998); Moon <i>et al.</i> (1998); Rattanachaiyanont <i>et al.</i> (1998)



## 4.6 **Technique**

### 4.6.1 Introduction

Since the first pregnancies in ICSI were reported (Palermo *et al.*, 1992; Van Steirteghem *et al.*, 1993a,b), the basic technique has been modified slightly. Today most laboratories apply the following technique: Holding and injection pipettes are made to certain specifications to ensure easy handling combined with accuracy and minimizing damage. Oocytes are cleaned with hyaluronidase, and only metaphase II oocytes are injected. An incubation time of 3-4 hours before injection is allowed and semen samples are washed and motile spermatozoa isolated, using different methods. No extra sperm treatment is necessary, and spermatozoa to be injected are added to 10% polyvinylpyrrolidone (PVP) to facilitate successful injection. A motile spermatozoon is immobilized by touching the sperm tail and aspirated tail-first into the pipette. The polar body is positioned at the 12 or 6 o'clock position and the sperm cell injected at the 3 o'clock position. Ooplasm is aspirated to ensure penetration of the membrane. The technique of ICSI, especially the handling of the spermatozoon and the actual injection into the ooplasm, may play the most important role in the success of fertilization (Ng *et al.*, 1993; Van Steirteghem *et al.*, 1993a,b; Tesarik and Sousa, 1995b; Joris *et al.*, 1998; Mansour, 1998). When this technique fails in any way, fertilization is compromised (Ng *et al.*, 1993; Svalander *et al.*, 1995).

### 4.6.2 General factors

Svalander *et al.* (1995), reported on the factors of importance for the establishment of a successful ICSI program. They found a twofold increase in fertilization rates when standardized injection pipettes, immobilization of the spermatozoon and aspiration of a minimal amount of ooplasm was introduced into their program. A learning curve and accumulation of the technical skill were also found to be important in the outcome of the results. The design and quality of microtools were stressed - blunt or too large injection pipettes can cause damage to the oocyte and can result in too much PVP injected into the oocyte (Liu *et al.*, 1995; Svalander *et al.*, 1995). Vanderzwalmen *et al.* (1996) and Palermo *et al.* (1996a) reported similar results.

### 4.6.3 Spermatozoa located in the perivitelline space.

In a review article by Ng *et al.* (1993) it was concluded that after ICSI, some spermatozoa are located in the PVS or in oolemma-bound vacuoles, isolating the sperm cell from the ooplasm. This can possibly be related to an incorrect injection technique, but also to the oocytes' ability to expel sperm cells, especially acrosome intact spermatozoa. In similar studies by Flaherty *et al.* (1995a,b) it was also postulated that the ejection of the spermatozoon into the PVS after ICSI, could be one of the reasons for failed fertilization. It was however found not to be a major cause of fertilization failure (Lopes *et al.*, 1998b). Spermatozoa were found in the PVS, attached to the outside of the zona near or in the injection hole. Sometimes sperm cells were not seen at all, indicating total ejection into the surrounding medium. This phenomenon can be due to injection technique, but the authors assumed that ejection took place during incubation, since injected sperm cells were always present inside the ooplasm after closure of the injection furrow (Flaherty *et al.*, 1995b). Missing sperm heads in cytogenetic studies (Schmiady *et al.*, 1996) can be explained by the fact that spermatozoa were ejected into the PVS as a consequence of non-breaking of the oocyte membrane.

#### 4.6.4 Immobilization

Immobilization of the spermatozoon causes marked physiological modifications (mechanical and biochemical) in the sperm plasma membrane when the injection needle touches the sperm tail during immobilization. The membrane is destabilized due to the damage to the tail and allows the membrane to become permeable. The permeabilized membrane can permit the release of cytosolic sperm factors into the ooplasm that is able to initiate the activation of the egg (Vanderzwalmen *et al.*, 1996). Fishel *et al.* (1995) stressed the significant increase in fertilization rates and decrease in cytoplasmic fragmentation when a permanently immobilized spermatozoon is used in ICSI. According to their study immobilization has the following possible effects: sperm plasma membrane changes that initiates the acrosome reaction; changes in the spermatozoon required for oocyte activation and prevention of the disruption of the ooplasm by an active sperm tail.

##### 4.6.4.1 Mode of immobilization

The mode of sperm immobilization and its effect on ICSI fertilization was investigated by Palermo *et al.* (1996c). Standard immobilization (maintaining the shape of the tail) was compared to aggressive immobilization (clearly kinked, looped or convoluted sperm tail). The latter showed increased fertilization rates in ejaculated, testicular and especially epididymal spermatozoa. The higher fertilization rates with aggressive immobilization in immature spermatozoa were explained by their different membrane constitution, indicating that immature gametes may require additional manipulation. It was also noted that it is essential to damage the sperm tail of non-motile spermatozoa (Vanderzwalmen *et al.*, 1996) to increase fertilization rate. This is especially true for testicular spermatozoa where the majority of spermatozoa are alive but non-motile because of their immaturity.

##### 4.6.4.2 Immobilization site

Since the entire spermatozoon is covered with the plasma membrane, disruption of its integrity (immobilization) can be at any site. Chen *et al.* (1996), investigated different immobilization techniques (compressing the mid-piece, dissecting the tail-tip and cutting the tail at the mid-portion). The three methods gave the same results with regard to fertilization and damage of injected oocytes and also embryo cleavage. They found the dissecting of the tail-tip to be superior. Sticking of immobilized spermatozoa to the pipette was less, damage to the sperm mid-piece and possibly to the centriole was minimized and the technique proved to be the simplest and easiest.

##### 4.6.4.3 Sperm decondensation

Flaherty *et al.* (1995b) suggested that complete failure of sperm head decondensation after ICSI, is due to incomplete sperm immobilization. In successful immobilization, damage to the membrane enables the glutathione- like activity in the oocyte cytoplasm to access the nucleus of the sperm cell, resulting in decondensation. Insufficient damage can therefore result in failure of sperm head decondensation. In a more recent study published by Dozortsev *et al.* (1997) showed that sperm plasma membrane damage makes the membrane permeable and the sperm nucleus accessible for low molecular weight molecules (and presumably also for the sperm nucleus decondensing factor (SNDF). They also showed that damage induced by immobilization of the sperm cell in ICSI is essential for the onset of nuclear swelling. The sperm associated oocyte activating factor (SAOAF), however, is released during the sperm swelling phase, but only after the induction by the so-called sperm nucleus decondensing factor (SNDF) of the oocyte. Once

again insufficient damage to the sperm membrane can lead to fertilization failure (Vanderzwalmen *et al.*, 1996; Dozortsev *et al.*, 1997). It has been shown previously that the ability of the human oocyte to decondense the sperm nuclei (in ICSI), is time-limited. It was suggested in a study by Dozortev *et al.* (1994), that in some spermatozoa, insufficient sperm membrane damage during immobilization could lead to a time associated inability to access ooplasmic decondensation factors. Similar results were reported by Schmiady *et al.* (1996). The whole sperm cell, enclosed in its membranes is exposed to the ooplasm in the case of ICSI and the behavior of spermatozoa in the cytoplasm might therefore be different when compared to IVF (Schmiady *et al.*, 1996). The different degrees of PCC in unfertilized ICSI oocytes can be explained by the fact that ooplasmic chromosome decondensing factors can migrate into the sperm nucleus inside the unactivated oocyte, and induce PCC. Immobilization and membrane damage is therefore an important prerequisite to ensure normal sperm nucleus decondensation. If ooplasmic factors cannot penetrate the sperm membrane, it will leave the sperm head unchanged. The degree of membrane damage may influence the degree of sperm decondensation and PCC (Schmiady *et al.*, 1996).

#### 4.6.5 Cytoplasmic aspiration

Cytoplasmic aspiration appears to be a prerequisite in ICSI for successful activation and fertilization (Tesarik and Sousa, 1995b; Joris *et al.*, 1998). It is also a very delicate part of the procedure and the crucial factor seems to be the amount of ooplasm aspirated and re-injected into the oocyte (Fishel *et al.*, 1995; Liu *et al.*, 1995; Vanderzwalmen *et al.*, 1996). Here the diameter of the pipette plays an important role - a wider diameter will allow more fluid to be aspirated (Vanderzwalmen *et al.*, 1996). In general, ooplasm has to be aspirated gently until a rapid outflow of cytoplasm is visualized, signaling rupture of the oolemma. The oolemma of the human oocyte is very elastic and it seems from the results from most studies that penetration thereof without cytoplasmic aspiration is not easily achieved. A spike on the tip of the injection pipette seems to help somewhat to make penetration easier.

A study by Mansour *et al.* (1996), however concluded that cytoplasmic aspiration is not essential for oocyte activation and therefore fertilization. They also found an increased rate of damage and cytoplasmic fragments when cytoplasm was aspirated. The authors commented in their study that ooplasmic aspiration as such is not essential for oocyte activation, but merely a way of making sure that the oolemmal membrane is pierced and the sperm cell deposited inside the ooplasm and not in the artificial furrow formed during the injection. Therefore any technique that ensures penetration of the oolemma, will have the potential to facilitate fertilization (Mansour *et al.*, 1996; Mansour, 1998). In a study comparing suction patterns (weak, normal, and strong), it was found that different patterns had no effect on ICSI fertilization rates (Moon *et al.*, 1998).

#### 4.6.6 Orientation of the oocyte

In most laboratories the orientation of the oocyte before injection is such that the polar body is either at the 6 or 12 o'clock position so that the insertion of the injection pipette is at 3 o'clock (Palermo *et al.*, 1996a; Joris *et al.*, 1998; Mansour, 1998). This is done to ensure that as little as possible damage is done to the spindle- assuming that it is situated in the vicinity of the polar body. In some studies the incorrect injection procedure was thought to cause spindle and cytoskeleton disturbances which will lead to arrest at metaphase II and possibly PCC (premature chromosome condensation) (Schmiady *et al.*, 1996).

Cortical granularity (supposedly the site of germinal vesicle breakdown and position of the chromosomes and mitotic spindle) was also mentioned as an area that should be avoided (Mansour *et al.*, 1996; Palermo *et al.*, 1996a). Recent studies showed however that neither the position of the polar body nor the positioning of the granular site had any influence on ICSI outcome (Silva *et al.*, 1999, Zaninovic and Rosenwaks, 1998). Silva *et al.* (1999), using digital polarization microscopy, also found that the polar body does not accurately predict the location of the spindle. The authors suggest that the ability to locate the spindle with this method before injection and avoidance thereof will probably increase ICSI success. They also however say that because of the small size of the injection pipette it will probably not be a likely cause of spindle damage unless excessive aspiration of the cytoplasm during ICSI takes place (Palermo *et al.*, 1996a; Silva *et al.*, 1999). Zaninovic and Rosenwaks (1998) concluded that there are no preferable sites for sperm injection into human oocytes.

Van der Westerlaken *et al.* (1999) came to the conclusion that fertilization rates were significantly increased when ICSI was performed with the injection needle opening towards the animal pole (6 o'clock - first polar body) of the oocyte when compared to the 12 o'clock position [51% vs 45%]. A higher pregnancy rate with embryos resulting from the 6 o'clock injection technique was also found [36% vs. 18%]. Nagy *et al.* (1995c) also reported that injection with the polar body at the 6 o'clock position resulted in a higher number of "transfer quality" embryos (fertilization rate was similar however). These results can possibly be linked to the polarity of human oocytes and the rotation of the cytoplasm after sperm depositing diametrically opposite the metaphase spindle (Edwards and Beard, 1997; Payne *et al.*, 1997; Fluka *et al.*, 1998; Garello *et al.*, 1999). Edwards and Beard (1997) as well as Fluka *et al.* (1998) conclude that the success of ICSI could depend on the correct positioning of the sperm centrosome and the subsequent ooplasm rotation, preparing the oocyte for pronuclear apposition and syngamy.

## **4.7 Spermatozoa defects**

### 4.7.1 Introduction

It is well known that both oocyte and sperm quality play a major role in the success of IVF. In a study done by Plachot *et al.* (1993), zona pellucida function, ooplasmic function and the role of spermatozoa in fertilization was investigated. They identified a few possible reasons for fertilization failure. Oocyte quality, inadequate sperm receptors on the zona, impaired sperm-zona binding, sperm impairment and a mixture of factors was given as reasons. Similar results were reported by Windt *et al.* (1996).

### 4.7.2 Semen parameters

In the case of male factor infertility, semen parameters play a very important role. In IVF, a decrease in sperm concentration, progressive motility and especially morphology, (Tygerberg strict criteria), has been shown to impair fertilization (Nagy *et al.*, 1995b; Hammadah *et al.*, 1996; Tasdemir *et al.*, 1997; Coetzee *et al.*, 1998).

The introduction of ICSI, presently the most efficient technique to treat male factor infertility, made fertilization with very impaired semen parameters possible. Studies by Nagy *et al.* (1995b; 1998) and others concluded that none of the three semen parameters analyzed (sperm concentration, motility and morphology) influenced the outcome of ICSI (Nagy *et al.*, 1995b; 1998; Hammadeh *et al.*, 1996; Küpker *et al.*, 1998b; Sallam *et al.*, 1998;). Morphological abnormal spermatozoa do not necessarily reflect a genetic abnormality of the male gamete, but the inability to penetrate the egg, according to Nagy *et al.*, (1995b). Only one condition, immotile (presumable dead) spermatozoa, had a strong negative influence on ICSI outcome.

There is however some other studies commenting on the influence of semen parameters on ICSI success.

#### 4.7.2.1 Motility

Although sperm motility patterns are thought not to influence fertilization in ICSI, a recent study (Van den Bergh *et al.*, 1998) showed a significant increase in ICSI fertilization (84%vs 68%) when sperm with a higher straight line velocity (VSL) were injected. They suggest that the most motile sperm cell must be selected for ICSI.

#### 4.7.2.2 Morphology

Regarding sperm morphology and its effect on ICSI fertilization, Tasdemir *et al.* (1997) reported that even in cases with 100% teratozoospermia, fertilization and cleavage rates were high (50.8% and 93.2%). Pregnancy rates were however lower than in cycles where normal spermatozoa were injected (17% vs 27%), and ongoing pregnancies were very low (5.88%) with an increased abortion rate. The authors suggest that abnormal head morphology may reflect abnormalities in spermatogenesis that is manifested by embryos with a low implantation potential. Moomjy *et al.* (1998) however, found total teratozoospermia to be the only apparent reason for total fertilization failure in 4 of 20 couples presenting with this outcome. A few more recent studies also indicate that sperm morphology (strict criteria) does in fact influence ICSI fertilization and subsequent pregnancy outcome. Levran *et al.* (1998) recorded the sperm morphology of each injected sperm cell, and found that fertilization declined with the following morphology appearance: short acrosome region, round head and amorphous head defect. No pregnancy occurred in the amorphous head defect group. The authors conclude that the injection of spermatozoa with head defects, results in decreased fertilization rates and poor embryo quality. Kahraman *et al.* (1998,1999) also found decreased fertilization and pregnancy rates with the injection of megalog head and multiple tail spermatozoa. They suggest that a high incidence of chromosomal abnormalities may be associated with these morphological forms and can therefore be the reason for low fertilization and pregnancy. The advantage of using ICSI in cases with poor prognosis sperm morphology [i.e. < 5% morphologically normal spermatozoa] compared to IVF, was shown in studies by O'Neil *et al.* (1998) and Moon *et al.* (1998). Fertilization rate was increased, but spontaneous abortion in this group was very high and ongoing pregnancy after ICSI with poor morphology spermatozoa, decreased.

In a study by Osawa *et al.* (1999) it was reported that only in the case of severely tapered sperm heads, a decrease in ICSI fertilization (13%) was observed. They comment that such spermatozoa have a prolonged and incomplete decondensation pattern that can possibly explain the decrease.

In general, round-headed spermatozoa or globozoospermia, lack the capacity to bind to the zona and penetrate oocytes (Palermo *et al.*, 1996a). The acrosomal and post-acrosomal sheath is absent and abnormal mitochondria and mid-pieces are also prevalent. They are however, not associated with chromosomal abnormalities (Rybouchin *et al.*, 1996). ICSI is an effective procedure, which allows fertilization even in cases of extreme oligoasthenoteratozoospermia. Round-headed, acrosomeless spermatozoa are however an exception and fertilization with such spermatozoa was reduced in ICSI, although fertilization and some pregnancies have been reported (Liu *et al.*, 1995; Rybouchin *et al.*, 1996; Kilani *et al.*, 1998). The results in a study by Rybouchin *et al.* (1996) revealed that round-headed spermatozoa are deficient in oocyte-activation capacity due to the absence of SAOAF (Rybouchin *et al.*, 1996). Battaglia *et al.* (1997) also concluded that round-headed spermatozoa used in ICSI were unable to induce oocyte activation. Treatment of unfertilized oocytes with calcium ionophore, showed that activation was in fact possible. This study also speculates that round-headed spermatozoa are deficient in SAOAF.

In a case study reported by Kilani *et al.* (1998) a 65% fertilization rate with round-headed spermatozoa in three cycles was achieved. The success was attributed to the vigorous stimulation of the oocyte by cytoplasmic aspiration. A triplet pregnancy followed transfer of four embryos. Results are therefore somewhat contradictory, but in many cases patients have a heterogeneous sperm population and the injected sperm cell is not always representative of the initial diagnosis (Rybouchin *et al.*, 1996).

#### 4.7.3 Immotile spermatozoa

Studies concluded that the only ultimate criterion for successful ICSI is the presence of at least one living spermatozoon per oocyte (Nagy *et al.*, 1995c, 1998; Moomjy *et al.*, 1998). In an analysis of total fertilization failure cycles, Liu *et al.* (1995), found similar results. Total fertilization failure was mainly caused by injection of non-viable spermatozoa. Dozortsev *et al.*, (1995) conducted a study to investigate the role of the sperm cell in oocyte activation and concluded that initially motile and therefore live spermatozoa are essential, since immotile and (presumed) non viable spermatozoa did not result in oocytes activation, possibly due to the absence of sperm associated oocyte activating factor (SAOAF) in dead spermatozoa. Dozortsev *et al.* (1997) also reported that heat-treated (90°C/30 minutes) spermatozoa showed significantly lower oocyte activation when compared to untreated spermatozoa. This indicated that SAOAF is inactivated by this treatment. It is also possible that immotile spermatozoa may have lost their sperm cytosolic factor (SCF) due to membrane damage (Palermo *et al.*, 1997).

A study by Gearon *et al.* (1995) however, showed different results. They found that non-viable spermatozoa, when injected in the presence of exogenous calcium, were able to activate human oocytes with subsequent cleavage. Their explanation for these contradictory results was the difference in the degree of ooplasm disruption during ooplasm aspiration. It was also reported by Nijs *et al.* (1996) that totally immotile spermatozoa from the ejaculate, testis and epididymus have the capacity to fertilize oocytes after ICSI. The capacity of totally immotile ejaculated spermatozoa to fertilize was however significantly lower than that in the epididymal and testicular groups. The authors stress the fact that even immotile spermatozoa must undergo membrane damage to destabilize the membrane in order to release the sperm factor. The difference in fertilization rates between the groups was thought to be due to the fact that immotile, testicular spermatozoa are probably not dead, but have not yet switched on their pathways for motility.

The previous studies stress the need for the embryologist to differentiate between live immotile and non-viable, immotile spermatozoa for ICSI. A number of studies investigated the possibility to use the hypo-osmotic swelling test (HOST) to select live immotile spermatozoa for ICSI (Casper *et al.*, 1996; Ahmadi *et al.*, 1997; Barros *et al.*, 1997a,b; Tsai *et al.*, 1997). In all five of the studies, the results demonstrated that spermatozoa selected for ICSI with a positive HOST result, showed significantly increased fertilization rates when compared to unselected spermatozoa. These studies confirmed the fact that lack of sperm movement does not necessarily mean cell death (Barros *et al.*, 1997a,b). A recent study by Arruda *et al.*, (1998) however, questioned the use of HOS to select viable spermatozoa. They showed that exposure to HOS conditions could in fact cause a decline in viability within minutes.

#### 4.7.4 DNA abnormalities

In contrast to the general sperm defects (low count, poor motility, abnormal morphology), some spermatozoa have defects in their surface proteins and chromatin organization. These hidden anomalies in the composition of sperm nuclei, present as loosely packaged chromatin and damaged DNA (Sakkas *et al.*, 1996). Sakkas *et al.* (1996) used the fluorochrome chromomycin A<sub>3</sub> (CMA<sub>3</sub>) to show that poor spermatozoal chromatin packaging and/or damaged DNA in spermatozoa, may contribute to failure of sperm decondensation and therefore fertilization failure in ICSI. In a study investigating the occurrence of PCC in unfertilized ICSI oocytes, the possibility of poor chromatin packaging and damaged DNA as contributing factors to PCC was indicated (Schmiady *et al.*, 1996).

The aniline blue staining test, showing the degree of nuclear condensation or maturation, was used by Hammadeh *et al.* (1996), to determine the possible relationship between sperm chromatin condensation and ICSI fertilization rates. The test is highly predictive for classical IVF fertilization. Their study showed however that aniline blue staining and therefore the nuclear maturation status of spermatozoa used in ICSI, failed to predict fertilization and has limited prognostic value for ICSI.

Twigg *et al.* (1998) studied the effect of oxidative stress on spermatozoa in the fertilization outcome of ICSI. Reactive oxygen species (ROS) can cause chromatin and DNA damage and spermatozoa selected for ICSI, probably come from environments experiencing oxidative stress. There is therefore a risk that such spermatozoa can be injected and cause fertilization failure. The results of the study showed however, that whatever biochemical mechanisms are involved in oxidative damage in human spermatozoa, it does not prevent pronucleus formation in ICSI. These results implicate that genetically damaged spermatozoa can achieve normal fertilization following ICSI (Twigg *et al.*, 1998).

In ICSI the sperm-oocyte interaction is no longer relevant and the quality of the sperm chromatin and ability of sperm decondensation became more important. The study by Lopes *et al.*, (1998a) suggested that some sperm cells selected for ICSI, may have fragmented DNA and result in fertilization failure. Such chromatin packaging anomalies are because of defects in the sperm nuclear condensation mechanisms. Faulty protamine deposition, persistence of histones and increased DNA instability may be representative of spermatozoa that have failed to complete maturation.

#### 4.7.5 Centrosomal abnormalities

The sperm centrosome provides the active division centre for the embryo, and plays a very important role in the first division of the embryo at syngamy (Sathanathan *et al.*, 1996). The functional, proximal sperm centriole is carried into the oocyte at fertilization, persists during sperm decondensation and organizes the sperm aster and the first mitotic spindle (Ng *et al.*, 1993; Sathanathan *et al.*, 1996). It has been shown that immotile spermatozoa have more centriolar defects than motile spermatozoa. Such a centriole dysfunction can therefore cause lower fertilization rates and can also compromise embryo development in IVF and ICSI (Ng *et al.*, 1993; Sathanathan *et al.*, 1996; Palermo *et al.*, 1996a; Wall *et al.*, 1996).

### 4.8 Testicular and epididymal spermatozoa

ICSI with testicular and epididymal spermatozoa have been shown to be very successful, although some studies initially reported lower fertilization rates than with ejaculated spermatozoa (Palermo *et al.*, 1996a; Moomjy *et al.*, 1998; Shulman *et al.*, 1999). A recent study by Calderon *et al.*, (1998), also reported a lower ICSI fertilization rate with testicular spermatozoa (45%) when compared with donor sperm IVF (65%). This difference was not statistically significant and pregnancy rates were similar. The study concludes that azoospermic patients should be offered ICSI with testicular spermatozoa as the first treatment.

Results with testicular sperm have gradually increased and the most recent studies showed that results in ICSI using ejaculated, testicular or epididymal spermatozoa did not differ significantly (Ghazzawi *et al.*, 1998; Mansour, 1998). Even non-obstructive azoospermic male infertility, can be successfully treated to obtain fertilization and pregnancy (Schoysman *et al.*, 1994; Nagy *et al.*, 1995a; Silber *et al.*, 1995). There was however a significant decrease in the fertilization rates in cases of non-obstructive azoospermia when compared to obstructive azoospermia (Mansour, 1998).

Palermo *et al.* (1996c) and Ghazzawi *et al.* (1998), suggested that more vigorous immobilization can increase fertilization with testicular spermatozoa.

#### 4.8.1 Cryopreserved testicular spermatozoa

Cryopreservation of human spermatozoa is a widely used and accepted procedure (Brotherton *et al.*, 1990) although it was shown to cause some damage to the sperm cell. The main effect of such damage can be seen in classical fertilization, since damage is mainly structural and functional (motility, acrosome, peripheral sperm membranes, sperm metabolism). Thawed sperm cells deteriorate faster than fresh spermatozoa. This is true for ejaculated, epididymal and testicular spermatozoa and is mainly manifested as reduced motility (Brotherton *et al.*, 1990; Perraguin-Jayot *et al.*, 1997). The disadvantages mentioned above however do not apply in ICSI, where structural and functional integrity is not essential. Frozen-thawed testicular spermatozoa were even shown to increase in progressive motility with time as more spermatozoa become mature (Edirisinghe *et al.*, 1996). This was not as pronounced as in fresh testicular spermatozoa, but was shown to give comparable fertilization results (Nagy *et al.*, 1995a; Perraguin-Jayot *et al.*, 1997).



Fertilization and pregnancies after the use of frozen-thawed testicular spermatozoa in ICSI, have been reported (Fisher *et al.*, 1996; Gil-Salmon *et al.*, 1996; Hovatta *et al.*, 1996; Podsiadly *et al.*, 1996; Khalifeh *et al.*, 1997; Oates *et al.*, 1997; De Croo *et al.*, 1998; Rives *et al.*, 1998; and Windt and Coetzee, 1999) and were shown to be comparable with the use of fresh testicular spermatozoa. De Croo *et al.*, (1998) found however a decreased implantation rate when frozen-thawed testicular spermatozoa were used and conclude that the detrimental effect of freezing on testicular sperm may only be expressed at the implantation stage.

#### 4.9 Spermatis

Recently, ICSI with spermatis (round and elongated) was also shown to be possible and resulted in fertilization and pregnancies (Tesarik *et al.*, 1995c; Sousa *et al.*, 1996b; Vanderzwalmen *et al.*, 1997; Bernabeu *et al.*, 1998; Mansour, 1998; Prapas *et al.*, 1999). In a study reported by Vanderzwalmen *et al.* (1997), ICSI fertilization and implantation rates with round spermatis were very low (22% and 5.5% respectively), when compared to ICSI with testicular spermatozoa.

Both Sofikitis *et al.* (1998) and Aslam *et al.* (1998) summarized and reviewed in detail the use of spermatis injection in the last 4 years, and reported much lower fertilization and pregnancy rates when compared to the use of testicular spermatozoa. This was also reported by Prapas *et al.* (1999).

Although the haploid set of chromosomes of spermatis are potentially capable to pair with chromosomes of oocytes and participate in syngamy and full embryonic development, low fertilization rates can be caused by genetic abnormalities, centrosome status and the inability to activate the oocyte (deficiency or lack in SAOAF) (Palermo *et al.*, 1997; Vanderzwalmen *et al.*, 1997; Aslam *et al.*, 1998; Sofikitis *et al.*, 1998). It was however concluded that non-activation of the oocytes was the main reason for low fertilization rates in these cases (Aslam *et al.*, 1998; Sofikitis *et al.*, 1998). Suboptimal activity or deficiency of oocyte activating factor seems to be the main reason and Aslam *et al.* (1998) suggest that  $Ca^{2+}$  ionophore should be applied to activate the oocyte.

Sofikitis *et al.* (1998) mentions however that there is evidence that human OASIS (oocyte activating substance in spermatozoon/spermatis) is activated before or at the round spermatis stage. Difficulty to render spermatis permeable (membrane damage and destabilization) could also contribute to low fertilization rates (Palermo *et al.*, 1997). The relative large amount of cytoplasm around the round spermatis can also contribute to lower fertilization rates when the egg ooplasm cannot digest the sperm cytoplasm to expose the activating factor to the oocyte (Sofikitis *et al.*, 1998). Sofikitis *et al.* 1998 also stresses the importance of viability, maturation stage, media for culture and fertilization observation of spermatis, in fertilization rates.

It was concluded in most studies that maturer, elongated spermatis resulted in a much higher fertilization and implantation rate (Vanderzwalmen *et al.*, 1997; Antinori *et al.*, 1997, 1998; Aslam *et al.*, 1998; Sofikitis *et al.*, 1998; Prapas *et al.*, 1999) compared to round spermatis and should preferably be used.

## 5. Concluding Remarks

It is clear from this literature study that fertilization failure is caused primarily by abnormalities and deficiencies in either the male or female gamete (or both) and in ICSI especially, the microinjection technique itself. In most cases of fertilization failure, events leading to non-activation of the oocyte, is the major cause.

When evaluating the role of the **spermatozoon**, motility seems to be the most important factor. Normal and sufficient concentrations of "sperm associated oocyte activating factor" (SAOAF) also plays a very important role as does the ability of the spermatozoon to decondense. Also important, is the genetic status of the spermatozoon and recently certain types of morphological abnormal spermatozoa have also been indicated to influence ICSI fertilization rates.

The contribution of the **oocyte** to fertilization failure in ICSI, lies mainly in its inability to become activated and undergo cortical granule activation. Therefore, genetic and cytoplasmic maturity is very important as well as the oocyte's ability to undergo normal calcium oscillation patterns and become activated. Certain morphological abnormalities (vacuoles, central disk, degeneration, "bull's eye", refractile body) are also contributory as well as a deficiency in sperm decondensing factor (SDF).

In ICSI fertilization, the **injection technique** is of utmost importance and is the main contributory factor to fertilization failure when the gametes are normal. The correct immobilization of the spermatozoon is very important. Immobilization damages the membrane to destabilize and permeabilize it for the release of SAOAF and make it accessible to SDF. The correct penetration and breakage of the membrane to ensure that the spermatozoon is deposited inside the ooplasm, and mixing of the spermatozoon with the ooplasm, is also essential.

Finally, quality control, culture conditions, defined media, excellent microtools and equipment and dedicated embryologists are the cornerstone of a successful ICSI laboratory.

*This review was published in "An Atlas of the Ultrastructure of Human Oocytes - A Guide for Assisted Reproduction" (2000) edited by M. El. Shafie, M. Sousa, M.-L.- Windt and T.F. Kruger (Parthenon Publishing).*

## References

- Abdelmassih, R., Solia, M.L.T., Moretto, M. *et al.* (1996) Female age is an important parameter to predict treatment outcome in intracytoplasmic sperm injection. *Fertil. Steril.*, **65**, 573-577.
- Ahmadi, A. and Ng, S-C. (1997) The single sperm curling test, a modified hypo-osmotic swelling test, as a potential technique for the selection of viable sperm for intracytoplasmic sperm injection. *Fertil. Steril.*, **68**, 346-350.
- Almeida, P.A. and Bolton V.N. (1994) The relationship between chromosomal abnormalities in the human oocytes and fertilization *in vitro*. *Hum. Reprod.*, **9**, 343-346.
- Alrayyes, S., Fakih, H. and Khan, I. (1997) Effect of age and cycle responsiveness In patients undergoing intracytoplasmic sperm injection. *Fertil. Steril.*, **68**, 123-127.
- Antinori, S., Versaci, C., Dani, G. *et al.* (1997) Fertilization with human testicular spermatids: four successful pregnancies. *Hum. Reprod.*, **12**, 286-291.
- Antinori, S., Dani, G., Vidali, A. *et al.* (1998) The use of round or elongated spermatids for ICSI. Which is more effective ? *Fertil. Steril.*, **70**, (suppl.1), P-349.
- Arruda, J., Vigue, L. and Huszar, G. (1998) The effects of hypo-osmotic exposure (HOS) on sperm viability monitored in both the tail and head. . *Fertil. Steril.*, **70**, (suppl.1), P-821.
- Asch, R., Simerly, C., Ord, T. *et al.* (1995) The stages at which human fertilization arrests: microtubule and chromosome configurations in inseminated oocytes which failed to complete fertilization and development in humans. *Mol. Hum. Reprod.*, **10**, 1897-1906.
- Aslam, I., Fishel, S., Green, S. *et al.* (1998) Can we justify spermatid microinjection for severe male factor infertility? *Hum. Reprod. Update*, **4**, 213-222.
- Balaban, B., Urman, B., Sertac, A. *et al.* (1998) Oocyte morphology does not affect fertilization rate, embryo quality and implantation rate after intracytoplasmic sperm injection. *Hum. Reprod.*, **13**, 3431-3433.
- Ballesteros, A., Carneiro, P., Amorocho, B. *et al.* (1998) The relationship between oocyte morphology and ICSI outcome. *Fertil. Steril.*, **70**, (suppl.1), P-979.
- Barros, A., Sousa, M., Angelopoulos, T. *et al.* (1997a) Efficient modification of intracytoplasmic sperm injection technique for cases with total lack of sperm movement. *Hum. Reprod.*, **12**, 1227-1229.
- Barros, A., Sousa, M., Oliveira, C. *et al.* (1997b) Pregnancy and birth after intracytoplasmic sperm injection with totally immotile sperm recovered from the ejaculate. *Fertil. Steril.*, **67**, 1091-1094.
- Battaglia, D.E., Koehler, J.K., Klein, N.A. *et al.* (1997) Failure of oocyte activation after intracytoplasmic sperm injection using round-headed sperm. *Fertil. Steril.*, **68**, 118-122.
- Bedford, J.M. and Kim, H.H. (1993) Sperm-egg binding patterns and oocytes cytology in retrospective analysis of fertilization failure *in vitro*. *Hum. Reprod.*, **8**, 453-463.
- Bergère, M., Selva, J., Volante, M. *et al.* (1995) Cytogenetic analysis of uncleaved oocytes after intracytoplasmic injection. *J. Assis. Reprod. Genetics*, **12**, 322-325.
- Bernabeu, R., Cremades, N., Takahashi, M. *et al.* (1998) Successful pregnancy after spermatid injection. *Hum. Reprod.*, **13**, 1898-1900.
- Brotherton J. Cryopreservation of human spermatozoa (1990) *Arch. of Androl.*, **25**, 181-195.

- Calderon, I., Dirnfeld, M., Ishai, D. *et al.* (1998) Is the fertilization rate of testicular sperm and its capacity to achieve pregnancy as good as or comparable to that of donor sperm? *Fertil. Steril.*, **70**, (suppl.1), P 462.
- Casper, R.F., Meriano, J.S., Jarvi, K.A. *et al.* (1996) The hypo-osmotic swelling test for selection of viable sperm for intracytoplasmic sperm injection In men with complete asthenozoospermia. *Fertil. Steril.*, **65**, 972-976.
- Chen, S-U., Ho, H-N., Chen, H-F. *et al.* (1996) Intracytoplasmic sperm injection (ICSI) for severe semen abnormalities: dissecting the tail of spermatozoa at the tip. *Hum. Reprod.*, **11**, 2640-2644.
- Coetzee, K., Kruger, T.F and Lombard, C.J. (1998) Predictive value of normal sperm, morphology: a structured literature review. *Hum. Reprod. Update*, **4**, 73-82.
- De Croo, I., Van der Elst, J., Eveaert, K. *et al.* (1998) Fertilization, pregnancy and embryo implantation rates after ICSI with fresh or frozen-thawed testicular spermatozoa. *Hum. Reprod.*, **13**, 1893-1897.
- De Sutter, P., Dozortsev, D., Qian, C. *et al.* (1996) Oocyte morphology does not correlate with fertilization rate and embryo quality after intracytoplasmic sperm injection. *Hum. Reprod.*, **11**, 595-597.
- De Vos, A., Van de Velde, H., Joris, H. *et al.* (1999) In vitro matured metaphase-I oocytes have a lower fertilization rate but similar embryo quality as mature metaphase-II oocytes after intracytoplasmic sperm injection (ICSI). *Hum. Reprod.*, **14**, 1859-1863.
- Devroey, P., Godoy, H. and Smits, J., *et al.*, (1996) Female age predicts embryonic implantation after ICSI: a case-controlled study. *Hum. Reprod.*, **11**, 1324-1327.
- Dozortsev, D., De Sutter, P. and Dhont, M. (1994) Behaviour of spermatozoa in human oocytes displaying no or one pronucleus after intracytoplasmic sperm injection. *Hum. Reprod.*, **9**, 2139-2144.
- Dozortsev, D., Rybouchkin, A., De Sutter, P. *et al.* (1995) Human oocyte activation following intracytoplasmic injection: the role of the sperm cell. *Hum. Reprod.*, **10**, 403-407.
- Dozortsev, D., Qain, C., Ermilov, A., *et al.* (1997) Sperm-associated oocyte-activating factor is released from the spermatozoon within 30 minutes after injection as a result of the sperm-oocyte interaction. *Hum. Reprod.*, **12**, 2793-2796.
- Edirisinghe, W.R., Junk, S.M., Matson, P.L. *et al.* (1996) Changes in motility patterns during in-vitro culture of fresh and frozen/thawed testicular and epididymal spermatozoa: implications for planning treatment by intracytoplasmic sperm injection. *Hum. Reprod.*, **11**, 2474-247.
- Edwards, R.G., (1993) Intracytoplasmic sperm injections (ICSI) and human fertilization: does calcium hold the key to success? *Hum. Reprod.*, **8**, 988-989.
- Edwards, R.G. and Beard, H.K. (1997) Oocyte polarity and cell determination in early mammalian embryos. *Mol. Hum. Reprod.*, **3**, 863-905.
- Ergun, B., Takeuchi, T., Veeck, L.L. *et al.* (1998) Influence of female factor infertility on ICSI outcome. *Fertil. Steril.*, **70**, (suppl.1), P-328.
- Fishel, S., Lisi, F., Rinaldi, L. *et al.* (1995) Systematic examination of immobilizing spermatozoa before intracytoplasmic sperm injection in the human. *Hum. Reprod.*, **10**, 497-500.
- Fisher, R., Baukloh, V., Naether, O.G.J. *et al.* (1996) Pregnancy after intracytoplasmic sperm injection of spermatozoa extracted from frozen-thawed testicular biopsy. *Hum. Reprod.*, **11**, 2197-2199.
- Flaherty, S.P., Payne, D., Swann, N.J. *et al.* (1995a) Aetiology of failed and abnormal fertilization after intracytoplasmic sperm injection. *Hum. Reprod.*, **10**, 2623-2629.

- Flaherty, S.P., Payne, D., Swann, N.J. *et al.* (1995b) Assessment of fertilization failure and abnormal fertilization after intracytoplasmic sperm injection. *Reprod.Fertil. Dev.*, **7**, 197-210.
- Flaherty, S.P., Payne, D. and Matthews, C.D. (1998) Fertilization failures and abnormal fertilization after intracytoplasmic sperm injection. *Hum. Reprod.*, **13**, (Suppl. 1) 155-164.
- Fluka Jr, J., Kárníková, L. and Moor, R.M. (1998) Oocyte polarity: ICSI, cloning and related techniques. *Hum. Reprod.*, **13**, 3303-3305.
- Frydman, N., Bergere, M., Rodrigues, D. *et al.* (1998) Analysis of ICSI failures of same technician: A model of quality control in ICSI procedure. *Fertil. Steril.*, **70**, (suppl.1), P-549.
- Gabrielsen, A., Petersen, K., Mikkelsen, A.L. *et al.* S. (1996) Intracytoplasmic sperm injection does not overcome an oocyte defect in previous fertilization failure with conventional in-vitro fertilization and normal spermatozoa. *Hum. Reprod.*, **11**, 1963-1996.
- Garello, C., Baker, H., Rai, J. *et al.* (1999) Pronuclear orientation, polar body placement, and embryo quality after intracytoplasmic sperm injection and in-vitro fertilization: further evidence for polarity in human oocytes? *Hum. Reprod.*, **14**, 2588-2595.
- Gearon, C.M., Taylor, A.S. and Forman, R.G. (1995) Factors affecting activation and fertilization of human oocytes following intracytoplasmic injection. *Hum. Reprod.*, **10**, 896-902.
- Ghazzawi, I.M., Sarraf, M.G., Taher, M.R. *et al.* (1998) Comparison of the fertilizing capability of spermatozoa from ejaculates, epididymal aspirates and testicular biopsies using intracytoplasmic sperm injection. *Hum. Reprod.*, **13**, 348-352.
- Gil-Salmon, M., Romero, J., Minguez Y. *et al.* (1996) Pregnancies after intracytoplasmic sperm injection with cryopreserved testicular spermatozoa. *Hum. Reprod.*, **11**, 1309-1313.
- Gook, D., Osborn, SM., Bourne, H. *et al.* (1998) Fluorescent study of chromatin and tubulin in apparently unfertilized human oocytes following ICSI. *Mol. Hum. Reprod.*, **4**, 1130-1135.
- Greco, E., Manna, C. and Rienzi, L. (1996) Delayed cleavage of human oocytes after intracytoplasmic sperm injection. *Hum. Reprod.*, **11**, 1357-1358.
- Guthauser, B., Frydman, N., Rodrigues, D. *et al.* (1998a) Oocyte morphology is not related to the low success of intracytoplasmic sperm injection (ICSI) for unexplained failure of conventional in vitro fertilization. *Fertil. Steril.*, **70**, (suppl.1), P-367.
- Guthauser, B., Rodrigues, D., Hamamah, S. *et al.* (1998b) Influence of oocyte morphological appearance on fertilization rate and embryo quality after intracytoplasmic sperm injection (ICSI). *Fertil. Steril.*, **70**, (suppl.1), P-368.
- Hammadeh, M.E., Al-Hassan, S., Stieber, M. *et al.* (1996) The effect of chromatin condensation (Aniline blue staining) and morphology (strict criteria) of human spermatozoa on fertilization, cleavage and pregnancy rates in an intracytoplasmic sperm injection programme. *Hum. Reprod.*, **11**, 2468-2471.
- Hariprashad, J., Colombero, L.T. and Rosenwaks, Z. (1998) The incidence and relevance of chromosomal abnormalities in human spermatozoa to the outcome of assisted reproduction. *Fertil. Steril.*, **70**, (suppl.1), P-360.
- Homa, S.T., Carroll, J. and Swann, K. (1993) The role of calcium in mammalian oocyte maturation and egg activation. *Hum. Reprod.*, **8**, 1274-1281.
- Homa, S.T. and Swann, K. (1994) A cytosolic sperm factor triggers calcium oscillations and membrane hyperpolarizations in human oocytes. *Hum. Reprod.*, **9**, 2356-2361.

- Hovatta, O., Foudila, T., Sieberg, R. *et al.* (1996) Pregnancy resulting from intracytoplasmic injection of spermatozoa from frozen-thawed testicular biopsy specimen. *Hum. Reprod.*, **11**, 2472-2473.
- Joris, H., Nagy, Z., Van de Velde, H. *et al.* (1998) Intracytoplasmic sperm injection: laboratory set-up and injection procedure. *Hum. Reprod.*, **13**, (Suppl. 1) 76-86.
- Kahraman, S., Akarsu, C., Cengi, G. *et al.* (1999). Fertility of ejaculated and testicular megalohed spermatozoa with intracytoplasmic sperm injection. *Hum. Reprod.*, **14**, 726-730.
- Kahraman, S., Akarsu, C., Sozen, E. *et al.* (1998) Fertility of pinhead and multiple tail megalohed spermatozoa only in the ejaculate with ICSI. *Fertil. Steril.*, **70**, (suppl.1), P- 812.
- Khalifeh, F.A., Sarraf, M. and Dabit, S.T. (1997) Full-term delivery following intracytoplasmic sperm injection with spermatozoa from frozen-thawed testicular tissue. *Hum. Reprod.*, **12**, 87-88.
- Kilani, Z.M., Shaban, M.A., Ghunaim, S.D. *et al.* (1998) Triplet pregnancy and delivery after intracytoplasmic injection of round-headed spermatozoa. *Hum. Reprod.*, **13**, 2177-2179.
- Küpker, W., Diedrich, K. and Edwards, R.G. (1998a) Principles of mammalian fertilization. *Hum. Reprod.*, **13**, (Suppl. 1) 20-32.
- Küpker, W., Schukze, W. and Diedrich, K. (1998b) Ultrastructure of gametes and intracytoplasmic sperm injection: the significance of sperm morphology. *Hum. Reprod.*, **13**, (Suppl. 1) 99-106.
- Levrán, D., Nahum, H., Zakut, H. *et al.* (1998) The impact of injected sperm morphology on fertilization rate, embryo quality and pregnancy rate in IVF-ICSI cycles. *Fertil. Steril.*, **70**, (suppl.1), P 972
- Levron, J., Aviram, A., Madgar, I. *et al.* (1998). High rate of chromosomal aneuploidies in testicular spermatozoa retrieved from azoospermic patients undergoing testicular sperm extraction for in vitro fertilization. *Fertil. Steril.*, **70**, (suppl.1), O-003.
- Liu, J., Nagy, Z., Joris, H. *et al.* (1995) Analysis of 76 total fertilization failure cycles out of 2732 intracytoplasmic sperm injection cycles. *Hum. Reprod.*, **10**, 2630-2636.
- Lopes, S., Sun, J.-G., Juriscova, A., Meriano, J. and Casper, R.F. (1998a) Sperm deoxyribonucleic acid fragmentation is increased in poor-quality semen samples and correlates with failed fertilization in intracytoplasmic sperm injection. *Fertil. Steril.*, **69**, 528-532.
- Lopes, S., Juriscova, A. and Casper, R.F. (1998b) Gamete-specific DNA fragmentation in unfertilized human oocytes after intracytoplasmic sperm injection. *Hum. Reprod.*, **13**, 703-708.
- Mansour, R.T., Aboulghar, M.A., Serour, G.I. *et al.* (1996) Successful intracytoplasmic sperm injection without performing cytoplasmic aspiration. *Fertil. Steril.*, **66**, 256-259.
- Mansour, R. (1998) Intracytoplasmic sperm injection: a state of the art technique. *Hum. Reprod. Update*, **4**, 43-56.
- Martini, E., Flaherty, S.P., Swann, N.J. *et al.* (1997) Analysis of unfertilized oocytes subjected to intracytoplasmic sperm injection using to rounds of fluorescence in-situ hybridization and probes to five chromosomes. *Hum. Reprod.*, **12**, 2011-2018.
- Matson, P. (1998) Internal quality control and external quality assurance in the IVF laboratory. *Hum. Reprod.*, **13** (suppl 4), 156.
- Meng, L. and Wolf, D.P. (1997) Sperm-induced oocyte activation in the rhesus monkey: nuclear and cytoplasmic changes following intracytoplasmic sperm injection. *Hum. Reprod.*, **12**, 1062-1068.

Moomjy, M., Sills, E.S., Rozenwaks, Z. *et al.* (1998) Implications of complete fertilization failure after intracytoplasmic sperm injection for subsequent fertilization and reproductive outcomes. *Hum. Reprod.*, **13**, 2212-2216.

Moon, S.Y., Jung, B.J., Jee, B.C. *et al.* (1998), Assessment of oocyte morphology, oolemma breakage, and suction types as a predictor of normal fertilization after ICSI. *Fertil. Steril.*, **70**, (suppl.1), P-323.

Nagy, Z., Liu, J., Janssenwillen, C., Silber, S. *et al.* (1995a) Using ejaculated, fresh, and frozen-thawed epididymal and testicular spermatozoa gives rise to comparable results after intracytoplasmic sperm injection. *Fertil. Steril.*, **63**, 808-815.

Nagy, Z.P., Liu, J., Joris, H., *et al.* (1995b) The result of intracytoplasmic sperm injection is not related to any of the three basic sperm parameters. *Hum. Reprod.*, **10**, 1123-1129.

Nagy, Z.P., Liu, J., Joris, H. *et al.* (1995c) Th influence of the site of sperm deposition and mode of oolemma breakage at intracytoplasmic sperm injection on fertilization and embryo developmnt rates. *Hum. Reprod.*, **12**, 3171-3177.

Nagy, P.Z., Verheyen, G., Tournaye, H. *et al.* (1998) Special applications of intracytoplasmic sperm injection: the influence of sperm count, motility, morphology source and sperm antibody on the outcome of ICSI. *Hum. Reprod.*, **13**, (Suppl. 1) 143-154.

Ng, S-C., Liow, S-L., Sathanathan, H., Bongso, A. *et al.* (1993) Review: Microinjection of human sperm directly into human oocytes. *J. Assis. Reprod. Genetics*, **10**, 337-352.

Nijs, M., Vanderzwalmen, P., Vandamme, B. *et al.* (1996) Fertilizing ability of immotile spermatozoa after intracytoplasmic sperm injection. *Hum. Reprod.*, **11**, 2180-2185.

Oates, R.D., Mulhall, J., Burgess, C. *et al.* (1997) Fertilization and pregnancy using intentionally cryopreserved testicular tissue as the sperm source for intracytoplasmic sperm injection in 10 men with non-obstructive azoospermia. *Hum. Reprod.*, **12**, 734-739.

Oehninger, S., Veeck, L., Lazendorf, S. *et al.* (1995) Intracytoplasmic sperm injection: achievement of high pregnancy rates in couples with severe male factor infertility is dependent primarily upon female and not male factors. *Fertil. Steril.*, **64**, 977-981.

Oehninger, S., Franken, D.R., and Kruger, T.F. (1997) Approaching the next millennium: how should we manage andrology diagnosis in the intracytoplasmic sperm injection era? *Fertil. Steril.*, **67**, 434-436.

O'Neil, J., Lundquist, L., Ritter, J. *et al.* (1998) Should strict morphology be used to indicate the need for intracytoplasmic sperm injection? . *Fertil. Steril.*, **70**, (suppl.1), P-442.

Osawa, Y., Sueoka, K., Iwata, S. *et al.* (1999) Assessment of the dominant abnormal form is useful for predicting the outcome of intracytoplasmic sperm injection in the case of severe teratozoospermia. *J. Assis. Reprod. Genetics*. **16**, 436-442.

Palermo, G., Joris, H., Devroey, P. *et al.* (1992) Pregnancy after intracytoplasmic injection of a single spermatozoon into an oocyte. *Lancet*, **2**, 17-18.

Palermo, G., Cohen, J. and Rosenwaks, Z. (1996a) Intracytoplasmic sperm injection: a powerful tool to overcome fertilization failure. *Fertil. Steril.*, **65**, 899-908.

Palermo, G., Alkani, M., Bertoli, M. *et al.* (1996b) Oolemma characteristics in relation to survival and fertilization patterns of oocytes treated by intracytoplasmic sperm injection. *Hum. Reprod.*, **11**, 172-176.

Palermo, G.P., Schlegel P.N., Colombero, L.T. *et al.* (1996c) Aggressive sperm immobilization prior to intracytoplasmic sperm injection with immature spermatozoa improves fertilization and pregnancy rates. *Hum.Reprod.*, **11**, 1023-1029.

- Palermo, G.D., Avrech, O.M., Colombero, L.T. *et al.* (1997) Human sperm cytosolic factor triggers Ca<sup>2+</sup> oscillations and overcomes activation failure of mammalian oocytes. *Mol. Hum. Reprod.*, **3**, 367-374.
- Pang, M.G., Hoegerman, S.F., Pfeffer, J. *et al.* (1998) Aneuploidy in sperm from forty-four oligoasthenoteratozoospermic (OAT) patient undergoing intracytoplasmic sperm injection (ICSI). *Fertil. Steril.*, **70**, (suppl.1), 0-017.
- Payne, D., Flaherty, S.P., Barry, M.F. *et al.* (1997) Preliminary observations on polar body extrusion and pronuclear formation in human oocytes using time-lapse video cinematography. *Hum. Reprod.*, **12**, 532-541.
- Parrington, J., Swann, K. and Shevchenko, V. (1996) Calcium oscillations in mammalian eggs triggered by a soluble sperm protein. *Nature*, **379**, 364-369.
- Perraguin-Jayot, S., Audebert, A., Empeaire, J.C. *et al.* (1997) Ongoing pregnancies after intracytoplasmic injection using cryopreserved testicular spermatozoa. *Hum. Reprod.*, **12**, 2706-2709.
- Plachot, M., Mandelbaum, J., Junca, A-M. *et al.* (1993) A function test to assess the responsibility of oocyte and sperm quality in in vitro fertilization failure. *J. Assis. Reprod. Genetics*, **10**, 228-234.
- Podsiadly, B.T., Woolcott, R., Stanger, J.D. *et al.* (1996) Pregnancy resulting from intracytoplasmic injection of cryopreserved spermatozoa recovered from testicular biopsy. *Hum. Reprod.*, **11**, 1306-1308.
- Prapas, Y., Chatziparasidou, A., Vanderzwalmen, P. *et al.* (1999) Spermatid injection: Reconsidering spermatid injection *Hum. Reprod.*, **14**, 2186-2188
- Rattanachaiyanont, M., Léveill  , M.-C. and Leader, A. (1998) Oocyte characteristics have effect on the outcomes of intracytoplasmic sperm injection. *Fertil. Steril.*, **70**, (suppl.1), P-967.
- Rienzi, L., Ubaldi, F., Anniballo, R. *et al.* (1998) Preincubation of human oocytes may improve fertilization and embryo quality after intracytoplasmic sperm injection. *Hum. Reprod.*, **13**, 1014-1019.
- Rives, N., Sibert, L., Clavier, B. *et al.* (1998) Full-term delivery following intracytoplasmic sperm injection with frozen-thawed immotile testicular spermatozoa. *Hum. Reprod.*, **13**, 3399-3401.
- Rybouchkin, A., Dozortzev, D., Pelinck, M.J. *et al.* (1996) Analysis of the oocyte activating capacity and chromosomal complement of round-headed human spermatozoa by their injection into mouse oocytes. *Hum. Reprod.*, **11**, 2170-2175.
- Sakkas, D., Urner, F., Bianchi, P.G. *et al.* (1996) Sperm chromatin anomalies can influence decondensation after intracytoplasmic sperm injection. *Hum. Reprod.*, **11**, 837-843.
- Sallam, H.N., Sallam, A.N. and Agamia, A.F. (1998) The correlation between eight sperm parameters assessed objectively and the fertilization rate in IVF and ICSI. *Fertil. Steril.*, **70**, (suppl.1), P-371.
- Sathananthan, A.H., Ratman, S.S., Ng, S.C. *et al.* (1996) The sperm centriole: its inheritance, replication and perpetuation in early human embryos. *Hum. Reprod.*, **11**, 345-356.
- Schmiady, H., Tandler-Schneider, A. and Kentenich, H. (1996) Premature chromosome condensation of the sperm nucleus after intracytoplasmic sperm injection. *Hum. Reprod.*, **11**, 2239-2245.
- Schoysman, R., Vanderzwalmen, P., Nijs, M. *et al.* (1994) Pregnancy obtained with human testicular spermatozoa in an in vitro fertilization program. *J. Androl.*, **15**, 10S-13S.
- Serhal, P.F., Ranieri, D.M., Kinis, A. *et al.* (1997) Oocyte morphology predicts outcome of intracytoplasmic sperm injection. *Hum. Reprod.*, **12**, 1267-1270.



- Shulman, A., Feldman, B., Madgat, I. *et al.* (1999) In-vitro fertilization treatment for severe male factor: the fertilization potential of immotile spermatozoa obtained by testicular biopsy. *Hum. Reprod.*, **14**, 749-752.
- Silber, S.J., Van Steirteghem, A.C., Liu, J. *et al.* (1995) High fertilization and pregnancy rate after intracytoplasmic sperm injection with spermatozoa obtained from testicle biopsy. *Hum. Reprod.*, **10**, 148-152.
- Silber, S.J., Nagy, Z., Devroey, P. *et al.* (1997) The effect of female age and ovarian reserve on pregnancy rate in male infertility: treatment of azoospermia with sperm retrieval and intracytoplasmic sperm injection. *Hum.Reprod.*, **12**, 2693-2700.
- Silber, S.J. (1998) Intracytoplasmic sperm injection today: a personal review. *Hum. Reprod.*, **13**, (Suppl. 1) 208-218.
- Silva, C.P., Kommineni, K., Oldenburg, R. *et al.* (1999) The polar body does not predict accurately the location of the meiotic spindle in mammalian oocytes. *Fertil. Steril.*, **71**, 719-721.
- Sofikikis, N., Miyagawa, I., Yamamoto, Y. *et al.* (1998) Micro-and macro-consequences of ooplasmic injections of early haploid male gametes. *Hum. Reprod. Update*, **4**, 197-212.
- Sousa, M. and Tesarik, J. (1994) Ultrastructural analysis of fertilization failure after intracytoplasmic sperm injection. *Hum. Reprod.*, **9**, 2374-2380.
- Sousa, M., Barros, A. and Tesarik, J. (1996a) The role of ryanodine-sensitive Ca<sup>2+</sup> stores in the Ca<sup>2+</sup> oscillation machine of human oocytes. *Mol. Hum. Reprod.*, **2**, 265-272.
- Sousa, M., Mendoza, C., Barros, A. *et al.* (1996b) Calcium responses of human oocytes after intracytoplasmic sperm injection of leukocytes, spermatocytes and round spermatids. *Mol. Hum. Reprod.*, **2**, 853-857
- Sousa, M., Barros, A., Mendoza, C. *et al.* (1997) Role of Ca<sup>2+</sup> oscillations during human preimplantation embryo development. *Ass. Reprod. Rev.*, **7**, 139-150.
- Spandorfer, S.D., Avrech, O.M., Colombero, L.T. *et al.* (1998) Effect of parental age on fertilization and pregnancy characteristics in couples treated by intracytoplasmic sperm injection. *Hum. Reprod.*, **13**, 334-338.
- Strehler, E., Baccetti, B., Sterzik, K. *et al.* (1998) Detrimental effects of polyvinylpyrrolidone on the ultrastructure of spermatozoa (*Notulae seminologiae* 13). *Hum. Reprod.*, **13**, 120-123.
- Svalander, P., Forsberg, A-S., Jakobsson, A-H. *et al.* (1995) Factors of importance for the establishment of a successful program of intracytoplasmic sperm injection treatment for male infertility. *Fertil. Steril.*, **63**, 828-837.
- Swann, K., Homa, S. and Carroll, J. (1994) Calcium in oocyte maturation. An inside job: the results of injecting whole sperm into eggs supports one view of signal transduction at fertilization. *Hum.Reprod.*, **9**, 978-980.
- Tasdemir, I., Tasdemir, M., Tavukcuoglu, S. *et al.* (1997) Effect of abnormal sperm head morphology on the outcome of intracytoplasmic sperm injection in humans. *Hum. Reprod.*, **12**, 1214-1217.
- Taylor, C.T., Lawrence, Y.M., Kingsland, C.R. *et al.* (1993) Oscillations in intracellular free calcium induced by spermatozoa in human oocytes at fertilization. *Hum. Reprod.*, **8**, 2174-2179.
- Taylor, C.T. (1994) Calcium in oocyte maturation. Calcium signals and human oocyte activation: implications for assisted conception. *Hum.Reprod.*, **9**, 980-984.
- Tesarik, J. and Thébault, A. (1993) Fertilization failure after subzonal sperm insertion associated with defective fusional capacity of acrosome-reacted spermatozoa. *Fertil. Steril.*, **60**, 639-371.
- Tesarik, J. (1994) Calcium in oocyte maturation. How the spermatozoon awakens the oocyte: lessons from intracytoplasmic sperm injection. *Hum. Reprod.*, **9**, 977-978.

- Tesarik, J., Sousa, M. and Testart, J. (1994) Human oocyte activation after intracytoplasmic sperm injection. *Hum. Reprod.*, **9**, 511-518.
- Tesarik, J. and Sousa, M. (1995a) More than 90% fertilization rates after intracytoplasmic sperm injection and artificial induction of oocyte activation with calcium ionophore. *Fertil. Steril.*, **63**, 343-349.
- Tesarik, J. and Sousa, M. (1995b) Key elements of a highly efficient intracytoplasmic sperm injection technique: Ca<sup>2+</sup> fluxes and cytoplasmic dislocation. *Fertil. Steril.*, **64**, 770-776.
- Tesarik, J., Mendoza, C. and Testart, J. (1995) Viable embryos from injection of round spermatids into oocytes (letter) *N. Engl. J. Med.*, **333**, 525.
- Tomás, C., Orava, M., Tuomivaara, L. *et al.* (1998) Low pregnancy rate is achieved in patients treated with intracytoplasmic sperm injection due to previous low or failed fertilization in in-vitro fertilisation. *Hum. Reprod.*, **13**, 65-70.
- Tsai, Y.-I., Liu, J., Garcia, E. *et al.* (1997) Establishment of an optimal hypo-osmotic swelling test by examining single spermatozoa in four different hypo-osmotic solutions. *Hum. Reprod.*, **12**, 1111-1113.
- Twigg, J.P., Irvine, D.S., and Aitken, R.J. (1998) Oxidative damage to DNA in human spermatozoa does not preclude pronucleus formation at intracytoplasmic sperm injection. *Hum. Reprod.*, **13**, 1864-1871.
- Van Blerkom, J. (1993) Human oocyte maturation and fertilization I and II. *Twenty-sixth annual postgraduate course: Course XI: Contemporary methods of sperm, oocyte, and embryo morphology assessment*. Am. Fert. Soc. Montreal, Canada (October 9-14), 121-133.
- Van Blerkom, J., Davis, P.W. and Merriman, J. (1994) A retrospective analysis of unfertilized and presumed parthenogenetically activated human oocytes demonstrates a high frequency of sperm penetration. *Hum. Reprod.*, **9**, 2381-2388.
- Van de Velde, H., Nagy, Z.P., Joris, H. *et al.* (1997) Effects of different hyaluronidase concentrations and mechanical procedures for cumulus removal on the outcome of intracytoplasmic sperm injection. *Hum. Reprod.*, **12**, 2246-2250.
- Van den Bergh, M., Emiliani, S., Biramane, J. *et al.* (1998) A first prospective study of the individual straight line velocity of the spermatozoon and its influences on the fertilization rate after intracytoplasmic sperm injection. *Hum. Reprod.*, **13**, 3103-3107.
- Van Steirteghem, A.C., Liu, J., Joris, H. *et al.* (1993a). Higher success rate by intracytoplasmic sperm injection than by subzonal insemination. Report on a second series of 300 consecutive treatment cycles. *Hum. Reprod.*, **8**, 1055-1060.
- Van Steirteghem, A.C., Nagy, Z., Joris, H. *et al.* (1993b). High fertilization and implantation rates after intracytoplasmic sperm injection. *Hum. Reprod.*, **8**, 1061-1066.
- Van Wissen, B., Eisenberg, C., Debey, P. *et al.* (1992) In vitro DNA fluorescence after in vitro fertilization (IVF) failure. *J. Assis. Reprod., Genetics*, **9**, 564-571.
- Van Wissen, B. and Bomsell-Helmreich, O. (1994) DNA fluorescence revealing oocyte quality, sperm behaviour, during gamete interaction, and embryo morphology. *Ass. Reprod. Reviews*, **4**, 128-133.
- Vanderzwalmen, P., Bertin, G., Lejeune, B. *et al.* (1996) Two essential steps for a successful intracytoplasmic sperm injection: Injection of immobilized spermatozoa after rupture of the oolemma. *Hum. Reprod.*, **11**, 540-547.
- Vanderzwalmen, P., Zech, H., Birkenfeld, A. *et al.* (1997) Intracytoplasmic sperm injection of spermatids retrieved from testicular tissue: influence of testicular pathology, type of selected spermatids and oocyte activation. *Hum. Reprod.*, **12**, 101-111.

- Van der Westerlaken, L.A.J., Helmerhorst, F.M., Hermans, J. *et al.* (1999) Intracytoplasmic sperm injection: position of the polar body affects pregnancy rate. *Hum. Reprod.*, **14**, 2565-2569.
- Vatev, I. and Toncheva, D. (1998) Chromosomal aberrations in unfertilized human oocytes. *Fertil. Steril.*, **70**, (suppl.1), P-1046.
- Veeck, L. (1991) Abnormal morphology of the human oocyte and conceptus. In: *Atlas of the human oocyte and early conceptus. Volume 2*, pp.151-179.
- Veeck, L. (1999) Abnormal morphology of the human oocyte and conceptus. In; *An atlas of human gametes and conceptuses. An Illustrated Reference for assisted Reproductive Technology*. pp. 57-68.
- Wall, M.B., Marks, K., Smith, T.A. *et al.* (1996) Cytogenetic and fluorescent in-situ hybridization chromosomal studies on in-vitro fertilized and intracytoplasmic sperm injected 'failed-fertilized' human oocytes. *Hum. Reprod.*, **11**, 2230-2238.
- Windt, M.-L., Franken, D.R., Kruger, T.F. *et al.* (1996) In vitro fertilization failure: Identification of gamete defects by investigation of sperm-zona pellucida binding capacity of unfertilized oocytes. *Andrologia*, **28**, 211-215.
- Windt, M.-L. and Coetzee, K. (1999) Ongoing pregnancies resulting from intracytoplasmic sperm injection (ICSI) of spermatozoa from frozen-thawed testicular biopsy specimen. - two case reports. *Andrologia*, **31**, 169-172.
- Wu, H., He, C.L. and Fissore, R.A. (1997) Injection of a porcine factor triggers calcium oscillations in mouse oocytes and bovine eggs. *Mol. Reprod. Dev.*, **46**, 176-189.
- Xia, P. (1997) Intracytoplasmic sperm injection: correlation of oocyte grade based on polar body, perivitelline space and cytoplasmic inclusions with fertilization rate and embryo quality. *Hum. Reprod.*, **12**, 1750-1755.
- Yanagida, K., Yazawa, H., Katayose, H. *et al.* (1998) Influence of oocyte preincubation time on fertilization after intracytoplasmic sperm injection. *Hum. Reprod.* **13**, 2223-2226.
- Yie, S.-M., Collins, J.A., Daya, S. *et al.* (1996) Polyploidy and failed fertilization in in-vitro fertilization are related to patient's age and gamete quality. *Hum. Reprod.*, **11**, 614-617.
- Zaninovic, N. and Rosenwaks, Z. (1998) Is oocyte orientation a factor in the outcome of ICSI? *Fertil. Steril.*, **70**, (suppl.1), P-361.

# CHAPTER 2

## MATERIALS AND METHODS

---

- **Intracytoplasmic sperm injection (ICSI)**

- ICSI technique
- Semen preparation
- Testicular sperm cryopreservation
- Stimulation protocols
- Embryo culture
- Embryo transfer

## INTRACYTOPLASMIC SPERM INJECTION (ICSI)

### Introduction

Intracytoplasmic sperm injection (ICSI) has become an accepted and widely used treatment method in most reproductive biology units across the world.

The very first reported fertilization success with ICSI in the human was as early as 1988 (Lazendorf *et al.*, 1988), but it took another 5 years for the first successful pregnancy to be reported by Palermo *et al.* in 1992. This success was preceded by years of applying other similar methods. Partial zona dissection (PZD) and subzonal sperm injection (SUZI) were the initial micromanipulation methods used to treat the severe male factor, but showed limited success. ICSI proved to be superior to all the other micromanipulation methods (Cohen *et al.*, 1992; van Steirteghem *et al.*, 1993a; Fishel *et al.*, 1994; Payne *et al.*, 1994) and has now replaced both PZD and SUZI.

In the past 4-5 years, ICSI has developed into a method that in some centers have produced 70% fertilization and up to 40% pregnancy rates (Palermo *et al.*, (1995). Developments that influenced the success rate included new and better equipment and microinjection needles, orientation of the polar body (not to injure the maternal chromosomal material), immobilization of the injected spermatozoon (to destabilize the sperm membrane) and aspiration of the ooplasm into the injection pipette (to ensure penetration into the oocyte and oocyte activation) (Fishel *et al.*, 1995; Tesarik *et al.*, 1994).

Pregnancies have also been reported after replacement of cryopreserved ICSI embryos (Van Steirteghem *et al.*, 1994). The use of epididymal and testicular spermatozoa in ICSI are also now common practice in most units offering ICSI (Silber *et al.*, 1995; Kahraman *et al.*, 1996) and recently cryopreserved testicular tissue (Nagy *et al.*, 1995; Romero *et al.*, 1996) has been used as a source of spermatozoa for ICSI. The injection of spermatides and spermatocytes is still controversial, but pregnancies and normal births have been reported. (Edwards *et al.*, 1994; Vanderzwalmen *et al.*, 1997; Fishel *et al.*, 1997).

ICSI has revolutionized the treatment of couples suffering from infertility due to a severe male factor, and one of the main concerns in this field is the possible risk of abnormalities in the offspring of such couples. Recent studies have, however, shown that no increased risk was indicated (Engel *et al.*, 1996; Govaerts *et al.*, 1996).

ICSI has now become an accepted and essential treatment method in an *in vitro* fertilization laboratory and has therefore become an important skill for the reproductive embryologist in the treatment of the severe male factor (Svalander *et al.*, 1995) to master.

### Micromanipulation media

During the micromanipulation procedure it is important not to expose the gametes to changes in temperature, pH and osmolarity. Two basic media (commercially available) are used in our ICSI programme,

1. HEPES buffered Earle's Balanced Salt Solution (EBSS) supplemented with a protein supplement and antibiotics. (Medicult universal IVF medium - Harrilabs, Johannesburg, South Africa)
2. NaHCO<sub>3</sub> buffered Earle's Balanced Salt Solution (EBSS) supplemented with a protein supplement and antibiotics. (Medicult sperm preparation medium - Harrilabs, Johannesburg, South Africa)
3. Blastocyst expanding medium (NaHCO<sub>3</sub> buffered) (Medicult M3 medium - Harrilabs, Johannesburg, South Africa)

All mediums are placed in a 5% CO<sub>2</sub> and 37°C environment for 20 hours prior to use. The HEPES buffered EBSS is incubated in a closed tissue culture flask and the NaHCO<sub>3</sub> buffered EBSS in a loosely capped tissue culture flask (to equilibrate the medium at the correct pH). All gamete manipulations are performed using the HEPES buffered EBSS and all incubations using the NaHCO<sub>3</sub> buffered EBSS.

#### Polyvinylpyrrolidone (PVP)

PVP (PVP-K90, MW 360 000) is commercially available at the required concentration of 10% in HEPES-buffered medium. (Medicult PVP, Harrilabs, Johannesburg, South Africa)

The use of this viscous solution slows sperm movement, facilitates sperm manipulation in the microinjection pipette and the injection of the sperm into the oocyte ooplasm.

#### Liquid paraffin

Equilibrated liquid paraffin is used to overlay all medium used in the micromanipulation and incubation procedures, to ensure a constant pH and osmotic pressure.

Pre-washed liquid paraffin (Medicult liquid paraffin, Harrilabs, Johannesburg, South Africa) is pipetted into a tissue culture flask and incubated at 5% CO<sub>2</sub> and 37°C for 20 hours before used to overlay the ICSI systems.

### **Stimulation Protocols and oocyte aspiration for ICSI**

#### Standard stimulation protocol

Ovarian hyperstimulation is carried out by the administration of gonadotrophin-releasing hormone agonist (GnRHa) (Synarel®; Montosano South Africa, Searle) in a long protocol, followed by human menopausal gonadotrophins (HMG) (Pergonal®; Serono, South Africa (Pty) Ltd) and/or pure follicle-stimulating hormone (FSH) (Metrodin®; Serono, South Africa (Pty) Ltd) from cycle day 3. Patients are followed up by doing serum luteinizing hormone (LH) and estradiol determinations as well as serial ultrasonographical measurement of the Graafian follicle. Ovulation is induced by the administration of human chorionic gonadotrophin (HCG) (Profasi®; Serono, South Africa (Pty) Ltd) as soon as the leading follicle reaches 18 mm in diameter.

#### Oocyte aspiration

Follicle aspiration is done under conscious sedation (Dormicum - Roche Products (Pty) Ltd South Africa or Diprovan - Zeneca Pharmaceuticals, South Africa ). Oocytes are recovered by

transvaginal ultrasound-guided follicle aspiration 34-36 hours after HCG administration. The aspirated oocytes are then cultured in Medicult universal IVF medium (Harrilabs, Johannesburg, South Africa) at 5% CO<sub>2</sub> and 37°C for 3-6 hours before denuding.

### **Sperm preparation**

The sperm preparation method used is determined by the quality of the sample produced for the ICSI procedure. Therefore the visual/microscopic analysis of the sample is extremely important. Factors that may determine the separation method are; percentage motile sperm, rate of forward progression, concentration (total count) and the number of other cells in the semen sample.

Two basic procedures (wash and swim-up and gradient centrifugation) and modifications of these are used for the majority of semen samples. The standard wash and swim-up procedure, however, remains the best procedure for sperm preparation, even for ICSI. Swim-up ensures that no foreign particles are introduced into the sample, the sample is free of other cells and the percentage of motile sperm is high.

The medium used for all the sperm preparation procedures is a basic salt solution buffered with NaHCO<sub>3</sub> and HEPES and supplemented with a protein supplement (Medicult sperm preparation medium - Harrilabs, Johannesburg, South Africa)

#### Wash and swim-up

On the completion of liquefaction the semen sample is diluted 1:2 (semen:medium) in a round bottomed test tube and centrifuged at 350 to 400xg for 10 minutes. The supernatant is aspirated after centrifugation and the pellet resuspended with 2mL of medium and recentrifuged. After the 2nd centrifugation the supernatant is aspirated and the pellet carefully overlaid with 1mL of medium. The test tube is placed at an approximate 45° angle in a 5% CO<sub>2</sub> and 37°C environment for 60 minutes.

When faced with a problem sample the above procedure can be modified as follows: the number of test tubes the sample is divided into can be increased with a subsequent decrease in the volume of overlay medium on each pellet. Different test tube shapes can also be employed. In cases of very low initial concentrations the standard flat-bottomed tubes can be replaced with conical tubes.

#### Gradient centrifugation

This technique remains the best for samples with extremely low concentrations and samples with high concentrations of other cells. The best example of such a sample is of course a testis biopsy sample. Percoll (Sigma) gradient centrifugation is used for most of these samples. Recently substitutes for Percoll also became commercially available (Ixaprep, Pure sperm, Sil Select).

#### Percoll Stock solution (10mL)

0.021g of NaHCO<sub>3</sub> is dissolved in 1mL of 10X concentrated Hams F10medium (Gibco)  
9mL of Percoll is added to this solution

#### Gradients

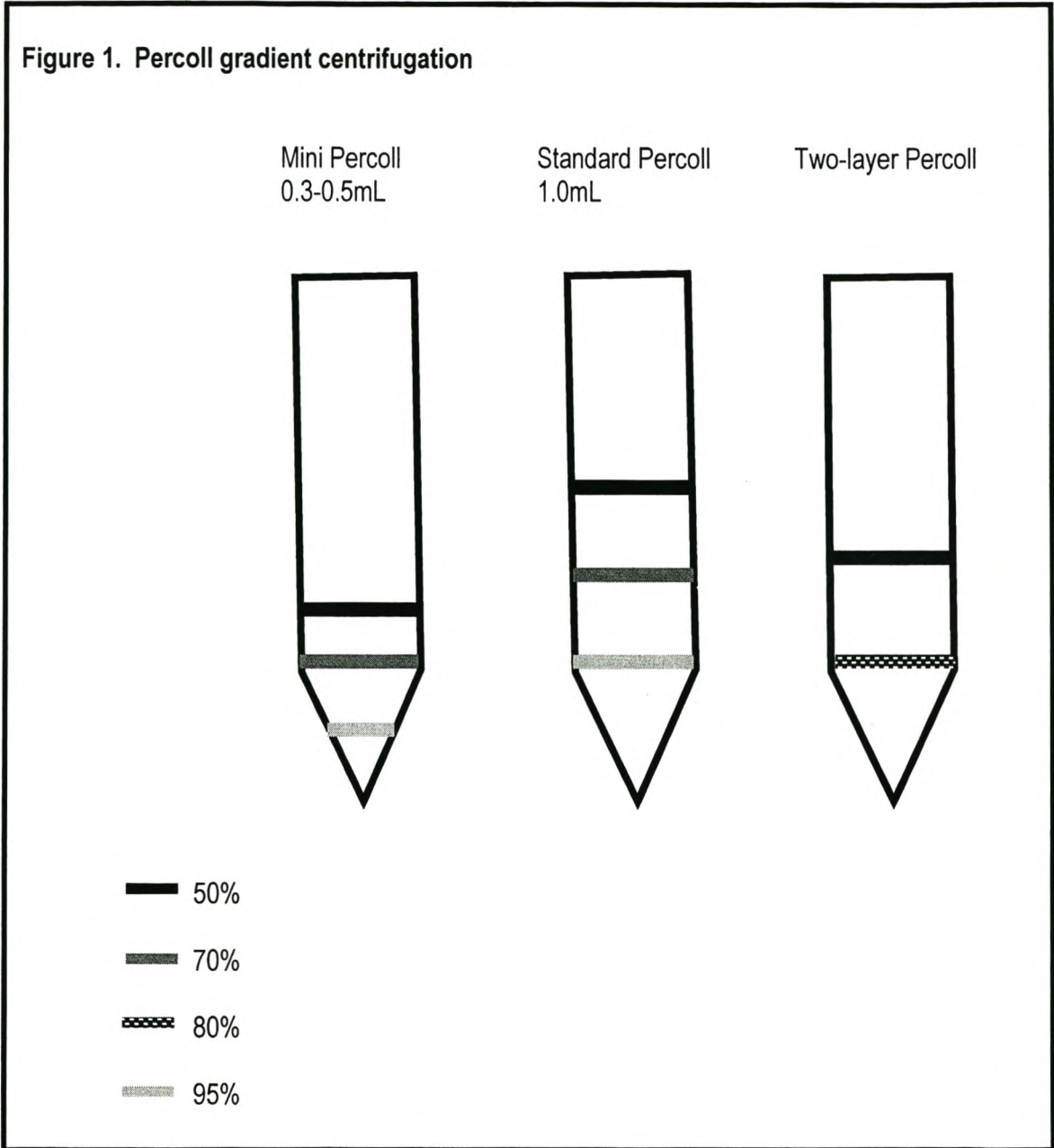
95%, 0.95mL of stock solution plus 0.05mL of medium

70%, 0.7mL of stock solution plus 0.3mL of medium

50%, 0.5mL of stock solution plus 0.5mL of medium

(Medicult sperm preparation medium - Harrilabs, Johannesburg, South Africa)

These solutions are carefully layered on each other, starting with the 95% solution at the bottom of a conical tube and allowed to equilibrate in an 5% CO<sub>2</sub> and 37°C environment (Figure1).



On the completion of liquefaction the semen sample is diluted 1:2 (semen: medium) in a test tube and centrifuged at 350 to 400xg for 10 minutes. The pellet is resuspended in 1mL of medium and carefully overlaid on the gradient. The gradient is centrifuged for 25 to 30 minutes at 300xg. After centrifugation the top layers are removed, the pellet resuspended in 0.3 to 0.5mL of medium and aspirated into a clean conical tube. The resuspended sperm sample is diluted with at least 3mL of



medium and washed by centrifugation (300 to 450xg for 10 minutes). The last step is repeated once more and the resultant pellet is resuspended in 0.3 to 0.5mL of medium.

It is not necessary to wash the semen sample prior to being overlaid onto the gradient, the raw semen sample can be used. When faced with a problem sample the volumes of the gradient can be decreased (0.3mL; mini-Percoll, Figure 1), the number of gradients can be increased and a two-step gradient can be used. The concentrations for a two-step gradient are, 80% and 50% (Figure 1). The latter procedure results in a higher final sperm concentration, but a decreased percentage of motile sperm.

#### Testis biopsy spermatozoa

Two surgical procedures are generally followed. The one is used to obtain epididymal aspirate and the other testicular tissue (tubules).

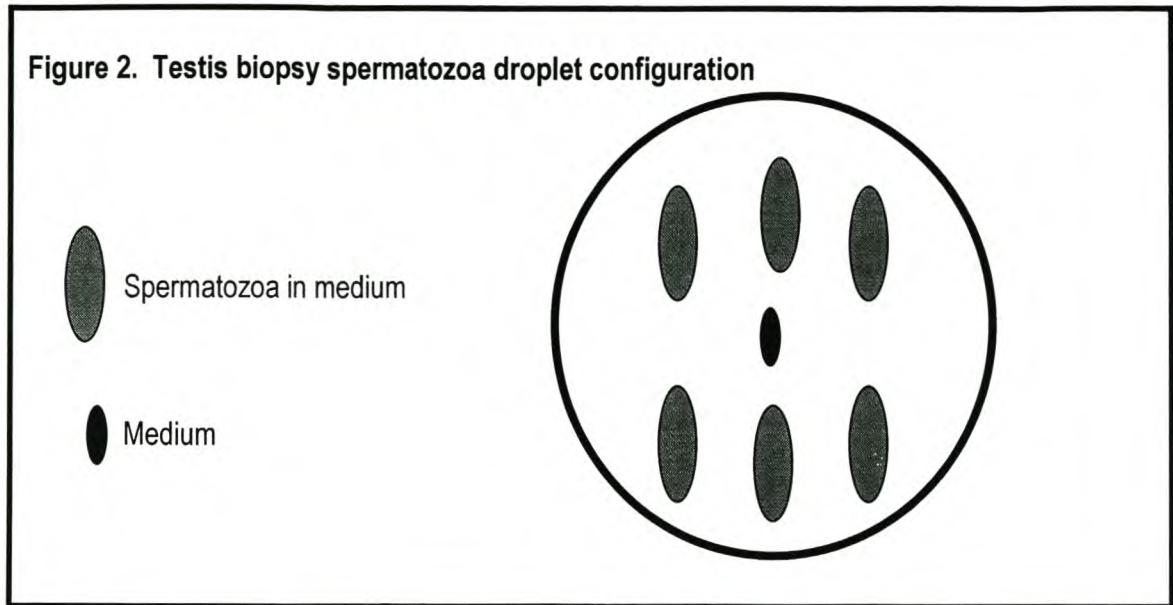
#### *Epididymal aspirate:*

Epididymal fluid is aspirated into a tube or Petri dish containing HEPES-buffered medium. (Medicult sperm preparation medium - Harrilabs, Johannesburg, South Africa). The aspirate-medium mixture received is microscopically examined for the presence of spermatozoa. If present, motile spermatozoa are obtained from the aspirate by mini-Percoll gradient centrifugation.

#### *Testis tissue:*

Testicular tissue removed by testis biopsy is placed into a Petri dish containing HEPES buffered medium (Medicult sperm preparation medium - Harrilabs, Johannesburg, South Africa). The tissue is then minced under microscopic view in the Petri dish using two surgical blades. The medium is continuously checked for the presence of spermatozoa. If found, the medium-tissue mixture is pipetted into a conical tube. The mixture is vortexed and left to stand for a few seconds so that the large tissue pieces can settle to the bottom. The supernatant is carefully removed and motile spermatozoa are obtained by mini-Percoll gradient centrifugation.

The number of sperm obtained after the separation process is extremely low. The resuspended pellet obtained from the gradient centrifugation must therefore be used to prepare a Petri dish as shown in Figure 2. After preparation the dish (droplets covered with parafin oil) is placed into the incubator for a few minutes to allow all the cells to settle. During this time the inverted microscope used for the microinjection is set-up with a microinjection needle (inner diameter 20µm). The Petri dish is placed onto the heated stage and the droplets searched for motile spermatozoa (Inverted microscope - Nikon Diaphot). Motile spermatozoa found in the droplets are transferred to the small medium droplet, until a sufficient number has been obtained. The spermatozoa are directly transferred to the PVP droplet of the microinjection Petri dish just before injection.



Experience has shown that the majority of testis biopsy spermatozoa obtained after Percoll gradient centrifugation are immotile. The spermatozoa do, however, become motile after a pre-incubation period. To allow for this "maturation" period, testis biopsies are performed 24 hours before the oocyte aspiration. This approach allows us the opportunity to thoroughly search the droplets for the presence of spermatozoa and to allow a 20 hour maturation period. If no spermatozoa are obtained, patients have time to reconsider the treatment regimen being followed.

### **Cryopreservation of testicular sperm/tissue**

In cases where enough testicular spermatozoa are obtained, cryopreservation can be done. The cryopreservation of supernumerary testicular spermatozoa or tissue avoids subsequent scrotal surgery. The cryopreservation of testicular tissue has many advantages; lower cost, lower patient stress, lower surgical risk (decreased surgical procedures) and facilitates the clinical management of the couple. The use of cryopreserved testicular tissue and spermatozoa is therefore a viable option for azoospermic men. The sample is usually incubated for 24 hours before cryopreservation to allow for maturation and an increase of motile spermatozoa.

The homogenate (including testicular tissue) is diluted 1:1 with cryoprotectant (v/v; egg-yolk 1: glycerol 2: citrate buffer 3) and thoroughly vortexed. The mixture is drawn into cryopreservation straws and frozen with a Planar (Kryo 10 Series) cryopreserver, using a stepwise controlled freezing programme.

For subsequent use, a single straw with cryopreserved testicular tissue is thawed at room temperature for 15 minutes. The thawed semen, cryoprotectant mixture is diluted slowly with sperm preparation medium and centrifuged for 10 minutes at 350xg. To isolate motile spermatozoa, the resuspended pellet is centrifuged on a discontinuous Percoll gradient (95, 70, 50%). The 95% layer is washed twice more and resuspended in 100 µl medium, incubated at room temperature, until used in the ICSI.

### Denuding of oocytes

Cumulus and corona cells are removed using a hyaluronidase solution and fire drawn and polished Pasteur pipettes.

#### Hyaluronidase solution

The enzyme is commercially available (Sigma) at different international unit concentrations. For example,

100 mg containing 320 IU/mg  $\Rightarrow$  32 000 IU


dissolve in 4 mLs of sterile phosphate buffered saline (PBS)  $\Rightarrow$  8000 IU/mL



aliquot 10  $\mu$ L (80 IU) amounts into Eppendorf vials and store at -20°C

#### Denuding pipettes

Two sizes (internal lumen diameter) of Pasteur pipettes are required;  $\pm$  150  $\mu$ m,  $\pm$  200  $\mu$ m. The pipettes (150 mm) are fire drawn and polished by trial and error. It is preferable to use borosilicate glass Pasteur pipettes (the quality of the glass is superior and ensure easy preparation - cutting with a diamond pen is easy and exact). The pipettes are attached to a mouth suction device with a 22  $\mu$ m filter inserted when used in the cleaning process.

Figure 3. Enzymatic denuding of oocytes



-  Hyaluronidase solution
-  HEPES buffered medium

### Enzyme treatment

The hyaluronidase concentration used for the denuding of the oocytes is 40 IU/mL (10  $\mu$ L containing 80 IU of enzyme, diluted in 2 mL of Hams F 10 medium [Gibco]).

One 4-well NUNC multidish (Falcon) is prepared for every 6-8 oocytes (Figure 3). Hyaluronidase solution (40 IU/mL) is pipetted into the first well and HEPES-buffered medium (Medicult sperm preparation medium - Harrilabs, Johannesburg, South Africa) into the other 3 wells. The solutions in each well are covered with liquid paraffin (Medicult). The aspirated oocytes are transferred to the hyaluronidase solution using a standard Pasteur pipette. This pipette is used to remove the majority of cumulus cells by a gentle flushing motion (20-30 seconds). The cleaned oocytes are transferred to the next well with clean medium. The oocytes are again transferred to the next well with the medium pipette. The smallest pipette is now used to remove the remaining corona cells, using gentle but firm suction and transferred to the last well. The oocytes can now be evaluated for maturity (prophase I, metaphase I and metaphase II) and be separated according to their maturity.

A holding dish (consisting of a Petri dish with two large medium droplets [Medicult universal IVF medium - Harrilabs, Johannesburg, South Africa], covered with liquid paraffin), is used to store the oocytes prior to injection - metaphase II oocytes in one droplet and prophase I and metaphase I oocytes in the other (Figure 6).

### **Intracytoplasmic sperm injection (ICSI)**

The microinjection procedure is performed on an inverted microscope (Nikon Diaphot, IMP South Africa) equipped with,

- A heated microscope stage (37°C) (Winsam - IMP, South Africa)
- Two coarse and fine control manipulators (Narishige, IMP South Africa).
- Two microinjectors, one for the holding pipette and the other for the injection pipette (Narishige, IMP, South Africa and Research Instruments, UK).

The holding pipette (prepared in our own laboratory with a Narishige pipette puller, forger and grinder from glass capillary tubes (Drummond), is inserted into the pipette holder and manually positioned so that the angled section is perpendicular to the microscope stage (Figure 4). The pipette is positioned using the coarse manipulators. The microinjection pipette is inserted into the pipette holder and manually positioned so that the angled section is at angle of approximately 20° to the microscope stage (Figure 4). The angle is to ensure that the tip of the microinjection needle will touch the surface first. It must also be ensured that the two pipettes (holding and injection) move in line with each other.

*The capillaries for the injection and holding pipettes are washed twice in distilled water and sterilized with dry heat (3 hours/150° C). Finished pipettes are once heat sterilized before use.*

The microinjection dish contains oocyte droplets, spermatozoa and a PVP droplet (Figure 5).

Spermatozoa can be added to the microinjection dish in a number of ways:

- Sperm solution can be added to a large droplet of medium.
- Sperm solution can be added to a large droplet of PVP.
- Testis biopsy sperm are transferred from the testis biopsy dish (medium droplet) to a small PVP droplet in the microinjection dish.

One oocyte is added to each of the 5 oocyte droplets (Figure 5).

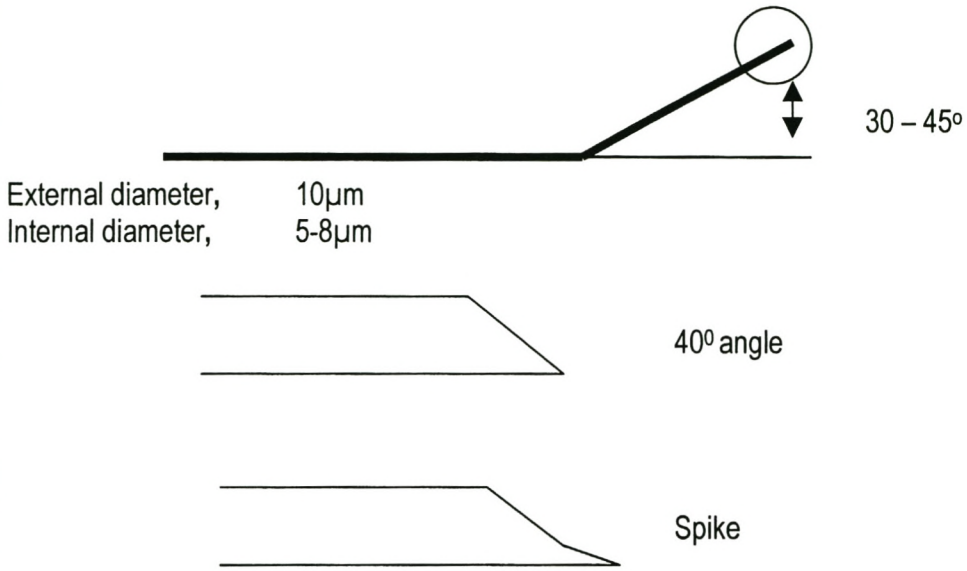
#### Selection and immobilization of sperm

The microinjection pipette is first carefully lowered into the clean PVP droplet. Before the manipulation of sperm is attempted, PVP medium is repeatedly aspirated and expelled to coat the inside of the microinjection pipette. A large enough volume (for optimum control) of PVP is aspirated and the pipette is lifted and moved to the sperm storage droplet.

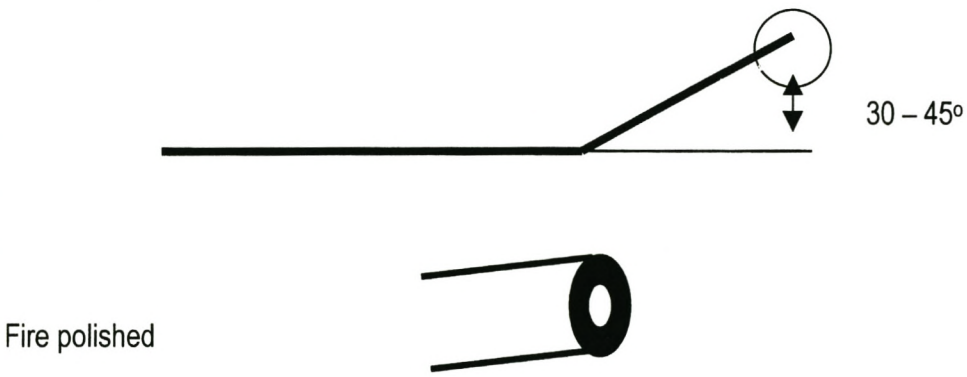
The motile spermatozoa pipetted into the storage droplet (medium or PVP) swim to the outer perimeter of the droplet. When selecting a sperm cell, preference is given to sperm which appear morphologically normal and which swim progressively forward. The motile sperm cell is aspirated into the injection pipette, the pipette is lifted and moved to the clean PVP droplet. The pipette is lowered to just above the surface in the PVP droplet, the sperm is slowly ejected moving the pipette up or down so that the sperm tail is transversally positioned to the pipette. The pipette point is lowered onto the section of the tail just below the midpiece. The pressure and the movement of the microinjection needle on and over the sperm tail, destabilizes the sperm membrane system and immobilizes the sperm. Destabilizing the sperm membrane before ICSI appears to be of crucial importance for decondensation of the sperm activation of the oocyte and ultimately pronuclei formation. It must be ensured that the sperm is immotile before injection, as a motile sperm may cause structural damage within the oocyte ooplasm. The sperm cell is aspirated and ejected repeatedly to ensure that it can be ejected during the injection procedure. The selected immobilized sperm is aspirated tail first into the microinjection pipette. The microinjection pipette containing the sperm is lifted and moved to the oocyte droplet.

**Figure 4. Micro-manipulation tools**

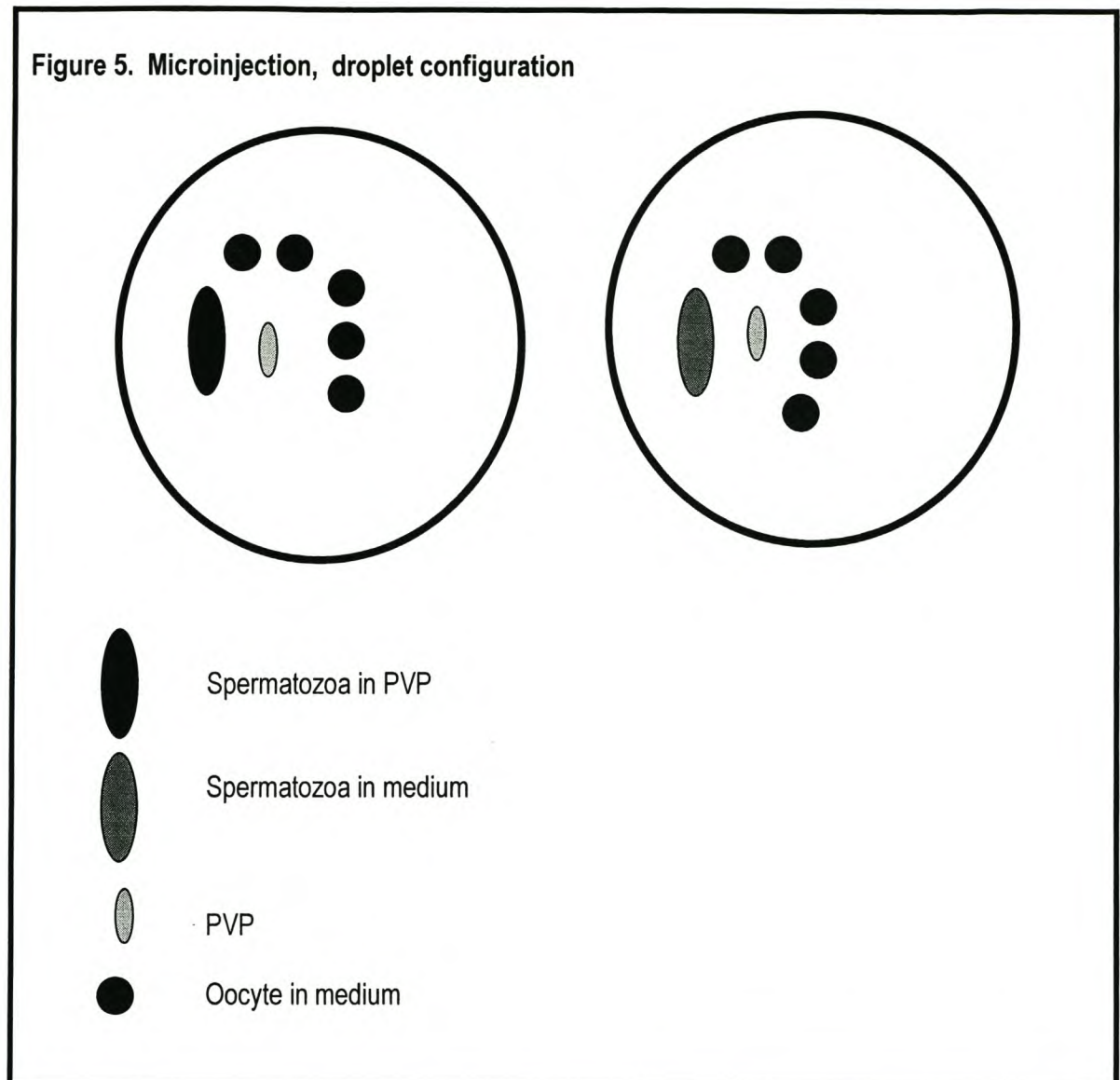
Micro-injection pipettes



Holding pipettes



External diameter, 90-100µm  
Internal diameter, 15-20µm

**Figure 5. Microinjection, droplet configuration**

### Oocyte microinjection

Using the microinjection pipette the oocyte is rotated to locate the polar body at the 12 o'clock or 6 o'clock position. The holding pipette is also lowered and the oocyte held by gentle suction close to the bottom of the dish. The microscope is focused on the oocyte's equatorial plane and the internal lumen of the holding pipette. The microinjection pipette is lowered into the same focus plane at the 3 o'clock position. The plane of the microinjection pipette can be corrected by gently pushing on the zona pellucida. The sperm is carefully brought forward to the point of the microinjection pipette and the pipette pushed carefully through the zona pellucida and through the oolemma into the ooplasm. The successful penetration of the oolemma is indicated by the ability to aspirate ooplasm into the pipette. The ooplasm and the sperm are then carefully ejected into the oocyte and the microinjection pipette withdrawn and the oocyte is released from the holding pipette. Care must be taken not to eject a large volume of PVP medium into the oocyte, because this inevitably leads to oocyte degeneration. This whole procedure is repeated for all the oocytes in the microinjection dish.

The oolemma of oocytes may have differences in elasticity that may depend on the hyperstimulation regiment followed, the female patient's age, the maturation of the oocyte and the in vitro age. A highly elastic oolemma makes penetration difficult (deeply invaginates when penetration is attempted). Repeat penetration may therefore be required to successfully penetrate the oolemma. These repeat penetrations must be performed without penetrating the opposite oolemma, as this may result in oocyte degeneration.

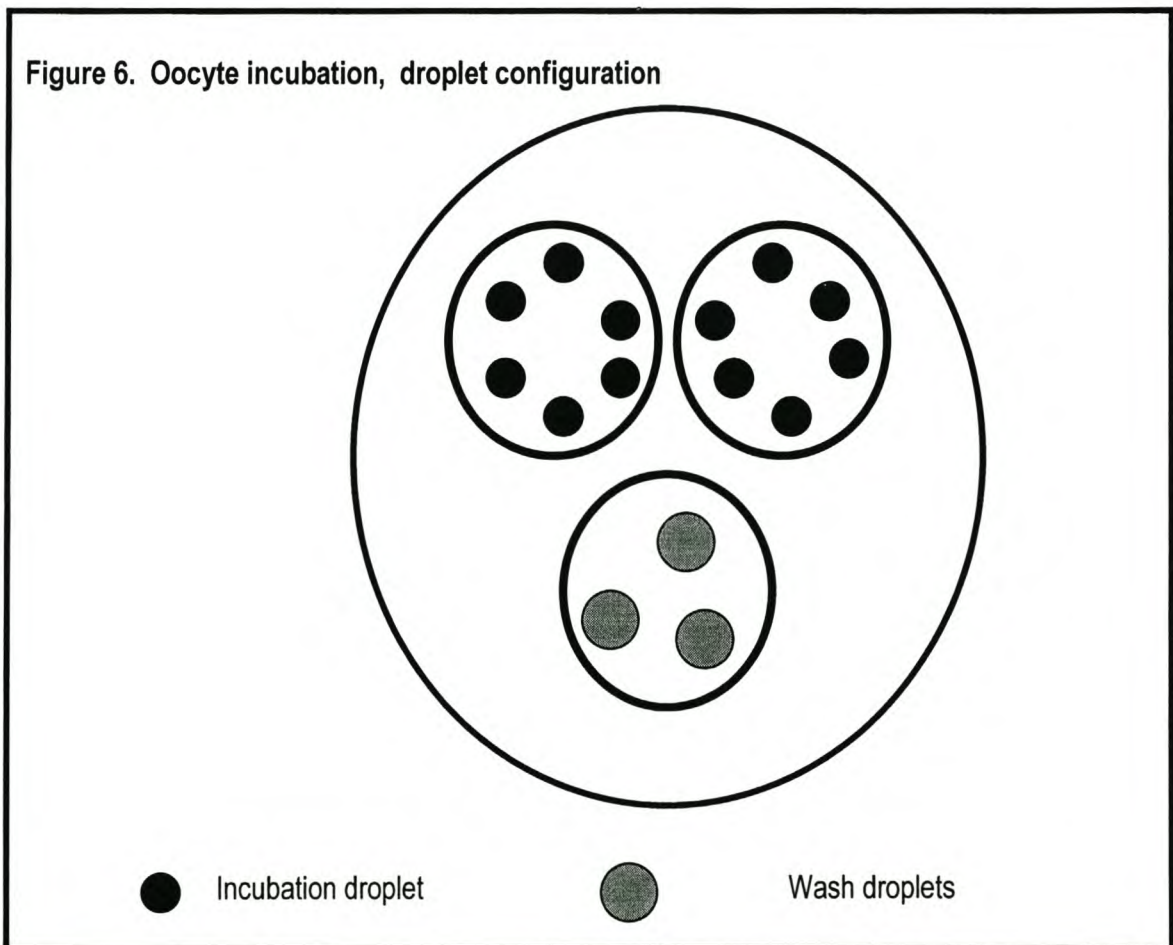
### **Embryo development, embryo transfer and pregnancy evaluation**

#### Embryo development

The injected oocytes are transferred to the oil covered wash droplets (Medicult universal IVF medium - Harrilabs, Johannesburg, South Africa) in the incubation dish and then transferred to individual droplets for further culture (Figure 6). The oocytes are examined 18-20 hours after injection for pronuclear development and transferred to a new incubation dish; 26 hours post injection for 2 cell division and at approximately 40 hours for 4 cell cleavage. If incubation goes to the 8 cell stage, embryos are transferred to M3 Medium (Medicult, Harrilabs, Johannesburg, South Africa). It is important to transfer the developing embryos into new medium daily, because of the small volume used for incubation.

Incubation dishes are covered with paraffin oil (Medicult, Harrilabs, Johannesburg, South Africa) at all times and incubation is at 5% CO<sub>2</sub> and 37°C.

**Figure 6. Oocyte incubation, droplet configuration**





### Embryo Transfer

Transfer at the 4 cell stage takes place in IVF Medicult medium and is either a tubal (laparoscopic) transfer (2 or 3 embryos transferred) or a uterine (trans-vaginal) transfer (2,3 or 4 embryos transferred). Transfer at the 6-8 cell is performed exactly as for 4 cells but in M3 Medicult medium.

Uterine transfer is done atraumatically with an Edwards-Wallace catheter (Simms, UK) after aspiration of obvious cervical mucus. In difficult cases a vasselum and/or Edwards-Wallace stillet (Simms, UK) is additionally applied. Tubal transfer is done by laparoscopy with a GIFT transfer catheter. The catheter is passed through a canula and subsequently inserted up to a distance of 2 cm through the fimbrial opening of the fallopian tube.

Early dividing (2 cell at 26 hours post injection) embryos are always the first choice for transfer - the rest of embryos for transfer are chosen using embryo quality grading.

### Pregnancy evaluation

Pregnancy tests are done on serum 10 days and 14 days post transfer. Pregnancy is diagnosed by  $\beta$  HCG levels ( $>10$  mIU/mL and on day 14 be at least 4 times the value of day 10 for a clinical pregnancy). A fetal heartbeat (ultra sound) at 7 weeks post transfer and at least 20 weeks gestation confirms an ongoing pregnancy pregnancy.

## References

- Ahmadi, A., Ng, S.-C. (1997) The single sperm curling test, a modified hypo-osmotic swelling test, as a potential technique for the selection of viable sperm for intracytoplasmic sperm injection. *Fertil. Steril.*, **68**, 346-350.
- Barros, A., Sousa, M., Angelopoulos, T. *et al.* (1997) Efficient modification of intracytoplasmic sperm injection technique for cases with total lack of sperm movement. *Hum. Reprod.*, **12**, 1227-1229.
- Bonduelle, M., Legein, J., Buysse, A., *et al.* (1996) Prospective follow-up of 423 children born after intracytoplasmic sperm injection. *Hum. Reprod.*, **11**, 1558-1564.
- Casper, R.F., Meriano, J.S., Jarvi, K.A, *et al.* (1996) The hypo-osmotic swelling test for selection of viable sperm for intracytoplasmic sperm injection in men with complete asthenozoospermia. *Fertil. Steril.*, **65**, 972-976.
- Cohen, J., Talansky, B.E., Adler, A. *et al.* (1992) Controversies and opinions in clinical microsurgical fertilization. *J. Assist. Reprod. Genet.*, **9**, 94-96.
- Chen, S.-U., Ho, H.-N., Chen, H.-F., *et al.* (1996) Intracytoplasmic sperm injection (ICSI) for severe semen abnormalities, dissecting the tail of spermatozoa at the tip. *Hum. Reprod.*, **11**, 640-2644.
- Edwards, R.G., Tarin, J.J., Dean, N. *et al.* (1994) Are spermatid injections into human oocytes mandatory? *Hum. Reprod.*, **9**, 2217-2219.
- Engel, W., Murphy, D., Schmid, M. (1996) Are there genetic risks associated with microassisted reproduction? *Hum. Reprod.*, **11**, 2359-2370.
- Fishel, S., Timson, J., Lisi, F. *et al.* (1994) Micro-assisted fertilization in patients who have failed subzonal insemination. *Hum. Reprod.*, **9**, 501-505.
- Fishel, S., Lisi, F., Rinaldi, L., *et al.* (1995) Systematic examination of immobilizing spermatozoa before intracytoplasmic sperm injection in the human, in Experiences with ICSI. *Hum. Reprod.*, **10**, 497-500.
- Fishel, S., Green, S., Hunter, A. *et al.* (1997) Human fertilization with round and elongated spermatids. *Hum. Reprod.*, **12**, 336-340.
- Gerris, J., Mangelschots, K., Van Royen, E., *et al.* (1995) ICSI and severe male-factor infertility, breaking the sperm tail prior to injection, in Experiences with ICSI. *Hum. Reprod.*, **10**, 484-486.
- Govaerts, I., Koenig, I., Van den Bergh, M. *et al.* (1996) Is intracytoplasmic sperm injection (ICSI) a safe procedure? What do we learn from early pregnancy data about ICSI? *Hum. Reprod.*, **11**, 440-443.
- Kahraman, S., Özgür, S., Alatas, C. *et al.* (1996) High implantation and pregnancy rates with testicular sperm extraction and intracytoplasmic sperm injection in obstructive and non-obstructive azoospermia. *Hum. Reprod.*, **11**, 673-676.
- Lazendorf, S.E., Maloney, M.K., Veeck, L.L. *et al.* (1988) A preclinical evaluation for pronuclear formation by microinjection of human spermatozoa into human oocytes. *Fertil. Steril.*, **49**, 835-842
- Meschede, D., Host, J. (1997) Sex chromosomal anomalies in pregnancies conceived through intracytoplasmic sperm injection, a case for genetic counselling. *Hum. Reprod.*, **12**, 1125-1127.
- Nagy, Z., Liu, J., Janssenwillen, C., Silber, S. *et al.* (1995) Using ejaculated, fresh, and frozen-thawed epididymal and testicular spermatozoa gives rise to comparable results after intracytoplasmic sperm injection. *Fertil. Steril.*, **63**, 808-815.
- Palermo, G., Joris, H., Devroey, P. *et al.* (1992) Pregnancies after intracytoplasmic injection of a single spermatozoon into an oocyte. *Lancet*, **340**, 17-18.

- Palermo, G.D., Cohen, J., Alikani, M. *et al.* (1995) Intracytoplasmic sperm injection; a novel treatment for all forms of male factor infertility. *Fertil. Steril.*, **63**; 1231-1240.
- Pauer, H.U., Hinney, B., Michelmann, H.W., *et al.* (1997) Relevance of genetic counselling in couples prior to intracytoplasmic sperm injection. *Hum. Reprod.*, **12**, 1909-1997.
- Payne, D., Flaherty, S.P., Jeffrey, R. *et al.* (1994) Successful treatment of severe male factor infertility in 100 consecutive cycles using intracytoplasmic sperm injection. *Hum. Reprod.*, **9**, 2051-2057.
- Romero, J., Remohí, J., Mínguez, Y. *et al.* (1996) Fertilization after intracytoplasmic sperm injection with cryopreserved testicular spermatozoa. *Fertil. Steril.*, **65**, 877-879.
- Silber, S.J., Van Steirteghem, A.C., Liu, J. *et al.* (1995) High fertilization and pregnancy rate after intracytoplasmic sperm injection with spermatozoa obtained from testicle biopsy. *Hum. Reprod.*, **10**, 148-152.
- Svalander, P., Forsberg, A.-S., Jakobsson, A.-H. *et al.* (1995) Factors of importance for the establishment of a successful program of intracytoplasmic sperm injection treatment for male infertility. *Fertil. Steril.*, **63**, 828-837.
- Tesarik, J., Sousa, M., Testart, J. (1994) Human oocyte activation after intracytoplasmic sperm injection. *Hum. Reprod.*, **9**, 511-518.
- Van de Velde, H., Nagy, Z.P., Joris, H., *et al.* (1997) Effects of different hyaluronidase concentrations and mechanical procedures for cumulus removal on the outcome of intracytoplasmic sperm injection. *Hum. Reprod.*, **12**, 2246-2250.
- Van Steirteghem, A.C., Liu, J., Joris, H. *et al.* (1993a) Higher success rate by intracytoplasmic sperm injection than by subzonal insemination. Report of a second series of 300 consecutive treatment cycles. *Hum. Reprod.*, **8**, 1055-1060.
- Van Steirteghem, A.C., Nagy, Z., Joris, H. *et al.* (1993b) High fertilization and implantation rates after intracytoplasmic sperm injection. *Hum. Reprod.*, **8**, 1061-1066.
- Van Steirteghem, A.C., Van der Elst, J., Van den Abbeel, E. *et al.* (1994) Cryopreservation of supernumerary multicellular human embryos obtained after intracytoplasmic sperm injection. *Fertil. Steril.*, **62**, 775-780.
- Vanderzwalmen, P., Zech, H., Birkenfeld, A. *et al.* (1997) Intracytoplasmic injection of spermatids retrieved from testicular tissue, influence of testicular pathology, type of selected spermatids and oocyte activation. *Hum. Reprod.*, **12**, 1203-1213.

# CHAPTER 3

## RESULTS OF A 5 YEAR ICSI PROGRAM

---

- **Intracytoplasmic sperm injection (ICSI): five years of experience**
  
- **Intracytoplasmic sperm injection (ICSI) with testicular spermatozoa: five years of experience**

## INTRACYTOPLASMIC SPERM INJECTION (ICSI): FIVE YEARS OF EXPERIENCE

Windt M-L  
Kruger TF  
Coetzee  
Van der Merwe JP  
Stander FSH  
Erasmus EL  
Smit K  
Menkveld R

Reproductive Biology Unit, Department of Obstetrics and Gynaecology, University of Stellenbosch, Tygerberg Hospital, TYGERBERG, South Africa.

### Abstract

Intracytoplasmic sperm injection (ICSI) has been developed for the treatment of severe male infertility in the human - patients who could not be helped by standard in vitro fertilization techniques due to too few motile or morphological normal spermatozoa and also poor fertilization outcomes. ICSI can also be offered to azoospermic patients. Fresh and frozen-thawed epididymal and testicular spermatozoa from obstructive and also many non-obstructive azoospermic men can be successfully applied in ICSI. This review reports the results of 5 years of ICSI experience (1995-1999) at the Reproductive Biology Unit, Tygerberg Hospital. ICSI was performed in 634 cycles and in 593 an embryo transfer was possible. In 41 (6.5%) of the cycles there was no fertilization and therefore no transfer. Testicular spermatozoa were used in 158 (24.9%) of the cycles. ICSI was performed on 4495 metaphase II oocytes and of these 13.1% was damaged (86.9% intact). Of the intact oocytes, 62.2% were successfully fertilized and 94.8% developed into cleaved embryos. A total of 1708 embryos were transferred in 593 cycles; 341 tubal transfers and 252 uterine transfers. The clinical pregnancy rate and ongoing pregnancy rate was 26.1% and 19.1%, respectively (female age < 40 and > one embryo transferred). In tubal transfer cycles a 31.5% clinical and 24.4% ongoing pregnancy rate was reported. (Uterine transfer 16.9% and 10.0%, respectively). Fresh and frozen-thawed testicular cycle pregnancy rates were 30.2% and 30.4%, respectively. Selective transfer of early dividing embryos into the tube resulted in an ongoing pregnancy rate of 38.5%. Semen parameters, normal morphology and total motile spermatozoa had no effect on ICSI pregnancy rates. The pregnancy rate in tubal transfer cycles with 0-4% morphologically normal spermatozoa was 30.4%.

At the time of publication, 128 pregnancies have been reported; 75 pregnancies resulted in the birth of 97 healthy babies and 15 pregnancies are still ongoing.

## Introduction

In the new millennium, assisted reproductive medicine offers several different treatment options, each suited to the specific need of the infertile couple involved. Intra-uterine insemination (IUI), in vitro fertilization (IVF) and gamete intra-fallopian tube transfer (GIFT) are well-established methods of treatment for couples with mild male factor infertility combined with several female infertility problems. These methods are however not very successful in cases of severe male factor infertility (low concentration and progressive motility and poor sperm morphology), recurrent non- or poor fertilization, paraplegic patients and azoospermic (obstructive and non-obstructive) cases. Many of these patients were previously included in sperm donor programs and adoption programs.

The introduction of intracytoplasmic sperm injection (ICSI), a technique where one single sperm cell is injected into a mature oocyte, changed the fate and treatment of this group of patients. Since the first pregnancy report after ICSI fertilization (Palermo *et al.*, 1992), the method took off with leaps and bounds and is currently a routine procedure in most infertility units around the world. Modifications to the technique such as immobilization of the sperm cell (destabilizing the membrane) (Fishel *et al.*, 1995b; Vanderzwalmen *et al.*, 1996), gentle aspiration of the cytoplasm, (Vanderzwalmen *et al.*, 1996; Svalander *et al.*, 1995) positioning of the polar body (Palermo *et al.*, 1996) and development of fine microtools (Svalander *et al.*, 1995), resulted in increased fertilization and pregnancy rates.

Today in the year 2000, ICSI with fresh as well as cryopreserved testicular spermatozoa (Silber *et al.*, 1996; Nagy *et al.*, 1995b; Gil-Salom *et al.*, 1996; Windt *et al.*, 1999) and even spermatids from the testis (Tesarik *et al.*, 1995a; Fishel *et al.*, 1995a; Antinori *et al.*, 1997) were shown to be successful and many pregnancies have been reported.

We report our own experience with an ICSI programme (January 1995- December 1999) in the Reproductive Biology Unit, Tygerberg Hospital.

## Materials and Methods

### Patients

Patients treated with ICSI were either azoospermic, severe oligo-, astheno-, teratozoospermic or had previous poor or non-fertilization cycles. Female partners included patients with a normal fertility investigation, endometriosis, anovulation, tubal factor, immunologic factor, premature ovarian failure, cervical factor, and polycystic ovarian syndrome.

### Media

Medicult media and products (Harrilabs, South Africa) were used for all procedures:

Sperm preparation medium (HEPES buffered), was used for semen preparation; enzymatic oocyte denuding and sperm injection drops. Universal IVF medium was used for oocyte washing and incubation drops. Paraffin oil was used to cover medium drops and PVP used for the sperm immobilization drop.

### Stimulation protocol

Ovarian hyper-stimulation was carried out by the administration of gonadotrophin-releasing hormone agonist (GnRHa) (Synarel®; Montosano South Africa, Searle) in a long protocol, followed by human menopausal gonadotrophins (HMG) (Pergonal®; Serono, South Africa (Pty)

Ltd) and/or pure follicle-stimulating hormone (FSH) (Metrodin®; Serono, South Africa (Pty) Ltd) from cycle day 3. Patients were followed up by doing estradiol determinations as well as serial ultrasonographical measurement of the Graafian follicle. Ovulation was induced by the administration of human chorionic gonadotrophin (HCG) (Profasi®; Serono, South Africa (Pty) Ltd) as soon as the leading follicle reached 18 mm in diameter.

#### Semen preparation

Motile spermatozoa were isolated by a standard swim-up technique (whenever possible). In cases of oligo – and asthenozoospermia, gradient centrifugation was the method of choice. Ejaculated, testicular biopsy, cryopreserved ejaculated and cryopreserved testicular biopsy sperm specimens were included in the study.

#### *Testicular spermatozoa and cryopreservation*

In all cases, an open testicular biopsy was performed, 24 hours before the sonographic oocyte aspiration or on the same day of the aspiration. Testicular tissue (2-5 biopsies) was thoroughly dissected with two no 23 scalpel blades in 0.5 ml culture media (Medicult sperm preparation medium) and the resultant supernatant examined for the presence of spermatozoa. An aliquot of the testicular homogenate was prepared for the ICSI procedure (washed once with culture media, resultant pellet centrifuged on a discontinuous gradient (50%: 70%: 95%) and washed twice. The rest of the testicular biopsy homogenate was prepared for cryopreservation. The homogenate (including testicular tissue) was diluted 1:1 with cryoprotectant (v/v; egg-yolk 1: glycerol 2: citrate buffer 3) and thoroughly vortexed. The mixture was drawn into cryopreservation straws and frozen with a Planar (Kryo 10 Series) cryopreserver, using a stepwise controlled freezing program (20°C to -5°C at -1°C /minute; then -5°C to -80°C at -10°C/minute).

A single straw with cryopreserved testicular tissue was thawed at room temperature for 15 minutes. The thawed sperm:cryoprotectant mixture was diluted slowly with sperm preparation medium and centrifuged for 10 minutes at 350xg. To isolate motile spermatozoa, the resuspended pellet was centrifuged on a discontinuous gradient (95%: 70%: 50%). The 95% layer was washed twice and resuspended in 100µl medium, incubated at room temperature, until used in the ICSI.

#### Follicle aspiration and oocyte handling

Follicle aspiration was done under conscious sedation (Dormicum®; - Roche Products (Pty) Ltd) South Africa or Diprovan®; - Zeneca Pharmaceuticals, South Africa). Oocytes were recovered by transvaginal ultrasound-guided follicle aspiration 34-36 hours after HCG administration.

Retrieved oocytes were incubated with their cumulus mass for at least 3 hours in a small petri dish with lid (37°C, 5 % CO<sub>2</sub>) until denuding.

The cumulus mass was removed 3-5 hours post retrieval using 40 IU/mL hyaluronidase (Sigma) and denuding mouth pipettes. Denuded oocytes were rinsed 3X with 1 ml medium. Metaphase II oocytes were identified and incubated in 50µl drops covered with pre-equilibrated paraffin oil until injection (37°C, 5 % CO<sub>2</sub>).

#### Pre-embryo definition:

*(Pre-embryo: The conceptus during early cleavage stages until development of the embryo. The pre-embryonic period ends at approximately 14 days after fertilization with the development of the primitive streak) (Veeck, 1999).*

Hereafter the term "embryo" will be used for preembryo.

### Intracytoplasmic sperm injection (ICSI)

A standard method was followed. Prerequisites for successful injection were immobilization of the sperm cell in PVP and mild cytoplasmic aspiration. Oocytes were washed after injection and then incubated individually in 50 $\mu$ l drops of medium (under oil, 37°C, 5 % CO<sub>2</sub>). Oocytes were transferred to fresh medium daily and embryos cultured to the 8-cell stage, transferred into and cultured in Medicult M3 medium.

### Evaluation of fertilization, early division, cleavage and embryo quality

Each oocyte was evaluated individually at the following times:

- At  $\pm$  18 hours post injection for 2PN and 2 polar bodies;
- 25-27 hours ( $\pm$ 26 hours) post injection for 2 cell division (early division);
- $\pm$  45 hours post injection for 4 cell division;
- $\pm$  72 hours post injection for 6-8 cell division.

Early division and embryo quality were accurately reported. Embryos were regarded as "good quality" embryos when: they were at the 4 cell stage at 48 hours post injection with a morphological grading of 4 or 5 or at the 6-8 cell stage, 72 hours post injection with a morphological grading of 4 or 5.

- Grade 1*        *Pre-embryo with few blastomeres of any size, severe or complete fragmentation*
  - Grade 2:*      *Pre-embryo with blastomeres of equal and unequal size, significant cytoplasmic fragmentation*
  - Grade 3:*      *Pre-embryo with blastomeres of distinctly unequal size, few or no cytoplasmic fragments.*
  - Grade 4:*      *Pre-embryo with blastomeres of equal size; minor cytoplasmic fragments.*
  - Grade 5:*      *Pre-embryo, with blastomeres of equal size; no cytoplasmic fragments.*
- [Adapted from Veeck, (1999)]

### Embryo Transfer and Pregnancy evaluation

Embryos were transferred either at the 4 cell or 6 - 8 cell stages (day 2 or 3). Two transfer methods were followed: tubal (laparoscopic) transfer or uterine (trans-vaginal) transfer using the Wallace catheter (Simms, UK) or Tom Cat catheter. (Sovereign Sherwood Medical, St Louis, MO).

Two or more (but less than five) embryos were transferred per patient depending on the age of the female patient and the quality of the oocytes (more for increasing age and decreasing quality).

Pregnancies (clinical) were reported as positive when  $\beta$ HCG serum levels were >10 m IU/ml 10 days post transfer and increased to four times the value on day 14, post transfer. Ongoing pregnancies were reported when a fetal heartbeat (ultra sound) was present 7 weeks post transfer.

### Statistical analysis

For statistical analysis the programme Statistica® 6.0 was used. Basic statistics for the difference between two proportions (two-sided) were used to compare percentages. Basic statistics for the difference between means (normal distribution - two-sided) were used to compare mean values.



## Results

The results were analysed for certain time periods since the initial implementation of our ICSI programme.

The ICSI technique was performed on an experimental basis from May 1993 until December 1994, mainly on excess oocytes donated from gamete intrafallopian tube transfer (GIFT) cycles. The fertilization rate for this time period was 33.3% (136/406) and the damage rate 18.8% (96/502). In cases where ICSI embryos were transferred, no pregnancy resulted. Sperm immobilization and cytoplasmic aspiration as well as the use of more refined micropipettes were then initiated into the programme and for the next 49 injected oocytes (40 successfully) the fertilization rate improved to 40% (16/40) with the damage rate still high 18.4% (9/49). The first pregnancy was reported in January 1995 and the rest of the results are presented for each year from this time onwards.

Patients receiving **donated oocytes** are not included in Tables 1-7 and are reported separately: Twenty-five donor oocyte ICSI cycles resulted in a fertilization rate of 61.9% (73/118) and a pregnancy rate of 32.0% (8/25). The ongoing pregnancy rate was 12% (3/25). The average oocyte donor and recipient ages were 30.9 and 39.7 years respectively. Oocyte donors were mainly patients participating in infertility treatment in the unit.

Female patients **40 years and older** (n=88) (not in the donor oocyte programme) and patients receiving only **one embryo for transfer** (n=91) are also not included in the results presented in Table 1-7 and are reported separately: The pregnancy rate in the > 39 year (average 41.5 years) female age cycles was 2.3% (2/88) and both pregnancies ended in early abortion. In the 91 cycles where only one embryo was available for transfer, only 3 pregnancies resulted (3.3%) and only one was ongoing and resulted in the birth of a healthy child (1.1%).

Results presented in Tables 1-4, 6 and 7 are for female age < 40 years and where more than one embryo was available for transfer (Table 5 < 38 years). Cycles where embryos from classical IVF were transferred with ICSI embryos were not analysed in this report.

The overall results for ICSI cycles for the five-year period January 1995 to December 1999 are individually presented in Tables 1 and 2. The fertilization rate of 59% in 1995/1996 increased to 70% in the following three years and the damage rate decreased from  $\pm 14\%$  to < 10%. Clinical and ongoing pregnancy rates also increased, especially for the time period 1998/1999 ( $\pm 20\%$  to 30% clinical and  $\pm 17\%$  to 22% ongoing, respectively). From Table 1 it is also evident that fertilization and pregnancy rates were the lowest in 1996. The number of embryos transferred and female age was not different for the respective years. The average results for the five years are: Fertilization (65%); damage (12.1%); cleavage (94.2%); female age (32.7); embryos transferred (3.3); clinical pregnancy rate (26.1%) and ongoing pregnancy rate (19.1%). The results in Table 2 also show a higher prevalence of multiple pregnancies in 1997, 1998 and 1999 (2, 8 and 4 twins and 1, 1 and 2 triplets, respectively) compared to 1995 and 1996 (only one twin pregnancy). At the time of publication 97 babies have been born; 40 male and 57 female and 15 pregnancies are ongoing.

**Table 1**  
**Intracytoplasmic sperm injection (ICSI) results - 5 years of experience (January 1995 to December 1999)**

	1995 (n=62)	1996 (n=93)	1997 (n=95)	1998 (n=89)	1999 (n=91)	Total '95-99 (n=430)
<b>Female age (mean)</b>	32.2	32.7	32.7	33.3	32.7	<b>32.7</b>
<b>Fertilization (%)</b>	65.0 (264/406)	53.1 (405/762)	70.1 (459/654)	70.3 (455/647)	68.3 (480/703)	<b>65.0</b> <b>(2063/3172)</b>
<b>Damage (%)</b>	13.8 (65/471)	12.5 (109/871)	14.4 (104/722)	11.2 (82/729)	9.1 (70/773)	<b>12.1</b> <b>(430/3566)</b>
<b>Cleavage (%)</b>	87.5 (231/264)	93.8 (380/405)	93.7 (430/459)	97.1 (442/455)	96.3 (462/480)	<b>94.2</b> <b>(1945/2063)</b>
<b>Embryos transf. (mean)</b>	3.4	3.0	3.4	3.3	3.2	<b>3.3</b>
<b>Clinical pregnancy rate (%)</b>	25.8 (16/62)	18.2 (17/93)	24.2 (23/95)	31.5 (28/89)	30.8 (28/91)	<b>26.1</b> <b>(112/430)</b>
<b>Ongoing pregnancy rate (%)</b>	19.3 (12/62)	16.1 (15/93)	15.8 (15/95)	21.3 (19/89)	23.1 (21/91)	<b>19.1</b> <b>(82/430)</b>

**Table 2**  
**Intracytoplasmic sperm injection (ICSI) results: details of pregnancy outcome.**

	1995	1996	1997	1998	1999	Total
<b>Babies born (ongoing)</b>	13	18	19	33	14(15)	<b>97(15)</b>
<b>Male (n)</b>	6	7	7	15	5 (?)	<b>NA</b>
<b>Female (n)</b>	7	11	12	18	9 (?)	<b>NA</b>
<b>Singletons (n)</b>	11	14	12	14	5(10)	<b>56 (10)</b>
<b>Twins (n)</b>	1	2	2	8	3 (1)	<b>16 (1)</b>
<b>Triplets (n)</b>	0	0	1	1	1 (1)	<b>3 (1)</b>

Two transfer methods, transcervical uterine and laparoscopic tubal transfer, are practised in the unit and the respective results for the two methods are presented in Table 3. From the results it is clear that pregnancy rates after tubal transfer was significantly increased when compared to uterine transfer (clinical pregnancy rate: 31.5% (85/270) vs 16.9% (27/160);  $p = 0.0007$ , respectively and ongoing pregnancy rate: 24.4% (66/270).vs 10.0 % (16/160). Fertilization rates, female age and number of embryos transferred per patient were not significantly different for the two transfer methods. Pregnancy rates gradually increased in consecutive years for tubal transfer cycles. In uterine transfer cycles the best pregnancy results were obtained in 1998 (26.2%, 11/42) and a decreased rate was experienced in 1999 (15.2%, 5/33).

**Table 3**  
**Intracytoplasmic sperm injection (ICSI) results: the influence of transfer route (5 years of experience - January 1995 to December 1999)**

	1995	1996	1997	1998	1999	Total
<b><u>Tubal transfer</u></b>	(n=34)	(n=81)	(n=50)	(n=47)	(n=58)	(n=270)
<b>Fertilization rate (%)</b>	64.0	53.7	70.0	73.2	70.3	66.2
<b>Female age (mean)</b>	32.6	32.0	32.6	32.6	32.8	32.5
<b>Embryos transf. (mean)</b>	3.3	3.1	3.3	2.9	3.2	3.2
<b>Clinical pregnancy rate (%)</b>	38.2•	19.7	32.0	36.2	39.7Ψ	31.5♣
<b>Ongoing pregnancy rate (%)</b>	29.4*	17.2	20.0	25.5	31.0φ	24.4♦
<b><u>Uterine transfer</u></b>	(n=28)	(n=12)	(n=45)	(n=42)	(n=33)	(n=160)
<b>Fertilization rate (%)</b>	66.4	48.0	70.4	67.5	65.1	63.5
<b>Female age (mean)</b>	31.7	33.3	32.8	34.0	32.5	32.9
<b>Embryos transf. (mean)</b>	3.5	2.8	3.2	3.6	3.3	3.3
<b>Clinical pregnancy rate (%)</b>	10.7•	8.3	15.5	26.2	15.2Ψ	16.9♣
<b>Ongoing pregnancy rate (%)</b>	7.1*	8.3	11.1	16.7	9.1φ	10.0♦

♣  $p = 0.0007$

♦  $p = 0.0005$

•  $p = 0.0187$

\*  $p = 0.0321$

Ψ  $p = 0.0150$

φ  $p = 0.0186$

The results of 116 cycles where testicular sperm were injected are reported in Table 4. The pregnancy rates in these cycles compared favourably with that of ICSI with ejaculated spermatozoa (30.2% (35/116) and 24.5% (77/314), respectively). The use of cryopreserved testicular spermatozoa in ICSI was comparable to that of fresh testicular spermatozoa (30.4% (9/17) and 30.1% (19/76) pregnancy rate, respectively). Twenty-four hour incubation of testicular spermatozoa resulted in a significantly increased pregnancy rate when compared to non-incubated spermatozoa used in ICSI (53.9% (9/17) and 25.0% (19/76);  $p = 0.02$ , respectively).

**Table 4**  
**Intracytoplasmic sperm injection (ICSI) results with testicular spermatozoa. (5 years of experience - January 1995 to December 1999)**

	Clinical Pregnancy rate (%)	Fertilization rate (%)
<b>Testicular versus ejaculated spermatozoa</b>	30.2 (35/116) vs. 24.5 (77/314)	65.0 (585/900) vs. 65.0 (1478/2272)
<b>Cryopreserved versus fresh testicular spermatozoa</b>	30.4 (7/23) vs. 30.1 (28/93)	69.7 (108/155) vs. 64.0 (477/745)
<b>24 hour incubation versus 0 hour incubation testicular spermatozoa</b>	53.9 (9/17) vs. 25.0 (19/76)♣	73.7 (98/133) vs. 61.9 (379/612)♦

♣  $p = 0.02$       ♦  $p = 0.009$

**Table 5**  
**Pregnancy rates (%) after tubal and uterine transfer of early dividing embryos (Group A).**

Patient group		Group A	Group B
<b>Total</b>	Clinical Pregnancy rate [PR](%)	41.3 (26/63) <sup>d</sup>	20.0 (16/80) <sup>e</sup>
	Ongoing PR (%)	33.3 (21/63) <sup>a</sup>	16.3 (13/80) <sup>b</sup>
<b>Tubal ET</b>	Clinical Pregnancy rate [P](%)	43.6 (17/39) <sup>j</sup>	27.2 (12/44) <sup>k</sup> 22.7 (10/44) <sup>h</sup>
	Ongoing PR (%)	38.5 (15/39) <sup>g</sup>	
<b>Uterine ET</b>	Clinical Pregnancy rate [PR](%)	37.5 (9/24) <sup>p</sup>	11.1 (4/36) <sup>q</sup>
	Ongoing PR (%)	25.0 (6/24) <sup>m</sup>	8.3 (3/36) <sup>n</sup>

**Group A:** At least one early dividing embryo transferred  
**Group B:** No early dividing embryo transferred

$P^{ab} = 0.0191$   
 $P^{de} = 0.0069$   
 $p^{pq} = 0.0160$   
 $p^{lq} = 0.0022$   
 $p^{gn} = 0.0031$

Recent results with selective transfer of early dividing embryos (cleavage to the 2 cell stage 26 hours post injection) have shown an increased pregnancy rate when compared to slower dividing embryos; 41.3% (26/63) and 20.0% (16/80);  $p = 0.007$ ), respectively (Table 5). In case of tubal transfer of early dividing embryos, pregnancy results increased even more, but compared favourably with uterine transfer of early dividing embryos (43.6% (17/39) and 38.5% (15/39), respectively. (Table 4). Slow dividing embryos transferred into the uterus resulted in a decreased pregnancy rate of 11.1% (4/36). Statistical analysis indicated early division and tubal transfer to be the two factors to significantly determine a higher pregnancy rate.

The effect of sperm morphology and total motile number of spermatozoa on ICSI fertilization is presented in Table 6 and 7. Fertilization and pregnancy rates were similar for the two different morphology groups, 0-4% and 5-14%; (64.3% (958/1490) and 66.1% (345/522) fertilization rate and 25.5% (51/200) and 25.3% (19/75) pregnancy rate, respectively. The pregnancy rates of tubal transfer cycles in the two morphology groups were increased when compared to uterine transfer. For 0-4%; 30.4%(38/125) and 17.3% (13/75) and for 5-14%; 31.8% (14/44) and 16.1% (5/31), respectively. Testicular spermatozoa (morphology not possible to evaluate) gave similar results than ejaculated spermatozoa in terms of pregnancy rates: 30.2% (35/116) versus 25.5% and 25.3% for the two morphology groups (Table 6).

**Table 6**  
**The effect of normal sperm morphology on ICSI fertilization and pregnancy rate.**

Sperm morphology categories	Mean normal sperm morphology (%)	Fertilization rate (%)	Pregnancy rate (%)			Ongoing pregnancy rate (%)		
			Total	Tubal	Uterine	Total	Tubal	Uterine
<b>0-4 %</b> (n=200)	2.13	64.3 (958/1490)	25.5 (51/200)	30.4 (38/125)	17.3 (13/75)	20.0 (40/200)	23.2 (29/125)	14.7 (11/75)
<b>5-14 %</b> (n=75)	7.6	66.1 (345/522)	25.3 (19/75)	31.8 (14/44)	6.1 (5/31)	16.0 (12/75)	25.0 (11/44)	3.2 (1/31)
<b>Testicular spermatozoa</b> (n=116)	NA	65.0 (585/900)	30.2 (35/116)	31.6 (25/79)	27.0 (10/37)	22.4 (26/116)	24.0 (19/79)	18.9 (7/37)

The total number of motile spermatozoa (after preparation) did not have an influence on ICSI fertilization and pregnancy rates. For  $<1 \times 10^6$  and  $\geq 1 \times 10^6$  motile spermatozoa respectively, the fertilization rate was 65.3% (1324/2027) and 64.4% (741/1150) and pregnancy rate 27.6% (75/272) and 23.4% (37/157) (Table 7).

**Table 7**

**The effect of total motile spermatozoa on ICSI fertilization and pregnancy rate.**

Total motile spermatozoa ( $\times 10^6$ )	Mean number of motile spermatozoa ( $\times 10^6$ )	Fertilization rate (%)	Pregnancy rate (%)	Ongoing pregnancy rate (%)
$< 1 \times 10^6$ (n=272)	0.164	65.3 (1324/2027)	27.6 (75/272)	19.1 (52/272)
$\geq 1 \times 10^6$ (n= 158)	7.5	64.4 (741/1150)	23.4 (37/158)	18.9 (30/158)

**Table 8**

**Summary of patient statistics after ICSI (January 1995-December 1999)**

Total number of transfer cycles	593
Testicular sperm cycles	158
Total fertilization failure cycles	41
Oocytes injected	4495
Oocytes damaged	589 (13.1%)
Oocytes successfully fertilized (2PN)	2429 (62.2%)
Cleaved oocytes	2303 (94.8%)
Embryos transferred	1708
Tubal transfer cycles	341
Uterine transfer cycles	252
Pregnancies	128
Babies born	97
Boys	40
Girls	57
Singleton	56
Twins	16
Triplets	3
Ongoing pregnancies	15
Miscarriages/abortions	37
Ectopic pregnancies	2
Average female age (years)	34.5

Table 8 summarizes the overall statistics for ICSI cycles for the 5-year time period (January 1995 to December 1999) at the Reproductive Biology Unit, Tygerberg Hospital. A total of 634 ICSI stimulation cycles were performed and the average female age was 34.4 years. A total of 4495 oocytes were injected; 589 (13.1%) were damaged during the injection process and 2429 oocytes (62.2%) were successfully fertilized. The cleavage rate of successfully injected oocytes was 94.8%. One thousand seven hundred and eight (1708) embryos were transferred into 593 patients; 341 tubal and 252 uterine transfers. At the time of publication, 128 pregnancies have been reported; 75 pregnancies resulted in the birth of 97 healthy babies and 15 pregnancies are still ongoing. Two ectopic pregnancies and 37 early abortions were also reported. Of the 97 births, 57 were girls and 40 boys (56 singletons; 16 twins and 3 triplets). One hundred and fifty eight (158) patients were treated with testicular spermatozoa and ICSI. Forty one (41) cases with total fertilization failure after ICSI were reported (6.4% [41/634] of all retrieval cycles).

## Discussion

The first report of a pregnancy after intracytoplasmic sperm injection (ICSI) by Palermo *et al.* (1992), changed the treatment of severe male infertility. This report was soon followed by many others (Van Steirteghem *et al.*, 1993; Craft *et al.*, 1993; Schoysman *et al.*, 1993; Payne *et al.*, 1994; Mansour *et al.*, 1996) and ICSI is now a routine procedure practised in most in vitro fertilization centres all over the world.

In our own clinic, The Reproductive Biology Unit at the Tygerberg Hospital, Cape Town, South Africa, the first ICSI pregnancy in the country was announced in January 1995. At the time of this publication, almost 600 ICSI transfer cycles have been performed in our unit, almost 5 000 oocytes have been injected and 128 pregnancies have been reported. Ninety-three healthy babies have been born and another 15 pregnancies are ongoing.

From the results presented here it is clear that we, similarly to other reports (Svalander, *et al.*, 1995; Joris *et al.*, 1998), experienced a growth curve, with fertilization and pregnancy rates gradually increasing during the 5 year period. Damage rate decreased, indicating an improvement in skill and of microtools used. The increased incidence of multiple pregnancies in 1998 and 1999, also indicate an improvement in technical skill, possibly resulting in better quality embryos available for transfer.

The importance of the ICSI technique is demonstrated by the fact that the fertilization rates in this study was almost doubled when sperm immobilization and cytoplasmic aspiration were implemented in the programme. Joris *et al.* (1998) and Svalander, *et al.* (1995) reported similar results. Sperm immobilization produces membrane destabilization rendering it permeable to permit the release of cytosolic sperm factors into the ooplasm that is able to initiate the activation of the egg (Fishel *et al.*, 1995b; Flaherty *et al.*, 1995; Vanderzwalmen *et al.*, 1996; Dozortsev *et al.*, 1997). Cytoplasmic aspiration appears to be a prerequisite for successful activation and ICSI fertilization (Tesarik and Sousa 1995b; Joris *et al.*, 1998), a way of making sure that the oolemma membrane is pierced and the sperm cell deposited inside the ooplasm and not in the artificial furrow formed during the injection. The quality of the microtools is also very important. In our experience the implementation of standardized pipettes decreased the damage rate and also reflected in better embryo quality and higher pregnancy rates as was reported by Svalander, *et al.* (1995) and Joris *et al.* (1998).

In 1996, two additional embryologists were trained in ICSI technique and started partaking in our ICSI programme. This was also the year when we experienced the lowest fertilization rates. The reason once again being the effect of a growth curve in an ICSI programme when embryologists have to acquire a new skill.

Overall results for this 5-year retrospective study (26.1% positive  $\beta$ -HCG outcome and 19.1% viable pregnancy rate - for ejaculated sperm specifically, the positive  $\beta$ -HCG outcome was 24.5%) compared favourably to other published results. In a review article by Silber (1998), a 30% pregnancy rate for ejaculated sperm was quoted. Similarly the report from the ESHRE Task Force (Tarlatis and Bili, 1998), reported a 28% positive  $\beta$ -HCG outcome and 21.3% viable pregnancy rate. The results of a 5-year period of ICSI cases from the group of Van Steirteghem (Van Steirteghem *et al.*, 1998) showed a positive  $\beta$ -HCG outcome of 36.2% and a delivery rate of 27.4%. The pregnancy results from a number of individual studies reviewed by Mansour (1998), varied between 29% and 56%. The fertilization rate in the studies mentioned above varied between 61% and 72% and also compare favourable to 65% reported in our own study. When the semen parameters, strict sperm morphology and sperm motility were correlated with ICSI fertilization rate and pregnancy rate it was found not to have any effect.

Fertilization and pregnancy rates in the 0-4 % (P-pattern) and 5-14 % (G-pattern) normal morphology groups in this study were similar. This finding was in agreement with several other reports which also found no effect on ICSI outcome (Nagy *et al.*, 1995b; 1998; Mansour *et al.*, 1995; Hammadeh *et al.*, 1996; Sallam *et al.*, 1998; K pker *et al.*, 1998). When ICSI is performed, the spermatozoa with the best morphology are chosen for injection (Nagy *et al.*, 1998). The effect on fertilization is therefore possibly not a true reflection of the abnormal profile of the semen sample. Some reports have however indicated that certain abnormal morphological features result in decreased fertilization and pregnancy rates (Tasdemir *et al.*, 1997; Moomjy *et al.*, 1998; Levran *et al.*, 1998b; Kahraman *et al.*, 1998,1999; O'Neil *et al.*, 1998; Osawa *et al.*, 1999). These features included abnormal head morphology, short acrosome region, round head, amorphous head, megalo head, severely tapered sperm heads and multiple tail spermatozoa.

Fertilization and pregnancy rates reported for severe teratozoospermia (0-4%) from the reports mentioned above, ranged from 44% to 70% and 13.3% to 50%, respectively (Nagy *et al.*, 1995a; Tasdemir *et al.*, 1997; Moomjy *et al.*, 1998; Kahraman *et al.*, 1998,1999; O'Neil *et al.*, 1998; Osawa *et al.*, 1999). Our own results in this group were 64.3% (fertilization) and 25.5% (pregnancy), which compare favourably.

The incidence of round-headed spermatozoa (globozoospermia) is one of the sperm morphology conditions associated with decreased fertilization, but can be effectively treated with ICSI. Fertilization with such spermatozoa is reduced, although fertilization and some pregnancies have been reported (Liu *et al.*, 1995; Rybouchin *et al.*, 1996; Battaglia *et al.*, 1997; Kilani *et al.*, 1998). In our clinic, one such case was reported (Coetzee *et al.*, 2000). The patient had reduced (42.9%, 3/7), but successful fertilization and a normal, ongoing twin pregnancy resulted after transfer of three embryos.

It has been shown that percentage normal sperm morphology (strict criteria) has an influence on fertilization in vitro and also on pregnancy rates in the GIFT procedure (Coetzee *et al.*, 1998, 1999). The P-pattern (0-4% normal forms) group of patients are especially at risk and poor normal sperm morphology is often a reason for the choice to perform ICSI. Our own protocol



currently allows one GIFT cycle in the P-pattern group (provided that an adequate number of motile spermatozoa are available). When the fertilization rate of excess oocytes is < 50% in a GIFT cycle, an ICSI cycle is considered. From the results shown here it is evident that the pregnancy rate with ICSI (combined with tubal transfer) in this specific group is increased when compared to that of GIFT (30.4% [38/125] vs 25% (De Bruijn *et al.*, 2000) and 30.4% [38/125] vs 15.2% (Coetzee *et al.*, 1999). This result shows that ICSI can be offered with confidence to patients where P-pattern sperm morphology seems to be the reason for the couple's infertility and especially where previous GIFT cycles were not successful.

When patients were divided into two groups where <math> < 1 \times 10^6 </math> and  $\geq 1 \times 10^6$  motile spermatozoa were recovered after preparation, fertilization and pregnancy rates were also not different. Previous studies also concluded that sperm motility and concentration do not influence fertilization and pregnancy in ICSI (Nagy *et al.*, 1995a; 1998; Hammadeh *et al.*, 1996; Sallam *et al.*, 1998; K pker *et al.*, 1998). An exception is for cases where only immotile (and presumably dead) spermatozoa are injected. In such cases both fertilization and pregnancy rates are significantly lower (Nagy *et al.*, 1995a; 1998). A recent study (Van den Bergh *et al.*, 1998) however showed a significant increase in ICSI fertilization (84% vs 68%) when sperm with a higher straight line velocity (VSL) were injected and suggest that the most motile sperm cell must be selected for ICSI.

Treatment for azoospermic patients using testicular spermatozoa in ICSI has been applied very successfully in our programme. Compared to ICSI with ejaculated spermatozoa of all morphology groups, ICSI with testicular spermatozoa gave similar fertilization and pregnancy rates. The results with testicular spermatozoa compares very favourable with published results from other groups (Mansour, 1998, Tarlatzis and Bili, 1998; Van Steirteghem *et al.*, 1998; Silber, 1998). Fertilization rates ranged from 38% to 65.5% compared to 65% in our own study. The pregnancy rate was also comparable (range 11.3% to 62.5% and 30.2% for Tygerberg).

Cryopreserved testicular and epididymal spermatozoa can also be used (Nagy *et al.*, 1995b; Silber *et al.*, 1996; Gil-Salom *et al.*, 1996; Romero *et al.*, 1996; Windt *et al.*, 1999). It has been shown to be as successful as fresh sperm in our own study as well as in other studies (Friedler *et al.*, 1997; Liu *et al.*, 1997; Tournaye *et al.*, 1999). Cryopreservation minimizes the number of testicular biopsies and facilitates patient management. A pregnancy rate of 30.4% (7/23) was achieved in cryopreserved testicular cycles and compares well with other reports (Gil-Salom *et al.*, 1996 [33%; 6/18]; Friedler *et al.*, 1997 [27%; 3/11] and Liu *et al.*, 1997 [33%; 4/12]). We also adapted our protocol and now perform testicular biopsies the day before the oocyte aspiration (Nagy *et al.*, 1995b; Edirisinghe *et al.*, 1996; Perraguin-Jayot *et al.*, 1997; Ben Yosef *et al.*, 1999; Balaban *et al.*, 1999). Testicular tissue is incubated at room temperature for 24 hours. This protocol increased the progressive motility of the spermatozoa and also showed significantly increased ICSI pregnancy rates compared to non-incubated testicular spermatozoa (53.9% [9/17] versus 25.0% [19/76]) (Table 4).

From the results presented here it is also clear that laparoscopic tubal transfer of ICSI embryos showed higher pregnancy rates than transcervical uterine transfer in the respective years reported. For both transfer routes, the effect of a growth curve is also evident. Initial uterine transfers (1995-June 1997) were performed with the Tom Cat catheter, a rigid and relatively inflexible catheter. A change to the softer, flexible Edward-Wallace catheter from June 1997, resulted in increased uterine transfer pregnancy rates, but pregnancy rates were still lower than

that of tubal transfer. Previous studies also showed an increased success in tubal transfer of early stage embryos over that of uterine transfer (Hammit, *et al.*, 1990; Frederick, *et al.*, 1994; Van Voorhis, *et al.*, 1995; Boldt, *et al.*, 1996; Tournaye, *et al.*, 1996; Bulletti, 1996; Kumar, *et al.*, 1997; Yovich, *et al.*, 1988; Levran, *et al.*, 1998a; Castelbaum, *et al.*, 1998). Although the uterus seems to be a suitable environment for embryos (Scott and Smith, 1998), the uterus and tube have different nutritional environments (Gardner *et al.*, 1996, 1998) and cleavage stage embryos are usually found in the fallopian tube and not in the uterus.

Recent results with the selective transfer of early dividing embryos (2 cell division 26 hours after injection) showed increased pregnancy rates compared to that of embryos dividing later (Windt *et al.*, 2000, submitted). Early division is indicative of embryo viability (Edwards and Beard, 1997; Shoukir *et al.*, 1997; Sakkas *et al.*, 1998; Sakkas, 1999) and preliminary studies in our clinic have shown a correlation between early dividing embryos and the ability for blastocyst formation. Twenty nine percent (29%) of early dividing embryos developed into blastocysts compared to 9% for slower dividing embryos. The combination of early dividing embryos and the tubal transfer route was once again the more successful one.

ICSI results in older women (> 40years), with transfer of their own fertilized oocytes, were very poor. It is known that older women have a decreased response to stimulation protocols, producing less oocytes, often associated with genetic abnormalities (Oehninger *et al.*, 1995; Devroey *et al.*, 1996; Abdelmassih *et al.*, 1996; Silber *et al.*, 1997; Yie *et al.*, 1996; Alrayyes *et al.*, 1997; Spandorfer *et al.*, 1998). These women had an increased pregnancy chance when they joined a donor oocyte programme. The oocyte donor programme combined with ICSI, proved to be successful and is a viable treatment option for older women as well as women with anovulation, poor ovarian response and ovarian failure.

Transfer of only one embryo also resulted in poor pregnancy rates. In all these cases only one embryo was available for transfer indicating either poor stimulation response or poor fertilization. It is arguable that such cycles should be terminated. One such pregnancy resulted however in the birth of a healthy child, but the prognosis of single embryo transfer in our experience is poor.

ICSI is therefore now an established treatment option for patients with severe male factor infertility, azoospermia and poor fertilization results. Pregnancy rates similar to that of other treatments such as IVF and GIFT can be and are achieved. Challenges for the future include: assisted hatching procedures for older patients and for zona hardening; blastomere biopsy for pre-implantation diagnosis (PGD) of genetically linked diseases; spermatid identification and injection; successful blastocyst culture and a link between early dividing embryos and blastocyst development; cytoplasm transfer and germinal vesicle transfer in patients with poor fertilization and poor embryo quality. Successful embryo selection methods to minimize multiple pregnancies using additional selection criteria such as oocyte polarity and pronuclear morphology, are also future prospects to investigate.

### **Acknowledgements**

Sincere thanks to the personnel of the Reproductive Biology Unit, Tygerberg Hospital and the theatre personnel of the Tygerberg Hospital.

This research was supported by the Harry and Doris Crossley Research Fund, University of Stellenbosch, Tygerberg.

## References

- Abdelmassih, R., Sollia, M.L.T., Moretto, M. *et al.* (1996) Female age is an important parameter to predict treatment outcome in intracytoplasmic sperm injection. *Fertil. Steril.*, **65**, 573-577.
- Alrayeres, S., Fakih, H. and Khan, I. (1997) Effect of age and cycle responsiveness in patients undergoing intracytoplasmic sperm injection. *Fertil. Steril.*, **68**, 123-127.
- Antinori, S., Versaci, C., Dani, G.A. *et al.* (1997) Fertilization with human testicular spermatids: four successful pregnancies. *Hum. Reprod.*, **12**, 286-291.
- Balaban, B., Urman, B., Sertac, A. *et al.* (1999) In-vitro culture of spermatozoa induces motility and increases implantation and pregnancy rates after testicular sperm extraction and intracytoplasmic sperm injection. *Hum. Reprod.*, **14**, 2808-2811.
- Battaglia, D.E., Koehler, J.K., Klein, N.A. *et al.* (1997) Failure of oocyte activation after intracytoplasmic sperm injection using round-headed sperm. *Fertil. Steril.*, **68**, 118-122.
- Ben-Yosef, D., Yogev, L., Hauser, R. *et al.* (1999) Testicular sperm retrieval and cryopreservation prior to initiating ovarian stimulation as the first line approach in patients with non-obstructive azoospermia. *Hum. Reprod.*, **14**, 1794-1802.
- Boldt, J., Schnarr, P., Ajamie, A. *et al.* (1996) Success rates following intracytoplasmic sperm injection are improved by using ZIFT vs IVF for embryo transfer. *J. Assist. Reprod. Genet.*, **13**, 782-785.
- Bulletti, C. (1996) Debating tubal transfer in assisted reproductive technologies. *Hum. Reprod.*, **11** 1820-1822.
- Castelbaum, A.J. and Freedman, M.F. (1998) Is there a role for gamete intra-fallopian tube transfer and other tubal insemination procedures? *Curr. Opin. Obstet. Gynecol.*, **10**, 239- 242.
- Coetzee, K., Kruger, T.F., Lombard, C.J. (1998) Predictive value of normal sperm, morphology: a structured literature review. *Hum. Reprod. Update*, **4**, 73-82.
- Coetzee, K., De Villiers, A., Kruger, T.F. *et al.* (1999) Clinical value in using an automated sperm morphology analyzer (IVOS). *Fertil. Steril.*, **71**, 222-225.
- Coetzee, K., Windt M-L., Menkveld, R. *et al.* (2000) An intracytoplasmic sperm injection pregnancy with a globozoospermia male. *J. Assis. Reprod. Genetics*, (submitted)
- Craft, I., Bennett, V. and Nicholsson, N. (1993) Fertilizing ability of testicular spermatozoa. *Lancet*. **349**, 846.
- De Bruijn, J.M., Kruger, T.F. and Lombard, C.J. (2000) Factors affecting the pregnancy outcome in a gamete intrafallopian transfer (GIFT) program. *J. Assis. Reprod. Genetics*, (submitted)
- Devroey, P., Godoy, H. Smitz, J., *et al.* (1996) Female age predicts embryonic implantation after ICSI: a case-controlled study. *Hum. Reprod.*, **11**, 1324-1327.
- Dozortsev, D., Qain, C., Ermilov, A. *et al.* (1997) Sperm-associated oocyte-activating factor is released from the spermatozoon within 30 minutes after injection as a result of the sperm-oocyte interaction. *Hum. Reprod.*, **12**, 2793-2796.
- Edwards, R.G. and Beard, H.K. (1997) Oocyte polarity and cell determination in early mammalian embryos. *Mol. Hum. Reprod.*, **3**, 863-905.
- Edirisinghe, W.R., Junk, S.M., Matson, P.L. *et al.* (1996) Changes in motility patterns during in-vitro culture of fresh and frozen/thawed testicular and epididymal spermatozoa: implications for planning treatment by intracytoplasmic sperm injection. *Hum. Reprod.*, **11**, 2474-2476.

- Fishel, S., Green, S., Bishop, M. *et al.* (1995a) Pregnancy after intracytoplasmic sperm injection of spermatids. *Lancet*, **345**, 1641-1642.
- Fishel, S., Lisi, F., Rinaldi, L. *et al.* (1995b) Systematic examination of immobilizing spermatozoa before intracytoplasmic sperm injection in the human. *Hum. Reprod.*, **10**, 497-500.
- Flaherty, S.P., Payne, D., Swann, N.J *et al.* (1995) Assessment of fertilization failure and abnormal fertilization after intracytoplasmic sperm injection. *Reprod.Fertil. Dev.*, **7**, 197-210.
- Frederick, J.L., Ord, T., Stone, S.C. *et al.* (1994) Frozen zygote intrafallopian transfer: A successful approach for transfer of cryopreserved embryos. *Fertil. Steril.*, **61**, 504-507.
- Friedler, S., Raziel, A., Soffer, Y. *et al.* (1997) Intracytoplasmic sperm injection of fresh and cryopreserved testicular spermatozoa in patients with non-obstructive azoospermia - a comparative study. *Fertil. Steril.*, **68**, 892-897.
- Gardner, D.K., Lane, M., Calderon, I. *et al.* (1996) Environment of the pre-implantation human embryo *in vivo*: metabolite analysis of oviduct and uterine fluids and metabolism of cumulus cells. *Fertil. Steril.*, **65**, 349-353.
- Gardner, D.K., Schoolcraft, B., Wagley, L. *et al.* (1998) A prospective randomized trial of blastocyst culture and transfer in in-vitro fertilization. *Hum. Reprod.*, **13**, 3434-3440.
- Gil-Salom M, Romero J, Minguez Y. *et al.* (1996) Pregnancies after intracytoplasmic sperm injection with cryopreserved testicular spermatozoa. *Hum. Reprod.*, **11**, 1309-1313.
- Hammadeh, M.E., Al-Hassan, S., Stieber, M. *et al.* (1996) The effect of chromatin condensation (Aniline blue staining) and morphology (strict criteria) of human spermatozoa on fertilization, cleavage and pregnancy rates in an intracytoplasmic sperm injection programme. *Hum. Reprod.*, **11**, 2468-2471.
- Hammit, D.G., Syrop, S.J., Walker, D.L. *et al.* (1990) Comparison of concurrent pregnancy rates for in-vitro fertilization - embryo transfer, pronuclear stage embryo transfer and gamete intra-Fallopian transfer. *Hum. Reprod.*, **5**, 947-954.
- Joris, H., Nagy, Z., Van de Velde, H. *et al.* (1998) Intracytoplasmic sperm injection: laboratory set-up and injection procedure. *Hum. Reprod.*, **13**, (suppl 1) 76-86.
- Kahraman, S., Akarsu, C., Sozen, E. *et al.* (1998) Fertility of pinhead and multiple tail megalohad spermatozoa only in the ejaculate with ICSI. *Fertil. Steril.*, **70**, (suppl.1), P- 812.
- Kahraman, S., Akarsu, C., Cengi, G. *et al.* (1999). Fertility of ejaculated and testicular megalohad spermatozoa with intracytoplasmic sperm injection. *Hum. Reprod.*, **14**, 726-730.
- Kilani, Z.M., Shaban, M.A., Ghunaim, S.D. *et al.* (1998) Triplet pregnancy and delivery after after intracytoplasmic injection of round-headed spermatozoa. *Hum. Reprod.*, **13**, 2177-2179.
- Kumar, A., Benny, P., Lenton, E.A. *et al.* (1997) Retrograde tubal embryo transfer in natural cycle in-vitro fertilization. *Hum. Reprod.*, **12**, 484-486.
- Küpker, W., Schukze, W. and Diedrich, K. (1998) Ultrastructure of gametes and intracytoplasmic sperm injection: the significance of sperm morphology. *Hum. Reprod.*, **13**, (Suppl. 1) 99-106.
- Levrán, D., Mashiach, S., Dor, J. *et al.* (1998a) Zygote fallopian transfer may improve pregnancy rate in patients with repeated failure of implantation. *Fertil. Steril.*, **69**, 26-30.
- Levrán, D., Nahum, H., Zakut, H *et al.* (1998b) The impact of injected sperm morphology on fertilization rate, embryo quality and pregnancy rate in IVF-ICSI cycles. *Fertil. Steril.*, **70**, (suppl.1), P 972

- Liu, J., Nagy, Z., Joris, H., Tournaye, H. *et al.* (1995) Analysis of 76 total fertilization failure cycles out of 2732 intracytoplasmic sperm injection cycles. *Hum. Reprod.*, **10**, 2630-2636.
- Liu, J., Tsai, Y-L., Katz, E. *et al.* (1997) Outcome of in-vitro culture of fresh and frozen-thawed human testicular spermatozoa. *Hum. Reprod.*, **12**, 1667-1672.
- Mansour, R. T., Aboulghar, M.A., Serour, G.I. *et al.* (1995) The effect of sperm parameters on the outcome of intracytoplasmic sperm injection. *Fertil. Steril.*, **64**, 982-986.
- Mansour, R., Aboulghar, M. A. Serour, G. *et al.* (1996) Intracytoplasmic sperm injection in six hundred and fifty consecutive cycles: The Egyptian IVF-ET Center Experience. *Middle East Fertil. Soc. J.*, **1**,55-60.
- Mansour, R. (1998) Intracytoplasmic sperm injection: a state of the art technique. *Hum. Reprod. Update*, **4**, 43-56.
- Moomjy, M., Sills, E.S., Rozenwaks, Z. *et al.* (1998) Implications of complete fertilization failure after intracytoplasmic sperm injection for subsequent fertilization and reproductive outcomes. *Hum. Reprod.*, **13**, 2212-2216.
- Nagy, Z.P., Liu, J., Joris, H. *et al.* (1995a) The result of intracytoplasmic sperm injection is not related to any of the three basic sperm parameters. *Hum. Reprod.*, **10**, 1123-1129.
- Nagy, Z., Liu, J., Janssenwillen, C., Silber, S. *et al.* (1995b) Using ejaculated, fresh, and frozen-thawed epididymal and testicular spermatozoa gives rise to comparable results after intracytoplasmic sperm injection. *Fertil. Steril.*, **63**, 808-815.
- Nagy, P.Z., Verheyen, G., Tournaye, H. *et al.* (1998) Special applications of intracytoplasmic sperm injection: the influence of sperm count, motility, morphology, source and sperm antibody on the outcome of ICSI. *Hum. Reprod.*, **13**, (Suppl. 1) 143-154.
- O'Neil, J., Lundquist, L., Ritter, J. *et al.* (1998) Should strict morphology be used to indicate the need for intracytoplasmic sperm injection? . *Fertil. Steril.*, **70**, (suppl.1), P-442.
- Oehninger, S., Veeck, L., Lazendorf, S. *et al.* (1995) Intracytoplasmic sperm injection: achievement of high pregnancy rates in couples with severe male factor infertility is dependent primarily upon female and not male factors. *Fertil. Steril.*, **64**, 977-981.
- Osawa, Y., Sueoka, K., Iwata, S. *et al.* (1999) Assessment of the dominant abnormal form is useful for predicting the outcome of intracytoplasmic sperm injection in the case of severe teratozoospermia. *J. Assis. Reprod. Genetics.* **16**, 436-442.
- Palermo, G., Joris, H., Devroey, P. *et al.* (1992) Pregnancy after intracytoplasmic injection of a single spermatozoon into an oocyte. *Lancet*, **2**, 17-18.
- Palermo, G., Cohen, J. and Rosenwaks, Z. (1996) Intracytoplasmic sperm injection: a powerful tool to overcome fertilization failure. *Fertil. Steril.*, **65**, 899-908.
- Payne, D., Flaherty, S.P., Jeffrey, R *et al.* (1994) Successful treatment of severe male factor infertility in 100 consecutive cycles using intracytoplasmic sperm injection. *Hum. Reprod.*, **9**, 2051-2057.
- Perraguin-Jayot, S., Audebert, A., Empeaire, J.C. *et al.* (1997) Ongoing pregnancies after intracytoplasmic injection using cryopreserved testicular spermatozoa. *Hum. Reprod.*, **12**, 2706-2709.
- Romero, J., Remohi, J., Minguez, Y. *et al.* (1996) Fertilization after intracytoplasmic sperm injection with cryopreserved testicular spermatozoa. *Fertil. Steril.*, **65**, 877-879.
- Rybouchkin, A., Dozortzev, D., Pelinck, M.J. *et al.* (1996) Analysis of the oocyte activating capacity and chromosomal complement of round-headed human spermatozoa by their injection into mouse oocytes. *Hum. Reprod.*, **11**, 2170-2175.

Sakkas, D. (1999) Blastocyst stage transfer: Pitfalls and benefits. The use of blastocyst culture to avoid inheritance of an abnormal paternal genome after ICSI. *Hum. Reprod.*, **14**, 4-5.

Sakkas, D., Shoukir, Y., Chardonnens, D. *et al.* (1998) Early cleavage of human embryos to the two-cell stage after intracytoplasmic sperm injection as an indicator of embryo viability. *Hum. Reprod.*, **13**, 182-187.

Sallam, H.N., Sallam, A.N. and Agamia, A.F. (1998) The correlation between eight sperm parameters assessed objectively and the fertilization rate in IVF and ICSI. *Fertil. Steril.*, **70**, (suppl.1), P-371.

Schoysman, R., Vanderzwalmen, P., Nijs, M. *et al.* (1993) Pregnancy after fertilization with testicular sperm (letter) *Lancet*, **342**, 1237.

Scott, L.A. and Smith, S. (1998) The successful use of pronuclear embryo transfers the day following oocyte retrieval. *Hum. Reprod.*, **13**, 1003-1013.

Shoukir, Y., Campana, A., Farley, T. *et al.* (1997). Early cleavage of in-vitro fertilized embryos to the 2-cell stage: a novel indicator of embryo quality and viability. *Hum. Reprod.*, **12**, 1531-1536.

Silber, S., Van Steirteghem, A.C., Nagy Z. *et al.* (1996) Normal pregnancies resulting from testicular sperm extraction and intracytoplasmic sperm injection for azoospermia due to maturation arrest. *Fertil. Steril.*, **55**, 110-117.

Silber, S.J., Nagy, Z., Devroey, P. *et al.* (1997) The effect of female age and ovarian reserve on pregnancy rate in male infertility: treatment of azoospermia with sperm retrieval and intracytoplasmic sperm injection. *Hum.Reprod.*, **12**, 2693-2700.

Silber, S. (1998) Intracytoplasmic sperm injection today: a personal review. *Hum. Reprod.*, **13**, (suppl 1) 208-218.

Spandorfer, S.D., Avrech, O.M., Colombero, L.T. *et al.* (1998) Effect of parental age on fertilization and pregnancy characteristics in couples treated by intracytoplasmic sperm injection. *Hum. Reprod.*, **13**, 334-338.

Svalander, P., Forsberg, A-S., Jakobsson, A-H. *et al.* (1995) Factors of importance for the establishment of a successful programme of intracytoplasmic sperm injection treatment for male infertility. *Fertil. Steril.* **63**, 828-837.

Tarlatzis, B.C. and Bili, H. (1998) Survey on intracytoplasmic sperm injection: report from the ESHRE Task Force. *Hum. Reprod.*, **13**, (suppl 1) 165-177.

Tasdemir, I., Tasdemir, M., Tavukcuoglu, S. *et al.* (1997) Effect of abnormal sperm head morphology on the outcome of intracytoplasmic sperm injection in humans. *Hum. Reprod.*, **12**, 1214-1217.

Tesarik, J., Mendoza, C. and Testart, J. (1995a) Viable embryos from injection of round spermatids into oocytes (letter) *N. Engl. J. Med.*, **333**, 525.

Tesarik, J. and Sousa, M. (1995b) Key elements of a highly efficient intracytoplasmic sperm injection technique: Ca<sup>2+</sup> fluxes and cytoplasmic dislocation. *Fertil. Steril.*, **64**, 770- 776.

Tournaye, H., Camus, M., Ubaldi, F. *et al.* (1996) Tubal Transfer: A forgotten art? Is there still an important role for tubal transfer procedures? *Hum. Reprod.*, **11**, 1815-1818.

Tournaye, H., Merdad, T., Silber, S. *et al.* (1999) No differences in outcome after intracytoplasmic sperm injection with fresh or with frozen-thawed epididymal spermatozoa. *Hum. Reprod.*, **14**, 90-95.

Van den Bergh, M., Emiliani, S., Biramane, J., *et al.* (1998) A first prospective study of the individual straight line velocity of the spermatozoon and its influences on the fertilization rate after intracytoplasmic sperm injection. *Hum. Reprod.*, **13**, 3103-3107.

Van Steirteghem, A.C., Liu, J., Joris, H *et al.* (1993) Higher success rate by intracytoplasmic sperm injection than by subzonal insemination. Report of a second series of 300 consecutive cycles. *Hum. Reprod.*, **8**, 1055-1060.

- Van Steirteghem, A., Nagy, P., Joris, H. *et al.* (1998) Results of intracytoplasmic sperm injection with ejaculated, fresh and frozen-thawed epididymal and testicular spermatozoa. *Hum. Reprod.*, **13**, (suppl 1) 134-142.
- Van Voorhis, B.J., Syrop, C.H., Vincent Jr, R.D. *et al.* (1995) Tubal versus uterine transfer of cryopreserved embryos: a prospective randomized trail. *Fertil. Steril.*, **63**, 578-583.
- Vanderzwalmen, P., Bertin, G., Lejeune, B. *et al.* (1996) Two essential steps for a successful intracytoplasmic sperm injection: Injection of immobilized spermatozoa after rupture of the oolemma. *Hum.Reprod.*, **11**, 540-547.
- Veeck, L. (1999) Appendix. In; *An atlas of human gametes and conceptuses. An Illustrated Reference for Assisted Reproductive Technology.* pp. 103-107.
- Windt, M.-L. and Coetzee, K. (1999) Ongoing pregnancies resulting from intracytoplasmic sperm injection (ICSI) of spermatozoa from frozen-thawed testicular biopsy specimen - two case reports. *Andrologia*, **31**, 169-172.
- Windt M-L., Kruger, T.F., Coetzee, K. *et al.* (2000) Comparative analysis of pregnancy rates after the transfer of early dividing embryos versus slower dividing embryos. *Hum.Reprod.*, (submitted).
- Yie, S.-M., Collins, J.A., Daya, S. *et al.* (1996) Polyploidy and failed fertilization in in-vitro fertilization are related to patient's age and gamete quality. *Hum. Reprod.*, **11**, 614-617.
- Yovich, J.L., Yovich J.M. and Edirisinghe, W.R. (1988) The relative chance of pregnancy following tubal or uterine transfer procedures. *Fertil. Steril.*, **49**, 858-864.

## **INTRACYTOPLASMIC SPERM INJECTION (ICSI) WITH TESTICULAR SPERMATOZOA: 5 YEARS OF EXPERIENCE**

**Windt M-L  
Coetzee K  
Kruger TF  
Menkveld R  
Van der Merwe JP**

Reproductive Biology Unit, Department of Obstetrics and Gynaecology, University of Stellenbosch, Tygerberg Hospital, TYGERBERG, South Africa.

### **Abstract**

**T**he aim of the study was to gain insight into the optimal management of the infertile couple with the husband suffering from azoospermia. One hundred and forty two intracytoplasmic sperm injection cycles performed with testicular extracted spermatozoa were retrospectively analysed. The following factors were investigated for their possible influence on fertilization, cleavage, damage, pregnancy and ongoing pregnancy rates; the use of fresh, cryopreserved and pre-incubated (24 hours) spermatozoa and the etiology of the husbands azoospermia (obstructive and non-obstructive). All microinjections were performed with apparently normal spermatozoa - a head with a tail of normal length. In 116 cycles at least 2 embryos were available for transfer. The overall fertilization, clinical pregnancy and ongoing pregnancy rates obtained for the 116 cycles were; 65.0%, 30.2% and 22.4% respectively. Similar outcomes were obtained for cycles using fresh testicular and cryopreserved testicular spermatozoa. Similarly, no significant differences were obtained between the cycles using spermatozoa from obstructive or non-obstructive azoospermic patients. An increase in motility after a 24 hour pre-incubation was dependent on the initial motility. If the motility initially was at least between 10 and 20% there was a significant increase in motility, below 10% there was no increase in total motility, but an increase in progressive movement was evident. Although the group was relatively small (n = 17) a significant improvement in fertilization (73.7%) and pregnancy (53.9%) rate was obtained when the testicular sample was pre-incubated for 24 hours. All our testicular biopsies are therefore performed the day before oocyte retrieval, superfluous spermatozoa cryopreserved and the remaining testicular homogenate pre-incubated for the 24 hours prior to oocyte retrieval.



## Introduction

The capability of intracytoplasmic sperm injection (ICSI) to effect high fertilization and pregnancy rates regardless of the source and the quality of the sperm parameters have extended its application to azoospermic patients. This is due to the unique condition that ICSI only requires a single viable spermatozoon per oocyte. Testicular sperm extraction and ICSI have therefore become common procedures in assisted reproduction programs for the treatment of both obstructive and non-obstructive azoospermic patients. Even couples in which the husband's spermatogenesis is severely impaired now have the possibility of fathering their own genetic children.

The performance of testicular biopsies are subject to two major problems; (1) the motility of testicular spermatozoa in fresh biopsies is often poor, making the selection of viable spermatozoa difficult and (2) and the detrimental effect of biopsies on spermatogenesis (testicular trauma). A number of published studies have indicated means of overcoming these problems. Incubating the testicular sperm for at least 24 hours, in culture medium, may increase the number of motile and progressively motile sperm (Edirisinghe *et al.*, 1996, Balaban *et al.*, 1999). The improvement in motility facilitates the selection of viable sperm thereby increasing the probability of fertilization. The cryopreservation of superfluous testicular tissue negates the necessity for repeat testicular sperm extractions, as repeat procedures may result in damage to testicular tissue, due to the invasive nature of the procedure (Nagy *et al.*, 1995, Gil-Salom *et al.*, 1996, Friedler *et al.*, 1997, Liu *et al.*, 1997, Oates *et al.*, 1997).

In this study we retrospectively examine the data collected from ICSI cycles that were performed with the use of testicular extracted spermatozoa, ultimately to develop the best infertility management strategy for azoospermic patients.

## Materials and Methods

### Medium

Medicult sperm preparation medium (HEPES-buffered, HarriLabs, South Africa) was used for the processing of testicular tissue, testicular spermatozoa, washing denuded oocytes and injection of oocytes. Medicult universal IVF medium (HarriLabs, South Africa) was used for embryo development in vitro. All procedures for the ICSI process was performed under paraffin oil (Medicult, HarriLabs, South Africa) at 37°C. Spermatozoa were immobilized in Medicult PVP (HarriLabs, South Africa).

### Patients

In the period of the study (January 1995 to December 1999) 142 ICSI cycles were performed in which the husbands had presented with azoospermia (obstructive and non-obstructive). In all cycles testicular biopsy was performed followed by the extraction of sperm from the testicular tissue.

### Testis Biopsy, sperm preparation and cryopreservation

In all cases an open testicular biopsy was performed. The husbands underwent multiple testicular biopsies from each testis. The number (2 to 5) depended on the presence or absence of spermatozoa. An incision of approximately 10mm was made into the tunica albuginea and the protruding tissue was removed by cutting with microsurgical scissors.

In 125 cycles the testicular biopsy was performed on the day of the aspiration and in 17 the day before the aspiration. Testicular tissue was thoroughly dissected in culture medium (Medicult, sperm preparation medium) and the homogenate examined for the presence of spermatozoa. No more than 5 biopsies were taken from a testis. Even if no sperm were identified in the testicular extraction fluid, on first inspection, the testicular sample was processed for ICSI.

If sufficient numbers of spermatozoa were present in the testicular extraction fluid the major part of testicular biopsy homogenate was cryopreserved. The cryopreservation was performed on the day of the testis biopsy. The homogenate (including the testicular tissue) was diluted 1:1 with cryopreservation medium (v/v egg yolk 1: glycerol 2: citrate buffer 3) and thoroughly mixed. The mixture was drawn into cryopreservation straws (0.5 or 0.25 ml) and frozen with a Planar (Kryo 10 series) cryopreserver, using a stepwise controlled freezing program (20°C to -5°C at -1°C/minute; then -5°C to -80°C at -10°C/minute). Straws are kept at -80°C for 10 minutes and then plunged into liquid nitrogen. The straws were stored in a liquid nitrogen cryogenic tank until used. During the study period 23 frozen homogenates were thawed for use in an ICSI cycle. After allowing to thaw for 15 minutes at room temperature the testicular fluid was diluted slowly with sperm preparation medium (Medicult) and processed by gradient centrifugation. The whole or a portion of the sample, depending on the concentration of spermatozoa, was layered on a discontinuous (95%,70%,50%) mini-Percoll gradient and centrifuged for 30 minutes (300 g). The supernatant was aspirated and the resultant pellet washed twice more by centrifugation (1000 g). In the lid of a small Petri dish two large square drops were made from the final pellet on both sides of a small drop of culture medium (Medicult, sperm preparation medium) and covered with liquid paraffin.

The Petri dish containing the two processed droplets was examined for the presence of spermatozoa. The number of spermatozoa collected was dependent on the number of oocytes obtained. The droplets were first examined for motile spermatozoa, these were aspirated using an injection needle and placed in the clean culture medium droplet. Where no motile sperm could be found immotile spermatozoa were collected. Because of the apparent higher incidence of decapitation when immobilizing testicular spermatozoa we normally collect twice as many spermatozoa as oocytes. All spermatozoa selected for injection were exhibiting a head with an appearance as near to normal as possible and with a tail of normal length.

### Stimulation

Ovarian hyperstimulation was performed in the female partners by using a combination of gonadotropin-releasing hormone agonist (GnRH-a, Synarel®, Searle, South Africa), human menopausal gonadotropin (HMG, Perganol®, Serono, South Africa) and follicle stimulating hormone (FSH, Metrodin®, Serono, South Africa), using a long protocol. Patients were followed up from around day 8 with serial ultrasonographical measurements on follicular growth. Ovulation was induced by administering human chorionic gonadotropin (HCG, Profasi®, Serono, South Africa) when the leading follicle reached 18 mm in diameter.

### Oocyte aspiration and preparation

Oocyte aspiration was performed by transvaginal ultrasound puncture 36 hours after HCG administration. The cells of the cumulus and corona radiata were removed after a 2-hour incubation period. First the oocytes were placed in HEPES-buffered culture media with 50 IU/ml of hyaluronidase (Type IV, Sigma, South Africa). After a brief incubation ( $\approx$  30sec) the remaining cells were stripped using hand-drawn glass pipettes. The denuded oocytes were washed 3 times

in fresh HEPES-buffered culture medium and assessed for maturity (prophase I, metaphase I and metaphase II). The assessed oocytes were placed in droplets (under paraffin oil) according to their nuclear maturity. ICSI was carried out on only the morphologically intact oocytes with an extruded polar body (metaphase II).

#### Intracytoplasmic sperm injection

In the lid of a small Petri dish (Falcon 3001) a small square droplet of PVP was placed (slightly off-center) and 5 droplets of HEPES-buffered culture medium were placed in a semi-circle around it. The droplets were covered with paraffin oil. Five metaphase II oocytes were placed one each in the droplets and the required number of spermatozoa transferred into the PVP droplet. A single sperm was immobilized using the injection pipette and aspirated tail first into the pipette. The Petri dish was moved to visualize an oocyte. The oocyte was positioned so that the polar body was located at the 12 or 6 o'clock position and secured in position by a holding pipette. The immobilized sperm was injected into the ooplasm. Mild cytoplasmic aspiration was used to confirm penetration of the oolemma. The procedure was repeated until all metaphase II oocytes were injected.

The injected oocytes were washed and placed, individually, in droplets of culture medium, under paraffin oil. The Petri dishes with the injected oocytes were placed in an incubator (37°C, 5% CO<sub>2</sub>). About 16-18 hours after injection the oocytes were inspected for fertilization - the presence of two distinct pronuclei (2PN). After a further 24 hours of culture in fresh culture medium the ova were inspected for cleavage. Embryos were graded according to blastomere size and the percentage of anucleate fragments. Three or 4 embryos were transferred at the 4- or 8-cell stage into the fallopian tube or into the uterus.

Pregnancy (clinical) was confirmed on day 10 (>10 IU/ml) and day 14 (>40 IU/ml) by measuring serum  $\beta$ HCG (IU/ml) concentrations. Ongoing pregnancy was confirmed by observing a gestational sac (heart beat) sonographically at 7 weeks of pregnancy.

#### Statistical analysis

Only data on the cycles in which at least 2 embryos were transferred and where the female age was <40 years were included for statistical analysis. Cases where the etiology of azoospermia was not known or was uncertain (9 cases) were not included in the separate analysis of obstructive and non-obstructive azoospermia.

Statistica® 6.0 was used for statistical analysis. Basic statistics for the difference between two proportions (two-sided) were used to compare percentages.

## Results

Of the original 142 cycles 7 cycles produced no fertilization (5%) and 19 cycles produced only 1 embryo for transfer (13.4%). In the 19 cycles in which only 1 embryo was transferred no pregnancies resulted. In remaining 116 (81.7%) cycles at least 2 embryos could be transferred and were therefore further analysed.

The outcomes of the 116 cycles are summarized in Table 1. One thousand and five metaphase II oocytes were injected, 900 of which remained morphologically normal, - representing a total damage rate of 10.4%. The fertilization rate (2PN) in the 116 cycles was 65.0%, with a cleavage rate of 93.8% per fertilized oocyte. The average number of embryos transferred was 3.2, resulting in a pregnancy rate ( $\beta$ HCG) of 30.2%. Twenty-six of the initial 35 pregnancies had a confirmation of a gestational sac and fetal heartbeat at 7 weeks of gestation.

Near identical outcomes were obtained when comparing the use of fresh and cryopreserved testicular spermatozoa (Table 1). Ongoing pregnancy in the fresh spermatozoa group was decreased (but not significantly) compared to the cryopreservation group (20.4% and 30.4% respectively,  $p = > 0.05$ ).

**Table 1**  
**The ICSI outcome of fresh or cryopreserved testicular spermatozoa cycles.**

	Cycle s (N)	Fertilization rate	Cleavage rate	Damage rate	Mean number of ova transferred	Pregnancy/ cycle	Ongoing pregnancy/ cycle
<b>Total</b>	116	65.0% 585/900	93.8% 549/585	10.4% 105/1005	3.2 373/116	30.2% 35/116	22.4% 26/116
<b>Fresh</b>	93	64.0% 477/745	98.9% 442/477	10.5% 87/832	3.3 305/93	30.1% 28/93	20.4% 19/93
<b>Cryopreserved</b>	23	69.7% 108/155	99.1% 107/108	10.4% 18/173	3.0 68/23	30.4% 7/23	30.4% 7/23
<b>P value (fresh versus cryopreserved)</b>		NS	NS	NS	NS	NS	NS

The pre-incubation of testicular sperm for 24 hours, to allow for maturity and an increase in motility, resulted in a significantly higher fertilization rate (73.7% vs. 61.9%,  $p = 0.009$ ) and pregnancy (53.9% vs. 25.0%,  $p = 0.021$ ) and higher ongoing pregnancy (35.3% vs. 19.7%,  $p = 0.186$ ) rate (Table 2). Although significant, the number of pre-incubation cycles was relatively small. The most visible manifestation after the pre-incubation period was a significant increase in the progressive movement, with little increase in total motility.

**Table 2**  
Comparison of the ICSI outcomes for fresh or preincubated (24 hours) spermatozoa.

	Cycles (N)	Fertilization rate	Cleavage rate	Damage rate	Mean number of ova transferred	Pregnancy/cycle	Ongoing pregnancy/cycle
<b>Fresh</b>	76	61.9% 379/612	93.1% 353/379	10.9% 75/687	3.3 247/76	25.0% 19/76	19.7% 15/76
<b>Incubated (24 hours)</b>	17	73.7% 98/133	90.8% 89/98	8.3% 12/145	3.4 58/17	53.9% 9/17	35.3% 6/17
<b>P value</b>		0.009	NS	NS	NS	0.021	NS

The etiology (obstructive or non-obstructive) of the husbands azoospermia did not seem to have an effect on the outcomes measured. The pregnancy rate in the non-obstructive azoospermic group was 29.4%, as compared to the 31.5% for the obstructive group (Table 3).

**Table 3**  
Comparison of the ICSI outcome for spermatozoa from obstructive or non-obstructive azoospermic men.

	Cycles (N)	Fertilization rate	Cleavage rate	Damage rate	Mean number of ova transferred	Pregnancy/cycle	Ongoing pregnancy/cycle
<b>Obstructive</b>	73	63.6% 348/547	91.7% 319/348	11.2% 69/616	3.1 229/73	31.5% 23/73	24.7% 18/73
<b>Non-obstructive</b>	34	66.6% 193/290	93.4% 186/193	10.5% 34/324	3.4 117/34	29.4% 10/34	17.6% 6/34
<b>P value</b>		NS	NS	NS	NS	NS	NS

Note: In 9 cases the true etiologies were unknown and were therefore not included for comparison.

## Discussion

Since its inception, the therapeutic application of ICSI has dramatically increased to now even include different azoospermic etiologies. The reason being that consistent and relatively high fertilization and pregnancy rates can be achieved, regardless of the semen parameters. Through this broad application couples whom in the past had only the option of adoption or donor spermatozoa can now be successfully treated to obtain their own genetic off-spring. The major concern when confronted with an azoospermic patient in an assisted reproductive program is the patient's correct etiology and the corresponding probability of obtaining spermatozoa from a testicular sperm extraction. It has been reported that no spermatozoa may be isolated from the harvested testicular tissue in 20 -30% of men who have non-obstructive azoospermia. This uncertainty is mainly due to the fact that there are no reliable pre-operative parameters that predict whether spermatozoa will or will not be obtained from the tissue (Ezeh *et al.*, 1998; Jezek *et al.*, 1998).

The 2 azoospermic etiologies (obstructive and non-obstructive), because of their differing spermatogenic activity, have been surgically categorized. Non-obstructive azoospermia was normally linked with testicular sperm extraction (biopsy) techniques and obstructive azoospermia to microsurgical techniques and needle aspirations. Because of the inherent inconsistency of prognoses, open biopsies were performed and are preferred for all patients in our clinic. This preference has also been reported by others (Ezeh *et al.*, 1998; Amer *et al.*, 1999). No statistical differences have been found between the fertilization, cleavage and pregnancy rates of epididymal and testicular spermatozoa used in ICSI (Silber *et al.*, 1995; Ghazzawi *et al.*, 1998).

The ICSI outcomes for ejaculated spermatozoa obtained during the same study period was 61.2% (fertilization) and 24.5% (pregnancy). These outcomes compare favourably with those obtained using testicular spermatozoa (Table 1), 65.0% (fertilization) and 30.2% (pregnancy). Confirming the precedent that sperm parameter quality was of no real significance when used in the performance of an ICSI, in our study the etiology of the husband's azoospermia also had no effect on the outcomes. Near identical outcomes were obtained for obstructive and non-obstructive azoospermic fertilization (63.6% versus 66.6%) and pregnancy (31.5% versus 29.4%) rates (Table 3). This was, however, contrary to a recent study published by Palermo *et al.* (1999), who obtained higher fertilization and pregnancy rates in cases of obstructive azoospermia than those in which spermatozoa were obtained from non-obstructive azoospermia cases. The surgical procedure may therefore be the most important step in the treatment of non-obstructive azoospermia. Testicular biopsies must be performed in a manner that maximizes the probability of obtaining tissue from focal areas of spermatogenic activity. This may require the performance of multiple, bilateral testicular biopsies (Jezek *et al.*, 1998).

The motility of spermatozoa obtained from freshly biopsied testicular tissue was more than often poor, demonstrating only a sporadic, non-progressive movement. A vital spermatozoon being a prerequisite for successful outcomes in ICSI often may result in a time consuming search for the collection of vital (motile) spermatozoa. The solution to the problem has been the in vitro culture of the testicular extracted spermatozoa. A number of groups (Edirisinghe *et al.*, 1996; Liu *et al.*, 1997; Balaban *et al.*, 1999) have demonstrated a significant improvement in the motility of testicular sperm after at least 24 hours of pre-incubation. After extraction, testicular sperm samples were cultured with testicular cells (prior to gradient centrifugation/separation) to gain any beneficial effects from the acellular and cellular contents of the testicular homogenates. A significant improvement in the motility was only seen after 24 hours of pre-incubation if the initial

motility was at least between 10 and 20%. In especially non-obstructive cases the initial motility was all, but non-existent. In these cases, after 24 hours of pre-incubation, the percentage of motility did not significantly change, but the progressive movement of the vital spermatozoa did become better. This improved forward progression facilitated and helped to expedite the identification and collection of vital spermatozoa. Our results also show that performing the testis biopsy on the day before oocyte recovery had a significant effect on the fertilization and pregnancy outcomes (Table 2). The pre-incubation period may serve as selection step by eliminating the possibly apoptotic spermatozoa and increase the motility of vital and DNA intact spermatozoa. Obtaining the testicular biopsies the day before oocyte retrieval also provides the opportunity to counsel patients where no spermatozoa were obtained with regard to their present and future options.

The correct management of an infertile couple with the husband suffering from azoospermia is critical, as a successful cycle requires the co-ordination of the recovery of vital gametes from both partners. Here the ability to successfully cryopreserve testicular extracted sperm has come to the rescue. A number of groups have published studies and case reports showing that the cryopreservation of testicular sperm did not detrimentally affect fertilization or pregnancy (Gil-Salom *et al.*, 1996, Friedler *et al.*, 1997, Liu *et al.*, 1997, Oates *et al.*, 1997, Ben-Yosef *et al.*, 1999, Gianaroli *et al.*, 1999, Windt *et al.*, 1999). The results from our study reflect this same ability, as the fertilization (69.7%) and pregnancy (30.4%) outcomes were nearly identical to that obtained with fresh spermatozoa (Table 1). It has also been speculated that cryopreservation may also serve as selection step by eliminating the apoptotic spermatozoa. This manifestation has significantly improved the management of our azoospermic patients. Current clinical and laboratory methods have poor predictive value of testicular sperm extraction outcome and this fact has become the driving force to perform the testicular biopsy prior to the assisted reproduction cycle. The obvious reasons being that; primarily the presence of spermatozoa can be confirmed and if sufficient numbers of spermatozoa were present multiple samples could be cryopreserved. This alleviates the necessity for multiple testicular biopsies. Multiple assisted reproduction cycles can therefore be planned, because of the certainty of having spermatozoa for each cycle.

The outcomes of this study have provided us with new insight regarding the management of the infertile couple with the husband suffering from azoospermia. A testis biopsy performed prior to the oocyte recovery cycle and cryopreservation of the remaining sample is beneficial for therapeutic and diagnostic purposes. Pre-cycle counselling and thorough examination of the husband is done to identify patients with a higher risk of a failed testicular biopsy outcome to prepare them for other options. Testicular biopsies are performed either prior to the assisted reproduction cycle or the day before oocyte aspiration. When spermatozoa are found in the biopsy specimen, testicular tissue is cryopreserved for subsequent treatment cycles. When no sperm are obtained, the couple is already prepared for other options (i.e. donor spermatozoa). When the number of spermatozoa obtained is not sufficient to warrant cryopreservation, only one ICSI cycle is possible and the timing of biopsy repetitions must be carefully monitored (Amer *et al.*, 1999) to assure optimal retrieval in successive cycles. In these cases future testicular sperm harvesting must also be managed carefully by perfecting tissue sampling and preparation techniques.

Couples with azoospermic male partners can therefore be treated successfully for their infertility problem. Fresh and cryopreserved testicular spermatozoa from both obstructive and non-

obstructive azoospermic cases, combined with ICSI, resulted in pregnancies. Incubation of testicular spermatozoa seems to increase sperm quality and also possibly fertilization and pregnancy rates.

### **Acknowledgements**

Sincere thanks to the personnel of the Reproductive Biology Unit, Tygerberg Hospital and the theatre personnel of the Tygerberg Hospital.

*The results from this chapter was submitted for publication to "Journal of Assisted Reproduction and Genetics", (2000).*



## References

- Amer, M., Hagggar, S.E.L., Moustafa, T. *et al.* (1999) Testicular sperm extraction: impact of testicular histology on outcome, number of biopsies to be performed and optimal time for repetition. *Hum. Reprod.*, **14**, 3030-3034.
- Balaban, B., Urman, B., Sertac, A. *et al.* (1999) In-vitro culture of spermatozoa induces motility and increases implantation and pregnancy rates after testicular sperm extraction and intracytoplasmic sperm injection. *Hum. Reprod.*, **14**, 2808-2811.
- Ben-Yosef, D., Yogev, L., Hauser, R. *et al.* (1999) Testicular sperm retrieval and cryopreservation prior to initiating ovarian stimulation as the first line approach in patients with non-obstructive azoospermia. *Hum Reprod*, **14**, 1794-1801.
- Edirisinghe, W.R., Junk, S.M., Matson, P.L. *et al.* (1996) Changes in motility patterns during in-vitro culture of fresh and frozen/thawed testicular and epididymal spermatozoa: implications for planning treatment by intracytoplasmic sperm injection. *Hum. Reprod.*, **11**, 2474-2476.
- Ezeh, U.I.O., Martin, M., Cooke, I.D. *et al.* (1998) Correlation of testicular pathology and sperm extraction in azoospermic men with ejaculated spermatids detected by immunofluorescent localization. *Hum. Reprod.*, **13**, 3061-3065.
- Friedler, S., Raziel, A., Soffer, Y. *et al.* (1997) Intracytoplasmic injection of fresh and cryopreserved testicular spermatozoa in patients with non-obstructive azoospermia – a comparative study. *Fertil. Steril.*, **68**, 892-897.
- Gil-Salom, M., Romera, J., Minguez, Y. *et al.* (1996) Pregnancies after intracytoplasmic sperm injection with cryopreserved testicular spermatozoa. *Hum. Reprod.*, **11**, 1309-1313.
- Ghazzawi, I.M., Sarraf, M.G., Taher, M.R. *et al.* (1998) Comparison of the fertilizing capability of spermatozoa from ejaculated, epididymal aspirates and testicular biopsies using intracytoplasmic sperm injection. *Hum. Reprod.*, **13**, 348-352.
- Gianaroli, L., Magli, M.C., Selman, H.A. *et al.* (1999) Diagnostic testicular biopsy and cryopreservation of testicular tissue as an alternative to repeated surgical openings in the treatment of azoospermic men. *Hum. Reprod.*, **14**, 1034-1038.
- Jezeq, D., Knuth, U.A. and Schulze, W. (1998) Successful testicular extraction (TESE) in spite of high serum follicle stimulating hormone and azoospermia: correlation between testicular morphology, TESE results, semen analysis and serum hormone values in 103 infertile men. *Hum. Reprod.*, **13**, 1230-1234.
- Liu, J., Tsai, Y.-L., Katz, E. *et al.* (1997) Outcome of in vitro culture of fresh and frozen-thawed human testicular spermatozoa. *Hum. Reprod.*, **12**, 1667-1672.
- Nagy, Z., Liu, J., Cecile, J., Silber, S. *et al.* (1995) Using ejaculated, fresh, and frozen-thawed epididymal and testicular spermatozoa gives rise to comparable results after intracytoplasmic sperm injection. *Fertil. Steril.*, **63**, 808-815.
- Oates, R.D., Mulhall, J., Burgess, C. *et al.* (1997) Fertilization and pregnancy using intentionally cryopreserved testicular tissue as the sperm source for intracytoplasmic sperm injection in 10 men with non-obstructive azoospermia. *Hum. Reprod.*, **12**, 734-739.
- Palermo, G.D., Schleger, P.N., Hariprashad, J.J. *et al.* (1999) Fertilization and pregnancy outcome with intracytoplasmic sperm injection for azoospermic men. *Hum. Reprod.*, **14**, 741-748.
- Silber, S.J., Van Steirteghem, A.C., Liu, J. *et al.* (1995) High fertilization and pregnancy rate after intracytoplasmic sperm injection with spermatozoa obtained from testicle biopsy. *Hum. Reprod.*, **10**, 148-152.

Windt, M.-L. and Coetzee, K (1999) Ongoing pregnancies resulting from intracytoplasmic sperm injection (ICSI) of spermatozoa from frozen-thawed testicular biopsy specimen. - two case reports. *Andrologia*,**31**, 169-172.

## CHAPTER 4

### RESULTS OF THE INFLUENCE OF TRANSFER METHOD AND EMBRYO QUALITY/VIABILITY ON ICSI PREGNANCY RATES.

---

- **Intracytoplasmic sperm injection (ICSI): Comparison of laparoscopic tubal versus transvaginal uterine embryo transfer**  
**Phase 1** (Tom Cat uterine embryo transfer)
  
- **Intracytoplasmic sperm injection (ICSI): Comparison of laparoscopic tubal versus transvaginal uterine embryo transfer**  
**Phase 2** (Edwards-Wallace uterine embryo transfer)
  
- **Comparative analysis of pregnancy rates after the transfer of early dividing embryos versus slower dividing embryos.**  
**Phase 3**

## INTRACYTOPLASMIC SPERM INJECTION (ICSI): COMPARISON OF LAPAROSCOPIC TUBAL VERSUS TRANSVAGINAL UTERINE EMBRYO TRANSFER Phase 1 (Tom Cat uterine embryo transfer)

Windt M-L  
Kruger TF.  
Coetzee K  
Van der Merwe JP  
Stander FSH  
Erasmus EL  
Smith K

Reproductive Biology Unit, Department of Obstetrics and Gynaecology, University of Stellenbosch, Tygerberg Hospital, TYGERBERG, South Africa.

### Abstract

In most intracytoplasmic sperm injection (ICSI) cases, female partners have normal gynaecological profiles and qualify for either tubal or uterine embryo transfer. The aim of this study was to compare the pregnancy outcome in 50 patients randomly receiving either tubal (n=25) or uterine (n=25) embryo transfer of ICSI fertilized embryos. Motile spermatozoa retrieved by masturbation or surgery on the testis were isolated and each cumulus-free metaphase II oocyte was injected with a single immobilized spermatozoon. Oocytes were incubated (37°C, 5% CO<sub>2</sub> in air) and inspected for fertilization and cleavage. Embryos were transferred either into the fallopian tube (A) or into the uterus (B) (using the Tom Cat catheter for uterine transfer) in a randomized manner. Fisher's exact test was used to compare pregnancy outcome.

Statistical analysis showed that for A and B respectively, *clinical pregnancy rate/transfer* (32% vs. 12%; p=0.08) and *ongoing pregnancy rate/transfer* (28% vs. 8%; p= 0.06) differed, but not significantly. The difference in pregnancy rates in the controlled study was regarded as clinically important.

A retrospective analysis of all ICSI embryo transfers (uncontrolled) showed similar results. Tubal transfer (n=94) vs. uterine transfer (Tom Cat catheter) (n=44) [25.5% vs. 9.0% pregnancy rate; p <0.05]. The higher pregnancy rate in the tubal transfer group (A) stresses the importance of the in vivo tubal environment for cleavage stage embryo growth.

## Introduction

Recently, high fertilization and pregnancy rates have been obtained with intracytoplasmic sperm injection (ICSI) (Van Steirteghem *et al.*, 1993), even with spermatozoa from epididymal aspirations (Tournaye *et al.*, 1994) and testis biopsies (Schoysman *et al.*, 1994). This has given new hope to couples suffering from severe male factor infertility problems. The ICSI procedure is now successfully applied in most cases of azoospermia, severe teratozoospermia, oligozoospermia, and asthenozoospermia as well as in cases of poor or non-fertilization.

In most cases the female partners in these couples are gynaecological normal with patent fallopian tubes and no other pathology. It is therefore possible to perform transvaginal uterine transfers as well as laparoscopic tubal transfers. Several investigators reported the advantage of tubal embryo transfer over uterine transfer (Yovich *et al.*, 1988; Hammitt *et al.*, 1990; Frederick *et al.*, 1994; Van Voorhis *et al.*, 1995) and due to a higher success rate with gamete intra-fallopian tube transfer (GIFT) compared to in vitro fertilization (IVF) in our unit, it was of importance to evaluate the two transfer methods in ICSI patients.

This prospective, randomized, controlled study was performed to compare the pregnancy outcome in two ICSI groups: **Group A (tubal embryo transfer)** and **Group B (uterine embryo transfer)**.

A retrospective analysis of all ICSI transfers was also performed, comparing the total results of all tubal and uterine embryo transfers.

## Materials and Methods

### Patients

Couples were selected for ICSI when semen parameters were not adequate for GIFT or IVF and when previous poor or non-fertilization was reported. Fifty cycles, where female age was <38 years and where at least one fallopian tube was present, were randomly allocated to either tubal (Group A) or uterine transfer (Group B).

### Ovulation Induction

Ovarian hyper-stimulation was carried out by the administration of gonadotrophin-releasing hormone agonist (GnRHa) (Synarel®; Montosano South Africa, Searle) in a long protocol, followed by human menopausal gonadotrophins (HMG) (Pergonal®; Serono, South Africa (Pty) Ltd) and/or pure follicle-stimulating hormone (FSH) (Metrodin®; Serono, South Africa (Pty) Ltd) from cycle day 3. Patients were followed up by doing estradiol determinations as well as serial ultrasonographical measurement of the Graafian follicle. Ovulation was induced by the administration of human chorionic gonadotrophin (HCG) (Profasi®; Serono, South Africa (Pty) Ltd) as soon as the leading follicle reached 18 mm in diameter.

### Semen preparation

Motile spermatozoa were isolated by a standard swim-up technique, glasswool filtration or Percoll gradient centrifugation (95%;70%;59%) (Sigma, South Africa). In cases of oligo – and asthenozoospermia, gradient centrifugation was the method of choice. Hepes buffered Hams F10 medium (Medicult, Harrilabs, Johannesburg, South Africa) was used for all semen preparation procedures.

#### Epididymal sperm aspiration and preparation

Male partners underwent microsurgical scrotal exploration under general anaesthesia and after unilateral hemi-scrotomy, the testicle and epididymus were explored. Epididymal fluid was aspirated with a 23-gauge hypodermic needle attached to a tuberculin syringe. Epididymal fluid was diluted immediately with medium. Each aspirate was investigated for the presence of motile spermatozoa and samples containing motile spermatozoa were combined and washed once with medium. Spermatozoa were further processed on a mini-Percoll gradient (95%/70%/50%) to obtain a clean and motile sperm sample.

#### Testicular spermatozoa

A testicular biopsy was performed under general anaesthesia. Biopsy material was macerated with microsurgical blades and the resultant fluid investigated for the presence of spermatozoa, then washed once through centrifugation and motile spermatozoa were isolated on a mini- Percoll gradient.

#### Follicle aspiration

Oocytes were recovered by trans-vaginal ultrasound-guided follicle aspiration 34-36 hours after HCG administration. The aspirated oocytes were then cultured in Medicult Hams F10 medium (Harrilabs, Johannesburg, South Africa) at 5% CO<sub>2</sub>/37°C for 3-6 hours before denuding.

#### Cumulus Removal

The cumulus mass was removed 3-5 hours post retrieval, using 80 IU hyaluronidase (Sigma) and denuding mouth pipettes. Denuded oocytes were rinsed three times. Metaphase II oocytes were identified and incubated in 50µl drops Medicult Hams F10 medium (Harrilabs, Johannesburg, South Africa) and covered with pre-equilibrated paraffin oil (Medicult) until injection (37°C, 5 % CO<sub>2</sub>).

#### Intracytoplasmic sperm injection (ICSI)

ICSI was performed using the equipment and method similar to that of Van Steirteghem *et al.* (1993).

Five minutes before injection, 4µl of the motile sperm suspension was added to the 10% PVP droplet. A motile, "normal" appearing sperm cell was immobilized by touching its tail with the tip of the injection pipette and aspirated tail first into the pipette. A metaphase II oocyte was secured by gentle suction with the holding pipette and so positioned that the polar body was either at 6 or 12 o'clock. The injection pipette containing the immobilized sperm cell was inserted into the oocyte, cytoplasm was aspirated into the pipette to confirm oolemma penetration and oocyte activation. In cases where very few motile spermatozoa were isolated, separate sperm drops were made and single motile spermatozoa transferred to the PVP drop before immobilization and injection. Injected oocytes were washed 3X with and incubated in Medicult Hams F10 medium (Harrilabs, Johannesburg, South Africa) supplemented with 10% maternal serum.

#### Evaluation of fertilization, cleavage and embryo quality

Each oocyte was evaluated individually at ± 18 hours post injection for 2PN and 2 polar bodies and ± 45 hours post injection for cleavage (4-cell stage).

#### Embryo Transfer

Embryos were transferred at the 4-cell stage. Two transfer methods were followed: tubal (laparoscopic) transfer or uterine (trans-vaginal) transfer. The Tom Cat catheter (Sovereign Sherwood Medical, St Louis, MO.) was used for uterine transfer.

### Pregnancy evaluation

Pregnancies (clinical) were reported as positive when  $\beta$ HCG serum levels were >10 mIU/ml, 10 days post transfer and increased to four times that value on day 14 post transfer. Ongoing pregnancies were reported when a foetal heartbeat (ultra sound) was present 7 weeks post transfer.

### **Results**

Fifty (n=50) patients were included in the prospective, controlled study. The average female age was 31.5 years (24-36 years). A total of 385 metaphase II oocytes were injected, 336 were intact after injection (damage rate 12.7%). Of the intact oocytes, 208 fertilized (fertilization rate 61.9%) and 11 patients fell pregnant (clinical pregnancy rate 22.0%). The ongoing pregnancy rate was 18.0% (9/50).

The results of the two compared groups A and B are presented in Table 1. Statistical analysis was performed using a two by two table (Fishers exact test).

The mean female age was 31.8 and 31.2 years; fertilization rate 59.6 and 64.9%; clinical pregnancy rate /transfer 32.0 and 12.0% ( $p = 0.08$ ) and ongoing pregnancy rate/transfer 28.0% and 8.0% ( $p = 0.06$ ) in group A and B respectively.

**Table 1**

**Results of the prospective, randomized, controlled study, comparing tubal and uterine transfer (Tom Cat catheter) of ICSI fertilized oocytes.**

	<b>A (n = 25)</b>	<b>B (n = 25)</b>
Female age	31.8 (26-36)	31.2 (24-36)
Oocytes injected	220	165
Oocytes damaged %	14.5 (32/220)	10.3 (17/165)
Fertilization rate %	59.6 (112/188)	64.9 (96/146)
Embryos transferred (mean and variation)	3.2 (1-6)	3.4 (1-6)
<b>Clinical pregnancy rate/transfer %</b>	<b>32.0 (8/25)</b>	<b>12.0 (3/25)*</b>
<b>Ongoing pregnancy rate/transfer %</b>	<b>28.0 (7/25)</b>	<b>8.0 (2/25)**</b>

\*  $p = 0.08$

\*\*  $p = 0.06$

**A Tubal embryo transfer**  
**B Uterine embryo transfer.**

The uncontrolled, retrospective study included 138 cycles where the criteria were a female age of <38 years and at least one patent fallopian tube. Uterine transfer was performed in 44 cycles and tubal transfer in 94. The results are presented in Table 2. In the tubal and uterine transfer groups the female age was 31.7 and 32.4 years; fertilization rate 61.4 and 78.1%; clinical pregnancy rate /transfer 25.5 and 9.0% ( $p = 0.02$ ) and ongoing pregnancy rate/transfer 18.0% and 6.8% ( $p = 0.06$ ), respectively.

**Table 2**

**Results of the retrospective, uncontrolled study, comparing tubal and uterine transfer (Tom Cat catheter) of ICSI fertilized oocytes.**

	<b>A (n = 94)</b>	<b>B (n = 44)</b>
Female age	31.7 (24-36)	32.4 (23-36)
Embryos transferred	2.9 (1-6)	3.2 (1-6)
Fertilization rate %	61.4 (365/594)	78.1 (153/196)
<b>Clinical pregnancy rate/transfer %</b>	<b>25.5 (24/94)</b>	<b>9.0 (4/44)*</b>
<b>Ongoing pregnancy rate/transfer %</b>	<b>18.0 (17/94)</b>	<b>6.8 (3/44)**</b>

\*  $p = 0.018$

\*\*  $p = 0.063$

**A Tubal embryo transfer**  
**B Uterine embryo transfer.**

### **Discussion**

Although reports regarding tubal versus uterine embryo transfer (ET) success rates are contradictory, (Balmaceda *et al.*, 1992; Fluker *et al.*, 1993), numerous studies concluded that tubal ET is advantageous over uterine ET (Yovich *et al.*, 1988; Hammitt *et al.*, 1990; Frederick *et al.*, 1994; Van Voorhis *et al.*, 1995). In two studies using frozen-thawed embryos, a consistent higher pregnancy rate with tubal transfer vs uterine transfer was reported; 41 vs. 15% and 58 vs. 19%, respectively (Hammitt *et al.*, 1990; Frederick *et al.*, 1994). This was also the case with the transfer of "fresh" embryos (Hammitt *et al.*, 1990). Possible reasons for the increased pregnancy rates in tubal ET, are thought to be the protective environment of the fallopian tube, appropriate time of entry into the uterine cavity and avoidance of endometrial trauma associated with uterine transfer (Hammitt *et al.*, 1990; Frederick *et al.*, 1994). Tubal transfer methods are however done laparoscopically and are associated with increased medical cost and risk. Careful evaluation of the advantage of tubal over uterine ET is therefore important.



In most cases, ICSI treatment addresses male factor infertility. The female partners of such couples qualify for either tubal or uterine ET. Taking the results of the studies mentioned above into consideration, tubal transfer of ICSI embryos for patients with patent tubes seems to be the best option. Patients receiving the GIFT procedure (tubal ET), in our own hands also have an increased pregnancy rate when compared to IVF patients (uterine ET). GIFT is offered as the treatment of choice for patients without tubal occlusions and adequate semen parameters. ICSI patients are also often GIFT candidates, except for the fact that semen parameters disqualify them for a GIFT cycle. We therefore argued that a controlled, randomized study to confirm a hypothesis i.e., that tubal ET will benefit our ICSI patients, was warranted.

In our prospective, controlled study on tubal (A) vs. uterine (B) transfer of ICSI embryos, statistical analysis of the pregnancy rates in the two compared groups (A and B respectively) did not reach statistical significance (32% vs. 12% respectively  $p = 0.08$ ). This was probably due to the small numbers of the study. The difference was however regarded as clinically important and the randomized study was terminated after 50 cycles due to the excellent results obtained with tubal transfer.

A bigger, retrospective, uncontrolled study revealed similar clinical pregnancy results for tubal vs. uterine ET (25.5% vs. 9.0%) and reached statistical significance ( $p = 0.018$ ). This outcome indicates the important role of the in vivo site of embryo transfer. In our hands, tubal transfer for patients without tubal occlusions, in this case the majority of ICSI treated patients, is more successful than uterine transfer.

### **Acknowledgements**

Sincere thanks to the personnel of the Reproductive Biology Unit, Tygerberg Hospital and the theatre personnel of the Tygerberg Hospital.

## References

- Balmaceda, J.P., Alam, V., Roszjtein, D. *et al.*, (1992) Embryo implantation rates in oocyte donation: prospective comparison of tubal versus uterine transfers. *Fertil. Steril.*, **57**, 870-874.
- Fluker, M.R., Zouves, C.G. and Bebbington, M.W. (1993) A prospective randomized comparison of zygote intrafallopian transfer and in vitro fertilization-embryo transfer for nontubal factor infertility. *Fertil. Steril.*, **60**, 515-519.
- Frederick, J.L., Ord, T., Stone, S.C. *et al.*, (1994) Frozen zygote intrafallopian transfer: A successful approach for transfer of cryopreserved embryos. *Fertil. Steril.*, **61**, 504-507.
- Hammit, D.G., Syrop, S.J., Walker, D.L. *et al.*, (1990) Comparison of concurrent pregnancy rates for in-vitro fertilization - embryo transfer, pronuclear stage embryo transfer and gamete intra-Fallopian transfer. *Hum Reprod.*, **5**, 947-954.
- Schoysman., R., Vanderzwalmen, P., Nijs, M. *et al.*, (1994). Pregnancy obtained with human testicular spermatozoa in an in vitro fertilization programme. *J. Androl.*, **87**, 10S-13S
- Tournaye, H., Devroey, P., Liu, J. *et al.*, (1994) Microsurgical epididymal sperm aspiration and intracytoplasmic sperm injection: a new effective approach to infertility as a result of congenital bilateral absence of the vas deferens. *Fertil. Steril.*, **61**, 1045-1051.
- Van Steirteghem, A.C., Nagy, Z., Joris, H. *et al.*, (1993). High fertilization and implantation rates after intracytoplasmic sperm injection. *Hum Reprod.*, **8**, 1061-1066.
- Van Voorhis, B.J., Syrop, C.H., Vincent Jr, R.D. *et al.*, (1995) Tubal versus uterine transfer of cryopreserved embryos: a prospective randomized trail. *Fertil. Steril.*, **63**, 578-583.
- Yovich, J.L., Yovich J.M. and Edirisinghe, W.R. (1988) The relative chance of pregnancy following tubal or uterine transfer procedures. *Fertil. Steril.*, **49**, 858-864.

## INTRACYTOPLASMIC SPERM INJECTION (ICSI): COMPARISON OF LAPAROSCOPIC TUBAL VERSUS TRANSVAGINAL UTERINE EMBRYO TRANSFER

### Phase 2 (Edwards-Wallace uterine embryo transfer)

Windt M-L  
Kruger TF  
Coetzee K  
Van der Merwe JP  
Stander FSH  
Erasmus EL  
Smith K

Reproductive Biology Unit, Department of Obstetrics & Gynaecology, Tygerberg Hospital, Tygerberg, Republic of South Africa.

#### Abstract

In the uterine transfer technique of embryos, certain very important factors must be considered. One of the factors indicated to influence pregnancy outcome, is the choice of transfer catheter. In Phase I, the Tom Cat catheter was used for uterine embryo transfer. This catheter is relatively rigid and has a sharp tip and was thought to be one of the reasons for the poor pregnancy rates in the uterine transfer group (Phase I).

The aim of this study was to compare the pregnancy outcome for patients receiving either tubal or a modified uterine embryo transfer of ICSI fertilized embryos. A modified uterine transfer technique and catheter (Edwards-Wallace) were implemented compared to the Tom Cat transfer catheter in Phase 1. Motile spermatozoa retrieved by masturbation or surgery on the testis were isolated and each cumulus-free metaphase II oocyte was injected with a single immobilized spermatozoon. Oocytes were incubated (37°C, 5% CO<sub>2</sub> in air) and inspected for fertilization and cleavage. Embryos were transferred either into the fallopian tube (A) or into the Uterus (B) (Edwards-Wallace catheter) in a prospective, uncontrolled manner (Phase II).

Statistical analysis for this prospective, uncontrolled study (Phase II) showed for A and B respectively: clinical pregnancy rate; 30.9% and 20.6% ( $p = 0.068$ ) and ongoing pregnancy rate 21.1% and 13.4% ( $p = 0.092$ ). The clinical pregnancy rate in Phase II for group B (uterine ET) was increased when compared to that of Phase I (20.6% and 9.0%,  $p = 0.0828$ , respectively) and also for ongoing pregnancy rate (13.4% and 6.8%,  $p = 0.2541$ , respectively). Pregnancy results for tubal transfer in the two phases (Phase I and Phase II) were similar [30.9% and 25.5% (clinical),  $p = 0.3734$ ; 21.1% and 18.0% (ongoing),  $p = 0.5432$ , respectively].

The higher pregnancy rate in the tubal transfer group (A) again stresses the importance of the in vivo environment for cleavage stage embryo growth. The increased pregnancy rates after uterine transfer with the Edwards-Wallace transfer catheter compared to the Tom Cat catheter, stresses the importance of a soft, atraumatic transfer technique.

## Introduction

In a previous study in our laboratory, tubal embryo transfer (ET) was found to be more successful than uterine ET when the Tom Cat catheter (Sovereign Sherwood Medical, St Louis, MO) was used. The Tom Cat catheter is very rigid and can theoretically cause trauma to the uterine wall. Bleeding and contractions is therefore often the negative effect of this technique. In a recent report by Kovacs (1999), the choice of a soft transfer catheter, resulting in an atraumatic transfer, was shown to be third on a list of factors influencing pregnancy outcome. Bleeding and contractions were also rated as important factors in the ultimate success (Kovacs, 1999).

The poor pregnancy rates in uterine ET with the Tom Cat was a matter of concern and not acceptable and the introduction of a different transfer catheter was decided on.

In this study therefore, a new modified uterine ET method was implemented introducing the soft, Edwards-Wallace Embryo Replacement Catheter (SIMS Portex Limited, Hythe, Kent, UK: REF SP/1816). Pregnancies after tubal ET and modified uterine ET were compared. Pregnancy rates for Phase I and Phase II were also compared.

## Materials and Methods

### Patients

Couples were selected for ICSI when semen parameters were not adequate for GIFT or IVF and when previous poor or non-fertilization was reported. Patients included in this study were <38 years old and had at least one open fallopian tube. Two groups were analysed prospectively, but uncontrolled: tubal ET (Group A; n = 223) or uterine ET (Group B; n = 97).

### Ovulation Induction

Ovarian hyper-stimulation was the same as for Phase I.

### Semen preparation

Ejaculated, Epididymal and Testicular spermatozoa were obtained and prepared as for Phase I. The medium used was HEPES buffered sperm preparation medium (Medicult, Harrilabs, Johannesburg, South Africa).

### Follicle aspiration

Oocytes were recovered by transvaginal ultrasound-guided follicle aspiration 34-36 hours after HCG administration. The aspirated oocytes were then cultured in Medicult Universal IVF medium (Harrilabs, Johannesburg, South Africa) at 5% CO<sub>2</sub>/37°C for 3-6 hours before denuding.

### Cumulus Removal and Intracytoplasmic sperm injection (ICSI)

Cumulus removal and intracytoplasmic sperm injection (ICSI) was performed as for Phase I. The medium used for washing the oocytes after cumulus removal and also for sperm injection was HEPES buffered sperm preparation medium (Medicult, Harrilabs, Johannesburg, South Africa). ICSI was performed using the equipment and method similar to that of Van Steirteghem *et al.* (1993). In Phase II, a separate sperm drop was made and a single motile spermatozoon transferred to a PVP drop before immobilization and injection.

Evaluation of fertilization, cleavage and embryo quality

Each oocyte was evaluated individually at  $\pm$  18 hours post injection for 2PN and 2 polar bodies and for cleaving at  $\pm$  45 hours post injection (4-cell stage) and 72 hours post injection (8-cell stage).

Embryo Transfer

Embryos were transferred at the 4-cell or 8-cell stage. Two transfer methods were followed: tubal (laparoscopic) transfer or uterine (trans-vaginal) transfer using the Edwards-Wallace Embryo Replacement Catheter. Uterine transfer was performed with as little as possible trauma. Any visible cervical mucus was removed by gentle suction.

Pregnancy evaluation

Pregnancies (clinical) were reported as positive when  $\beta$ HCG serum levels were  $>10$  mIU/ml 10 days post transfer and increased to four times that value on day 14 post transfer. Ongoing pregnancies were reported when a foetal heartbeat (ultra sound) was present 7 weeks post transfer.

**Results****Group A - Tubal ET; Group B - uterine ET****Phase I - Tom Cat uterine transfer; Phase II - Edward-Wallace uterine transfer**

The clinical pregnancy rate for group A was increased when compared to group B; 30.9% (69/223) and 20.6% (20/97) respectively,  $p = 0.068$ . Similar results were reported for ongoing pregnancy rate; 21.1% (47/223) and 13.4% (13/97) respectively,  $p = 0.092$ . The differences were not significant. Female age, fertilization rates and the mean number of embryos transferred were not different in the two transfer groups (Table 1).

**Table 1**

**Results of a prospective, uncontrolled study, comparing tubal and uterine transfer of ICSI fertilized oocytes. Phase II (Edwards-Wallace catheter).**

	A	B	p value
Clinical pregnancy rate %	30.9 (69/223)	20.6 (20/97)	0.0679
Ongoing pregnancy rate %	21.1 (47/223)	13.4 (13/97)	0.0918
Fertilization rate %	65.8 (1117/1698)	67.6 (469/694)	NS
Mean number of embryos transferred	3.1 (686/223)	3.4 (325/97)	NS

A Tubal embryo transfer  
B Uterine embryo transfer

When the results from the two phases were compared for uterine ET, Phase II (Edwards-Wallace ET) showed increased clinical and ongoing pregnancy rates when compared to Phase I (Tom Cat ET); clinical (20.6% and 9.0%,  $p = 0.0828$ ) and ongoing (13.4% and 6.8%,  $p = 0.2541$ ) (Table 2).

**Table 2**

**Results of the comparison of uterine transfer in Phase I (Tom Cat catheter) and Phase II (Edwards-Wallace catheter) of ICSI fertilized oocytes.**

	Clinical Pregnancy rate %	Ongoing Pregnancy rate %
<b>Phase I (Tom Cat)</b>	9.0 (4/44)	6.8 (3/44)
<b>Phase II (Wallace)</b>	20.6 (20/97)	13.4 (13/97)
p value	0.0828	0.2541

The results for tubal transfer in Phase II and Phase I was not significantly different; clinical (30.9% and 25.5%,  $p = 0.3734$ ) and ongoing (21.1% and 18.0%,  $p = 0.5432$ ). (Table 3). Female age, fertilization rates and the mean number of embryos transferred were not different in Phase I and Phase II (data not shown).

**Table 3**

**Results of the comparison of tubal transfer in Phase I and Phase II of ICSI fertilized oocytes.**

	Clinical Pregnancy rate %	Ongoing Pregnancy rate %
<b>Phase I</b>	25.5 (24/94)	18.0 (17/94)
<b>Phase II</b>	30.9 (69/223)	21.1 (47/223)
p value	0.3734	0.5432

## Discussion

Although the advantages of tubal transfer compared to uterine transfer have been reported and discussed before, (see Phase 1), the *technique* of uterine transfer may play a very important role in pregnancy outcome. Tubal transfer involves a laparoscopy and the site of transfer can be visualized accurately. Uterine transfer is essentially a blind procedure and many factors can influence the success of transfer. In literature there is some information on factors influencing uterine transfer success (Wood *et al.*, 1985; Wisanto *et al.*, 1989; Mansour *et al.*, 1990; Gonen *et al.*, 1991; Al-Shawaf *et al.*, 1993; Ghazzawi *et al.*, 1999), but some of the most important factors seems to be absence of blood on the catheter, type of catheter used, not touching the fundus and avoiding the use of a tenaculum (Kovacs, 1999, Lesny *et al.*, 1999). All these factors stress the importance of an atraumatic transfer technique where the implementation of a soft flexible transfer catheter is essential.

In Phase I of our study, the Tom Cat catheter was routinely used in our clinic for uterine transfer. Tubal transfer was however also a possibility and in a controlled study to compare the two transfer methods, tubal transfer performed better. An uncontrolled, retrospective analysis confirmed the results. Pregnancy rates in the uterine transfer group were however low compared to data from other laboratories. The transfer catheter was thought to be the most important reason. We therefore, prospectively, investigated the influence of the implementation of a new, soft and flexible catheter (Edwards-Wallace) on pregnancy results in uterine transfer cycles

The introduction of the Edwards-Wallace catheter in the Phase II study (replacing the Tom Cat) resulted in an almost two-fold increase in clinical and ongoing pregnancy rate after uterine transfer. Although the difference did not reach significance, it was an important finding since tubal transfer results in Phase II and Phase I was not different. This result was indicative of the negative influence of the Tom Cat catheter in uterine transfers.

In Phase II of the study, the higher pregnancy rate in the tubal transfer group (A) compared to group B was not significant, but again stresses the possible importance of the *in vivo* tubal environment for cleavage stage embryo growth (especially at the 4 and 8-cell stage). The increased pregnancy rates after uterine transfer with the Edwards-Wallace transfer catheter compared to the Tom Cat catheter, stresses the importance of a soft, atraumatic transfer technique.

For uterine transfer therefore, the Edwards-Wallace catheter is now routinely used in our laboratory. In a follow-up Phase III study, the importance of embryo selection and the route of transfer will be investigated in an effort to find the most successful combination for increased singleton pregnancies.

## Acknowledgements

Sincere thanks to the personnel of the Reproductive Biology Unit, Tygerberg Hospital and the theatre personnel of the Tygerberg Hospital.

## References

- Al-Shawaf, T., Dave, R., Harper, J. *et al.* (1993) Embryo transfer into the uterus: How much do technical factors affect pregnancy rate? *J.Assis. Reprod. Genet.* **10**, 3136.
- Ghazzawi, I. M., Al-Hasani, S., Karaki, R. *et al.* (1999) Transfer technique and catheter choice influence the incidence of transcervical embryo expulsion and the outcome of IVF. *Hum Reprod.*, **14**, 667-682.
- Gonen, Y., Dirnfeld, M., Goldman, S. *et al.* (1991) Does the choice of catheter for embryo transfer influence the success of rate of in-vitro fertilization? *Hum Reprod.*, **6**, 1092-1094.
- Kovacs, G. T. (1999) What factors are important for successful embryo transfer after in-vitro fertilization. *Hum Reprod.*, **14**, 590-592.
- Lesny, P., Killick, S.R., Robinson, J. *et al.* (1999) Junctional zone contractions and embryo transfer: is it safe to use a tenaculum? *Hum. Reprod.* **14**, 2367-2370.
- Mansour, R., Aboulghar, M., Serour, G. (1990) Dummy embryo transfer: A technique that minimizes the problems of embryo transfer and improves the pregnancy rate in human in vitro fertilization. *Fertil. Steril.*, **54**, 678-681.
- Van Steirteghem, A.C., Nagy, Z., Joris, H. *et al.* (1993). High fertilization and implantation rates after intracytoplasmic sperm injection. *Hum. Reprod.*, **8**, 1061-1066.
- Wisanto, A., Janssens, R., Deschacht, J. *et al.* (1998) Performance of different transfer catheters in a human in-vitro fertilization program. *Fertil. Steril.*, **52**, 79-84.
- Wood, C., McMaster, R., Rennie, G. *et al.* (1985) Factors influencing pregnancy rates following in vitro fertilization and embryo transfer. *Fertil. Steril.*, **43**, 245-250.



## COMPARATIVE ANALYSIS OF PREGNANCY RATES AFTER THE TRANSFER OF EARLY DIVIDING EMBRYOS VERSUS LATE DIVIDING EMBRYOS

### Phase 3

Windt M-L

Kruger TF

Coetzee K

Reproductive Biology Unit, Department of Obstetrics and Gynaecology, University of Stellenbosch, Tygerberg Hospital, TYGERBERG, South Africa.

Lombard CJ

Division of Epidemiology and Biostatistics, CERSA, Medical Research Council, TYGERBERG, South Africa.

### Abstract

The goal of embryo selection is to be able to choose the embryo that will have the best chance of implantation and a successful pregnancy. A few non-invasive methods to determine these viable embryos have been proposed. Embryo quality and morphology is the method used in most IVF programmes. Recently, pronuclear morphology and events in the oocyte connected to oocyte polarity have also been proposed to indicate embryo viability. Early division to the 2-cell stage is another easy and non-invasive method used to evaluate embryo viability. In this study we compared the pregnancy outcome in two groups of intracytoplasmic sperm injection (ICSI) patients, using the early division (26 hours post injection) to the 2-cell stage as a criterion for embryo viability and quality. Early cleavage was observed in 44% (63/143) of the cycles included in the study. For group A, at least one "early dividing" was transferred and in group B no "early dividing" embryo was transferred. Clinical pregnancy and ongoing pregnancy rates in Group A were significantly increased when compared with that in Group B [41.3% (26/63) vs. 20.0% (16/80);  $p = 0.0069$  and 33.3% (21/63) vs. 16.3% (13/80);  $p = 0.0191$  respectively]. Two transfer methods were followed; laparoscopic tubal transfer and uterine transfer. When the pregnancy outcome of the two transfer methods were compared, the tubal transfer route showed increased (but not significant) ongoing pregnancy rates in both group A and B (38.5% (15/39) Group A and 22.7% (10/44) Group B) when compared with uterine transfer (25.0% (6/24) Group A and 8.3% (3/36) Group B). Clinical pregnancy rates in uterine transfer cycles in group A were however significantly increased compared to group B (37.5% (9/24) and 11.1% (4/36) respectively;  $p = 0.016$ ). The results also showed that the highest ongoing pregnancy rate resulted from tubal transfer of early dividing (group A) embryos (38.5%) and the lowest rate from uterine transfer of embryos without early division (group B - 8.3%). Additional statistical analysis considering all the important variables, also showed a significant increasing trend in pregnancy rate with increasing numbers of early dividing embryos transferred (RR = 1.401,  $p = 0.0103$  for clinical pregnancy). Tubal transfer also showed a significant advantage over uterine transfer (RR = 3.989,  $p = 0.0266$ ) when these two transfer groups were compared. We propose that the method of "early cleavage" can be used to select viable embryos for transfer. Our results also suggest that when early cleavage embryos (group A) are available, both tubal and uterine embryo transfers can be considered. When no early cleavage embryos (group B) are available, tubal transfer should be considered.

## Introduction

The question by Edwards and Beard (1999): "do any other species (but the human) display such an immense loss of reproductive potential?" summarises the disappointment of scientists and patients when embryo transfer success rarely exceeds 30%. The selection of the embryo destined for implantation can improve the success and many embryo selection methods have been proposed and tried - in an effort to identify the embryo with the ability to implant. And at the same time assuring that multiple pregnancies are avoided.

Embryo selection is traditionally done using embryo morphology as guide (Gerris *et al.*, 1999; Van Royen *et al.*, 1999). Blastocyst culture in defined sequential media (Gardner *et al.*, 1998, Tsirigotis, 1998; Jones and Trounson, 1999; Sakkas, 1999; Behr, 1999 and Edwards and Beard, 1999) has also received much attention in the last few years and has become the method of choice in many laboratories. Oocyte and pronuclei polarity and cleavage symmetry are new developments indicating interesting possibilities for embryo selection (Payne *et al.*, 1997; Scott and Smith, 1998; Edwards and Beard, 1997, 1999; Fluka Jr, *et al.*, 1998; Behr, 1999; Garello *et al.*, 1999; Tesarik and Greco, 1999).

The method of selection has however to be non-invasive and not time consuming. Studies by Shoukir *et al.* (1997) and Sakkas *et al.* (1998), using "early division" to the two cell stage, 25-27 hours post insemination/injection, showed significantly improved pregnancy rates when such embryos were transferred. Edwards and Beard (1999) also commented on the importance of the first cleavage and suggested that early selection criteria up to and including the first division may have advantages. The correct assessment of pronucleated and 2-cell embryos may therefore prove to be more important than other implantation stages.

In this study we applied the simple and non-invasive method of selecting early dividing embryos for transfer to evaluate its effect on pregnancy rates in ICSI patients. The effect of the embryo transfer route i.e. tubal or uterine was also evaluated.

## Materials and Methods

### Patients

This prospective study includes patients qualifying for our Intracytoplasmic Sperm Injection (ICSI) programme. One hundred and forty three (143) ICSI cycles were evaluated.

#### *Female patients:*

Female partners of the couples included in the study had patent fallopian tubes and were  $\leq 37$  years old. Only transfer cycles where at least two embryos were available for transfer were included in the results.

#### *Male patients:*

All categories (idiopathic, male factor, azoospermic) of male partners were included in the study.

### Media

Medicult sperm preparation medium, HEPES buffered (Harrilabs, South Africa) was used for semen preparation; enzymatic embryo denuding and sperm injection drops. Medicult universal IVF medium (Harrilabs, South Africa) was used for embryo washing and incubation drops. Medicult paraffin oil (Harrilabs, South Africa) was used to cover medium drops and Medicult PVP (Harrilabs, South Africa) used for sperm immobilization.

### Stimulation protocol

Ovarian hyper-stimulation was carried out by the administration of gonadotrophin-releasing hormone agonist (GnRHa) (Synarel®; Montosano South Africa, Searle) in a long protocol, followed by human menopausal gonadotrophins (HMG) (Pergonal®; Serono, South Africa (Pty) Ltd) and/or pure follicle-stimulating hormone (FSH) (Metrodin®; Serono, South Africa (Pty) Ltd) from cycle day 3. Patients were followed up by doing estradiol determinations as well as serial ultrasonographical measurement of the Graafian follicle. Ovulation was induced by the administration of human chorionic gonadotrophin (HCG) (Profasi®; Serono, South Africa (Pty) Ltd) as soon as the leading follicle reached 18 mm in diameter.

### Semen preparation

Motile spermatozoa were isolated by a standard swim-up technique (whenever possible). In cases of oligo – and asthenozoospermia, gradient centrifugation was the method of choice. Ejaculated, testicular biopsy, cryopreserved ejaculated and cryopreserved testicular biopsy semen specimens were included in the study.

### Follicle aspiration and oocyte handling

Follicle aspiration was done under conscious sedation (Dormicum - Roche Products (Pty) Ltd South Africa or Diprovan - Zeneca Pharmaceuticals, South Africa). Oocytes were recovered by transvaginal ultrasound-guided follicle aspiration 34-36 hours after HCG administration.

Retrieved oocytes were incubated with their cumulus mass for at least 3 hours in a small petri dish with lid (37°C, 5 % CO<sub>2</sub>) until denuding.

The cumulus mass was removed 3-5 hours post retrieval using 40 IU/mL hyaluronidase (Sigma) and denuding mouth pipettes. Denuded oocytes were rinsed 3X with 1 mL medium. Metaphase II oocytes were identified and incubated in 50µl drops covered with pre-equilibrated paraffin oil until injection (37°C, 5 % CO<sub>2</sub>).

### Intracytoplasmic sperm injection (ICSI)

A standard method was followed. Prerequisites for successful injection were immobilization of the sperm cell in PVP and mild cytoplasmic aspiration. Oocytes were washed and then incubated individually in 50µl drops of medium (under oil, 37°C, 5 % CO<sub>2</sub>). Oocytes were transferred to fresh medium daily and embryos cultured to the 8-cell stage, transferred into and cultured in Medicult M3 medium.

### Evaluation of fertilization, early division, cleavage and embryo quality

Each oocyte was evaluated individually at the following times:

- At ± 18 hours post injection for 2PN and 2 polar bodies;
- 25-27 hours (±26 hours) post injection for 2-cell division (early division);
- ± 45 hours post injection for 4-cell division;
- ± 72 hours post injection for 6-8-cell division.

Early division and embryo quality were accurately reported. Embryos were regarded as “good quality” embryos when: they were at the 4-cell stage at 48 hours post injection with a morphological grading of 4 or 5 or at the 6-8-cell stage, 72 hours post injection with a morphological grading of 4 or 5.

- Grade 1      *Pre-embryo with few blastomeres of any size, severe or complete fragmentation*  
Grade 2:      *Pre-embryo with blastomeres of equal and unequal size, significant cytoplasmic fragmentation.*  
Grade 3:      *Pre-embryo with blastomeres of distinctly unequal size, few or no cytoplasmic fragments.*  
Grade 4:      *Pre-embryo with blastomeres of equal size; minor cytoplasmic fragments.*  
Grade 5:      *Pre-embryo with blastomeres of equal size; no cytoplasmic fragments.*

Pre-embryo definition:

*(Pre-embryo: The conceptus during early cleavage stages until development of the embryo. The pre-embryonic period ends at approximately 14 days after fertilization with the development of the primitive streak) (Veeck, 1991).*

Hereafter the term "embryo" will be used for pre-embryo.

Embryo Transfer and Pregnancy evaluation

Embryos were transferred either at the 4-cell or 6-8-cell stage. Two transfer methods were followed: tubal (laparoscopic) transfer or uterine (trans-vaginal) transfer using the Edwards-Wallace catheter (Simms, UK). Two or more (but less than five) embryos were transferred per patient.

For transfer, early dividing embryos (2-cell stage 26 hours post injection) were always the first choice. The rest of embryos were chosen using embryo morphology grading.

Pregnancies (clinical) were reported as positive when  $\beta$ HCG serum levels were >10 mIU/ml 10 days post transfer and increased to four times the value on day 14 post transfer. Ongoing pregnancies were reported when a foetal heartbeat (ultra sound) was present 7 weeks post transfer.

Outcomes Measured

Patients were divided into two groups to evaluate the pregnancy rate. **Group A:** cycles where at least one of the transferred embryos showed early division at 26 hours. **Group B:** cycles where none of the transferred embryos showed early division at 26 hours post injection.

Two outcomes were considered namely, clinical pregnancy rate (PR) and ongoing pregnancy rate (OPR). The association of pregnancy rates with early cleavage through the measurement of the number of early cleavage embryos transferred, was investigated. Other important variables considered were; the age of the women, the placement of the returned embryos and the number of good quality embryos returned. The analysis had to consider the *conditional limitation* of the number of embryos returned to the women since this number determined the number of early cleavage and good quality embryos returned.

Statistical analysis

Basic statistics (Statistica® 6.0) for the difference between two proportions (two-sided) were used to compare percentages. Basic statistics for the difference between means (normal distribution - two-sided) were used to compare mean values.

The clinical and ongoing pregnancy rates in this study were high (>20%) and therefore relative risk ratio (RR) models were used to model the outcome variables on the co-variables (Lee and Chia, 1993). This modeling was done using the Cox proportional hazards model with an artificial survival time variable and using the pregnancy outcome as the event indicator. The method also allowed a stratified approach, with the number of embryos returned used as the strata. A common parameter across the strata was used for some of the co-variables in the model. For the number of early cleavage embryos returned, the parameter estimated was a slope of a linear trend effect. The sample size of the study was fairly small and therefore extensive models were not possible and the number of co-variables were limited to the most important factors.

## Results

Early cleavage was observed in 44%, (63/143) of the cycles included in the study. Of the total number of embryos, 14.5% (110/759) were early dividing embryos. Of the total number of transferred embryos 23.8% (110/462) were early dividing embryos. The pregnancy results are shown in Table1.

Group A: At least one early dividing embryo transferred; Group B: no early dividing embryo transferred;

### Group A versus Group B

Clinical pregnancy and ongoing pregnancy rate for Group A was significantly increased when compared to that for Group B (41.3% and 20.0 %;  $p = 0.0069$ ) and (33.3% and 16.3 %;  $p = 0.0191$ ) respectively [Table 1].

### Tubal transfer: Group A versus Group B

Clinical pregnancy rate for group A was increased when compared to group B, but not significantly (43.6% and 27.2% respectively). Similar results were found for ongoing pregnancy rate (38.5% and 22.7% respectively) [Table1].

### Uterine transfer: Group A versus Group B

Clinical pregnancy rate for group A was significantly increased when compared to group B, (37.5% and 11.1 % respectively,  $p = 0.0160$ ). Ongoing pregnancy rate in group A was also increased compared to group B, but not significantly (25.0% and 8.3% respectively) [Table1].

### Group A: Tubal versus uterine transfer

Clinical pregnancy rate for tubal transfer was 43.6% and 37.5% for uterine transfer (not significant). Similar results were found for ongoing pregnancy rate (38.5% and 25.0% respectively). The average number of early dividing embryos transferred into the tube and uterus was 1.46 (57/39) and 2.2 (53/24), respectively.

### Group B: Tubal versus uterine transfer

Clinical pregnancy rate for tubal transfer was 27.2% and 11.1% for uterine transfer (not significant). Similar results were found for ongoing pregnancy rate (22.7% and 8.3% respectively) [Table1].

The highest clinical pregnancy rate resulted after tubal transfer of Group A (early dividing) embryos (43.6%) and the lowest for uterine transfer of Group B (no early dividing) embryos

(11.1%). The difference was significant,  $p = 0.0022$ . This was also the case for ongoing pregnancy rate (38.5% group A/tubal and 8.3% group B/uterine,  $p = 0.0031$ ).

The female age (31.7; 33.3 years), fertilization rates (71.4; 70.4%) and number of embryos transferred (3.3; 3.2) were very similar for Group A and B. The effect of age on the results was shown to be marginally significant ( $p = 0.049$ ) [Table 5 & 6]. The mean number of embryos transferred for group A and B were not different (3,3 and 3.2 respectively,  $p = 0.4593$ ).

The mean overall embryo quality of transferred embryos for Group A was significantly better than those for Group B (2.08 vs. 1.38;  $p = 0.001$ ).

The selection of early dividing embryos for ET (Group A) resulted in a high percentage of triplet and twin gestations (14.3% (3/21) and 23.8% (5/21) per ongoing pregnancy, respectively). Singleton gestations were 61.9% (13/21). In group B no triplet gestations were found. Twin gestations per ongoing pregnancy was 38.5% (5/13) and the singleton pregnancy rate 61.5% (8/13), similar to group A.

**Table 1**  
**Pregnancy rates (%) for Group A and B after tubal and uterine transfer of embryos**

Patient group		Group A	Group B
<b>Total</b>	Clinical Pregnancy rate [PR](%)	41.3 (26/63) <sup>d</sup>	20.0 (16/80) <sup>e</sup>
	Ongoing PR (%)	33.3 (21/63) <sup>a</sup>	16.3 (13/80) <sup>b</sup>
<b>Tubal ET</b>	Clinical Pregnancy rate [PR](%)	43.6 (17/39) <sup>j</sup>	27.2 (12/44) <sup>k</sup>
	Ongoing PR (%)	38.5 (15/39) <sup>g</sup>	22.7 (10/44) <sup>h</sup>
<b>Uterine ET</b>	Clinical Pregnancy rate [PR](%)	37.5 (9/24) <sup>p</sup>	11.1 (4/36) <sup>q</sup>
	Ongoing PR (%)	25.0 (6/24) <sup>m</sup>	8.3 (3/36) <sup>n</sup>

Group A: At least one early dividing embryo transferred

Group B: No early dividing embryo transferred

$P_{ab} = 0.0191$

$P_{de} = 0.0069$

$p^{pq} = 0.0160$

$p^{jq} = 0.0022$

$p^{gn} = 0.0031$

$p^{mn} = 0.0744$

$P^{jk} = 0.1324$

$p^{gm} = 0.2580$

$p^{jp} = 0.6407$

$p^{kq} = 0.0779$

$p^{hn} = 0.0743$

Table 2, 3 and 4 show the effect of the number of early cleavage embryos transferred on clinical pregnancy rate (PR) and ongoing pregnancy rate (OPR). An increase was evident for all three strata (2, 3, and  $\geq 4$  total number of embryos transferred).

**Table 2**

**Pregnancy outcome for cases where a total of two embryos were transferred**

Number of early cleaving embryos transferred	None	One	Two
Clinical pregnancy rate (PR) [%]	8.3 1/12	28.6 2/7	0.0 0/1
Ongoing pregnancy rate (OPR) [%]	8.3 1/12	0.0 0/7	0.0 0/1

**Table 3**

**Pregnancy outcome for cases where a total of three embryos were transferred**

Early cleaving embryos transferred	None	One	Two	Three
Clinical pregnancy rate (PR) [%]	25.0 10/40	38.9 7/18	37.5 3/8	71.4 5/7
Ongoing pregnancy rate (OPR) [%]	20.0 8/40	33.3 6/18	37.5 3/8	42.9 3/7

**Table 4**

**Pregnancy outcome (%) for cases where a total of four or more embryos were transferred**

Early cleaving embryos transferred	None	One	Two	Three	Four
Clinical pregnancy rate (PR) [%]	20.0 5/25	16.7 1/6	14.3 1/7	50.0 2/4	100.0 3/3
Ongoing pregnancy rate (OPR) [%]	8.0 2/25	16.7 1/6	14.3 1/7	25.0 1/4	66.7 2/3

Table 5 and 6 contains information on the relative risk ratios and the 95% confidence intervals (CI) together with the estimated model parameters for clinical pregnancy rate (PR) and ongoing

pregnancy rate (OPR), respectively. Age and placement were used as co-variables with the number of early cleavage embryos. Placement specific parameters were estimated separately for the stratum 2 and 3 combined and for stratum  $\geq 4$ .

For the (PR) (Table 5) in this study, the significance of age was marginal. The parameter estimate indicated a negative association with increasing age (-0.087),  $p = 0.049$ ). Placement of the embryos into the fallopian tube had a significant advantage when less than 4 embryos were transferred with a relative risk ratio of nearly 4 times that of the uterus ( $RR = 3.989$ ,  $p = 0.0266$ ). This advantage disappeared in the case were four or more embryos were transferred ( $RR = 1.132$ ,  $p = 0.8558$ ). There was a significant benefit in transferring more early cleavage embryos in the number being transferred. The relative risk ratio from the table represents the advantage of one embryo more being transferred and is the common estimated value across the three strata. If for example three embryos were transferred and three early cleavage embryos were available, the relative risk ratio for three versus no early cleavage embryos transferred was estimated at 2.74 (95% CI: 2.12 - 3.56).

**Table 5**  
**The relative risk ratios, 95% confidence intervals (CI) and estimated parameters for the clinical pregnancy rate (PR) model**

Variable	Estimated parameter	SE	P-value	Relative risk ratio (RR)	95% CI Lower Limit	95% CI Upper Limit
Age	-0.087	0.049	0.0775	0.917	0.833	1.010
Early Cleavage	0.337	0.131	0.0103	1.401	1.083	1.812
Placement (2,3 embryos)	1.361	0.614	0.0266	3.989	1.171	12.976
Placement ( $\geq 4$ embryos)	0.124	0.682	0.8558	1.132	0.297	4.312

Model Chi-square: 16.397 with 4 degrees of freedom,  $p = 0.0025$

The smaller number of ongoing pregnancies in the three strata (Table 6) was reflected in the wider and even extreme confidence intervals, especially for the placement parameters. The estimated effect of the number of early cleavage embryos transferred was nearly identical to that of the PR model and therefore the discussion above holds here as well. The placement effect (<4 embryos transferred) for the smaller strata was much stronger ( $RR = 9.475$ ,  $p = 0.0286$ ), but the estimate should be interpreted with caution since the sample size and outcomes are small. Estimating a common parameter for placement resulted in relative risk ratio of 2.742 (95% CI: 1.048-7.171) which still indicates a significant benefit of placement in the fallopian tube with more stable statistical properties.

**Table 6**



**The relative risk ratio, 95% confidence intervals (CI) and estimated parameters for the ongoing pregnancy rate (OPR) model**

Variable	Estimated parameter	SE	P-value	Relative risk ratio (RR)	95% CI Lower Limit	95% CI Upper Limit
Age	-0.071	0.059	0.2272	0.932	0.831	1.045
Early Cleavage Placement (2,3 embryos)	0.337	0.157	0.0324	1.401	1.029	1.908
Placement (≥4 embryos)	2.248	1.027	0.0286	9.475	1.265	70.946
	-0.609	1.092	0.5768	0.543	0.064	4.626

Model Chi-square: 15.520 with 4 degrees of freedom,  $p = 0.0037$ .

The nature of the selection and procedures used in the clinic had a direct impact on the design of the models needed to analyze the pregnancy outcome in the data. Since none of the clinical decisions were randomized, confounding will be an important issue and it was attempted in the analysis of clinical and ongoing pregnancies to accommodate these aspects. The observational nature and size of the data however, limits the extent of the model and only the two most important known co-factors were included in the models.

**Discussion**

The ultimate goal of assisted reproduction is to achieve a singleton, ongoing pregnancy. It is therefore obvious that there is a need to characterise embryos with optimal implantation potential. All the different embryo development stages (from one cell to blastocyst) have been proposed as markers for the evaluation of embryo quality and viability.

In this study the first cell division after ICSI fertilization was used to indicate embryo viability. An *early dividing embryo* was defined as an embryo that showed division to the 2-cell stage, 26 hours after microinjection. We performed a prospective, comparative study to investigate the influence on pregnancy rate of selective transfer of at least one embryo showing early 2-cell division versus embryos showing no early 2-cell division. This approach, to use the timing of the first cell division to select embryos for transfer, was reported by Shoukir *et al.* (1997) and Sakkas *et al.* (1998). Their results for ICSI and IVF showed significantly increased pregnancy rates in the early dividing group compared to the late dividing group (33.3% vs. 14.7% for IVF and 25.9% vs. 3.2% for ICSI). The results of our own study were similar for clinical and ongoing pregnancy rates. The clinical (41.3% vs. 20.0%,  $p = 0.009$ ) and ongoing (33.3% vs. 16.3%,  $p = 0.019$ ) pregnancy rates in the cases where early dividing embryos (group A) were transferred, were significantly higher than when no early dividing embryos (group B) were available for transfer. It was also evident from the Cox proportional hazards model that transfer of increasing numbers of early dividing embryos resulted in increased clinical and ongoing pregnancy rates.

Analysis of female age, fertilization rates and mean number of oocytes transferred in both groups was very similar. It was however of interest that there were significantly more good quality embryos transferred in the early dividing Group (A) compared to Group B (2.08 and 1.38 respectively,  $p = 0.001$ ). This is in accordance with the results of Shoukir *et al.* (1997) and Sakkas *et al.* (1998). This result also underlines similar thoughts by Edwards and Beard (1999) that early dividing embryos are more viable and will most probably be the ones that will become blastocysts.

The decision to use the early cleaving 2-cell embryo method (Shoukir *et al.*, 1997 and Sakkas *et al.*, 1998) in our study was initially because of its non-invasiveness and simplicity to identify possible viable embryos. The superiority of early cleaving embryos was however also reported by Edwards *et al.* (1984). Scott and Smith (1998) also assigned the highest value to embryos that had divided to the 2-cell stage at 24-26 hours post insemination in their study on pronuclear morphology and patients in this group also had a higher pregnancy rate. Sakkas *et al.* (1998) conclude that early cleaving embryos also give rise to better quality embryos due to an intrinsic, unknown factor within the oocyte. Scott and Smith (1998) reported that good quality, fast cleaving embryos with good morphology are possibly those with the correct spatial arrangement. Our own results confirm these reports and showed increased pregnancy rates in the early dividing group. The early dividing group also showed an increased number of good quality embryos.

With the recent interest in blastocyst transfer the issue of synchronization of the endometrium and embryo cell stage was raised. Cleavage stage embryos are usually found in the fallopian tube and not in the uterus. The uterus and tube have different nutritional environments (Gardner *et al.*, 1996, 1998) and embryos are therefore maybe better adapted for growth in the fallopian tube. Jones and Trounson (1999) commented on the receptivity of the uterus for early stage embryos and mentioned that 80% of embryos do not implant and therefore uterine blastocyst transfer will be more successful. Although the uterus seems to be a suitable environment for embryos (Scott and Smith, 1998), many studies showed the increased success of tubal transfer of early stage embryos over that of uterine transfer (Yovich, *et al.*, 1988; Hammitt, *et al.*, 1990; Frederick, *et al.*, 1994; Van Voorhis, *et al.*, 1995; Boldt, *et al.*, 1996; Tournaye, *et al.*, 1996; Bulletti, 1996; Kumar, *et al.*, 1997; Levrán, *et al.*, 1998; Castelbaum, *et al.*, 1998).

For this reason we were also interested in the comparison of two transfer methods i.e. tubal and uterine transfer. The study was not randomized and patients were given the choice for either tubal or uterine transfer after counselling and explanation of the details of each method. Our results indicated increased pregnancy rates after tubal transfer and also the possible advantage of implementing the tubal route for late dividing embryos. The combination of early division and tubal transfer resulted in an ongoing pregnancy rate of 38.5%, the highest of all combinations. In both groups (A and B), tubal transfer always resulted in higher pregnancy rates (Table 1). Also of interest was the comparative result after transfer of Group A embryos into the tube and the uterus. Clinical pregnancy rates were similar (43.6% and 37.5% respectively;  $p = 0.6407$ ) for the two transfer routes, indicating that the transfer route did not influence pregnancy rates when Group A embryos (early dividers) were transferred.

Our results may indicate that the tubal transfer of group B embryos (no early division) might "rescue" these probably less viable embryos. Tubal transfer results (clinical pregnancy) for Group B were not significantly different from Group A (27.2% and 43.6% respectively,  $p = 0.01324$ ), but when Group B embryos were transferred into the uterus however, clinical pregnancy rates were

significantly decreased when compared to Group A (11.1% and 37.5% respectively,  $p = 0.0016$ ). The results confirm the better quality and implantation ability of early dividing embryos and also the possible advantage of the tubal environment for late dividing embryos. This finding was also confirmed by additional statistical analysis, showing a significant advantage for placement in the fallopian tube. Similarly a significant benefit in transferring more early cleavage embryos was shown for both clinical pregnancy rates and ongoing pregnancy rates. The lower pregnancy rates in cases where four or more embryos were replaced can be explained in terms of embryo quality. In cases of tubal transfer, more than 3 embryos are only transferred only when poor quality embryos are available. In uterine transfers, a protocol of three or four embryos for transfer is followed irrespective of embryo quality.

The timing of the first cell division is only one of a few embryo selection methods. Other methods are also available and reported in the literature. At the one extreme is the evaluation of the pronucleated pre-embryo morphology to select embryos for transfer. Nucleolar abnormalities include the lack of pronuclear apposition (resulting from an abnormal functioning of the sperm centriole and microtubule organization) and failure of pronuclear growth (incomplete nuclear protein transition in the sperm cell) (Tesarik and Greco, 1999). The distribution and placement of nucleolar precursor bodies (NPB) can possibly be explained by the polarization and rotation of chromatin and NPB as described by Payne *et al.* (1997) and Edwards and Beard (1997,1999). These events are important steps in the formation of the embryonic axes and subsequent cell division and pronucleus evaluation can therefore possibly be used to select viable embryos. Early cell division can therefore also be an indication that these events were optimal. Tesarik and Greco (1999) used the number and distribution of nucleolar precursor bodies (NPB) in the pronucleus for evaluation. They reported a 50% clinical pregnancy rate after embryo transfer of a specific polarised pattern (pattern 0) compared to 9% after transfer of other patterns (pattern 1-5). A similar study by Scott and Smith (1998) also used pronuclear pre-embryo morphology to select embryos for transfer and reported a 71% clinical pregnancy rate in the group with juxtaposed pronuclei with nucleoli aligned at the pronuclear interface and a "halo" effect in the cytoplasm (Scott and Smith, 1998). Transfer of embryos without these characteristics resulted in a clinical pregnancy rate of only 8%. In an article by Edwards and Beard (1999), commenting on the work done by Shoukir *et al.* (1997) and Sakkas *et al.* (1998), they suggested that early cleaving embryos are possibly related to pronuclear morphology (Scott and Smith, 1998) and also to oocyte polarity as shown by cytoplasmic rotation of the pronucleus (Payne *et al.*, 1997). They also stated that "more information can be gleaned on embryo quality by correctly assessing the pronucleated/2cell embryo rather than other implantation stages"

The other extreme is the prolonged culture to the blastocyst stage (day 5 or 6) in sequential media (Gardner *et al.*, 1998; Jones and Trounson, 1999; Edwards and Beard, 1999). This extended culture expose the "best" and most viable embryos and the transfer of a lower number of blastocysts can result in high pregnancy rates, but lower multiple pregnancies (Gardner *et al.*, 1998; Jones and Trounson, 1999). It is therefore a method that aims to improve embryo selection, reduce multiple pregnancy and obtain a better synchronization between the embryo and the reproductive tract (Tsirigotis, 1998). Jones and Trounson (1999) conclude that the method of extended culture has the advantage of selecting developmentally competent embryos, embryos that have proven the potential to grow and develop under embryonic genomic control. The reproductive biologist population has however met blastocyst stage transfer with mixed opinions. Although it has been proved to increase pregnancy rates and especially implantation rates (Gardner *et al.*, 1998), some concerns were raised regarding its use in poor responders

(Behr, 1999), blastocyst selection criteria and timing of transfer (Tsirigotis, 1998; Behr, 1999). There is also the possibility of cycles where no transfer will be possible (no blastocyst formation) when this selection method is followed. (Tsirigotis, 1998; Edwards and Beard, 1999; Sakkas, 1999; Van Royen *et al.*, 1999). Preliminary results from our clinic indicated a possible correlation between early dividing embryos and the ability for blastocyst formation in specified blastocyst medium. Twenty nine percent (29%) of early dividing embryos developed into blastocysts compared to 9% for late dividing embryos (unpublished data), indicating a possible earlier embryo stage for selection of viable embryos.

Between these two extremes is the traditional, universally accepted embryo morphology and quality method, still used by most assisted reproduction centres, to select embryos for transfer. Previous reports have shown the correlation between embryo morphology and pregnancy rate (Staessen *et al.*, 1995). Very recently, Gerris *et al.* (1999) and Van Royen *et al.* (1999) reported that the transfer of one "top quality" embryo resulted in ongoing pregnancy and implantation rates of 38.5% and 42.3%, respectively. "Top quality" embryo characteristics were the absence of multinucleated blastomeres, 4 or 5 blastomeres on day 2 and 7 or more blastomeres on day 3 and  $\leq 20\%$  anucleated fragments. The authors suggest this selection method to be superior to the 'expensive and work-intensive' blastocyst culture method. The results from our study also indicated that embryo quality (morphology) of early cleaving embryos was significantly better than late cleaving embryos, indicating an indirect way of selecting the best quality embryos.

Edwards and Beard (1999) suggested that all the above mentioned methods target the same embryos and should be combined to find which early selection criteria indicate viable blastocysts. This would avoid long-term culture needed for blastocyst transfer. Behr (1999) also reported that blastocyst formation might reflect the quality of the gametes they are derived from and Van Royen *et al.* (1999) also suggested that a combination of all the methods might show that prolonged culture is not necessary.

From the analysis, early cleavage and tubal embryo transfer seems to be important factors to consider in the clinical decision making of which and where to transfer available embryos. The transfer of early dividing embryos resulted in an increased pregnancy rate in our study and we also suggest that when no early dividing embryos are available, tubal transfer should be considered. In the case when early dividing embryos were available, tubal and uterine transfer resulted in comparable pregnancy rates. We also propose that blastocyst transfer can be an option when no early dividing embryos are available. This is especially applicable when a high number of embryos are available (Racowsky *et al.*, 2000) and selection criteria for transfer is not obvious.

## **Acknowledgements**

Sincere thanks to the personnel of the Reproductive Biology Unit, Tygerberg Hospital and the theatre personnel of the Tygerberg Hospital.

This research was supported by the Harry and Doris Crossley Research Fund, University of Stellenbosch, Tygerberg.

*The study has been submitted for publication to Human Reproduction, 2000.*

## References

- Behr, B. (1999) Blastocyst stage transfer: Pitfalls and benefits. Blastocyst culture and transfer. *Hum. Reprod.*, **14**, 5-6.
- Boldt, J., Schnarr, P., Ajamie, A. *et al.* (1996) Success rates following intracytoplasmic sperm injection are improved by using ZIFT vs. IVF for embryo transfer. *J. Assist. Reprod. Genet.*, **13**, 782-785.
- Bulletti, C. (1996) Debating tubal transfer in assisted reproductive technologies. *Hum. Reprod.*, **11** 1820-1822.
- Castelbaum, A.J. and Freedman, M.F. (1998) Is there a role for gamete intra-fallopian tube transfer and other tubal insemination procedures? *Curr. Opin. Obstet. Gynecol.*, **10**, 239- 242.
- Edwards, R.G., Fishel, S.B., Cohen, J., *et al.* (1984) Factors influencing the success of *in vitro* fertilization for alleviating human infertility. *J. In. Vitro Fertil. Embryo Transfer*, **1**, 3-23.
- Edwards, R.G. and Beard, H.K. (1997) Oocyte polarity and cell determination in early mammalian embryos. *Mol. Hum. Reprod.*, **3**, 863-905.
- Edwards, R.G. and Beard, H.K. (1999) Blastocyst stage transfer: Pitfalls and benefits. Is the success of human IVF more a matter of genetics and evolution than growing blastocysts? *Hum. Reprod.*, **14**, 1-4.
- Frederick, J.L., Ord, T., Stone, S.C. *et al.* (1994) Frozen zygote intrafallopian transfer: A successful approach for transfer of cryopreserved embryos. *Fertil. Steril.* **61**, 504-507.
- Fulka, Jr. J., Kárníková, L. and Moor, R.M. (1998) Oocyte polarity: ICSI, Cloning and related techniques. *Hum. Reprod.*, **13**, 3303-3305.
- Gardner, D.K., Lane, M., Calderon, I. and Leeton J. (1996) Environment of the preimplantation human embryo *in vivo*: metabolite analysis of oviduct and uterine fluids and metabolism of cumulus cells. *Fertil. Steril.*, **65**, 349-353.
- Gardner, D.K., Schoolcraft, B., Wagley, L. *et al.* (1998) A prospective randomized trial of blastocyst culture and transfer in in-vitro fertilization. *Hum. Reprod.*, **13**, 3434-3440.
- Garello, C., Baker, H., Rai, J. *et al.* (1999) Pronuclear orientation, polar body placement, and embryo quality after intracytoplasmic sperm injection and in-vitro fertilization: further evidence for polarity in human oocytes? *Hum. Reprod.*, **14**, 2588-2595.
- Gerris, J., De Neubourg, D., Mangelschots, K. *et al.* (1999) Prevention of twin pregnancy after in-vitro fertilization or intracytoplasmic sperm injection based on strict embryo criteria: a prospective randomized clinical trial. *Hum. Reprod.*, **14**, 2581-2587.
- Hammit, D.G., Syrop, S.J., Walker, D.L. *et al.* (1990) Comparison of concurrent pregnancy rates for in-vitro fertilization - embryo transfer, pronuclear stage embryo transfer and gamete intra-Fallopian transfer. *Hum. Reprod.*, **5**, 947-954.
- Jones, G.M. and Trounson, A.O. (1999) Blastocyst stage transfer: Pitfalls and benefits. The benefits of extended culture. *Hum. Reprod.*, **14**, 1405-1408.
- Kumar, A., Benny, P., Lenton, E.A. *et al.* (1997) Retrograde tubal embryo transfer in natural cycle in-vitro fertilization. *Hum. Reprod.*, **12**, 484-486.
- Lee, J., and Chia, K. S. (1993) Estimation of prevalence rate ratios for cross sectional data: an example in occupational epidemiology. *Brit. J. Indus. Med.*, **50**, 861-864.
- Levrán, D., Mashíach, S., Dor, J. *et al.* (1998) Zygote fallopian transfer may improve pregnancy rate in patients with repeated failure of implantation. *Fertil. Steril.*, **69**, 26-30.

Payne, D., Flaherty, S.P., Barry, M.F. *et al.* (1997) Preliminary observations on polar body extrusion and pronuclear formation in human oocytes using time-lapse video cinematography. *Hum. Reprod.*, **12**, 532-541.

Racowsky, C., Jackson, K.V., Cekleniak, N.A. *et al.* E.S. (2000) The number of eight-cell embryos is a key determinant for selecting day3 or day 5 transfer. *Fertil. Steril.*, **73**, 558-564.

Sakkas, D. (1999) Blastocyst stage transfer: Pitfalls and benefits. The use of blastocyst culture to avoid inheritance of an abnormal paternal genome after ICSI. *Hum. Reprod.*, **14**, 4-5.

Sakkas, D., Shoukir, Y., Chardonnens, D. *et al.* (1998) Early cleavage of human embryos to the two-cell stage after intracytoplasmic sperm injection as an indicator of embryo viability. *Hum. Reprod.*, **13**, 182-187.

Scott, L.A. and Smith, S. (1998) The successful use of pronuclear embryo transfers the day following oocyte retrieval. *Hum. Reprod.*, **13**, 1003-1013.

Shoukir, Y., Campana, A., Farley, T. *et al.* (1997). Early cleavage of in-vitro fertilized embryos to the 2-cell stage: a novel indicator of embryo quality and viability. *Hum. Reprod.*, **12**, 1531-1536.

Staessen, C., Nagy, Z.P., Liu, J. *et al.* (1995) One year's experience with selective transfer of two good quality embryos in the human in-vitro fertilization and intracytoplasmic sperm injection programmes. *Hum. Reprod.*, **10**, 3305-3312.

Tesarik, J. and Greco, E. (1999) The probability of abnormal preimplantation development can be predicted by a single static observation on pronuclear stage morphology. *Hum. Reprod.*, **14**, 1318-1323.

Tournaye, H., Camus, M., Ubaldi, F. *et al.* (1996) Tubal Transfer: A forgotten art? Is there still an important role for Tubal transfer procedures? *Hum. Reprod.*, **11**, 1815-1818.

Tsirigotis, M. (1998) Blastocyst stage transfer: Pitfalls and benefits. Too soon to abandon current practice? *Hum. Reprod.*, **13**, 3285-3295.

Van Royen, E., Mangelschots, K., De Neubourg, D. *et al.* (1999) Characterization of a top quality embryo, a step towards single-embryo transfer. *Hum. Reprod.*, **14**, 2345-2349.

Van Voorhis, B.J., Syrop, C.H., Vincent Jr, R.D. *et al.* (1995) Tubal versus uterine transfer of cryopreserved embryos: a prospective randomized trail. *Fertil. Steril.*, **63**, 578-583.

Veeck, L. (1991) Abnormal morphology of the human oocyte and conceptus. In *Atlas of the human oocyte and early conceptus. Volume 2*, pp.151-179.

Yovich, J.L., Yovich J.M. and Edirisinghe, W.R. (1988) The relative chance of pregnancy following tubal or uterine transfer procedures. *Fertil. Steril.* **49**, 858-864.

## CHAPTER 5

### SHORT COMMUNICATIONS: INTERESTING CASE STUDIES FROM AN ICSI PROGRAMME

---

---

- I      **Metaphase I oocytes**
  - a)      **Fertilization and pregnancy using metaphase I oocytes in an intracytoplasmic sperm injection (ICSI) program.**
  - b)      **A pregnancy and birth after in vitro maturation of metaphase I oocytes. A case study.**
  
- II     **An intracytoplasmic sperm injection twin pregnancy with a globozoospermia male.**
  
- III    **Ongoing pregnancies resulting from intracytoplasmic sperm injection (ICSI) of spermatozoa from frozen-thawed testicular biopsy specimen. - Two case reports.**

## **FERTILIZATION AND PREGNANCY USING METAPHASE 1 OOCYTES IN AN INTRACYTOPLASMIC SPERM INJECTION (ICSI) PROGRAM.**

In this study we showed that a successful pregnancy is possible with matured metaphase I oocytes treated with ICSI. ICSI also allowed us to visualize other oocyte abnormalities and immature states of denuded oocytes and led to the implementation of TEM, where we were able to further investigate these abnormalities (Chapter 6). In some cases the inability of metaphase I oocytes to mature in vitro, can indicate an inherent abnormality of the oocyte and this unexplained infertility problem can be elucidated with TEM (Chapter 6).



## A) FERTILIZATION AND PREGNANCY USING METAPHASE I OOCYTES IN AN INTRACYTOPLASMIC SPERM INJECTION (ICSI) PROGRAM.

Windt M-L

Coetzee K

Reproductive Biology Unit, Department of Obstetrics and Gynaecology, University of Stellenbosch, Tygerberg Hospital, TYGERBERG, South Africa.

### Abstract

In this study we investigated whether metaphase I oocytes collected in an intracytoplasmic sperm injection program could successfully be matured and fertilized by injecting aged (> 20hr) spermatozoa. Metaphase I oocytes aspirated were preincubated for 20 hr to allow the oocytes to reach meiotic maturity. Only matured metaphase II oocytes were injected. The original sperm sample processed on the day of aspiration was used in the microinjection process. One hundred and eighty three oocytes were collected, of which 42 (23%) were metaphase I oocytes. These were incubated for 20 hr and microinjected with the original sperm sample. Thirty one (74%) of the metaphase I oocytes reached meiotic maturity (extruded a polar body); 67.7% showed two pronuclei 18 hr after injection and 61.3% showed embryo development 40 hr post-injection. No difference in fertilization and embryo development rate was found in metaphase II oocytes injected 6 hr post-aspiration versus 20 hr post-aspiration. A case study of an ongoing pregnancy achieved using only embryos obtained from matured metaphase I oocytes is also described. Metaphase I oocytes can be successfully matured *in vitro* and injected using aged (>20 hr) sperm samples. Matured metaphase I oocytes, if successfully injected, produce embryos able to induce pregnancy.

## Introduction

The oocyte cohort collected after ovarian hyperstimulation and follicle aspiration often has differing nuclear maturity. Their maturational states can span from prophase 1 to metaphase II oocytes. The indiscriminant insemination of all the oocytes at the same time may compromise fertilization and subsequent embryo development in many of the oocytes. Oocytes inseminated before reaching metaphase II stage may be penetrated by spermatozoa but will fail to initiate events leading to fertilization and embryo development (Asch *et al.*, 1995). Van der Merwe *et al.* (1992) showed an increase in pregnancy rate when four metaphase II oocytes compared to four metaphase I were transferred in gamete intrafallopian transfers, in a group of patients with >14% normal sperm forms. A prerequisite for successful fertilization is therefore the completion of meiotic maturation exhibited by extrusion of the first polar body. From this rationalization a number of questions arise: Are all immature oocytes a lost cause or can their fertilization ability be rescued and do the immature oocytes constitute a group large enough to warrant extra attention?

With the advent of intracytoplasmic sperm injection (ICSI) programs, oocytes can now be more accurately evaluated for maturity, as the cumulus cells precluding careful evaluation, are enzymatically removed. In the present study the identified metaphase I oocytes were matured *in vitro* for 20 hr, microinjected, and evaluated for fertilization success.

## Materials and Methods

### Patients and preparations

Twenty-one ICSI cycles in which at least one metaphase I oocyte was collected were retrospectively included in the study.

Two ovulation induction protocols were used to achieve ovarian hyperstimulation: a combination of clomiphene citrate and human menopausal gonadotropin (HMG) or a combination of gonadotropin releasing hormone agonist (GnRH-a) and HMG. Follicular growth was monitored by serial ultrasonography measurements and luteinizing hormone determinations. On the day the leading follicle was >18 mm in diameter, 10 000 IU of human chorionic gonadotropin (HCG) was administered. The transvaginal aspiration of follicles was performed 36hr after HCG was administered. Oocytes collected were incubated in Ham's F10 (Medicult, Harrilabs, South Africa) supplemented with 10% maternal serum, in a humidified atmosphere of 5% CO<sub>2</sub> in air. In preparation for the ICSI (Van Steirteghem *et al.*, 1993 a,b) the cumulus cells were removed with 80IU/ml hyaluronidase (TypeVIII, Sigma Chemical Co., St Louis, MO) and by washing with a micropipette. Cleaned, washed oocytes were then evaluated for the presence of a polar body. Metaphase II oocytes were placed in 20µl droplets of HEPES-buffered Ham's F10 supplemented with 10% maternal serum in the lid of a Petri dish. A 10µl droplet of 10% polyvinylpyrrolidone (PVP; Medicult, Harrilabs, South Africa) was placed in the center of the lid and all the droplets were covered with warmed, equilibrated paraffin oil (Medicult, Harrilabs, South Africa). Metaphase I oocytes were matured in paraffin oil-covered 100µl droplets of Ham's F10 (10% maternal serum) in a Petri dish. The metaphase I oocytes were checked for polar body extrusion at 6 and 20 hr post-aspiration.

Sperm and semen samples were obtained by means of masturbation, epididymal aspiration, or testis biopsy. Motile enriched sperm samples were prepared by means of mini-Percoll (Sigma Chemical Co.) gradient (50:70:95%) centrifugation (300g for 20min) using HEPES-buffered

Chemical Co.) gradient (50:70:95%) centrifugation (300g for 20min) using HEPES-buffered Ham's F10 supplemented with 10% maternal serum. The motile enriched sperm samples were kept at room temperature for the 20hr period.

#### Intracytoplasmic Sperm Injection

Sperm cells were transferred into the PVP (10%) droplet to restrict their forward progression. A motile, normal appearing sperm cell was selected, immobilized by touching the tail just below the neck region with the microinjection pipette and aspirated tail first into the pipette. A metaphase II oocyte was positioned with its polar body at 6 or 12 o'clock and secured by gentle suction through a holding pipette. The injection pipette containing the spermatozoon was pushed through the zona pellucida and oolemma into the ooplasm up to the 9 o'clock position. Ooplasm was carefully aspirated into the pipette and slowly expelled with the spermatozoon.

#### Fertilization

Injected oocytes were incubated in 100µl droplets of Ham's F10 (10% maternal serum) covered with paraffin oil. Ova were evaluated for fertilization at 16-18 hr post-injection (pronuclei) and at 48hr for embryo development (cleavage).

### **Results**

The total number of oocytes obtained from the 21 patients was 183 (mean = 8.7, SD = 3.7). At the time of aspiration 141 (77%) oocytes were at the metaphase II stage and 42 (23%) at the metaphase I stage (Table 1). No prophase I oocytes were obtained. The 42 metaphase I oocytes constitute a mean (SD) of 2 (1.3) oocytes per patient.

The 20 hr preincubation period of the metaphase I oocytes resulted in the maturation (extrusion of a polar body) of 31 (74%) of the oocytes (Table 1). Eleven (36%) of the preincubated metaphase I oocytes showed no sign visible signs of maturation.

**Table 1**  
**Descriptive data on the oocytes collected and matured**

	<b>N (%)</b>	<b>Mean (SD)</b>
<b>Oocytes collected</b>		
<b>Total</b>	183	8.7 (3.7)
<b>Metaphase II</b>	141 (77)	6.7 (4.0)
<b>Metaphase I</b>	42 (23)	2.0 ( 1.3)
<b>Prophase I</b>	0.0	0.0
<b>Post incubation</b>		
<b>Metaphase II</b>	31 (74)	
<b>Metaphase I</b>	11 (26)	

Eighty-eight metaphase II oocytes were successfully microinjected, 6 hr post-aspiration. (fifty-three MII oocytes were damaged either during denuding or injection). Fifty-seven (64.8%) of these oocytes were fertilized (2PN) and also underwent embryo development (cleavage) (Table 2). Thirty-one MI matured (polar body extruded after 20 hr) metaphase II oocytes were microinjected, of which 21 (67.7%) were fertilized and 19 (61.3%) exhibited embryo development (Table 2). The 11 metaphase I oocytes that did not mature achieved a fertilization rate of 36.4% (4/11) and an embryo development rate of 27.3% (3/11).

**Table 2**  
**Intracytoplasmic sperm injection (ICSI) of initially mature (6 hr) and in vitro matured (20 hr) oocytes.**

	No. Injected	2PN, N (%)	Cleavage, N (%)
<b>Metaphase II</b>			
6 hr	88	57 (64.8)	57 (64.8)
20 hr	31	21 (67.7)	19 (61.3)
<b>Metaphase I</b>			
20 hr	11	4 (36.4)	3 (27.3)

An ongoing pregnancy and birth was also reported after the transfer of two four-cell embryos that developed from microinjected, matured, metaphase I oocytes.

### Discussion

From an unselected population of oocytes (n=323) in our unit, the percentage of metaphase I and prophase I oocytes was 13.6% (44/323), compared to the 23% obtained in our study group. The study group was selected on the basis that at least one metaphase I oocytes was present in the oocyte cohort collected. Metaphase I oocytes do not therefore constitute a major group under the ovulation induction regimes used in our *in vitro* programme.

The use of metaphase I oocytes in an ICSI programme depends on the time available, the success of maturation, and the number of oocytes obtained for a specific patient. The number of oocytes collected is important because the generally reported fertilization rate for ICSI is between 60% and 70 %. Such a fertilization rate requires that at least six to eight metaphase II oocytes must be collected to ensure that three or four embryos (the number transferred in our protocol) are available for transfer. A more aggressive ovulation induction regime required to deliver the number of metaphase II oocytes needed, means however a higher cost to the patient and an increased risk of hyperstimulation syndrome. Regarding maturation success, this study has shown that under an adequate *in vitro* environment, 74% of metaphase I oocytes can reach meiotic maturation. The total number of metaphase II oocytes (initially mature and in vitro matured) obtained by using the ovulation induction regime described, was 172 (94%).

In this study microinjecting these matured oocytes produced fertilization and embryo development rates that were no different from those produced with the microinjection of metaphase II oocytes 6 hr post-aspiration (Table 2). Any superfluous (not transferred) embryos produced as the result of metaphase I oocyte management can be cryopreserved, which may increase the cumulative pregnancy rate for the patient group.

The successful fertilization of the matured metaphase I oocytes was achieved notwithstanding the fact that the sperm sample for the microinjection was also 20 hr old. It is well known that sperm preincubated for such a period lose their ability to fertilize oocytes normally (Singer *et al.*, 1985). This possible impairment is therefore successfully overcome with the ICSI procedure, as the non-fertilization lies at the level of sperm interaction and penetration of the cumulus cells, zona pellucida and oolemma. Whereas the problem of the "old" sperm sample can be overcome by the collection of a new fresh sample the following day, this may not be possible for patients who have undergone epididymal aspirations and/or testicular biopsies.

Only 6% of oocytes aspirated did not reach meiotic maturity, even after a 20 hr preincubation period. These were, however, microinjected and consequently a fertilization and embryo development rate lower than that obtained for metaphase II oocytes was obtained. The viability of the embryos obtained from these oocytes exhibiting possible meiotic arrest, must however be questioned and their transfer avoided.

Fertilization is a process delineated by a series of dependent and independent events; the failure of any one of the events can result in non-fertilization. Meiotic maturation is one such and event, which was shown to be obtainable in the majority of metaphase I oocytes collected using an appropriate ovulation induction regime and pre-incubation period. All oocytes that reached this stage, even if under *in vitro* conditions, have the same fertilizing probability, therefore metaphase I oocyte maturation may help to increase the number of embryos available for transfer in an ICSI programme.

## **B) A PREGNANCY AND BIRTH AFTER IN VITRO MATURATION OF METAPHASE I OOCYTES. A case study**

### **Abstract**

One of the patients included in the previous study was a good example of the dilemma faced. Only two metaphase I oocytes were collected, necessitating their preincubation for maturation. Both oocytes reached meiotic maturity after 20 hr and were subsequently injected. At 48-hr post injection two four-cell embryos developed and were transferred laparoscopically, from which a clinical pregnancy developed and a healthy baby was born. This case confirms that matured metaphase I oocytes can be cytogenetically normal.

### **Case study**

A 38-year-old female (P2G2) and her 39-year-old husband were treated for secondary infertility for 4 years. A GIFT cycle showed non-fertilization of excess oocytes and no pregnancy resulted. Two ICSI cycles followed. The first one showed good fertilization (70% [5/7]) and three embryos were transferred but no pregnancy resulted. In the second ICSI cycle three oocytes were obtained, but they did not fertilize.

In a third ICSI cycle superovulation was achieved with human menopausal gonadotropin (Pergonal, Serono). A spontaneous LH surge occurred and transvaginal follicle aspiration took place 10 hours after injection of 10 000 IU of HCG (Profasi, Serono).

Two metaphase I oocytes were recovered. The oocytes were incubated and matured in Ham's F10 (Mediatec) supplemented with 10% maternal serum. The oocytes were still immature 6 hours after aspiration and were incubated for another 18 hours. Twenty-four hours post-aspiration, both oocytes had extruded the first polar body and were classified as metaphase II oocytes

Semen parameters of the male partner were classified as sub-fertile: concentration  $8 \times 10^6/\text{ml}$ , motility 40% and normal morphology (strict criteria) 5%. Mini-Percoll treatment resulted in the recovery of  $1.5 \times 10^6$  motile spermatozoa. Both matured metaphase II oocytes were injected with an immobilized spermatozoon. Both oocytes showed 2PN at 18 hr and cleaved 48-hr post injection. The two 4-cell embryos were transferred laparoscopically into the tube and a singleton pregnancy proceeded uneventfully. A healthy boy was born.

The *in vitro* maturation of immature oocytes should be considered when too few mature oocytes are available, especially in the case of ICSI patients.

### **Acknowledgements**

Sincere thanks to the personnel of the Reproductive Biology Unit Tygerberg Hospital and the theatre personnel of the Tygerberg Hospital and especially to Dr Kevin Coetzee for the use of the information in this study.

*The A section of this study was published in J. Assis. Reprod. Genet., (1996) 13, 775-778.*

## References

Asch, R., Simerly, C., Ord, T. *et al.* (1995) The stages at which human fertilization arrests: microtubule and chromosome configurations in inseminated oocytes which failed to complete fertilization and development in humans. *Mol. Hum. Reprod.*, **10**, 1897-1906.

Singer, S.L., Lambert, H., Overstreet, J.W. *et al.* (1985) The kinetics of human sperm binding to human zona pellucida and zona-free hamster oocytes *in vitro*. *Gamete Res.*, **12**, 29-39.

Van der Merwe, J.P., Kruger, T.F., Swart, Y. *et al.* (1992) The role of oocyte maturity in the treatment of infertility because of teratozoospermia and normozoospermia with gamete intrafallopian transfer. *Fertil. Steril.*, **58**, 581-586.

Van Steirteghem, A.C., Liu, J., Joris, H. *et al.* (1993a). Higher success rate by intracytoplasmic sperm injection than by subzonal insemination. Report on a second series of 300 consecutive treatment cycles. *Hum. Reprod.*, **8**, 1055-1060.

Van Steirteghem, A.C., Nagy, Z., Joris, H. *et al.* (1993b). High fertilization and implantation rates after intracytoplasmic sperm injection. *Hum. Reprod.*, **8**, 1061-1066.

## **AN INTRACYTOPLASMIC SPERM INJECTION TWIN PREGNANCY WITH A GLOBOZOOSPERMIA MALE**

The successful twin pregnancy reported in this case study of ICSI with globozoospermic spermatozoa showed that ICSI can, in many cases, overcome even the most severe sperm morphology abnormality (Chapter 1 & 2). This case was even more unique when transmission electron microscopy (TEM) showed spermatozoa without any signs of acrosomal vesicles or membranes.



## AN INTRACYTOPLASMIC SPERM INJECTION TWIN PREGNANCY WITH A GLOBOZOOSPERMIA MALE

**Windt M-L**  
**Coetzee K**  
**Menkveld R**  
**Kruger TF**

Reproductive Biology Unit, Department of Obstetrics and Gynaecology, University of Stellenbosch, Tygerberg Hospital, TYGERBERG, South Africa.

**Kitshoff M**

Diagnostic Electron Microscopy Unit, Department of Anatomical Pathology, University of Stellenbosch, Tygerberg Hospital, Tygerberg, Republic of South Africa.

**Sousa M**

Laboratory of Cell Biology, Institute of Biomedical Sciences, University of Porto, Porto, Portugal.

### Abstract

**T**he incidence of male patients suffering from globozoospermia (round-headed) has been estimated to be less than 0.05%. These round-headed spermatozoa show an absence of the acrosomal structures and contents and have been reported to have severely reduced capacity to bind to the zona pellucida and penetrate an oocyte normally. If the hurdles to normal fertilization can be overcome, embryos that develop from these round-headed sperm are normal in all other respects. The microinjection (ICSI) of round-headed spermatozoa has resulted in varying levels of success (fertilization and cleavage), ranging from 0% to 90%, but the general consensus is that it is lower than that of standard intracytoplasmic sperm injection cases. We report here on a case of a male patient with type I globozoospermia treated with ICSI. Three embryos (3/7; 43%) developed with quality ranging from poor (one) to good (two). The transfer of these 3 embryos resulted in an ongoing twin gestation.

## Introduction

The identification of a male patient suffering from globozoospermia is a relatively rare occurrence with an incidence in the infertile population of less than 0.05%.

Due to the absence of the acrosomal structures and contents round-headed spermatozoa have been reported to have severely reduced capacity to bind to the zona pellucida and penetrate an oocyte normally. These spermatozoa have also been shown to be deficient in oocyte-activation factor and may have chromosomal defects (Rybouchkin *et al.*, 1996; Edirisinghe *et al.*, 1998). The initiation of fertilization using round-headed spermatozoa may therefore require the oocyte to be artificially activated (Edirisinghe *et al.*, 1998; Battaglia *et al.*, 1997). Intracytoplasmic sperm injection has the capacity to overcome the deficiencies of round-headed spermatozoa and initiate fertilization, albeit at a lower rate than normal, and ultimately a viable pregnancy (Kilani *et al.*, 1998; Stone *et al.*, 2000). With the general availability of intracytoplasmic sperm injection the once sterile diagnosis that globozoospermia patients were condemned to has now in most cases been converted to one of infertile.

In this case report we discuss the infertility follow-up and treatment of a couple in which the male has been diagnosed with globozoospermia.

## Case report

The couple was referred to our clinic suffering from approximately five years of primary infertility. The husband, 38 years of age, presented at our laboratory with a semen sample in which 99% of the spermatozoa were round-headed, acrosomeless spermatozoa (Figure 1). The other major semen parameters were within our normal ranges; concentration,  $38 \times 10^6$  spermatozoa/mL, motility, 40%, and forward progression, 2.5 (scale of 1-4). The exception being the percentage of normal cells (strict criteria) which was 0%. The wife, 34 years of age, presented with a diagnosis of anovulation.

Assisted reproduction, with intracytoplasmic sperm injection to initiate fertilization, was advocated. Superovulation was induced and controlled with a combination of Fertomid® (CC, Cipla-Medpro South Africa Pty Ltd), Perganol® (FSH/LH, Serono South Africa Pty Ltd), and Metrodin® (FSH, Serono South Africa Pty Ltd) starting on day 2 of her cycle. Follicular growth was followed-up by means of vaginal sonography and luteinizing hormone determinations from day 8. On day 9 10 000IU of Profasi (HCG, Serono South Africa Pty Ltd) was administered. Thirty-four hours later a trans-vaginal aspiration under ultrasound guidance was performed. Seven oocytes were obtained. A semen sample was obtained from the husband after the follicular aspiration and prepared using a wash and swim-up procedure. The resultant sperm sample had a concentration of  $10 \times 10^6$  motile spermatozoa/mL.

The intracytoplasmic sperm injection procedure used was based on the method described by Van Steirteghem *et al.* (1993). Seven mature (metaphase II) oocytes were injected, using sperm only selected on their motility. Post-injection the ova were not subjected to any artificial activation process. Eighteen hours post injection 3 ova showed the presence of 2 pronuclei, with all 3 developing into embryos. On day 3 post-aspiration three, 6 cell embryos had developed and were transabdominally transferred into one fallopian tube.

A pregnancy was signalled by two serum  $\beta$ HCG readings. The readings were 101 IU/L (day 10) and 1181 IU/L (Day 14). A clinical twin pregnancy was confirmed by ultrasound at 7 weeks of

gestation. The ultrasound examination revealed two gestational sacs both containing a fetal heartbeat. The pregnancy is proceeding uneventful.

### **Discussion**

ICSI has revolutionised the treatment of male infertility to such an extent that Nagy *et al.* (1995) stated that their results showed that there was no important influence from either the type or the extent of sperm impairment on the outcome of ICSI. Ultimately the only criterion for successful ICSI is the presence of at least one living spermatozoon per oocyte. To every rule there is an exception and maybe patients diagnosed with globozoospermia represent one of these. The injection of round-headed spermatozoa has resulted in varying levels of success (fertilization and cleavage), ranging from 0% to 90%, but the general consensus is that it is lower than that of standard intracytoplasmic spermatozoa injection cases (Liu *et al.*, 1995; Edirisinghe *et al.*, 1998; Kilani *et al.*, 1998; Stone *et al.*, 2000). The underlying pathology of round-headed spermatozoa and the intracytoplasmic sperm injection technique itself may be the major contributors to this variation. The examination of the semen sample must confirm whether the spermatozoa from the sample are type I (complete lack of acrosomal structures and contents) or type II (limited acrosomal structures) (Stone *et al.*, 2000). In our case the spermatozoa would be classed as type I (confirmed by transmission electron microscopy - Figure 2). Other varying aspects which future investigations may indicate is what proportion of the spermatozoa are deficient in oocyte activating factor and contain chromatin abnormalities (Rybouchkin *et al.*, 1996; Edirisinghe *et al.*, 1998). The chromatin abnormalities may lead to for example, premature chromosome condensation. When performing intracytoplasmic sperm injection with round-headed spermatozoa, attention to oocyte activation must be paid, be it mechanically (cytoplasmic aspiration technique) or chemically (calcium ionophore).

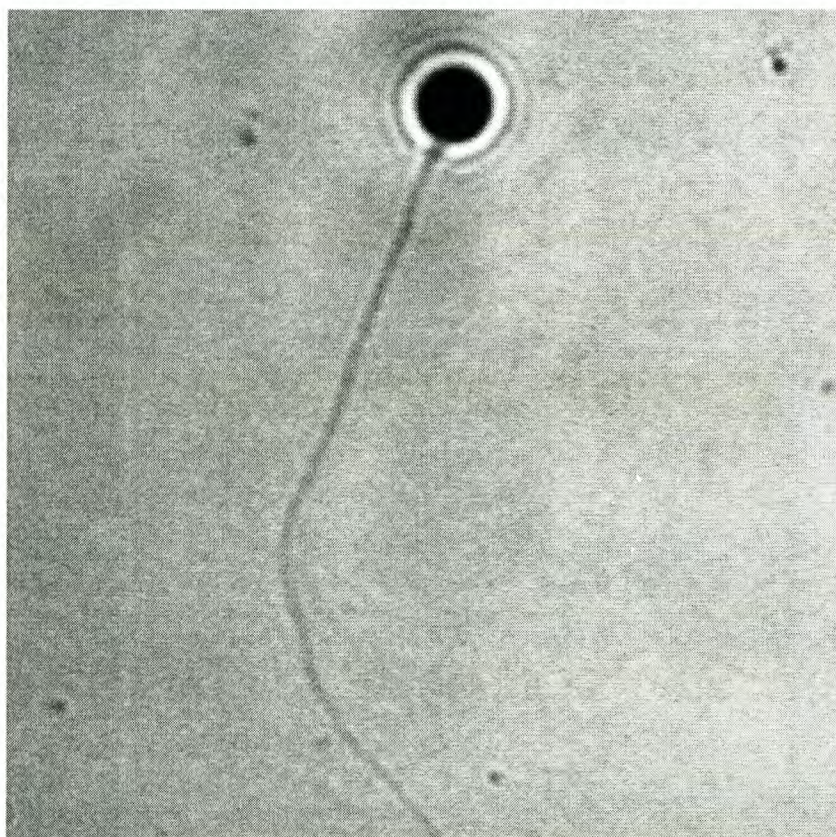
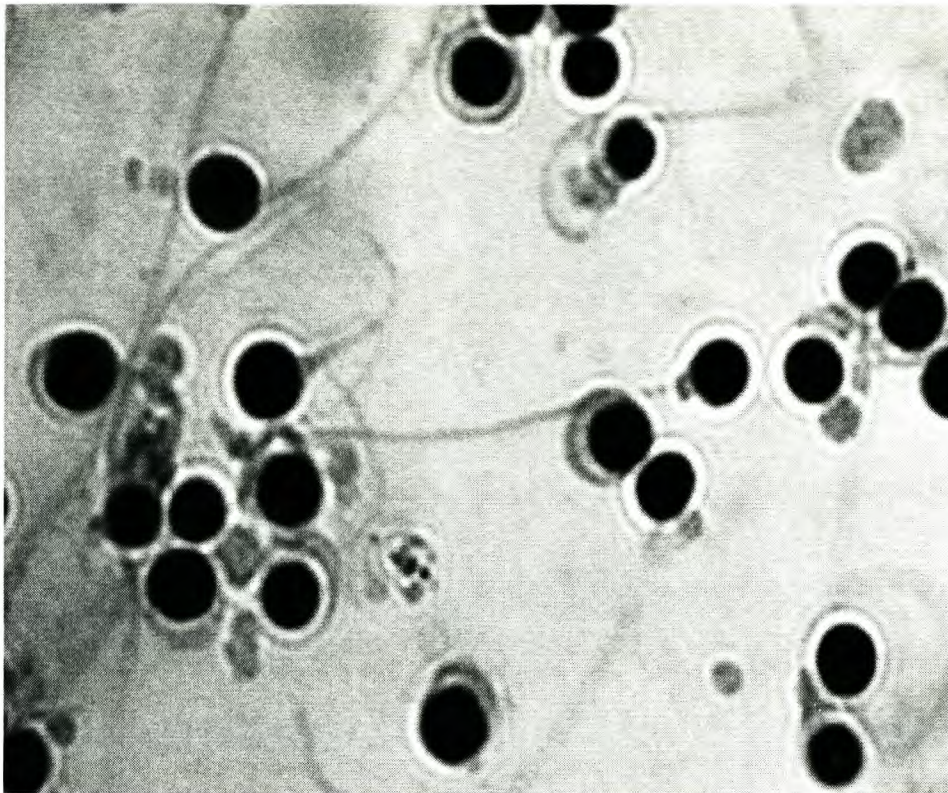
This and a number of other studies have shown that if the hurdles to normal fertilization can be surmounted the embryos that develop from these round-headed spermatozoa are normal in all other respects. In our case three embryos (3/7; 43%) developed with quality ranging from poor (one) to good (two). The transfer of these 3 embryos resulted in an ongoing twin gestation. With better understanding of the underlying pathologies of round-headed spermatozoa and improvement in intracytoplasmic sperm injection technology, greater success may be achieved in the treatment of this unique male diagnostic group.

### **Acknowledgements**

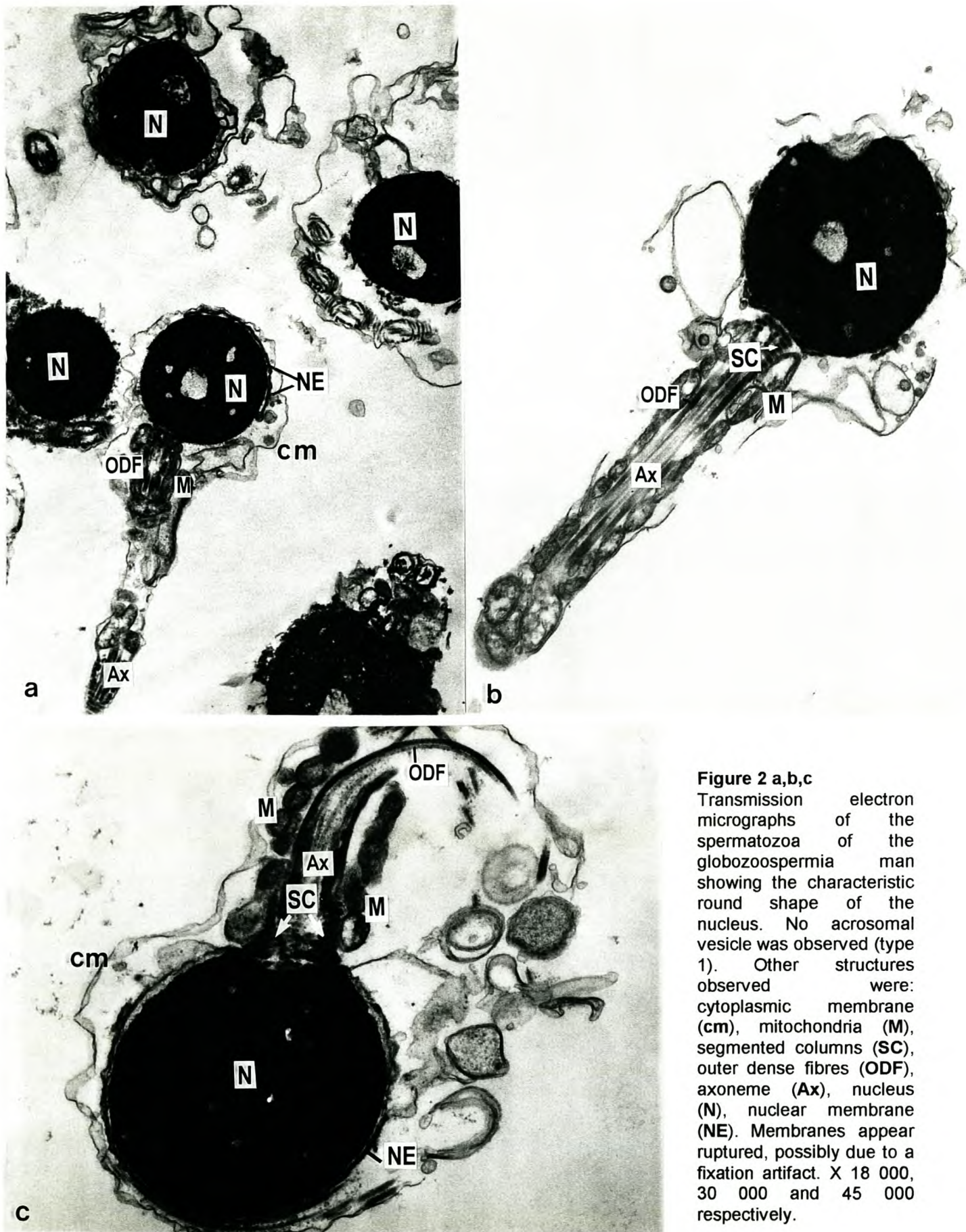
Sincere thanks to the personnel of the Reproductive Biology Unit, Tygerberg Hospital and the theatre personnel of the Tygerberg Hospital.

This research was supported by the Harry and Doris Crossley Research Fund, University of Stellenbosch, Tygerberg.

*This case study was submitted for publication to "Journal of Assisted Reproduction and Genetics", (2000).*



**Figure 1**  
Light micrograph demonstrating the characteristic roundheaded spermatozoa. (Original magnification = X1000).



**Figure 2 a,b,c**  
Transmission electron micrographs of the spermatozoa of the globozoospermia man showing the characteristic round shape of the nucleus. No acrosomal vesicle was observed (type 1). Other structures observed were: cytoplasmic membrane (cm), mitochondria (M), segmented columns (SC), outer dense fibres (ODF), axoneme (Ax), nucleus (N), nuclear membrane (NE). Membranes appear ruptured, possibly due to a fixation artifact. X 18 000, 30 000 and 45 000 respectively.

## References

- Battaglia, D.E., Koehler, J.K., Klein, N.A. *et al.* (1997) Failure of oocyte activation after intracytoplasmic sperm injection using round-headed sperm. *Fertil. Steril.*, **68**, 118-122.
- Edirisinghe, W.R., Murch, A.R., Junk, S.M. *et al.* (1998) Cytogenetic analysis of unfertilized oocytes following intracytoplasmic sperm injection using spermatozoa from a globozoospermia man. *Hum. Reprod.*, **13**, 3094-3098.
- Kilani, Z.M., Shaban, M.A., Ghunaim, S.D. *et al.* (1998) Triplet pregnancy and delivery after intracytoplasmic injection of round-headed spermatozoa. *Hum. Reprod.*, **13**, 2177-2179.
- Liu, J., Nagy, Z., Joris, H. *et al.* (1995) Analysis of 76 total failure cycles out of 2732 intracytoplasmic sperm injection cycles. *Hum. Reprod.*, **10**, 2630-2636.
- Nagy, Z.P., Liu, J., Joris, H. *et al.* (1995) The result of intracytoplasmic sperm injection is not related to any of the three basic semen parameters. *Hum. Reprod.*, **10**, 1123-1129.
- Rybouchkin, A., Dozortsev, D., Pelinck, M.J. *et al.* (1996) Analysis of the oocyte activation capacity and chromosomal complement of round-headed human spermatozoa by their injection into mouse oocytes. *Hum. Reprod.*, **11**, 2170-2175.
- Stone, S., Mahony, F.O., Khalar, Y. *et al.* (2000) A normal livebirth after intracytoplasmic sperm injection for globozoospermia without assisted oocyte activation. *Hum. Reprod.*, **15**, 139-141.
- Van Steirteghem, A.C., Nagy, Z.P., Joris, H. *et al.* (1993) High fertilization and implantation rates after intracytoplasmic sperm injection. *Hum. Reprod.*, **8**, 1061-1066.

**ONGOING PREGNANCIES RESULTING FROM INTRACYTOPLASMIC SPERM INJECTION (ICSI) OF SPERMATOZOA FROM FROZEN-THAWED TESTICULAR BIOPSY SPECIMEN. - Two case reports.**

In this preliminary pilot study, the use of frozen-thaw testicular spermatozoa was the first report of pregnancy success in our unit. This success led to the routine implementation of frozen-thaw testicular spermatozoa in ICSI. Several other successful cases followed and the cumulative results on the use of testicular spermatozoa are presented in Chapter 3.

**ONGOING PREGNANCIES RESULTING FROM INTRACYTOPLASMIC SPERM INJECTION (ICSI) OF SPERMATOZOA FROM FROZEN-THAWED TESTICULAR BIOPSY SPECIMEN. - Two case reports.**

**Windt M-L**

**Coetzee K**

**Kruger TF**

Reproductive Biology Unit, Department of Obstetrics and Gynaecology, University of Stellenbosch, Tygerberg Hospital, TYGERBERG, South Africa.

**Abstract**

**W**e report two ongoing pregnancies following intracytoplasmic sperm injection (ICSI) of spermatozoa from frozen-thawed testicular biopsies in two azoospermic men. The use of spermatozoa from cryopreserved testicular tissue is therefore a viable option for azoospermic men, as our results indicate that pregnancies are achievable in these cases.



## Introduction

The introduction of intracytoplasmic sperm injection (ICSI) in assisted reproduction has revolutionised the treatment of male infertility (Palermo *et al.*, 1992; Van Steirteghem *et al.*, 1993), to the extent that even obstructive and non-obstructive azoospermic male infertility, where epididymal and testicular spermatozoa have to be used, can be successfully treated to obtain fertilization and pregnancy (Nagy *et al.*, 1995; Schoysman *et al.*, 1994; Silber *et al.*, 1995). The treatment of this specific patient group however, requires the performance of repeated testis biopsies or aspirations.

Recently, fertilization and pregnancies after the use of frozen-thawed testicular spermatozoa in ICSI, have been reported (Gil-Salom *et al.*, 1996; Podsiadly *et al.*, 1996). The cryopreservation of supernumerary testicular spermatozoa avoids subsequent scrotal surgery, but generally yields very small numbers of spermatozoa with extremely poor motility. Salzburn *et al.* (1996) and Hovatta *et al.* (1996) proposed the cryopreservation of testicular tissue with glycerol as cryoprotectant. Fisher *et al.* (1996), Khalifeh *et al.* (1997) and Oates *et al.* (1997), using similar regimes, reported obtaining adequate yields of testicular spermatozoa after thawing and also reported successful fertilization and pregnancy outcomes.

We report here on our first two ongoing pregnancies (to our knowledge the first in Southern Africa) using spermatozoa from frozen-thawed testicular biopsies.

## Case 1

The couple presented at the IVF clinic with primary infertility. The 32-year-old male partner had a history of a left orchidopexy and orchidectomy as child. A semen analysis revealed azoospermia, but normal FSH (5.7mIU/ml). The 31-year-old female partner was healthy and a fertility workup showed that she was ovulatory with no other reproductive problems. During an attempt to do a by-pass operation on the patient, testicular tissue was cryopreserved. An open testicular biopsy was performed and testicular tissue (2-5 biopsies, 2-3 mm<sup>3</sup>) was thoroughly dissected with two No. 23 scalpel blades in 0.5 ml culture media (Medicult sperm preparation medium) and the resultant supernatant examined for the presence of spermatozoa. An aliquot from this tissue showed that spermatozoa were present and subsequent histology revealed normal spermatogenesis.

### Testicular spermatozoa and cryopreservation

The testicular biopsy homogenate was prepared for cryopreservation. The homogenate (including testicular tissue) was diluted 1:1 with cryoprotectant (v/v; egg-yolk 1: glycerol 2: citrate buffer 3) and thoroughly vortexed. The mixture was drawn into cryopreservation straws and frozen with a Planar (Kryo 10 Series) cryopreserver, using a stepwise controlled freezing programme.

Three months after this procedure the couple was included in the ICSI programme and spermatozoa from the cryopreserved sample were used.

### Stimulation and oocyte retrieval

The female partner was superovulated using a combination of GnRH-a (Synarel, Searle, South Africa) and FSH (Pergonal, Serono). Vaginal ultrasound-guided follicle puncture took place 36 h after injection of HCG (Profasi, Serono).

### Oocyte and spermatozoa preparations for ICSI

Aspirated oocytes were enzymatically treated with 50 IU of hyaluronidase (Sigma type IV) to remove cumulus (Van Steirteghem *et al.*, 1993). Metaphase II oocytes were washed and further incubated in Medicult IVF medium (37°C).

A single cryopreserved straw with testicular tissue was thawed at room temperature for 15 minutes. The thawed semen:cryoprotectant mixture was diluted slowly with sperm preparation medium (Medicult) and centrifuged for 10 minutes at 350xg. To isolate motile spermatozoa, the resuspended pellet was centrifuged on a discontinuous Percoll gradient (95, 70, 50 %). The 95% layer was washed twice more and resuspended in 100 µl medium, incubated at room temperature, until used in the ICSI. Sixty sperm with a non-progressive motility (twitching) were recovered after 4 hours of incubation.

### Intacytoplasmic sperm injection (ICSI)

The ICSI procedure was similar to that of van Steirteghem *et al.* (1993). Eight cumulus-free metaphase II oocytes were successfully injected with a single initially motile but immobilized spermatozoon. All eight injected oocytes showed fertilization (2PN formation) after 18 hours. Seven oocytes developed to the 4-cell stage at 48 hours, one to the 2 cell stage. Four 4-cell embryos of good quality were transferred laparoscopically into one fallopian tube.

A pregnancy was confirmed 10 days after embryo transfer as indicated by an elevated serum βHCG level of 285 IU/l. This level more than doubled 14 days after transfer and an 8 week ultrasound scan indicated three fetal heartbeats. The patient went into spontaneous labour at 32 weeks. Three babies were delivered with Caesarean section. A male child died due to placental incompetence and two small, but healthy girls (1.8 and 1.5 kg) survived and did well post delivery.

## **Case 2**

The couple presented at the IVF clinic with primary infertility. The 34-year-old male partner presented with a history of undescended testicles as child. A left orchidectomy was previously performed, but the right testicle had a normal volume and a diagnostic testis biopsy showed normal spermatogenesis and extra-testicular obstruction of the epididymus or vas deferens. In the 35-year-old female partner, routine gynaecological examinations and fertility tests were shown to be normal. The couple underwent three ICSI cycles with fresh testicular spermatozoa. Each time an open testicular biopsy was performed and testicular tissue (2-5 biopsies, 2-3 mm<sup>3</sup>) was thoroughly dissected with two No. 23 scalpel blades in 0.5 ml culture media (Medicult sperm preparation medium) and the resultant supernatant examined for the presence of spermatozoa. Aliquots from this tissue showed that spermatozoa were present. The testicular homogenate was prepared for the ICSI procedure (washed once with culture media, resultant pellet centrifuged on a mini-Percoll discontinuous gradient (50%: 70%: 95%) and washed twice more to remove the Percoll) and after ICSI two embryos were transferred in each of the three cycles. No pregnancy resulted.

### Testicular spermatozoa and cryopreservation

In the third cycle, the rest of the testicular biopsy homogenate was prepared for cryopreservation. The homogenate (including testicular tissue) was diluted 1:1 with cryoprotectant (v/v; egg-yolk 1: glycerol 2: citrate buffer 3) and thoroughly vortexed. The mixture was drawn into cryopreservation straws and frozen with a Planar (Kryo 10 Series) cryopreserver, using a stepwise controlled

freezing programme. In a subsequent fourth cycle, testicular spermatozoa from the cryopreserved sample were used in ICSI.

#### Stimulation and oocyte retrieval

The female partner was superovulated using a combination of GnRH-a (Synarel, Searle, South Africa) and FSH (Pergonal, Serono). Vaginal ultrasound-guided follicle puncture took place 36 h after injection of HCG (Profasi, Serono).

#### Oocyte and spermatozoa preparations for ICSI

Aspirated oocytes were enzymatically treated with 50 IU of hyaluronidase (Sigma type IV) to remove cumulus (Van Steirteghem *et al.*, 1993). Metaphase II oocytes were washed and further incubated in Medicult IVF medium (37°C).

A single straw with cryopreserved testicular tissue was thawed at room temperature for 15 minutes. The thawed semen:cryoprotectant mixture was diluted slowly with sperm preparation medium and centrifuged for 10 minutes at 350xg. To isolate motile spermatozoa, the resuspended pellet was centrifuged on a discontinuous Percoll gradient (95, 70, 50%). The 95% layer was washed twice more and resuspended in 100 µl medium, incubated at room temperature, until used in the ICSI. In this case 50 spermatozoa were recovered and 20 of them had a good progressive motility after 3-4 hours of incubation.

#### Intracytoplasmic sperm injection (ICSI)

The ICSI procedure was similar to that of van Steirteghem *et al.* (1993). Six cumulus-free metaphase II oocytes were injected with a single initially motile but immobilized spermatozoon. Five 2PN stage embryos were seen after 18 hours and at 72 hours four good quality 8 cell embryos, cultured in M3 medium (Medicult) were seen and transferred with a Wallace catheter into the uterine cavity.

An 8-week ultrasound scan indicated three gestational sacs, two showed fetal heartbeats and one was empty. At 10 weeks only one fetal heartbeat was seen. A healthy girl (3,3 kg) was delivered by Caesarean section at 39 weeks.

### **Discussion**

Cryopreservation of human spermatozoa is a widely used and accepted procedure (Brotherton, 1990) although it was shown to cause some damage to the sperm cell. The main effect of such damage can be seen in classical fertilization, since damage is mainly structural and functional (motility, acrosome, peripheral sperm membranes, sperm metabolism).

The disadvantages mentioned above do however not apply in ICSI, where structural and functional integrity is not essential. Frozen-thawed testicular spermatozoa were even shown to increase in progressive motility with time as more spermatozoa become mature (Edirisinghe *et al.*, 1996). This was not as pronounced as in fresh testicular spermatozoa, but was shown to give comparable fertilization results (Perraguin-Jayot *et al.*, 1997; Nagy *et al.*, 1995).

The use of testicular spermatozoa from cryopreserved tissue in ICSI was shown to be successful in this preliminary report from our IVF unit. It was possible to obtain adequate numbers of motile spermatozoa for ICSI. Our results also indicate that the fertilization rate, using spermatozoa from

cryopreserved tissue, compares favourably with the results obtained when using fresh testicular spermatozoa (60.2% fertilization) as well as fresh ejaculated spermatozoa (69.6% fertilization) in our ICSI programme (Windt *et al.*, 1997).

Cryopreservation of testicular tissue, as described, has many advantages; the main being avoidance of repeated and multiple surgical invasion. Additional advantages include lower cost, lower patient stress, lower surgical risk (decreased surgical procedures) and facilitation of the clinical management of the couple (Perraguin-Jayot *et al.*, 1997). Cryopreservation of a homogenate of the tissue ensures better access for cryoprotectant, as when compared to the cryopreservation of whole tissue. The inclusion of all the testicular tissue in the cryopreserved sample is also beneficial as it serves as a natural milieu for the maturation of immature testicular spermatozoa (Khalifeh *et al.*, 1997). It was also suggested that cryopreservation of testicular tissue can possibly serve as a method of selection of the "best" spermatozoa. Our own as well as other authors' results show at least that cryopreserved spermatozoa can be used as successfully as fresh spermatozoa from the testis (Nagy *et al.*, 1995 and Salzburn *et al.*, 1996). The use of cryopreserved testicular tissue and spermatozoa is therefore a viable option for azoospermic men, as shown by our own and other authors' results.

### **Acknowledgements**

Sincere thanks to the personnel of the Reproductive Biology Unit, Tygerberg Hospital and the theatre personnel of the Tygerberg Hospital.

*This study was published in "The South African Medical Journal, (1998) 88 (10), 348 (letter to the Editor) and also in "Andrologia" (1999) 31(3), 169-172.*

## References

- Brotherton, J. (1990) Cryopreservation of human spermatozoa. *Arch. of Androl.* **25**, 181-195.
- Edirisinghe, W.R., Junk, S.M., Matson, P.L. *et al.* (1996) Changes in motility patterns during in-vitro culture of fresh and frozen/thawed testicular and epididymal spermatozoa: implications for planning treatment by intracytoplasmic sperm injection. *Hum. Reprod.* **11**, 2474-2477.
- Fisher, R., Baukloh, V., Naether, O.G.J. *et al.* (1996) Pregnancy after intracytoplasmic sperm injection of spermatozoa extracted from frozen-thawed testicular biopsy. *Hum. Reprod.* **11**, 2197-2199.
- Gil-Salom, M., Romero, J., Minguez, Y. *et al.* (1996) Pregnancies after intracytoplasmic sperm injection with cryopreserved testicular spermatozoa. *Hum. Reprod.*, **11**, 1309-1313.
- Hovatta, O., Foudila, T., Sieberg, R. *et al.* (1996) Pregnancy resulting from intracytoplasmic injection of spermatozoa from frozen-thawed testicular biopsy specimen. *Hum. Reprod.*, **11**, 2472-2473.
- Khalifeh, F.A., Sarraf, M., and Dabit, S.T. (1997) Full-term delivery following intracytoplasmic sperm injection with spermatozoa from frozen-thawed testicular tissue. *Hum. Reprod.*, **12**, 87-88.
- Nagy, Z., Liu, J., Janssenwillen, C. *et al.* (1995) Using ejaculated, fresh, and frozen-thawed epididymal and testicular spermatozoa gives rise to comparable results after intracytoplasmic sperm injection. *Fertil Steril* **63**, 808-815.
- Oates, R.D., Mulhall, J., Burgess, C. *et al.* (1997) Fertilization and pregnancy using intentionally cryopreserved testicular tissue as the sperm source for intracytoplasmic sperm injection in 10 men with non-obstructive azoospermia. *Hum. Reprod.*, **12**, 734-739.
- Palermo, G., Joris, H., Devroey, P. *et al.* (1992) Pregnancies after intracytoplasmic sperm injection of single spermatozoa into an oocyte. *Lancet*, **430**, 17-18.
- Perraguin-Jayot, S., Audebert, A., Empeaire, J.C. *et al.* (1997) Ongoing pregnancies after intracytoplasmic injection using cryopreserved testicular spermatozoa. *Hum. Reprod.*, **12**, 2706-2709.
- Podsiadly, B.T., Woolcott, R., Stanger, J.D. *et al.* (1996) Pregnancy resulting from intracytoplasmic injection of cryopreserved spermatozoa recovered from testicular biopsy. *Hum. Reprod.*, **11**, 1306-1308.
- Salzburn, A., Benson, D.M., Holstein, A.F. *et al.* (1996) A new concept for the extraction of testicular spermatozoa as a tool for assisted fertilization (ICSI). *Hum. Reprod.*, **11**, 752-755.
- Schoysman, R., Vanderzwalmen, P., Nijs, M. *et al.* (1994) Pregnancy obtained with human testicular spermatozoa in an in vitro fertilization program. *J. Androl.*, **15**, 10S-13S.
- Silber, S.J., Van Steirteghem, A.C., Liu, J. *et al.* (1995) High fertilization and pregnancy rate after intracytoplasmic sperm injection with spermatozoa obtained from testicle biopsy. *Hum. Reprod.*, **10**, 148-152.
- Van Steirteghem, A.C., Nagy, Z., Joris, H. *et al.* (1993) High fertilization and implantation rates after intracytoplasmic sperm injection. *Hum. Reprod.*, **8**, 1061-1066.
- Windt, M.-L., Stander, F.S.H., Coetzee, K. *et al.* (1997) Intracytoplasmic sperm injection- new hope for severe male factor infertility (letter) *S. Afr. Med.J.*, **87**, 1154.

## CHAPTER 6

### TRANSMISSION ELECTRON MICROSCOPIC (TEM) IMAGES OF HUMAN OOCYTES

---

- I **Materials and Methods: Transmission electron microscopy (TEM) for a single cell:**  
TEM of the human oocyte  
TEM of spermatozoa
  
- II **Transmission electron microscopic (TEM) ultrastructure of normal, abnormal and unfertilized (ICSI) human oocytes to explain possible reasons for fertilization failure**
  
- III **Transmission electron microscopic (TEM) evaluation of oocytes arrested at metaphase I**  
A case study

## TRANSMISSION ELECTRON MICROSCOPY FOR A SINGLE CELL - TEM OF THE HUMAN OOCYTE

### Handling the ovum

**B**ecause the ovum is so small, special handling methods are used. All processing is done using a stereo microscope. The first steps (the buffer rinses and the osmium post-fixation) are carried out in a transparent plastic holder illuminated from below, since the ovum is very difficult to see before it has been stained by the osmium. Subsequent stages are carried out in the hollows of a ceramic spotting (staining) tile illuminated from above, as the now-dark ovum is relatively easy to see against the white of the tile.

A capillary tube and rubber teat is used to handle the ovum. Although difficult at first, the procedure becomes easier with practice, requiring great skill and concentration.

The processing method used was adapted from the tried and tested procedures used for routine diagnostic tissue specimens. The changes made were mostly in the length of time the specimen spent in each solution, as less penetration time is needed for a single cell. Experimentation showed that the slightly longer polymerization period (21 hours instead of the routine overnight period) in the incubator led to much easier cutting.

### Fixation

The ovum is fixed in Karnovsky's fixative for one hour at 4°C, and then transferred to cacodylate buffer. It may be stored in this buffer at 4°C for as long as is necessary, until processing begins. It is important to remember that the fixative solution and the buffer are extremely toxic.

#### Reagents for fixation

##### **Karnovsky's fixative**

Sodium cacodylate buffer pH 7.4	2.5mL
Distilled water	2.5mL
Paraformaldehyde (4% in water)	1.0mL
Glutaraldehyde (25%)	0.6mL

##### **Cacodylate buffer**

###### **Stock solution A,**

Sodium cacodylate	4.28gm
Distilled water	100mL

###### **Stock solution B,**

Hydrochloric acid (concentrated)	1.7mL
Distilled water	100mL

##### **Working solution (pH 7.4)**

Stock solution A	25mL
Stock solution B	1.4mL

**Processing**Notes about the procedure.

- Each solution must be carefully labeled with the name of the solution, as well as the date on which it was made up and the name of the person who made it up.
- All glassware must be extremely clean and dry. (To ensure complete lack of moisture, the glassware is put into an incubator at 60°C before beginning the processing, and removed as needed.)
- Since many of the reagents used are toxic, processing is done in a fume cupboard.

Reagents for processing**Palade's buffered osmium tetroxide (working solution)**

Palade's buffer	5mL
0.1M HCl	5mL
Distilled water	2.5mL
3% stock osmium solution	12.5mL

**Palade's buffer**

Sodium barbitone	2.89g
Sodium acetate	1.15g
Distilled water	100mL

**3% Osmium tetroxide (stock solution)**

Osmium tetroxide	1g
Distilled water	33mL

**0.1M HCl**

Concentrated HCl	8.6mL
Distilled water	1000mL

**Spurr's epoxy resin**

Make up according to table:

<b>Blocks</b>	<b>NSA ( gm)</b>	<b>ERL ( gm)</b>	<b>DER ( gm)</b>	<b>S1( gm)</b>
<b>24</b>	13	to 18	to 21	to 21,2
<b>36</b>	19,5	to 27	to 31,5	to 31,8
<b>48</b>	26	to 36	to 42	to 42,4
<b>60</b>	32,5	to 45	to 52,5	to 53
<b>72</b>	39	to 54	to 63	to 63,6
<b>84</b>	45,5	to 63	to 73,5	to 74,2
<b>96</b>	52	to 72	to 84	to 84.8

NSA

Nonenyl succinic anhydride.

ERL

Vinyl cyclohexene dioxide.

DER

Diglycidyl ether of polypropylene glycol.

S1

(DMAE) Dimethylaminoethanol.



Place a clean dry beaker on the scale and tare to nil. Add the required amount of each reagent, increasing the weight to the next specified. Stir well, as thorough mixing is essential. Keep container tightly covered with Parafilm when not in use. Great care must be taken, as the resin mixture is highly toxic and is rapidly absorbed by skin contact.

#### Step by step method

1. Rinse the ovum in two changes of phosphate buffer, for one minute each.
2. Postfixation, place in osmium tetroxide working solution for one hour, in a dark place (a covered box can be used). At this time the uranyl acetate solution can be made up, as it dissolves thoroughly on standing. It must be kept in a dark cupboard until needed.
3. Rinse in two changes of distilled water.
4. Place in 2% uranyl acetate in 70% ethanol for 5 minutes, in a ceramic spotting (staining) tile. The tile must be lightly covered with a length of Parafilm during standing times, to prevent contamination and to keep evaporation to a minimum. (The use of uranyl salts during processing is a form of "en-bloc" staining, and helps to give greater contrast when scanning the ovum in the electron microscope.)
5. Place in 70% ethanol, for three to five minutes. From this step onwards, all steps are carried out in consecutive hollows in the ceramic tile.
6. 96% ethanol for three to five minutes each.
7. 2% uranyl nitrate in 96% ethanol for 10 minutes.
8. Two changes of 100% ethanol for 10 minutes, and a further two changes of the same solution for fifteen minutes each. (Absolute ethanol absorbs atmospheric moisture, and must be stored over a layer of anhydrous sodium sulphate.)
9. Place in a mixture of 1mL 100% ethanol and 1mL Spurr's resin for forty-five minutes.
10. Two changes of 100% resin for 30 minutes.
11. Embed.

#### **Embedding**

Plastic moulds are used for embedding instead of the gelatin capsules used for routine tissue blocks. The moulds should be placed in an incubator for at least an hour before use, to ensure that they are dry.

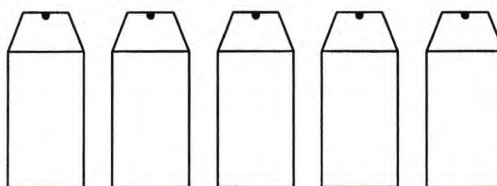


Figure 1. Spurr's epoxy resin blocks containing oocytes.

Resin is put into the mould, until it is a quarter full. The ovum is then inserted and gently guided down to the tip of the mould and carefully centered, using the capillary tube. If the ovum is too close to the edge of the block, trimming and cutting is made more difficult. The mould is then filled to the top, taking care not to disturb the ovum, so that it is still centered on the bottom of the mould. Leave to stand for twenty-one hours at 60°C.

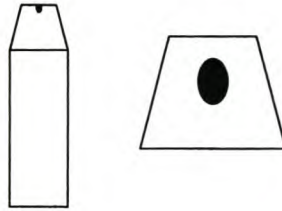


Figure 2: Trimmed Spurr's epoxy resin block containing an oocyte

### Trimming

Remove the block from the mould with care so as not to damage the top surface. Label the block with the identification number of the ovum. No gross trimming can be done, as it is only too easy to cut the entire ovum away in one careless stroke. Instead, progressing directly to the thin-section stage, the top of the block is trimmed manually using a firm blade into a trapezium shape, in preparation for cutting the sections.

### Cutting

#### Notes about the cutting procedure

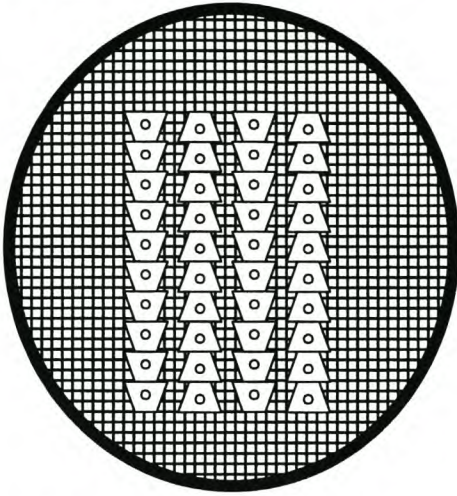
- The cutting of the ovum block must be done with great care. Some of the features to be looked for are so small that they appear in only one or two of the thin sections, and in order not to miss these structures, serial sections must be cut right through the entire depth of the cell, and every effort must be made not to waste any sections at all.
- A really good glass knife is adequate for cutting thin sections in practiced hands, otherwise a diamond knife should be used. A waterbath can be made from masking tape and filled with cooled freshly distilled water, using a clean pipette every time, to a level which is slightly concave.
- Make sure that both knife and block are tightly fastened before beginning to cut, to avoid fine chatters which are often only seen when scanning the sections.

#### Step by step method

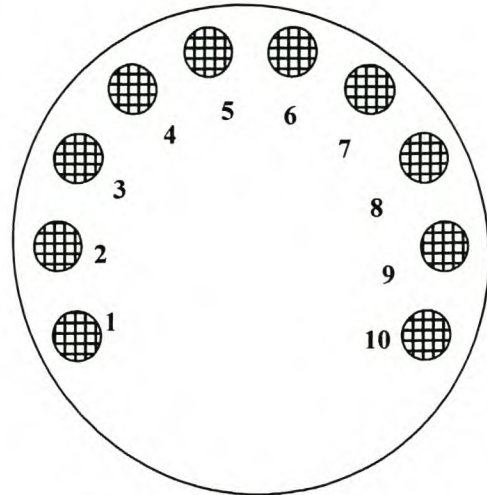
Fasten knife and block tightly in the microtome, and begin cutting as if for thin sections, with the microtome set on automatic, and a thickness of 70 - 90 nanometres (pale gold sections). The first sections, containing only resin, are discarded. If the block was correctly embedded the layer of resin covering the ovum is very thin and as soon as the smallest sign of irregularity in the resin is seen, the sections are kept.

Thin sections are cut in the form of long ribbons. Divided into smaller ribbons of ten sections each, the sections are maneuvered into a block comprising four ribbons lined up head to tail. A

fine sliver of Teflon taped to the end of an orange stick is used to move the sections around on the water.



Grid with 4 ribbons of thin sections.



Petri dish containing grids

Care must be taken to preserve the sequence of the sections. The block of ribbons is picked up on a 200-mesh copper grid, using a fine pair of forceps. The grid is first carefully washed in a stream of distilled water squirted from a Pasteur pipette. The grid is then slowly introduced into the water. Bringing the grid up under the group of sections at a 45° angle, the ribbons are gently attached, and the whole grid is lifted from the water.

Between 10 and 20 grids bearing 4 ribbons of sections each are cut from the block, until there is clearly only resin left in the sections. The grids are placed in sequence in a Petri dish lined with clean filter paper and covered immediately to keep out dust. The grids are carefully numbered so that they can be scanned in sequence. No more than ten grids are put into a Petri dish.

### Staining

The grids are stained by the same method (Reynolds' uranyl acetate/lead citrate method) used for routine EM cases.

#### Notes about the staining procedure

- It is at this point that the sections are most easily contaminated, with dust or precipitation from a contaminated staining solution. Extra care taken during staining can prevent wasted specimens, and wasted effort.
- Fresh solutions must be made up weekly.
- Care must be taken not to breathe over the wax strips during staining, as CO<sub>2</sub> causes the formation of lead carbonate crystals, which will be precipitated on the grids.
- To prevent the reagents drying out and causing the formation of crystals, staining is carried out on strips of dental wax placed on wet filter paper and kept covered with a clean Petri dish between changes.
- The solutions must be handled with care, as the heavy metal salts are toxic.

- A syringe fitted with a Millipore filter can be used to dispense drops of the staining solutions onto the wax strips. In this way, exposure to carbon dioxide is minimized, and the stain is filtered at the same time.

### Reagents for staining

#### **Uranyl acetate**

Uranyl acetate	1gm
50% ethanol	50mL
Store at 4°C, and replace if it becomes milky.	

#### **Reynold's lead citrate**

Lead nitrate	2.66gm
Sodium citrate	3.52gm
Distilled water	60mL
1M NaOH	16mL

1. Rinse all glassware with NaOH before starting.
2. Put ± 60mL distilled water into a flask.
3. Add sodium citrate and lead nitrate.
4. Shake well and allow to stand for 30 minutes, shaking every 5 minutes.
5. Allow to stand undisturbed for at least another 30 minutes.
6. Add 16mL freshly made NaOH. The milky solution should clear immediately.
7. Fill the flask to the 100mL mark with distilled water.
8. Store at 4°C.

#### **1M Sodium hydroxide (NaOH)**

NaOH	4gm
Distilled water	100mL

Mix well. (**NB**, Care must be taken when handling NaOH, as it is extremely caustic.)

### Step by step method

1. Filter the uranyl acetate/ethanol solution and place one drop for each grid to be stained on a strip of dental wax.
2. Using a clean pair of forceps, place a grid upside-down, with the sections downwards, on each drop. Allow staining for five minutes, covered with a Petri dish.
3. While waiting, filter the lead citrate solution and place a drop for each grid to be stained on a fresh piece of dental wax.
4. Remove the grids from the uranyl acetate solution, and rinse, first in 50% ethanol and then in two changes of distilled water, for 20 to 30 seconds each, with a rapid dipping movement. Blot carefully with filter paper to get rid of excess water and to prevent the grid from sliding down the forceps on opening.
5. Place upside-down on the Reynolds lead citrate solution and allow to stain for five minutes.

6. Rinse as before in two changes of distilled water, for 20 - 30 seconds each, again with a dipping movement, and blot carefully again with filter paper.
7. Allow drying for half an hour before scanning in the electron microscope.

## **TRANSMISSION ELECTRON MICROSCOPY FOR SPERMATOOZA.**

The preparation, fixation, embedding, cutting and evaluation of spermatozoa for TEM are very similar to that of the oocyte.

### Step by step method

1. Spermatozoa are washed free of seminal plasma with phosphate buffered saline (PBS) or Tyrodes buffer by centrifugation.
2. The pellet is resuspended in  $\leq 100\mu\text{l}$  buffer and fixed with 1.5mL Karnovsky's fixative or 2.5% gluteraldehyde for 2hr, 4°C.
3. The sample is then centrifuged at 4°C and the pellet resuspended in buffer and incubated for 2hr, 4°C.
4. The supernatant is removed and the pellet fixed with osmium tetroxide for 2 hr, 4°C.
5. The pellet is removed and cut with a needle into 1-2 mm fragments
6. The fixative supernatant is removed and the pellet dehydrated at room temperature in ethanol (70%, 96%, 100% for 15, 30 and 60 minutes respectively)
7. After dehydration, the fragments are treated with 50:50 Spurr's resin and ethanol for 90 minutes and then for 2hr in resin alone
8. Embedding, cutting and staining are as for the oocyte method.

## **Acknowledgements**

I wish to thank my colleagues at the Department of Anatomic Pathology, University of Stellenbosch; Marsia Kitshoff, Professor PAB Wranz and Pam McGregor for the successful development of this modified method.

I also wish to thank Dr. Mahmoud El. Shafie from Cairo, Egypt and Professor Mario Sousa from Porto, Portugal for introducing the method of single cell TEM to our laboratory.

## References

Bancroft, J.D. and Stevens, A. (eds) (1990) *Theory and Practice of Histological Techniques*, 3<sup>rd</sup> edn. Churchill Livingstone, Edinburgh.

Kay, D.(ed.) (1965) *Techniques for Electron Microscopy*, 2<sup>nd</sup> edn. Blackwell Scientific Publications, Oxford.

Sousa, M. and Tesarik, J. (1994) Ultrastructural analysis of fertilization failure after intracytoplasmic sperm injection. *Hum. Reprod.*, **9**, 2374-2380.

## **TRANSMISSION ELECTRON MICROSCOPIC (TEM) ULTRASTRUCTURE OF NORMAL, ABNORMAL AND UNFERTILIZED (ICSI) HUMAN OOCYTES TO EXPLAIN POSSIBLE REASONS FOR FERTILIZATION FAILURE**

### **Windt M-L**

Reproductive Biology Unit, Department of Obstetrics and Gynaecology, University of Stellenbosch, Tygerberg Hospital, TYGERBERG, South Africa.

### **Sousa M**

Laboratory of Cell Biology, Institute of Biomedical Sciences, University of Porto, PORTO, Portugal.

### **Kitshoff MS**

#### **MacGregor PM**

Diagnostic Electron Microscopy Unit, Department of Anatomical Pathology, University of Stellenbosch, Tygerberg Hospital, TYGERBERG, South Africa.

### **EI. Shafie M**

EI. Gallaa Maternity Hospital, CAIRO, Egypt.

### **Kruger TF**

Reproductive Biology Unit, Department of Obstetrics and Gynaecology, University of Stellenbosch, Tygerberg Hospital, TYGERBERG, South Africa.

## **Abstract**

**T**he development and implementation of a transmission electron microscopy (TEM) method for a single cell, in this study the human oocyte, revealed many interesting and valuable information on the ultrastructure of morphologically normal and abnormal appearing oocytes and ICSI unfertilized oocytes. Oocytes appearing yellowish and dark in colour were shown to be degenerated. Lysosomal and non-lysosomal degeneration were apparent at ultrastructural level. Vacuolated oocytes also showed signs of degeneration with large vacuoles prominent at ultrastructural level. The so-called refractile body was shown to be a secondary lysosome filled with lipid droplets and in our specific case caused the injected sperm cell to be ejected into the perivitelline space after collision with the refractile body. An abnormal fragmented oocyte showed several cytoplasmic abnormalities, the most obvious a large number of vacuoles and lamellae annulate indicating cytoplasmic immaturity.

ICSI failed fertilized metaphase II oocytes, revealed the following reasons for fertilization failure at ultrastructural level. Complete absence of oocyte activation; incomplete oocyte activation; female spindle abnormalities and subsequent complete absence of oocyte activation; ooplasm immaturity; an intact, partially decondensed or decondensed spermatozoon with subsequent complete absence or incomplete oocyte activation and extrusion of the injected spermatozoon into the perivitelline space. The TEM method can be used to help us understand the reasons for fertilization failure and gave valuable information on morphologically abnormal oocytes.

## Introduction

The introduction of intracytoplasmic sperm injection (ICSI) not only changed the treatment of male infertility, but also exposed the impact that oocyte morphology has on the fertilization process. For the first time we realized that many different oocyte anomalies exist - *in vitro* fertilization procedures oocytes were inseminated without really knowing much about the oocyte's appearance. In ICSI, oocytes are denuded before injection and each oocyte can be individually investigated microscopically for morphological appearance. Although light microscopy reveals obvious deviations from the normal, it does not give information about the ultrastructure of the oocyte. Transmission electron microscopy (TEM) is one way to look at the oocyte and reveal anomalies and also reasons for fertilization failure not obvious under light microscopy.

In this study we prepared and processed oocytes for TEM to look at the ultrastructure of normal, abnormal and unfertilized metaphase II oocyte features and organelles. In the case of unfertilized oocytes, we were interested in a possible diagnosis to explain fertilization failure, and also a possible prognosis and treatment for the patient.

## Materials and Methods

Patients undergoing routine IVF, GIFT and especially ICSI in our clinic donated normal, abnormal and unfertilized oocytes for the study.

Normal (n=3) and abnormal (n=8) donated oocytes were fixed within 24 hours post oocyte retrieval and were, in most cases, not inseminated or injected. Unfertilized (n=20) oocytes were fixed 48 hours post injection or insemination. No sign of fertilization (two pronuclei, two polar bodies or cleavage) was apparent in these oocytes.

### Oocyte preparation for single cell TEM

A detailed method has been described in the section Materials and Methods of this chapter. Briefly, the oocytes were fixed for at least one hour in Karnovsky' fixative (pH 7.4) at 4°C in a 4 well NUNC dish. After one hour, oocytes were washed in cacodylate buffer (pH 7.4) and stored at 4°C until further processing.

The washed oocytes were then treated with osmium tetra-oxide for 1 hour in the dark, rinsed with distilled water and placed in uranyl acetate (2% in 70% ethanol) for 5 minutes. Dehydration steps in 70%, 96% and 100% ethanol followed and the oocytes were finally embedded in Spurr's resin for 24 hours at 60°C (in specific plastic moulds).

The blocks from the moulds were processed for thin-sectioning with a diamond or glass knife (70-90 nanometers). The sections were then placed in sequence on a 200-mesh copper grid (10-20 sections). The copper grids were numbered to allow scanning in sequence and to ensure that no sections were lost.

The grids were then stained with Reynold's uranyl acetate/ lead citrate method and every section scanned. Sections with applicable features were photographed and evaluated.



## Description of ultrastructural features of the gametes investigated.

### Ultrastructure of a normal mature metaphase II oocyte

The ultrastructure of a normal metaphase II oocyte includes the following features (symbols to indicate the organelles are in brackets).

- The zona pellucida (**ZP**) containing cytomembranes (**F**) from the feet of follicular cells.
- The perivitelline space (**PVS**).
- Small microvilli (**Mv**) in the PVS.
- The oocyte cortex (**OC**) containing:
  - One to two rows of dense cortical vesicles (**CV**) beneath the oolemma.
  - Mitochondria (**M**).
  - Smooth endoplasmic reticulum (SER) aggregates of tubules (**T**) [SER-T].
  - SER large vesicles (**V**) [SER-V].
  - SER small vesicles (**arrows**).
  - SER isolated tubules (**arrowheads**).

The SER is a single organelle with regions with specialized functions and appearances. All elements of the SER are linked to each other, although in ultrathin sections they seem to be independent organelles. The SER-T and SER-V are always associated with mitochondria, but SER small vesicles can appear either isolated or associated with mitochondria. Most mitochondria are oval, moderately dense, with a few cristae. However, some mitochondria are flattened and crescent-shaped (**m1**) and encircles SER small vesicles (**v1**).

- The oocyte subcortex (**OSC**) mainly composed of:
  - SER-V with associated mitochondria.
  - SER very small vesicles and tubules.
  - Occasional isolated CV and SER-T.

- The first polar body (**1PB**) appears in the perivitelline space:

The 1PB is formed before gamete fusion and therefore contains all the features of the non-activated oocyte: - cortical vesicles, SER-V, SER small vesicles, SER isolated tubules, mitochondria, microtubules, a nucleus (**N**) with condensed chromatin.

- The second metaphase meiotic spindle with the female chromosomes:

Each chromosome shows a centromeric region (**double arrow**) and two chromatids (**C**). All the chromosomes are aligned in the same equatorial plane, with chromatids directed towards opposite poles. The microtubules (**Mt**) form the spindle and there are no asters (or centrioles) at the two poles of the spindle.

### Ultrastructure of an activated metaphase II oocyte

When the oocyte becomes activated, certain changes take place and this can be seen at ultrastructural level. There are three signs of oocyte activation.

- Complete cortical reaction, with no cortical vesicles being visible in the oocyte cortex, and cortical vesicle contents being dispersed in the perivitelline space.
- The smooth endoplasmic reticulum (SER) aggregates of tubules completely disappear from the cortex.

- The oocyte cortex shows a complete absence of SER large vesicles.

Intermediate stages can also be seen where the oocyte cortex shows a limited number of SER large vesicles, devoid of associated mitochondria. The appearance of SER small vesicles (**v1**) encircled by isolated mitochondria (**m1**) in the oocyte cortex is typical of a blocked, but fully activated oocyte. In this case the first polar body (**1PB**) will also be seen in the PVS, but without signs of meiosis resumption.

Meiosis resumption is diagnosed by the presence of the second polar body (**2PB**) in the PVS. Because the cytokinesis leading to 2PB extrusion always follows the cortical reaction, the 2PB never contains cortical vesicles. Another characteristic of the 2PB is that the segregated chromosomes almost always give origin to a decondensed nucleus (**N**), normally delimited by the nuclear envelope (**NE**). The 2PB can also have smooth endoplasmic reticulum (SER) vesicles (**V**), SER small vesicles (**arrows**), SER isolated tubules (**arrowheads**), mitochondria (**M**) and sometimes a Golgi complex (**G**) and microvilli (**Mv**).

If the oocyte reaches the two pronuclei stage, the oocyte cortex will show occasional SER large vesicles, either isolated or associated with only a few mitochondria, a few SER small vesicles, SER isolated tubules, and isolated mitochondria. In this case the oocyte has been fully activated, both cytoplasmically and meiotically.

#### Ultrastructure of an cytoplasmically immature oocyte

The following features diagnose cytoplasmic immaturity:

- Cortical vesicles (**CV**) are either dispersed in the oocyte cortex instead of being positioned beneath the oolemma or aggregated into numerous layers in the oocyte cortex or dispersed in the oocyte cortex and subcortex besides those correctly positioned beneath the oolemma.
- Golgi complexes (**G**) are present, still forming cortical vesicles.
- Annulate lamellae (**AL**) are present. AL are portions of the nuclear envelope shed into the ooplasm. Annulate lamellae later transform into endoplasmic reticulum cisternae.
- Mitochondria are absent or very scarce in the oocyte cortex, but present in the subcortex.
- Smooth endoplasmic reticulum (SER) aggregates of tubules (**T**) are absent.
- SER large vesicles (**V**), are present, but without associated mitochondria.

#### **Results**

The results of the study are presented as TEM micrographs showing the ultrastructure of the individual oocytes studied. The micrographs are representative of all the oocytes that were studied. Differences in the ultrastructure of cytoplasmically immature, mature and activated MII oocytes are summarized in Table 1.

#### Ultrastructure of a normal mature metaphase II oocyte

The normal features from normal metaphase II human oocytes are presented in Figures 1-6 and include all the organelles presented in the Materials and Methods section. Micrographs represent the results from two mature metaphase II oocytes and details of the normal organelle are presented in the legends to the micrographs.

#### Ultrastructure of failed fertilized oocytes

TEM revealed the following possible reasons for fertilization failure (after ICSI). TEM micrographs showing these features are presented in Figures 7-21 and represent 20 unfertilized oocytes.

In six unfertilized oocytes complete absence of oocyte activation was apparent. Figure 7 represents this result. Figures 8 & 9 represent micrographs from two oocytes where incomplete oocyte activation was the reason for fertilization failure. Female spindle abnormalities and subsequent complete absence of oocyte activation was shown in two unfertilized oocytes and are represented in Figures 10 & 11. Fertilization failure due to ooplasm immaturity was found in three oocytes (Figures 12-15). In another five unfertilized oocytes the injected spermatozoon were shown to be intact or partially decondensed with subsequent complete absence of oocyte activation or incomplete oocyte activation (Figures 16 & 19). Figures 17,18 & 20,21 represent micrographs of three unfertilized oocytes where the injected spermatozoon was found in the perivitelline space or in oolemma pouches. Details of all the features present in unfertilized oocytes are presented in the Materials and Methods section as well as in the legends to the micrographs.

#### Ultrastructure of abnormal oocytes

TEM were done on the following abnormal appearing oocytes and micrographs of the ultrastructure of these oocytes are presented in Figures 22-48.

Figures 22-30 represent micrographs from five oocytes showing dark, yellowish, granular cytoplasm indicative of autolysis, lysosomal and non-lysosomal degeneration. Lysosomal degeneration where lysosomes discharge their contents into the cytoplasm leads to autolysis and explains the loss of cytomembranes and the degeneration of organelles. Two multi-vacuolated, mature oocytes exhibited a polar body and many vacuole-like structures under inverted microscopy and their ultrastructure is represented in Figures 31-35. Figures 36-40 shows a mature oocyte with a refractile body. The oocyte remained unfertilized after ICSI and was processed for TEM after 48 hours incubation. Under inverted microscopy, this oocyte exhibited a polar body and also a round, dark body in the ooplasm. The ultrastructure of a fragmented oocyte is shown in Figures 41-48. The oocyte was enclosed in cumulus cells at aspiration and was not inseminated. Details of all the features present in these abnormal are presented the legends to the micrographs.

**Table 1**  
**Differences in the ultrastructure of cytoplasmically immature, mature and activated MII oocytes.**

	<b>Cytoplasmically immature MII oocyte</b>	<b>Cytoplasmically mature MII oocyte</b>	<b>Activated MII oocyte</b>
<b>Cortical vesicles (CV)</b>	Dispersed in the oocyte cortex and subcortex	Aligned into one or two rows beneath the oolemma	Not visible in the oocyte cortex; contents dispersed into PVS
<b>Mitochondria (M)</b>	Absent or scarce in oocyte cortex; present in subcortex	Present in oocyte cortex and subcortex.	Present in oocyte cortex and subcortex.
<b>SER aggregates of tubules (T)</b>	Absent	Present in the oocyte cortex and occasionally in subcortex	Absent from oocyte cortex
<b>SER large vesicles (V)</b>	Present but without associated mitochondria	Present in oocyte cortex and subcortex, associated with mitochondria	Absent from or limited numbers in the oocyte cortex
<b>SER small vesicles</b>	Present	Present	Present
<b>SER isolated tubules</b>	Present	Present	Present
<b>SER small vesicles (v1) encircled by isolated mitochondria (m1)</b>	Present	Present	Present
<b>First polar body (1PB)</b>	Present	Present	Present
<b>Second metaphase meiotic spindle with female chromosomes and microtubuli</b>	Present	Present	Present
<b>Microvilli (Mv)</b>	Present	Present	Present
<b>Golgi complexes (G) and annulate lamellae (AL)</b>	Present	Absent	Absent

## Discussion

In this descriptive study the ultrastructure of normal, morphological abnormal and unfertilized ICSI oocytes were evaluated and described.

The TEM method for a single cell, in this case the human oocyte, was adapted from the tried and tested procedures used for routine diagnostic tissue specimens (detailed methodology in Chapter 2). These modifications included changes in the length of time the oocyte spent in each solution due to its small size. The processing was done on a stereo microscope to ensure that the oocyte stayed visible before staining. After staining handling was done on a hollowed ceramic staining tile - the stained ovum was then relatively easy to see. Subsequent cutting was done very carefully to ensure that the whole oocyte is cut from top to bottom and each section preserved. Important information can be lost if sections are lost, for instance the spermatozoon, which is very small in size. It is also important to keep the sequence of the sections to ensure that the entire history of the oocyte is available for evaluation.

With the introduction of ICSI, the importance of oocyte morphology and appearance became evident. Oocytes are denuded for ICSI and gross morphological features can easily be seen through the inverted microscope and even the dissection microscope. These include changes in shape and colour, granularity, immaturity, inclusions, polar body and PVS status. Numerous studies (Van Wissen *et al.*, 1992; Bedford and Kim, 1993; Van Blerkom, 1993; De Sutter *et al.*, 1996; Palermo *et al.*, 1996; Serhal *et al.* 1997; Balaban *et al.*, 1998; Ballesteros *et al.*, 1998; Guthauser *et al.*, 1998a,b; Joris *et al.*, 1998; Moon *et al.*, 1998; Rattanachaiyanont *et al.*, 1998; Xia, 1998; Veeck 1999) have commented on the effect of oocyte morphology on fertilization and pregnancy outcome. In chapter I, these comments are reviewed. In most cases it was concluded that the only significant morphological abnormality which affected fertilization and pregnancy was vacuoles in the oocyte (Van Blerkom, 1993; De Sutter *et al.*, 1996; Guthauser *et al.*, 1998a,b). Colour changes due to degeneration or immaturity were obviously also negative factors (Van Blerkom, 1993).

In our own study, we found that dark coloured (brown or yellowish) oocytes were either very immature (prophase I) or degenerative. TEM of immature oocytes showed many cortical vesicles distributed throughout the ooplasm giving the oocyte a darker appearance under inverted microscopy. TEM also revealed that dark coloured mature oocytes were degenerated due to either lysosomal or non-lysosomal degeneration. In both cases the oolemma appeared to be ruptured giving rise to lysis of organelles in the oocyte. In some cases it is possible that oocytes can undergo degeneration in the follicle even before aspiration (Van Blerkom *et al.*, 1993). In most cases though, the oocyte is damaged either during the aspiration process or the denuding process essential for ICSI. It is possible that certain oocytes are more susceptible to damage due to the status of their membranes (Palermo *et al.*, 1996; Moon *et al.*, 1998) and one can reason that they would probably also be damaged during the injection procedure in ICSI. The prognosis for darkly coloured oocytes are therefore not very good unless prophase I oocytes can be successfully matured in *in vitro* culture. In our unit prophase I oocytes are matured and then injected, but other darkly coloured oocytes are discarded due to their degenerative nature as shown by TEM.

The impact of numerous vacuoles in the oocyte on fertilization became apparent when TEM evaluation of such oocytes in our study revealed its disorganized ultrastructure. The smooth endoplasmic reticulum (SER) did not show aggregates of tubules in this multi-vacuolated oocyte

and SER large vesicles surrounded by mitochondria were absent in the cortex and subcortex. Vacuole formation, from the fusion between numerous small SER vesicles, was also apparent in the 1PB, implying that the abnormal ooplasm existed before meiosis. Several other authors also commented on the detrimental effect of vacuoles (a sign of degeneration) on fertilization (Van Wissen *et al.*, 1992; Van Blerkom, 1993; Bedford and Kim, 1993; De Sutter *et al.*, 1996; Veeck, 1999). Oocytes with an obvious vacuolated appearance are therefore not normal and are discarded and not injected in our programme.

Another abnormality shown by our TEM study was that of the "refractile body". Several other authors reported that it has a negative effect on especially implantation (Veeck, 1991,1999; Bedford and Kim, 1993; Van Blerkom, 1993, Xia, 1997). In our own cases we found that some of these oocytes were fertilized and others not. TEM showed this ooplasmic inclusion to be a large lipofuscin body of accumulated lipids. The specific oocyte prepared for TEM were injected but did not fertilize. TEM revealed a normal ultrastructure, but fertilization failure was probably caused by spermatozoon extrusion after crushing of the injection needle against the refractile body. The sperm axoneme was present in the perivitelline space. These oocytes are injected taking care to avoid the refractile body when injecting. The etiology of refractile bodies are not known (Veeck, 1991) but can be a sign of intracellular degeneration (Van Blerkom, 1993).

The TEM ultrastructure of a fragmented oocyte, an uncommon abnormality, showed the main oocyte with three fragments. There were several cytoplasmic abnormalities in the main fragment and also in the smaller fragments, the most obvious was the large number of vacuoles. A polar body showed that the oocyte was at least genetically mature (and without vacuoles), but the appearance of lamellae annulate indicated some cytoplasmic immaturity. Female chromatin were present, but were abnormally dense. The etiology of this phenomenon is not known.

Fertilization failure after ICSI, the causes thereof and reasons why, are extensively reviewed and discussed in Chapter 1. In this study several apparently normal (metaphase II), but unfertilized, donated oocytes were evaluated with TEM. In many cases the only sign was that of oocyte activation failure, evident by intact cortical vesicles, but normal ultrastructure and normal female chromosomal material. Reasons for this event was probably due to some oocyte or sperm factor not detectable with TEM. In some cases partial activation was present with complete cortical reaction but no other ultrastructural events taking place pointing toward unknown oocyte or sperm factors, preventing the oocyte from resuming meiosis. Spindle abnormalities (mainly disorganized microtubules) were sometimes associated with oocyte activation failure causing female chromosomes to be dispersed and disarranged. In all these cases, unknown factors were causative and can be attributed to factors lacking the specific injected spermatozoon, inadequate immobilization, oocyte anomalies or possibly also laboratory conditions.

The appearance of the spermatozoon in unfertilized ICSI oocytes was either intact or partially decondensed and in most cases associated with oocyte activation failure. This can possibly be the result of an oocyte defect such as the absence or abnormal levels of sperm decondensing factor (SDF) (Dozortsev *et al.*, 1997). Inadequate immobilization can also be a reason (Dozortsev *et al.*, 1995, 1997; Palermo *et al.*, 1997). Cytoplasmic oocyte immaturity (Van Wissen *et al.*, 1992,1994) is also a possibility and it is of course possible that the injected sperm cell was not normal in terms of its biochemical and physiological abilities. Oocyte activation and sperm decondensation is interdependent events and has to be synchronized perfectly to result in normal

fertilization. TEM can only tell us that for a specific oocyte some events leading to total sperm decondensation and subsequent pronuclear formation, were not optimal.

In ICSI, fertilization failure can of course also be the result of the ICSI injection technique. Although it has been shown that injected spermatozoa can in some cases be extruded into the PVS after successful injection, the appearance of the sperm cell in the PVS or in oolemmal pouches, are mainly due to incorrect injection technique (Ng *et al.*, 1993; Flaherty *et al.*, 1995 a,b). In our TEM study two such unfertilized oocytes were evaluated. When the oolemma is not penetrated during ICSI, the sperm cell will move with the recovering oolemma to the PVS and can therefore not partake in the fertilizing events. It is therefore essential to make sure that the sperm cell is properly mixed with the ooplasm (by aspirating ooplasm into the injection pipette) and not only deposited in the furrow formed by the injection needle. TEM also showed a case where the sperm cell was caught in an oolemmal pouch in the cortex of the unfertilized oocyte. This was probably caused when the membrane was not properly penetrated and fused behind the sperm cell to form a pouch, rendering the sperm cell unavailable for cytoplasmic events.

Finally, some apparently mature unfertilized oocytes (genetically metaphase II) were shown by TEM to be cytoplasmically immature. Even metaphase II oocytes are routinely incubated for at least 3 hours before injection to allow for cytoplasmic maturity. In spite of this, TEM showed signs of immaturity (eg. Golgi apparatus, lamellae annulate, cortical vesicles dispersed in the oocyte cortex and subcortex as well as other structural features associated with immaturity (Figures 12-15) in some unfertilized oocytes. It is obvious that these oocytes were not able to follow the normal events of fertilization (Van Wissen *et al.*, 1994; Bergère *et al.*, 1995) and often result in premature chromatin condensation of the sperm cell, a sign of non-activation (Schmiady *et al.*, 1996).

Although TEM does not always reveal the exact reason for fertilization failure, this study has given us the opportunity to look into the oocyte and familiarize ourselves with what is normal and what is abnormal on ultrastructural level. In some cases it does however help us to understand the frustrating reality of fertilization failure. In some unique cases, where abnormalities are a recurrent event, TEM can be of significant diagnostic and prognostic value. In part B of this study, such a case will be discussed.

This TEM study allowed us to look at human gametes at ultrastructural level and made us realize how important the role of each gamete is, how very important the correct ICSI technique is and that in spite of all our endeavours, some oocytes are not destined for fertilization.

### **Acknowledgements**

Sincere thanks to the personnel of the Reproductive Biology Unit Tygerberg Hospital and the theatre personnel of the Tygerberg Hospital; Prof. PAB Wranz and his personnel from the Diagnostic Electron Microscopy Unit, Department of Anatomical Pathology, University of Stellenbosch, Tygerberg Hospital.

This research was supported by the Harry and Doris Crossley Research Fund, University of Stellenbosch, Tygerberg.

*The results of this study is in preparation for publication in Human Reproduction, 2000 and Fertility and Sterility, 2000.*

## Legends to figures

### Normal metaphase II oocyte

#### ***Ultrastructure of a normal metaphase II oocyte***

**Figure 1.** The zona pellucida (ZP) with normal, loose fibrillar structure; numerous cytomembranes (F) derived from the feet of follicular cells; normal perivitelline space (PVS), appearing as a narrow light space between the oolemma and the inner surface of the ZP; normal small microvilli (Mv); a normal oocyte cortex (OC); one to two rows of dense cortical vesicles (CV) beneath the oolemma (it is normal that a few isolated CV appear in the oocyte cortex); mitochondria (M), smooth endoplasmic reticulum (SER) aggregates of tubules (T); SER large vesicles (V); SER small vesicles (arrows); SER isolated tubules (arrowheads); flattened, crescent-shaped mitochondria (m1) encircling SER small vesicles (v1); a normal oocyte subcortex (OSC) with SER-V with their associated mitochondria, SER very small vesicles and tubules, and occasional isolated CV and SER-T. X 4 500.

**Figure 2.** A higher magnification of the cortex showing mitochondria (M), smooth endoplasmic reticulum (SER) aggregates of tubules (T), SER large vesicles (V), SER small vesicles (arrows), SER isolated small tubules (arrowheads) and crescent-shaped mitochondria (m1) encircling SER small vesicles (v1). The small vesicles of the SER appear either isolated or associated with mitochondria. X 30 000.

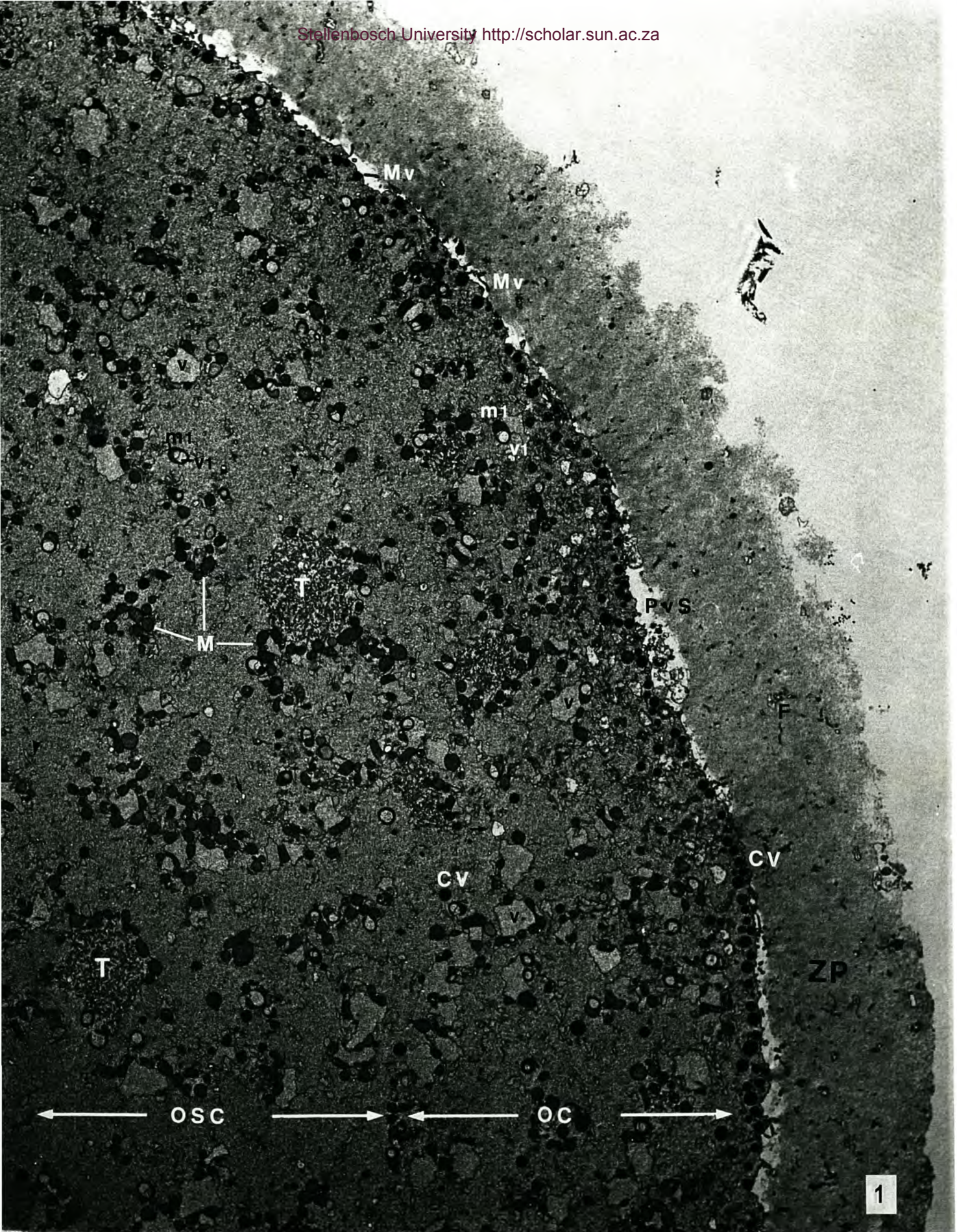
**Figure 3.** A higher magnification of the inner cytoplasm: SER small vesicles are subdivided into vesicles of small (v) and very small (arrows) dimensions. Small vesicles can appear either isolated or associated with mitochondria (M), very small vesicles are always isolated. Small vesicles are inter-linked by tubules (or cisternae) demonstrating the continuity of the SER. Isolated tubules of the SER (arrowheads) appear either isolated, linking SER small vesicles, or encircling mitochondria. Some of the SER small vesicles (v1) are encircled by flattened, crescent-shaped mitochondria (m1). X 60 000.

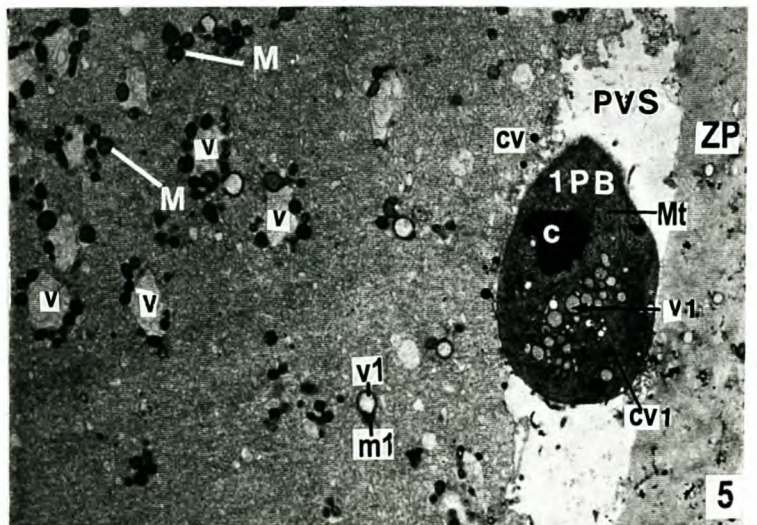
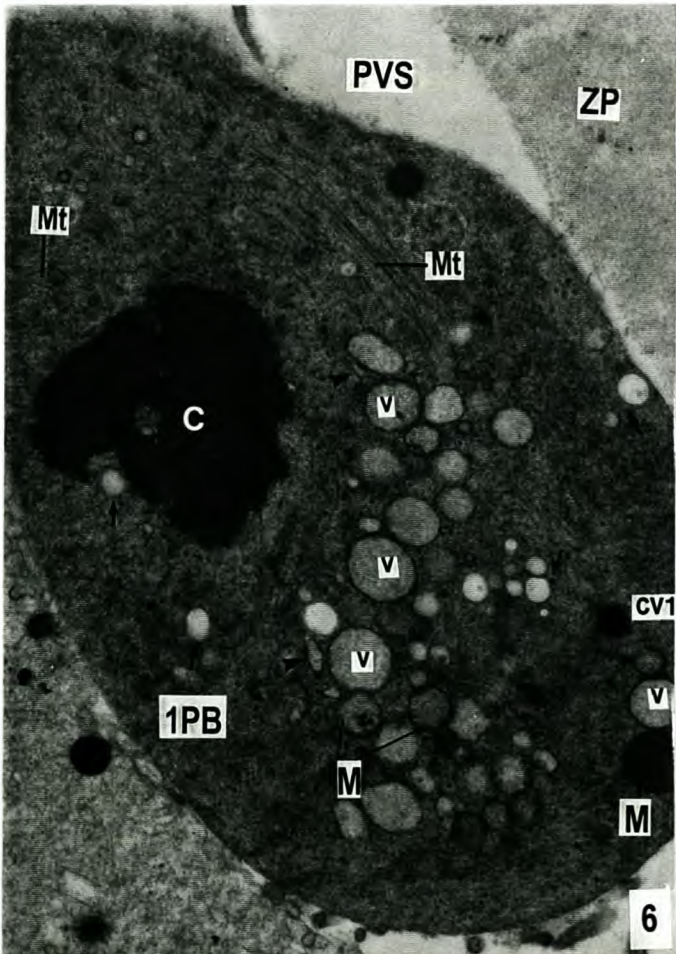



**Figure 4.** The normal second metaphase meiotic spindle in the subcortex. Each chromosome shows the centromeric region (double arrow) and two chromatids (C). Chromosomes are aligned in the same equatorial plane, with chromatids directed towards opposite poles. The microtubules (Mt) of the spindle show an accumulation of SER isolated small vesicles (arrows) and SER isolated tubules (arrowheads) at the two poles (\*) of the spindle but note that there are no asters. The spindle appears surrounded by SER aggregates of tubules (T) and SER large vesicles (V), both associated with mitochondria (M), and by SER small vesicles (v1) that are encircled by flattened, crescent-shaped mitochondria (m1). X 10 500.

**Figure 5.** The first polar body (1PB) in the PVS, containing intact cortical vesicles (CV1), SER large vesicles (V1), and microtubules (Mt). The 1PB also shows a condensed chromatin mass (C) not delimited by a nuclear envelope. X 6 000.

**Figure 6.** A higher magnification of the first polar (1PB) containing the same organelles of a mature unfertilized oocyte: intact cortical vesicles (CV1), mitochondria (M), smooth endoplasmic reticulum (SER) large vesicles (V), SER small vesicles (arrows), SER isolated tubules (arrowheads), and microtubules (Mt, in longitudinal and transversal sections). The 1PB also shows a condensed chromatin mass (C) not delimited by a nuclear envelope. PVS, perivitelline space; ZP, zona pellucida. X 24 000.







## **Unfertilized metaphase II oocytes after ICSI**

### ***Ultrastructure of failed fertilized (ICSI) metaphase II oocyte due to complete absence of oocyte activation:***

**Figure 7.** The oocyte cortex has a normal structure with no signs of activation. The cortical vesicles (CV) are dense and intact and arranged in two rows beneath the oolemma (no cortical reaction). It also contains smooth endoplasmic reticulum (SER) aggregates of tubules (T), microvilli (Mv), mitochondria (M), SER large vesicles (V), SER small vesicles (arrows), SER isolated small tubules (arrowheads), flattened, crescent-shaped mitochondria (m1), encircling SER small vesicles (v1) and the first polar body (1PB) in the perivitelline space (PVS). In the 1PB region the PVS is wider and the oocyte microvilli (Mv) longer. The 1PB was formed before gamete fusion and contains cortical vesicles (CV). ZP, zona pellucida. X 9 000.

### ***Ultrastructure of failed fertilized (ICSI) metaphase II oocyte due to incomplete oocyte activation (no meiosis resumption):***

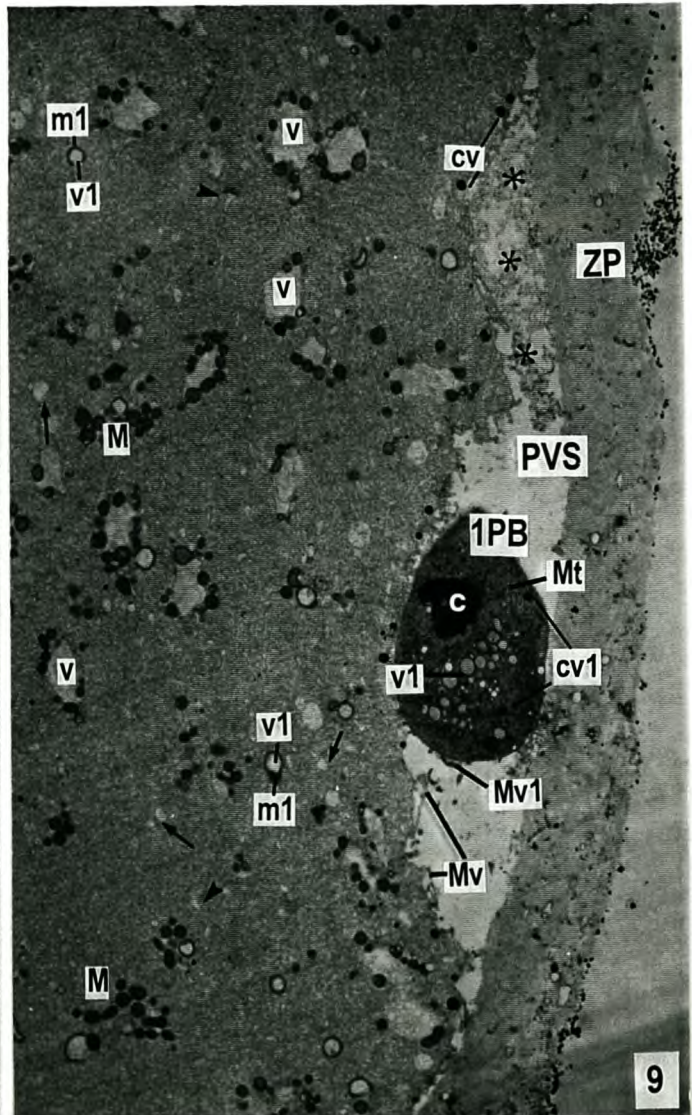
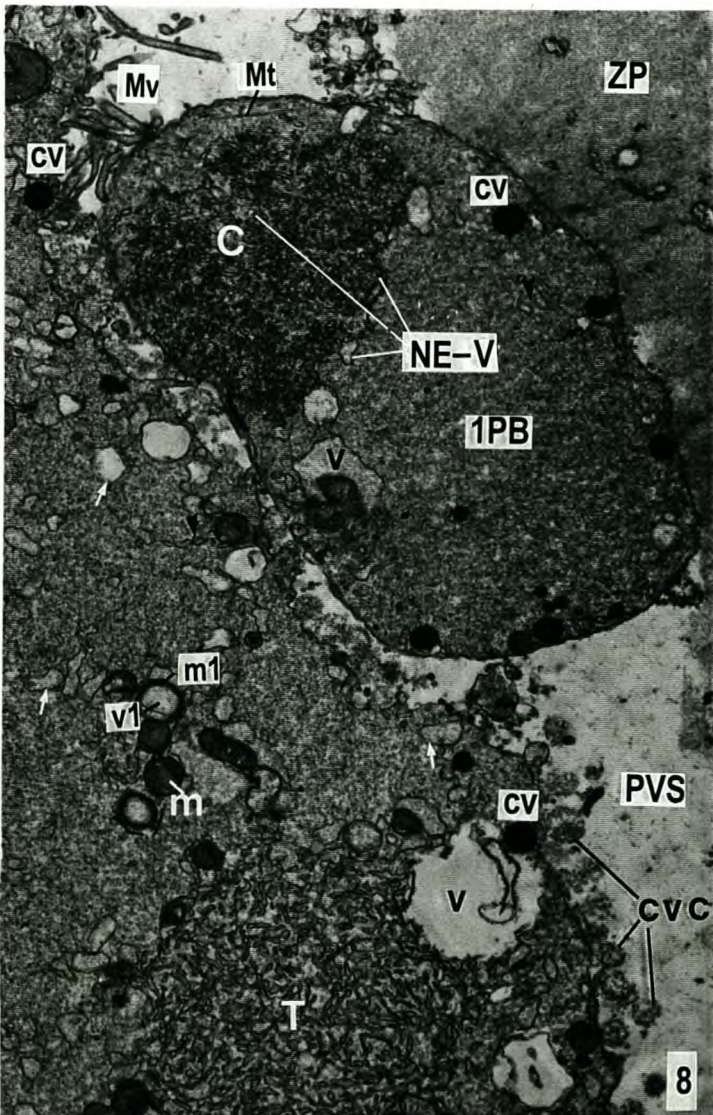

**Figure 8.** Complete cortical reaction took place: no swollen or oolemma-fused cortical vesicles in the oocyte cortex, cortical vesicle contents appear free in the perivitelline space (PVS) as round loose fibrillar structures above the oocyte surface (CVC). Some dense cortical vesicles (CV) remained intact in the oocyte's cortex (normal finding). The rest of the oocyte cortex remained unchanged, with mitochondria (M), smooth endoplasmic reticulum (SER) aggregates of tubules (T), SER large vesicles (V), SER small vesicles (arrows), SER isolated tubules (arrowheads) and crescent-shaped mitochondria (m1), encircling SER small vesicles (v1). The first polar body (1PB) contains intact CV, SER-V, SER small vesicles (arrows), SER isolated tubules (arrowheads), and microtubules (Mt; in longitudinal and transversal section). The 1PB also shows a chromatin mass (C) intermingled with SER tubules or cisternae (NE-V) that have not yet fused to form the nuclear envelope. ZP, zona pellucida; Mv, oocyte microvilli. X 15 000.

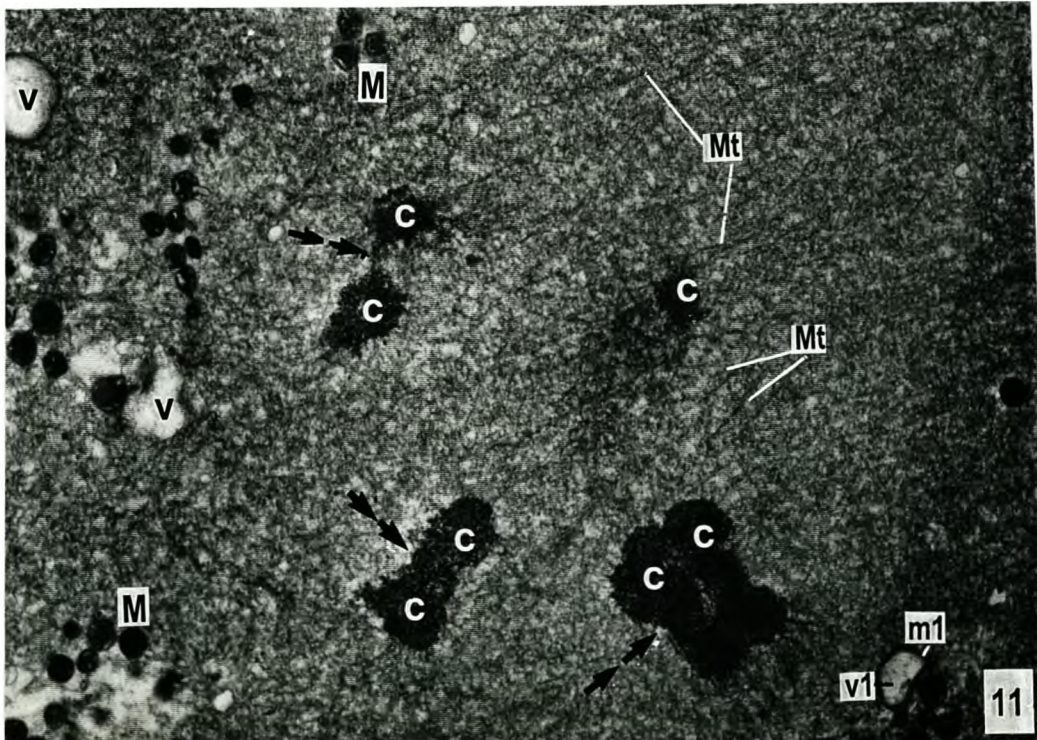
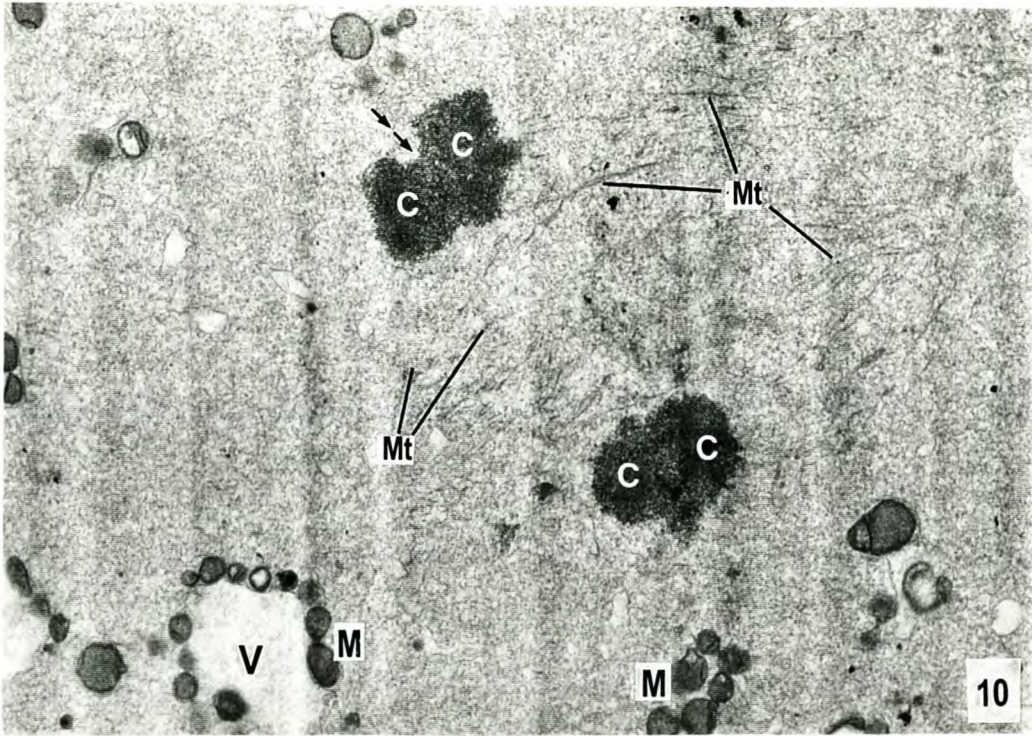
**Figure 9.** Complete cortical reaction took place: no swollen or oolemma-fused cortical vesicles in the oocyte cortex and cortical vesicle contents appear free in the perivitelline space (PVS) (\*) above the oocyte surface. Some dense cortical vesicles (CV) remained intact (normal); also the smooth endoplasmic reticulum (SER) aggregates of tubules have disappeared from the oocytes cortex. The rest of the oocyte cortex remained unchanged; mitochondria (M), SER large vesicles (V), SER small vesicles (arrows), and SER isolated tubules (arrowheads), flattened, crescent-shaped mitochondria (m1), encircling SER small vesicles (v1). The 1PB contains intact cortical vesicles (CV1), SER large vesicles (V1), microtubules (Mt), a condensed chromatin mass (C) not delimited by a nuclear envelope. Mv, oocyte microvilli; Mv1, microvilli of the 1PB. X 6000.

### ***Ultrastructure of failed fertilized (ICSI) metaphase II oocyte due to absence of oocyte activation and female spindle abnormalities:***

**Figure 10.** This oocyte showed no signs of a cortical reaction and smooth endoplasmic reticulum (SER) aggregates of tubules (T) appeared in the OC (not shown in the figure). The second metaphase meiotic spindle of the oocyte however also appears abnormal showing a reduced number of chromosomes after serial sectioning. Microtubules (Mt) appear slightly disorganized. Each chromosome shows, however a normal centromeric region (double arrow) and two chromatids (C) and each chromatid is correctly aligned to opposite poles. The few chromosomes present are also correctly aligned in the same plane. The spindle is surrounded normally by SER large vesicles (V) associated with mitochondria (M). X 18 000.

**Figure 11.** This oocyte also showed no signs of a cortical reaction and smooth endoplasmic reticulum (SER) aggregates of tubules (T) appeared in the OC (not shown in the figure). The second metaphase meiotic spindle of the oocyte is abnormal because chromosomes (C) appear dispersed (not aligned in a metaphasic plate) and the microtubules (Mt) appear slightly disorganized. Each chromosome shows, however, a normal centromeric region (double arrows) and two chromatids (C) correctly aligned to opposite poles. The spindle are surrounded normally by SER large vesicles (V), associated with mitochondria (M); by SER vesicles (v1) encircled by flattened, crescent-shaped mitochondria (m1). Mitochondria appear however abnormally small and dense, and the v1 vesicles, appear abnormally large. X 15 000.





## Unfertilized metaphase II oocytes after ICSI

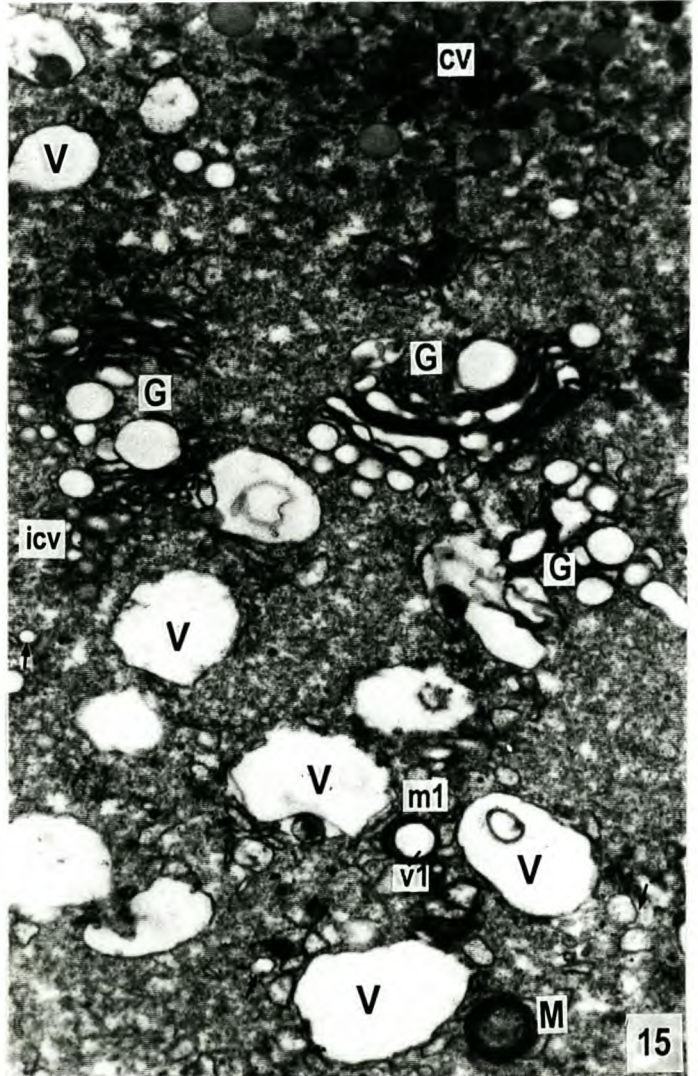

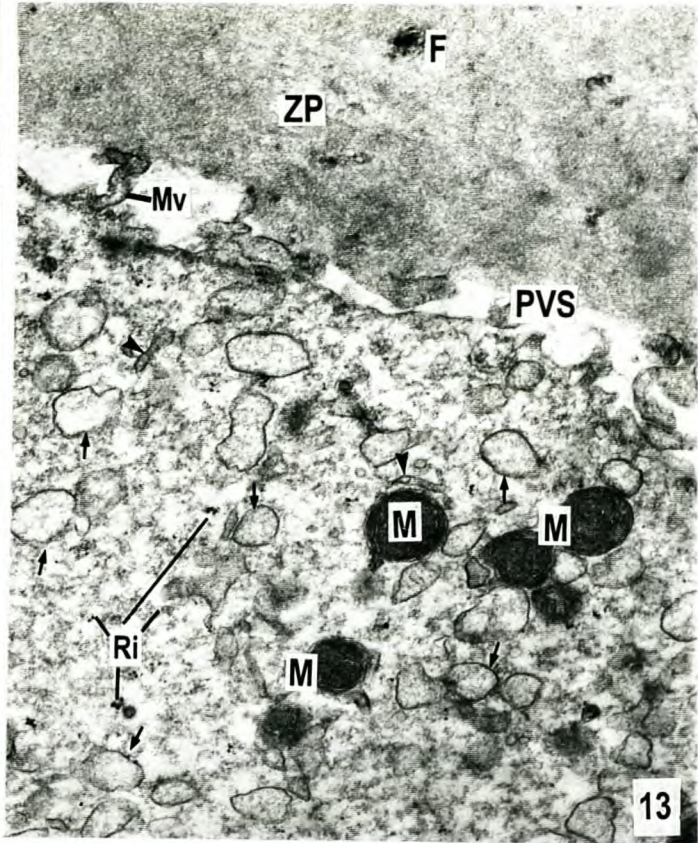
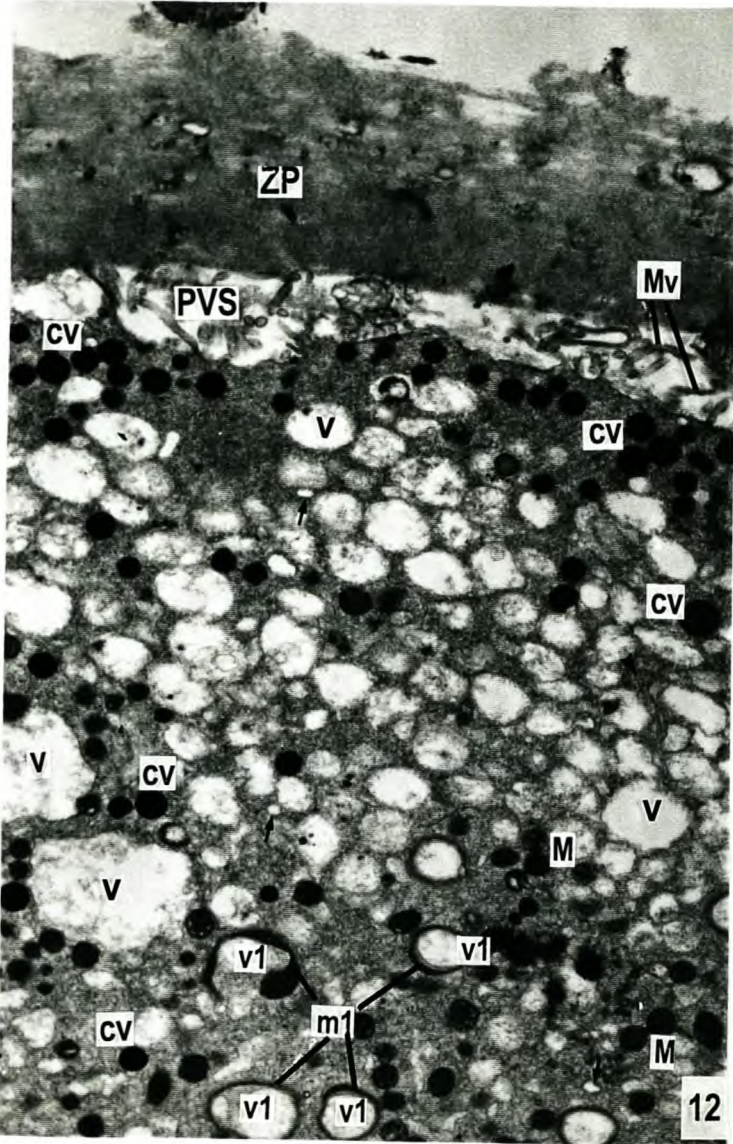
### ***Ultrastructure of failed fertilized (ICSI) metaphase II oocyte due to cytoplasmic immaturity:***

**Figure 12.** Numerous cortical vesicles (CV) dispersed in the oocyte cortex and subcortex besides those correctly positioned beneath the oolemma; mitochondria (M) present only in the subcortex; smooth endoplasmic reticulum (SER) aggregates of tubules absent in both OC and OSC; enormous amounts of SER large vesicles (V) devoid of their associated mitochondria in the cortex; normal amounts of SER large vesicles with associated mitochondria in the subcortex. (This accumulation of SER-V in the oocyte cortex should not be confused with the vacuolar degeneration that is characteristic of certain aged oocytes. In vacuolar degeneration, SER-V are larger and fill the cortex and subcortex and CV are not found between those vesicles). SER small vesicles (arrows) and SER isolated tubules (arrowheads), PVS, perivitelline space, Mv, microvilli, ZP, abnormally dense zona pellucida. X 15 000.

**Figure 13.** The cortex only presents isolated mitochondria (M), SER small vesicles (arrows), SER isolated tubules (arrowheads), and numerous free ribosomes (Ri). There are no cortical vesicles, smooth endoplasmic reticulum (SER) aggregates of tubules and SER large vesicles associated with mitochondria. Mv, microvilli, PVS, perivitelline space, ZP, zona pellucida, F, feet of follicular cells. 36 000.

**Figure 14.** Golgi complexes (G) and annulate lamellae (AL). Mitochondria (M), cortical vesicles (CV), SER small vesicles (arrows), SER large vesicles (V). X 18 000.

**Figure 15.** Increased numbers of SER large vesicles (V) with decreased numbers of associated mitochondria; numerous Golgi complexes (G) still forming cortical vesicles (icv). SER small vesicles (arrows) and SER isolated tubules (arrowheads), mitochondria (M), cortical vesicles (CV), SER vesicles (v1) encircled by flattened, crescent-shaped mitochondria (m1). X 10 600.



## Unfertilized metaphase II oocytes after ICSI

### ***Ultrastructure of failed fertilized (ICSI) metaphase II oocyte, absence of oocyte activation: Partial male chromatin decondensation:***

**Figure 16.** The injected spermatozoon is in the subcortex and has lost the cytoplasmic membrane, the acrosomal vesicle, the equatorial region, and the nuclear envelope. The dense chromatin is completely decondensed (**C**) except for some central regions (**C1**). The decondensed male chromatin is encircled by oocyte organelles, smooth endoplasmic reticulum (SER) small vesicles (**arrows**), SER isolated tubules (**arrowheads**), and mitochondria (**M**). The oocyte cortex appears normal, showing cortical vesicles (**CV**), SER large vesicles (**V**), with associated mitochondria (**M**), SER small vesicles (**arrows**), and SER isolated tubules (**arrowheads**). However, SER aggregates of tubules are missing. **Mv**, microvilli; **ZP**, zona pellucida. X 24 000.

### ***Ultrastructure of failed fertilized (ICSI) metaphase II oocyte due to extrusion of the injected spermatozoon into the PVS:***

**Figures 17 and 18.** The extruded spermatozoon is visible in the perivitelline space (**PVS**) showing an intact cytoplasmic membrane (**cy**), mitochondria (**M**), and nuclear envelope (**NE**), partially decondensed chromatin (**C**) and a complete degenerated acrosomal vesicle (**AV**). The oocyte cortex shows normal components of a non-activated mature oocyte; intact cortical vesicles (**CV**), smooth endoplasmic reticulum (SER) aggregates of tubules (**T**), SER large vesicles (**V**), mitochondria (**M**), SER small vesicles (**arrows**), SER isolated tubules (**arrowheads**) and SER small vesicles (**v1**) encircled by flattened, crescent-shaped mitochondria (**m1**). **Ax**, axoneme of the spermatozoon in the PVS, **ZP**, zona pellucida. X 24 000 and X 45 000, respectively.

### ***Ultrastructure of failed fertilized (ICSI) metaphase II oocyte, absence of oocyte activation: absence of male chromatin decondensation:***



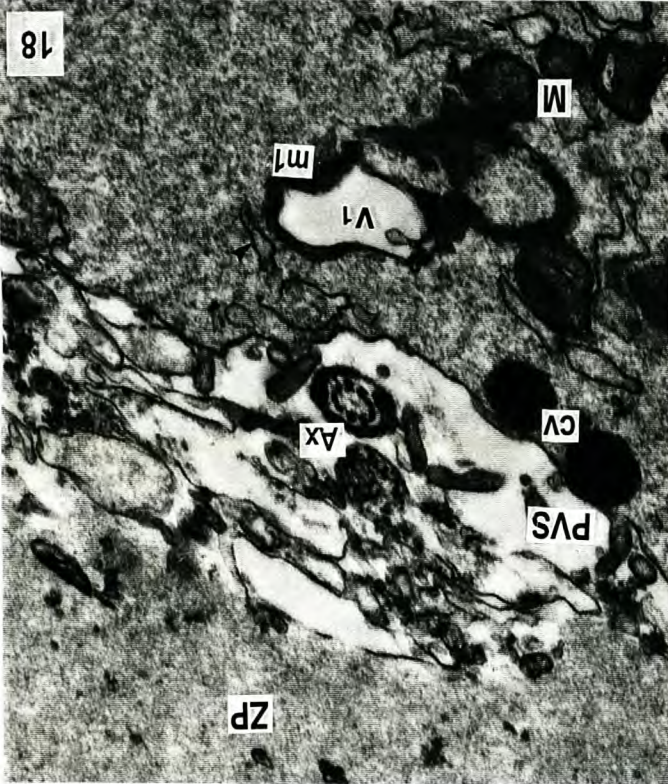
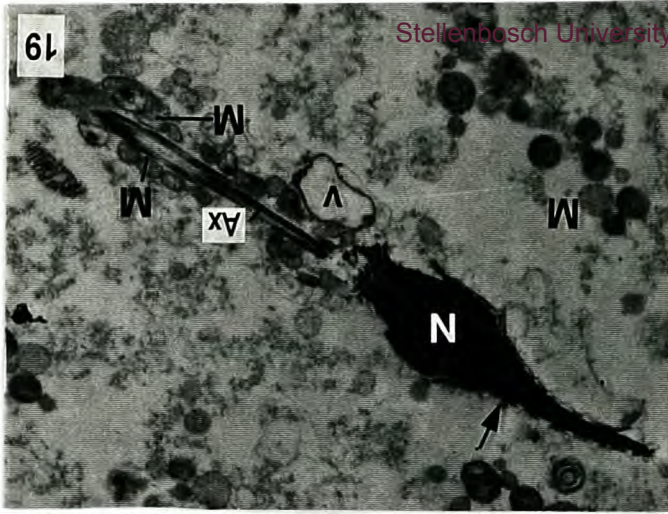
**Figure 19.** The male chromatin of the sperm cell is still condensed. The injected spermatozoon is acrosome reacted (**arrow**), but the dense nucleus (**N**) remained intact. **Ax**, axoneme, **M** mitochondria. X 30 000.

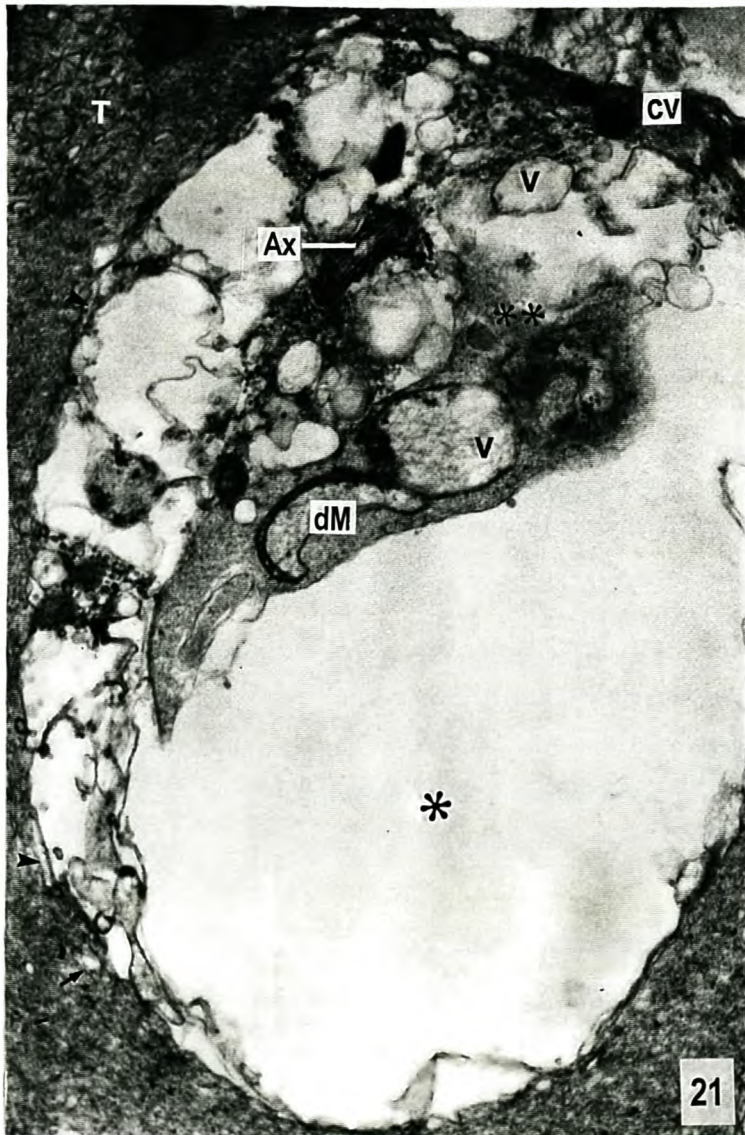
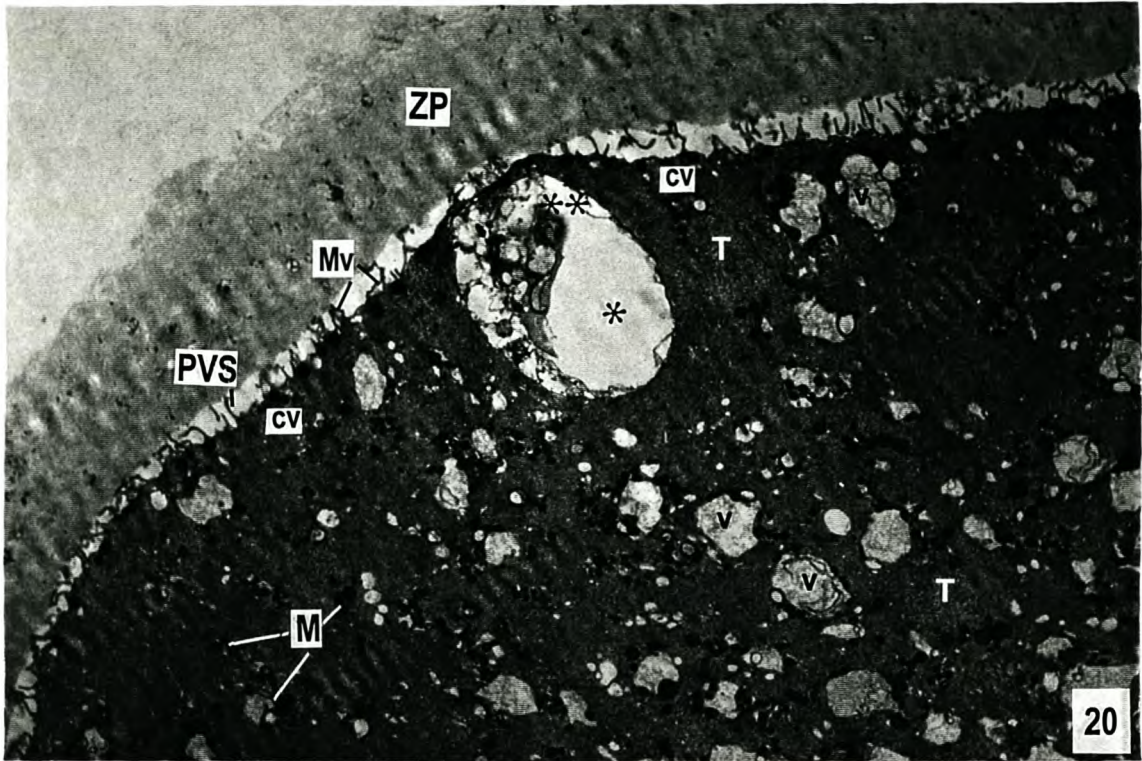
### ***Ultrastructure of failed fertilized (ICSI) metaphase II oocyte due to extrusion of the injected spermatozoon.***

**Figure 20.** An oolemma pouch (\*) (oolemmal invagination) caused by oolemma inversion during microinjection with remnants of extruded ooplasm (\*\*). The oocyte cortex shows normal components of a non-activated mature oocyte; intact cortical vesicles (**CV**), smooth endoplasmic reticulum (SER) aggregates of tubules (**T**), SER large vesicles (**V**), mitochondria (**M**), SER small vesicles (**arrows**), SER isolated tubules (**arrowheads**). **Mv**, microvilli; **PVS**, perivitelline space; **ZP**, zona pellucida. X 6 000.

**Figure 21.** Higher magnification of the oolemma pouch (\*) showing remnants of extruded ooplasm (\*\*), containing smooth endoplasmic reticulum (SER) large vesicles (**V**), SER small vesicles (**arrows**); degenerated mitochondria (**dM**) and the axoneme (**Ax**) of the extruded spermatozoon. X 24 000.







## **Abnormal oocytes**

**Figure 22.** A light microscopic photograph showing an oocyte appearing **dark, granular and yellowish in colour**. X 200.

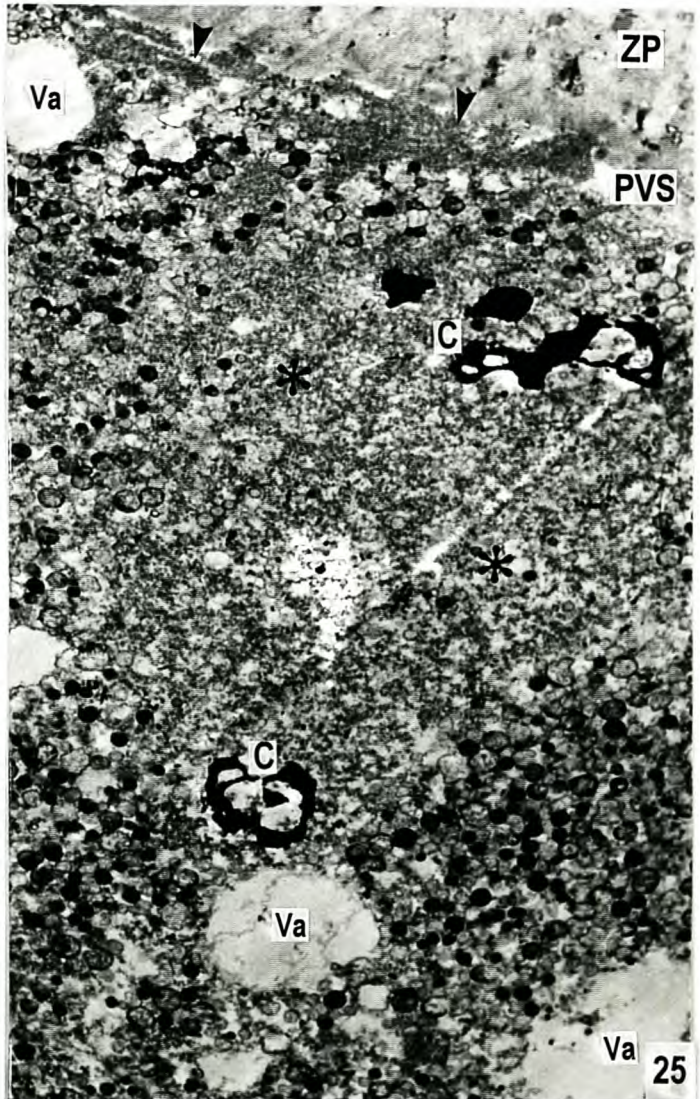
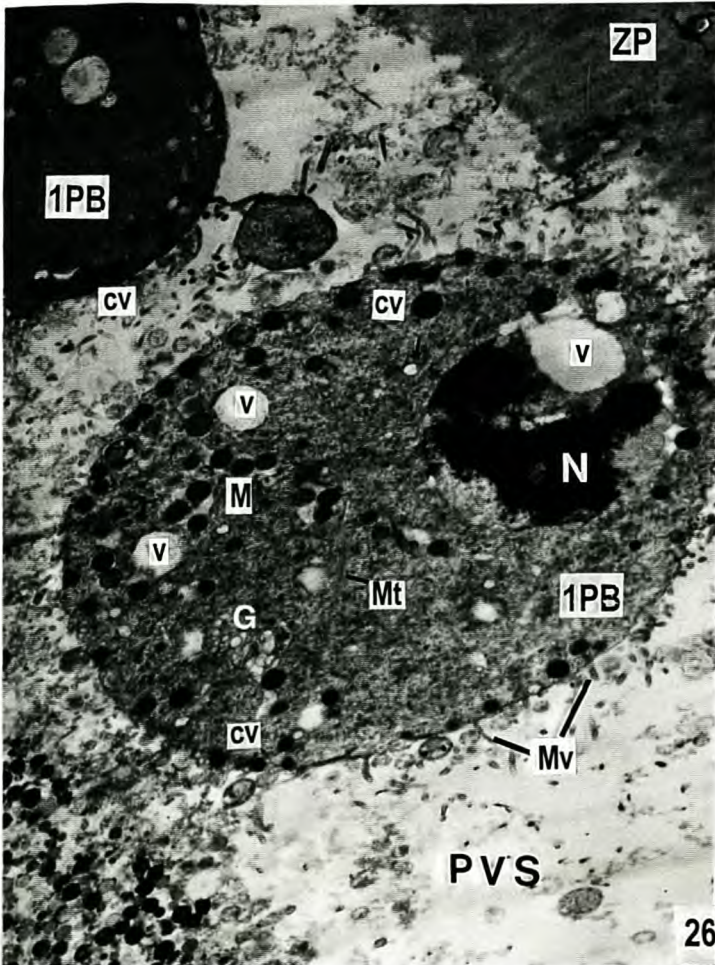
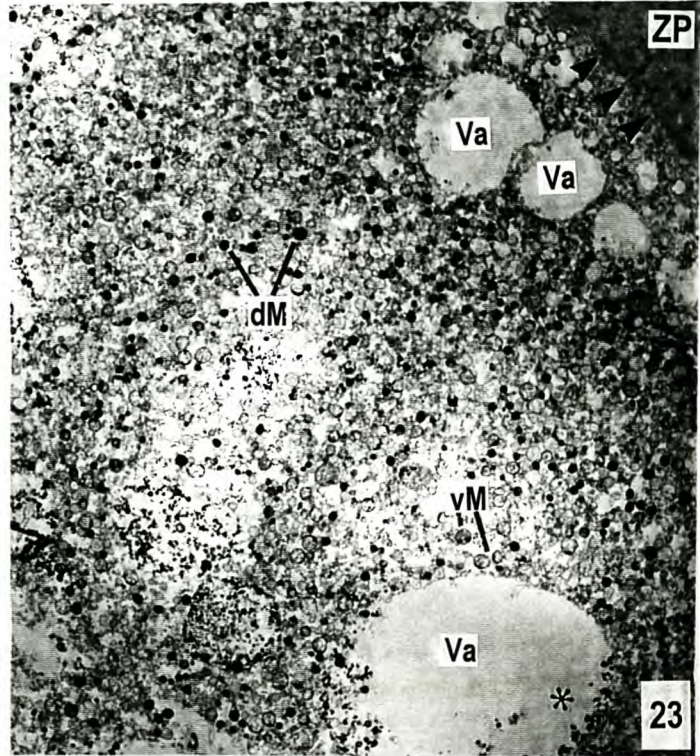

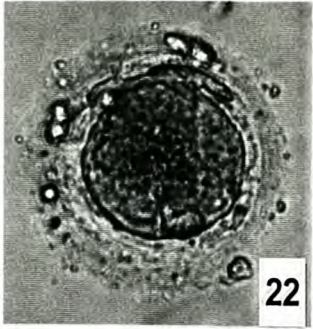
### ***Ultrastructure of an oocyte appearing dark, granular and yellowish in colour under inverted light microscopy (lysosomal degeneration):***

**Figure 23.** The oolemma is ruptured and the ooplasm lies directly beneath (**arrowheads**) the abnormally dense zona pellucida (**ZP**). Cortical vesicles and the typical smooth endoplasmic reticulum (SER) vesicles and tubules do not appear in the cytoplasm. Mitochondria appear abnormally dense (**dM**) or vacuolated (**vM**). Numerous small vesicles of the SER (most of them with ruptured membranes) appear as open, light, small spaces. Numerous light vacuoles (**Va**) appear in the ooplasm, some of them showing heterogeneous dense contents (\*). Disruption of membranes and fusion with secondary lysosomes, or fine fibrillar contents is followed by penetration of cytoplasmic contents into the vacuolar space. Lysosomal degeneration where lysosomes discharge their contents into the cytoplasm leads to autolysis and explains the loss of cytomembranes and the degeneration of organelles. X 4 500.

**Figure 24.** A higher magnification of the same oocyte. Smooth endoplasmic reticulum (SER) vesicles and tubules do not appear in the cytoplasm. Mitochondria are abnormally dense (**dM**) or vacuolated (**vM**). Numerous small vesicles of the SER (most of them with a ruptured membrane) appear as open, light, small spaces. **Va**, light vacuoles, heterogeneous dense contents (\*), fine fibrillar contents (**arrows**). Note also the fusion between the different vacuoles. X 10 500.

**Figure 25.** The same oocyte as in Figure 23, showing a ruptured membrane and ooplasm (**arrowheads**) in the perivitelline space (**PVS**) directly beneath the zona pellucida (**ZP**). The female meiotic chromosomes (**C**) are abnormally condensed and aggregated inside an organelle free area (\*) X 9 000.

**Figure 26.** The same oocyte as in Figure 23. In this image, the first polar body (**1PB**) is shown and the PVS appears conserved. The 1PB is fragmented, with one of the fragments showing a nucleus (**N**), a rare event, since the 1PB normally exhibits the condensed chromosomes free in the cytoplasm. In spite of the severe degeneration of the oocyte, the structure of the 1PB is well conserved, showing microvilli (**Mv**), cortical vesicles (**CV**), mitochondria (**M**), Golgi complexes (**G**), smooth endoplasmic reticulum (SER) large vesicles (**V**), SER small vesicles (**arrows**) and microtubules (**Mt**). **ZP**, zona pellucida. X 10 500.



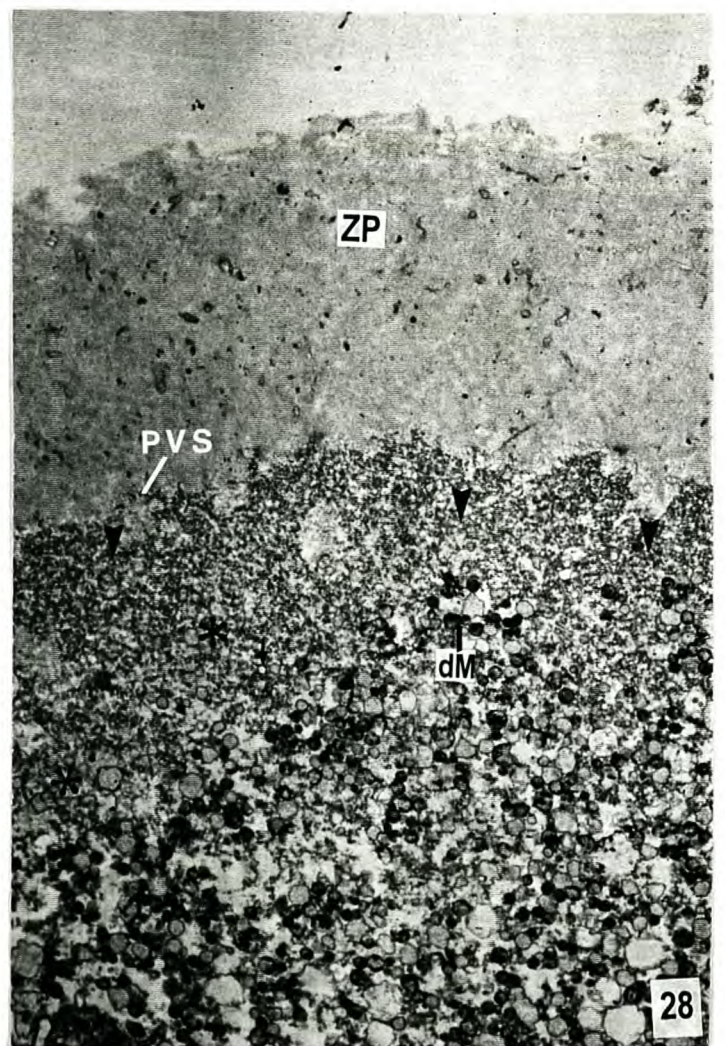
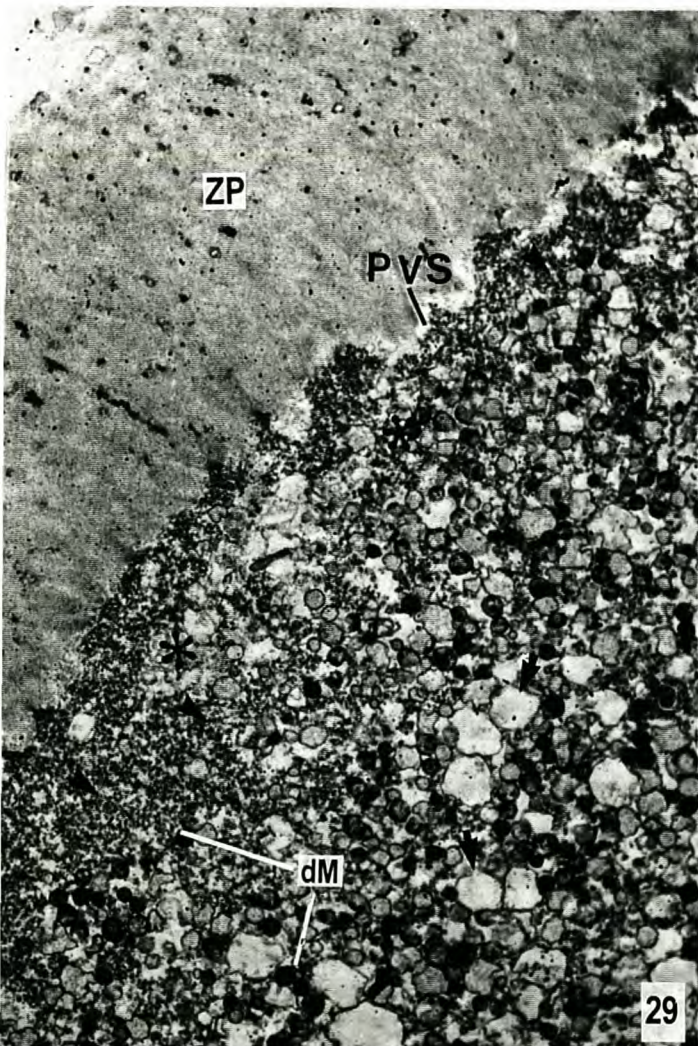
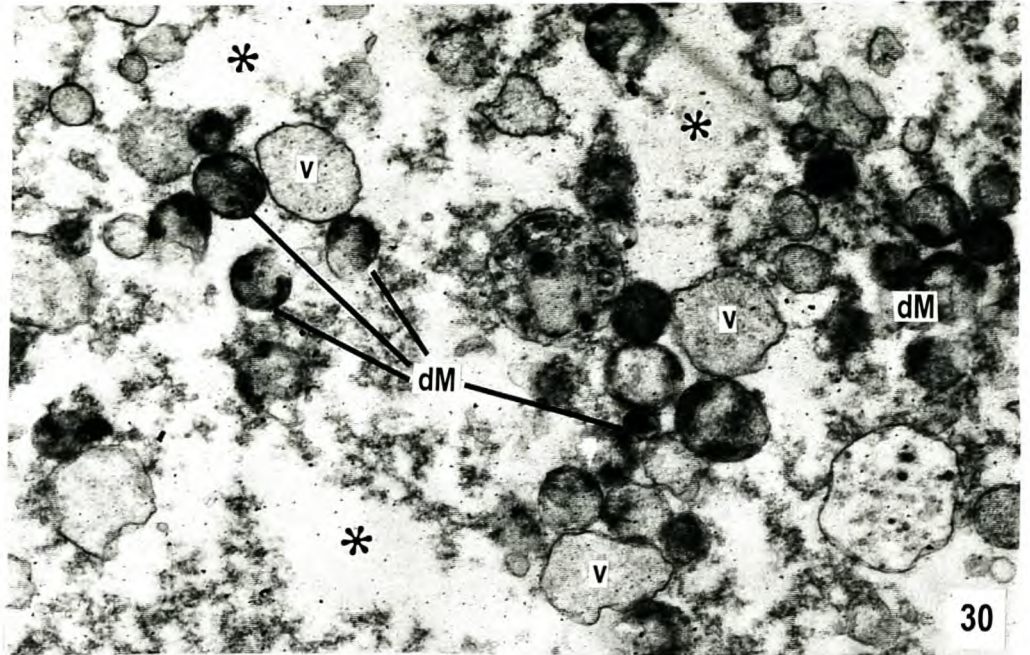
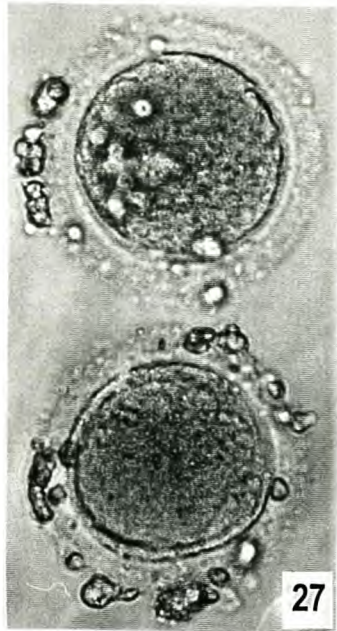
## **Abnormal oocytes**

**Figure 27.** A light microscopic photograph showing an oocyte appearing dark, granular and yellowish in colour.

### ***Ultrastructure of an oocyte appearing dark, granular and yellowish in colour under inverted light microscopy. (Degenerated oocyte without evidence of lysosomal degeneration):***

**Figures 28 and 29.** The oolemma is ruptured, ooplasmic contents (**arrowheads**) and fibrillar material (\*) are apparent in the perivitelline space (**PVS**). The ooplasm shows no intact cortical vesicles, but numerous degenerated mitochondria of the dense type (**dM**). The smooth endoplasmic reticulum (SER) has ruptured creating numerous small open light spaces. Occasional SER small vesicles remained intact (**arrows**). **ZP**, zona pellucida. X 6 000 and X 9 000, respectively.

**Figure 30.** The mitochondria appear abnormally dense and degenerated (**dM**). Numerous small vesicles of the smooth endoplasmic reticulum (SER) (most of them with ruptured membranes), appear as open light spaces (\*). Many of the SER large vesicles (**V**) appear however intact despite the degenerative process. X 30 000.



## **Abnormal oocytes**

**Figure 31.** Light microscopic view (inverted phase contrast) of a **multi-vacuolated** mature oocyte. The oocyte was not inseminated or micro-injected. X 200.

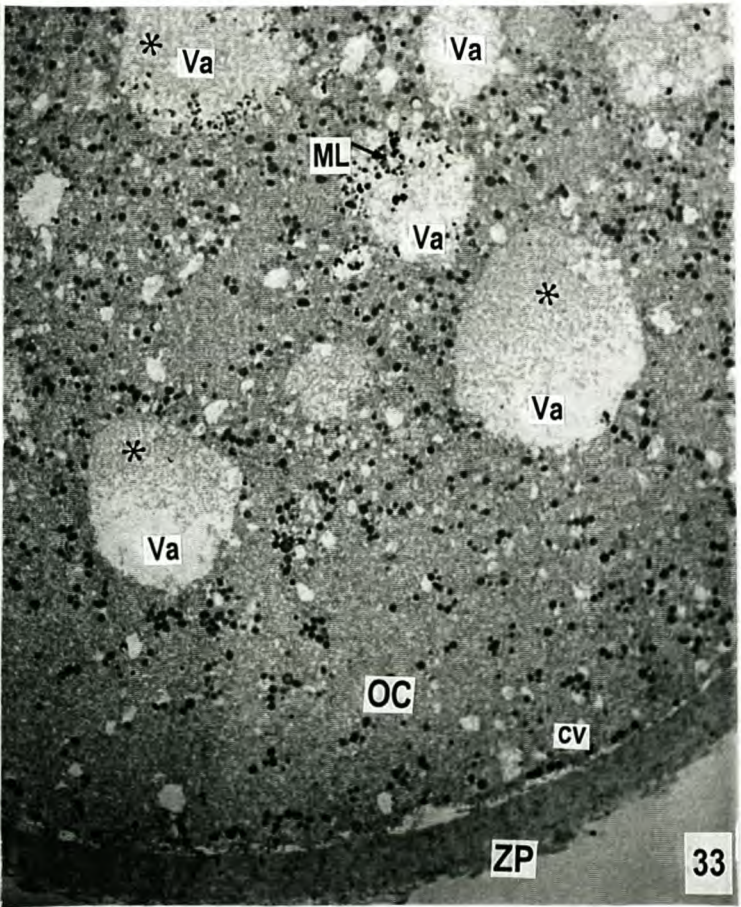
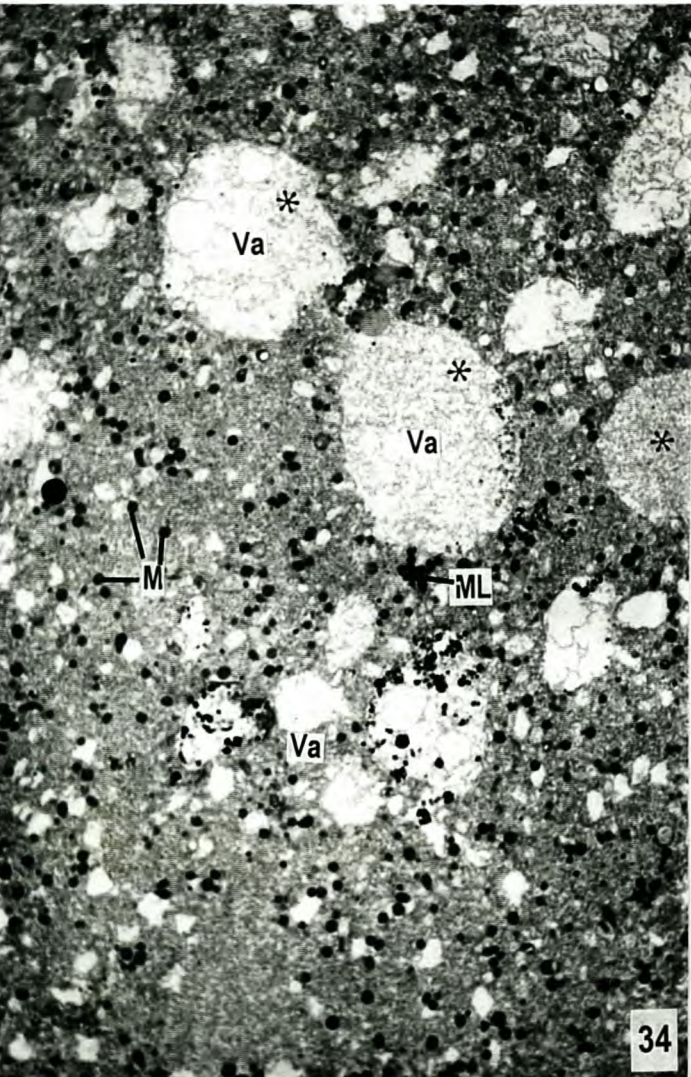
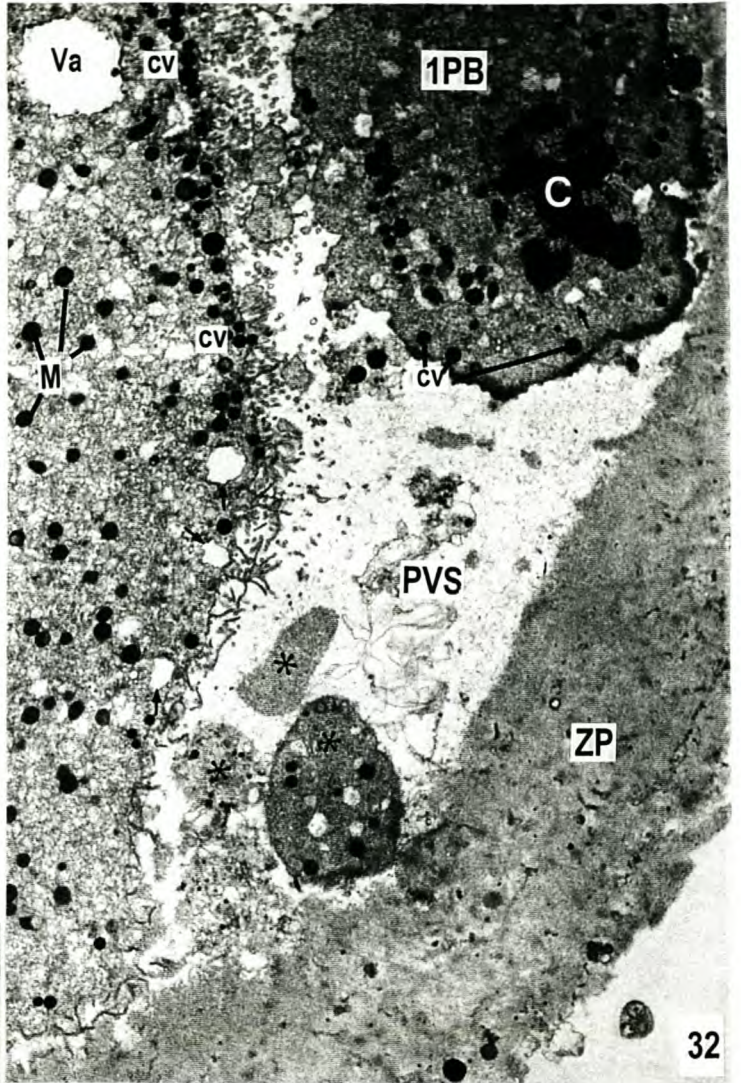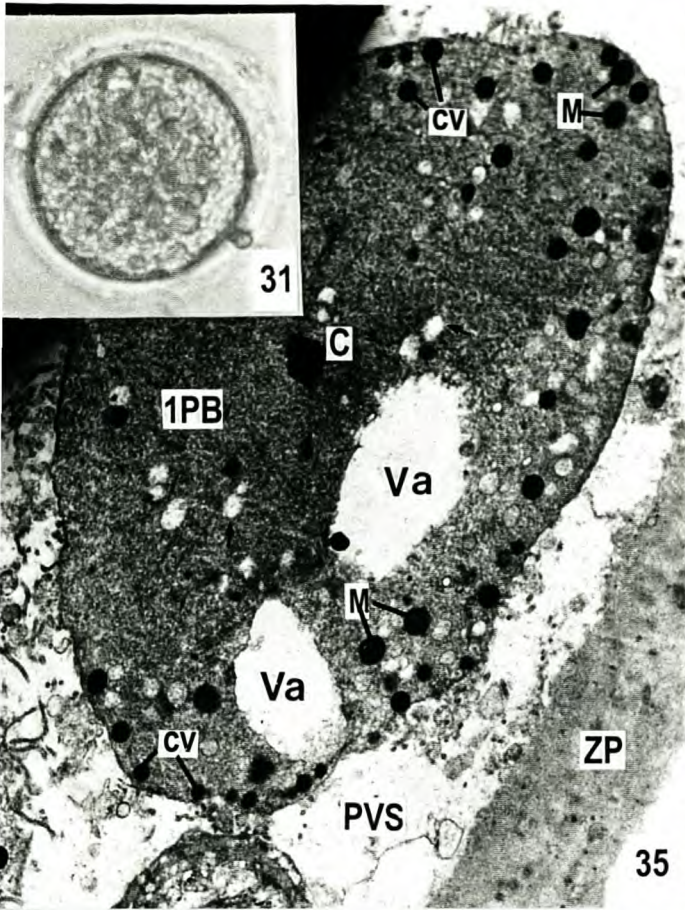
### ***Ultrastructure of multivacuolated mature metaphase II oocyte:***

**Figure 32.** The ooplasm shows normal, intact small dense cortical vesicles, but the smooth endoplasmic reticulum (SER) does not show aggregates of tubules nor the SER large vesicles surrounded by mitochondria. The SER is arranged into numerous small vesicles (**arrows**), and mitochondria (**M**) appear isolated or occasionally associated with the small vesicles. The first polar body (**1PB**) and its fragments (\*) are shown in the perivitelline space (**PVS**). The 1PB shows the same cytoplasmic constitution as in the oocyte. **ZP**, zona pellucida, **C**, condensed chromosomes of the 1PB. **Va**, SER vacuoles X 6 000.

**Figure 33.** Large SER vacuoles (**Va**) appear filled with a fine fibrillar material and by myelin-like dense structures (**ML**) at their periphery. **CV**, cortical vesicles, **OC**, oocyte cortex, **ZP**, zona pellucida X 3 000.

**Figure 34.** Large SER vacuoles (**Va**) with fibrillar (\*) and the myelin-like dense structures (**ML**) inside the vacuoles. **M**, mitochondria. X 4 500.

**Figure 35.** The **1PB** also contains large SER vacuoles (**Va**), this implicates that the abnormal ooplasm existed before meiosis. **PVS**, perivitelline space; **ZP**, zona pellucida; **CV**, cortical vesicles; **M**, mitochondria; **arrows**, small vesicles. X 9 000.





## **Abnormal oocytes**

**Figure 36.** Light microscopic view (inverted, phase contrast) of an oocyte with a "**refractile body**". The oocyte was micro-injected (ICSI), but failed to fertilize. **1PB**, first polar body; **arrows**, refractile body. X100 and X200, respectively.

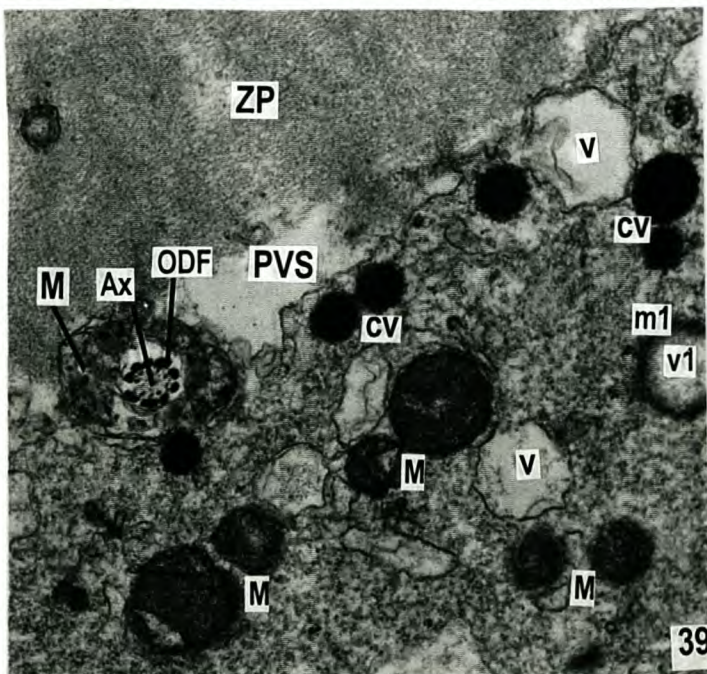
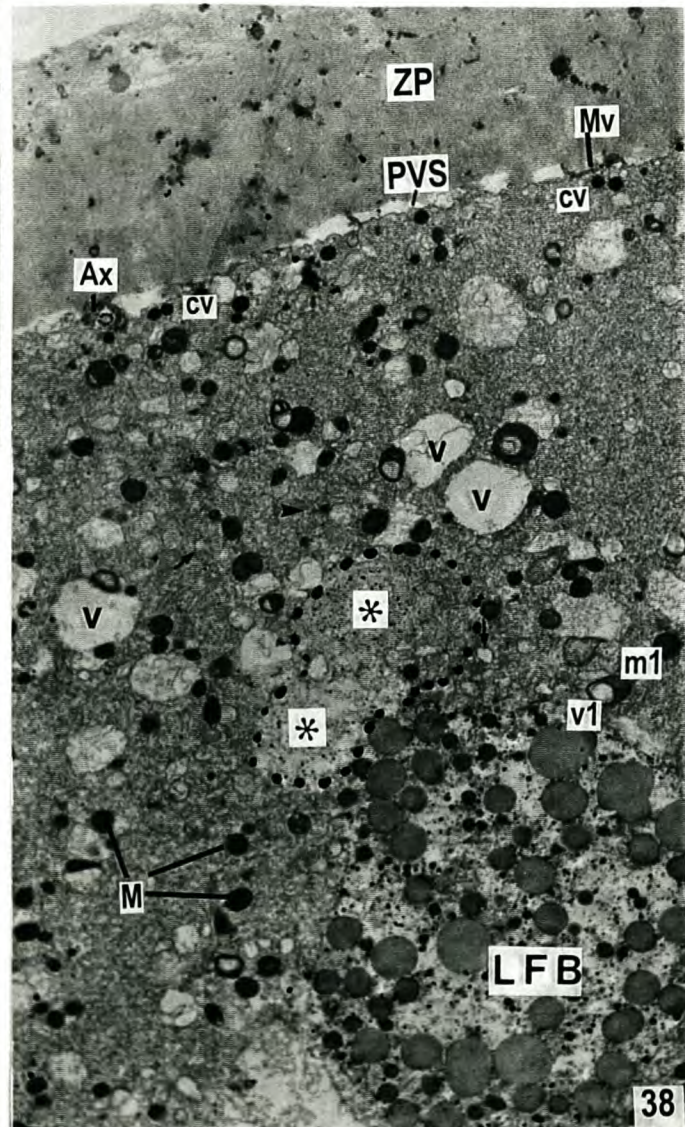

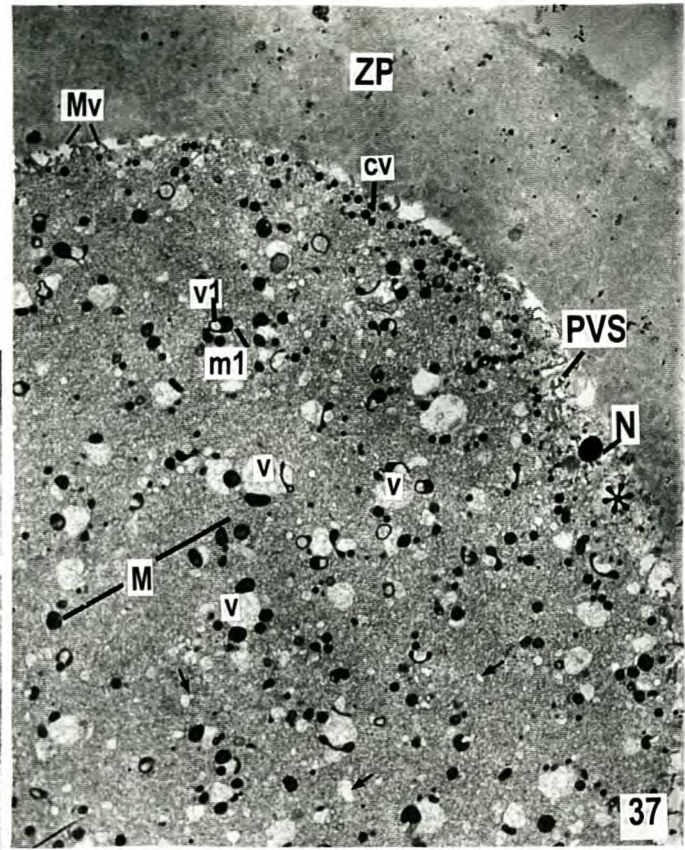
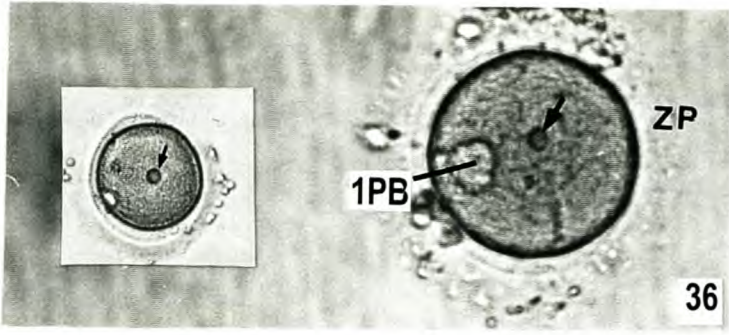
### ***Ultrastructure of an unfertilized (ICSI) metaphase II oocyte with a refractile body:***

**Figure 37.** The oocyte does not show any sign of activation, presenting intact dense small cortical vesicles (**CV**), SER large vesicles (**V**), SER small vesicles (**v1**) encircled by flattened crescent-shaped mitochondria (**m1**) and SER small vesicles (**arrows**). The dense nucleus (**N**) of the injected spermatozoon together with some ooplasm (\*) is found in the perivitelline space (**PVS**). Fertilization failure was therefore caused by the extrusion of the injected spermatozoon. **Mv**, microvilli; **ZP**, zona pellucida, **M**, mitochondria. X 4 500.

**Figure 38.** In the sub-cortical region of the same oocyte a large secondary lysosome filled with multiple small lipid droplets is found (lipofuscin body (**LFB**)). The LFB is also called a "refractile body". A pouch of oolemma (**dashed line**) filled with ooplasm (\*) above the LFB indicates that the channel (invagination) produced by the entering microinjection pipette did not return to its original position. This suggests that the extrusion of the injected spermatozoon was caused by collision against the LFB (injection of oocytes containing refractile bodies should be performed avoiding such a collision). In the PVS, the axoneme (**Ax**) of the injected spermatozoon can be observed. **Arrowheads**, SER isolated small tubules, **CV**, cortical vesicles, **V**, large vesicles, **v1**, small vesicles encircled by flattened crescent-shaped mitochondria (**m1**), SER small vesicles (**arrows**), **PVS**, perivitelline space, **Mv**, microvilli, **ZP**, zona pellucida, **M**, mitochondria. X 9 000.

**Figure 39.** A higher magnification with the middle piece of the spermatozoon (**M**, mitochondria, **ODF**, outer dense fibres, **Ax**, axoneme) in the PVS. **v1**, small vesicles encircled by flattened crescent-shaped mitochondria (**m1**), **ZP**, zona pellucida, **PVS**, perivitelline space, **V**, large vesicles, **M**, mitochondria, **CV**, cortical vesicles. X 36 000.

**Figure 40.** Oolemma pouch (retention of the invaginated oocyte cytoplasmic membrane), filled with ooplasm (\*), spermatozoon remnants (\*\*), and microvilli (**double arrows**). These structures are found between the LFB and the PVS, demonstrating that crushing against the refractile body caused spermatozoon extrusion. **ZP**, zona pellucida, **V**, large vesicles, **v1**, small vesicles encircled by flattened crescent-shaped mitochondria (**m1**) and SER small vesicles (**arrows**), **M**, mitochondria, **arrowheads**, SER isolated small tubules, **LFB**, lipofuscin body, **CV**, cortical vesicles, **T**, aggregates of tubules. X 6 500.



## **Abnormal oocytes**

**Figure 41.** A light microscopic view (inverted, phase contrast) of an abnormal **fragmented oocyte**. Note the pear-shaped zona pellucida (ZP) and the oocyte fragments (three (a,b,c) of four fragments can be observed). X 200.

### ***Ultrastructure of an abnormal, fragmented oocyte:***

**Figure 42.** Section through the major oocyte fragment with several small fragments (\*) in the perivitelline space (PVS). The major fragment represents the oocyte itself. Cortical vesicles are absent, and the smooth endoplasmic reticulum (SER) is disarranged. The SER shows no aggregates of tubules or the large vesicles associated with mitochondria. The SER is arranged into two major types of vesicles: the small vesicles (**arrows**) and the large vacuoles (**Va**). Vacuoles appear filled with a fine fibrillar material. **1PB**, first polar body. **ZP**, zona pellucida, **FC**, follicular cells, **M**, mitochondria X 3 000.

**Figure 43.** Small oocyte fragment (\*) exhibiting the same organelles found in the oocyte, except vacuoles. **M**, mitochondria, **ZP**, zona pellucida, (**arrows**) small vesicles, **PVS**, perivitelline space, **Mv**, oocyte microvilli. X 6 000

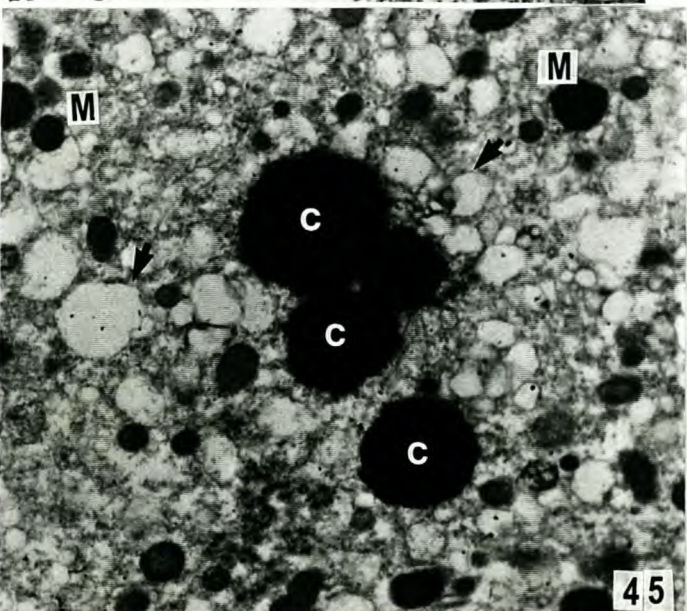
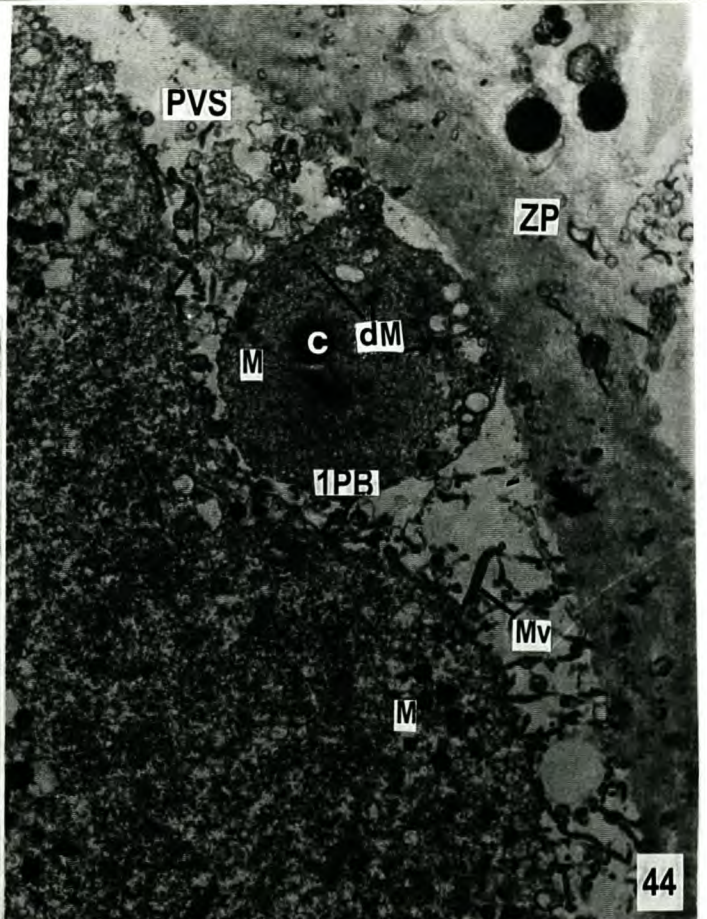
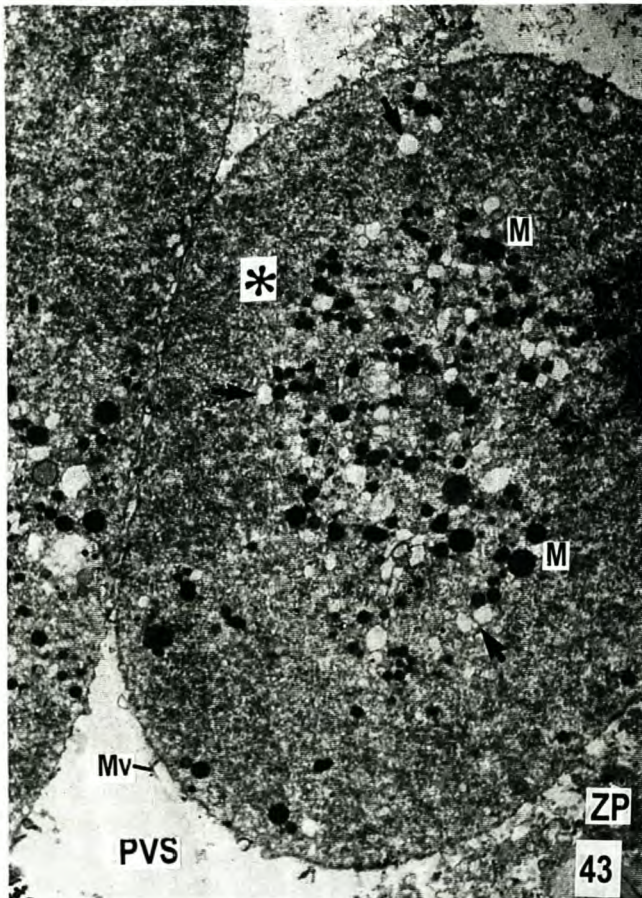
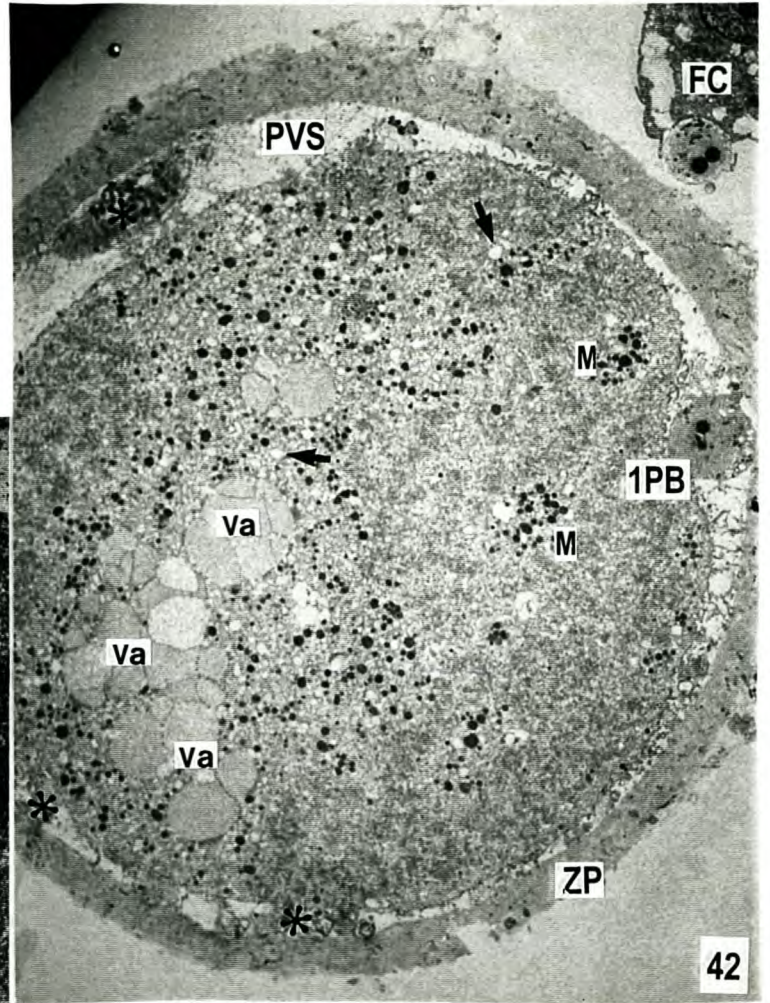
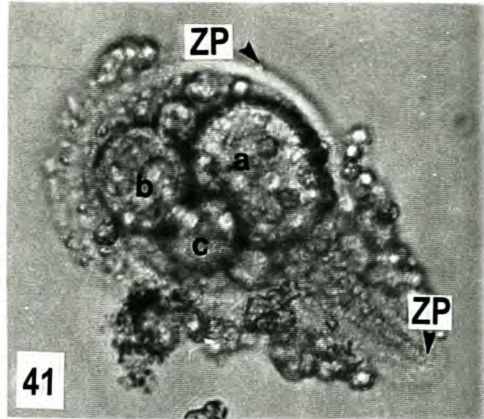
**Figure 44.** The first polar body (**1PB**) exhibiting the same organelles found in the oocyte, except vacuoles. It also shows normal (**M**) and degenerated (**dM**) mitochondria. The chromatin is condensed into large round dense masses (**C**). **M**, mitochondria, **ZP**, zona pellucida, (**arrows**) small vesicles, **PVS**, perivitelline space, **Mv**, oocyte microvilli. X 10 000.

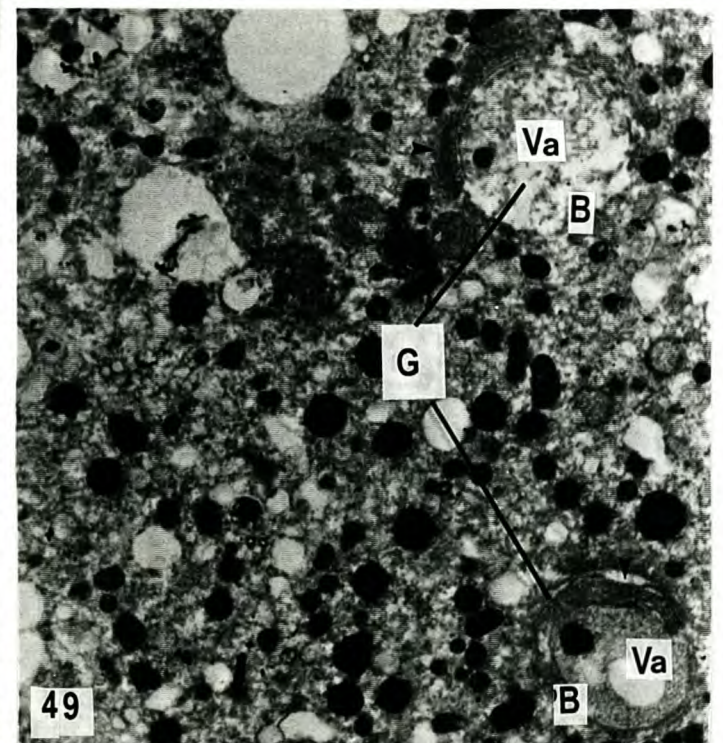
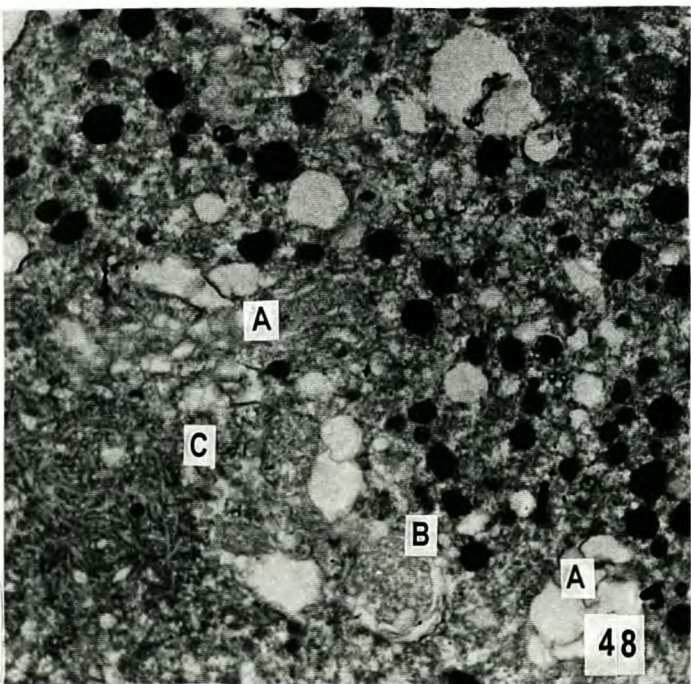
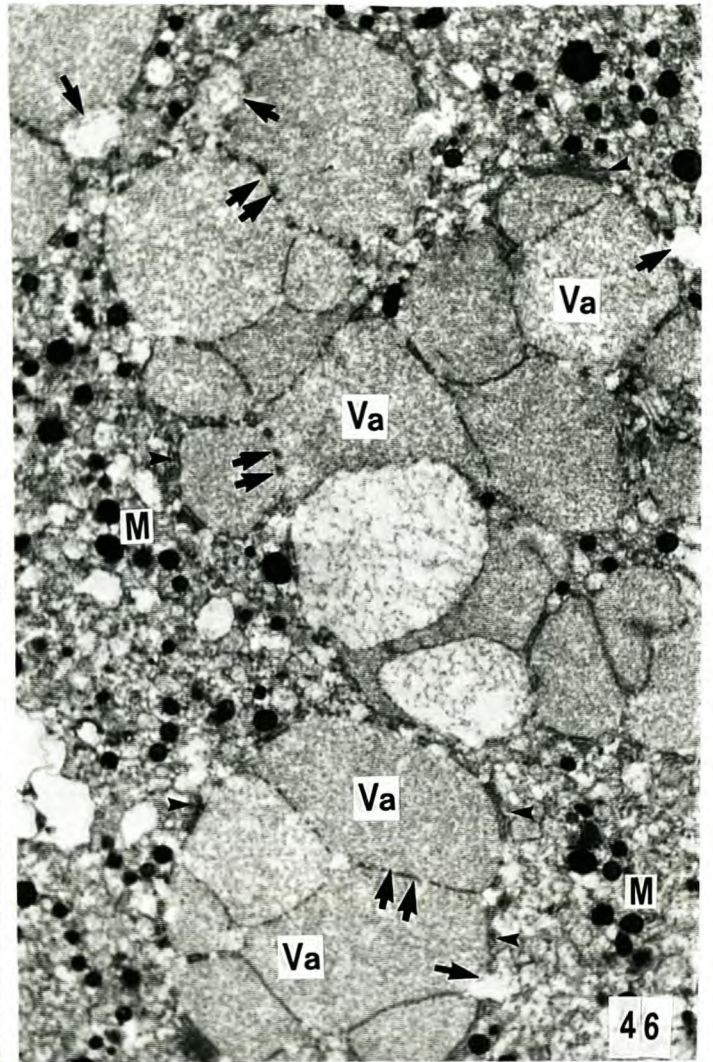
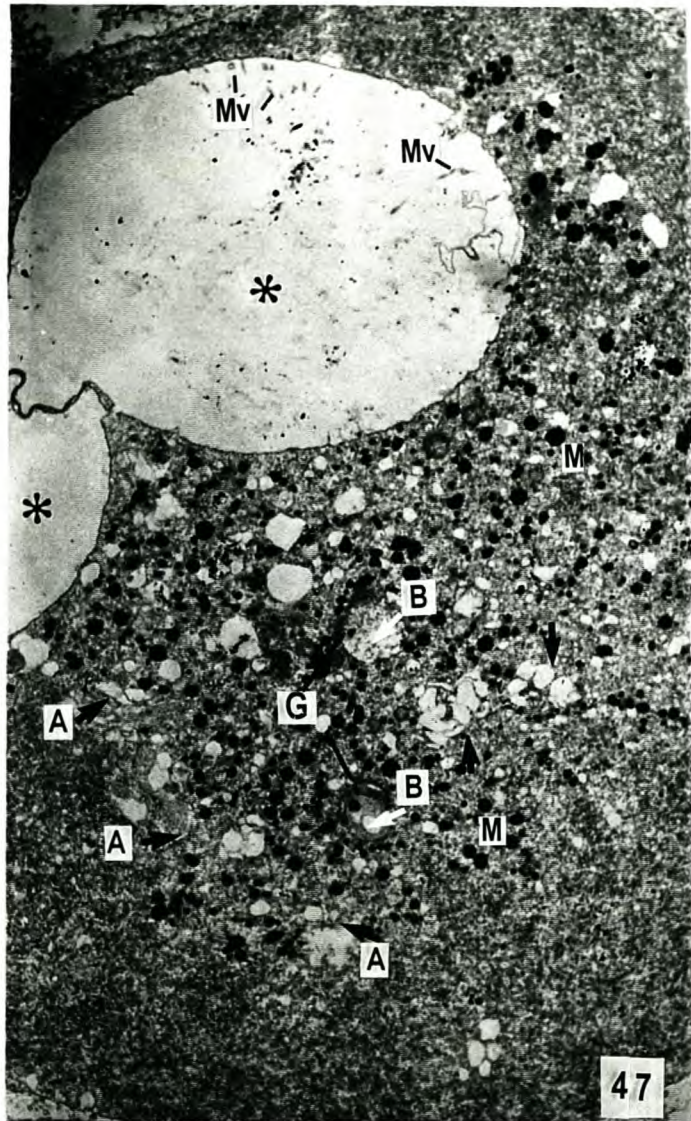
**Figure 45.** Female oocyte chromosomes appear as round dense masses (**C**) similar to that of the 1PB. **M**, mitochondria, (**arrows**) small vesicles. X 18 000.

**Figure 46.** Aggregates of vacuoles (**Va**) in the ooplasm. Note that vacuoles are surrounded by packed tubules (**arrowheads**). Vacuoles show a discontinuous limiting membrane. At the points where the membrane appears interrupted, they are fusing with small SER vesicles (**arrows**) or with other vacuoles (**double arrows M**, mitochondria. X 10 500.

**Figure 47.** The major oocyte fragment, showing two deep oolemma invaginations (\*) diagnosed by its empty structure and by the presence of microvilli (**Mv**). In the ooplasm, the two major origins of vacuoles (**Va**) can be observed: (**A**) fusion between SER small light vesicles (**arrows**), and (**B**) vacuole formation by Golgi complexes (**G**). **M**, mitochondria. X 4 500.

**Figure 48 & 49.** A higher magnification of the previous ooplasmic region. Note (**B**) that the stacks of tubules (**arrowheads**) form the Golgi complex (**G**), and that at its trans face a vacuole (**Va**) is forming. Also note vacuole formation from the fusion between small SER vesicles (**A**). In some regions, both types (**A and B**) of vacuole formation appear intermingled (**C**). X 12 000.





## References

- Balaban, B., Urman, B., Sertac, A. *et al.* (1998) Oocyte morphology does not affect fertilization rate, embryo quality and implantation rate after intracytoplasmic sperm injection. *Hum. Reprod.*, **13**, 3431-3433.
- Ballesteros, A., Carneiro, P., Amorochio, B. *et al.* (1998) The relationship between oocyte morphology and ICSI outcome. *Fertil. Steril.*, **70**, (suppl.1), P-979.
- Bedford, J.M. and Kim, H.H. (1993) Sperm-egg binding patterns and oocytes cytology in retrospective analysis of fertilization failure *in vitro*. *Hum. Reprod.*, **8**, 453-463.
- Bergère, M., Selva, J., Volante, M. *et al.* (1995) Cytogenetic analysis of uncleaved oocytes after intracytoplasmic injection. *J. Assis. Reprod. Genetics*, **12**, 322-325.
- De Sutter, P., Dozortsev, D., Qian, C. *et al.* (1996) Oocyte morphology does not correlate with fertilization rate and embryo quality after intracytoplasmic sperm injection. *Hum. Reprod.*, **11**, 595-597.
- Dozortsev, D., Rybouchkin, A., De Sutter, P. *et al.* (1995) Human oocyte activation following intracytoplasmic injection: the role of the sperm cell. *Hum. Reprod.*, **10**, 403-407.
- Dozortsev, D., Qian, C., Ermilov, A. *et al.* (1997) Sperm-associated oocyte-activating factor is released from the spermatozoon within 30 minutes after injection as a result of the sperm-oocyte interaction. *Hum. Reprod.*, **12**, 2793-2796.
- Flaherty, S.P., Payne, D., Swann, N.J. *et al.* (1995a) Aetiology of failed and abnormal fertilization after intracytoplasmic sperm injection. *Hum. Reprod.*, **10**, 2623-2629.
- Flaherty, S.P., Payne, D., Swann, N.J. *et al.* (1995b) Assessment of fertilization failure and abnormal fertilization after intracytoplasmic sperm injection. *Reprod.Fertil. Dev.*, **7**, 197-210.
- Guthauser, B., Frydman, N., Rodrigues, D. *et al.* (1998a) Oocyte morphology is not related to the low success of intracytoplasmic sperm injection (ICSI) for unexplained failure of conventional *in vitro* fertilization. *Fertil. Steril.*, **70**, (suppl.1), P-367.
- Guthauser, B., Rodrigues, D., Hamamah, S. *et al.* (1998b) Influence of oocyte morphological appearance on fertilization rate and embryo quality after intracytoplasmic sperm injection (ICSI). *Fertil. Steril.*, **70**, (suppl.1), P-368.
- Joris, H., Nagy, Z., Van de Velde, H. *et al.* (1998) Intracytoplasmic sperm injection: laboratory set-up and injection procedure. *Hum. Reprod.*, **13**, (Suppl. 1) 76-86.
- Moon, S.Y., Jung, B.J., Jee, B.C. *et al.* (1998), Assessment of oocyte morphology, oolemma breakage, and suction types as a predictor of normal fertilization after ICSI. *Fertil. Steril.*, **70**, (suppl.1), P-323
- Ng, S-C., Liow, S-L., Sathanathan, H. *et al.* (1993) Review: Microinjection of human sperm directly into human oocytes. *J. Assis. Reprod. Genetics*, **10**, 337-352.
- Palermo, G., Alikani, M., Bertoli, M. *et al.* (1996) Oolemma characteristics in relation to survival and fertilization patterns of oocytes treated by intracytoplasmic sperm injection. *Hum. Reprod.*, **11**, 172-176.
- Palermo, G.D., Avrech, O.M., Colombero, L.T. *et al.* (1997) Human sperm cytosolic factor triggers  $Ca^{2+}$  oscillations and overcomes activation failure of mammalian oocytes. *Mol. Hum. Reprod.*, **3**, 367-374.
- Rattanachaiyanont, M., Léveillé, M.-C. and Leader, A. (1998) Oocyte characteristics have effect on the outcomes of intracytoplasmic sperm injection. *Fertil. Steril.*, **70**, (suppl.1), P-967.
- Schmiady, H., Tandler-Schneider, A. and Kentenich, H. (1996) Premature chromosome condensation of the sperm nucleus after intracytoplasmic sperm injection. *Hum. Reprod.*, **11**, 2239-2245.

Serhal, P.F., Ranieri, D.M., Kinis, A. *et al.* (1997) Oocyte morphology predicts outcome of intracytoplasmic sperm injection. *Hum. Reprod.*, **12**, 1267-1270.

Van Blerkom, J. (1993) Human oocyte maturation and fertilization I and II. *Twenty-sixth annual postgraduate course: Course XI: Contemporary methods of sperm, oocyte, and embryo morphology assessment*. Am. Fert. Soc. Montreal, Canada (October 9-14), 121-133.

Van Wissen, B. and Bomsell-Helmreich, O. (1994) DNA fluorescence revealing oocyte quality, sperm behaviour, during gamete interaction, and embryo morphology. *Ass. Reprod. Reviews*, **4**, 128-133.

Van Wissen, B., Eisenberg, C., Debey, P. *et al.* (1992) In vitro DNA fluorescence after in vitro fertilization (IVF) failure. *J. Assis. Reprod., Genetics*, **9**, 564-571.

Veeck, L. (1991) Abnormal morphology of the human oocyte and conceptus. In: *Atlas of the human oocyte and early conceptus. Volume 2*, pp.151-179.

Veeck, L. (1999) Abnormal morphology of the human oocyte and conceptus. In; *An atlas of human gametes and conceptuses. An Illustrated Reference for assisted Reproductive Technology*. pp. 57-68.

Xia, P. (1997) Intracytoplasmic sperm injection: correlation of oocyte grade based on polar body, perivitelline space and cytoplasmic inclusions with fertilization rate and embryo quality. *Hum. Reprod.*, **12**, 1750-1755.

## TRANSMISSION ELECTRON MICROSCOPIC (TEM) EVALUATION OF OOCYTES ARRESTED AT METAPHASE I. A CASE STUDY

**Windt M-L**  
**Coetzee K**  
**Kruger TF**  
**Marino H**

Reproductive Biology Unit, Department of Obstetrics and Gynaecology, University of Stellenbosch, Tygerberg Hospital, TYGERBERG, South Africa.

**Sousa M**

Laboratory of Cell Biology, Institute of Biomedical Sciences, University of Porto, PORTO, Portugal.

**Kitshoff MS**

Diagnostic Electron Microscopy Unit, Department of Anatomical Pathology, University of Stellenbosch, Tygerberg Hospital, TYGERBERG, South Africa.

### Abstract

Oocytes are normally assumed to reach full fertilization competence only after meiotic and cytoplasmic maturation has been completed. The inherent variability of nature, however often not only causes non-synchronous oocyte maturation, leading to a heterogeneous population of oocytes (prophase I, metaphase I, metaphase II), but also numerous anomalies in the genetic and cytoplasmic maturation process. This gives rise to a small, but important group of patients with unexplained infertility. In the present study we used transmission electron microscopy (TEM) to examine a patient's oocytes that suffer from possible recurring genetic maturation arrest. On more than one occasion, none of the oocytes obtained showed any evidence of polar body extrusion, even after extensive in vitro incubation (maturation).

The couple, with 5 years history of infertility, was treated in our clinic. Routine investigation in the female showed elevated prolactin levels, normal CT scan, normal female chromosomal complement, but consistent non-fertilization and negative pregnancy outcome after artificial insemination (AI), gamete intrafallopian transfer (GIFT) and in vitro fertilization (IVF). Two intracytoplasmic sperm injection (ICSI) cycles were finally performed and three unfertilized oocytes were processed for TEM. A modified TEM method for single cells was used. The 4 spermograms performed on the husband's semen sample revealed persistent teratozoospermia.

All oocytes (n=17) in both ICSI cycles were at the metaphase I stage and failed to mature in vitro. ICSI resulted in total non-fertilization and no cleavage was seen after 3 days of incubation. TEM of two of the unfertilized oocytes showed an almost identical ultrastructure. The main abnormality observed was related to the metaphase spindle. Microtubules appeared to be absent, chromosomes were dispersed (not aligned with evident centromeres) with some situated outside the spindle region. Numerous mitochondria and small smooth endoplasmic reticulum vesicles also abnormally invaded the spindle region.

Oocytes were unable to mature because of the absence of the female metaphase I spindle. We can only postulate that this can be due to abnormalities in tubulins, enzymes, microtubule-associated proteins or the proteins of the microtubule polymerizing centre. Treatment options for this patient is unfortunately limited since the couple is not comfortable with oocyte donation. The only means of treating this patient to have genetically related offspring would be by donor cytoplasm transfer or germinal vesicle transfer into donor oocytes. Unfortunately results from these techniques are still preliminary.



## Introduction

The objective of exogenous hormone administrations used routinely for ovarian hyperstimulation in *in vitro* fertilization programmes is to produce a large cohort of mature follicles. The induction of meiotic maturation of the contained oocytes is accomplished either in response to an endogenous luteinizing hormone surge or to the administration of human chorionic gonadotropins. Meiosis is a complex process that involves both progressive and stage-specific events at the nuclear and cytoplasmic levels, including germinal vesicle breakdown, formation of metaphase structures, chromosomal condensation, polar body extrusion and not least of all cytoplasmic maturation (Van Blerkom *et al.*, 1994). Oocytes are normally assumed to reach full fertilization competence only after this meiotic and cytoplasmic maturation has been completed. The inherent variability of nature, however often not only causes non-synchronous oocyte maturation, leading to a heterogeneous population of oocytes (prophase I, metaphase I, metaphase II), but also numerous anomalies in the genetic and cytoplasmic maturation process. Some of these anomalies can result in unexplained infertility, not detectable with routine observations through the inverted microscope.

The routine performance of intracytoplasmic sperm injections (ICSI) has provided the opportunity to evaluate oocytes more accurately because of denudation, prior to injection. Using light microscopy (inverted) some of the genetic subgroups and to a lesser extent cytoplasmic subgroups, can be identified. In the present study we use transmission electron microscopy (TEM) to examine a patient's oocytes that suffer from possible recurring genetic maturation arrest, perhaps the reason for her unexplained infertility problem. None of the oocytes obtained showed any evidence of polar body extrusion even after extensive *in vitro* incubation (maturation) on more than one occasion.

## Case report

In 1995, the couple first presented with primary infertility of 1 year and 3 months duration. Infertility investigations revealed normal female (laparoscopy) and male (clinical evaluation) genitalia. The wife had regular menstrual periods with a cycle length of 28-32 days. She did, however, regularly present with elevated levels of prolactin (35-45 ng/ml), however computerized tomography (CT) showed a normal pituitary fossa. She was consequently placed on 2.5mgs of Parlodel (Novartis) per day. In 1998 a chromosomal analysis (idiogramme and karyotype) was performed on cultured lymphocytes indicating a normal female chromosomal complement (46,XX). The 4 spermograms performed on the husband's semen sample revealed persistent teratozoospermia (G pattern) (Table 1).

Three unsuccessful intrauterine inseminations were performed in 3 consecutive spontaneous cycles in our clinic during the period August to November 1995. An additional three unsuccessful assisted reproductive cycles were performed in 1996 at another fertility clinic showing total fertilization failure of inseminated/injected oocytes (Table 2). The couple returned to our clinic in 1998 and it was decided to continue treatment with ICSI. Following pituitary desensitization (Synarel ®, Searle, South Africa, long protocol) ovarian hyperstimulation was performed with human menopausal gonadotropin (Pergonal, Serono, South Africa). Human chorionic gonadotropin (Profasi, Serono, South Africa) was administered when two follicles had reached a size >17mm. Nine oocytes were recovered from transvaginal (sonographical) needle aspirates. A second ICSI was performed in 1999 using the same stimulation protocol as before. The patient

was 34 years of age at the time of this last procedure. Eight oocytes (MI) were recovered. The ICSI was performed according to our standard protocol using Medicult (HarriLabs, South Africa) media for manipulations and culture.

**Table 1**  
**Summarized spermograms of husband**

Date	Volume (ml)	Concentration X10 <sup>6</sup> /ml	Motility (%)	FP (1-4)	Normal Morphology (%)
November 1994	4.5	50.0	80	3	8
April 1995	3.3	48.0	80	3	10
August 1995	2.4	17.6	50	3	5
August 1998	2.0	51.0	50	2+	4

FP = forward progression on a scale of 1-4 (4 = very fast progressive)

Normal Morphology = normal sperm morphology percentage (normal = >14%)

**Table 2**  
**Details of the assisted reproduction cycles performed.**

Date	Female age	Procedure	Oocytes retrieved	Oocyte maturity	Insem /ICSI	2PN
March 1996	30	GIFT	9 (*4)	Unknown	5	0
May 1996	30	IVF	7	Unknown	7	0
August 1996	30	ICSI	15	Unknown	12	0
November 1998	32	ICSI	9	MI	9	0
April 1999	33	ICSI	8	MI	8	0

\* 4 oocytes were transferred into the fallopian tube

Insem = in vitro insemination

MI = metaphase I

## Results

The oocytes retrieved in the last two cycles (6/11/1999 and 5/4/1999) were denuded 3 hours after their aspiration. No germinal vesicles were present in the resultant 17 denuded oocytes and there was no visual evidence of extruded polar bodies (day 1) for any of the oocytes. All oocytes appeared to be at metaphase I, without any other obvious abnormalities. The oocytes were not injected on the day of aspiration, but were cultured individually in droplets of culture medium under paraffin oil. On day 2 the oocytes were again examined for the presence of polar bodies. No polar bodies were present. After consultation with the couple, the oocytes (n = 9 and n = 8, respectively) were nonetheless injected.

No pronuclei were visible in any of the ova 18 hours after injection. None of the ova showed any sign of cleavage even after 3 days (post injection) of incubation. Two of the unfertilized ova from the last cycle were processed for TEM to investigate the possible underlying ultrastructural anomaly associated with non-extrusion of the first polar body.

The primary abnormalities observed in both ova were biochemical dysfunction of the ooplasm and non-existent spindle microtubules. Oocytes were unable to mature because of the absence of the female metaphase I spindle. We can only postulate that this can be due to abnormalities in tubulins, enzymes, microtubule-associated proteins or the proteins of the microtubule polymerizing centre.

### *Ultrastructure of oocyte 1*

The cytoplasmic characteristics observed were typical of what one would normally associate with an immature metaphase I oocyte (Figures 1 – 4). The main abnormality observed was related to the metaphase spindle. Microtubules appeared to be absent, chromosomes were dispersed (not aligned with evident centromeres) with some situated outside the spindle region. Numerous mitochondria (**M**) and smooth endoplasmic reticulum (small) vesicles (**v**) also abnormally invaded the spindle region (Figures 5 - 7).

Other abnormalities were also observed. The inner 3<sup>rd</sup> of the zona pellucida (**ZPf**) was observed to be abnormally dense (dense bundle of filaments) (Figures 1,3 & 4). The oocyte surface had normal microvilli (**Mv**), but there was shedding of ooplasmic contents (cytoplasmic fragmentation) into the perivitelline space (**PVS**) (Figure 1). Low numbers of peripherally located cortical vesicles (**CV**) and smooth endoplasmic reticulum tubular aggregates (**T**) were present (Figure 2).

Another abnormal feature of this oocyte was the appearance of aggregates of SER small vesicles (**SVA**) in the sub-cortex and cortex. They represent an excess of SER small vesicles possibly related to a biochemical dysfunction and can possibly be related to the observed surface shedding (Figures 3 & 4). Ultra-thin sections did not show the injected spermatozoon

### *Ultrastructure of oocyte 2*

The image obtained for the second oocyte was nearly identical to that of the first oocyte - a metaphase I oocyte unable to mature because of the complete absence of spindle microtubules (Figures 10 & 11). The spindle region was abnormally invaded with cell organelles such as mitochondria (**M**), numerous SER small vesicles (**arrows**) and SER large vesicles (**V**) (Figure 10). Microtubules appeared absent and the female chromosomes (**Ch**) were dispersed and not

aligned and also without evident centromeres and kinetochores. Female chromosomal (**Ch**) material appeared even outside the spindle region. (Figure 11).

The cytoplasm appeared to be mature (segregated) with large smooth endoplasmic reticulum vesicles (**V**) and smooth endoplasmic reticulum tubule aggregates (**T**) concentrated in the peripheral regions (Figures 8 & 9). Small smooth endoplasmic reticulum vesicles (**v1**) occupied the inner cytoplasm region (correctly associated with mitochondria (**m1**)). The cortical vesicles (**CV**) appeared normally dense, but typical of the metaphase I oocyte, are still migrating towards the oolemma (Figure 8).

Similar to the first oocyte, this oocyte's surface had normal microvilli (**Mv**), but there was shedding of ooplasmic contents (cytoplasmic fragmentation) into the perivitelline space (**PVS**) (Figure 9). The inner 3<sup>rd</sup> of the zona pellucida (**ZPf**) was also observed to be abnormally dense and fibrous (Figure 8). It can be postulated that this appearance is induced by shed ooplasmic enzymes.

In the processing of the second oocyte the injected spermatozoon could also be observed (Figure 12 & 13). The sperm nuclear membrane had been lost but decondensation of chromatin was not normal. In this case the decondensation was abnormal and more pronounced in the centre (**A**) than at the periphery (**B**). Decondensation areas also appeared to be blocked at the course chromatin stage with a ladder appearance instead of fine fibrils (Figure 13). This abnormal event could be because of the immaturity of the specific oocyte or to an oocyte anomaly specific to the patient.

## Discussion

Despite controlled administrations of exogenous hormones, used routinely for ovarian hyperstimulation and ovulation in *in vitro* fertilization programmes, the outcomes are never certain with regards to the cytogenetic maturity and/or normality of the resultant oocytes. Oocyte immaturity can be visualised microscopically as the presence of a germinal vesicle and no visible polar body. Immaturity may be overcome with *in vitro* culture, but other cytogenetic anomalies may remain undetected resulting in no fertilization and/or embryogenesis.

Racowsky and Kaufman (1992) studied meiotically immature but normal appearing oocytes retrieved after oophorectomy after culture for 9 – 46 hours. Of the 101 oocyte chromatin configurations analyzed, 71.3% were normal, 11.9% were degenerate and 16.8% displayed meiotic aberrations. The significant majority (88.2%) of the aberrant chromatin configurations were associated with morphologically normal and viable oocytes. Our understanding and detection of these cytogenetic anomalies is severely limited, making the successful treatment of patients suffering from gross cytogenetic anomalies impossible and therefore missing the real reason for these patient's unexplained infertility. In this study we attempted to understand the ultrastructural implications of oocytes that failed to mature further than the metaphase I stage (non-extrusion of the first polar body).

Whereas it may not be that uncommon to have one or two oocytes from a cohort not maturing *in vitro*, it is relatively rare to have a whole cohort suffering from maturity arrest and more so as a recurring phenomenon. Our case, as well as three other published cases, presents findings with regards to this relatively rare phenomenon. In 1990 Rudak *et al.* documented the first cases of patients suffering from idiopathic oocyte maturation disorders. In the cases where no polar bodies

were extruded they speculated that it was an anomaly related to the formation or functioning of the meiotic spindle. Eichenlaub-Ritter *et al.* (1995) investigated a patient whom had undergone 4 unsuccessful in vitro fertilization attempts. All the patient's oocytes showed no signs of a polar body nor pronuclei when examined for fertilization. It was thought in this case that rapid maturation to metaphase II and ageing in vivo before aspiration may have resulted in the degeneration of the polar body. The degenerate metaphase II spindles typical of aged oocytes were probably responsible for the developmental block and the induction of premature chromosome condensation (PCC) of sperm chromatin seen in the patient's oocytes. The authors conclude that the patient suffered from an "unusual asynchrony in follicular, cytoplasmic and chromosomal maturation kinetics". The suggested treatment for this case was earlier oocyte aspiration (Eichenlaub-Ritter *et al.*, 1995). More recently, Hartshorne *et al.* (1999) investigated a similar case of maturation arrest. Two cycles were investigated and in the second cycle the hyperstimulation was changed from a long to a "flare-up" protocol. The cumulus complexes were incubated in medium supplemented with recombinant FSH and HCG for up to 2 days without success (extrusion of polar bodies), as in the previous cycle. They observed that the arrangement of the chromatin of all the oocytes were characteristic of arrest at entry to M-phase. In a study by Kim *et al.* (1998) the important role of microtubules and microfilaments in the reconstruction and proper positioning of chromatin after germinal vesicle breakdown and during meiotic maturation was shown. This implicated that absence or abnormalities in microtubules and microfilaments can influence oocyte maturation.

The two oocytes investigated by us, using TEM, showed signs of persistent cytoplasmic immaturity and the absence of microtubules (essential for spindle formation), despite normal vesicle breakdown and metaphasic chromosome condensation. This state of immaturity was observed even though the oocytes were cultured for 3 days after injection. Two possible reasons for the outcome can be proposed; 1) protein synthesis and polymerization necessary for spindle formation was arrested, or 2) disintegration of the spindle (cytoplasmic post maturity), closely associated with maternal age (40 years old). Since TEM showed the oocytes to be immature and not overmature and our patient was 34 years old at the time, we postulate that the latter reason was not the cause of the absence of microtubules. We conclude that it was possibly due to abnormal tubulins, enzymes or the microtubule polymerizing centre. The presence of a partially decondensed spermatozoon, limited signs of activation and condensation, and incomplete cortical vesicle migration even after 3 days of culture also points to an oocyte unable to activate and be activated. Normal oogenesis requires synchronous follicular, cytoplasmic and chromosomal maturation kinetics to mature to a normal fertilizable metaphase II oocyte. In all probability these complex processes were not synchronous in our patient.

Treatment options for this patient is unfortunately limited since the couple is not comfortable with oocyte donation. The fact that no germinal vesicles were observed in the cycles from our patient, indicates that nuclear and cytoplasmic factors governing germinal vesicle breakdown and chromosome condensation were functioning normally. The affected step seems to be the tubulin and/or biochemical spindle polymerization machinery. Taking into consideration our limited knowledge on the interactions between the nuclear genome and the cytoplasmic factors, the only means of treating this patient to have genetically related offspring, would be by donor cytoplasm transfer or germinal vesicle transfer into donor oocytes.

Unfortunately results from these techniques are still preliminary (Flood *et al.*, 1990; Cohen *et al.*, 1997, 1998; Takeuchi *et al.*, 1998; Zhang *et al.*, 1999) and there are concerns regarding the contribution of mitochondrial DNA from donor oocytes (Tsai *et al.*, 2000).

However, using the TEM method, we were able to find a reason for this couple's unexplained infertility and with the appropriate stimulation protocol (maximise probability of germinal vesicles) and micromanipulation techniques, in future the patient's germinal vesicles could be transferred into donated enucleated oocytes.

### **Acknowledgements**

Sincere thanks to the personnel of the Reproductive Biology Unit Tygerberg Hospital and the theatre personnel of the Tygerberg Hospital; Prof PAB Wranz and his personnel from the Diagnostic Electron Microscopy Unit, Department of Anatomical Pathology, University of Stellenbosch, Tygerberg Hospital

This research was supported by the Harry and Doris Crossley Research Fund, University of Stellenbosch, Tygerberg.

*The results from this study are in preparation for publication in Human Reproduction, 2000.*

## Legends to Figures

### Ultrastructure of Oocyte 1

**Figure 1.** The zona pellucida (**ZP**) appears abnormally dense and narrow and the inner 3<sup>rd</sup> has a fibrous appearance (**ZPf**). The PVS is filled with shed ooplasmic fragments (\*). **V**, SER large vesicles, **v1**, small vesicles encircled by flattened crescent-shaped mitochondria (**m1**), SER small vesicles (**arrows**), **M**, mitochondria, **CV**, cortical vesicles, **FC**, follicular cells, **N**, nucleus. X 4 500.

**Figure 2.** The cytoplasm of the immature metaphase I oocyte. Low numbers of cortical vesicles (**CV**) on the periphery of the oocyte, isolated CV in the oocyte's subcortex, low numbers of SER tubular aggregates (**T**). Normal features include SER large vesicles (**V**), associated mitochondria (**M**), SER small vesicles (**arrows**) either free or associated with crescent-shaped mitochondria (**m1**). X 7 500.

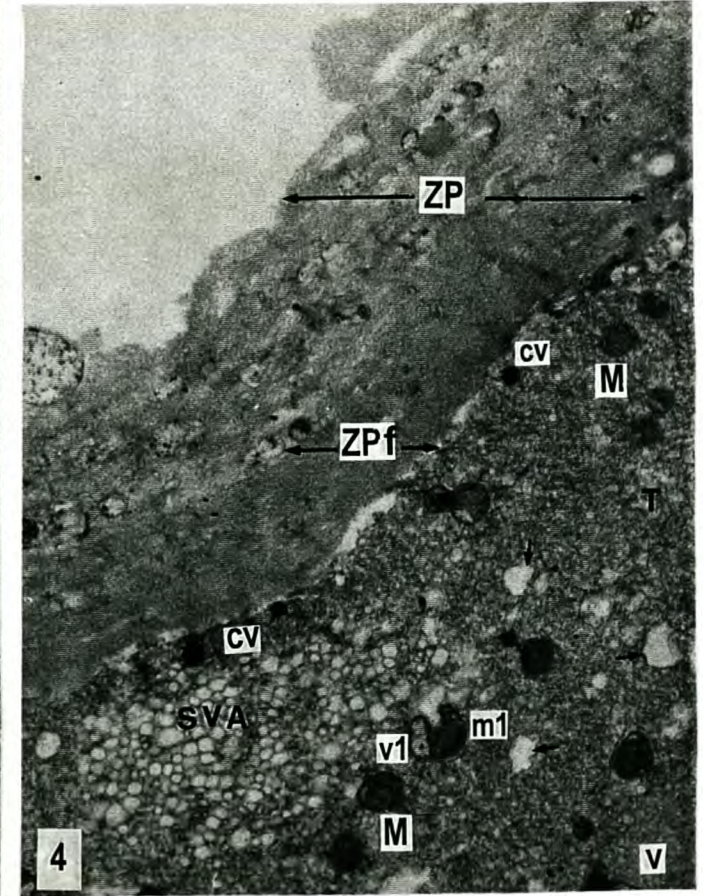
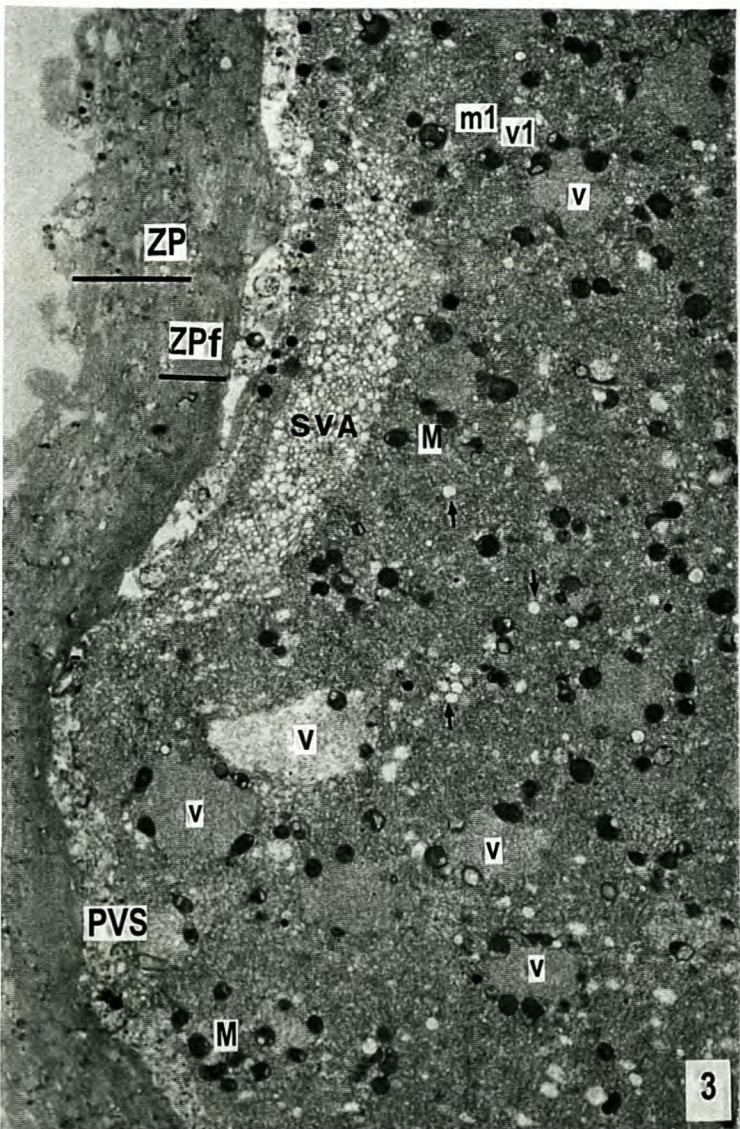
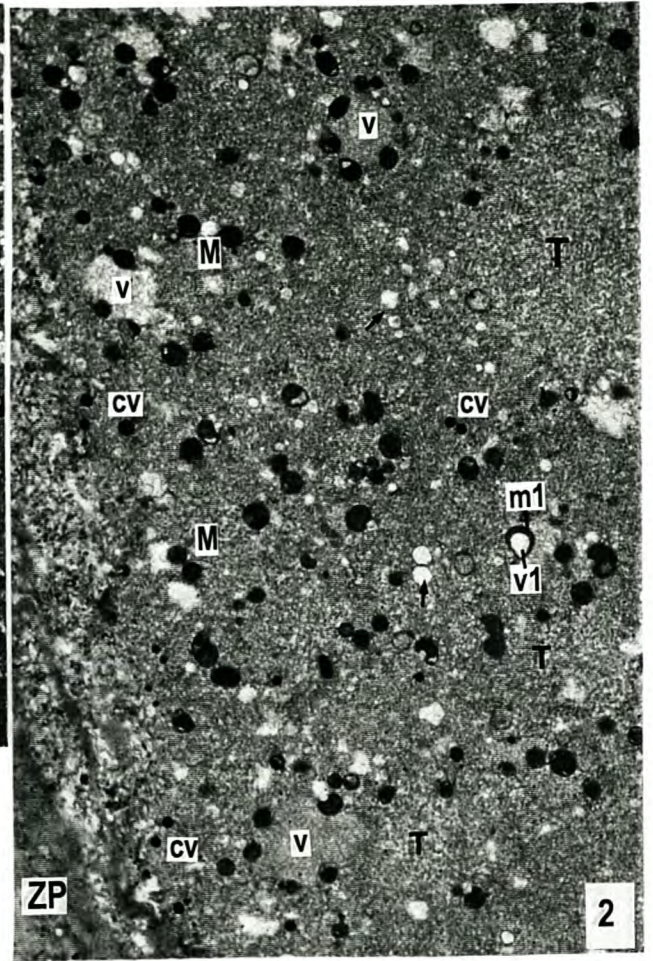

**Figure 3.** An abnormal aggregation of SER small vesicles (**SVA**) and two distinct layers of the zona pellucida (**ZP**) and the inner 3<sup>rd</sup> fibrous ZP (**ZPf**). Other structures appear normal: **V**, SER large vesicles, **v1**, small vesicles encircled by flattened crescent-shaped mitochondria (**m1**) and SER small vesicles (**arrows**), **M**, mitochondria, **CV**, cortical vesicles, **PVS**, perivitelline space. X 7 500

**Figure 4.** A higher magnification to show the two layers of the zona pellucida: normal (**ZP**) and fibrous (**ZPf**) and the aggregation of SER small vesicles (**SVA**). **V**, SER large vesicles, **v1**, small vesicles encircled by flattened crescent-shaped mitochondria (**m1**) and SER small vesicles (**arrows**), **M**, mitochondria, **arrowheads**, SER isolated small tubules, **CV**, cortical vesicles, **T**, aggregates of tubules X 15 000.



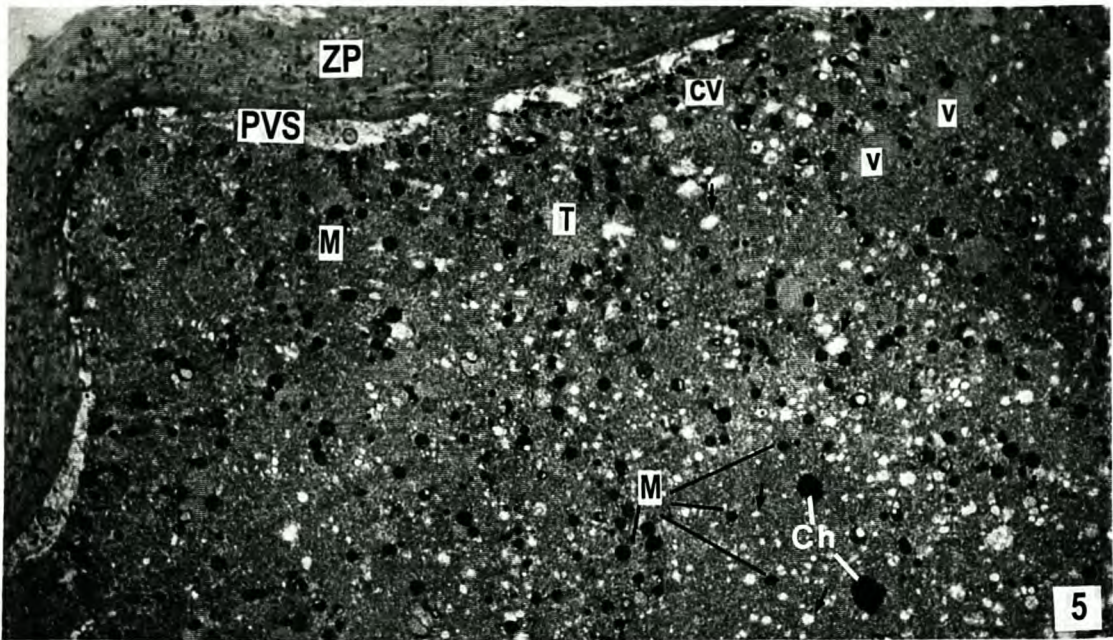
**Figure 5.** The spindle region showing abnormal invasion with cell organellae such as mitochondria and numerous SER small vesicles (**arrows**). Microtubules appear absent and chromosomes (**Ch**) are dispersed and not aligned and also without evident centromeres and kinetochores. **ZP**, zona pellucida, **V**, SER large vesicles, **M**, mitochondria, **CV**, cortical vesicles, **T**, aggregates of tubules, **PVS**, perivitelline space. X 4 500.

**Figure 6.** Another section through the spindle region showing abnormal invasion with cell organellae such as mitochondria (**M**), SER small vesicles (**arrows**) and **v1**, small vesicles encircled by flattened crescent-shaped mitochondria (**m1**). Microtubules appear absent and chromosomes (**Ch**) are dispersed and not aligned. X 6 000

**Figure 7.** Another section through the spindle region. In this image chromosomal (**Ch**) material appeared even outside the spindle region. **V**, SER large vesicles, **M**, mitochondria, SER small vesicles (**arrows**). X4 500.







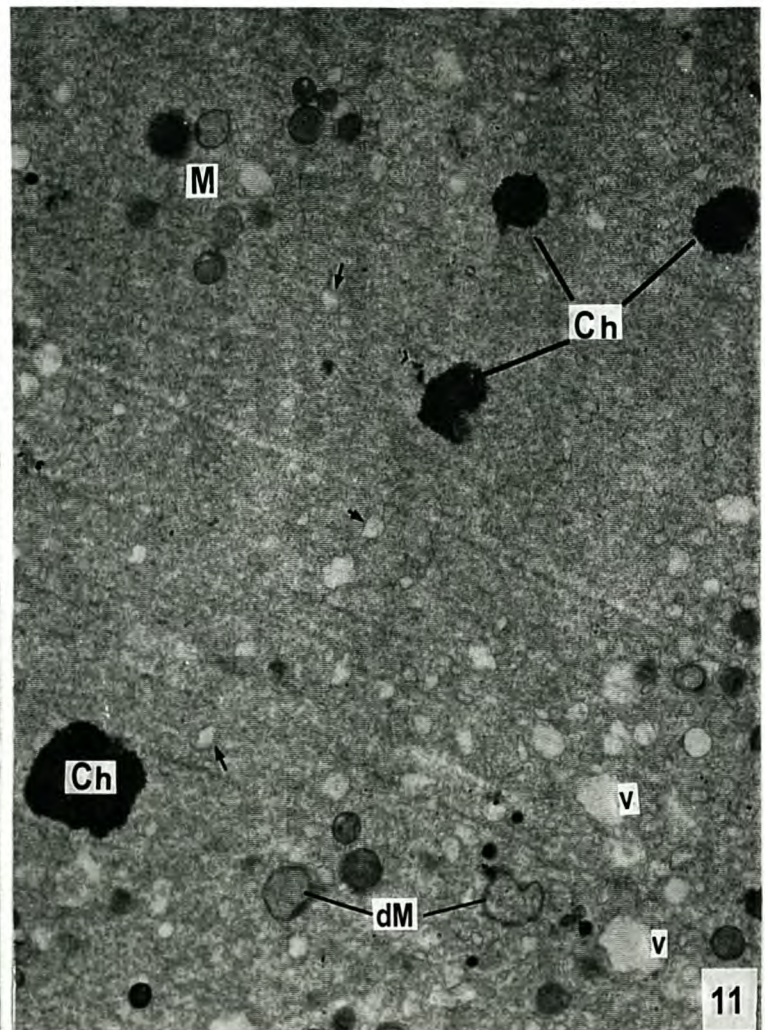
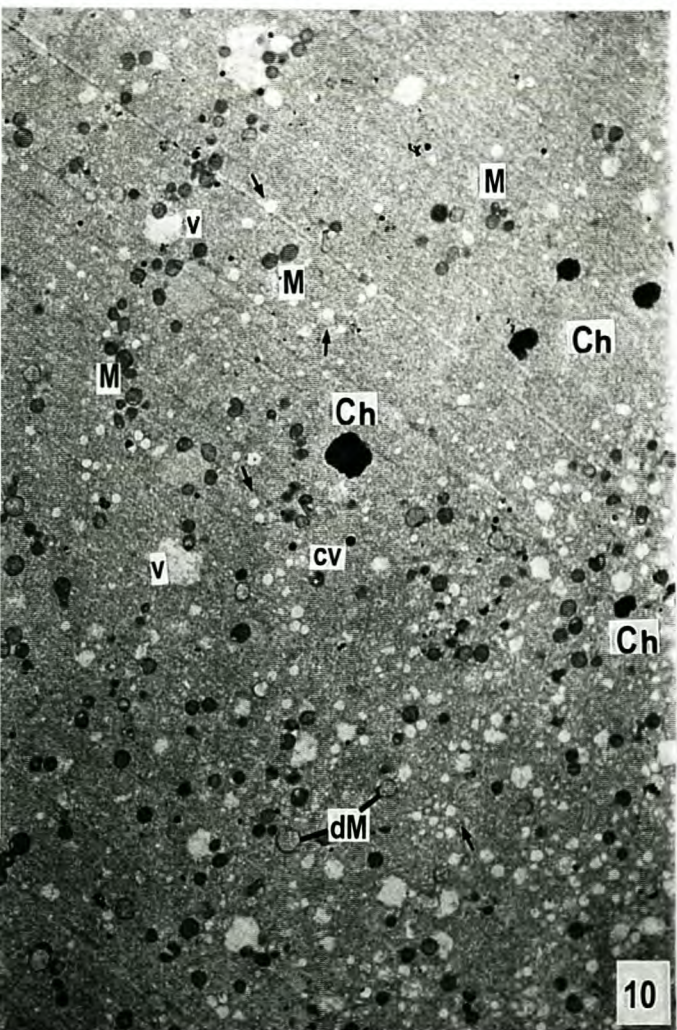
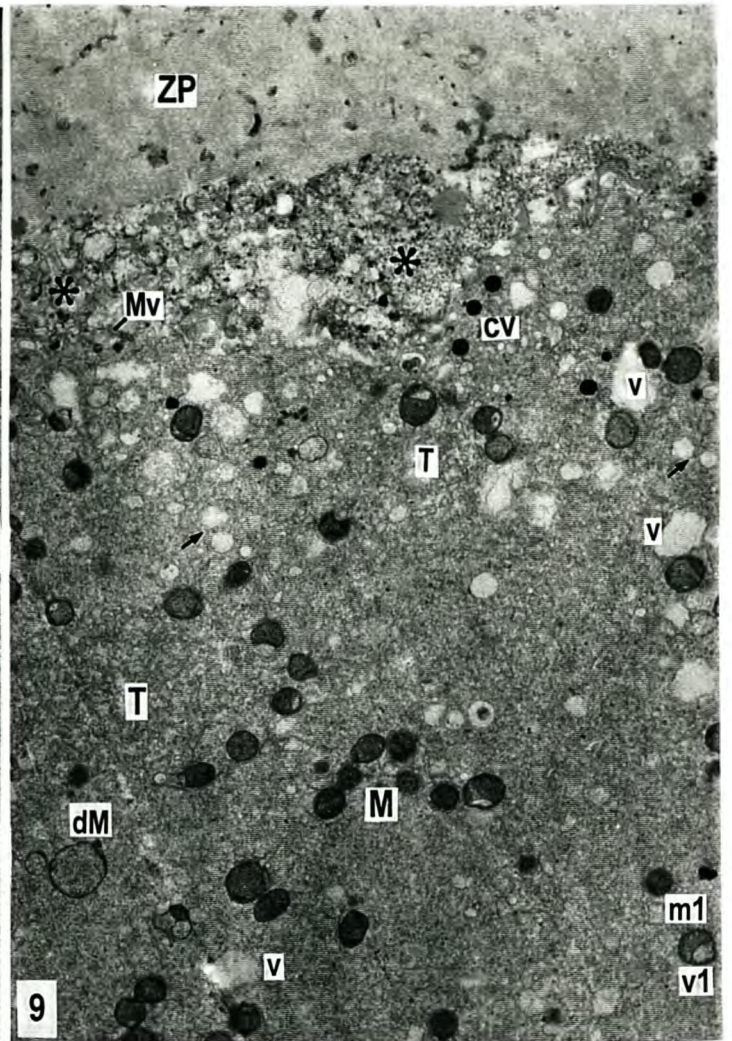
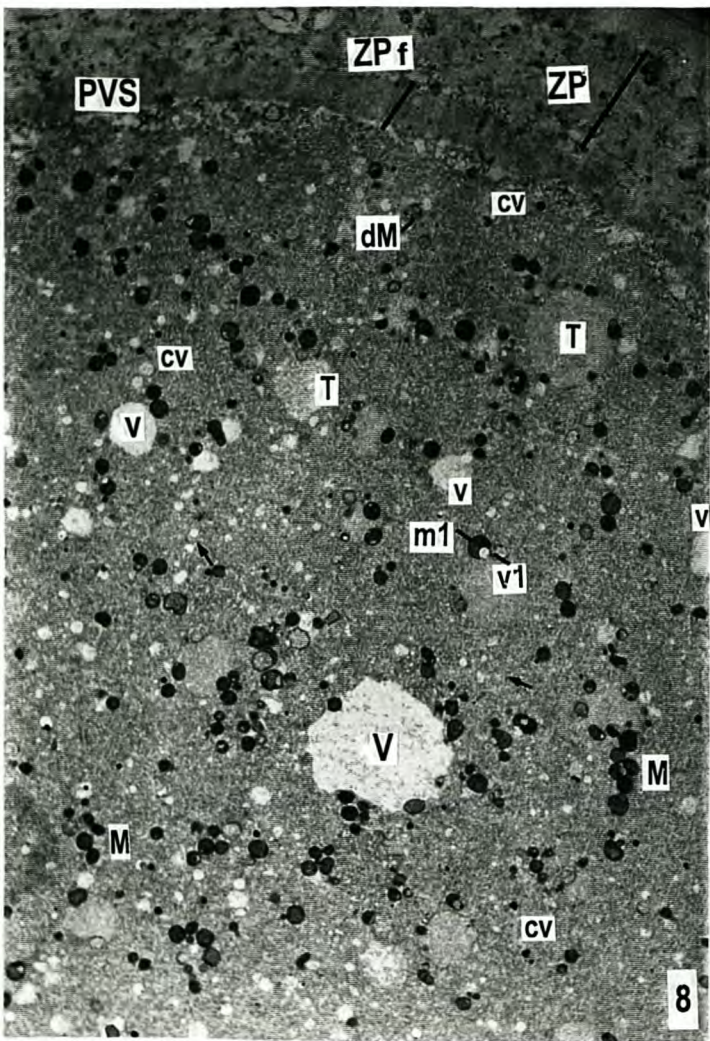
## Ultrastructure of Oocyte 2

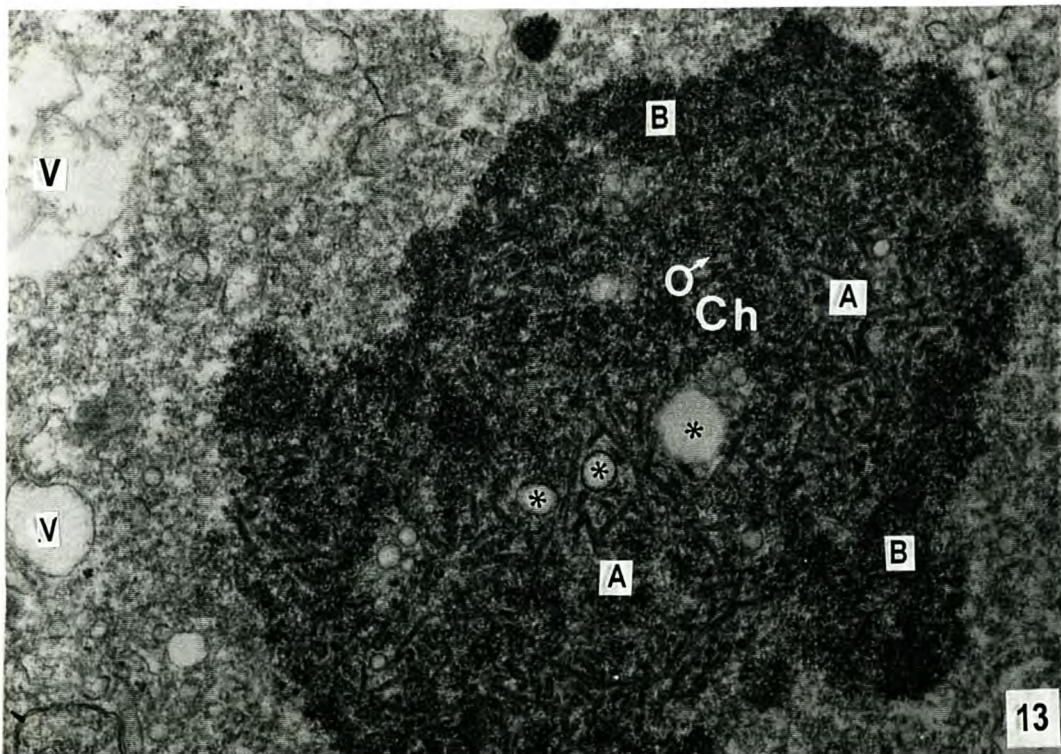
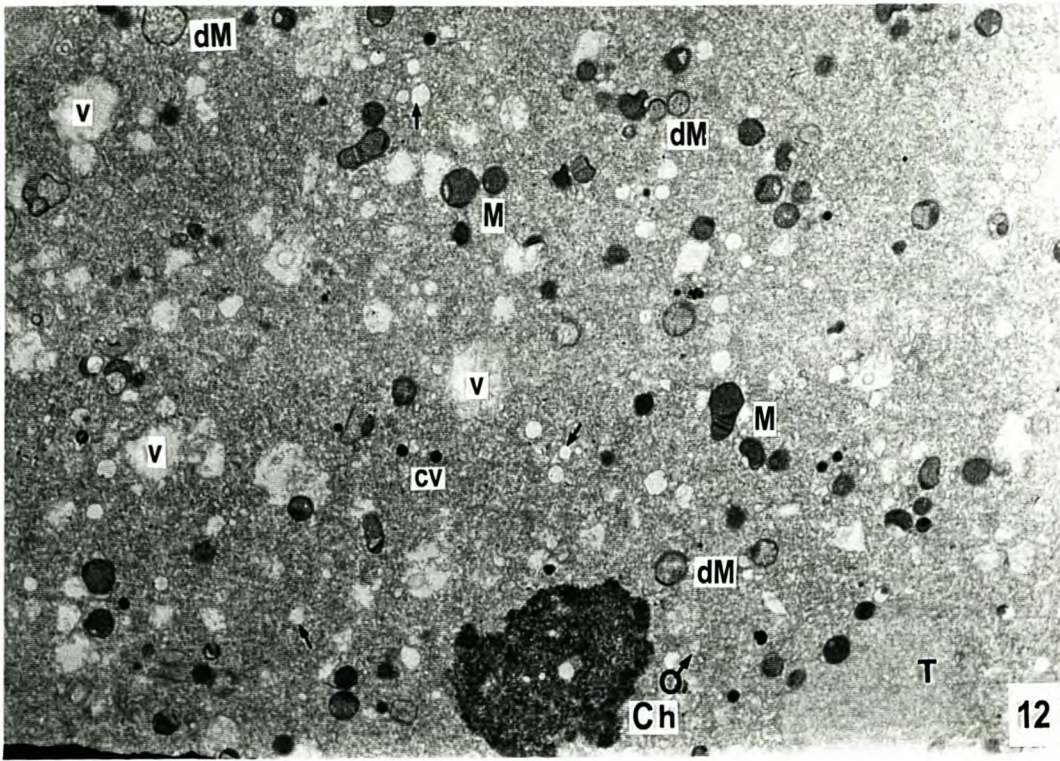
**Figure 8.** The zona pellucida (ZP) is split into two distinct regions. The inner 3<sup>rd</sup> has a fibrous appearance (ZPf), but the outer two thirds appear normal. Note the low numbers of cortical vesicles (CV) on the periphery of the oocyte and isolated CV in the oocyte subcortex still migrating towards the oolemma. This is normal for a metaphase I oocyte. The presence of degenerating mitochondria (dM) is also a normal feature. V, SER large vesicles, v1, small vesicles encircled by flattened crescent-shaped mitochondria (m1), SER small vesicles (arrows), M, mitochondria, SER tubular aggregates (T). X 4 500.

**Figure 9.** The cytoplasm of the metaphase I oocyte. It appears more mature than oocyte 1. Normal features include: low numbers of cortical vesicles (CV) on the periphery of the oocyte, SER tubular aggregates (T), SER large vesicles (V), associated mitochondria (M), SER small vesicles (arrows) either free or associated with crescent-shaped mitochondria (m1). The oocyte has normal microvilli (Mv), but shed ooplasm contents (\*) are found in the PVS filling it with fibrillar materials. X 10 5000.

**Figure 10 and 11.** The spindle region showing abnormal invasion with cell organelles such as mitochondria, numerous SER small vesicles (arrows) and SER large vesicles (V). Microtubules appear absent and female chromosomes (Ch) are dispersed and not aligned and also without evident centromeres and kinetochores. In this image female chromosomal (Ch) material appeared even outside the spindle region. M, mitochondria, CV, cortical vesicles. X 4 500 and 12 000, respectively.

**Figure 12 and 13.** Partially decondensed male chromatin (Ch) of the injected spermatozoon. The nuclear envelope has already been lost and nuclear envelope vesicles are present within the male chromatin. Decondensation appears to be abnormal – more pronounced at the center (A) than at the periphery (B). Decondensation was also blocked at the coarse chromatin stage (with a ladder appearance) and did not proceed to fine fibrils. V, SER large vesicles; M, mitochondria, dM, degenerating mitochondria, CV, cortical vesicles, SER small vesicles (arrows), nuclear envelope vesicles (\*). X 9 000 and 36 000, respectively.





## References

- Cohen, J., Scott, R., Schimmel, T. *et al.* (1997) Birth of an infant after transfer of anucleate donor oocyte cytoplasm into recipient eggs. *Lancet*, **350**, 186-187.
- Cohen, J., Scott, R., Alikani, M. *et al.* (1998) Ooplasmic transfer in mature human oocytes. *Mol. Hum. Reprod.*, **4**, 269-280.
- Eichenlaub-Ritter, U., Schmiady, H., Kantenich, H *et al.* (1995) Recurrent failure in polar body formation and premature chromosome condensation in oocytes from a human patient: indicators of asynchrony in nuclear and cytoplasmic maturation. *Hum. Reprod.*, **10**, 2343-2349.
- Flood, J.T., Chillik, C.F., van Uem, J.F.H.M. *et al.* (1990) Ooplasmic transfusion: prophase germinal vesicle oocytes made developmentally competent by microinjection of metaphase II egg cytoplasm. *Fertil. Steril.*, **53**, 1049-1054.
- Hartshorne, G., Montgomery, S. and Klentzeris, L. (1999) A case of failed maturation in vivo and vitro. *Fertil. Steril.*, **71**, 567-570.
- Kim, N.H., Chung, H.M., Cha, K.-Y. *et al.* (1998) Microtubule and microfilament organization in maturing human oocytes. *Hum. Reprod.*, **13**, 2217-2222.
- Racowsky, C. and Kaufman, M.L. (1992) Nuclear degeneration and meiotic aberrations observed in human oocytes matured in vitro: analysis by light microscopy. *Fertil. Steril.*, **58**, 750-755.
- Rudak, E., Dor, J., Kimchi, M. *et al.* (1990) Anomalies of human oocytes from infertile women undergoing treatment by in vitro fertilization. *Fertil. Steril.*, **54**, 292-296.
- Takeuchi, T., Ergun, B., Huang, T.H. *et al.* (1998) Preliminary experience of nuclear transplantation in human oocytes. *Fertil. Steril.*, **70**, Suppl 1, S86-S87.
- Tsai, M.C., Takeuchi, T., Bedford, J.M. *et al.* (2000) Alternative sources of gametes: reality or science fiction? *Hum. Reprod.*, **15**, 988-998.
- Van Blerkom, J., Davis, P.W. and Merriam, J. (1994) The developmental ability of human oocytes penetrated at the germinal vesicle stage after insemination in vitro. *Hum. Reprod.*, **9**, 697-708.
- Zhang, J., Wang, C.-W., Krey, L. *et al.* (1999) In vitro maturation of human preovulatory oocytes reconstructed by germinal vesicle transfer. *Fertil. Steril.*, **71**, 726-731.