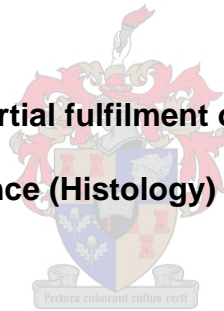

**ANCILLARY METHODS TO IMPROVE DIAGNOSTIC
ACCURACY OF THYROID NODULES ON FINE-
NEEDLE ASPIRATION CYTOLOGY SMEARS**

Christine van Wyk

**This thesis is presented in partial fulfilment of the requirements for the
degree of Master of Science (Histology) at Stellenbosch University**



Supervisor: Dr Mercia Louw

Co-supervisor: Prof Colleen Wright

December 2007

I, the undersigned, hereby declare that the work contained in this thesis is my original work and that I have not previously in its entirety or in part submitted it at any university for a degree.

Signature:

Date:

SUMMARY

Thyroid nodules are a common clinical problem encountered by physicians, surgeons and radiologists who deal with the head and neck region. However, most follicular lesions of the thyroid are benign, so that the indications for surgery should be as accurate as possible. The morphological difficulty on fine-needle aspiration biopsy (FNAB) of reliably distinguishing preoperatively between benign and malignant lesions has led to a search for ancillary methods that can assist with the diagnosis.

The aim of the first study was to develop a cytological scoring system to improve diagnostic accuracy of fine-needle aspiration biopsy of papillary carcinomas with special reference to the follicular variant of papillary carcinoma. The objective of the second study was the application of immunodiagnostic markers Galectin-3 and HBME-1 to histology tissue sections and their corresponding fine-needle aspiration cytology smears to assess their value in distinguishing benign from malignant thyroid lesions.

In the first study 16 different cytological features such as background, architecture and cellular morphology were quantitatively assessed and scored. Only 14 of the 16 variables were statistically significant. The statistical analysis demonstrated that a score ≥ 4 was indicative of a papillary carcinoma with a sensitivity of 96%. A score < 4 suggested a benign multinodular goiter with a specificity of 97%.

In the second study Galectin-3 and HBME-1 were applied to histology tissue sections and their corresponding fine-needle aspiration cytology smears. Statistical analyses showed that the sensitivity of immunohistochemistry for diagnosing malignancy was better than the immunocytochemistry, but the specificity of immunocytochemistry was superior. Furthermore the diagnostic accuracy of immunohistochemistry (86%) and immunocytochemistry (88%) using co-expression of these two antibodies was excellent.

In this study on immunocytochemistry, papillary carcinomas were clearly identified with a 100% co-expression in the classic and 71% in the follicular variant of papillary carcinoma. For the surgeon the identification of papillary carcinoma is critical, as this determines the extent of surgery. Similarly, the confirmation of a non-neoplastic lesion may prevent surgery. In most cases follicular neoplasms, benign or malignant, will usually be excised for histopathology, prior to definite therapy.

These studies show that the implementation of ancillary methods such as a scoring system and immunodiagnostic markers can improve the diagnostic accuracy of thyroid fine-needle aspiration biopsies in our laboratory. This may lead to better management of thyroid nodules. However, it is advisable that cytopathologists always take all the clinical features and image analyses into consideration before making a diagnosis.

OPSOMMING

Die akkurate diagnoseering van tasbare tiroïed nodules is 'n algemene probleem vir geneeshere en radioloë. Alhoewel fynnaald-aspirasie sitologie 'n erkende diagnostiese metode is, mag dit sitomorfologies onmoontlik wees om sekere benigne follikulêre letsels van malignes te onderskei. In hierdie studies word metodes nagevors wat moontlik bydraend mag wees.

Die doel van die eerste studie was om 'n sitologiese puntstelsel te ontwikkel om die diagnostiese akkuraatheid van papillêre karsinome en veral die follikulêre variant, te verbeter. In die tweede studie word immunodiagnostiese merkers Galectin-3 en HBME-1 op histologiese weefselsnitte en hul ooreenstemmende fynnaald-sitologie smere aangewend. Die doel van die studie was om te bepaal watter rol die twee merkers mag speel om benigne van maligne tiroïed letsels te onderskei.

In die eerste studie is sestiën verskillende sitologiese kenmerke mikroskopies ondersoek en 'n numeriese waarde toegevoeg. Die kenmerke was agtergrond, sellulêre argitektuur en selmorfologie. Slegs 14 van die 16 veranderlikes was statisties betekeniswaardig. Die statistiese analise het getoon dat 'n numeriese waarde ≥ 4 aanduidend was van 'n papillêre karsinoom met 'n sensitiwiteit van 96%. 'n Numeriese waarde < 4 was aanduidend van 'n multinodulêre goiter met 'n spesifisiteit van 97%.

In die tweede studie is Galectin-3 and HBME-1 op histologiese weefselsnitte en hul ooreenstemmende fynnaald-aspirasie sitologie smere aangewend. Alhoewel die statistiese berekeninge aandui dat die immunohistochemiekleuring meer sensitief was vir die diagnoseering van maligne letsels, die immunositochemiekleuring 'n hoër spesifisiteit toon. Die kokspressie vir beide teenliggame was statisties betekenisvol in die immunohistochemie (86%) asook immunositochemie (88%) kleurings.

In die immunositochemie studie kon klassieke papillêre karsinome duidelik onderskei word. Klassieke papillêre karsinome het 'n ko-ekspressie van 100% met beide immunomerkers getoon. In teenstelling hiermee het die follikulêre variant slegs 71% ko-ekspressie getoon. Die akkurate diagnosering van papillêre karsinome is belangrik vir die klinikus, omdat dit die omvang van chirurgie bepaal. In teenstelling hiermee word nie-neoplastiese letsels nie chirurgies verwyder nie. Follikulêre neoplasmas, hetsy benigne of maligne, word chirurgies verwyder vir histopatologie.

Die studieresultate toon dat 'n numeriese puntstelsel asook die aanwending van immunodiagnostiese merkers, die diagnostiese akkuraatheid van fynnaaldaspirasiesitologiesmere in 'n laboratorium mag verbeter. Die toepassing van hierdie hulpmiddels mag lei tot verbeterde kliniese hantering van pasiënte met tiroïed nodules.

ACKNOWLEDGEMENTS

My sincere gratitude to Dr Mercia Louw, my supervisor, Principal Pathologist and Head of the Cytology Unit in the Discipline of Anatomical Pathology, NHLS, Tygerberg Hospital, for her unfailing expert advice and guidance. My sincere thanks to Prof Colleen Wright, my co-supervisor, Chief Pathologist and Head of the Discipline of Anatomical Pathology, University of Stellenbosch, for her assistance, guidance and permission to undertake this project. Thank you to the NHLS for allowing me to do this research and Dr John Simpson, Business Manager, NHLS, Tygerberg Hospital. Thank you to Dr Martin Kidd for invaluable assistance with the statistical analysis and Mr Dieter Geiger for research advice.

I would like to express my appreciation and gratitude to my loyal colleagues in Cytology, Mrs E Braithwaite for her IT expertise and Mrs G Neethling for the photography. Thank you to Mr B Henrico and fellow technologists, working in the Immunohistochemistry and Histology laboratory, for your technical help and assistance. Thank you to Abe and Derek for retrieving the cytology slides and tissue blocks from the archives and Mr A du Toit for ordering the reagents and materials.

Last, but not the least, I wish to express my appreciation to my family for unfailing patience and continuous, encouraging support during the preparation of this study.

TABLE OF CONTENTS

Table of Contents	I
List of Figures	IV
List of Tables	V
List of Abbreviations	VI

Chapter 1. Introduction and Literature Review

1.1 Background

1.1.1 The Normal Thyroid Gland

1.1.2 Nodular Thyroid Enlargements

1.1.2.1 Follicular Lesions

1.1.2.2 Goiter

1.1.2.3 Follicular Neoplasms

1.1.2.4 Papillary Carcinoma

1.1.2.4.1 Follicular Variant of Papillary Carcinoma

1.1.3 Evaluation of Thyroid Nodules

1.1.3.1 Fine-needle Aspiration Biopsy

1.1.3.2 Studies to Improve Diagnostic Accuracy

1.1.3.2.1 Scoring Systems

1.1.3.2.2 Immunodiagnostic Markers

1.2 Aims and Objectives

1.3 Study Design

Chapter 2. Development of a Cytological Scoring System for Papillary Carcinoma

- 2.1 Introduction and Literature Review
 - 2.1.1 Papillary Carcinoma
 - 2.1.2 Studies to Improve Predictive Value of Malignancy
- 2.2 Scoring System
 - 2.2.1 Background Features
 - 2.2.2 Architectural Features
 - 2.2.3 Morphologic Features
- 2.3 Materials and Methods
- 2.4 Results
 - 2.4.1 Cyto/histological Correlation
 - 2.4.1.1 Cytological False Positive Diagnoses
 - 2.4.1.2 Cytological False Negative Diagnoses
- 2.5 Discussion
- 2.6 Conclusion

Chapter 3. Application of Immunodiagnostic Markers Galectin-3 & HBME-1 to Histological Sections and Corresponding Cytology Smears

- 3.1 Introduction and Literature Review
 - 3.1.1 Immunochemistry
 - 3.1.1.1 Galectin-3
 - 3.1.1.2 HBME-1
 - 3.1.1.3 Usefulness of Galectin-3 and HBME-1 in Immunohistochemical Literature
 - 3.1.1.4 Usefulness of Galectin-3 and HBME-1 in Immunocytochemical Literature
 - 3.1.1.5 Usefulness of Galectin-3 and HBME-1 in Oncocytic Cell Neoplasms
 - 3.1.1.6 Prerequisites for Immunocytochemical Staining
 - 3.1.1.7 Rules for Immunocytochemical Staining

3.2 Material and Methods

3.2.1 Immunohistochemistry

3.2.2 Cytology Fine-needle Aspiration Smears

3.2.3 Evaluation of Immunochemical Staining

3.2.4 Immunolocalization of Galectin-3 and HBME-1 in Tissues and FNA Smears

3.2.5 Statistical Analysis

3.3 Results

3.3.1 Immunodiagnostic Staining in Non-neoplastic Lesions

3.3.2. Immunodiagnostic Staining in Neoplastic Lesions

3.3.2.3 Statistical Analysis of Immunocytochemical Staining

3.3.3 Statistical Analysis of Immunodiagnostic Staining

3.4 Discussion

3.4.1 Histology Tissue Sections

3.4.2 Fine-needle Aspiration Cytology Smears

3.5 Conclusion

Chapter 4. Future Studies

Chapter 5. References

LIST OF FIGURES

- Figure 2.1: Fingerlike projections of papillary carcinoma. Diff-Quik stain(x400).
- Figure 2.2: Dome-shaped aggregates representing tips of papillary carcinoma. Pap stain(x400).
- Figure 2.3: Pale hypochromatic nuclei with small eccentric nucleoli in papillary carcinoma. Pap stain(x400).
- Figure 2.4: Monolayer sheets with dense cytoplasm and nuclear grooves in papillary carcinoma. Pap stain(x400).
- Figure 2.5: The ROC displays an optimal cut-off point of > 3 for papillary thyroid carcinoma.
- Figure 2.6: The histograms display the sensitivity (left panel) and specificity (right panel) for the 28 papillary carcinomas.
- Figure 2.7: The mean score for 15 PC and 123 FVPC was 7.5 and 6 respectively.
- Figure 3.1: Immunohistochemical stain of a follicular variant of papillary carcinoma showing Galectin-3 expression.
- Figure 3.2: Immunohistochemical stain of a follicular variant of papillary carcinoma showing HBME-1 expression.
- Figure 3.3: Cytology smear of a papillary carcinoma showing positive HBME-1 expression.
- Figure 3.4: Cytology smear of a papillary carcinoma showing positive Galectin-3 expression.
- Figure 3.5: Cytology smear of a follicular variant of papillary carcinoma showing HBME-1 expression.
- Figure 3.6: Cytology smear of a follicular variant of papillary carcinoma showing Galectin-3 expression.
- Figure 3.7: Cytology smear of a follicular carcinoma showing HBME-1 expression.

LIST OF TABLES

Table 2.1: Results of the cytological and histological diagnoses.

Table 2.2: The univariate comparisons of all variables with benign or malignant diagnoses.

Table 2.3: The 10 variables in 28 papillary carcinomas.

Table 2.4: Results of initial cyto/histological concordance.

Table 3.1: Immunohistochemical expression for Galectin-3 and HBME-1 in 25 non-neoplastic lesions

Table 3.2: Immunocytochemical expression for Galectin-3 and HBME-1 in 25 non-neoplastic lesions.

Table 3.3: Immunohistochemical expression and co-expression for Galectin-3 and HBME-1 in 37 neoplastic lesions.

Table 3.4: Immunocytochemical expression and co-expression in cytology smears of 33 neoplastic lesions.

Table 3.5: Comparison of Galectin-3 and HBME-1 co-expression between neoplastic and non-neoplastic lesions in cytology smears.

Table 3.6: Galectin-3 and HBME-1 expression and co-expression in histology tissue sections and cytology smears.

ABBREVIATIONS

FNA	Fine-needle aspiration
FNAB	Fine-needle aspiration biopsy
Pap	Papanicolaou
D-Q	Diff-Quik ®
MNG	Multinodular goiter
FN	Follicular neoplasm
FVPC	Follicular variant of papillary carcinoma
FC	Follicular carcinoma
FA	Follicular adenoma
TSH	Thyroid stimulating hormone
FSE	Frozen section examination
ICC	Immunocytochemistry
MGG	May-Grünwald Giemsa
INCI	Intra-nuclear cytoplasmic inclusion
PC	Papillary carcinoma
ROC	Receiver Operating Curve
IHC	Immunohistochemistry
CK	Cytokeratin
mRNA	Messenger-ribonucleic-acid
IDS	Immunodiagnostic staining
PBS	Phosphate-buffered-saline
DAB	Diaminobenzidine
TP	True positive
TN	True negative
FP	False positive
FN	False negative
OCN	Oncocytic cell neoplasm
OCC	Oncocytic cell carcinoma
LBC	Liquid based cytology
RT-PCR	Reverse Transfer Polymere Chain Reaction
TSHR/tg mRNA)	Thyroid stimulating hormone/thyroglobulin mRNA

CHAPTER 1

INTRODUCTION AND LITERATURE REVIEW

Thyroid nodules are a common clinical problem encountered by physicians, surgeons and radiologists who deal with the head and neck region. The distinction between lesions that are benign, malignant or indeterminate for malignancy is important for further management [1].

Currently, fine-needle aspiration biopsy (FNAB) is used as the primary screening modality for the diagnostic evaluation of thyroid nodules and its value in thyroid practice cannot be over-estimated. FNAB has a diagnostic accuracy of more than 70% and leads to correct management in more than 90% of patients [2,3]. Fine-needle aspiration biopsy has reduced the number of surgical procedures by about half [4-7] and at the same time has at least doubled the proportion of cancers found at surgery. The major clinical indication for FNAB is to confirm a non-neoplastic nodule e.g. a dominant nodule in a multinodular goiter from a true neoplasm [8].

1.1 BACKGROUND

The use of iodized salt has made **papillary carcinoma** (PC) the most common thyroid malignancy in America and occurs in up to three quarters of these cases. Papillary carcinoma is two to three times more common in women than men [10]. Patients with a history of radiation exposure are at risk for papillary carcinoma [6,11] and although the peak incidence occurs in the second to fifth decade, [11], no age is exempt.

Papillary carcinoma accounts for up to 90% of childhood thyroid cancers and it has an excellent prognosis (>90% overall survival rate at 20 years) [9]. However, the prognosis is worse in men older than 40 years and women older than 50 years. Recurrence and death may occur late in patients with papillary carcinoma; therefore long-term follow-up is indicated [11].

The optimal treatment strategy for patients with papillary carcinoma involves complete surgical resection of clinically and radiographically evident disease within the neck, the selective use of adjuvant radioiodine therapy (RAI) and post-operative thyroid-stimulating hormone (TSH) suppression [11-13].

Furthermore papillary carcinoma is the most common cystic neoplasm of the thyroid gland [9,14]. Papillary carcinoma can be predominantly solid, partially cystic (~ 50% of cases), or predominantly cystic (~ 10% of cases) [15]. Cystic lesions can be under diagnosed as benign and are a common cause of a

false-negative diagnosis. According to De la Santos [16] and Hammer [17], the risk of malignancy in surgically excised cysts ranges from 3% to 25%, and up to 50% of cystic papillary carcinomas may be missed on fine-needle aspiration biopsy [18-20], as cystic papillary carcinoma may frequently be mistaken for benign thyroid cysts on FNAB [21].

Histologic and cytologic diagnosis of classic papillary carcinoma is usually straightforward. In contrast, the diagnosis of follicular variant of papillary carcinoma (FVPC), especially when it is encapsulated, lacks vascular or capsular invasion, or shows only focal characteristic nuclear features, can be extremely challenging [22,23]. There have been a few reported cases of encapsulated follicular variant of papillary carcinoma with bone metastases, in which the initial thyroidectomy specimens were misdiagnosed as follicular adenomas but showed multifocal nuclear features of papillary carcinoma on retrospective evaluation [24].

Papillary carcinoma is defined on the basis of its characteristic nuclear features [25]. Most papillary carcinomas demonstrate a mixture of papillary and follicular structures. The classical diagnostic feature of papillary carcinoma is delicate finger-like epithelial projections with fibrovascular cores (i.e., true papillae). According to Rosai, [26] only a small minority of cases grow in a purely papillary pattern and in the follicular variant of papillary carcinoma papillae can be completely absent [27].

Follicular variant of papillary carcinoma (FVPC) is the most common subtype of papillary carcinoma and is defined as a papillary carcinoma with a predominantly or entirely follicular pattern of growth [15, 27,25]. Histologically, the appearance of follicular variant of papillary carcinoma overlaps with benign and neoplastic follicular lesions such as adenomatoid nodule, follicular adenoma and follicular carcinoma. The follicular growth pattern of papillary carcinoma can closely mimic a follicular neoplasm and consequently these tumours can be misdiagnosed histologically as follicular neoplasms [28-31].

Furthermore, the identification of follicular variant of papillary carcinoma on aspiration cytology is fraught with difficulties. This is primarily because of the absence/paucity of papillary fragments [32,33]. To further complicate this issue, the presence of microfollicular architecture causes overlap with other follicular lesions, including neoplasms [34,35].

1.1.1 The Normal Thyroid Gland

1.1.1.1 Anatomy and Physiology

The word thyroid comes from the Greek word “thyreos” which describes the shield shaped gland in the anterior portion of the neck. The normal thyroid gland is described as butterfly shaped and located just below the cricoid cartilage. The adult gland consists of a right and a left lobe connected by the isthmus. The normal gland weight ranges from 14 -18 g, depending on the size and sex of the individual, as well as the appropriate iodine intake [36,37].

The thyroid gland is supplied by the inferior and superior thyroid arteries and the intra-glandular and sub-capsular lymphatics drain into the internal jugular lymph nodes [8].

The thyroid is an endocrine gland and its primary function is to produce and store thyroid hormone and calcitonin. Thyroid hormone thyroxine [T_4] and triiodothyronine [T_3] stimulate almost all aspects of metabolism, both anabolic and catabolic [1]. It is essential for normal cellular growth, development and function. Either hormone excess or deficiency may result in serious consequences [8].

1.1.1.2 Microscopic Appearance

The functional unit of the thyroid is the follicle. Microscopically it is composed of a central ball of viscous fluid, called colloid, surrounded by a single layer of follicular epithelial cells [38,39]. Twenty to 40 follicles make up a lobule. The average follicular size is about 200 μ m in diameter. The number of cells and size of the follicles become more heterogeneous with age. These two components of the follicle, namely follicular cells and colloid, play a fundamental role in fine-needle aspiration diagnosis [39].

The thyroid contains a second cell population known as C cells, which secrete calcitonin. Small collections of C cells are situated within the confines of the basement membrane of the thyroid follicle [40]. These C cells form a small percentage of the fine-needle aspiration (FNA) cellular component, unless

they are the cause of the pathology. More than 99% of thyroid fine-needle aspirate cells are the cells producing thyroid hormone [39].

1.1.1.3 The Follicular Cells

Follicular cells produce thyroid hormone. The appearance of the normal follicular cell varies somewhat with the functional activity of the gland. In cytology, the more active the cell is, the more abundant the cytoplasm [41].

Aspirated follicular cells are uniform cells forming flat, orderly cohesive sheets, in a honeycomb arrangement [42]. The nuclei line up in a regular manner without crowding, overlap, or significant microfollicle formation. Microfollicle formation is seen as rosette-like or microacinar structures [42]. According to Atkinson [43], single intact follicular cells are sparse in benign aspirates. This orderly arrangement is an important feature of non-neoplastic follicular epithelium e.g. goiters. The presence of crowding, numerous microfollicles [44] and any true papillae should raise the suspicion of a neoplasm.

The nucleus is round to oval and normally about the size of a lymphocyte [42]. According to Boon [45] and Wright [46], the nuclear size varies not only due to staining, fixation and method of preparation, but also with the functional state of the cell (normal, inflamed, hypoplastic, hyperplastic, neoplastic) and age of the patient [47]. The nuclear membrane is normally smooth and nuclear moulding is unusual [5]. The chromatin is normally distinctly granular (but not coarse) and moderately hyperchromatic. The quality of the chromatin also

varies with the functional state of the cell. It is dense to pyknotic in involution and more open in hyperactivity. The nucleoli are normally inconspicuous to invisible but may be more prominent in reactive or regenerating cells. Even in benign smears, an occasional nucleus may be large and hyperchromatic and naked nuclei are common. The cytoplasm of the normal follicular cell is pale and delicate in the Papanicolaou stain (Pap) and stains light blue - purple in the Diff-Quik stain[®] (D-Q). The cell borders are ill-defined [42].

1.1.1.4 Hürthle Cells (Oncocytes)

When the cytoplasm of follicular cells becomes packed with mitochondria, they become so-called oncocytes. They are also known as Askanazy cells, oxyphilic cells and Hürthle cells. Hürthle cells are essentially nonfunctional. They do not synthesize thyroxine but thyroglobulin synthesis is variable [48]. Collections of Hürthle cells usually form cold nodules and are associated with Hashimoto's thyroiditis and other conditions including goiters [49] and neoplasms.

The most characteristic feature of the Hürthle cells is abundant, dense and granular cytoplasm. The granules are mitochondria and the cells are polygonal, with well-defined cell borders. The cytoplasm stains purplish with D-Q and blue to bright orange with the Pap stain. The nuclei are eccentrically located, enlarged (two to four times normal size) and binucleation is common. Multinucleation can also occur. The nucleoli can be very large and prominent,

or small and inconspicuous. The chromatin varies from fine to course to pyknotic. [42]

1.1.1.5 Colloid

Colloid is a glycoprotein and the storing site of iodinated thyroid hormones. Colloid is characteristic of the benign thyroid nodule and is variably described as watery or dense [42]. It plays a central role in the fine-needle aspiration biopsy diagnosis of several common thyroid diseases, particularly follicular lesions (goiter and follicular neoplasms).

The ratio of the colloid to the follicular cells reflects the size of the follicles: abundant colloid and few cells (colloid predominance) correlate with large or macrofollicles; abundant cells and little colloid (cellular predominance) correlates with small cells or microfollicles [8]. The more active the gland is, the more watery the colloid is and the less active the gland, the denser the colloid. In nodular hyperplasia, parts of the gland are active and parts of the gland are relatively inactive; consequently both watery colloid and dense colloid are often seen in combination.

Watery colloid is difficult to recognize microscopically, and is easily confused with serum. Watery colloid is more difficult to recognize in the Pap than the D-Q stain [1]. Watery colloid stains light blue with D-Q stain and light green with Papanicolaou stain [42].

Microscopically, watery colloid has a tendency to crack and is described as having a cellophane or ruffled tissue appearance. It also has the tendency to surround follicular cells and during processing may drop off the slide leaving the erythrocytes lined up in rows [1].

Dense colloid is relatively easy to spot. It looks like irregular or round chips of translucent, homogenous material that stains shades of blue or pink in Pap and deep purple in D-Q stains [1]

1.1.2 Nodular Thyroid Enlargements

Palpable thyroid nodules or enlargements are quite common in approximately 4%-7% of the adult population [50] and approximately 10% of older individuals have palpable thyroid nodules [51]. Thyroid nodules are more common in females than males and the ratio is approximately 4:1 [50,52]. Although thyroid cancer is more common in women, the ratio of malignant to benign lesions in males is smaller (\pm 2:1) [53]. According to Ashcraft [14], Campbell [54] and Van Herle [55], virtually any disease of the thyroid can present as a nodule and it is usually not possible to distinguish benign from malignant nodules with non-invasive procedures.

A thyroid nodule is the classical clinical finding in thyroid cancer. Thyroid cancer is by far the most common endocrine malignancy (\pm 90% of cases) [56], but it still accounts for only approximately 1% of all cancers and less than

one in ten patients with thyroid cancer will die of disease [57]. Excision of all clinically detected thyroid nodules carries a higher morbidity/mortality than leaving them all in-situ [58]. Therefore non-operative ways of diagnosing thyroid lesions are necessary to minimize unnecessary surgery.

Cancer occurs more often in a solitary nodule than in a multinodular goiter [14,59,60]. Clinical distinction between a solitary nodule and a multinodular goiter (MNG) is subjective. According to Carpi [58], the presence of a multinodular goiter does not exclude malignancy and even diffuse goiters may harbor malignancy [61].

Palpation can detect approximately half of cancers less than 1 cm in size and sensitivity increases with tumour size [62]. Irregular, hard, fixed and fast growing nodules are suspicious for malignancy [63-65], however according to Lo Gerfo [66] the physical characteristics of thyroid nodules are poor indicators of their malignant potential. The presence of a thyroid nodule with cervical lymphadenopathy however is the strongest indicator of a thyroid malignancy [14,67].

1.1.2.1 Follicular Lesions

The term “follicular lesion” includes dominant nodules in multi nodular goiter, follicular neoplasms (FN’s), as well as the follicular variant of papillary carcinoma (FVPC). In the approach to the **cytological diagnosis** of follicular lesions of the thyroid, the proportion of colloid and follicular cells plays a major

role. The two essential principles are: *the more colloid, the more likely the lesion is benign; and the more cells, the more likely the lesion is malignant* [1].

Cytological these lesions are confusing; because they share many of the same morphological features [32,68,69]. Therefore differentiating between a cellular, but non-neoplastic multinodular goiter, which is usually a 'medical' disease, and a follicular neoplasm, which is usually managed surgically, is a common problem [70,71].

Follicular lesions are divided into three **Zones (I, II, III)** depending on the amount of colloid and cells. This forms the foundation for a scientific approach to the cytological diagnosis of follicular lesions [1].

Zone I. Colloid dominates the smear with a few cells. This corresponds to a pattern of a colloid nodule (nodular hyperplasia) and is usually a benign lesion. According to Gharib [2], Rojeski [72], and Harach [73], a Zone I lesion has an approximately 1% chance of being a follicular carcinoma. Based on surgical pathology follow-up, 90% to 95% of Zone I lesions will correspond to nodular (colloid) goiter [68,72]. Cyto-histologic correlation in a further study proved that less than 5% Zone I biopsies will show follicular adenomas as opposed to a goiter, but are never malignant [60].

Zone II corresponds to an intermediate or suspicious lesion. There are many cells in follicular arrangements and colloid is still present. This is the pattern of an adenomatous or cellular nodule. According to DeMay [1], these patients have a risk of a neoplasm but a low risk of cancer. In thyroid FNAB these

lesions (Zone II) pose a diagnostic problem for cytopathologists who have to distinguish a cellular (adenomatous) goiter with little colloid from a follicular neoplasm with minimal colloid [74].

Zone III. Cells dominate the smear with little or no colloid. This pattern points to a follicular neoplasm, whether benign or malignant [44,75,76,77]. Histopathology correlation of Zone III lesions shows that 85% to 95% are follicular adenomas or carcinomas [73,78-82]. According to Gharib [51], Silver [82] and Harach [73], approximately 20% of Zone III lesions are follicular carcinomas (range: 15% to 50%).

As mentioned before, one of the difficulties in thyroid fine-needle aspiration biopsy is to distinguish a cellular (adenomatous) goiter with little colloid, from a follicular neoplasm with some colloid (essentially Zone II lesions). The findings on FNAB, the most commonly used procedure in thyroid nodular disease, do not always correlate with postoperative histopathological diagnosis, sometimes giving a false negative result [56,69,71,83].

Furthermore, cytological studies of follicular lesions by Kini [84] show a spectrum of changes that merge imperceptibly with each other. There is an overlap in the degree of cellularity, the amount of colloid, the architecture, cohesion and types of cells.

1.1.2.2 Goiter

The term “goiter” refers to any thyroid enlargement, whether benign or malignant. There are various causes for goiter e.g. diet [69] and inherited enzyme defects [85].

If thyroid hormone is not maintained at adequate levels, the pituitary secretes thyroid stimulating hormone (TSH), which causes the thyroid to increase colloid production or storage and the epithelial cells to become hyperplastic. The thyroid gland enlarges diffusely and this is a **simple goiter** [3].

Thyroid cells are heterogeneous [86]. Due to stimulation by TSH they have different responses, some grow, others produce colloid and some do both. Inevitably certain areas of the gland undergo involution while other areas undergo further hyperplasia. The blood supply becomes compromised, resulting in infarction, haemorrhage, degeneration, cyst formation, chronic inflammation, fibrosis and calcification. After years of this continued cycle the gland enlarges and becomes nodular. This is a **multinodular goiter** [1].

One nodule may be dominant in a multi nodular goiter. Sixty to 80% of thyroid gland fine-needle aspirations are from patients with a dominant nodule in nodular hyperplasia or a non-toxic goiter [6,72,78].

1.1.2.2.1 Microscopic Appearance of Multinodular Goiter (MNG)

Microscopically, multi nodular goiter can be sub classified as either colloid-rich or adenomatous, depending on whether the colloid storage, or the epithelium, predominates. In approximately 50% to 80% of goiters, macrophages are seen in the background [73,75,87]. Abundant macrophages are a sign of cystic degeneration. This is common in goiters [69], but unusual in follicular neoplasms. According to Harach [32], multinucleated giant cells are present in approximately one third of cases. These cells may contain phagocytosed red blood cells or haemosiderin.

The follicle size in goiters vary from small to large [32,88], but is mostly medium to large. Microfollicles are few and the follicular cells are usually arranged in a regularly spaced, honeycomb pattern. The cells rarely show overlapping or crowding of nuclei. This honeycomb pattern is usually present in goiters, but absent in neoplasia [75].

The nuclei are about the size of a red blood cell [63] or lymphocyte. The chromatin remains granular and uniform as in the normal thyroid and the nucleoli are inconspicuous. Furthermore, the presence of different cell types (follicular, Hürthle, flame, foam etc.) favours a goiter [32].

Unfortunately, the features described are only suggestive of, rather than diagnostic, of goiter [1]. High cellularity is present in 30% of goiters, colloid is scant in 15% to 20% and a microfollicular pattern is seen in 5% to 10% of

cases [32,76]. In approximately a third of follicular neoplasms, adenomas and carcinomas, cystic changes and macrophages are seen [87]. Hürthle or flame cells may be present in benign and malignant follicular neoplasms [68].

1.1.2.3 Follicular Neoplasms (FN)

Follicular neoplasms include both follicular adenomas and follicular carcinomas [90]. They are classified together, because the cells from both neoplasms can appear the same. Usually it is impossible for the cytopathologist to evaluate the features definitive for distinguishing neoplasm from carcinoma (i.e. vascular or capsular invasion) [90]. Histological evidence of invasion is the gold standard for malignancy of follicular neoplasms [9]. There are certain cytological features that favour a diagnosis of a follicular neoplasm over a goiter. In 85% of cases high cellularity is seen [44,75] and a microfollicular pattern is present in 80%-90% of cases [75]. Microfollicles are 6-12 cells in a ring, or rosette like configuration with or without colloid in the centre [91]. When these microfollicles are arranged in three-dimensional, crowded, overlapping syncytia, a follicular neoplasm is favoured [71,88]. The nuclei of follicular neoplasms may be enlarged, but usually remain uniform with inconspicuous, sometimes infrequent nucleoli [89].

Follicular adenomas (FA) are benign solitary neoplasms. They are completely encapsulated with a different architectural composition inside and outside and lack invasion of the follicular cells through the capsule [92]. The presence or absence of a capsule is critical in determining if the lesion is an adenoma (no capsule: nodular hyperplasia: capsule: adenoma). Histologically, if multiple nodules are present, the appropriate diagnosis is nodular hyperplasia [93], as adenomas should be solitary.

According to their histological appearance, adenomas may be subtyped i.e., simple, microfollicular, macrofollicular, trabecular, embryonal and foetal [92]. This sub classification has no clinical importance. If adenomas are excised they will not recur or metastasize [92].

Follicular carcinomas (FC) are separated from follicular adenomas by the presence of capsular and/or vascular space invasion [9] and this requires histological examination. Histologically, follicular adenomas and follicular carcinomas are composed of follicles and the neoplastic cells of a follicular carcinoma may appear identical to the cells of a follicular adenoma. Some studies have however shown that 10% to 15% of follicular carcinomas show obvious malignant features [68,87].

Fine-needle aspiration biopsy of follicular carcinoma is extremely cellular and there is an increase in the number of single cells [44] with little colloid present. The follicular cells are disorganized and distinct irregular follicles are present [94].

Although the nuclear size of follicular adenomas and carcinomas may be identical [45,89,95], larger nuclei are more frequently found in carcinomas. Furthermore, the presence of prominent or multiple nucleoli in most cells is more suggestive of a carcinoma, but their absence does not exclude malignancy [94,95]. Relatively smooth nuclear membranes may be found in carcinomas but the presence of coarse, irregular, chromatin favours carcinoma [89].

Thus, all these cytological criteria are not absolute, [76] and the final diagnosis still rests on histological demonstration of invasion.

1.1.2.4 Papillary Carcinoma (PC)

The use of iodized salt has made papillary thyroid carcinoma (PTC) the most common thyroid malignancy in America accounting for up to three quarters of thyroid malignancies. Papillary carcinoma is two to three times more common in women than men [9] Patients with a history of radiation exposure are at risk for papillary carcinoma [6,10] and the peak incidence occurs in the third to sixth decades. [11].

Papillary carcinoma can be predominantly solid, partially cystic (~ 50% of cases), or predominantly cystic (~ 10% of cases) [15]. According to Chan [21] cystic papillary carcinoma may be mistaken for a benign thyroid cyst on fine-needle aspiration biopsy.

The classical histological and cytological diagnostic feature of papillary carcinoma is finger-like epithelial projections with fibrovascular cores (i.e., true papillae). According to Rosai [26] only a minority of cases grow in a purely papillary pattern. In the subtype **follicular variant of papillary carcinoma** papillae can be completely absent [27].

Histologically, the nuclear changes distinctive of papillary carcinoma consists of enlarged, empty-appearing or ground glass (“Orphan Annie eye”) nuclei, prominent nuclear membranes and frequently, margined micronucleoli [9,26]. Although these nuclei are present in more than 80% of cases [9], it is not absolutely specific [96]. According to Hapke [96] and Rosai [26] similar nuclei can be seen in diffuse hyperplasia, Hashimoto’s thyroiditis and follicular neoplasms.

Intranuclear cytoplasmic invaginations (INCs) differ completely from Orphan Annie eye nuclei. Orphan Annie eye nuclei are fixation artefacts [26,41] and they have the same diagnostic significance [97] (see below).

Grooved nuclei are another important nuclear characteristic of papillary carcinoma and are present in most papillary carcinomas [9]; however grooved nuclei may be focally present in other thyroid conditions.

Another diagnostic significant architectural feature of papillary carcinoma in **fine-needle aspiration biopsies** is the presence of various types of papillary structures. Kini [84] reported that papillary structures are present in up to 90%,

or more cases. Monolayer sheets of cells are characteristic of papillary carcinoma [9,47,84,90] and are present in 33% to 66% of cases [84,99].

An important diagnostic nuclear feature of papillary carcinoma in **fine-needle aspiration biopsies** is the presence of nuclear grooves or irregularity of the nuclear membrane [100,101]. Almost all cases of papillary carcinoma, whether papillary or follicular variant [32,102], have these nuclear grooves [9,98].

With the nuclear membrane irregularity is the formation of intranuclear cytoplasmic inclusions (INCs), wherein the nuclear grooves invaginate and enclose a portion of cytoplasm [41]. Intranuclear cytoplasmic inclusions are found in as many as 90% or more of papillary carcinomas [98,99] and according to Lew [97] and Rosai [26] are the most important diagnostic feature of carcinoma. Intra nuclear cytoplasmic inclusions can be seen in other primary thyroid malignancies such as giant and spindle cell carcinoma, medullary carcinoma and insular carcinoma. In addition intranuclear cytoplasmic inclusions are very common in Hürthle cell neoplasms [99,103], but rarely occur in follicular carcinoma [97,103]

The chromatin of papillary carcinoma is mostly finely granular (powdery, dusty) and pale [21,26]. This feature is in contrast with the chromatin seen in normal thyroid, goiter or follicular neoplasms, which is usually distinctly granular and moderately hyperchromatic.

Another characteristic of papillary carcinoma is the presence of one to three conspicuous nucleoli, which tend to be margined in comparison to the central more prominent nucleoli of follicular carcinomas. Nuclear pleomorphism is minimal in papillary carcinoma [1].

The cytoplasm of the cells in papillary carcinoma can be delicate, however in 66%-100% of cases there is increased cytoplasmic density in some cells [99].

Another common feature of papillary carcinoma is the presence of giant cells. According to Leung [98] and Miller [99] they are present in up to 50% of cases. Giant cells may be present in other thyroid diseases such as goiters, cysts and thyroiditis [32]

Psammoma bodies are highly characteristic, but not pathognomonic, of papillary carcinoma. They are present in 20%-40% of cases [98,99]. Psammoma bodies are concentrically laminated, calcified structures that are clear and colourless with Diff-Quik, but stain magenta to dark purple with Papanicolaou stains.

Colloid is scanty in papillary carcinoma however the presence of dense colloid, so-called bubble-gum colloid, is diagnostically important. Colloid appears sticky and gummy and stains pink with Diff-Quik and pink-purple or blue-green with Papanicolaou. According to Basu [76] and Miller [99] bubblegum colloid is present in less than 25% of papillary carcinomas.

In summary features most commonly present in fine-needle aspiration biopsies of papillary carcinomas are grooved nuclei, intranuclear cytoplasmic inclusions, dense squamoid cytoplasm and papillary architecture [76,98]. The presence of one of these features is highly suggestive of carcinoma, but when all four of these features are present the diagnosis of papillary carcinoma is said to be certain [76,98].

1.1.2.4.1 Follicular Variant of Papillary Carcinoma (FVPC)

Follicular variant of papillary carcinoma (FVPC) is the most common subtype of papillary carcinoma and is defined as a papillary carcinoma with a predominantly or entirely follicular pattern of growth [15,25,27]. The follicular growth pattern of papillary carcinoma can closely mimic a follicular neoplasm and consequently these tumours can be misdiagnosed histologically as follicular neoplasms [28-31].

Histologically, the appearance of follicular variant of papillary carcinoma overlaps with benign and neoplastic follicular lesions such as adenomatoid nodule, follicular adenoma and follicular carcinoma. The diagnosis of this follicular variant is solely dependant on its nuclear features such as oval, enlarged, overlapped nuclei with an optically clear or ground-glass appearance with nuclear grooves and intranuclear cytoplasmic inclusions [25].

Follicular variant of papillary carcinoma of the thyroid is a well-recognised entity on histology; however its identification on aspiration cytology is fraught

with difficulties. This is primarily because of the absence/paucity of papillary fragments [32,33]. Cytology may miss the diagnosis of follicular variant of papillary carcinoma in a significant proportion of cases and may misdiagnose them as follicular neoplasms.

The diagnosis of follicular variant of papillary carcinoma may also be very challenging due to overlapping cytomorphologic features between non-neoplastic and neoplastic follicular lesions [34,35,104-106]. The follicular variant behaves as a papillary carcinoma and not as the more aggressive follicular carcinoma or as a benign adenoma [23] and the prognosis is similar to papillary carcinoma. However, there may be a propensity to distant metastases if the tumour is infiltrating [9,15,25].

1.1.3 Evaluation of Thyroid Nodules

Various efforts have been made to minimize nontherapeutic surgical interventions and a number of clinical parameters have been evaluated for their association with a higher risk of malignancy.

Before the introduction of FNAB, using other conventional diagnostic methods i.e. **physical examination, radiology and sonar**, only about 10% to 25% of all surgically removed thyroid nodules turned out to be malignant [12,107]. This meant a 75% to 90% false positive rate. According to Carillo [108], radiologic features (heterogeneity or irregular borders on ultrasound), may increase the suspicion of malignancy.

Male patients, older age, and larger nodules may be more predictive of carcinoma in the setting of follicular cytology on fine-needle aspirations [24,108,109]. Recently, several **molecular markers** have shown initial promise with respect to improving the accuracy of FNAB diagnosis [108].

1.1.3.1. Fine-needle Aspiration Biopsy

Diagnosis by aspiration is as reliable as the combined intelligence of the clinician and pathologist makes it.

- Fred W. Steward 1933

During medieval times, needle puncture of the thyroid was described by the Arabian physician Abulcasim (1013-1107 AD) to diagnose different types of goiters [110].

According to Webb in 1974, needle aspiration biopsy was first recorded by Kün in 1847. Today, because of its numerous advantages and successes, FNAB has become the cornerstone of clinical management of thyroid nodules [53,112].

Fine-needle aspiration biopsy can be defined as the removal of a sample of cells, using a fine needle, from a suspicious mass for diagnostic purposes and has evolved as a key sampling method [1]. Failure to find evidence of the disease does not necessary mean the patient is free of that disease and what

is found in a biopsy specimen can reasonably be assumed to have been present in the patient. In a study done by Gharib [78] he proposes that fine-needle aspiration, because of its diagnostic accuracy, should be the initial procedure used in thyroid nodule evaluation followed by ultrasonography for evaluation of thyroid gland structure.

False positive results are mainly the result of interpretative errors. These errors may be due to epithelial hyperplasia in hot nodules, misinterpretation of papillary fronds as evidence of papillary carcinoma, missing subtle nuclear changes (e.g., irregular nuclear membranes, intra-nuclear invaginations) and misinterpreting atypical cells of epithelial or mesenchymal repair as follicular cells [70,71,80,81,88].

As a diagnostic test, fine-needle aspiration biopsy can be used to diagnose papillary carcinoma, poorly differentiated carcinoma, medullary carcinoma, anaplastic carcinoma, metastatic malignancy, thyroiditis and most benign nodular goiters and cysts [74,113,114]. However, follicular adenoma, well-differentiated carcinoma and some hypercellular goiters are indistinguishable on fine-needle aspiration biopsy. However, fine-needle aspiration biopsy can be used to identify thyroid nodules that have a risk of malignancy (i.e., neoplasms) and would thus require surgical excision, from dominant nodules in a goiter that can be managed medically. Although fine-needle aspiration biopsy can reduce the number of diagnostic thyroidectomies, it does not eliminate all diagnostic surgical procedures [74,113].

The use of fine-needle aspiration biopsy of the thyroid is a **Simple, Accurate, Fast, Economic** as well as **SAFE** method of diagnosis of thyroid disorders [115,-123]. Fine-needle aspiration biopsy has been shown to be the most cost-effective diagnostic test available for evaluation of thyroid nodules.

One of the primary goals of fine-needle aspiration biopsy is to avoid unnecessary surgery. Palpable thyroid gland lesions are aspirated by cytopathologists and clinicians. Most aspirators perform three to five passes for non-cystic lesions [90]. For cystic lesions that produce a lot of fluid, cytopathologists, on average, perform two to four passes. If the lesion is cystic and a residual nodule is still palpated after aspiration, additional passes of the residual mass should be performed [1].

Suction and non-suction techniques have been described by various researchers for thyroid fine-needle aspirations [124-126]. Aspirates are performed using a 22-27 gauge needle to minimize a bloody aspirate that would be difficult to interpret. Some aspirators use a 10cc syringe, and some perform the aspirate without using suction [125,127-129]. Parallel preparations of air-dried and alcohol-fixed smears are made from the aspirated material. The air-dried smears are stained with Diff-Quick or May-Grünwald Giemsa and the alcohol-fixed smears with the Papanicolaou stain.

Because fine-needle aspiration of the thyroid is an invasive procedure, **complications** are possible, but serious complications are unlikely and extremely rare [130]. According to Johnson [131], most contraindications are considered relative rather than absolute, i.e., if it would take a more

dangerous procedure e.g. (surgery) to make a diagnosis, fine-needle aspiration biopsy (FNAB) may be preferred despite the risks. Because of the small calibre needle, fine-needle aspiration biopsy is usually no more traumatic than venepuncture and can be almost painless [118].

The **reliability** of fine-needle aspiration biopsy in differentiating benign from malignant follicular lesions of the thyroid is now the subject of renewed debate [132]. According to Baloch [133], with appropriate technique and interpretation by an experienced cytopathologist, the diagnostic accuracy of FNAB relative to the histology diagnosis approaches 90%. Over the years this has led to a substantial decrease in the number of thyroidectomies performed for benign disease and a concomitant increase in the yield of cancer found in surgically excised specimens [78].

Surgical intervention in the management of nodular disease has decreased dramatically. The number of surgical procedures decreased by approximately half and at the same time the proportions of cancer found at surgery doubled [4-7]. Caruso and Mazzaferri [6] studied 9,119 patients and found malignancy in 4% and benign lesions in 74%. Almost identical results (69% benign and 4% malignant) were obtained by Gharib [78] who studied 18,183 patients.

Although fine-needle aspiration cytology has greatly improved the clinical management of thyroid nodules, the pre-operative characterisation of follicular lesions is still very difficult [134], particularly the correct diagnosis of follicular variant of papillary carcinoma. According to Harach [32] and Powari [33],

cytology may miss the diagnosis of follicular variant of papillary carcinoma in a significant proportion of cases and may misdiagnose them as follicular neoplasms. This is primarily because of the absence/paucity of papillary fragments.

1.1.3.2 Studies to Improve Diagnostic Accuracy of Thyroid Lesions

Although clinical parameters, morphometric studies and several molecular markers have showed promise to improve the diagnostic accuracy of fine-needle aspiration biopsies, all these studies have had little impact on the interpretation of thyroid cytology [135].

Researchers, such as Atkinson [5], Boon [45], Crissman [136], Luck [137] and Salmon [138], have published conflicting and confirmatory results. **Morphometrical studies** are currently unreliable in distinguishing follicular adenomas from follicular carcinomas, especially when well-differentiated. Furthermore, efforts to distinguish benign from malignant thyroid disease, by combining **morphometry, DNA analysis and dipeptidyl aminopeptidase IV staining** of cytological preparations were performed by Aratake [139] and Kashyap [140]. All these procedures have had little impact on the diagnostic accuracy of thyroid fine-needle aspiration biopsies [6].

The finding of follicular lesions on thyroid fine-needle aspirations is an ongoing challenge [81,141]. More recent studies such as **electron microscopy, flow cytometry, image morphometry, immunohistochemical and genetic**

markers by various researchers have been an effort to try and improve the diagnostic accuracy of follicular neoplasms [142-145].

1.1.3.2.1 Scoring Systems

Several prognostic scoring systems have been developed and compared in patients with thyroid carcinoma and all provided useful prognostic information. The two most universally accepted systems are the AMES (age, distant metastasis, tumour extent, tumour size) and AGES (age, histological grade, tumour extent, tumour size) [146,147]. Both of these scoring systems have shown validity [146-148], but are not applied to fine-needle aspiration biopsies.

1.1.3.2.2 Immunodiagnostic Markers

Immunochemistry is the technique whereby an antigen reacts with an antibody specific to the antigen. The antibody is labeled with a suitable marker that will allow identification. Visualization of this reaction is achieved by labeling the antibodies with an enzyme such as horse radish peroxidase followed by a diaminobenzidine substrate. A dark brown permanent stain is obtained which is easily recognized microscopically.

Immunodiagnostic markers are monoclonal antibodies with distinct epitopes that separate epithelial, mesenchymal, and haematopoietic cells. Staining is confined to the target cells and is expressed in the cytoplasm, nucleus or cell

membrane. Immunochemical staining depending on antigen-antibody specificity is the most common approach adopted to detect specific antigens in tissue sections [149-152].

Immunocytochemistry (ICC) can be helpful in evaluating a variety of tumours that are difficult to classify [1]. The method can be applied to Papanicolaou stained cytological specimens [152-157]. Some cytology specimens may be limited in quantity and quality, and this may hamper or preclude the performance of immunocytochemistry. This occurs in cases where more than one antibody is required to arrive at the definitive diagnosis [158]. In a study by Dabbs and Wang [158], they developed a method whereby immunocytochemistry can be performed more than once on the very same cytology specimen if the initial immunocytochemistry antibody applied was negative.

Because of the diagnostic limitations of thyroid cytology, several immunodiagnostic markers of thyroid malignancy have been applied to attempt to distinguish follicular adenoma from carcinoma and also identify papillary carcinoma and its variants, both in surgical and cytological specimens [159]. These markers include **Galectin-3** [134,160-163] and **HBME-1** [163-166] **cytokeratin** [34,166-168] **thyroperoxidase** [169] and **high mobility group** (HMG)-Y proteins [170].

Among these markers HBME-1 and Galectin-3 have been proposed to improve pre-operative diagnosis of thyroid nodules and show promising results in predicting malignancy in thyroid lesions [167]. HBME-1 is a monoclonal antibody developed against the microvillous surface of mesothelial cells and subsequently applied to the diagnosis of malignant thyroid conditions [167]. HBME-1 is a protein that is expressed in the cytoplasm or membranes of malignant cells.

In a study done by Miettinen [164], 145 out of 145 papillary thyroid carcinomas stained strongly positive with HBME-1. Strong positive staining was also observed in 27 of 27 follicular thyroid carcinomas. Focal staining or no reactivity was observed in one third of cases of nodular goiter or papillary hyperplasia. The expression of HBME-1 in malignant thyroid lesions such as papillary and follicular carcinomas was also supported by studies performed by Cheung [166] and Nikiforova [171].

Galectin-3 is a beta-galactoside-binding protein of the lectin family that stains the cytoplasm of malignant cells. Galectin-3 is a protein involved in the regulation of cell-cell and cell-matrix interactions and is typically expressed in malignant thyroid cells [172,173]. The utility of Galectin-3 in fine-needle aspirates of thyroid follicular lesions was recently demonstrated by Kim [174].

Bartolazzi and colleagues [134] conducted a retrospective analysis of 618 thyroid tissue sections and 165 cell-blocks and a prospective analysis of 226 fine-needle aspiration specimens. Ninety eight percent (98%) of the malignant

lesions stained positive for Galectin-3 and only 3% of the papillary carcinomas did not express this marker. Of the minimally invasive follicular thyroid carcinomas, 93% were positive for Galectin-3 while this marker was not expressed in any of the cases of nodular hyperplasia or thyroiditis. In this prospective analysis Bartolazzi [134] concentrated on the 90 cases that had inconclusive cytology, where the application of Galectin-3 allowed the correct identification of all the malignant nodules. Galectin-3 had a sensitivity of 100% for detecting malignancy in this study and the specificity was 98%. The positive predictive value, negative predictive value and diagnostic accuracy were 92%, 100% and 99% respectively.

The studies by Bartolazzi [134], Gasbarri [173], Maruta [175], Papotti [162] and Saggiorato [176] showed that the use of immunochemical markers, i.e. Galectin-3, HBME-1 and CD44v6, have improved the diagnostic accuracy of fine-needle aspiration paraffin-embedded cell blocks. Other studies by Gaffney [177], Gasbarri [178], Herrmann [179], Martins [180], Mase [181], Nasir [182], Oestreicher-Kedem [183], Rigau [164], Teng [185], Volante [186] and Weber [187] supported these findings on histological tissue biopsies. According to Volante [186] the combination of Galectin-3 and HBME-1 increased the diagnostic sensitivity of oncocytic variant of papillary carcinoma to 99% on fine needle aspiration biopsies.

In a recent study done by Kim and colleagues [174], it was demonstrated that Galectin-3 could be used as a supplementary marker for cytological diagnosis, although it was not an absolute marker in determining whether a lesion was benign or malignant.

In the study done by Bartolazzi [134] co-expression of CD44v6 and Galectin-3 showed the sensitivity, specificity, positive predictive value and diagnostic accuracy of these markers to be 88%, 98%, 91% and 97% respectively. The sensitivity and specificity of Galectin-3 immuno-detection alone in discriminating benign from malignant thyroid lesions was more than 99% and 98% respectively. The positive predictive value and diagnostic accuracy was 92% and 99%.

Chheng and colleagues [188] reported that CD44v6 is useful in separating papillary carcinomas from other thyroid lesions with nuclear grooves. They reported that CD44v6 is only positive in papillary carcinomas. The study by Bartolazzi [134] demonstrated that CD44v6 was positive in 72% to 100% of carcinomas, but in benign proliferative lesions was present in 38% to 100%. This finding by Bartolazzi and colleagues [134] discouraged the use of CD44v6 immunodetection for discriminating in benign proliferative and malignant thyroid lesions. Although their study also concluded that CD44v6 may strengthen the significance of Galectin-3 expression on well-differentiated follicular lesions, the marker was not expressed in some papillary carcinomas, or in about 50% of undifferentiated malignant lesions. A study by Maruta [175]

reported positivity of 74% for follicular carcinoma and 30% for follicular adenoma with CD44v6.

The initial research proposal included the use of HBME-1, Galectin-3 and CD44v6 in the immunodiagnostic studies, but the performance of CD44v6 in the above-mentioned studies discouraged the use of this marker.

Recently, immunocytochemical evaluation of thyroid neoplasms was performed on thin-layer smears from fine-needle aspiration biopsies [189]. The researchers applied immunodiagnostic markers RET, HBME-1 and Galectin-3 to thin layer processed cytology smears. According to Rossi [189] the combined panel of antibodies and the pleomorphism of follicular cells were effective in distinguishing between thyroid nodules requiring surgery from thyroid nodules requiring only follow-up.

Malle and associates [190] studied the diagnostic accuracy of the ThinPrep® technique (Cytoc Corp., Boxborough, Massachusetts, U.S.A.) on thyroid fine-needle aspirations. Despite well-documented limitations such as shrinkage artifact, attenuation of nuclear details and alteration of background material [190-194] that hamper cytomorphologic interpretation of ThinPrep® - processed slides, Malle [190] and Cochand-Priolet [194] reported encouraging results for sensitivity, specificity and positive predictive value. The Malle results were comparable to those of direct smears and ThinPrep® split specimens in their own study and in contemporary articles employing the optimal approach [24, 34,133,190].

1.2 AIMS AND OBJECTIVES

The aim of the first study was the development of a cytological scoring system to improve the cyto/histological correlation of thyroid fine-needle aspiration biopsies of papillary carcinoma (including the follicular variant of papillary carcinoma) and multinodular goiters in our institution. Furthermore to determine how the total score reflects malignancy. Although the efficacy of a cytological scoring system was unknown, our hypothesis was that the higher the scoring value, the greater the possibility of malignancy.

The second study included the application of immunochemical markers Galectin-3 and HBME-1 to conventional fine-needle aspiration cytology smears and corresponding histopathology. The objective of this study was to assess the value of Galectin-3 and HBME-1 in distinguishing benign from malignant thyroid lesions and to determine if these antibodies can facilitate the diagnostic accuracy of fine-needle aspiration biopsies in our institution.

1.3 STUDY DESIGN

The first study was a retrospective comparative study. Sixty one thyroid fine-needle aspiration cases from June 1996 to November 2005 were retrieved from the archives of the Cytology Laboratory, NHLS, Tygerberg Hospital. All these cases had histological confirmation. These cases were reviewed blindly by 2 independent observers and scored numerically. A detailed cytological evaluation was done and sixteen cytological features such as background,

architecture and morphology were quantitatively assessed, scored and statistically analyzed.

Fine-needle aspiration biopsy smears were considered adequate if there were a minimum of 6 separate groups of at least 10 well-preserved follicular epithelial cells present on a slide [195]. Exclusion criteria were scanty cellular material, cells obscured by blood and no subsequent histology.

The cytological diagnosis was compared to the corresponding histopathological specimen. A FNAB result diagnosed as benign, that upon histopathologic examination revealed a carcinoma, was considered a false negative case. Conversely, a cytological diagnosis of malignancy, revealed after surgical resection and histopathological examination to be a benign lesion, was defined as a false positive [114].

In the second study immunodiagnostic markers Galectin-3 and HBME-1 were applied to 62 previously Papanicolaou-stained fine-needle aspiration cytology smears and their corresponding wax-embedded tissue sections. This study included cases from June 2001 to December 2005. Only fine-needle aspiration smears optimal for immunodiagnostic staining were used. Their individual and combined sensitivity, specificity, positive predictive value, negative predictive value and diagnostic accuracy for distinguishing benign from malignant thyroid lesions were statistically analyzed. The evaluation of antibody expression in the cytology smears was recorded as positive (> 50% staining), weakly positive (> 10% to < 50%) and negative/equivocal (< 10% or

no staining) [134,171,174]. The evaluation of antibody expression in the tissue sections was recorded as positive (diffuse or > 75% staining), focally positive (> 10% to < 75%) and negative/equivocal (< 10% or no staining) [196].

CHAPTER 2

DEVELOPMENT OF A CYTOLOGICAL SCORING SYSTEM

2.1 INTRODUCTION AND LITERATURE REVIEW

Historically it has been estimated that follicular carcinoma accounts for 10% to 20% of all thyroid cancers, but these figures may no longer be accurate [132]. Iodine deficiency, which is widely associated with follicular carcinoma, is on the decrease with the advent of iodine supplement in food products. This has led to a corresponding decline in thyroid follicular carcinoma [198]. Furthermore, DeMay [199] stated that follicular carcinomas are over-diagnosed and follicular variant of papillary carcinoma is often misinterpreted as follicular carcinoma.

However, if the prevalence of follicular carcinoma is on the decrease, then there is a greater need to enhance the predictive value of fine-needle aspiration biopsies for such lesions [132]. Therefore, other factors may need to be considered in combination with cytological findings to reliably identify benign follicular lesions.

2.1.1 Nodular Goiters

Fine-needle aspiration of benign nodular goiters usually yields scanty cellularity. In cysts foamy macrophages, giant cells, cholesterol clefts, haemosiderin laden macrophages, reparative stromal cells and degenerated debris predominates the aspirate (See Chapter 1).

2.1.2 Papillary Carcinoma

Fine-needle aspiration biopsy (FNAB) is a suitable diagnostic procedure in the management of patients with thyroid nodules. Despite the increasing utilization of FNAB, the cytological diagnosis may be problematical. However, it is very specific in diagnosing papillary thyroid carcinomas. The estimated accuracy is 94% [99,197]. The use of iodized salt has made **papillary carcinoma** (PC) the most common thyroid malignancy in America (See Chapter 1).

Histologic and cytologic diagnosis of classic papillary carcinoma is usually straightforward and papillary carcinoma is defined on the basis of its characteristic nuclear features [25] (See Chapter 1)

2.1.2.1 Cystic Papillary Carcinoma

Fine-needle aspiration biopsy is a common means of investigating cysts of the thyroid. According to Rojeski [72] 15% to 20% of all thyroid nodules are cysts. Macrophages are present in the background in approximately 50% to 80% of

goitres [76,87]. However, the presence of macrophages on fine-needle aspiration biopsies is a common cause of a false-negative diagnosis.

Papillary carcinoma is the most common cystic neoplasm of the thyroid gland [8,14,200] and may be predominantly solid, partially cystic (~ 50% of cases), or predominantly cystic (~ 10% of cases) [15]. Cystic papillary carcinoma may be under-diagnosed and mistaken for a benign thyroid cyst [21] (See Chapter 1).

Cytological features indicating that a cyst may be harbouring a papillary carcinoma include increased cellularity, epithelial cytological atypia and psammoma bodies [201]. Other neoplasms that may be cystic include follicular adenoma and Hürthle cell adenoma. However, nuclei of degenerating tumour cells appear more “plump” than those of histiocytes, with a moderately high nuclear to cytoplasmic ratio, dense cytoplasm with well-defined cytoplasmic borders [202]. Cystic change is uncommon in other thyroid malignancies.

2.1.2.2 Follicular Variant of Papillary Carcinoma (FVPC)

Follicular variant of papillary carcinoma (FVPC) is the most common subtype of papillary carcinoma and is defined as a papillary carcinoma with a predominantly or entirely follicular pattern of growth [15,25,27].

The **histological and cytological** diagnosis of classic papillary carcinoma is usually straightforward. In contrast, the diagnosis of follicular variant of papillary carcinoma (FVPC), especially when it is encapsulated, lacks vascular or capsular invasion, or shows only focal characteristic nuclear features, can be extremely challenging [22], [23]. There have been a few reported cases of encapsulated follicular variant of papillary with bone metastases, in which the initial thyroidectomy specimens were misdiagnosed as follicular adenomas but showed multifocal nuclear features of papillary carcinoma in retrospective evaluation [24].

Furthermore, the **histological appearance** of follicular variant of papillary carcinoma overlaps with non-neoplastic and neoplastic follicular lesions such as adenomatoid nodule, follicular adenoma and follicular carcinoma. According to Hamburger [28], Hamburger [29], Miller [30] and Tielens [31] the follicular growth pattern of papillary carcinoma can closely mimic a follicular neoplasm and consequently these tumours can be misdiagnosed histologically as follicular neoplasms.

According to Chan [22] there are no well-defined published minimal histological criteria for encapsulated follicular variant of papillary carcinoma and therefore the histological diagnosis of this lesion will continue to be a challenge for many pathologists.

The identification of follicular variant of papillary carcinoma on **fine-needle aspiration cytology** is fraught with difficulties. This is primarily because of the absence/paucity of papillary fragments [32], [33]. To further complicate this issue, the presence of microfollicular architecture causes overlap with other follicular lesions, including neoplasms [34], [35].

There are also no well-defined minimal criteria established for fine-needle aspiration biopsy diagnosis of follicular variant of papillary carcinomas. Many of those borderline thyroid tumours that contain focal but not unequivocal features of papillary carcinoma will be diagnosed as follicular adenoma or follicular carcinoma (with evidence of capsular or vascular invasion), while others will be diagnosed as follicular variant of papillary carcinoma.

The reality that follicular variant of papillary carcinoma may not be easily diagnosed on FNAB was supported by Nair and colleagues [204]. They reported that less than 1/3 of follicular variants of papillary carcinoma were correctly identified on fine-needle aspiration biopsy. The diagnostic challenge of follicular variant of papillary carcinoma on FNAB was also supported by Wu [205]. They performed a study to determine the minimal cytological criteria needed to identify follicular variant of papillary carcinoma in order to reduce false negative diagnoses. Fine chromatin, nuclear grooves and colloid were seen more often in follicular variant of papillary carcinoma than follicular neoplasms ($p < 0.01$). The combination of flat monolayered sheets, nuclear enlargement and fine chromatin was observed in all the follicular variants and therefore these criteria were considered as sensitive markers in detecting

follicular variant of papillary carcinoma. Logistic regression analysis revealed that the amount of colloid was the only predictor in favour of follicular variant over classic papillary carcinoma.

Follicular variant of papillary carcinoma behaves as papillary carcinoma and not as the more aggressive follicular carcinoma or as a benign adenoma [25] and the prognosis is similar to papillary carcinoma. However, there may be a propensity to distant metastases if the tumour is infiltrating [9,15,25].

2.1.2.3 Variants of Papillary Carcinoma

There are 4 aggressive variants of papillary carcinoma. They are the sclerosing, tall cell, columnar and Hürthle cell papillary carcinomas. Large cell size, numerous intranuclear cytoplasmic inclusions, marked nuclear pleomorphism, coarse chromatin or abundant dense, granular cytoplasm suggests one of these more aggressive variants [207].

2.1.3 Studies to Improve Predictive Value of Malignancy

Several attempts by various researchers have been performed to improve the predictive value of malignancy in thyroid lesions.

2.1.3.1 Scoring Systems

Various scoring systems have been developed over the past years to identify patients with thyroid carcinomas. D'Avanzo [208] compared scoring systems TNM, EORTC, AGES, AMES and MACIS to predict the survival of individuals with thyroid carcinoma. The two most universally accepted systems are the AMES (age, distant metastasis, tumour extent, tumour size) [146] and AGES (age, histological grade, tumour extent, tumour size), [147] systems. Both of these scoring systems have shown validity [146-148] but have not been applied to fine-needle aspiration cytology.

2.1.3.2 Clinical Parameters

Numerous clinical parameters have been evaluated by researchers for their ability to stratify risk of malignancy in patients with follicular thyroid lesions. According to research done by Baloch [24], male sex, age over 40 years and nodular size greater than 3 cm are significant predictors of carcinoma. Furthermore, Tuttle [109] suggested that lesions larger than 4cm were more predictive of carcinoma. A history of neck irradiation [108] and a fixed or solitary nodule was also a high-risk finding.

2.1.3.3 Image Morphometry

According to Loghsundaram [145], image morphometry on the nuclei of various follicular lesions may distinguish nonneoplastic follicular lesions (hyperplasia) from neoplastic lesions (adenomas and carcinomas), but may not improve diagnostic accuracy in distinguishing between benign and malignant neoplastic lesions.

Absolute distinction between an adenoma and a well-differentiated follicular carcinoma on morphological grounds has not been possible [209]. Methods to try and resolve this difficulty include nuclear DNA content [210,211] and nuclear morphometry [45,46,137,212]. Results of nuclear morphometry have been conflicting [45] and the technique shown to be unhelpful [46,137,212].

The proportion of cells with nucleoli and the number of nucleoli per cell appear to be helpful but do not discriminate absolutely. Three or more nucleoli per cell are rare in follicular adenomas and occur in up to 70% of follicular carcinomas [213].

Further studies by Montironi [214] proved that the combination of nuclear diameter, percentage of nucleolated cells and the number of nucleoli improves the distinction between adenoma and carcinoma above that achieved by subjective evaluation. The most useful atypical features are high cellularity, crowding in cell groups, increased nuclear size, more than 70% of cells with nucleoli, cells with 3 or more nucleoli, nuclear membrane irregularity and

irregular chromatin distribution [95,213,214]. The presence of necrotic debris also supports the suspicion of malignancy [32].

2.1.3.4 Morphology

Several studies such as by Greaves [3] have investigated the ability of certain morphological features (nuclear atypia and pleomorphism, cell overlapping) to enable a distinction to be made between follicular-patterned neoplasms. These neoplasms include follicular adenoma, follicular carcinoma and follicular variant of papillary carcinoma.

Clinical parameters, morphometric studies and several molecular markers have shown promise to improve the diagnostic accuracy of fine-needle aspiration biopsy, but all these studies have had little impact on the interpretation of fine-needle aspiration cytology of the thyroid [135]. Although fine-needle aspiration cytology has greatly improved the clinical management of thyroid nodules, the pre-operative characterisation of follicular lesions remains difficult [134].

2.2 SCORING SYSTEM

The devised scoring system was based on various criteria i.e. background, architecture and cellular morphology to distinguish papillary carcinoma and in particular follicular variant of papillary carcinoma from multinodular goitres.

The **background features** included abundant colloid, bubblegum colloid, psammoma bodies, giant cells, and haemosiderin laden macrophages. The **architectural features** were microfollicles, true papillae and flat monolayer sheets. The **cellular morphology** included hyperchromasia, hypochromasia, pleomorphism, intranuclear cytoplasmic inclusions, nuclear grooves, nuclear crowding/overlapping, multiple nucleoli and dense squamoid cytoplasm. Statistical analysis was performed using the histological diagnosis as the gold standard.

2.2.1 Background Features

The presence/absence and consistency of **colloid** is an important indicator of malignancy in the cytological diagnosis of fine-needle aspiration of thyroid nodules (Kini 1985). Abundant watery or thick colloid in the background is usually an indication of a benign lesion [2]. **Watery colloid** is uncommon in papillary carcinoma; however abundant thick colloid is common in papillary carcinoma, especially the follicular variant of papillary carcinoma [205]. In our study the finding of thick colloid in more than 10% of the background scored 1.

The thick colloid, so-called **bubble-gum colloid** appears sticky and gummy and stains pink with Diff-Quik and pink-purple or blue-green with Papanicolaou. Bubblegum colloid may also be present in benign diseases such as Grave's disease [76].

Papillary carcinoma is the most common cystic neoplasm of the thyroid gland [9,14,200] and they can be under diagnosed as benign and are a common cause of a false-negative diagnosis. According to De la Santos [16], and Hammer [17], the risk of malignancy in surgically excised cysts ranges from 3% to 25% and up to 50% of cystic papillary carcinomas may be missed on FNAB [18-20]. Therefore the diagnosis of a cyst does not rule out malignancy and careful follow-up is recommended. A significant number of cysts recur after therapy and recurring cysts may be an indication of malignancy [72].

Cellularity in cysts may be scant and foamy macrophages, giant cells, cholesterol clefts, haemosiderin laden macrophages, reparative stromal cells and degenerated debris may predominate. **Macrophages** are present in the background in 50% to 80% of goitres [76], [87]. According to Hsu [87], abundant macrophages may be an indication of cystic degeneration. This phenomenon is frequent in goitres [42], but rare in follicular neoplasms. A numerical score of 1 was selected when haemosiderin laden macrophages were present in at least 50% or more of the background area.

Another common feature of papillary carcinoma is the presence of **giant cells**. Giant cells can be present in up to 50% of cases [90,98,99]. They can be of macrophage or epithelioid type with elongated hypochromatic nuclei. The macrophage type giant cells have foamy cytoplasm and may be multinucleated [99]. The epithelioid type cells have hard cytoplasm without vacuoles and may be very large. Giant cells may be present in other thyroid diseases such as goitres, cysts and thyroiditis. According to Harach [32],

multinucleated giant cells are present in approximately one third of multinodular goitres. Because of the presence of giant cells in goitres, thyroiditis and cysts, benign disease must first be excluded.

Tsou [215] did a retrospective study to determine the significance of multinucleated giant cells in 100 cases of papillary carcinoma and 100 cases of benign nodular goitre (BNG). They concluded that multinucleated giant cells were twice as frequent (40%) in papillary carcinoma than in benign nodular goitre (26%). The multinucleated giant cells in benign nodular goitre tend to be smaller and ovoid, with foamy cytoplasm and had fewer nuclei. In contrast the multinucleated giant cells in papillary carcinoma were more diverse in size, shape, and cytoplasm and had numerous nuclei.

The presence of **psammoma bodies** plays an important role in the diagnosis of papillary carcinoma of the thyroid. Psammoma bodies are highly characteristic, but not pathognomonic, of papillary carcinoma. They are concentrically laminated, calcified structures that stain clear and colourless with Diff-Quik, but magenta to dark purple with Papanicolaou.

Histologically, psammoma bodies are present in 50% of papillary carcinoma and are rare in other thyroid conditions [15,21,26]. According to Kini [197], Leung [89] and Miller [99], they are present in 20%-40% of fine-needle aspiration biopsy specimens of papillary carcinoma. The presence of psammoma bodies has been described in other benign thyroid diseases such

as nodular hyperplasia, Grave's disease and Hashimoto's thyroiditis [14,99,197,216].

2.2.2 Architectural Features

The presence of various types of **papillary structures** is another important diagnostic feature of papillary carcinoma in fine-needle aspiration biopsies. Kini [197] reported that papillary structures are found in up to 90%, or more, of carcinomas. Three types of papillae can be recognised in papillary carcinoma. The first type is true papillary structures containing a fibrovascular core and is present in up to 60% of cases [84]. The neoplastic cells are arranged in a hobnail fashion along the core and cellular dissociation is common. However, true papillae may be seen in other thyroid diseases, such as Graves's disease, nodular hyperplasia, toxic adenoma, thyroiditis, medullary carcinoma and other neoplasias [79,99,197].

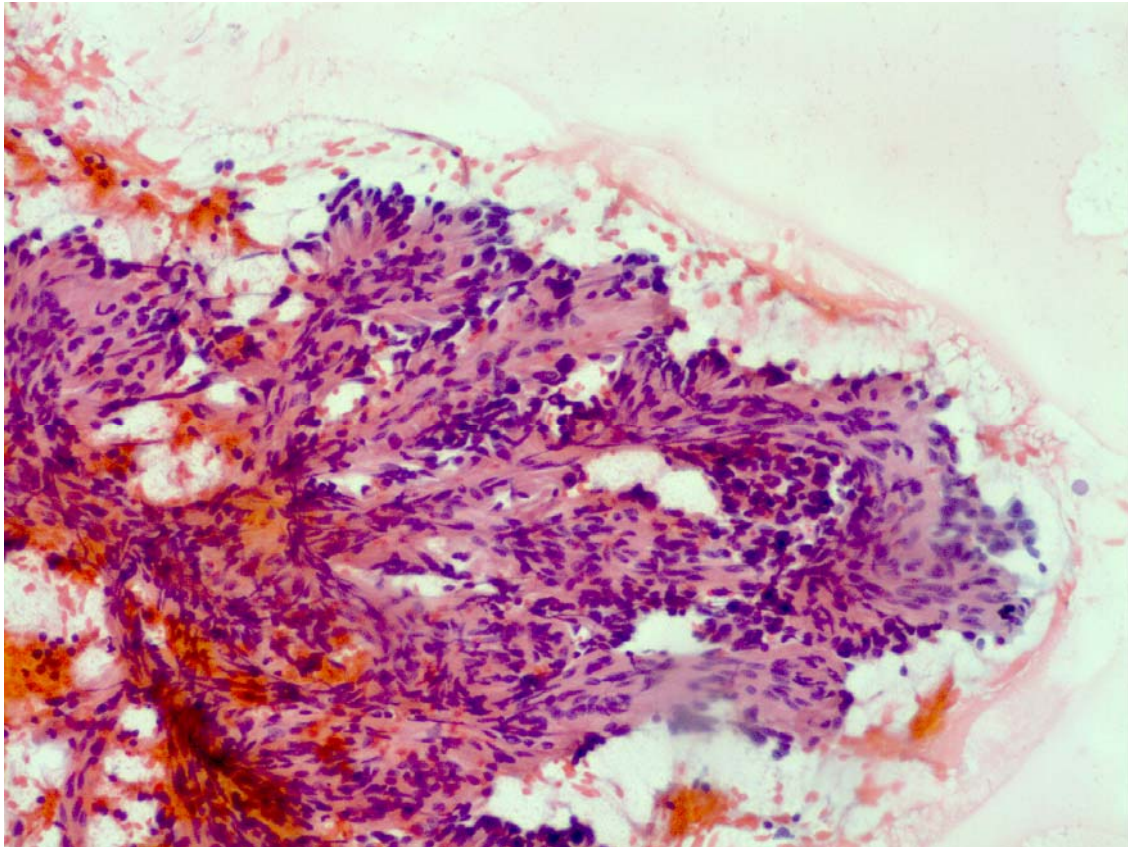


Figure 2.1: *Fingerlike projections of papillary carcinoma. Diff-Quik stain (x400).*

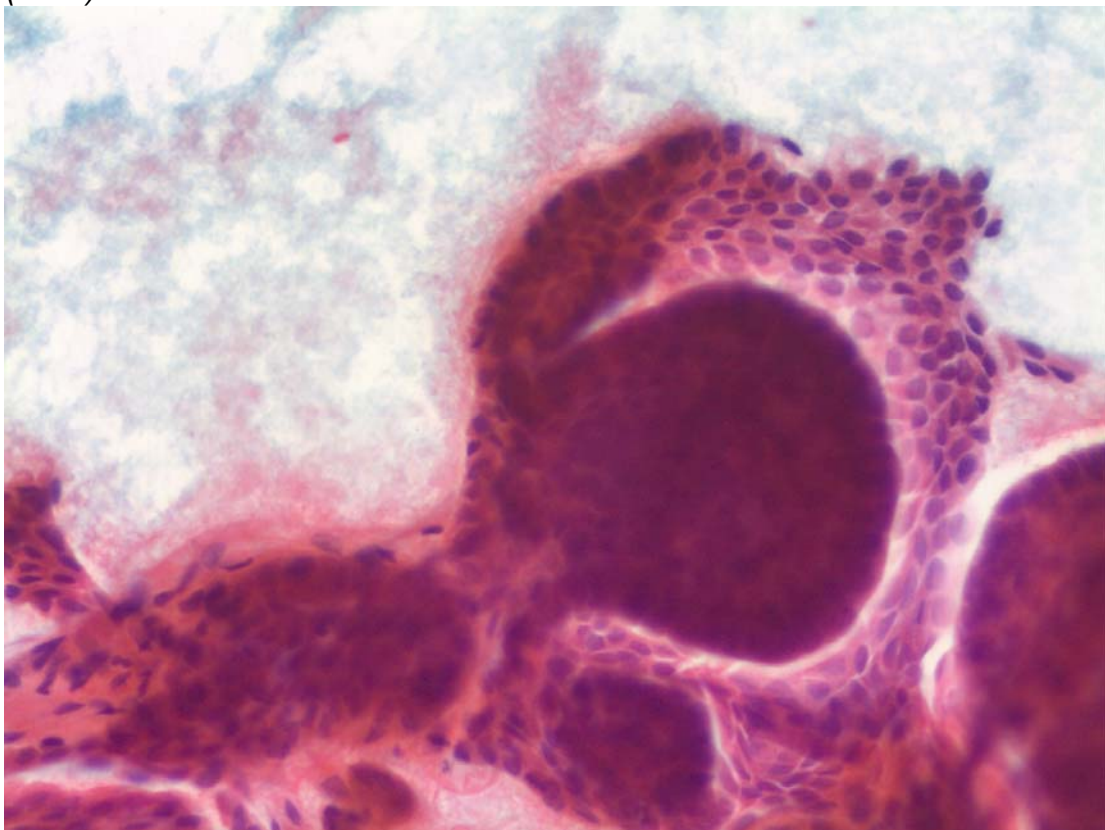


Figure 2.2: *Dome-shaped aggregates representing tips of papillary carcinoma Pap stain (x400).*

The second type of papillary structure seen in papillary carcinoma is avascular, three-dimensional, rounded dome-shaped aggregates that may represent the tips of papillae (caps). These are seen in up to 85% of cases [99].

Large **monolayered sheets** of cells are typical of papillary carcinoma, [42,70,74,197] and are present in 33% to 66% of cases, [98,99,197]. The malignant cells in these sheets are relatively large, polygonal and crowded. Three-dimensional, crowded and overlapping syncytial-like aggregates of microfollicles are particularly in contrast characteristic of follicular neoplasms [71,84]. A honeycombed pattern is usually present in goitres, but lost in neoplasia [75,84].

The presence of **microfollicles** on thyroid fine-needle aspiration biopsies can be a diagnostic dilemma and it is therefore of paramount importance to look at the nuclear features to exclude papillary carcinoma especially the follicular variant [104]. Follicular groups are seen in up to 85% of papillary carcinomas [99,197]. According to Miller [99], the presence of three-dimensional cell balls is highly suggestive of papillary carcinoma however, increased cellularity and formation of a microfollicular pattern is predictive of a follicular neoplasm [76]. According to Chu [88] the follicle size in goitres vary from small to large, but are mostly medium to large. Microfollicles are few and the follicular cells are mainly in a regularly spaced, honeycombed pattern. The cells rarely show overlapping or crowding of nuclei.

High cellularity is present in 30% of goitres, colloid is scant in 15% to 20% and a microfollicular pattern is seen in 5% to 10% of cases [32,76]. Cytological features that favour a diagnosis of a follicular neoplasm over a goitre are high cellularity (85% of cases) [44,75] and a microfollicular pattern (80%-90% of cases) [75]. However when these microfollicles are arranged in three-dimensional, crowded, overlapping syncytia it favours a follicular neoplasm [71,88].

2.2.3 Cellular Morphology

The nuclei of follicular cells are the size of a red blood cell and they are round to oval and uniform in size [84]. Enlarged nuclei 3 to 4 times the size of normal follicular cells are a sign of malignancy [84]. **Nuclear crowding/overlapping** occurs in cell groups of papillary carcinoma. In a study by Manju [206], 55 of 59 follicular variant of papillary carcinoma showed nuclear crowding/overlapping. The presence of extremely crowded three-dimensional groups of disorganized follicular cells and markedly irregular follicles are characteristic of follicular carcinoma [84,94].

Grooved nuclei are an important nuclear feature of papillary carcinomas [9]. According to Scopa [103] they are present in most fields. The **irregular nuclear membrane** with folds resembles a coffee-bean and this feature is more prominent in fine-needle aspiration biopsies than histology sections [100,101]. Almost all cases of papillary carcinoma, whether papillary or

follicular variant, have these nuclear grooves [9,98]. In a study by Manju [206] nuclear grooves were present in 54 of 59 cases of follicular variant of papillary carcinoma. In 10 of 54 cases it was only focally present. However, grooved nuclei may be focally present in other thyroid lesions such as thyroiditis, nodular hyperplasia, follicular adenoma and follicular carcinoma.

Associated with the nuclear membrane irregularity is the formation of **intra-nuclear cytoplasmic inclusions (INCIs)**, wherein the nuclear grooves invaginate and enclose a portion of cytoplasm [26]. Intranuclear cytoplasmic inclusions are found in up to 90% or more cases of papillary carcinoma [98,99,197] and according to Lew [97] and Rosai [26] are the most pathognomonic cytological feature of carcinoma. True inclusions are large and occupy one third to one half of the nuclear area. They have sharp margins without any ingested cytoplasmic material. In the study by Manju [206] intranuclear cytoplasmic inclusions were present in 49% of follicular variant of papillary carcinomas and similar findings were reported by Fulciniti [35] and Jogai [102].

Intranuclear cytoplasmic inclusions (INCIs) can be seen in other primary thyroid diseases such as giant and spindle cell carcinoma, medullary carcinoma and insular carcinoma. In addition INCIs are very common in Hürthle cell neoplasms [99,103], but occur rarely in follicular carcinomas [103,107]. Benign diseases that reportedly show nuclear pseudoinclusions include nodular hyperplasia and Hashimoto's thyroiditis [80], [99]. According

to Geisinger [8] nuclear degeneration can be mistaken for intranuclear cytoplasmic inclusions.

The chromatin pattern of papillary carcinoma is generally powdery, finely granular and pale thus **hypochromatic** [21,26]. On the Papanicolaou stain the nuclei appear washed out. This feature is in contrast with the chromatin seen in normal follicular cells, hyperplasia and follicular neoplasms, which is usually distinctly granular and moderately **hyperchromatic** [26].

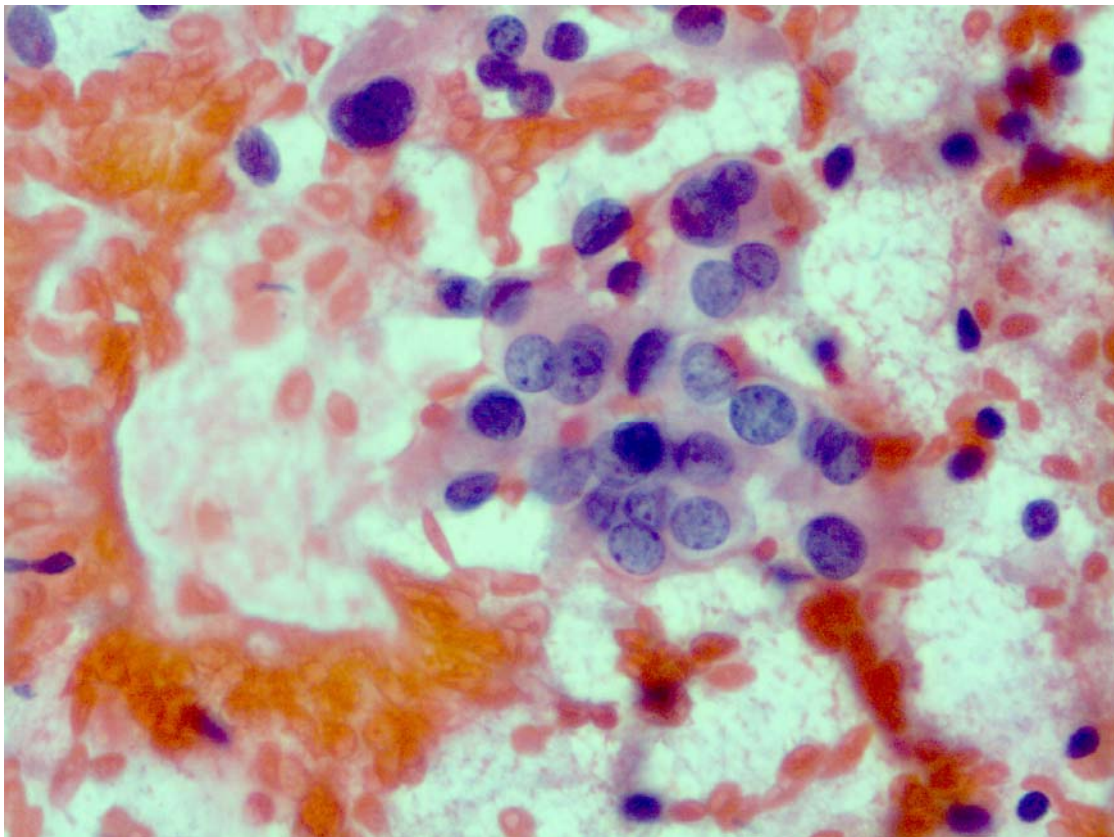


Figure 2.3: *Pale, hypochromatic nuclei with small eccentric nucleoli in papillary carcinoma. Pap stain (x400).*

The cytoplasm of neoplastic cells in papillary carcinoma is variable. It can be delicate, but in 66%-100% of cases there is increased **cytoplasmic density**

in some of the cells [99]. According to Miller [99], the cytoplasm is homogenous, dense or squamoid in appearance with well-defined cytoplasmic borders. In follicular variant of papillary carcinoma the cytoplasm may be finely granular. Manju [206] reported the presence of marginal vacuoles in 30% of follicular variant while a study by Das [217] demonstrated vacuoles in 50% of cases.

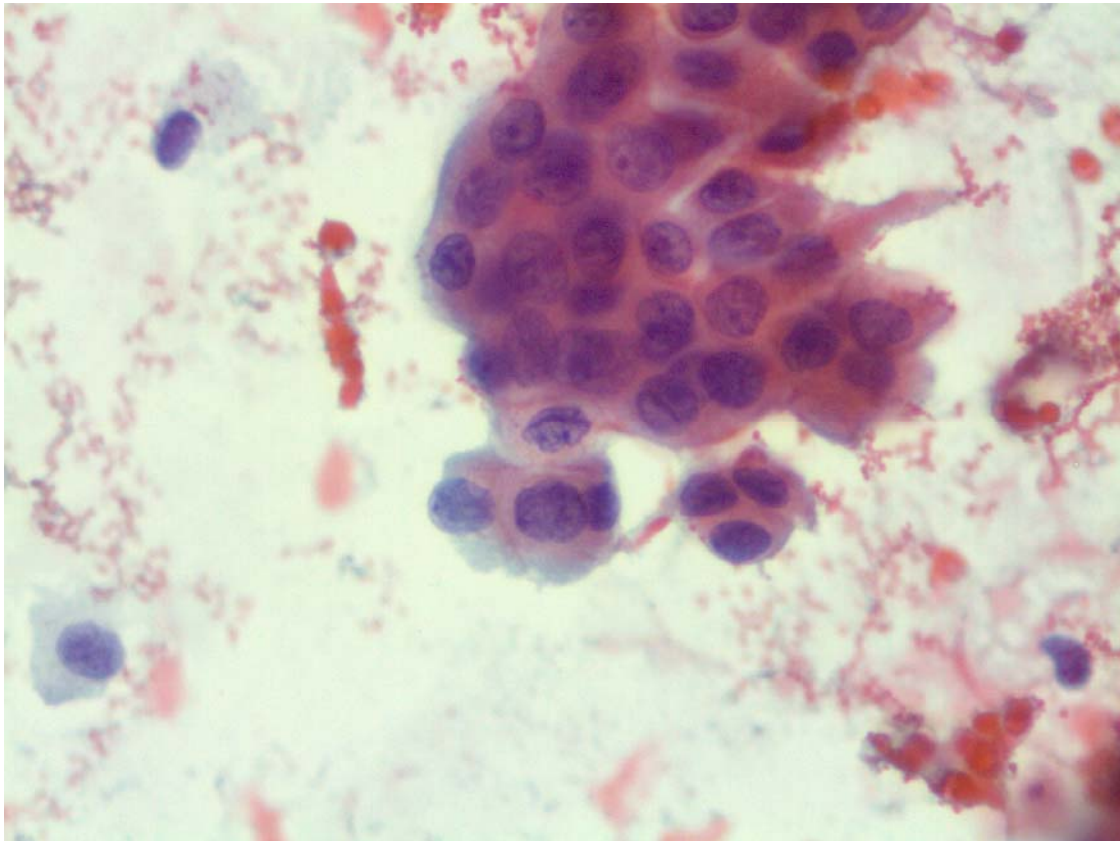


Figure 2.4: *Monolayered sheets with dense cytoplasm, nuclear membrane irregularity and nuclear grooves in papillary carcinoma. Pap stain (x400).*

Follicular neoplasm does not exhibit a dense cytoplasmic appearance. However, metaplastic cytoplasm may also be seen in benign thyroid conditions such as the hyperplasias, particularly the degenerated cystic hyperplasias and thyroiditis [76,92].

Papillary carcinoma typically has 1 to 4 small but conspicuous **nucleoli** and they tend to be marginated when compared to the more prominent, single central nucleoli of follicular carcinomas [26]. Some papillary carcinomas may have large central nucleoli [21,26]. Prominent or multiple nucleoli in most cells are suggestive of a carcinoma, but their absence does not exclude malignancy [94]. The **nucleoli** of normal follicular cells are mostly inconspicuous [84].

Nuclear **pleomorphism** is mild to moderate in papillary carcinoma [8]. The neoplastic nuclei are oval, uniform and larger than normal follicular cell nuclei. Nuclear enlargement was present in 100% follicular variant of papillary carcinoma in a study by Manju [206].

Several studies Basu [76] and Miller [99] have been performed to identify key diagnostic criteria for papillary carcinoma. The features most commonly present (when used in combination) in fine-needle aspiration biopsy are intranuclear cytoplasmic inclusions, nuclear grooves, dense squamoid cytoplasm and papillary architecture [76,99,197]. The presence of one of these features is highly suggestive of papillary carcinoma, but when all four features are present the diagnosis of carcinoma is almost certain [76,99].

2.3 MATERIALS AND METHODS

The study cohort was a retrospective computerized search of thyroid fine-needle aspiration biopsies performed on patients with papillary carcinomas

and multi nodular goiters received over a period of 9 years (1996 to 2005) at the Cytology Laboratory, NHLS, Tygerberg Hospital.

A total of 61 patients, with a mean age of 45 years, were investigated. The inclusion criteria were well-preserved, well-stained smears with histological confirmation. The exclusion criteria were poorly stained and preserved smears or blood obscuring the cells, and no subsequent histology.

These fine-needle aspiration biopsies (FNAB) had been performed by trained cytopathologists, clinicians and registrars at our institution using palpation and without ultrasonic guidance. Aspirations were performed with a 22-25 gauge needle attached to a 10 ml syringe. The skin was disinfected and two to four passes were performed depending on adequacy of material aspirated.

The aspirated material was spread onto glass slides and half the smears were immediately fixed with an ether-alcohol-based cytological fixative Fencott (Sangene Products, C.T. RSA) for routine Papanicolaou staining. The rest were air-dried for routine Diff-Quik (Clinical Sciences Diagnostic CC, Glenanda, South Africa) or May-Grünwald Giemsa (MGG) staining.

The investigation involved the blind microscopic review of these cases by 2 independent investigators. At least 4 slides per case were reviewed without knowledge of the previous diagnosis. Sixteen different cytological features such as background, architecture and cellular morphology were quantitatively assessed, scored and the data recorded.

The **background features** included abundant colloid, bubblegum colloid, psammoma bodies, giant cells, and haemosiderin laden macrophages. The **architectural features** were microfollicles, true papillae and monolayered sheets. The **cellular morphology** included hyperchromasia, hypochromasia, pleomorphism, intra-nuclear cytoplasmic inclusions, nuclear grooves, nuclear crowding/overlapping, multiple nucleoli and dense squamoid cytoplasm. The presence of any feature scored 1 and their absence was recorded as 0.

A numerical value based on the sum of the individual values was calculated for each case. Analysis of our data demonstrated numerical values between 2 and 8. The sensitivity/specificity of the scores was statistically evaluated using the histology diagnosis as a gold standard. Total scores indicating a benign or malignant diagnosis were calculated by using the Receiver Operating Curve (ROC). Pearson's chi-square test was used to test the potential of each variable to differentiate between the scores and only 14 of the 16 variables were included in the statistical analysis for developing a scoring system. The variables psammoma bodies and hyperchromatic nuclei were statistically not relevant as they were present in only 2 and 1 case respectively.

2.4 RESULTS

Fine-needle aspiration biopsies of 61 patients with histologically proven papillary carcinomas (28 cases) and multi nodular goiters (33 cases) were reviewed. The study included 57 females (93%) and 4 males (7%). Their ages

ranged from 19 to 78 with a mean of 45 years. The initial cytological and histological diagnoses are displayed in Table 2.1.

Table 2.1: Results of the cytological and histological diagnoses.

	MNG	Follicular/oncocytic neoplasms)	Papillary carcinoma	Total
Cytology diagnosis	12	29	20	61
Histology diagnosis	33	0	28	61

The malignant cases included 15 papillary carcinomas and 13 follicular variant of papillary carcinomas. The cytology diagnoses of 61 cases were 12 multinodular goiters, 29 follicular and/or oncocytic cell neoplasms and 20 papillary carcinomas (Table 2.1).

After reviewing 61 cases, a numerical score was allotted to each case. The p -values of the Chi-square tests were used as guideline for determining which variables were statistically significant. A cut-off of $p < 0.001$ was used for inclusion. The p -values of the 14 relevant variables are displayed in Table 2.2.

Table 2.2: The univariate comparisons of all the variables with benign or malignant diagnoses.

Cytologic variables	Chi-square <i>p</i>-value
Abundant colloid (benign)	< 0.001
Bubblegum colloid (malignant)	< 0.001
Multinucleated giant cells (malignant)	< 0.007
Haemosiderin laden macrophages (benign)	< 0.003
Microfollicles (malignant)	< 0.445
Papillary groups (malignant)	< 0.001
Monolayer sheets (malignant)	< 0.001
Hypochromasia (malignant)	< 0.001
Pleomorphism (malignant)	< 0.001
Intranuclear cytoplasmic inclusions (malignant)	< 0.001
Nuclear grooves (malignant)	< 0.001
Nuclear crowding/overlapping (malignant)	< 0.001
Multiple nucleoli (malignant)	< 0.047
Dense cytoplasm (malignant)	< 0.001

Ten of fourteen variables had a cut-off of $p < 0.001$ (Table 2.2). The four variables that were statistically insignificant were multinucleated giant cells ($p < 0.007$), haemosiderin laden macrophages ($p < 0.003$), microfollicles ($p < 0.445$) and multiple nucleoli ($p < 0.047$) and therefore not included in the scoring system.

The 10 variables that were statistically significant ($p < 0.001$) were abundant colloid, bubblegum colloid, papillary groups, monolayer sheets, hypochromasia, pleomorphism, nuclear grooves, intranuclear cytoplasmic inclusions, nuclear crowding/overlapping and dense cytoplasm (Table 2.2). Six of 10 features were cytomorphological, 2 background and 2 architectural.

Table 2.3: The 10 variables in the 28 papillary carcinomas.

Cytological Features	Malignant Histological Diagnosis		
	Classic PC (n=15)	FVPC(n=13)	TOTAL(n=28)
Hypochromasia	15	13	28 (100%)
Nuclear crowding/overlapping	15	13	28 (100%)
Nuclear grooves	15	12	27 (96%)
Dense cytoplasm	13	8	21 (75%)
Papillary groups	15	5	20 (71%)
Nuclear pleomorphism	10	10	20 (71%)
Bubblegum colloid	11	5	16 (57%)
INCIs	12	3	15 (54%)
Monolayer sheets	7	1	8 (29%)
Colloid	0	6	6 (21%)

In our study the 4 variables that were the most predictive of papillary carcinoma were hypochromasia (100%), nuclear crowding (100%), nuclear grooves (96%) and dense cytoplasm (75%).

In the statistical analysis the receiver operating curve (ROC) demonstrated that the cut-off point between a benign and malignant diagnosis was 4 (Figure 2.5). The analysis showed a cytological numerical score < 4 was indicative of a benign multinodular goitre and a score ≥ 4 indicative of a papillary carcinoma (including follicular variant). Figure 2.5 displays the relationship between the cut-off point and the histological diagnosis for the 28 papillary carcinomas.

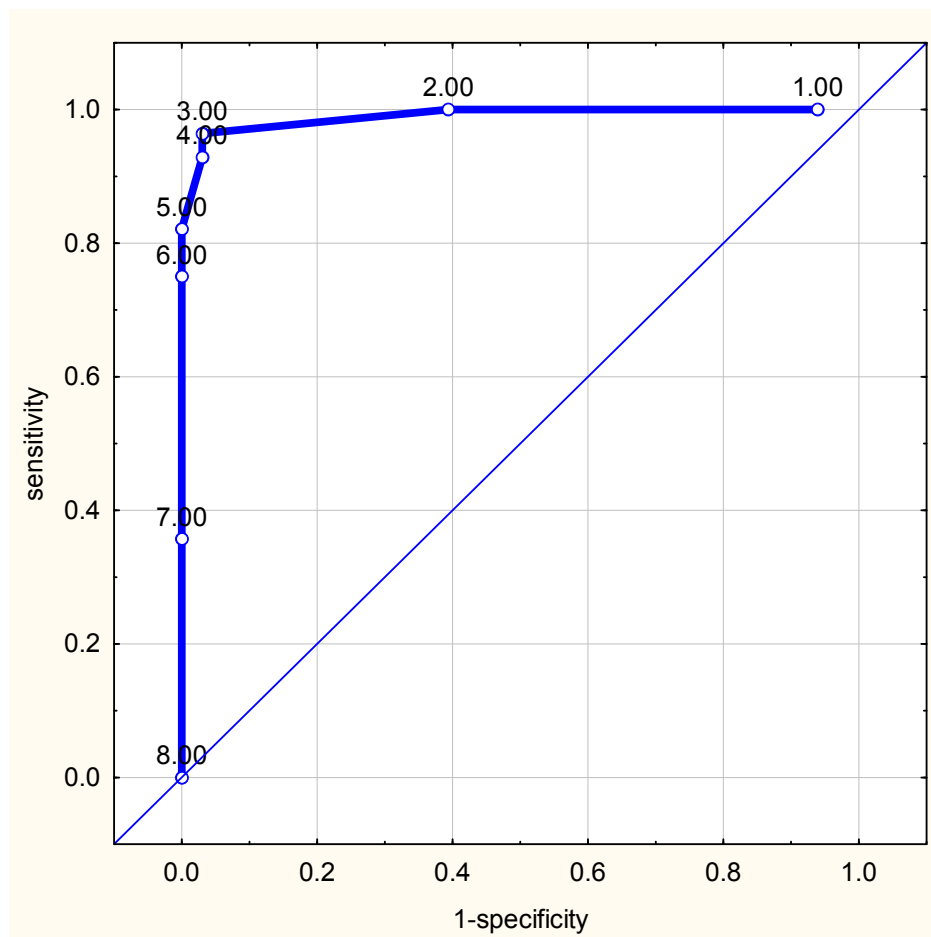


Figure 2.5: The ROC displays an optimal cut-off point of >3 for papillary thyroid carcinoma.

The sensitivity and specificity for malignancy and benignancy are displayed in the histograms in figure 2.6. The histogram on the left side of figure 2.6 shows a sensitivity of 96% with a score ≥ 4 for a papillary carcinoma (including the follicular variant), while the histogram on the right side shows a specificity of 97% with a score < 4 for a benign multinodular goiter.

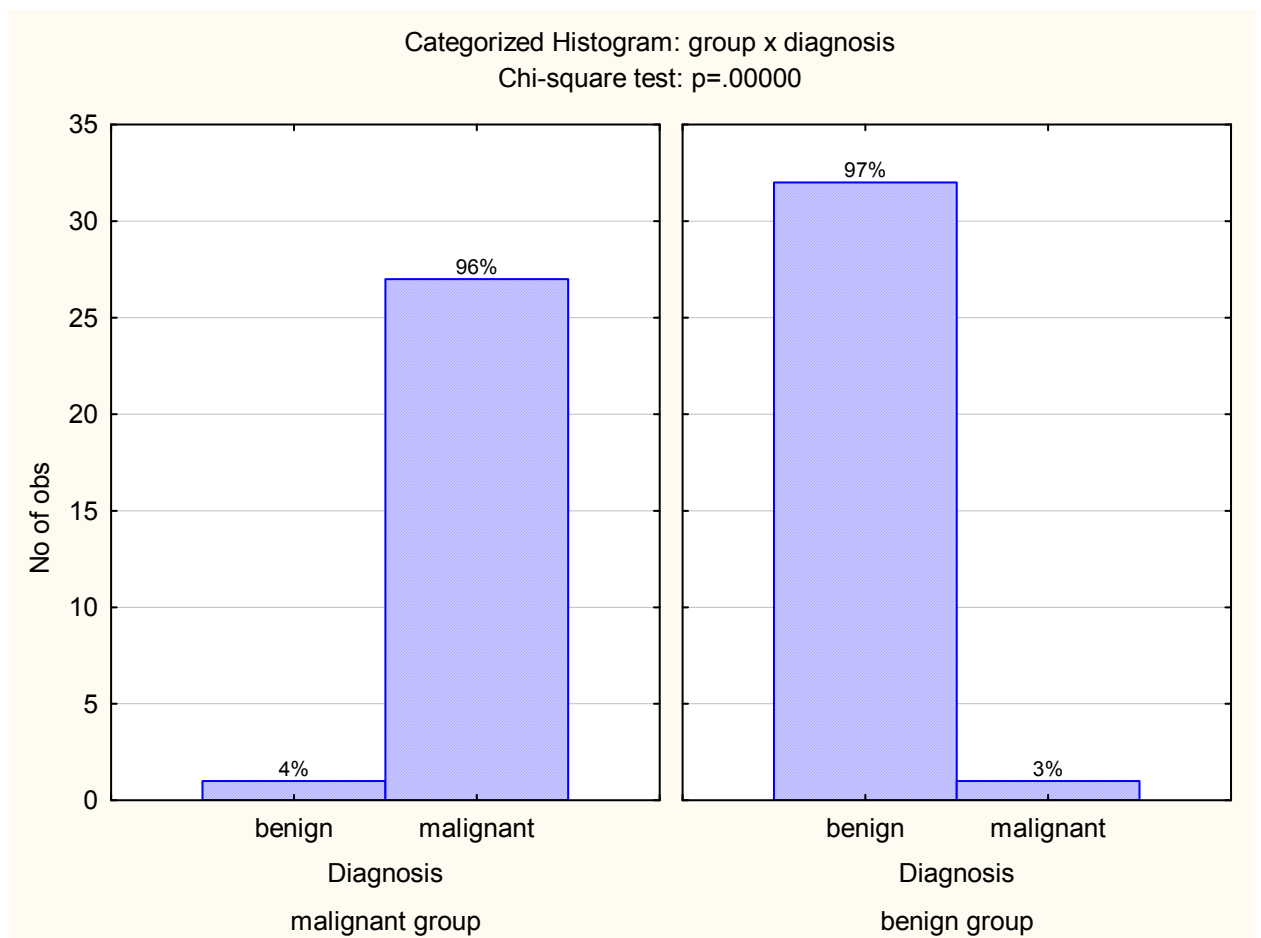


Figure 2.6: The histograms display the sensitivity (left panel) and specificity (right panel) for the 28 papillary carcinomas.

In figure 2.7 the statistical analysis between the numerical scores of the classic papillary carcinoma and the follicular variant are illustrated. Figure 2.7 shows the total cytological scores for the 28 papillary carcinomas. The mean score for 15 classic papillary and 13 follicular variant of papillary carcinoma was 7, 5 and 6 respectively.

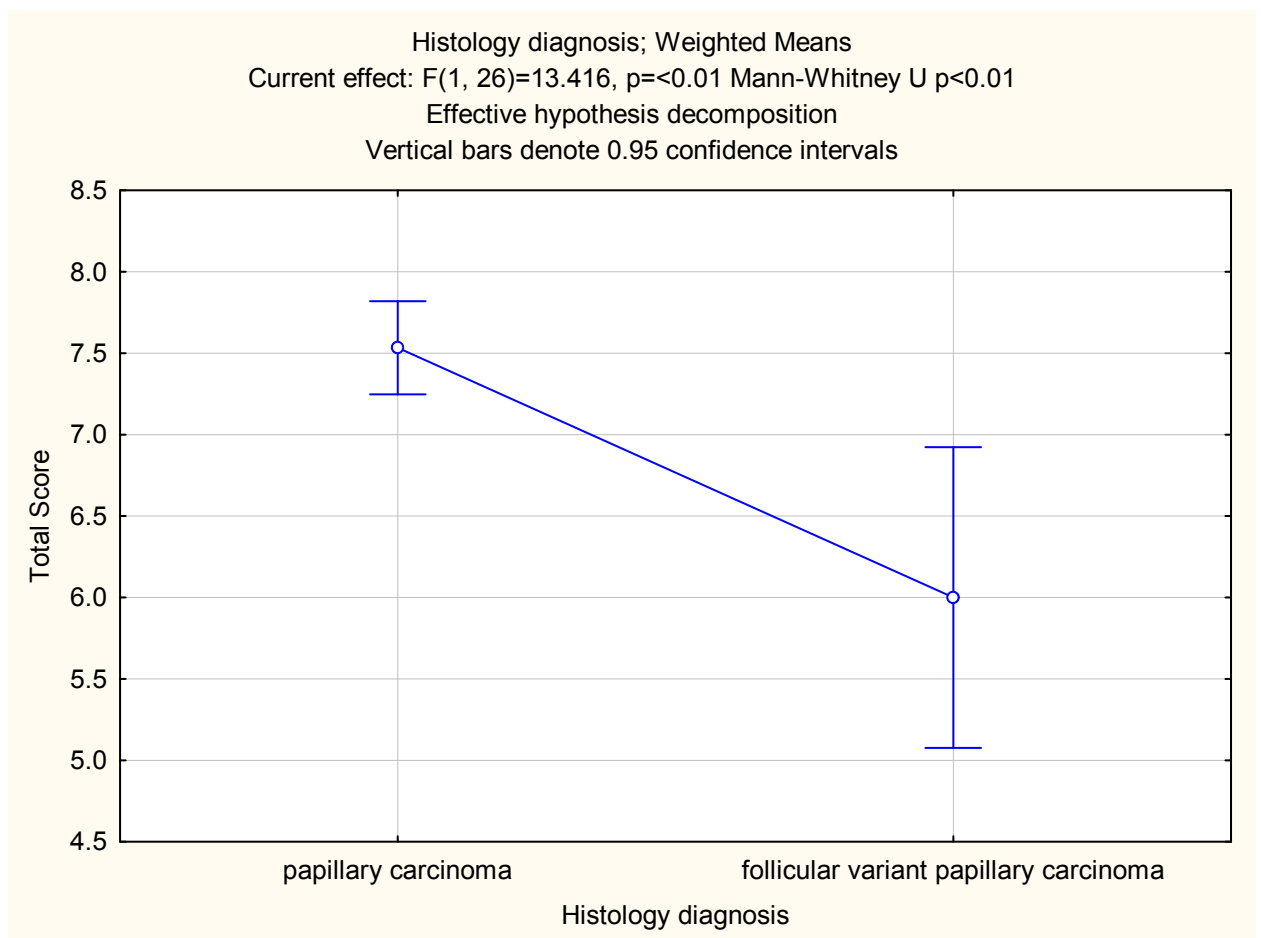


Figure 2.7: The mean score for 15 papillary carcinomas and 13 follicular variant of papillary carcinomas was 7, 5 and 6 respectively.

2.4.1 Cyto/histological Correlation

A total of 61 cases were evaluated in this study. The initial cytological diagnosis was 12 multinodular goiters, 29 follicular and/or oncocytic cell neoplasms and 20 papillary carcinomas. The corresponding histological diagnoses were 33 multinodular goiters and 28 papillary carcinomas (Table 2.1).

Table 2.4: Results of initial cyto/histological concordance.

Histological Diagnosis	Initial Cytological Diagnosis		
	Malignant(n=20)	Follicular Neoplasms(n=29)	Benign(n=12)
Multinodular Goiter(n=33)	1	23	9
Papillary Carcinoma(n=28)	19	6	3

Cytology only initially definitively identified 19 of 28 histologically proven papillary carcinomas, and a further 6 were called follicular and/or oncocytic neoplasms. The remaining 3 cases were diagnosed as non-neoplastic lesions. An interesting observation is that cytology could only correctly subclassify 2 of 13 histologically proven follicular variant of papillary carcinomas.

2.4.1.1 Cytological False Positive Diagnoses

Original cytology correctly identified 9 of the 33 (28%) histologically proven multinodular goiters. Cytology diagnosed 1 case (false positive) as atypical papillary cells and for statistical reasons the diagnosis of atypical papillary cells was included in the malignant category. The results are displayed in Table 2.4.

2.4.1.2 Cytological False Negative Diagnoses

Original cytology could identify 19/28 (68%) papillary carcinomas and if the 6 follicular and/or oncocytic neoplasms are included 25/28 (89%) neoplasms, necessitating surgical removal (Table 2.4). The 3 cases that were false negative and cytologically diagnosed as multinodular goiters were all histologically proven **follicular variants of papillary carcinoma**. After reviewing and application of the scoring system, a score of 3, 5 and 7 were respectively allocated to these cases, reclassifying 2/3 of them as papillary carcinomas.

On review, the cytological features present in the case that scored 5, were abundant colloid, hypochromasia, pleomorphism, nuclear grooves and nuclear overlapping/crowding. The features present in the case that scored 7 were abundant colloid, monolayered sheets, hypochromasia, pleomorphism,

intranuclear cytoplasmic inclusions, nuclear grooves and nuclear crowding/overlapping. In the case that scored 3 the features present were hypochromasia, nuclear crowding/overlapping and pleomorphism.

2.4.1.3 Cyto/histological concordance after application of scoring system

Table 2.5 illustrates the correlation of cytology with histology after application of the developed scoring system. The application of the scoring system clearly improves the diagnostic accuracy of cytology (See discussion below).

Table 2.5: *Cyto/histological concordance after application of scoring system*

Histological Diagnosis	Cytological Diagnosis	
	Malignant	Benign
Multinodular Goitre (n=33)	0	9 + 24 = 33
Papillary Carcinoma (n=28)	25 + 2 = 27	1

2.5 DISCUSSION

Fine-needle aspiration biopsy has been established as a highly accurate procedure in diagnosing papillary carcinoma, with a sensitivity of > 90% in

some studies [2]. However, the efficacy of cytology in diagnosing follicular variant of papillary carcinoma is controversial [98,204].

According to LiVolsi [9], Chhieng [188], Baloch [24] and Nayar [202], the diagnosis of papillary carcinoma in fine-needle aspiration biopsy specimens is made on the basis of nuclear features which include enlarged and elongated nuclei with nuclear chromatin clearing (hypochromatism), intranuclear cytoplasmic inclusions, nuclear grooves and small eccentric nucleoli.

However, according to Basu [76], Miller [99] and Kini [197], the most sensitive combination of criteria for diagnosing papillary carcinoma has been shown to be intra-nuclear cytoplasmic inclusions, nuclear grooves, papillary structures of cell balls and dense, metaplastic cytoplasm. These 4 criteria were included in our 10 scoring variables, but the 4 variables most sensitive for papillary carcinoma (including the follicular variant) in our study were nuclear hypochromasia (100%), nuclear crowding/overlapping (100%), nuclear grooves (96%) and dense cytoplasm (75%) (Table 2.3).

A feature observed in both histologic and cytologic specimens of benign thyroid lesions such as nodular goiter and lymphocytic thyroiditis are **nuclear chromatin clearing (hypochromasia)** [103], [218], [219]. By review and scoring this feature was present in 14/33 (42%) of the histologically proven multinodular goiters. After scoring and analysis, hypochromasia was present

in 100% of classic papillary (15/15) and follicular variant of papillary carcinomas (13/13) in our study (Table 2.3).

Nuclear crowding/overlapping occurs in cell groups of carcinoma and this feature was present in 100% (15/15 classic and 13/13 follicular variant) of cases in our study. Similar findings were reported by Manju [206]. In their study 55 of 59 (93%) follicular variants showed nuclear crowding and overlapping. A possible explanation for the sensitivity of nuclear crowding/overlapping in our study was the inclusion of 13 follicular variants of papillary carcinoma.

Some of these nuclear features; especially **nuclear grooves** can be seen in both histologic and cytologic specimens of benign thyroid lesions such as nodular goiter and lymphocytic thyroiditis [103,218,219]. Several investigators have studied the significance of nuclear grooves in the diagnosis of papillary carcinoma in histologic tissue sections [103] and cytologic specimens [219-221]. In our study, nuclear grooves were observed in the smears of 1 case of a histologically proven multinodular goitre, but were also present in 97% of papillary carcinomas (15/15 classic and 12/13 follicular variant) (Table 2.3).

Scopa [103] found nuclear grooves in 5 Hürthle cell adenomas and 4 Hürthle cell carcinomas as well as 35 follicular adenomas and 8 follicular carcinomas. Furthermore 4 medullary carcinomas and 2 undifferentiated carcinomas also

presented with nuclear grooves. In Scopa's study the nuclei of benign nodules such as Hashimoto's thyroiditis (5 cases), diffuse hyperplasia (5 cases) and adenomatous hyperplasia (1 case) also displayed grooves. However, in their study none of the cases of nodular goiter had any nuclear grooves.

In a similar study by Francis [219], nuclear grooves were present in 100% of papillary carcinomas but also in 88,2% of follicular neoplasms, 100% of Hürthle cell neoplasms, 85,7% of medullary carcinomas, and 75% of colloid goiters and in 100% of toxic goiters, chronic lymphocytic thyroiditis and subacute thyroiditis.

In our study the presence of **papillary structures** (71%) was not one of the 4 most sensitive criteria for diagnosing papillary carcinoma overall. A possible explanation for this is the inclusion of 13 follicular variants of papillary carcinoma. Papillae were present in 15/15 classic papillary carcinomas, and in addition in 5/13 follicular variants (Table 2.3)

The presence of **intranuclear cytoplasmic inclusions (INCIs)** has been said to be a hallmark of papillary carcinomas [76,99,197]. In our study intranuclear cytoplasmic inclusions were present in 15/28 (54%) of papillary carcinomas. Twelve of 15 (80%) classic papillary carcinoma exhibited intranuclear cytoplasmic inclusions while only 3/13 (23%) follicular variant papillary carcinomas showed intranuclear cytoplasmic inclusions.

Abundant colloid is associated with benign lesions [2] and if present could be a diagnostic pitfall. The presence of abundant colloid was a feature in 6/13 (46%) follicular variants of papillary carcinoma in our study while no classic papillary carcinomas showed this feature.

Furthermore 2 of the 3 false negative cases had abundant colloid present in the background. These 2 cases were initially diagnosed as multinodular goiters, but after review and classification scored 5 and 7 respectively, indicating a papillary carcinoma. Both these cases were histologically proven follicular variants of papillary carcinomas.

Similar findings were reported by Nair [204]. Their study demonstrated that less than 30% of the follicular variant of papillary carcinoma was correctly identified on fine-needle aspiration biopsy. The diagnostic challenge of the follicular variant on fine-needle aspiration biopsy was also supported by Wu [205]. They performed a study to determine the minimal cytological criteria needed to identify follicular variant of papillary carcinoma in order to reduce false negative diagnoses. Fine chromatin, nuclear grooves and colloid was seen more often in follicular variant of papillary carcinoma than in other follicular neoplasms ($p < 0.01$). The combination of flat monolayer sheets, nuclear enlargement and fine chromatin was observed in all follicular variants and therefore these criteria were considered as sensitive markers [205]. In

their study logistic regression analysis revealed that the amount of colloid was the only predictor in favour of the follicular variant over classic papillary carcinoma.

The histological appearance of follicular variant of papillary carcinoma overlaps with benign and neoplastic follicular lesions such as adenomatoid nodule, follicular adenoma and follicular carcinoma. According to Harach [32] and Rosai [25] the diagnosis of the follicular variant is solely dependant on nuclear features such as oval, enlarged, overlapped nuclei with an optically clear or ground-glass appearance with nuclear grooves and intranuclear cellular inclusions.

Studies by Manju [206] and [102] supported these findings that follicular variant of papillary carcinoma is a diagnostic pitfall on fine-needle aspirations. Follicular carcinomas are over-diagnosed and often misinterpreted as either benign or malignant lesions, particularly the follicular variant of papillary carcinoma [199]. This finding was supported in a study by Das [217]. All 10 cases of follicular variant of papillary carcinomas were missed during the initial diagnosis by fine-needle aspiration cytology. These cases were only correctly identified on review.

Cystic lesions under diagnosed as benign, are a common cause of a false-negative diagnosis. According to Ashcraft [14] the majority of cysts is benign and when focal atypia and cellularity is present this may cause a diagnostic problem. These findings were supported by Caranqui [15].

Cellularity in cysts may be scant. Foamy macrophages, giant cells, cholesterol clefts, haemosiderin laden macrophages, reparative stromal cells and degenerated debris predominates the aspirate. According to Hsu [87], abundance in macrophages may be a sign of cystic degeneration. This is a general finding is in goitres [42], but rare in follicular neoplasms. In this study a numerical score of 1 was selected when heamosiderin ladin macrophages were present in at least 50% or more of the background area.

Up to 50% of cystic papillary carcinomas may be missed on fine-needle aspiration smears [18], [19], [20]. A careful search for the nuclear features is essential because degeneration of malignant cells may look histiocytic [202].

A recent study by Nassar [203] supported these findings. They concluded that histiocytic cells in cystic goiterous nodules can show nuclear features which appear similar to papillary carcinoma nuclei. The histiocytic nature of the cells in Nasser's study was confirmed by CD68 immunostaining on the Pap-stained smears. The histiocytic cells showed strong cytoplasmic expression for CD68, whereas all follicular cells showed no expression.

In this study the presence of giant cells as well as multiple nucleoli was statistically insignificant ($p >.001$) and therefore not included as variables for developing the scoring system.

The potential for false-negative results is extremely worrisome, as any delay in the diagnosis of cancer may have morbid consequences [224]. The false-negative rate for fine-needle aspiration of the thyroid varies from 1.3%-11.5% and repeat FNAB after an initially benign or inadequate aspiration yields the correct diagnosis in approximately half of the cases [224]. These findings are corroborated by Gharib [78] and Chehade [225]. They reported that repeat aspirations increases the yield and therefore reduces the false negative diagnosis rate. Conscientious clinical follow-up of thyroid nodules and repeat aspirations performed in cases of inadequate specimens or persistent nodules is important [224]. In a study done by Cramer [226] and Ljung [227] they showed that the sensitivity of fine-needle aspiration can be markedly affected by operator training and the experience at a given institution.

However, false positive diagnosis of papillary carcinoma can occur if only the nuclear morphological features are taken into consideration. In a recent study by Renshaw [23] focal features of papillary carcinoma on fine-needle aspiration biopsies were studied. In their study only 15 of 28 cases diagnosed on cytology with papillary carcinoma had histologically proven papillary carcinoma resulting in a cytological false positive diagnosis in 13 cases. Caution is warranted against over-interpretation of nuclear features leading to false positive diagnoses.

This study revealed cyto/histological concordance in 9 of 33 histologically proven multinodular goitres. One case (cytologically diagnosed as atypical cells) had abundant colloid, monolayered sheets and crowded nuclei. Only one of these features was morphological while the other 2 were background and architectural features. Twenty three histologically proven multinodular goitres were diagnosed on cytology as follicular and/or oncocyctic neoplasms and 6 papillary carcinomas were diagnosed as follicular neoplasms (5 follicular variant). In this study 29/61 cases were incorrectly diagnosed as follicular neoplasms, but the true number of false positive cases was 23/61.

The cytological diagnostic dilemma of follicular variant of papillary carcinoma was also demonstrated in a study by Jogai [102]. In their study they attempted to find the level of histocytological concordance, discordance, possible reasons for discordance and ways in which it could be minimized. In all except 1 case, the diagnosis of classic papillary carcinoma could be made, however in 12 cases of histologically proven follicular variant of papillary carcinoma an initial cytological diagnosis could not be made. Jogai [102] concluded that a possible reason for this was that more emphasis was put on nuclear features than on the architectural pattern in their study.

Fine-needle aspiration biopsy of the thyroid is a sensitive tool for making the correct diagnosis in many different lesions. The need for surgery can be obviated in a great number of cases, proving it to be a cost-effective technique in the over-all management of thyroid nodules. An area of particular difficulty is the diagnosis of cystic papillary carcinoma and follicular variant of papillary carcinoma. The reasons for false positive or negative diagnoses include the presence of overlapping cytological features. Improper sampling and over interpretation of cytology findings can also lead to a false negative and false positive diagnosis, respectively.

2.6 CONCLUSION

Despite numerous clinical parameters evaluated [24,109] and various scoring systems [146,147] developed to enable risk-group stratification for patients; none of these could with accuracy be applied to thyroid fine-needle aspiration cytology. Fine-needle aspiration of thyroid lesions presents an continuing challenge, particularly when repeated aspiration fails to yield an adequate specimen.

Several researchers proved that fine-needle aspiration is highly specific in diagnosing papillary carcinomas with an estimated accuracy of 94% [99,197]. After review and application of the scoring system that we developed, our study demonstrated a sensitivity of 96% and specificity of 97% for diagnosing papillary carcinoma. Only 1 papillary carcinoma scored < 4 (score = 3) on review and classification.

Statistical analysis of the data showed that 10 cytological features: abundant colloid, bubblegum colloid, papillary groups, monolayer sheets, hypochromasia, pleomorphism, nuclear grooves, intranuclear cytoplasmic inclusions, nuclear crowding and dense cytoplasm were significant in distinguishing papillary carcinoma from multinodular goiter (p -value < 0.001). Two of 10 statistically selected variables were background features, 2 architectural and 6 cytomorphological features. Five of 6 cytomorphological features were nuclear and 1 cytoplasmic. These findings are supported by various studies in the literature.

This research has shown that cytomorphologic features are still a valuable tool in diagnosing benign and malignant lesions, but that these need to be used in combination and not in isolation. Increased specificity may be achieved by careful attention to cytological features and morphological detail. One area where the scoring system was particularly useful was in the diagnosis of follicular variant of papillary carcinoma and multinodular goitres.

The value of this scoring system lies in the potential for providing an objective and reproducible method that can aid the cytopathologist in enhancing the diagnostic accuracy of fine-needle aspiration biopsy of multinodular goiters, papillary carcinoma and moreover the follicular variant of papillary carcinoma. There may be a substantial degree of subjectivity and disagreement in making a final diagnosis by only using the scoring system in isolation. It is advisable that cytopathologists should always take the clinical features and radiological imaging into consideration before making a diagnosis.

Decisions cannot be based on scoring systems only, because they may be applied differently in various institutions and misinterpretations may occur. According to Yeh [224] fine-needle aspirations interpreted by cytopathologists at major centers were more sensitive than those performed elsewhere. Although fine-needle aspiration is a useful test, false-negative results remain a concern in the diagnosis for cancer and clinical findings should overrule cytologic data in order for timely treatment to occur [224].

This study showed that it is possible to cytologically distinguish papillary carcinoma from a multinodular goiter using a scoring system, taking into account many features which individually have been demonstrated to be statistically significant. The study numbers are however small.

In addition this study only dealt with the distinction between papillary carcinoma and multinodular goiter. The value of distinguishing papillary carcinoma from follicular neoplasm must still be assessed. A diagnosis of follicular neoplasm warrants excision of the nodule, but a diagnosis of papillary carcinoma warrants partial or total thyroidectomy with possible regional node dissection [267].

The diagnosis of papillary carcinoma on fine-needle aspiration biopsy has significant implications for the patient while the diagnosis of follicular neoplasm necessitates further diagnostic evaluation prior to definitive surgery.

CHAPTER 3

APPLICATION OF IMMUNODIAGNOSTIC MARKERS **GALECTIN-3 AND HBME-1 TO HISTOLOGICAL SECTIONS** **AND CORRESPONDING CYTOLOGY SMEARS**

3.1 INTRODUCTION AND LITERATURE REVIEW

Fine-needle aspiration biopsy (FNAB) is widely used to differentiate benign from malignant thyroid nodules. However, the interpretation of follicular lesions in thyroid aspirates has been a diagnostic pitfall for cytopathologists based on the overlapping cytological features between benign and malignant thyroid follicular lesions, the limited number of cases in most individual institutions and the fact that definitive diagnosis of follicular carcinoma requires capsular and/or vascular invasion, which can only be determined on histology [80,134].

The diagnosis of thyroid tumours is critical for clinical management: however, tumours with follicular architecture often present diagnostic and management problems [196]. Well-differentiated encapsulated tumours of the thyroid with a follicular architecture may cause diagnostic difficulties on histology due to the presence of incomplete or equivocal capsular penetration. This may induce the suspicion of follicular carcinoma. The occurrence of focal nuclear changes such as clearing, overlapping, grooves and intranuclear cytoplasmic

inclusions, may raise the possibility of the follicular variant of papillary carcinoma [159]. Depending on the grade of atypia in these cases and the bias of the observer, terms such as atypical adenoma, 'hybrid carcinoma, and - more recently – well-differentiated carcinoma not otherwise specified' were proposed [228-230].

A recent study by Hirikawa [231] compared the histological diagnosis of 21 follicular nodules by four American and four Japanese pathologists and showed concordance with regard to a benign versus malignant diagnosis in only 62% of the nodules. A review of 200 thyroid tumours by seven Italian pathologists revealed good concordance for papillary and anaplastic carcinomas, moderate for medullary carcinomas and poor for follicular carcinomas [232]. In another review of 41 follicular carcinomas by five experienced French pathologists, the concordance for malignancy varied from 5% amongst all five pathologists to 56% between two pathologists only [233]. Thus, despite well-documented criteria, the diagnostic agreement among pathologists remains poor and this underscores the need for additional diagnostic markers.

3.1.1 Immunochemistry

Immunohistochemistry (IHC) was introduced to the practice of pathology in the early 1970's [149], but in thyroid pathology its use has been largely restricted to the differential diagnosis between follicular and C-cell derived neoplasms [189]. Immunocytochemistry is currently recognised as an

essential and integral aspect of surgical pathology, and during the last two decades, there has been an increasing reliance on immunocytochemistry for the diagnosis, classification, prognosis and, more recently, the determination of specific forms of therapy [234].

Immunodiagnostic markers are monoclonal antibodies with distinct epitopes that distinguish between epithelial, mesenchymal, and hematopoietic cells. Staining is confined to the target cells and is expressed in the cytoplasm, nucleus or cell membrane. Immunochemical staining depending on antigen-antibody specificity is the most common approach adopted to detect specific antigens in tissue sections [149-151].

The detection of new markers of malignancy in the thyroid gland, which may distinguish malignant from benign lesions regardless of the presence of capsular or vascular invasion, is proving interesting [189].

Because of the diagnostic limitations of thyroid fine-needle aspiration biopsies, several **immunocytochemical (ICC)** markers have been investigated to improve the preoperative cytological diagnosis of thyroid nodules (see Chapter 1). These markers of malignancy have been claimed to be useful in distinguishing follicular adenoma from carcinoma and also to identify papillary carcinoma from its variants, both in surgical and cytological specimens [159].

Among these markers Galectin-3 and HBME-1 have been proposed to improve pre-operative diagnosis of thyroid nodules and have shown promising results in predicting malignancy in thyroid lesions [167].

Galectin-3 and HBME-1 have shown the best specificity and sensitivity in discriminating benign from malignant tumours [134,166]. De Matos and colleagues [237] have also demonstrated this in a recent study on tissue sections. HBME-1 was the most sensitive marker (94%) for thyroid malignancy followed by Galectin-3 (72.6%). However, no single antibody has shown enough diagnostic accuracy to be used alone in correctly diagnosing an encapsulated thyroid neoplasm [189].

3.1.1.1 Galectin-3

The galectins are a growing family of proteins, which have been implicated in regulation of cell growth, differentiation, and malignant transformation in a number of tissues [134,173,239]. Lectins are carbohydrate-binding proteins that recognise specific oligosaccharide structures on glycoproteins or glycolipids and facilitate certain cellular functions such as cell-cell and cell-matrix interactions. Alteration of glycoconjugates by glycosyltransferases glycosidases may lead to altered or lost cellular functions and subsequent malignant behaviour [172,173,239].

Increased expression of galectins was shown in transformed thyroid cells and thyroid carcinomas, and the distribution of these proteins in cancer samples

has been shown to localize to tumour cells, but not to the adjacent tissue of the normal thyroid [172,173,239].

Galectin -3 is also expressed in normal breast epithelial cells, inflammatory cells and various other malignant cells. Several investigators have found Galectin-3 expression to be of value in discriminating between benign and malignant thyroid nodules [160,161,172,173,174,239,240].

3.1.1.2 HBME-1

HBME-1 is a monoclonal antibody developed against the microvillous surface of mesothelial cells and has subsequently been applied in diagnosing malignant thyroid neoplasms [167]. It is a protein that is expressed in the cytoplasm or membranes of malignant thyroid cells [241]. The thick membrane staining pattern was shown to be of value in diagnosing malignant mesotheliomas but this marker may also stain other normal tissues [164,242].

HBME1 expression has been reported in papillary and follicular carcinoma, but not in normal thyroid cells [164,166,171]. It stains most mesotheliomas, but is also positive in a small percentage of adenocarcinomas, a fact that limits its diagnostic utility in this setting [167].

3.1.1.3 Usefulness of Galectin-3 and HBME-1 in Immunohistochemical

Literature

HBME-1

A recent study of De Matos [237] concluded that HBME-1 is the most sensitive marker for thyroid malignancy in a panel of three markers (HBME-1, Galectin-3 and CK 19) and is useful to differentiate between lesions with a follicular pattern, especially the follicular variant of papillary carcinoma. These three markers may be useful in specific cases. Immunoreactivity was predominantly seen in the cytoplasm and minimally expressed in the nucleus. Adjacent normal thyroid tissue was consistently negative, although a few sparse follicular cells and macrophages stained with this marker. In this study only 21% of the follicular carcinomas stained positive with HBME-1.

Galectin-3

Chiariotti and colleagues [243] have analysed Galectin-1 and Galectin-3 expression in benign and malignant thyroid tissue. Although Galectin-1 mRNA levels were increased in 28/40 (70%) papillary carcinomas, no change was seen in follicular carcinoma; moreover, Galectin-1 protein levels were positive in all papillary carcinomas. In a second study, Xu and colleagues [172] observed an increase in Galectin-1 and Galectin-3 protein expression in 16/16 (100%) papillary and 7/7 (100%) follicular carcinomas; the normal or benign samples remained negative.

A further study by Orlandi [160] supported these findings. It showed positive Galectin-3 immunoreactivity in 18/18 (100%) papillary and 14/17 (82%) follicular carcinomas, whereas only 3/29 (10%) follicular adenomas stained positively.

Martins [180] also confirmed that Galectin-3 was expressed in 100% of papillary carcinomas and 90% of follicular carcinomas. However, Galectin-3 was also expressed in 45% of the follicular adenomas and 17% of the multinodular goiters. The sensitivity for Galectin-3 expression was 93.8% and the diagnostic accuracy for benign vs. malignant lesions was 77%. The accuracy of Galectin-3 was only 68.9% in distinguishing follicular adenoma from follicular carcinoma.

Along the same lines, the most comprehensive study by Bartolazzi [134] showed immunohistochemical positivity for Galectin-3 in 195/201 (97%) papillary and 54/57 (95%) follicular carcinomas; Galectin-3 was largely negative in 75/75 (100%) normal control cases, 50/50 (100%) hyperplastic lesions, and 121/125 (97%) follicular adenomas. Subsequently, Galectin-3 positivity could even be detected in 17/17 (100%) minimally invasive follicular carcinomas, supporting the view of Galectin-3 as an early marker of thyroid cancer [161].

However, Mehrotra [244] performed a study that demonstrated that Galectin-3 was not a reliable immunohistochemical marker to distinguish benign from

malignant thyroid follicular lesions. The study was on formalin-fixed thyroid tissue sections from 124 patients with a histological diagnoses of papillary carcinoma (n=38), follicular carcinoma (n=19), follicular adenoma (n=32) and dominant nodules in multinodular goitre (n=35). Although Galectin-3 expression was observed in the majority of carcinomas (papillary 92%; follicular 74%), a large proportion of follicular adenomas (72%) and multinodular goitres (75%) also expressed Galectin-3. According to Mehrotra [244], Galectin-3 expression was observed in epithelial cells of normal thyroid tissue and Hashimoto's thyroiditis. Galectin-3 immunopositivity was significantly greater in papillary carcinomas than in dominant nodules or follicular adenomas ($P < 0.0001$, $P = 0.0005$, respectively). However, Galectin-3 expression was no greater in follicular carcinomas than in follicular adenomas ($P = 0.8735$).

Thus, the use of Galectin-3 immunodetection as a molecular marker for thyroid carcinoma must be interpreted with caution, particularly when distinguishing between follicular carcinoma and follicular adenoma [180].

Galectin-3 and HBME-1

In a recent study by De Matos [237] the usefulness of a panel of immunohistochemical markers such as HBME-1, cytokeratin 19 (CK 19) and Galectin-3 was investigated in histology specimens. They evaluated 170 thyroid lesions including 148 neoplastic lesions and 22 non-neoplastic lesions. The neoplastic lesions included 84 papillary carcinomas, 38 follicular

carcinomas, 18 follicular adenomas, 1 hyalinizing trabecular tumour, 5 medullary carcinomas and 2 anaplastic carcinomas. The non-neoplastic lesions included 12 adenomatous nodules and 10 cases of Hashimoto's thyroiditis.

The expression of HBME-1, Galectin-3 and CK19 was 94%, 72.6% and 72.6% respectively in papillary carcinomas and 63%, 21% and 21% in follicular carcinomas. All three markers were mostly negative in all the non neoplastic lesions. The most helpful marker in terms of sensitivity and specificity for the follicular variant of papillary carcinoma and for follicular carcinoma diagnosis was HBME-1. However, if the percentage of positive cells was taken into account, the differentiation between cases of follicular variant of papillary carcinoma and follicular carcinoma or adenoma was more reliable using Galectin-3 and CK19. Follicular variant of papillary carcinoma could be correctly differentiated from other follicular lesions (follicular carcinoma, follicular adenoma or adenomatous nodules) in 80.8%, 79.5% and 71.2% of the cases using Galectin-3, CK19 and HBME-1, respectively [237].

A recent study by Papotti and associates [159] indicated that the pattern of immunohistochemical reactivity for Galectin-3 and HBME-1 in tumours of uncertain malignant potential mirrors the ambiguous morphological differences between follicular adenomas and well-differentiated carcinomas. In their study, the pattern of immunoreactivity for Galectin-3 and HBME-1 for tumours of uncertain malignant potential has no diagnostic value and they feel

that the diagnosis of thyroid tumours of uncertain malignant potential should rests primarily on morphologic criteria as previously defined by Williams [245].

3.1.1.4 Usefulness of Galectin-3 and HBME-1 in Immunocytochemical Literature

HBME-1

Recent results by Ito [246] supported the finding that HBME-1 contributes to the diagnosis of papillary thyroid carcinoma, but it can not be applied in the preoperative diagnosis of follicular carcinoma in fine-needle aspiration biopsies. In their study 37/37 (100%) of papillary carcinomas expressed the marker HBME-1, while only 84/138 (60.9%) of the follicular carcinomas expressed the marker. The marker was also expressed in 30.3% of the follicular adenomas.

Galectin -3

The controversy about the usefulness of Galectin-3 as an immunodiagnostic marker of thyroid malignancies was also demonstrated in a fine-needle aspiration cell block study by Mills and colleagues [247]. Only 1 of 4 malignancies (a papillary carcinoma) stained positive with Galectin-3.

Other studies by Bernet [248], Takano [249] and Takenaka [250] have supported this. They found that quantitative Galectin-3 mRNA measurement is

useful in the identification of papillary carcinomas, but not in distinguishing follicular carcinomas from follicular adenomas.

In results by Niedziela [251] it was also evident that Galectin-3 was not only expressed in thyroid carcinomas of follicular origin, but also in Hashimoto's thyroiditis (4/30, 13%). According to Niedziela [252] the diagnosis of Hashimoto's thyroiditis must be excluded, before the usefulness of Galectin-3 in the diagnosis of malignancy is made.

Galectin-3 and HBME-1

A recent study supporting the usefulness of Galectin-3 and HBME-1 in cytological aspirates was demonstrated by Saggiorato [252]. They applied a panel of various immunodiagnostic markers to follicular neoplasms to further characterise these lesions. Their aim was to improve diagnostic accuracy in the preoperative cytological evaluation of follicular neoplasms in an attempt to reduce the number of thyroidectomies performed for benign lesions. Statistical analysis proved that Galectin-3 and HBME-1 were the most sensitive (92% and 80% respectively) markers.

3.1.1.5 Usefulness of Galectin-3 and HBME-1 in Oncocytic Cell Neoplasms

Oncocytic cell tumours (OCTs) of the thyroid include adenomas and carcinomas of follicular origin characterized by a predominant (usually more

than 75% of the tumour area) population of eosinophilic mitochondria-rich cells [253]. An oncocytic variant of papillary carcinoma (OVPC) has also been described by LiVolsi [254].

In a study by Papotti [255] it became evident that the clinical outcome of oncocytic cell tumours was by no means different from that of the corresponding non-oncocytic neoplasms (adenomas and carcinomas). Nevertheless their recognition by pathologists is important since these cells may also be found in non-neoplastic conditions (goiter and thyroiditis) [186].

Galectin-3 and HBME-1

Volante and colleagues [186] reported in a study that Galectin-3 is capable of correctly identifying 95% of malignant oncocytic cell tumours and the combination of Galectin-3 and HBME-1 positivity increases the sensitivity up to 99%. The combined use of Galectin-3 and HBME-1, suggested that their association in a panel of markers is optimal for better characterizing oncocytic cell carcinomas in histological and, possibly, cytological specimens. This panel of markers is probably the best choice in fine-needle aspiration cytological diagnosis of oncocytic cell tumours, to obtain the highest sensitivity in selecting presumably malignant cases referred for surgery [186].

HBME-1

Despite the findings of Volente and associates [186], a previous study by Mai [229] proved the opposite. According to Mai [229] it was evident that Hürthle cell tumours (including Hürthle cell carcinoma, Hürthle cell papillary carcinoma, Hürthle cell adenoma) showed negative or focal (< 10%) reactivity for HBME-1. Hürthle cell papillary thyroid carcinoma is considered as the Hürthle cell variant of papillary carcinoma since *Ret* oncogene, a specific molecular change in papillary carcinoma, is found in Hürthle cell papillary carcinoma [229]. In a recent study by Nikiforova [171] on oxyphilic tumours of the thyroid, Galectin-3 and HBME-1 expression was found to be related to molecular alterations such as PAX8-PPARgamma translocations [236] and ras oncogene mutations.

Galectin-3

However, the potential role of Galectin-3 as a marker of malignancy in oncocytic cell tumours has been questioned by some authors. Studies by Martins [180], Niedziela [251] and Nascimento [256] suggested that Galectin-3 immunodetection is not restricted to malignant tumours, but also observed in both benign (follicular adenomas) and non-neoplastic thyroid lesions. A significant number of follicular adenomas harbour Ras mutations like follicular carcinomas [171] and show Galectin-3 immunostaining [180,248].

A possible explanation for these discrepancies in oncocytic cell tumours comes from the knowledge that oncocytic cells are rich in endogenous biotin and Galectin-3 immunocytochemistry (as well as HBME-1) may provide false positive results in oncocytic cell tumours using biotin-based detection systems, especially when heat-induced antigen retrieval methods (required in the case of Galectin-3 immunocytochemistry), are employed. Therefore, Galectin-3 immunodetection may be a useful adjunct to distinguish benign from malignant thyroid tumours, but only if used in a biotin-free detection system [176,179].

Furthermore Vasco [257] suggested that some follicular adenomas may even represent a premalignant stage of follicular carcinomas. A reliable method that is able to differentiate preoperative malignant potential in patients presenting with thyroid nodules has not been proposed [258].

3.1.1.6 Prerequisites for Immunocytochemical Staining

According to Dalquen [259], the method of immunocytochemistry (ICC) should fulfill the following prerequisites 1. Cell fixation and sampling should be easy for the clinician. 2. Non-specific background staining such as blood and protein should not occur 3. Immunocytochemistry should be applicable to all cytological specimens. 4. Nuclear structure of tumour cells should not be destroyed by the procedure so that they can be clearly distinguishable from normal cells. The use of immunocytochemistry in diagnostic cytology is restricted by the limited number of specimens (slides) available.

3.1.1.7 Rules for Immunocytochemical Staining

The following rules should be observed: 1. Conventional light-microscopy examination must have priority over immunocytochemical examination. 2. Specimens for immunocytochemical examination must be adequately fixed and stored. 3. The examination must be carefully planned and the informative smear has to be spared for documentation and future training for cytologists and technologists. 4. Immunocytochemical examination in cytology is only justified if the diagnostic problem can be clearly identified. 5. Panel of antibodies should be carefully selected [259].

Immunocytochemistry in our institution is usually requested on the basis of findings in the Papanicolaou stained smears [259]. A panel of two antibodies (Galectin-3 and HBME-1) was investigated in this study, with the aim to assess the value of these two antibodies in discriminating benign from malignant thyroid lesions on fine-needle aspiration smears and corresponding histology tissue section.

3.2 MATERIAL AND METHODS

This was a retrospective comparative study. Sixty two optimal cases (from the previous study as well as cases from December 2005 to July 2006) were selected. The series included 2 males and 60 females with a mean age of 45 years. All the cases had histological confirmation and the immunodiagnostic

staining and review of cytology smears and tissue sections were performed in the Cytology Unit, Discipline of Anatomical Pathology, National Health Laboratory Services at Tygerberg Hospital. Suitable sections for immunohistochemistry included both the nodule and adjacent thyroid tissue.

3.2.1 Immunohistochemistry

Sixty two (62) formalin-fixed, paraffin embedded tissue blocks corresponding to the fine-needle aspiration cytology smears were retrieved for immunochemical staining from the archives. The neoplastic thyroid lesions included 7 papillary carcinomas, 8 follicular variant of papillary carcinomas, 6 follicular carcinomas, 13 follicular adenomas and 3 Hürthle cell adenomas. The non-neoplastic lesions included 15 dominant nodules in multinodular goiters (MNG), 6 multinodular goiters and 4 adenomatous nodules. The histological diagnosis was confirmed by two pathologists.

Tissue sections of 5µm thick were cut from the retrieved blocks and mounted onto SuperFrost® Plus (Menzel GmbH & Co KG, Braunschweig, Germany) glass slides. Standard immunohistochemical techniques [260] were applied after heat-induced antigen retrieval, using specific mouse monoclonal antibodies against Galectin-3 (Novocastra Laboratories Ltd., Newcastle upon Tyne, U.K.) and HBME-1 (DakoCytomation, California, USA.).

The tissue sections were deparaffinized in xylol and hydrated in a graded ethanol series. Endogenous peroxidase activity was blocked by treating the

sections with 0, 3% hydrogen peroxide in distilled water for 10 minutes. The hydrogen peroxide will quench any peroxidase activity that may be present in the tissue sections. For antigen retrieval the tissue sections were pressure cooked in sodium citrate buffer (0.01M, pH 6.0) for 10 minutes and incubated for 20 minutes with 5% fat free milk in PBS (phosphate-buffered-saline) for blocking of non-specific background. The slides were washed in PBS buffer and placed on staining racks. The primary antibodies Galectin-3 (1:100 dilutions) and HBME-1 (1:50 dilution) were optimally diluted in PBS and applied to the slides. After incubation for 45 minutes at room temperature, the excess primary antibody was washed off by rinsing for 10 minutes in 5% fat free milk in PBS buffer.

Monoclonal anti-mouse labelled polymers – HRP (EnVision®, DakoCytomation, California, USA.) (1:500) were applied as a secondary antibody and the slides were incubated for 30 minutes. The slides were placed in a PBS bath for 10 minutes before applying the avidin-biotin-peroxidase complex using diaminobenzidine (DAB) solution as substrate solution and incubated for 10 minutes. The slides were then rinsed in running tapwater and counterstained with Haematoxylin and Scott's tap water. After staining the slides were dehydrated and mounted with a cover slip. A positive control was included.

3.2.2 Cytology Fine-needle Aspiration Smears

Immunocytochemical staining was carried out with the avidin-biotin-peroxidase complex method on previously Papanicolaou stained cytology slides using the following specific monoclonal mouse antibodies: Galectin-3 (Novocastra Laboratories Ltd., U.K., 1:100 dilution) and HBME-1 (DakoCytomation, California, USA, 1:50 dilution).

The coverslips and mounting medium were removed by soaking the slides in xylol. The slides were hydrated and rinsed in water. Any endogenous peroxidase activity was blocked by incubating the slides with 0, 3% hydrogen peroxide in distilled water for 10 minutes. The slides were rinsed in running tap water and for antigen retrieval a sodium citrate buffer (0,01M, pH 6, 0) was used. The slides were incubated for 2 minutes in the hot citrate buffer (without boiling) and subsequently rinsed in running tap water. There after they were incubated for 20 minutes with 5% fat free milk in phosphate-buffered-saline (PBS) for blocking of non-specific background. The slides were washed in PBS and placed on staining racks for application of the primary antibodies. The primary antibodies galectin-3 and HBME-1 were optimally diluted in PBS and after application the smears were incubated for 45 minutes. Excess primary antibodies were rinsed off with PBS and subsequently washed for 10 minutes in 5% fat free milk in PBS buffer. The slides were rinsed in PBS and placed on staining racks.

Monoclonal anti-mouse labelled polymers – HRP (EnVision®, DakoCytomation, California, USA.) (1; 500 dilution) were applied as a secondary antibody and the slides were incubated for 30 minutes. After incubation the slides were washed in a phosphate-buffered-saline bath for 10 minutes and placed on staining racks. An avidin-biotin-peroxidase complex using diaminobenzidine (DAB) substrate solution was applied and incubated for 10 minutes. Finally the slides were rinsed in running tap water and counterstained with Haematoxylin and Scott's tap water. The slides were dehydrated and mounted with a coverslip.

3.2.3 Evaluation of Immunochemical Staining

Immunohistochemistry

Both the nodule and the adjacent thyroid tissue were assessed for intensity and proportion of positive staining compared with the positive control. The protein expression was assessed along a scale of 0-100% of tumour cells showing immunoreactivity.

The evaluation of antibody expression was done according to previous published scoring systems and the proportion of reactive cells within the lesions as well as the staining intensity and its distribution pattern was assessed [134,196,237]. A negative score indicated no immunolabelling and an equivocal result was weak staining interpreted as well below that of the positive control or < 10%. Positive focal distribution was significant positivity

with patchy distribution across the nodule (>10% but < 75%). A positive, diffuse result indicated significant positivity with diffuse staining.

Cells were regarded as positive for these proteins when the immunoreactivity was clearly observed in their nuclei, cell membranes and/or cytoplasm depending on the antibody. Staining of the colloid in the absence of staining of the follicular epithelium and/or cytoplasm was considered non-specific and negative.

Immunocytochemistry

The evaluation of antibody expression in the cytology smears was done according to previously published scoring systems by various researchers [134,171,174]. The immunocytochemical staining was regarded as positive when > 50% of the malignant cells stained positive with the immunodiagnostic marker, weakly positive when staining was < 50% but > 10%. The staining was considered negative if it was < 10 %.

3.2.4 Immunolocalization of Galectin-3 and HBME-1 in Tissues Sections and Cytology Smears

Galectin-3 staining in malignant epithelial cells was mostly cytoplasmic in location, sometimes diffuse, sometimes finely granular, and seldom membranous (luminal aspect of follicular formations). Nuclear staining was rarely observed and very pale in intensity. Colloid did not stain with the

antibody. Macrophages also showed focal weak cytoplasmic staining, usually granular. Adjacent normal thyroid tissue and the multinodular goiters showed scattered small foci of positive labeling affecting a few follicles. HBME-1 expression was mostly cytoplasmic and membranous with luminal accentuation in malignant epithelial cells.

3.2.5 Statistical Analysis

The statistical analysis was performed using the histological diagnosis as the gold standard. The cytological and immunohistochemical patterns in benign and malignant lesions were compared. Statistical analysis was performed by using a commercial available software package (STATISTICA (Version 7.1), Statsoft. USA). The chi-square test was used for categorical variables and the *t* test was used for continuous variables. A *p* value less than 0.05 were considered significant.

Immunochemical staining data was analysed using the χ^2 test. A false positive result (FP) was defined as a non-neoplastic lesion or a benign neoplasm staining positively with Galectin-3 or HBME-1 immunostaining, and a false negative result (FN) defined as a malignant neoplasm staining negatively with Galectin-3 or HBME-1.

Sensitivity, specificity, positive and negative predicative values and diagnostic accuracy were individually calculated for Galectin-3 and HBME-1 expression in malignant lesions. The co-expression of these markers was also assessed.

3.3 RESULTS

3.3.1 Immunodiagnostic Staining in Non-neoplastic Lesions

3.3.1.1 Tissue Sections

Immunohistochemistry was performed on 62 cases. In the study were 21 malignant and 41 benign lesions. The malignant neoplasms consisted of 7 classic papillary carcinomas, 8 follicular variants of papillary carcinomas, and 6 follicular carcinomas. The benign cases included 13 follicular adenomas, 3 Hürthle cell adenomas, and 25 non-neoplastic lesions: 6 dominant nodules in multinodular goiters, 15 multinodular goiters and 4 adenomatous nodules (hyperplasias).

3.3.1.1.1 Immunohistochemical Expression of Galectin-3 and HBME-1 in Non-neoplastic Lesions

The immunohistochemical expression of Galectin-3 and HBME-1 in the 25 non-neoplastic lesions is summarized in Table 3.1.

Table 3.1: Immunohistochemical expression of Galectin-3 and HBME-1 in 25 non-neoplastic lesions.

IHC NON- NEOPLASTIC LESIONS	GALECTIN-3			HBME-1		
	Diffusely Pos (%)	Focally Pos (%)	Negative / Equivocal(%)	Diffusely Pos (%)	Focally Pos (%)	Negative / Equivocal(%)
Dominant nodule (n=6)	0(0)	0(0)	6(100)	1(17)	0(0)	5(83)
Multinodular goiter (n=15)	0(0)	1(7)	14(93)	0(0)	2(13)	13(87)
Nodular hyperplasia (adenomatous) (n=4)	0(0)	0(0)	4(100)	0(0)	1(25)	3(75)
TOTAL (25)	0(0)	1(4)	24(96)	1(4)	3(12)	21(84)

Only 1 of 25 (4%) non-neoplastic lesions, stained focally positive with Galectin-3 while 24 (96%) lesions showed no expression. The lesion that stained focally positive was a multinodular goiter (Table 3.1).

In contrast, HBME-1 expression was seen in 4 of the 25 non-neoplastic lesions (Table 3.1). Diffusely positive staining was observed in 1(4%) lesion and focally positivity was seen in 3(12%) cases. The non-neoplastic lesion that stained diffusely positive with HBME-1 was a dominant nodule in a multinodular goiter and the 3 lesions that stained focally positive were 2 multinodular goiters and 1 adenomatous nodule. Twenty one of 25 (84%) non-neoplastic lesions showed no expression of HBME-1 (Table 3.1). In our study

no immunohistochemical co-expression was observed in any non-neoplastic lesions.

3.3.1.2 Cytology Smears

The results of the corresponding immunocytochemical expression of Galectin-3 and HBME-1 are illustrated in Table 3.2.

Table 3.2: Immunocytochemical expression of Galectin-3 and HBME-1 in 25 non-neoplastic lesions.

ICC NON- NEOPLASTIC LESIONS	GALECTIN-3			HBME-1		
	Positive (%)	Weakly Pos (%)	Negative (%)	Positive (%)	Weakly Pos (%)	Negative (%)
Dominant nodule (n=6)	0(0)	0(0)	6(100)	0(0)	1(17)	5(83)
Multinodular goiter (n=15)	0(0)	0(0)	15(100)	0(0)	0(0)	15(100)
Nodular hyperplasia (adenomatous) (n=4)	0(0)	0(0)	4(100)	0(0)	0(0)	4(100)
TOTAL (25)	0(0)	0(0)	25(100)	0(0)	1(4)	24(96)

3.3.1.2.1 Immunocytochemical Expression of Galectin-3 and HBME-1 Expression in Non-neoplastic Lesions

None of the 25 non-neoplastic lesions showed staining with Galectin-3 and 1 of 25 (4%), stained weakly positive with HBME-1 (a dominant nodule in a multinodular goiter).

3.3.2 Immunodiagnostic Staining in Neoplastic Lesions

3.3.2.1 Tissue Sections

The 37 neoplastic lesions included 16 benign neoplasms (13 follicular adenomas and 3 Hürthle cell adenomas) and 21 malignant neoplasms (15 papillary carcinomas and 6 follicular carcinomas).

3.3.2.1.1 Immunohistochemical Expression and Co-expression of Galectin -3 and HBME-1 in Neoplastic Lesions

The expression and co-expression of Galectin-3 and HBME -1 in the neoplastic lesions are summarized in Table 3.3.

Table 3.3: *Immunohistochemical expression and co-expression for Galectin - 3 and HBME-1 in 37 neoplastic lesions.*

IHC	GALEC-3	HBME-1	C0-EXPRESSION
MALIGNANT NEOPLASMS			
Papillary carcinoma (n=7)	7	7	7(100%)
Follicular variant PC (n=8)	8	7	7(88%)
Follicular carcinoma (n=6)	4	6	4(86%)
TOTAL (n=21)	19	20	18(86%)
BENIGN NEOPLASMS			
Follicular adenoma (n=13)	6	8	6(46%)
Hürthle cell adenoma (n=3)	0	0	0(0%)
TOTAL (n=16)	6	8	6(38%)

In this study 7/7 (100%) **classic papillary carcinomas** showed staining with Galectin-3 as well as HBME-1. Four of the 7 papillary carcinomas showed diffuse staining while 4 lesions were focally positive with Galectin-3. As for HBME-1, 6/7 lesions showed diffuse staining while 1/7 lesions showed focal positivity. Co-expression for both antibodies was seen in 100% of papillary carcinomas (Table 3.3).

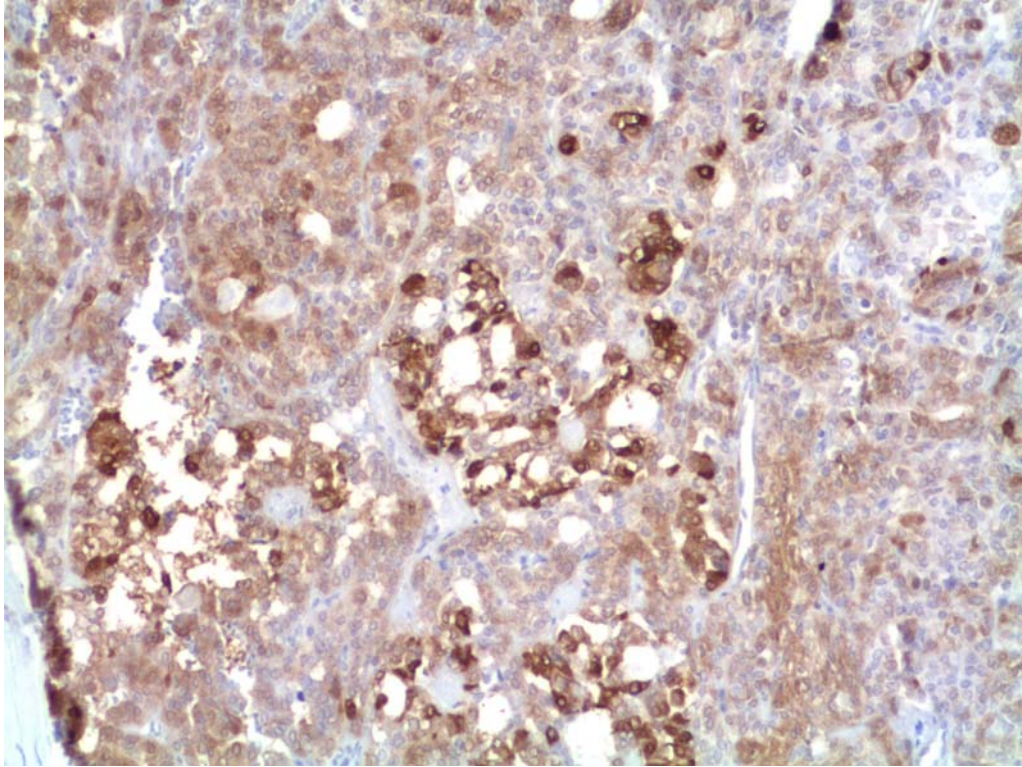


Figure 3.1: Immunohistochemical stain of a follicular variant of papillary carcinoma showing Galectin- 3 expression.

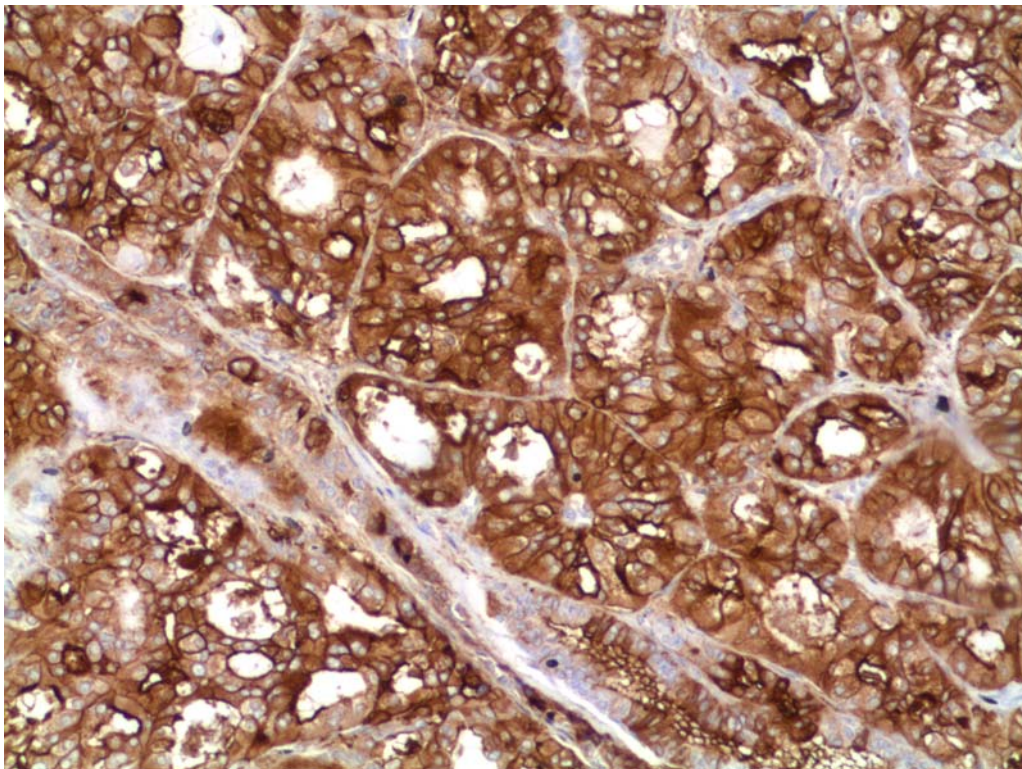


Figure 3.2: Immunohistochemical stain of a follicular variant of papillary carcinoma showing HBME-1 expression.

All follicular variants of papillary carcinoma showed positive staining with Galectin-3 - 100% (8/8) positivity in comparison with 7/8 (88%) with HBME-1. Five of eight showed diffuse and 3/8 focal positivity with Galectin-3. Diffuse HBME-1 expression was seen in 6/8 cases, while 1 case showed focal positivity. Co-expression for both antibodies was present in 7 of the 8 cases (88%) of the follicular variant of papillary carcinoma (Table 3.3).

Four of 6 (67%) **follicular carcinomas** showed positive staining with Galectin-3 in comparison to 6/6 (100%) with HBME-1 (Table 3.3). In 2 lesions Galectin-3 expression was diffusely positive while 2 lesions stained only focally positive. Two lesions stained diffusely positive and 4 only focally positive with HBME-1. Co-expression of HBME-1 and Galectin -3 was seen in 67% of the follicular carcinomas.

Overall, in this study 19/21 (90%) of the carcinomas showed positive staining with Galectin-3 and 20/21 (96%) with HBME-1. Co-expression for both antibodies was observed in 18/21 (86%) of malignant neoplasms (Table 3.3).

The **benign neoplasms** also showed positive staining with Galectin-3 and HBME-1. In our study 6/13 (46%) follicular adenomas were positive for Galectin-3. One (8%) of these benign neoplastic lesions expressed diffuse staining while 5/13 (38%) stained focally positive. Seven follicular adenomas did not express any positivity with Galectin-3.

Furthermore expression with HBME-1 was seen in 8/13 (62%) follicular adenomas. Three of these nodules showed diffuse positive staining while 5 stained focally positive. Five follicular adenomas (38%) showed no staining with HBME-1. Co-expression was observed in 6/13 (46%) of follicular adenomas (Table 3.3).

An interesting observation was that none of the **Hürthle cell adenomas** expressed positivity with Galectin-3 or HBME-1. Therefore the total expression of Galectin-3 and HBME-1 in the benign neoplastic lesions was 6/16 (37%) and 8/16 (50%) respectively. In this study the co-expression in the benign neoplastic lesions was 38% (Table 3.3).

3.3.2.2 Cytology Smears

Only 33 corresponding fine-needle aspiration biopsy smears were optimal for immunocytochemical staining with Galectin-3 and HBME-1.

3.3.2.2.1 Immunocytochemical Expression and Co-expression of Galectin -3 and HBME-1 Expression in 33 Neoplastic Lesions.

A total of 33 neoplastic lesions, 19 malignant and 14 benign neoplasms were included in our study. The results of the immunocytochemical expression and co-expression in the 33 corresponding fine-needle aspiration cytology smears are summarized in Table 3.4

Table 3.4: Immunocytochemical expression and co-expression for Galectin -3 and HBME-1 in 33 neoplastic lesions.

ICC	GALEC-3	HBME-1	C0-EXPRESSION
MALIGNANT NEOPLASMS			
Papillary carcinoma (n=6)	6	6	6 (100%)
Follicular variant PC (n=7)	6	6	5(71%)
Follicular carcinoma (n=6)	3	5	3(50%)
TOTAL (n=19)	15	17	14(74%)
BENIGN NEOPLASMS			
Follicular adenoma (n=11)	4	5	2(18%)
Hürthle cell adenoma (n=3)	0	1	0(0%)
TOTAL (n=14)	4	6	2(14%)

Of the 19 malignant neoplasms 6/6 **classic papillary carcinomas** showed positive staining with Galectin-3 and HBME-1. These carcinomas showed 100% co-expression for both antibodies (Table 3.4). Four of the 6 papillary carcinomas stained diffusely positive with Galectin-3 while 2 lesions stained focally positive. Five of 6 lesions expressed diffuse and 1 only focal positivity with HBME-1.

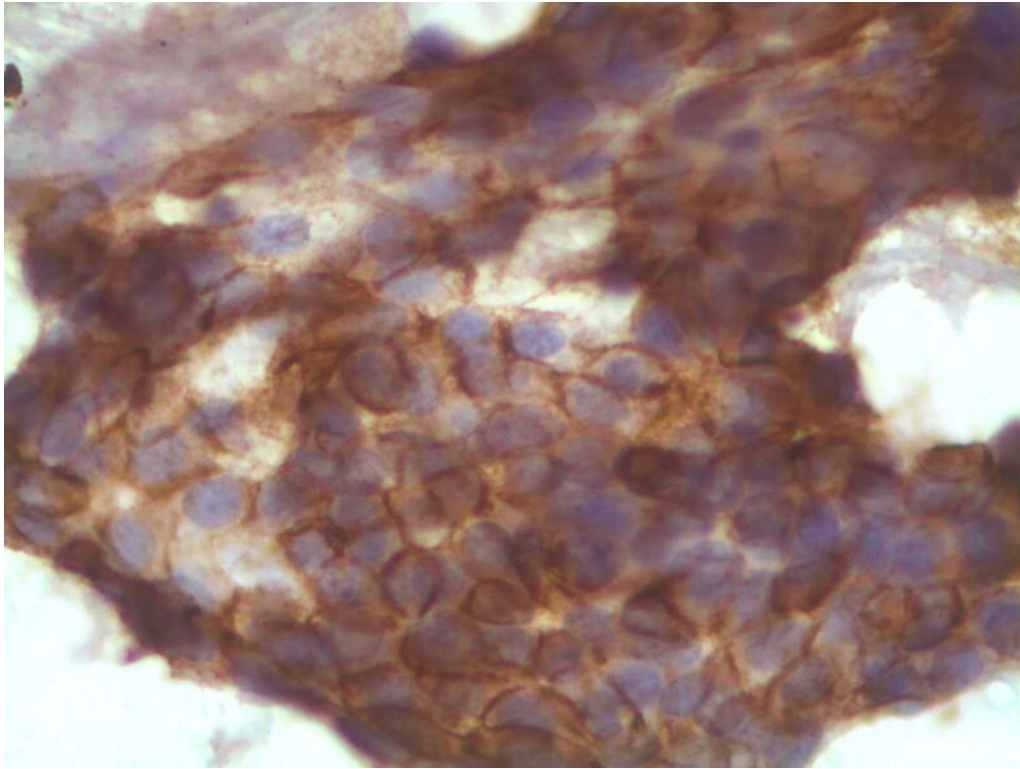


Figure 3.3: Cytology smear of a papillary carcinoma showing positive HBME-1 expression.

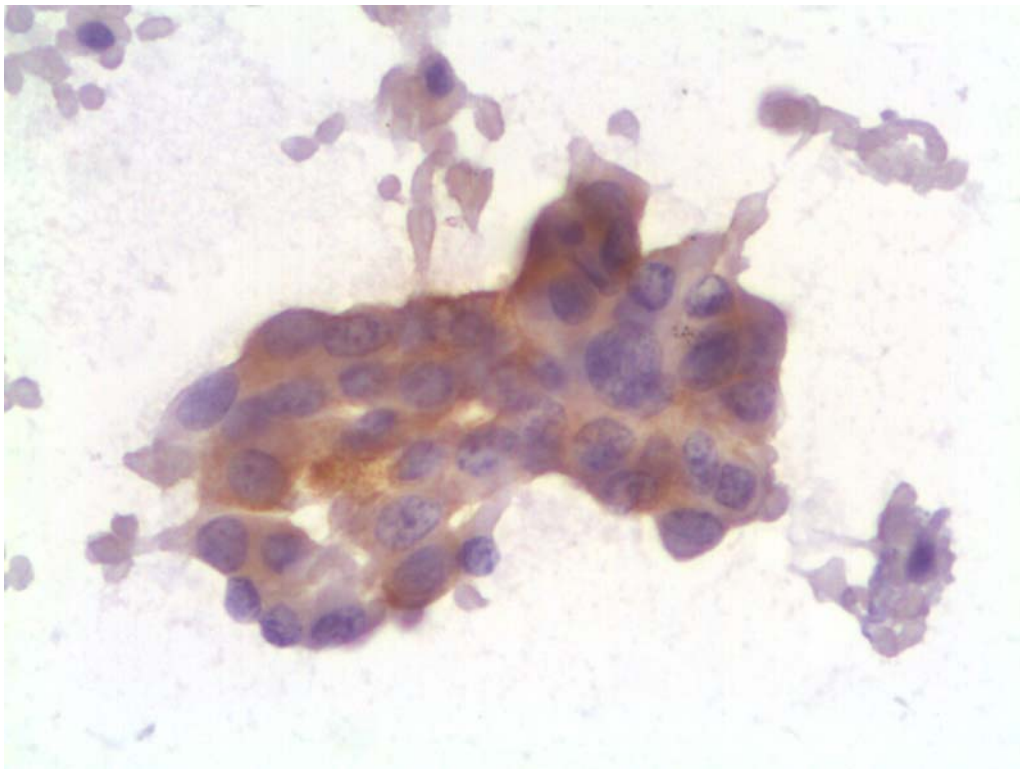


Figure 3.4: Cytology smear of a papillary carcinoma showing positive Galectin-3 expression.

Six of 7 **follicular variant of papillary carcinomas** expressed positivity with Galectin-3 as well as HBME-1. In both Galectin-3 and HBME-1, expression was diffuse in 5 lesions while 1 lesion stained focally positive. However, only 5 (71%) lesions showed co-expression with both these markers (Table 3.4).

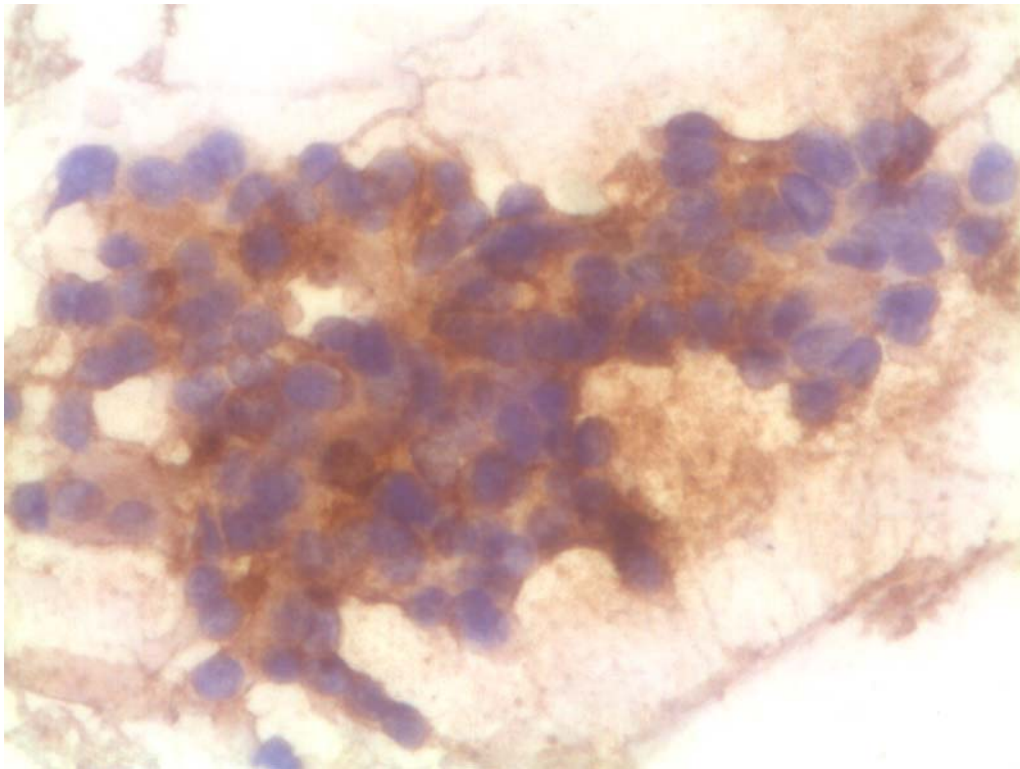


Figure 3.5: Cytology smear of a follicular variant of papillary carcinoma showing HBME-1 expression.

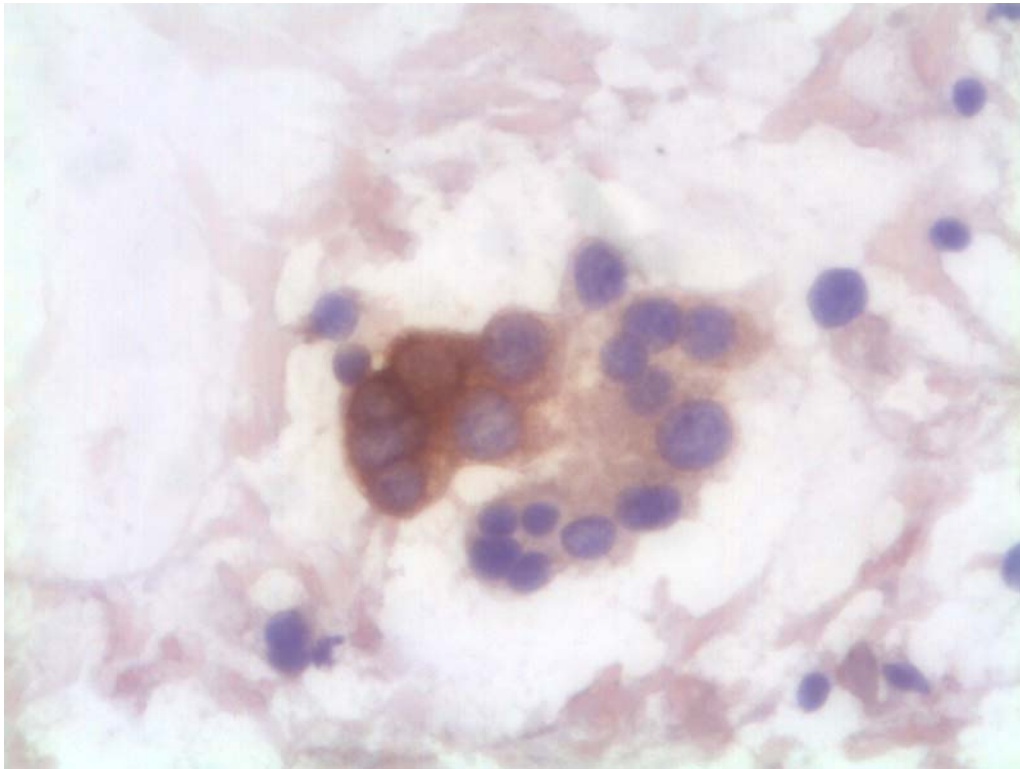


Figure 3.6: Cytology smear of a follicular variant of papillary carcinoma showing Galectin-3 expression.

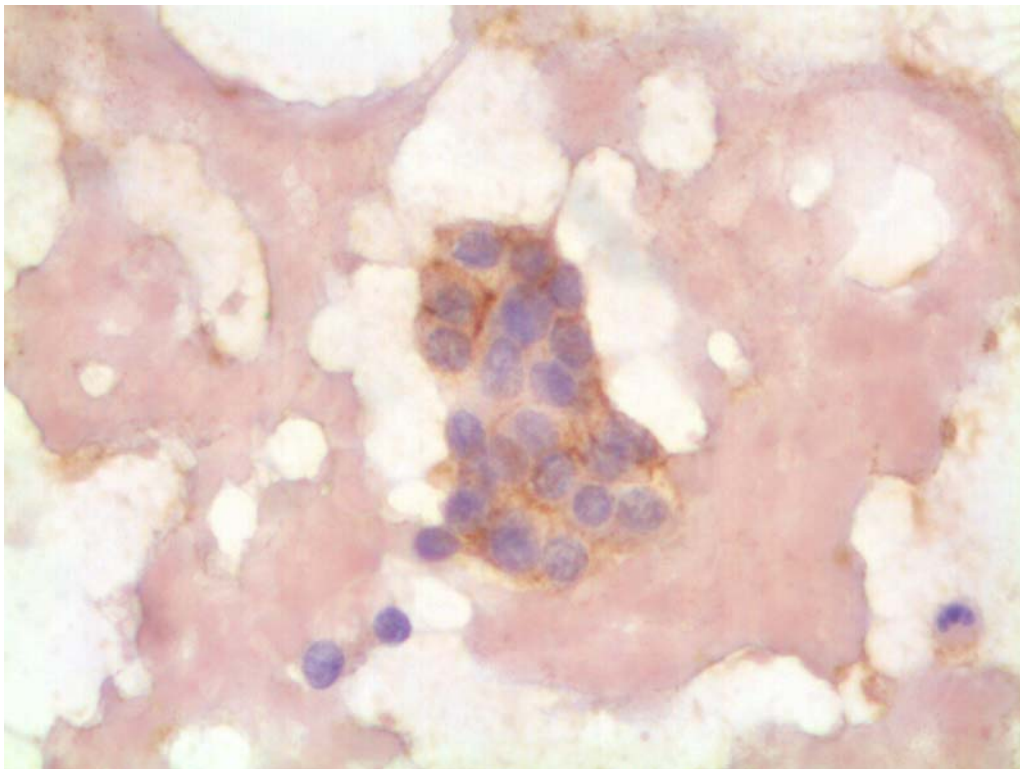


Figure 3.7: Cytology smear of a follicular carcinoma showing HBME-1 expression.

Galectin-3 and HBME-1 were expressed in 3/6 and 5/6 **follicular carcinomas** respectively, with co-expression in 3 (50%) of the neoplasms. The overall Galectin-3 and HBME-1 expression in the malignant neoplastic lesions was 15/19 (79%) and 17/19 (90%) respectively. Co-expression for both antibodies was seen in 14/19 (74%) lesions (Table 3.4).

The **benign neoplastic lesions** included 11 **follicular adenomas** and 3 **Hürthle cell adenomas**. Four of 11, (36%) and 5/11 (46%) stained positive with Galectin-3 and HBME-1 respectively. Diffuse positive staining with Galectin-3 was observed in 2 adenomas and weak positive staining in 2 lesions. Four of the five adenomas expressed strong positivity and 1 lesion stained weakly positive. Co-expression for both antibodies was observed in 2 (18%) adenomas (Table 3.4).

One Hürthle cell adenoma stained weakly positive with HBME-1, while no expression was seen with Galectin-3. In our study a total of 4/14 (29%) and 6/14 (43%) benign neoplastic lesions expressed Galectin-3 and HBME-1 respectively with co-expression in 2/14 (14%).

3.3.2.2.2 Comparison of Immunocytochemical Co-expression in Non-neoplastic and Neoplastic Lesions

The immunocytochemical co-expression of Galectin-3 and HBME-1 in malignant neoplastic lesions was 74% in comparison to 14% in the benign neoplasms and 0% in the non-neoplastic lesions. The results showed 100%

co-expression in classic papillary carcinoma, and 71% and 50% respectively in follicular variant of papillary carcinoma and follicular carcinoma (Table 3.5).

Table 3.5: The comparison of Galectin-3 and HBME-1 co-expression in non-neoplastic and neoplastic lesions in cytology smears.

ICC	Non-neoplastic	Benign neoplastic	Malignant neoplastic		
			Pap Ca	FVPC	Foll Ca
Coexpression	0%	14%	74%		
Coexpression			100%	71%	50%

3.3.3 Statistical Analysis of Immunodiagnostic Staining

The immunodiagnostic staining data was analyzed with the χ^2 test. A value of $p < 0.05$ was statistically significant. The sensitivity, specificity, positive and negative predictive values and diagnostic accuracy of Galectin-3 and HBME-1 for diagnosing malignancy was assessed and the results are summarized in Table 3.6.

Table 3.6: Galectin-3 and HBME-1 expression and co-expression in histology tissue sections and cytology smears.

	GALECTIN-3		HBME-1		GAL 3 + HBME-1	
	Histo	Cyto	Histo	Cyto	Histo	Cyto
Sensitivity	91%	79%	95%	90%	86%	74%
Specificity	83%	90%	71%	82%	86%	95%
Positive predictive value	73%	79%	63%	71%	75%	88%
Negative predictive value	94%	90%	97%	94%	92%	86%
Diagnostic accuracy	86%	86%	79%	85%	86%	88%

In this study the **sensitivity** of immunohistochemistry for diagnosing malignancy with both markers was better than the immunocytochemistry. The sensitivity of immunohistochemistry was 91% and 95% respectively with Galectin-3 and HBME-1 in comparison to 79% and 90% for the immunocytochemistry (Table 3.6). The sensitivity for co-expression with both markers was 86% for immunohistochemistry and 74% for immunocytochemistry respectively.

However, the **specificity** of immunocytochemistry was superior to the immunohistochemistry. Galectin-3 and HBME-1 expression was 90% and 82% respectively in comparison to the immunohistochemistry that showed a specificity of 83% and 71% respectively. Co-expression was 95% in immunocytochemistry and 86% immunohistochemistry (Table 3.6).

The **positive predictive value** was 73% and 63% respectively with Galectin-3 and HBME-1 for immunohistochemistry with a co-expression of 75%. The positive predictive value was 79% and 71% respectively with Galectin-3 and HBME-1 for immunocytochemistry with a co-expression of 88% (Table 3.6).

The **negative predictive value** was 94% and 97% respectively with Galectin-3 and HBME-1 respectively for immunohistochemistry with a co-expression of 92%. For immunocytochemistry the negative predictive values were 90% and 94% respectively with Galectin-3 and HBME-1 with co-expression in 86% (Table 3.6).

The **diagnostic accuracy** with Galectin-3 and HBME-1 was 86% and 79% respectively on immunohistochemistry with co-expression in 86%. The diagnostic accuracy on immunocytochemistry with Galectin-3 and HBME-1 was 86% and 85% respectively with co-expression in 88% (Table 3.6).

3.4 DISCUSSION

Difficulty in differentiating follicular lesions on fine-needle aspiration biopsy has led a search for molecular markers that could reliably distinguish preoperatively between benign and malignant lesions. Most of these lesions are benign therefore the indication for surgery should be as accurate as possible [261].

From this research it is clear that in both cytology and histology, morphologic analysis of each single thyroid neoplasm cannot reliably be replaced by immunochemistry. The use of more than one immunomarker further strengthens the possibility of a correct diagnostic approach, especially in follicular lesions.

3.4.1. Histology Tissue Sections

This data showed that Galectin-3 and HBME-1 are not absolute markers in determining whether a lesion is benign or malignant. However they could serve as a useful adjunct in determining malignancy. In this study HBME-1 proved to be a more sensitive marker (sensitivity 95%) for diagnosing thyroid

malignancy in **tissue sections** than Galectin-3 (sensitivity 91%) (Table 3.6). A higher sensitivity was demonstrated in papillary carcinomas, follicular carcinomas, as well as the follicular variant of papillary carcinomas. In our study the immunohistochemical co-expression in malignant neoplasms was 100% in classic papillary carcinomas while 88% and 67% co-expression was observed in the follicular variant of papillary carcinoma and follicular carcinomas respectively.

Papillary carcinoma

The finding that HBME-1 is a sensitive marker for classic papillary carcinomas is supported by many researchers. In our study 100% of the papillary carcinomas expressed positivity with HBME-1. Van Hoeven and colleagues [262] reported 100% sensitivity with HBME-1 in papillary carcinomas and this finding was also supported in publications by Mai [229] and De Matos [237] with 100% and 94%, respectively.

HBME-1 was originally described as a marker of normal and malignant mesothelial cells. It was later shown to also stain most papillary carcinomas and a fraction of follicular carcinomas, while adenomas are generally negative [163-166].

Furthermore, the finding of 100% positivity of papillary carcinomas with Galectin-3 was similar to previous results by Orlandi [160], Martins [180], Bartolazzi [134] and Mehrota [175]. They reported a 100%, 100%, 97% and

92% sensitivity with Galectin-3 expression respectively in papillary carcinomas. On the contrary, in a recent study by De Matos and colleagues [237], Galectin-3 was only expressed in 72, 6% of papillary carcinomas.

Follicular variant of papillary carcinoma

The **histologic and cytologic** diagnosis of classic papillary carcinoma is usually straightforward. In contrast, the diagnosis of follicular variant of papillary carcinoma (FVPC), especially when it is encapsulated, lacks vascular or capsular invasion, or shows only focal characteristic nuclear features, can be extremely challenging [22,23]. There have been a few reported cases of encapsulated follicular variant of papillary with bone metastases, in which the initial thyroidectomy specimens were misdiagnosed as follicular adenomas but showed multifocal nuclear features of papillary carcinoma on retrospective evaluation [24].

In this study the follicular variant of papillary carcinoma showed 100% and 88% positive staining respectively with Galectin-3 and HBME-1 in the tissue sections. Follicular variant of papillary carcinomas may be difficult to distinguish from follicular adenomas, especially when the nuclear features are not typical. Recent research by De Matos [237] demonstrated that HBME-1 was the most reliable marker of sensitivity and specificity for the follicular variant of papillary carcinoma. In contrast to this Galectin-3 was the most sensitive marker for the follicular variant of papillary carcinoma in our study.

Follicular carcinomas and adenomas

Furthermore, this study did not demonstrate a significant difference between the proportion of follicular carcinomas and follicular adenomas that showed expression with HBME-1 and Galectin-3 in the tissue sections. Although 100% of the follicular carcinomas expressed positivity with HBME-1, only 75% expressed positivity with Galectin-3.

HBME-1 and Galectin-3 expression was also seen in 62% and 46% of the follicular adenomas, respectively. According to Orlandi [160], Xu [172], Gasbarri [173] and Inohara [240], this finding suggests that Galectin-3 expression implies a potential early thyroid malignancy with molecular evidence of transformation.

Findings similar to these on tissue sections were recently published by De Matos [237]. Their research showed that HBME-1 and Galectin-3 expression was observed in 55% and 11% of follicular adenomas, respectively.

In the study by De Matos [237] the expression of HBME-1 and Galectin-3 was only 63% and 21% respectively in follicular carcinomas. Mehrotra [244] performed a study on formalin-fixed thyroid tissue sections that demonstrated that Galectin-3 was not a reliable immunohistochemical marker to distinguish benign from malignant thyroid follicular lesions. In their study Galectin-3

expression was observed in only 74% of the follicular carcinomas, but also in 72% of the follicular adenomas.

The use of Galectin-3 as a molecular marker for thyroid carcinoma must be interpreted with caution [180]. Martins [180] research showed that Galectin-3 was positively expressed in 90% of follicular carcinomas. However, it was also expressed in 45% of the follicular adenomas and 17% of the multinodular goiters. The sensitivity of Galectin-3 in diagnosing malignancy was 93.8% and the diagnostic accuracy between benign and malignant lesions was 77%. The diagnostic accuracy of Galectin-3 was only 68.9% when follicular adenoma was compared to follicular carcinoma [180].

Studies by other researchers demonstrated more significant differences between follicular carcinomas and adenomas. A study by Orlandi [160] showed positive Galectin-3 immunoreactivity in 82% follicular carcinomas, whereas only 10% follicular adenomas stained positive. Along the same lines, a comprehensive study by Bartolazzi [134] showed immunohistochemical positivity for Galectin-3 in 95% follicular adenomas and only 3% in follicular carcinomas.

Hürthle cell neoplasms

Oncocytic cell tumours of the thyroid include adenomas and carcinomas of follicular cell origin characterize by a predominant (usually more than 75% of the tumour area) population of eosinophilic mitochondria-rich cells [253]. In

our study none of the Hürthle cell adenomas expressed positivity with Galectin-3 or HBME-1.

The study by Mai and associates [229] concluded that all papillary thyroid carcinomas without Hürthle cell or apocrine-like differentiation showed positivity with HBME-1. On the contrary, Hürthle cell tumours and tumours with Hürthle cell or apocrine-like changes show negative or focal (< 10% and mostly < 1%) positivity with HBME-1.

The clinical outcome of oncocytic cell tumours is by no means different from that of the corresponding non-oncocytic tumours [255]. Their recognition is important since they may also be found in non-neoplastic conditions (multinodular goiter and especially Hashimoto's thyroiditis) [186]. Volante [186] reported in their study that Galectin-3 is capable of correctly identifying 95% of malignant oncocytic cell tumours and the combined use of Galectin-3 and HBME-1 increases the sensitivity up to 99%. The combined use of Galectin-3 and HBME-1 suggested that their association in a panel of markers is optimal for better characterizing oncocytic cell carcinomas in histological and, possibly, cytological specimens [186].

In concordance with this, 1 papillary carcinoma with oncocytic changes (of 7 papillary carcinomas) stained positive with HBME-1 and Galectin-3 in our study.

On the other hand, the potential role of Galectin-3 as a marker of malignancy in oncocytic cell tumours has been questioned by some authors. Studies by Martins [180], Niedziela [251] and Nascimento [256], suggested that Galectin-3 immunodetection is not restricted to malignant tumours, but also observed in both benign and neoplastic thyroid lesions. A significant number of follicular adenomas harbour Ras mutations like follicular carcinomas [171] and show Galectin-3 immunostaining [180,248].

A possible explanation for these discrepancies in oncocytic cell tumours comes from the knowledge that oncocytic cells are rich in endogenous biotin. Galectin-3 immunocytochemistry (as well as HBME-1) may provide false positive results in oncocytic cell tumours using biotin-based detection systems, especially when heat-induced antigen retrieval methods (required in the case of Galectin-3 immunocytochemistry), are employed. Therefore, Galectin-3 immunodetection may be a useful adjunct to distinguish benign from malignant thyroid tumours, if used in a biotin-free detection system [176,179].

Non-neoplastic lesions

In this study 96% and 84% of non-neoplastic lesions respectively showed no immunohistochemical staining with Galectin-3 and HBME-1. However 1 (4%) multinodular goiter stained focally positive with Galectin-3 while 2 multinodular goiters and 1 adenomatous nodule stained focally positive with HBME-1 (16%). In a study by Bartolazzi and associates [134], Galectin-3 expression

was negative in 100% of the normal control cases and 100% of the hyperplastic lesions.

Along the same lines Cheung [166], reported 100% negativity for HBME-1 in adenomatous nodules and multinodular goiters. In comparison to this, a study by Mehrota [244] showed that 33.3% of the adenomatous nodules and 75% of the multinodular goiters expressed Galectin-3.

This study of immunohistochemistry using co-expression of both these markers, classic papillary carcinoma could be clearly identified with 100% co-expression in comparison to the follicular variant of papillary carcinoma and follicular carcinoma which showed less positivity (Table 3.3). These results concur with many studies looking at follicular-patterned lesions and this research also found none of these markers sufficient to confer a sensitive and specific diagnosis.

3.4.2 Fine-needle Aspiration Smears

This data demonstrated that the majority of thyroid carcinomas diagnosed by conventional cytology alone were carcinomas on histology. Ten of twelve cytologically diagnosed carcinomas were carcinomas on histology. However, the major diagnostic discrepancies were in the follicular patterned lesions.

This finding was supported by Tuttle [109], Bartolazzi [134], Schlinkert [143] and Rosai [261]. Their research showed that most papillary carcinomas and

thyroiditis are easily detected by fine-needle aspiration cytology, but preoperative discrimination between benign and malignant follicular lesions are still very difficult.

A recent study supporting the usefulness of Galectin-3 and HBME-1 as immunocytochemical markers was performed by Saggiorato et al 2005. Their aim was to improve the diagnostic accuracy in the preoperative cytological evaluation of follicular neoplasms in an attempt to reduce the number of thyroidectomies performed for benign lesions. Statistical analysis proved that Galectin-3 and HBME-1 were the most sensitive (92% and 80% respectively) markers in malignant thyroid lesions [252].

Papillary carcinomas

Results by Ito [246] supported the finding that HBME-1 contributes to the diagnosis of papillary thyroid carcinoma. It could however not be applied to the preoperative diagnosis of follicular carcinoma in fine-needle aspiration biopsies. In their study, 100% of papillary carcinomas expressed the marker HBME-1. This finding was also reported by van Hoeven [262]. They reported 100% sensitivity with HBME-1 in papillary carcinomas.

Similar findings of 98% expression with Galectin-3 in papillary carcinomas on fine-needle aspiration cell blocks were reported by Bartolazzi [134]. These results were in line with the 100% Galectin-3 expression showed in our study.

In this study 6/6 classic papillary carcinomas expressed Galectin-3 and HBME-1 with co-expression in 100%. The sensitivity for immunohistochemistry was superior to immunocytochemistry with sensitivity for Galectin-3 and HBME-1 79% and 90% respectively with co-expression in 74% (Table 3.6).

Follicular variant of papillary carcinoma

In this study the immunocytochemistry on the corresponding cytology smears showed 86% (6/7) expression of Galectin-3 and HBME-1 in the follicular variant of papillary carcinomas. However, co-expression was only seen in 71% (5/7) of the neoplastic lesions (Table 3.4).

Follicular carcinoma and adenomas

In a recent study by Ito et al (2005) HBME-1 was expressed in only 60.9% of the follicular carcinomas. A similar finding was reported in a study by Orlandi [160]. Their research showed 82% Galectin-3 expression in follicular carcinomas on cytology cell blocks. Another study by Maruta et al 2004 showed 89% Galectin-3 expression in follicular carcinomas. On the contrary a study by Saggiorato [161] reported a 100% expression with Galectin-3 in minimally invasive follicular carcinomas. This finding supported the view of Galectin-3 as an early marker of thyroid malignancy. In a recent study by Ito et

al (2005) HBME-1 was expressed in only 60.9% of the follicular carcinomas. Their study showed a 33.3% expression with HBME-1 in follicular adenomas.

The results shown that Galectin-3 and HBME-1 was expressed in 50% (3/6) and 83% (5/6) of follicular carcinomas respectively. Co-expression for both markers was seen in 50% of the smears (Table 3.6).

Hürthle cell neoplasms

A study by Bartolazzi [134] reported a 7% and 59% expression respectively with Galectin-3 in Hürthle cell adenomas and carcinomas. In our study no positivity with Galectin-3 was demonstrated in the Hürthle cell adenomas, but 1 lesion (33%) expressed HBME-1.

Non-neoplastic lesions

Controversy about the usefulness of Galectin-3 as an immunodiagnostic marker of thyroid malignancies was recently demonstrated in a fine-needle aspiration cell block study by Mills and colleagues [247]. They reported a 25% Galectin-3 expression in thyroid malignancies. Studies by Bernet [248], Takano [249] and Takenaka [250] have supported these findings. They found that quantitative Galectin-3 mRNA measurement is useful in the identification of

papillary carcinomas, but not in distinguishing follicular carcinomas from follicular adenomas.

Results by Niedziela [251] showed that Galectin-3 was not only expressed in thyroid carcinomas of follicular origin, but also in 13% of lesions with Hashimoto's thyroiditis. According to Niedziela [251], the diagnosis of Hashimoto's thyroiditis must be excluded, before the diagnosis of malignancy is confirmed by the Galectin-3 marker.

In this study none of the non-neoplastic lesions showed positivity with Galectin-3 with only 1 lesion (4%) that stained weakly positive with HBME-1. Similar results by Bartolazzi [134], reported 100% negativity with Galectin-3 in non-neoplastic lesions while a study by Cheung [166] reported 100% negativity with HBME-1.

These results showed that 74% of the malignant neoplastic lesions showed co-expression of both these markers in comparison to only 14% of the benign neoplastic lesions (Table 3.4). In this study the non-neoplastic lesions could clearly be distinguished from the neoplastic lesions. Papillary carcinoma was clearly identified with 100% co-expression in comparison to the follicular variant of papillary carcinoma and follicular carcinoma whom showed less co-expression (Table 3.5).

Despite the lower sensitivity of immunocytochemistry for diagnosing malignancy to that of immunohistochemistry, the specificity of

immunocytochemistry was better in our study. These immunocytochemical results showed respectively a 90% and 82% specificity for Galectin-3 and HBME-1 to that of 83% and 71% of immunohistochemistry. Saggiolato et al 2005 reported an increase in sensitivity of up to 97% when both antibodies were applied. Results from this study demonstrated that the diagnostic accuracy of immunohistochemistry (86%) and immunocytochemistry (88%) using co-expression of these two antibodies was excellent (Table 3.6).

It is obvious from these results that Galectin-3 and HBME-1 are not absolute markers in determining follicular adenomas from follicular carcinomas and malignant from benign lesions. However they could serve as a useful adjunct in determining whether a lesion is a benign non-neoplastic nodule or a neoplasm [134,161,244].

This study confirms the findings of De Matos [237], that different markers are useful in specific thyroid carcinomas and that a panel of markers is useful to differentiate between follicular lesions of the thyroid. Immunopositivity for both was significantly more pronounced in malignant than benign lesions. The use of more than one immunomarker further strengthens the possibility of a correct diagnostic approach.

3.5 CONCLUSION

The distinction between benign and malignant thyroid lesions remains problematical in fine-needle aspiration cytology, and it is clear from the

literature that discrepant results have been reported in immunodiagnostic studies.

This study has demonstrated that HBME-1 is a more sensitive indicator of thyroid malignancy than Galectin-3 in histology tissue as well as in corresponding fine-needle aspiration smears. Furthermore this data showed that HBME-1 is a better marker of malignancy of papillary carcinomas and follicular carcinomas in tissue sections. This finding was supported by various researchers [164,165,229,262].

These results demonstrated that the sensitivity of immunohistochemistry for diagnosing malignancy was better than the immunocytochemistry, but the specificity of immunocytochemistry was superior. Furthermore the diagnostic accuracy of immunohistochemistry (86%) and immunocytochemistry (88%) using co-expression of these two antibodies was excellent.

In this study on immunocytochemistry using co-expression of Galectin-3 and HBME-1, we could clearly distinguish the non-neoplastic from the neoplastic lesions. None of the non-neoplastic lesions co-expressed any positivity with Galectin-3 and HMBE-1.

From these results it can be seen that a significant number of follicular adenomas showed expression of Galectin-3 and/or HBME-1 and this is consistent with findings in the literature [134,161,246]. However, only 14% of

the benign neoplastic lesions showed co-expression with these two antibodies in comparison to 74% of the malignant neoplasms.

This data showed that both these markers can play an important role in differentiating malignant thyroid nodules from benign nodules. However, their ability to distinguish follicular carcinomas from adenomas was not that reliable. Unfortunately, in contrast to studies by De Matos [237], Mills [247] and Niedziela [251] concerning the differential diagnosis of follicular-patterned lesions, we found none of these markers sufficient for a reliable diagnosis.

In this study on immunocytochemistry, papillary carcinomas were clearly identified with 100% co-expression in the classic and 71% in the follicular variant of papillary carcinoma. For the surgeon the identification of papillary carcinoma is critical, as this determines the extent of surgery. Similarly, the confirmation of a non-neoplastic lesion may prevent surgery. In most cases follicular neoplasms, benign or malignant, will usually be excised for histopathology, prior to definitive therapy.

The lack of reliable morphologic criteria for the diagnosis of malignancy in a number of thyroid neoplasms requires adherence to strict criteria to avoid unnecessary treatment. The use of more than one immunomarker further strengthens the possibility of a correct diagnostic approach, especially in follicular lesions. This study confirms the findings of De Matos [237], that different markers are useful in specific thyroid carcinomas and that a panel of markers is useful to differentiate between follicular patterned lesions of the

thyroid. Along with careful histological and cytological evaluation, this panel of immunodiagnostic markers provides a useful tool for the analysis of difficult thyroid lesions.

Fine-needle aspiration biopsies of palpable thyroid lesions remain an area of diagnostic difficulty in cytology, and despite the effectiveness of these methods, the diagnosis of follicular thyroid lesions in particular remains a diagnostic challenge.

CHAPTER 4

FUTURE STUDIES

The diagnostic accuracy of fine-needle aspiration cytology may be enhanced by the implementation of liquid based cytology techniques. Although thyroid fine-needle aspiration is widely accepted as the primary diagnostic procedure for thyroid nodules, studies by Afifi [192], Biscotti [263], Frost [264] and Zang [265] on liquid-based techniques have provided promising results.

Malle and colleagues [190] studied the diagnostic accuracy of the ThinPrep® technique (Cytoc Corp., Boxborough, Massachusetts, and U.S.A) (See Chapter 1). With liquid based cytology there is a substantial drop in the rate of unsatisfactory samples in fine-needle aspiration biopsies of the thyroid from 8.93% for conventional smears, to 3.92% for the ThinPrep method [190]. The Malle results [190] were comparable to those of direct smears and ThinPrep® split specimens in their own study and in contemporary articles employing the optimal approach [24,34,133,190].

We are currently investigating the possibility of performing liquid-based cytology techniques in our laboratory. The first study with the scoring system demonstrated that cytomorphological features play a paramount role in the cytological diagnosis of papillary carcinomas, especially the follicular variant. With liquid based cytology techniques, 50% of the background (blood,

inflammation and colloid) are washed away and the architectural and morphological features will be better preserved in comparison to the conventional smears. In the thin-layered study by Malle and associates [190] colloid was less (present in droplets), the background was cleaner and there was a substantial increase in cellularity. Moreover, nuclear detail, nucleoli and morphology were more prominent and better preserved and determination of malignancy was much easier.

The study of Malle [190] highlighted the ability of ThinPrep® to retain cellular material for a panel of immunohistochemical stains found to be helpful in challenging thyroid cases. According to Nasuti (2006) the ThinPrep® technique allows a cost-effective and labour-saving semi-automated processing. These attributes could make ThinPrep® processing an obvious choice for thyroid fine-needle aspirations and cellular material can be archived for ancillary studies.

Fine-needle aspiration biopsies of palpable thyroid lesions present an ongoing challenge and despite the effectiveness of these adjunctive methods, the diagnosis of thyroid lesions remains a diagnostic dilemma.

*“The art of cytology consists in refining our
visual criteria much as the connoisseur refines his
or her taste”*

- DeMay 1996

REFERENCES

- [1]. DeMay RM. Thyroid. In: The art and science of cytopathology. Chicago, IL: ASCP Press; 1996. pp 704-778.
- [2]. Gharib H, Goellner JR. Fine-needle aspiration biopsy of the thyroid: An appraisal. *Ann Intern Med* 1993a;118:282-9.
- [3]. Greaves TS, Olvera M, Florentine BD et al. Follicular lesions of thyroid: A 5-year experience. *Cancer* 2000;90:335-41.
- [4]. Al-Sayer HM, Krukowski ZM, Williams VMM et al. Fine needle aspiration cytology in isolated thyroid swellings: A prospective two year evaluation. *Br Med J* 1985;290:1490-2.
- [5]. Atkinson BF. Fine needle aspiration of the thyroid. *Monogr Pathol* 1993;35:166-99.
- [6]. Caruso D, Mazzaferri E. Fine needle aspiration biopsy in the management of thyroid nodules. *Endocrinologist* 1991;1:194-202.
- [7]. Hamburger JI. Consistency of sequential needle biopsy findings for thyroid nodules. Management implications. *Arch Intern Med* 1987;147:97-9.

[8]. Geisinger KR, Raab S, Stanley MW, Silverman JF. Thyroid gland fine needle aspiration. In: Modern Cytopathology. Philadelphia, Churchill Livingstone; 2004. pp. 731-780.

[9]. LiVolsi VA. Papillary neoplasms of the thyroid: pathologic and prognostic features. *Anat Pathol* 1992a;97:426-34.

[10]. DeGroot LJ. Clinical review 2: Diagnostic approach and management of patients exposed to irradiation to the thyroid. *J Clin Endocrinol Metab* 1989a;69:925-8.

[11]. DeGroot LJ, Kaplan EL, McCormic M et al. Natural history, treatment and course of papillary thyroid carcinoma. *J Clin Endocrinol Metab* 1990;71:414-24.

[12]. Hay ID, Grant CS, Bergstrahl EJ et al. Unilateral total lobectomy: is it sufficient surgical treatment for patient with AMES low-risk papillary thyroid carcinoma? *Surgery* 1998;124:958-64.

[13]. Mazzaferri EL, Jhiang SM. Long-term impact of initial surgical and medical therapy on papillary and follicular thyroid cancer. *Am J Med* 1994;97:418-28.

- [14]. Ashcraft MW, Van Herle AJ. Management of thyroid nodules.I: History and physical examination, blood tests, X-ray tests, and ultrasonography. *Head Neck Surg* 1981a;3:216-230.
- [15]. Carcangiu ML, Zampi G, Pupi A, et al. Papillary carcinoma of the thyroid: a clinicopathological study of 241 cases treated at the University of Florence, Italy. *Cancer* 1985a;55:805-28.
- [16]. De la Santos E, Keyhani-Rofagha S Cunningham J et al. Cystic thyroid nodules: the dilemma of malignant nodules. *Arch Intern Med* 1990;150:1422-7.
- [17]. Hammer M, Wortsman J, Folse R. Cancer in cystic lesions of the thyroid. *Arch Surg* 1982;117:1020-3.
- [18]. Jayaram G, Kaur A. Cystic thyroid nodules harbouring malignancy: a problem in the fine needle aspiration cytodiagnosis. *Acta Cytol* 1989;33:941-2.
- [19]. Muller N, Coopenberg P, Suen K et al. Needle aspiration biopsy in cystic papillary carcinoma of the thyroid. *Am J Res* 1985;144:251-3.
- [20]. Sarda A, Bal S, Gupta S, et al. Diagnosis and treatment of cystic disease of the thyroid by aspiration. *Surgery* 1988;103:593-6.

[21]. Chan JKC. Papillary carcinoma of Thyroid: Classical variants. *Histol Histopathol* 1990;5:241-57.

[22]. Chan JKC. Strict criteria should be applied in the diagnosis of encapsulated follicular variant of papillary thyroid carcinoma. *Am J Clin Pathol* 2002;117:16-8.

[23]. Renshaw AA, Gould EW. Why the tendency to “overdiagnose” the follicular variant of papillary thyroid carcinoma. *Am J Clin Pathol* 2002;117:16-8.

[24]. Baloch ZW, Fleisher S, LiVolsi VA, et al. Diagnosis of “follicular neoplasm” : A gray zone in thyroid fine-needle aspiration cytology. *Diagn Cytopathol* 2002;26:41-44.

[25]. Rosai J, Zampi G, Carcangiu ML. Papillary carcinoma of the thyroid. *Am J Surg Pathol* 1983;7:809-17.

[26]. Rosai J. Papillary carcinoma. *Monogr Pathol* 1993;35:138-65.

[27]. Chen KTK, Rosai J. Follicular variant of papillary carcinoma: A clinopathological study of six cases. *Am J Surg Pathol* 1977;1:123-30.

[28]. Hamburger JI, Hamburger SW. Declining role of frozen section in surgical planning for thyroid nodules. *Surgery* 1985;98:307-12.

- [29]. Hamburger JI, Husain M. Semiquantative criteria for fine-needle biopsy diagnosis: reduced false negative diagnosis. *Diagn Cytopathol* 1988;4:14-7.
- [30]. Miller JM, Hamburger JI, Kini SR. The needle biopsy diagnosis of papillary thyroid carcinoma. *Cancer* 1981;48:989-93.
- [31]. Tielens ET, Sherman SI, Hruban RH, et al. Follicular variant of papillary carcinoma: A clinicopathological study. *Cancer* 1994;73:424-31.
- [32]. Harach HR, Day ES, Zusman SB. Occult papillary microcarcinoma of the thyroid: A potential pitfall of fine needle aspiration cytology? *J Clin Pathol* 1992a;44:205-7.
- [33]. Powari M, Dey P, Saikia UN. Fine needle aspiration cytology of follicular variant of papillary carcinoma of thyroid. *Cytopathology* 2003;14:212-5.
- [34]. Baloch ZW, Abraham S, Roberts S et al. Differential expression of cytokeratins in follicular variant of papillary carcinoma: an immunohistochemical study and its diagnostic utility. *Hum Pathol* 1999;30:1161-71.
- [35]. Fulciniti F, Benincasa G, Vetrani A et al. Follicular variant of papillary carcinoma: Cytologic findings on FNAB samples-experience with 16 cases. *Diagn Cytopathol* 2001;25:86-93.

- [36]. Hegedus L, Perrild H, Poulsen LR et al. The determination of thyroid volume by ultrasound and its relationship to body weight and sex in normal subjects. *J Clin Endocrinol Metab* 1983;56:260-3.
- [37]. Pankow BG, Michalak J, McGee MK. Adult human thyroid weight. *Health Phys* 1985;49:1097-3.
- [38]. LiVolsi VA. Calcitonin: the hormone and its significance. *Prog Surg Pathol* 1980;1:71-103.
- [39]. Gould VE, Johannessen JV. Electron microscopy in human medicine, vol 10: Endocrine organs. New York: McGraw-Hill;1981. pp. 29-107.
- [40]. Hazard JV. The C-cells (parafollicular cells) of the thyroid gland and medullary thyroid carcinoma. *Am J Pathol* 1977;88:214-49.
- [41]. Söderstrom N. Puncture of goiters for aspiration biopsy: A preliminary report. *Acta Med Scand* 1952;144:237-44.
- [42]. Kini SR, Miller JM, Hamburger JI. Cytopathology of thyroid nodules. *Henry Ford Hosp Med J* 1982b;30:17-24.
- [43]. Atkinson B, Ernest CS, LiVolsi VA. Cytologic diagnosis of follicular lesions of the thyroid. *Diagn Cytopath* 1986;2:1-3.

[44]. Aggerwal S, Jayaram G, Kakar A. Fine needle aspiration cytology of the solitary colloid thyroid nodule: comparison with ultrasonography, radionuclide perfusion study and xeroradiography. *Acta Cytol* 1989;33:41-7.

[45]. Boon ME, Kok LP. An explanation for the reported variability of nuclear areas in air-dried Romanowsky-Giemsa-stained smears of follicular tumors of the thyroid. *Acta Cytol* 1987;31:527-30.

[46]. Wright RG, Castles H. Variability of thyroid cell nuclear size with Romanowsky stains. *Acta Cytol* 1987b;31:526-7.

[47]. Klencki PJ, Slowinska-Klencka D, Sporny S et al. Age related changes in the size of thyrocyte nuclei in aspirates from nontoxic nodular goiter. *Acta Cytol* 1994;38:524-6.

[48]. Heiman A, Moll U. Spinal metastasis of a thyroglobulin-rich hürthle cell carcinoma detected by fine-needle aspiration: Light and electron microscopic study of an unusual case. *Acta Cytol* 1998;33:639-44.

[49]. Bacci V, Giammarco V et al. Hürthle cell hyperplasia and sarcoidosis of the thyroid. *Arch Pathol Lab Med* 1991;115:1004-46.

[50]. Vander JB, Gaston EA, Dawber TR. The significance of nontoxic thyroid nodules: A final report of a 15-year study of the incidence of thyroid malignancy. *Ann Intern Med* 1968;69:537-40.

- [51]. Mazzaferri EL. Management of a solitary thyroid nodule. *New Eng J Med* 1993;328:553-9.
- [52]. Tunbridge WMG, Evered DC, Hall R et al. The spectrum of thyroid disease in a community: The Wickham survey. *Clin Endocrinol* 1977;7:481-93.
- [53]. Griffen JE. Southwestern Internal Medicine Conference: management of thyroid nodules. *Am J Med Sci* 1988;296:336-47.
- [54]. Campbell JP, Pillsbury HC III: Management of the thyroid nodule. *Head Neck* 1989;11:414-25.
- [55]. Van Herle AJ, Rich P, Ljung B-ME et al. The thyroid nodule. *Ann Intern Med* 1982;96:221-32.
- [56]. Wong CK, Wheeler MH. Thyroid nodules: Rational management. *World J Surg* 2000;24(8):934-41.
- [57]. Wingo PA, Tong T, Bolten S. Cancer Statistics. *CA Cancer J Clin* 1995;45:8-30.
- [58]. Carpi A, Toni MG, DiCoscio G et al: The thyroid nodule: Diagnostic strategy. *Thyroidology* 1991;3:17-23.

- [59]. Brener JL. Clinical features of benign and malignant goiter: Part 1: Thyroidexamination, hyperthyroid goiters, and the clinical manifestations of hyperthyroidism. *Hosp Med* 1967a;3:58-77.
- [60]. Mazzaferri EL, de los Santos ET, Rofagha-Keyani S. Solitary thyroid nodule: Diagnosis and management. *Med Clin North Am* 1988;72:1177-210.
- [61]. Franklyn JA, Daykin J, Young J et al. Fine needle aspiration cytology in diffuse and multinodular goitre compared with solitary nodules. *Br Med J* 1993;307:240.
- [62]. Miki H, Oshimo K, Inoue H et al. Diagnosis and surgical treatment of small papillary carcinomas of the thyroid gland. *J Surg Oncol* 1993;54:78-81.
- [63]. Hamming JF, Goslings BM, van Steenis GL et al. The value of fine-needle aspiration biopsy in patients with nodular thyroid disease divided into groups of suspicion of malignant neoplasms on clinical grounds. *Arch Intern Med* 1990; 150:113-6.
- [64]. Kuma K, Matsuzuka F, Kobayashi A et al. Outcome of long standing solitary thyroid nodules. *World J Surg* 1992;16:583-8.
- [65]. Wool MS. Thyroid nodules. The place of fine-needle aspiration biopsy in management. *Postgrad Med* 1993;94(1):111-22.

[66]. Lo Gerfo P, Starker P, Weber C et al. The incidence of cancer in surgically treated thyroid nodules based on method of selection. *Surgery* 1985;98:1197-201.

[67]. Layfield LJ, Reichman A, Bottles K et al. Clinical determinants for the management of thyroid nodules by fine-needle aspiration cytology. *Arch Otolarengol Head Neck Surg* 1992;118:717-21.

[68]. Jayaram G. Fine needle aspiration study of solitary thyroid nodule: Profile of 308 cases with histologic correlation. *Acta Cytol* 1985;29:967-73.

[69]. Kini SR. Needle aspiration biopsy of the thyroid: revisited. *Diagn Cytopathol* 1993;9:249-51.

[70]. Akerman M, Tennfall J, Björklund J et al. Sensitivity and specificity of fine needle aspiration cytology in the diagnosis of tumours of the thyroid gland. *Acta Cytol* 1985;29:850-5.

[71]. Block MA, Dailey GE, Robb JA. Thyroid nodules indeterminate by needle biopsy. *Am J Surg* 1983;146:72-8.

[72]. Rojeski MT, Gharib H. Nodular thyroid disease: Evaluation and management. *N Engl J Med* 1985;313:428-36.

- [73]. Harach HR. Usefulness of fine needle aspiration biopsy of the thyroid in an endemic goiter region. *Acta Cytol* 1989;33:31-5.
- [74]. Suen KC, Quenville NF. Fine needle aspiration biopsy of the thyroid gland: a study of 304 cases. *J Clin Pathol* 1983;36:1036-45.
- [75]. Busseniers A, Oertel Y. Cellular adenomatoid nodules of the thyroid: Review of 219 fine-needle aspirates. *Diagn Cytopathol* 1993;9:581-9.
- [76]. Basu D, Jayaram G. A logistic model for thyroid lesions. *Diagn Cytopathol* 1992; 8:23-7.
- [77]. Klemi P, Joensuu H, Nylamo E. Fine needle aspiration biopsy in the diagnosis of thyroid nodules. *Acta Cytol* 1991;35:434-8.
- [78]. Gharib H. Fine-needle aspiration biopsy of thyroid nodules: Advantages, limitations, and effect. *Mayo Clin Proc* 1994;69:44-9.
- [79]. Silverman JF, West RL, Larkin EW et al. The role of fine-needle aspiration biopsy in the rapid diagnosis and management of thyroid neoplasm. *Cancer* 1986a;57: 1164-70.
- [80]. Caraway NP, Sneige N, Samaan NA. Diagnostic pitfalls in thyroid fine-needle aspiration: a review of 394 cases. *Diagn Cytopathol* 1993;9:345-50.

[81]. Hamburger JI, Hamburger SW. Fine needle biopsy of thyroid nodules: avoiding the pitfalls. *NY State J Med* 1986;86:241-9.

[82]. Silver CE, Loirdice J, Johnson JM et al. Needle aspiration biopsy of thyroid nodules. *Surg Gynecol Obstet* 1981;152:469-72.

[83]. Watne AL, Stark J, McQuitty D et al. Follicular carcinoma of the thyroid. *Semin Surg Oncol* 1991;7:87-91.

[84]. Kini SR, Miller JM, Hamburger et al. Cytology of follicular lesions of the thyroid gland. *Diagn Cytopathol* 1985;1:130-2.

[85]. Kennedy J. The pathology of dys hormonogenic goitre. *J Pathol* 1969;99:251-64.

[86]. Struder H, Peter HJ, Gerber H. Natural heterogeneity of thyroid cells: The basis of understanding thyroid function and nodular goiter growth. *Endocrinol Rev* 1989; 10:125-35.

[87]. Hsu C, Boey J. Diagnostic pitfalls in the fine needle aspiration of thyroid nodules: a study of 555 cases in Chinese patients. *Acta Cytol* 1987;31:699-704.

[88]. Chu EW, Hanson TA, Goldman JM et al. Study of the cells in fine needle aspirations of the thyroid gland. *Acta Cytol* 1979;23:309-14.

[89]. Kini SR, Miller JM, Hamburger JL et al. Cytopathology of follicular lesions of the thyroid. *Diagn Cytolpathol* 1985;1:129-32.

[90]. Lowhagen T. Thyroid. In: Zajizek J, editor. *Aspiration biopsy cytology. I. Cytology of supradiaphragmatic organs*; 1974.

[91]. Gharib H, Goellner JR, Johnson DA. Fine-needle aspiration cytology of the thyroid: a 12- year experience with 11,000 biopsies. *Clin Lab Med* 1993b;13:699-709.

[92]. LiVolsi VA, Merino MJ. Squamous cells in the human thyroid gland. *Am J Surg Pathol* 1978;2:133-40.

[93]. Al-Moussa M, Berk J. Histometry of thyroids containing few and multiple nodules. *J Clin Pathol* 1986;39:483-8.

[94]. Faroux M, Pluot M, Delisle M et al. Evaluation of morphological criteria in the cytological diagnosis of thyroid cold nodules: a preliminary study. *Pathol Res Pract* 1990;186:330-5.

[95]. Suen KC. How does one separate cellular follicular lesions of the thyroid by fine-needle aspiration biopsy? *Diagn Cytolpathol* 1988;4:78-81.

[96]. Hapke MR, Denher LP. The optical clear nucleus: A reliable sign of papillary carcinoma of the thyroid? *Am J Surg Pathol* 1979;3:31-8.

[97]. Lew W, Orell S, Henderson DW. Intranuclear vacuoles in nonpapillary carcinoma of the thyroid: A report of three cases. *Acta Cytol* 1984;28:581-586.

[98]. Leung C-S, Hartwick RWJ, Bedard YC. Correlation of cytologic and histologic features in variants of papillary carcinoma of the thyroid. *Acta Cytol* 1993;37:645-50.

[99]. Miller TR, Bottles K, Holly EA et al. Step-wise logistic regression analysis of papillary carcinoma of the thyroid. *Acta Cytol* 1986;30:285-93.

[100]. Gould E, Watzak L, Chamiso W et al. Nuclear grooves in cytologic preparations: a study of the utility of this feature in the diagnosis of papillary carcinoma. *Acta Cytol* 1989;33:16-20.

[101]. Chan JKC, Saw D. The grooved nucleus: a useful diagnostic criterion of papillary carcinoma of the thyroid. *Am J Surg Pathol* 1986;10:672-9.

[102]. Jogai S, Al-Jassar A, Temmin L et al. Fine needle aspiration cytology of the thyroid: A cytohistologic study with evaluation of discordant cases. *Acta Cytol* 2005;49:483-7.

[103]. Scopa CD, Melachrinous M, Saradopolou C et al. The significance of the grooved nucleus in thyroid lesions. *Mod Pathol* 1993;6:691-694.

[104]. Lugani S, Gupta PK, LiVolsi VA et al. Thyroid nodules with FNA cytology suspicious for follicular variant of papillary carcinoma. *Diagn Cytopathol* 2000; 23:380-5.

[105]. Yan Z, Yang GCH, Waisman J. A low-power, "architectural", clue to the follicular variant of papillary thyroid adenocarcinoma in aspiration biopsy. *Acta Cytol* 2000;44:211-17.

[106]. Zacks JF, Morenas A, Beazley RM et al. Fine-needle aspiration cytology diagnosis of colloid nodule versus follicular variant of papillary carcinoma of the thyroid. *Diagn Cytopathol* 1998;18: 87-90.

[107]. Lawson W, Biller HF. The solitary thyroid nodule: Diagnosis and management of malignant disease. *Am J Otolaryngol* 1983;4:43-7.

[108]. Carillo JF, Frias-Mendivil M, Ochoa-Carillo FJ et al. Accuracy of fine-needle aspiration biopsy of the thyroid combined with an evaluation of clinical and radiologic factors. *Otolaryngol Head Neck Surg* 2000;122:917-21.

[109]. Tuttle RM, Lemar H, Burch HB. Clinical features associated with an increased risk of thyroid malignancy in patients with follicular neoplasia by fine-needle aspiration. *Thyroid* 1998;8:377-83.

[110]. Anderson JB, Webb AJ. Fine-needle aspiration biopsy and the diagnosis of thyroid cancer. *Br J Surg* 1987;74:292-6.

[111]. Webb AJ. Through a glass darkley (the development of needle aspiration biopsy) *Bristol Med Chir J* 1974;89:59-68.

[112]. DeGroot LJ. Laboratory diagnosis of thyroid tumours. *Ann Clin Lab Sci* 1983b;13:77-82.

[113]. Suen KC. Limitations of aspiration cytology in the diagnosis of primary neoplasms [letter]. *Acta Cytol* 1985;9:488-9.

[114]. Guidelines of the Papanicolaou Society of Cytology for the examination of fine-needle aspiration specimens from thyroid nodules. The Papanicolaou Society of Cytopathology task force on standards of practice. *Mod Pathol* 1996;9:710-15.

[115]. Abu-Nema T, Ayyash K, Tibblin S et al. Role of aspiration biopsy cytology in the diagnosis of cold solitary thyroid nodules. *Br J Surg* 1987;74:203.

[116]. Baskin HJ, Guarda LA. Influence of needle biopsy on management of thyroid nodules: reasons to expand its use. *South Med J* 1987;80:702-5.

[117]. Frable MA, Frable WJ. Fine needle aspiration biopsy of the thyroid gland. *Laryngoscope* 1980;90:1619-25.

[118]. Frable WJ. The treatment of thyroid cancer: the role of fine needle aspiration cytology. *Arch Otolaryngol Head Surg* 1986;112:1200-3.

[119]. Grant CS, Hay ID, Gough IR et al. Long term follow-up of patients with benign thyroid fine-needle aspiration cytology diagnosis. *Surgery* 1989;106:980-6.

[120]. Munn JS, Castelli C, Prinz RA et al. Needle biopsy of nodular thyroid disease. *Am Surg* 1988;54:438-43.

[121]. Piromalli D, Martelli G, del Prato I et al. The role of fine-needle aspiration in the diagnosis of thyroid nodules: analysis of 795 consecutive cases. *J Surg Oncol* 1992;50:247-50.

[122]. Schmid KW, Hittmair A, Öfner C et al. Metastatic tumours in fine needle aspiration biopsy of the thyroid. *Acta Cytol* 1986;35:722-4.

[123]. Tani EM, Skoog L, Löwhagen T. Clinical utility of fine needle aspiration cytology of the thyroid. *Ann Rev Med* 1988;39:255-60.

[124]. Dey P, Ray R. Comparison of fine needle sampling by capillary action and fine needle aspiration. *Cytopathology* 1993; 299-303.

[125]. Santos J, Leiman G. Nonaspiration fine needle cytology: Application of a new technique to nodular thyroid disease. *Acta Cytol* 1988;32:353-6.

- [126]. Yang GC, Liebeskind D, Messina AW. Ultrasound-guided fine-needle aspiration of the thyroid assessed by ultrafast Papanicolaou stain: data from 1135 biopsies with a two-to six-year follow-up. *Thyroid* 2001;11:581.
- [127]. Jayaram G, Gupta B. Nonaspiration fine needle cytology in diffuse and nodular thyroid lesions. *Acta Cytol* 1991;35:789-90.
- [128]. Mair S, Dumbar F, Becker P et al. Fine needle cytology: Is aspiration suction necessary? *Acta Cytol* 1989;33:809-13.
- [129]. Kumarasinghe M, Sherifdeen A. Fine needle sampling without aspiration. *Pathology* 1995;27:330-2.
- [130]. Nguyen G-K, Ginsberg J, Crockford PM. Fine-needle aspiration biopsy cytology of the thyroid: Its value and limitations in the diagnosis and management of solitary thyroid nodules. *Pathol Annu* 1991;26:63-91.
- [131]. Johnson DA, Goellner JR. Aspiration cytology of cystic thyroid neoplasms. *Acta Cytol* 1981;25:711.
- [132]. Smith J, Cheifetz RE, Schneidereit N et al. Can cytology accurately predict benign follicular nodules? *Amer J Surg* 2005;189; 592-5.
- [133]. Baloch ZW, Sack MJ, Yu GH, et al. Fine-needle aspiration of thyroid: an institutional experience. *Thyroid* 1998;8:565-9.

[134]. Bartolazzi A, Gasparri A, Papotti M et al. Application of an immunodiagnostic method for improving preoperative diagnosis of nodular thyroid lesions. *Lancet* 2001;357:1644-50.

[135]. Haugen BR, Woodmansee WW, McDermott MT. Towards improving the utility of fine-needle aspiration biopsy for the diagnosis of thyroid tumours. *Clin Endocrinol* 2002;56:281-6.

[136]. Crissman JD, Drozdowicz S, Johnson C et al. Fine needle aspiration diagnosis of the thyroid: a morphometric study. *Anal Quant Cytol Histol* 1991;13:321-8.

[137]. Luck JB, Mumaw VR, Frable WJ. Fine needle aspiration biopsy of the thyroid: differential diagnosis by videoplan image analysis. *Acta Cytol* 1982;26:793-9.

[138]. Salmon I, Gasperin P, Pasteels J-L et al. Relationship between histopathologic typing and morphonuclear assessments of 238 thyroid lesions: digital cell images analysis performed on Feulgen-stained nuclei from formalin-fixed, paraffin-embedded materials. *Am J Clin Pathol* 1992;97:776-86.

[139]. Arataki Y, Kotani T, Tamura K et al. Dipeptidyl aminopeptidase IV staining of cytologic preparations to distinguish benign from malignant thyroid disease. *Am J Clin Pathol* 1991;96:306-10.

[140]. Kashyab V, Kaushik N, Bhambhani S et al. Supportive role of image analysis and DNA ploidy pattern in the diagnosis of thyroid tumours. *Diagn Cytopathol* 1992; 8:228-30.

[141]. Gharib H, Goellner JR, Zinsmeister AR et al. Fine-needle aspiration biopsy of the thyroid; the problem of suspicious cytologic findings. *Ann Intern Med* 1984 1884;101:25-8.

[142]. Raber W, Kaserer K, Niederle B et al. Risk factors for malignancy of thyroid nodules initially identified as follicular neoplasia by fine-needle aspiration: Results of a prospective study of one hundred twenty patients. *Thyroid* 2000;10:70-12.

[143]. Schlinkert RT, Van Heerden JA, Goellner JR et al. Factors that predict malignant thyroid lesion when fine-needle aspiration is “ suspicious for follicular neoplasm” *Mayo Clin Proc* 1997;72:913-6.

[144]. Cerosimo E, Gharib H, Suman VJ et al. “Suspicious “ thyroid cytology findings: Outcome in patients without immediate surgical treatment. *Mayo Clin Proc* 1993;68:343-8.

[145]. Logdsundaram R, Saha M, Radhika S et al. Morphometric image analysis of follicular lesions of the thyroid. [Abstract] *Acta Cytol* 2004;48:455.

[146]. Cady B, Rossi R. An expanded view of risk-group definition in differentiating thyroid carcinoma. *Surgery* 1988;104:947-53.

[147]. Hay ID, Grant CS, Taylor WF et al. Ipsilateral lobectomy versus bilateral resection in papillary thyroid carcinoma: A retrospective analysis of surgical outcome using novel prognostic scoring system. *Surgery* 1987;102:1088-95.

[148]. Emerick GT, Duh Q, Siperstein AE et al. Diagnosis, treatment, and outcome of follicular thyroid lesions. *Cancer* 1993;72:3287-95.

[149]. Heitzmann H, Richards FM. Use of the avidin-biotin complex for specific staining of biological membranes in electron microscopy. *Proc Natl Acad Sci USA* 1974;71:3537-41.

[150]. Guesdon JL, Ternynck T, Avrameas S. The use of avidin-biotin interaction in immunoenzymatic techniques. *J Histochem Cytochem* 1979;27:1131-9.

[151]. Hsu SM, Raine L, Fanger H. Use of avidin-biotin-peroxidase complex (ABC) in immunoperoxidase techniques: a comparison between ABC and unlabeled antibody (PAP) procedures. *J Histochem Cytochem* 1981;29:577-80.

[152]. Chess Q, Hadju SI. The role of immunoperoxidase staining in diagnostic cytology. *Acta Cytol* 1986;30:1-7.

- [153]. Dabbs DJ, Hafer L, Abendroth CS. Intraoperative immunocytochemistry of cytological scrape specimens. A rapid immunoperoxidase method for triage and diagnosis. *Acta Cytol* 1995;39:157-63.
- [154]. Flens MJ, van der Valk P, Tadema TM et al. The contribution of immunocytochemistry in diagnostic cytology: Comparison and evaluation with immunohistology. *Cancer* 1990;65:2704-11.
- [155]. Myers JD. Development and application of immunocytochemical staining techniques: A review. *Diagn Cytopathol* 1989;5:318-330.
- [156]. Nadji M. The potential value of immunoperoxidase techniques in diagnostic cytology. *Acta Cytol* 1980;24:44-47.
- [157]. Nadji M, Ganjei P. Immunocytochemistry in diagnostic cytology: A 12-year perspective. *Am J Clin Pathol* 1990;94:470-5.
- [158]. Dabbs DJ, Wang X. Immunocytochemistry on cytologic specimens of limited quantity. *Diag Cytopathol* 1998;18:166-9.
- [159]. Papotti J, Rodriques J, De Pompa R et al. Galectin-3 and HBME-1 expression in well-differentiated thyroid tumors with follicular architecture of uncertain malignant potential. *Mod Pathol* 2005;18:541-6.

[160]. Orlandi F, Saggiorato E, Pivano G et al. Galectin-3 is a presurgical marker of human thyroid carcinoma. *Cancer Res* 1998;58:3015-20.

[161]. Saggiorato E, Cappia S, Guili PD et al. Galectin-3 as a presurgical immunodiagnostic marker of minimally invasive follicular thyroid carcinoma. *J Clin Endocrinol Metab* 2001;86:5152-8.

[162]. Papotti M, Volante M, Saggiorato E et al. Role of galectin-3 immunodetection in the cytological diagnosis of thyroid cystic papillary carcinoma. *Eur J Endocrinol* 2002;147:515-21.

[163]. Casey MB, Lohse CM, Lloyd RV. Distinction between papillary thyroid hyperplasia and papillary thyroid carcinoma by immunochemical staining for cytokeratin 19, galectin-3, and HBME-1. *Endocr Pathol* 2003;14:55-60.

[164]. Miettinen M, Karkkainen P. Differential reactivity of HBME1 and CD15 antibodies with benign and malignant thyroid tumors. Preferential reactivity with malignant tumors. *Virchows Arch* 1996;429:213-9.

[165]. Sack MJ, Astegno-Osuna C, Lin BT, Battifora H et al. HBME-1 immunostaining in thyroid fine needle aspirations: A useful marker in the diagnosis of carcinoma. *Mod Pathol* 1997;10:668-74.

[166]. Cheung CC, Ezzat S, Freeman JI et al. Immunohistochemical diagnosis of papillary thyroid carcinoma. *Mod Pathol* 2001;14:338-42.

[167]. Raphael SJ. The meanings of markers: Ancillary techniques in the diagnosis of thyroid neoplasia. *Endocr Pathol* 2002; 13:301-11.

[168]. Fonseca E, Nesland JM, Hoie J et al. Pattern of expression of intermediate cytokeratin filaments in the thyroid gland: an immunohistochemical study of simple and stratified epithelial-type cytokeratins. *Virchows Arch* 1997;430:239-45.

[169]. De Micco C, Ruf J, Chrestian MA et al. Immunohistochemical study of thyroid peroxidase in normal and neoplastic human thyroid tissues. *Cancer* 1991;67:3036-41.

[170]. Chiappetta G, Bandiera A, Berlingieri MT et al. The expression of the high mobility group HMGI (Y) protein correlates with the malignant phenotype of human thyroid neoplasias. *Oncogene* 1995;10:1307-14.

[171]. Nikiforova MN, Lynch RA, Biddinger PW, et al. Ras point mutations and PAX8-PPAR γ re-arrangement in thyroid tumors: Evidence of distinct molecular pathways in thyroid follicular carcinomas. *J Clin Endocrinol Metab* 2003;88:2318-26.

[172]. Xu XC, el-Nagger AK, Lotan R. Differential expression of galectin-1 and galectin-3 in thyroid tumors. Potential diagnostic implications. *Am J Pathol* 1995;147:815-22.

[173]. Gasbarri A, Martegani MP, Del Prete F et al. Galectin-3 and CD44v6 isoforms in the preoperative evaluation of thyroid nodules. *J Clin Oncol* 1999;17:3494-502.

[174]. Kim M-J, Kim HJ, Hong SJ et al. Diagnostic utility of galectin-3 in aspirates of thyroid follicular lesions. *Acta Cytol* 2006;50:28-34.

[175]. Maruta J, Hashimoto H, Yamashita H et al. Immunostaining of galectin - 3 and CD44v6 using fine needle aspiration for distinguishing follicular carcinoma from adenomas. *Diagn Cytopathol* 2004;31:392-6.

[176]. Saggiorato E, Aversa S, Deandreis D et al. Galectin-3: presurgical marker of thyroid follicular epithelial cell-derived carcinomas. *J Endocrinol Invest* 2004; 27:311-7.

[177]. Gaffney RL, Carney JA, Sebo TJ et al. Galectin-3 expression in hyalinizing trabecular tumours of the thyroid gland. *Am J Surg Pathol* 2003;27:494-8.

[178]. Gasbarri A, Marchetti C, Iervasi G et al. From the bench to the bedside. Galectin-3 immunodetection for improving the preoperative diagnosis of the thyroid nodule. *Biomed Pharmacother* 2004;58:356-9.

[179]. Herrmann ME, LiVolsi VA, Pasha TL et al. Immunohistochemical expression of galectin-3 in benign and malignant thyroid tumours Arch Pathol Lab Med. 2002; 126:710-3.

[180]. Martins L, Matsuo SE, Ebina KN et al. Galectin-3 messenger ribonucleic acid and protein are expressed in benign thyroid tumours. J Clin Endocrinol Metab 2002; 87:4806-10.

[181]. Mase T, Funahashi H, Koshikawa T et al. HBME-1 immunostaining in thyroid tumours especially in follicular neoplasm. Endocr J 2003;50:173- 7.

[182]. Nasir A, Catalane E, Calafati S et al. Role of p53, CD44v6 and CD57 in differentiating between benign and malignant follicular neoplasms of the thyroid. In Vivo 2004;18:189-95.

[183]. Oestriecher-Kedem Y, Halpern M, Roizman P et al. Diagnostic value of galectin-3 as a marker for malignancy in follicular patterned thyroid nodules. Head Neck 2004;26:960-6.

[184]. Rigau V, Martel B, Evrard C et al. HBME-1 staining in thyroid pathology. Ann Pathol 2001;21:15-20.

[185]. Teng XD, Wang LJ, Yao HT et al. Expression of cytokeratin 19, galectin-3 and HBME-1 in thyroid lesions and their differential diagnosis. Zhonghua Bing Li Xue Za Zhi 2004;33:212-6.

[186]. Volente M, Bozzalla-Cassione F, DePompa R et al. Galectin-3 and HBME-1 expression in oncocytic cell tumours of the thyroid. *Virchows Arch* 2004;445:183-8.

[187]. Weber KB, Shroyer KR, Heinz DE et al. The use of galectin-3 and thyroid peroxidase for the diagnosis of thyroid cancer. *Am J Clin Pathol* 2004;122:524-31.

[188]. Chhieng DC, Ross JS, McKenna BJ. CD44 immunostaining of thyroid fine-needle aspirates differentiates thyroid papillary carcinoma from other lesions with nuclear grooves and inclusions. *Cancer* 1997;81:157-62.

[189]. Rossi ED, Raffaelli MD, Minimo C et al. Immunocytochemical evaluation of thyroid neoplasms on thin-layer smears from fine-needle aspiration biopsies. *Cancer Cytopathol* 2005;105:87-95.

[190]. Malle D, Valeri RM, Pazaitou-Panajiotou K et al. Our experience from the use of ThinPrep technique in thyroid fine needle aspiration. *Acta Cytol* 2006;50:23-7.

[191]. Michael CW, Hunter B. Interpretation of fine-needle aspirates processed by the ThinPrep technique. *Diagn Cytopathol* 2000;23:6-13.

[192]. Afify AM, Liu J, Al-Khafaji BM. Cytologic artifacts and pitfalls of thyroid fine-needle aspiration using ThinPrep. *Cancer* 2001;93:179-86.

[193]. Nasuti JF, Tam D, Gupta PK. Diagnostic value of liquid-based (ThinPrep) preparations in nongynaecologic cases. *Diagn Cytopathol* 2001; 24:137-41.

[194]. Cochand-Priollet B, Pratt JJ, Polivka et al. Thyroid fine needle aspiration: The morphologic features on ThinPrep slide preparations: eighty cases with histological control *Cytopathology* 2003;14:343-9.

[195]. McHenry CR, Rosen IB, Walfish PG et al. Influence of fine-needle aspiration biopsy and frozen section examination on the management of thyroid cancer. *Am J Surg* 1993a;166:353-6.

[196]. Prasad ML, Pellegata NS, Huang Y et al. galectin-3, fibronectin-1, CITED-1, HBME1 and cytokeratin-19 immunohistochemistry is useful for the differential diagnosis of thyroid tumors. *Mod Pathol* 2005;18:48-57.

[197]. Kini SR, Miller JM, Hamburger JI et al. Cytopathology of papillary carcinoma of the thyroid by fine-needle aspiration. *Acta Cytol* 1980;24:511-21.

[198]. LiVolsi VA, Asa SL. The demise of follicular carcinoma of the thyroid gland. *Thyroid* 1994;4:233-6.

[199]. DeMay RM. Follicular lesions of the thyroid-w(h)ither follicular carcinoma? *Am J Clin Pathol* 2000;114:681-3.

[200]. Goellner JR, Gharib H, Grant CS, Johnson DS. Fine needle aspiration of the thyroid, 1980 to 1986. *Acta Cytol* 1987;31:587-90.

[201]. Kung I, Yuen R. Fine needle aspiration of the thyroid: distinction between colloid nodules and follicular neoplasms using cell blocks and 21-gauge needles. *Acta Cytol* 1989;33:53-60.

[202]. Nayar R, Frost AR. Thyroid aspiration cytology: a 'cell pattern' approach to interpretation. *Sem Diagn Pathol* 2001;18:81-98.

[203]. Nasser S, Pitman M, Pilch B et al. Fine-needle aspiration biopsy of papillary thyroid carcinoma: diagnostic utility of cytokeratin 19 immunostaining. *Cancer* 2000;90:307-11.

[204]. Nair M, Kapila K, Karak AK et al. Papillary carcinoma of the thyroid and its variants: A cytohistological correlation. *Diagn Cytopathol* 2001;24:167-73.

[205]. Wu HH, Jones JN, Grzybicki DM et al. Sensitive cytologic criteria for the identification of follicular variant of papillary carcinoma in fine-needle aspiration biopsy. *Diagn Cytopathol* 2003;29:262-6.

[206]. Manju A, Mallik A, Kusum V. Fine needle aspiration cytology of follicular variant of papillary carcinoma of the thyroid. *Acta Cytol* 2005;50:663-8.

[207]. Damiani S, Dina R, Eusebi V. Cytologic grading of aggressive and nonaggressive variants of papillary carcinoma. *Am J Clin Pathol* 1994;101:651-55.

[208]. D'Avanzo KD. An expanded view of risk-group definition in differentiating thyroid carcinoma. *Surgery* 1988;104:947-53.

[209]. Gray WG, McKee GT. The thyroid gland. In: *Diagnostic Cytopathology*. 2nd edition. Philadelphia: Churchill Livingstone; 2003. pp.577-601.

[210]. Greenbaum E, Koss LG, Elequin F et al. The diagnostic value of flow cytometric DNA measurements in follicular tumours of the thyroid gland. *Cancer* 1985;56:2011-8.

[211]. Joensuu H, Klemi P, Eerola E. DNA aneuploidy in follicular adenomas of the thyroid gland. *Am J Pathol* 1986;124:373-6.

[212]. Fadda G, Rabitti C, Minimo C et al. Morphologic and planimetric diagnosis of follicular thyroid lesions on fine needle aspiration cytology. *Anal Quant Cytol Histol* 1995;17:247-56.

[213]. Montoroni R, Braccischi A, Scarpelli M et al. The number of nucleoli in benign and malignant thyroid lesions: a useful diagnostic sign in cytological preparations. *Cytopathol* 1990;1:153-61.

- [214]. Montoroni R, Braccischi A, Scarpelli M et al. Well-differentiated follicular neoplasms of the thyroid: reproducibility and validity of a decision tree classification based on nuclear and karyometric features. *Cytopathol* 1992;3:209-22.
- [215]. Tsou P-L, Hsiao Y-L, Chang T-C. Multinucleated giant cell in fine needle aspirates: Can they help differentiate papillary thyroid cancer from benign nodular goiter. *Acta Cytol* 2002;46:823-7.
- [216]. Riazmontazer N, Bedayat G. Psammoma bodies in fine needle aspirates from thyroid nodules containing nontoxic hyperplastic nodular goiters. *Acta Cytol* 1991;365-6.
- [217]. Das DK, Khanna CM, Tripathi RP et al. Solitary nodular goiter: Review of cytomorphologic features of 441 cases. *Acta Cytol* 1999;43:563-74.
- [218]. Fiorella RM, Isley W, Miller LK. Multinodular goiter of the thyroid mimicking malignancy: diagnostic pitfalls in fine-needle aspiration biopsy. *Diagn Cytopathol* 1993;9:351-7.
- [219]. Francis IM, Das DK, Sheikh ZA. Role of nuclear grooves in the diagnosis of papillary carcinoma. A quantitative assessment on fine needle aspiration smears. *Acta Cytol* 1995;39:409-15.

[220]. Deligeorgi-Politi H. Nuclear crease as a cytodagnostic feature of papillary carcinoma in fine-needle aspiration biopsies. *Diagn Cytopathol* 1987;3:307-10.

[221]. Shurbaji MS, Guptha PK, Frost JK. Nuclear grooves: a useful criterion in the cytopathologic diagnosis of papillary carcinoma. *Diagn Cytopathol* 1988;4:91-4.

[222]. Kesmodel SB, Terhune KP, Canter RJ et al. The diagnostic dilemma of follicular variant of papillary thyroid carcinoma. *Surgery* 2003;134: 1005-11.

[223]. Mesonero CE, Jugle JE, Wilbur DC et al. Fine-needle aspiration of the macrofollicular and microfollicular subtypes of the follicular variant of papillary carcinoma of the thyroid. *Cancer* 1998;84:235-44.

[224]. Yeh MW, Demircan O, Ituarte P et al. False-negative fine-needle aspiration cytology results delay treatment and adversely affect outcome in patients with thyroid carcinoma. *Thyroid* 2004;14:207-15.

[225]. Chehade JM, Silverburg AB, Kim J et al. Role of repeated fine-needle aspiration of thyroid nodules with benign cytologic features. *Endocr Pract* 2001;7:237-43.

[226]. Cramer H. Fine-needle aspiration cytology of the thyroid: An appraisal. *Cancer* 2000;90:325-9.

[227]. Ljung BM, Drejet A, Chiampi N et al. Diagnostic accuracy of fine-needle aspiration biopsy is determined by physician training in sampling technique. *Cancer* 2001;93:263-8.

[228]. Castro P, Fonseca E, Magalhaes J et al. Follicular, papillary and, 'hybrid' carcinomas of the thyroid. *Endocrinol Pathol* 2002;13:313-20.

[229]. Mai KT, Bokhary R, Yazdi HM et al. Reduced HBME-1 immunoreactivity of papillary thyroid carcinoma and papillary thyroid carcinoma-related neoplastic lesions with Hürthle cell and/or apocrine-like changes. *Histopathology* 2002;40:133-42.

[[230]. Tzen CY, Huang YW, Fu YS. Is atypical follicular adenoma of the thyroid a preinvasive malignancy? *Hum Pathol* 2003;34:666-9.

[231]. Hirikawa M, Carney JA, Goellner JR et al. Observation in encapsulated follicular lesions of the thyroid. *Am J Surg Pathol* 2002;26:1508-14.

[232]. Fassina AS, Montesco MC, Ninfo V et al. Histological evaluation of thyroid carcinomas: reproducibility of the 'WHO' classification. *Tumori* 1993;79:314-20.

[233]. Franc B. Observer variation of lesions of the thyroid. *Am J Surg Pathol* 2003;27:1177-8.

- [234]. Leong S-Y, Cooper K, Leong FJ. Manual of diagnostic antibodies for immunohistology. 2nd ed. London. Greenwich Medical Media Ltd. 2003.
- [235]. Brabant G, Hoang-Vu C, Cetin Y et al. E-cadherin: a differentiation marker in the thyroid malignancies. *Cancer Res* 1993;53:4987-93.
- [236]. Kroll TG, Sarraf P, Pecciarini L et al. PAX8-PPARgamma 1 fusion oncogene in human thyroid carcinoma. *Science* 2000;289:1357-60.
- [237]. De Matos PS, Ferreira AP, Facuri F deO, et al. The usefulness of HBME-1, cytokeratin 19, and galectin-3 immunostaining in the diagnosis of thyroid carcinoma. *Histopathology* 2005;47:391-401.
- [238]. Perillo NL, Marcus ME, Baum CG. Galectins: versatile modulators of cell adhesion, cell proliferation, and cell death. *J Mol Med* 1998; 76:402-12.
- [239]. Fernandez PL Merino MJ, Gomez M et al. Galectin-3 and laminin expression in neoplastic and non-neoplastic thyroid tissue. *J Pathol* 1997;181:80-6.
- [240]. Inohara H, Honjo Y, Yoshii T et al. Expression of galectin-3, in fine-needle aspirates as a diagnostic marker differentiating benign from malignant thyroid neoplasms. *Cancer* 1999;85:2475-84.

[241]. Rosai J. Immunochemical markers of thyroid tumors: significance and diagnostic applications. *Tumori* 2003;89:517-9.

[242]. Renshaw AA, Pinkus GS, Corson JM. HBME-1 aids in distinguishing mesotheliomas and adenocarcinomas of the lung and breast. *Mod Pathol* 1995;8: 152-4.

[243]. Chiariotti L, Berlingieri MT, Battaglia C et al. Expression of galectin-1 in normal thyroid gland and in differentiated and poorly differentiated thyroid tumours. *Int J Cancer* 1995;64:171-5.

[244]. Mehrotra A, Okporam A, Bouhaider R et al. Galectin-3 does not reliably distinguish benign from malignant thyroid neoplasms. *Histopathology* 2004;45:493-500.

[245]. Williams ED. Guest editorial: two proposals regarding the terminology of thyroid tumours *Int J Surg Pathol* 2000;8:181-3.

[246]. Ito Y, Yoshida H, Tomoda C et al. HBME-1 expression in follicular tumor of the thyroid: an investigation of whether it can be used as a marker to diagnose follicular carcinoma. *Anticancer Res* 2005;25:179-82.

[247]. Mills LJ, Poller DN, Yiangou C. Galectin-3 is not useful in thyroid FNA. *Cytopathol* 2005;16:132-8.

- [248]. Bernet VJ, Anderson J, Vaishnav Y, Solomon B et al. Determination of galectin-3 messenger ribonucleic acid overexpression in papillary thyroid cancer by quantitative transcription-polymerase chain reaction. *J Clin Endocrinol Metab* 2002;87:4792-6.
- [249]. Takano T, Miyauchi A, Matsuzuka F et al. Ubiquitous expression of galectin-3 mRNA in benign and malignant thyroid tumours. *Cancer Lett* 2003;199:69-73.
- [250]. Takenaka Y, Inohara H, Yoshi T et al. Malignant transformation of thyroid follicular cells by galectin-3. *Cancer Lett* 2003;195:111-9.
- [251]. Niedziela M, Maceluch J, Korman E. Galectin-3 is not a universal marker of malignancy in thyroid nodular disease in children and adolescents. *J Clin Endocrinol Metab* 2002;87:4411-5.
- [252]. Saggiorato E, De Pompa R, Volante M et al. Characterization of thyroid 'follicular neoplasms' in fine-needle aspiration cytological specimens using a panel of immunohistochemical markers: a proposal for clinical application. *Endocr Relat Cancer* 2005;12:305-17.
- [253]. Tallini G. Oncocytic tumors. *Virchows Arch* 1998;433:5-12.
- [254]. LiVolsi VA. *Surgical pathology of the thyroid*. Philadelphia, Saunders;1990.

[255]. Papotti M, Torchio B, Grassi L et al. Poorly differentiated oxyphilic (Hürthle cell) carcinomas of the thyroid. *Am J Surg Pathol* 1996;20:686-94.

[256]. Nascimento MC, Bisi H, Alves VA et al. Differential reactivity for galectin-3 in Hurthle cell adenomas and carcinomas. *Endocr Pathol* 2001;12:275-9.

[257]. Vasco V, Ferrand M, Cristofaro JD et al. Specific pattern of Ras oncogene mutations in follicular thyroid tumors. *J Clin Endocrinol Metab* 2003;88:2745-52.

[258]. Wagner K, Arciaga R, Siperstein A, Milas M et al. Thyrotropin receptor/thyroglobulin messenger ribonucleic acid in peripheral blood and fine-needle aspiration cytology: Diagnostic synergy for detecting thyroid cancer. *J Clin Endocrinol Metab* 2005;90:1921-4.

[259]. Dalquen P, Sauter G, Epper R et al. Immunocytochemistry in diagnostic cytology. *Recent Results Cancer Res* 1993;133:47-80.

[260]. Durhamel RC, Johnson DA. In: *Immunochemical staining methods* 3rd edition DAKO 1985; California, JHC.

[261]. Rosai J, Carcangiu ML, De Lellis RA. *Atlas of tumor pathology: tumors of the thyroid gland, 3rd series, fascicle 5*. Washington DC: Armed Forces Institute of Pathology 1992;1-343.

[262]. Van Hoeven KH, Kovatich AJ, Miettinen M. Immunocytochemical evaluation of HBME-1, CA 19-9, and CD-15 (Leu-M1) in fine-needle aspirates of thyroid nodules. *Diagn Cytopathol* 1998;18:93-7.

[263]. Biscotti CV, Hollow JA, Toddy SM et al. ThinPrep versus conventional smear cytology preparations in the analysis of thyroid fine needle aspiration specimens. *Am J Clin Pathol* 1995;104:150-3.

[264]. Frost AR, Sidawy MK, Ferfelli M et al. Utility of thin-layer preparations in fine needle aspiration: diagnostic accuracy, cytomorphology and optimal sample preparation. *Cancer (Cancer Cytopathol)* 1998;84:17-25.

[265]. Zhang Y, Fraser JL, Wang HH. Morphologic predictors of papillary carcinoma on fine needle aspiration of thyroid with ThinPrep preparations. *Diagn Cytopathol* 2001;24:378-83.

[266]. Nasuti JF. Utility of ThinPrep ® technique in thyroid fine needle aspiration: optimal vs practical approaches. *Acta Cytol* 2006;50:3-4.

[267]. DeLellis RA, Lloyd RV, Heitz PU et al. Tumours of endocrine organs. WHO classification of tumours. Lyon, IAPC Press;2004.