

# **OPTIMAL UTILIZATION OF GAMMA CAMERA TIME IN Tc-99m MDP BONE SCINTIGRAPHY**

ZABAH MUHAMMAD JAWA  
(MBBS, BscMedSchHons, FMCR (Nig))

Thesis presented in partial fulfilment of the requirements for the degree of

Master of Science in Medical Sciences (Nuclear Medicine)

at the Stellenbosch University



SUPERVISORS: Dr Sietske Rubow

Dr James Warwick

March 2007

## DECLARATION

I, ZABAH MUHAMMAD JAWA hereby declare that the work contained in this thesis is my own original work and I have not previously in its entirety or in part submitted it at any University for a degree.

.....


DR ZABAH MUHAMMAD JAWA

..... Day of ..... 2007

Division of Nuclear Medicine

Department of Medical Imaging and Clinical Oncology

Stellenbosch University



## ABSTRACT

**Introduction:** Whole body bone scintigraphy with Tc-99m MDP is able to provide a survey of the entire skeleton. The question arises if it is mandatory to perform a whole body bone scan in all patients, irrespective of the clinical indication. The aim of this study is to determine the implications of performing limited imaging in patients who had whole body bone scan for various clinical pathology with Tc-99m MDP, in order to determine if limited imaging would be acceptable in selected pathologies. This may enable gamma camera time to be optimally utilized in units with limited facilities.

**Materials and Methods:** Reports of 3015 patients with various clinical pathologies who had whole body bone scans with Tc-99m MDP in our department from January 2002 to December 2004 were retrospectively reviewed. The presence of pathologic radiotracer uptake was analyzed in order to establish the pattern of distribution. Clinically significant skeletal lesions were classified according to the anatomical regions where they were located viz; skull (including the neck), axial skeleton (including the pelvis and shoulders) and limbs.

**Results:** Our results showed that in patients with lung cancer, soft tissue sarcoma, and myeloma, there was an error in more than 25% of patients when limited imaging was performed. In patients with cancer of the breast, prostate, kidney, gastrointestinal system, and reproductive system and lymphoma there is an error in less than 5% of patients when limited imaging is employed. For

patients with more localized musculoskeletal disorders such as suspected stress fractures, complicated joint prosthesis and avascular necrosis of the femur head, regional imaging of the area of pathology showed a percentage error of less than 6%.

**Discussion:** From the results it is clear that in lung cancer, myeloma, soft tissue sarcoma and suspected osteomyelitis whole body imaging is essential. For renal and gastrointestinal cancers axial and skull imaging is adequate, while in patients with breast, prostate and reproductive system cancers and lymphoma, axial only imaging is suggested. In patients with suspected stress fractures, complicated joint prosthesis and avascular necrosis of the femur head, regional imaging of the area of pathology suffices.

Considering the time taken to perform a whole body bone scan and the shortage of Nuclear Medicine facilities coupled with a high patient load, especially in much of Africa, utilization of available imaging acquisition time is critical. Our study suggests clinical indications in which regional or limited imaging is acceptable.

## OPSOMMING

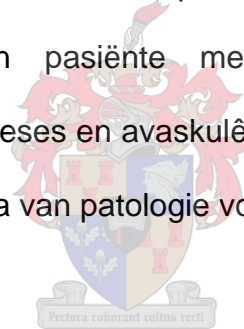
**Inleiding:** Heelligaam beenflikkergrafie met Tc-99m MDP kan 'n oorsig van die hele skelet bied. Die vraag ontstaan of dit noodsaaklik is om op alle pasiënte, ongeag die kliniese indikatie, 'n heelligaam beenflikkergram te doen. Die doel van hierdie studie is om in pasiënte wat heelligaam beenflikkergramme met Tc-99m MDP vir verskeie kliniese indikasies gehad het, vas te stel wat die implikasies van beperkte beelding sou wees. Daarvolgens word dan bepaal of beperkte beelding in geselekteerde patologiese toestande aanvaarbaar sou wees. Dit mag dit moontlik maak om gammakamera tyd in Kerngeneeskunde eenhede met beperkte fasiliteite optimaal te benut.

**Metodes:** Verslae van 3015 pasiënte met verskeie kliniese indikasies op wie heelligaam beenflikkergramme met Tc-99m MDP in ons departement tussen Januarie 2002 en Desember 2004 gedoen is, is retrospektiewelik beoordeel. Die aanwesigheid van patologiese opname van die radiofarmaseutikum is geanaliseer om die patroon van verspreiding van letstels vas te stel. Klinies betekenisvolle letsels is volgens die anatomiese area waar hulle voorkom geklassifiseer, nl. skedel (insluitende die nek), aksiale skelet (insluitende pelvis en skouers) en ledemate.

**Resultate:** Ons resultate het getoon dat daar in meer as 25% van pasiënte met longkanker, sagteweefsel sarkoom en miëloom 'n fout begaan word indien beperkte beelding uitgevoer word. In pasiënte met bors-, prostaat- en nierkanker, en kanker van die gastrointestinale en reprodktiewe stelsels asook

limfoom is daar 'n fout in minder as 5% van gevalle indien beperkte beelding uitgevoer word. In pasiënte met meer gelokaliseerde muskuloskeletale patologie soos stresfrakture, komplikasies van gewrigsprosteses en vermoedelike avaskulêre nekrose van die femurkop, het regionale beelding van die area van patologie 'n fout van minder as 6% getoon.


**Bespreking:** Uit die resultate is dit duidelik dat heelligaambeelding noodsaaklik is in longkanker, miëloom, sagteweefsel sarkoom en vermoedelike osteomiëlitis. Vir renale en gastro-intestinale kankers is beelding van die aksiale skelet en skedel voldoende, terwyl beelding van slegs die aksiale skelet voorgestel word in pasiënte met bors-, prostaat-, en reprodktiewe stelsel kankers asook limfoom. In pasiënte met vermoedelike stresfrakture, komplikasies van gewrigsprosteses en avaskulêre nekrose van die femurkop, is regionale beelding van die area van patologie voldoende.



As die tyd benodig vir heelligaam beenflikkergrafie en die tekort aan Kerngeneeskunde fasiliteite gepaardgaande met hoë pasiëntladings veral in Afrika in ag geneem word, is optimale gebruik van beskikbare beeldingstyd krities. Ons studie bied voorstelle vir kliniese indikasies waarin regionale of beperkte beelding aanvaarbaar is.

## DEDICATION

THIS BOOK IS DEDICATED TO GOD ALMIGHTY AND MY PARENTS, WIFE  
AND SON.



## TABLE OF CONTENTS


	<b>Page</b>
Declaration .....	ii
Abstract .....	iii
Opsomming .....	v
Dedication .....	vii
Table of contents .....	viii
List of tables .....	ix
Acknowledgements .....	x
Chapter 1: Introduction .....	1
Chapter 2: Literature Review .....	4
Chapter 3: Materials and Methods .....	22
Chapter 4: Results .....	27
Chapter 5: Discussion .....	42
Appendix I .....	60
References .....	62





**LIST OF TABLES**

	<b>Page</b>
Table 1 .....	27
Table 2 .....	34
Table 3 .....	35
Table 4 .....	59



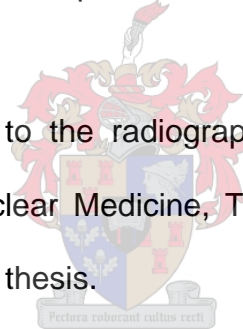
## ACKNOWLEDGEMENTS

I wish to express my unalloyed indebtedness and profound gratitude to Professor Annare Ellmann, Head: Department of Medical Imaging and Clinical Oncology, Tygerberg Hospital and Stellenbosch University for her untiring teaching, instruction and constant encouragement and support during the course of my training in this Department. She is indeed a great tutor a wonderful and understanding mother.

I am equally grateful to Drs James Warwick and Sietske Rubow for their tremendous assistance and continuous valuable advice.

To my colleagues in the department, I am grateful for their general understanding and support.

My gratitude also goes to the radiographers, nurses, technicians, and porters of the Division of Nuclear Medicine, Tygerberg Hospital, for the help rendered at every stage of this thesis.



I am also grateful to my family and relatives, especially my wife who has to bear long hours of my absence from home in pursuance of excellence during this period.

Finally, my gratitude to God, the Almighty by whose grace my life is spared, my strength is full and sustenance is constant till this day.

## CHAPTER ONE

### INTRODUCTION

Bone scintigraphy is undoubtedly one of the great success stories of nuclear medicine. It is a sensitive, non-invasive means of detecting a wide spectrum of skeletal disorders. Having started with the introduction of strontium-85m, strontium-87m, and fluorine-18 as the first radionuclides and subsequently technetium-labelled phosphorus-containing bone scanning agents, bone scintigraphy has grown to become one of the most performed procedures in nuclear medicine (1). Clinical applications of bone scintigraphy continue to enjoy growth covering an increasing number of benign and malignant conditions.

The value of bone scintigraphy lies in its ability to provide clinicians with information necessary to make an early diagnosis of diseases, allowing the timely initiation of appropriate therapy. In certain clinical conditions, such as carcinoma of the breast, the bone scan findings can completely alter the therapeutic approach. In other diseases such as osteomyelitis, bone scanning makes earlier diagnosis possible than with alternative diagnostic modalities such as radiographs, thus permitting earlier, and more appropriate therapy. The majority of disorders show earlier involvement on a bone scan than can be seen on conventional radiographs, while in certain disorders, the stage of the pathological process and its activity can be delineated most accurately by the bone scan (2, 3).

Another of the strengths of bone scintigraphy is its ability to image the whole skeleton. However, depending on the clinical indication for the bone scan, a whole body scan or a limited view of part of the skeleton may be imaged. There are however no universal guidelines for this. In many institutions, a whole body scan is performed for the majority of indications. For example when scanning to detect complications of a knee prosthesis, much time may be spent imaging the entire skeleton with probably little additional information being obtained. The additional time spent may be better be used to image other patients, particularly in a situation where resources are limited. This will reduce the waiting time for patients, the workload of the nuclear medicine practitioners, and improve the utilization of the equipment and technical staff.

The time required for image acquisition depends not only on the extent of the particular region being studied, but also depends on the type of gamma camera, and to some extent on the height and build of the patient. With dual detector gamma cameras, a whole body scan in anterior and posterior projections takes approximately 20 to 35 minutes to complete, whereas about 10 minutes are required for regional imaging of the lower limbs for example. With single headed cameras scanning times can increase to over an hour if the whole body is to be imaged. Because of the longer time necessary to perform a whole body scan, it requires relatively more resources in terms of camera time, staff, and overheads, thus indirectly resulting in a greater cost and an increased demand on often limited facilities. Conversely, despite the longer time it takes to acquire a whole body bone scan, it has the advantage of depicting the entire skeleton and therefore lesions that are poorly localised clinically or other unexpected clinical conditions are less likely to be missed. Failure to detect such findings

may significantly negatively influence the subsequent management of the patient. Therefore a balance needs to be found between the optimal utilization of resources, and the effective diagnosis and localization of pathology.

Considering the shortage of Nuclear Medicine facilities coupled with high patient loads in most of Africa and elsewhere in the developing world, optimization of imaging acquisition times is critical. In Africa Nuclear Medicine equipment is particularly limited, manpower is inadequate, and infrastructure such as electricity is poor. Nigeria, with a population of over 120 million people, and only one Nuclear Medicine facility, is an example of a country where optimal use of limited Nuclear Medicine facilities is essential.

The aims of this study are to:


1. Determine the proportion of significant skeletal lesions that would not have been detected using limited imaging protocols, in patients referred for a variety of clinical indications.
2. To make recommendations for imaging protocols for each clinical indication to ensure optimal gamma camera time utilization in a situation where gamma camera facilities are limited.

## CHAPTER TWO

### LITERATURE REVIEW

#### **Mechanism of biphosphonate uptake by the skeleton**

Bone scintigraphy provides information that reflects skeletal metabolic activity. The precise mechanisms involved in biphosphonate uptake in the skeleton are not fully understood. It appears however that these agents adhere to the hydroxyapatite complex in bone by the process of chemisorption (1). The two important factors that affect this are thought to be osteoblastic activity and skeletal perfusion with preferential uptake at sites of active bone formation. Consequently, blood flow plays a role in tracer delivery and distribution, while reactive bone formation also significantly affects the appearance of the scan.



Thus, one can readily appreciate the fact that any condition that alters blood flow or affects reactive bone formation will either cause “hot” (increased tracer deposition) or “cold” (decreased tracer deposition) areas on the bone scan . Therefore bone scans often reflect a reaction to the disease processes, rather than the disease process itself. Because of its ability to detect physiological (functional) changes, the bone scan can often be strongly positive, well before the anatomical (structural) changes occur, especially radiographic changes (4, 5, 6).

It is important to note that aside from bone, soft tissue can also accumulate bone-seeking agents, in heterotopic new bone formation (myositis ossificans) the mechanism is similar to that of skeletal uptake. In other conditions, multiple factors are usually involved, the most common of which are, altered vascularity, expansion of interstitial fluid volume, the presence of dystrophic calcification of

metastatic microcalcification and, finally tissue ischaemia or infarction. Occasionally, a high tissue iron or immature collagen content may be important.

### **Radiopharmaceuticals**

Technetium-99m-polyphosphates were first successfully prepared and investigated by Subramanian and McAfee in 1971 (1). However, in the early 1970's, a different class of Tc-99m labeled agent, the diphosphonate, characterized by a P-C-P bond, was introduced for bone scanning (1). Currently, there are four bone scanning agents that are routinely available: pyrophosphate (PYP), diphosphonate (DIP), methylene diphosphonate (MDP), and hydroxymethylene diphosphonate (HMDP). At this time, Tc-99m methylene diphosphonate (MDP) is the most commonly used radiopharmaceutical for bone imaging (4).

Technetium-99m is a desirable label for radioactive compounds because of its availability from the Mo-99/Tc-99m generator system, its practical 6-hour half life, a 140 keV principal gamma photon (88% abundant), which provides good tissue penetration and imaging capabilities for use with gamma cameras, and the absence of beta decay, thus providing a low radiation dose. Technetium-99m labeled bone agents are prepared by the addition of sodium pertechnetate ( $\text{NaTcO}_4$ ) obtained from a Mo-99/Tc-99m generator to a vial containing the phosphonate compound and stannous ion, Sn(II), a reducing agent. Technetium-99m forms a chelate with the diphosphonate. However, successful labeling requires sufficient Sn(II) to reduce Tc(VII) to effect the chelation. Should oxygen be allowed into the vial, Sn(II) is hydrolyzed, with the formation of colloidal impurities that can result to reticuloendothelial uptake in vivo,

degrading images of the skeleton. Free pertechnetate may also be formed, leading to uptake in various organs especially the stomach, thyroid and salivary glands. A successful preparation is generally considered to be one in which more than 95% of the technetium is bound to the bone scanning agent (2).

After intravenous administration, Tc-99m MDP is rapidly distributed throughout the extracellular space and by 2 to 6 hours approximately 50% of the injected dose is in the skeleton. Excretion of the remainder is via the kidneys, primarily by glomerular filtration, and by 24 hours 50% to 60% of the injected dose is excreted in the urine of a patient with normal renal function. The critical organ for dosimetry is the bladder wall. Because the skeletal-to-background tissue ratio improves with time, imaging begins 2 to 3 hours after tracer administration. By then the blood level is normally 3% to 5% of the injected dose (2, 4).

### **Indications for bone scintigraphy**

Bone scintigraphy has been used to evaluate a wide spectrum of musculoskeletal disorders. The most widely used indications for bone scanning are as follows:

#### **1. Malignant disease**

The detection of skeletal metastases remains the most important indication for performing a bone scan (3). The common cancers that metastasize to the bone are those of prostate, breast and lung. Bone scintigraphy can also be helpful in monitoring the response to therapy of known bone metastases (4).



## 2. Evaluation of primary bone tumours

A wide variety of benign and malignant bone tumours can be investigated with bone scintigraphy;

- a. Primary tumours (e.g. Ewing's sarcoma, osteosarcoma): Staging, evaluation of response to therapy and follow-up of primary bone tumours.
- b. Secondary tumours (metastases): Staging and follow-up of neoplastic diseases and evaluating the distribution of osteoblastic activity prior to therapy. This is mostly for the detection of metastatic disease to the rest of the skeleton. Occasionally it may help to characterise known lesions if anatomical imaging is equivocal (4). Osteoid osteoma, osteoblastoma and chondroblastoma are the commonest benign bone tumours evaluated in this way.

## 3. Diagnosis of osteomyelitis

Bone scanning has been demonstrated to be useful in the evaluation of osteomyelitis and discitis (6, 7). The role of bone scanning in osteomyelitis includes early diagnosis, the detection of disease at remote skeletal sites (8), and differentiating osteomyelitis from soft tissue infection (9). The evaluation of blood flow was not included in our study.


## 4. Evaluation of skeletal pain, skeletal trauma, and sports injuries

Bone scintigraphy plays an important role in determining the cause of bone pain particularly in patients with known malignancy (10). SPECT imaging of the vertebra is helpful in differentiating metastases from degenerative disease as a cause of back pain in patients with malignancy (11, 12). However, information on SPECT findings was not included in the current study.

Bone scanning has been used to diagnose fractures not visible on conventional X-rays such as stress fractures, occult fractures e.g. of the scaphoid or femoral neck, and fracture complications such as delayed union, non-union, infection, and avascular necrosis (AVN) (13). Other sports injuries involving the skeleton including shin splints, rhabdomyolysis, osteitis pubis and others, can be detected by a bone scan (14). It can also play a valuable role in the detection of non-accidental injuries in children.

#### 5. Evaluation of painful joint prostheses

Bone scintigraphy plays an important role in detecting and differentiating between loosening and infection in patients with joint prostheses presenting with pain. The distinction between loosening and infection is critical in guiding management (15).



#### 6. Evaluation of bone infarction and osteonecrosis

Bone scintigraphies is important in the diagnosis and follow up of patients with avascular necrosis of the head of the femur, Legg-Calve-Perthes disease, steroid osteonecrosis, sickle cell anaemia, and to determine the viability of bone grafts (16).

#### 7. Evaluation of metabolic bone diseases

Metabolic bone diseases such as hyperparathyroidism (17), renal osteodystrophy (18), osteomalasia, and hypervitamosis D have a characteristic appearance that may be encountered incidentally during skeletal scintigraphy (19, 20)

## 8. Miscellaneous conditions

Bone scans may assist in the diagnosis of costochondritis (21) arthropathies and reflex sympathetic dystrophy (22), and child abuse (23).

### **Image acquisition**

#### **Instrumentation**

A single- or double-headed gamma camera equipped with a low-energy, high-resolution collimator is used for bone scan with Tc-99m. A 10% energy window: ( $\pm 5\%$ ), centred over the 140-keV photopeak of Tc-99m should be set (24).

#### **Acquisition parameters**

Both the European (24) and American guidelines (25) on bone scintigraphy state that routine images are usually obtained between 2 and 5 h after injection. Later (6–24 h) delayed images may permit better evaluation of the pelvis if this was obscured by bladder activity on the earlier images. Six- to 24-h delayed imaging may be particularly helpful in patients with renal insufficiency or peripheral circulatory disorders and those with urinary retention (24).

Whole-body bone scintigraphy can be done by obtaining multiple overlapping (spot) images or with continuous imaging (i.e. whole-body scan) obtained in both anterior and posterior projections (24). In adults, whole-body studies are currently preferred. In children, spot views are commonly used (25).

When spot views are used as the main method of image acquisition, the regions of the skeleton covered by each spot view must overlap, to avoid missing any area. The EANM guidelines on bone scintigraphy recommend that the initial spot view of the axial skeleton should be acquired for approximately 500,000 to

1 million counts depending on the field of view (FOV) of the gamma camera (24). The larger the FOV, the more counts are required to give similar count densities over equivalent regions of the skeleton. The presence of physiologically high count density organs such as the kidneys may impede visualisation of nearby structures such as the vertebrae (26, 27). All the further spot views are then acquired for the same time as the first view. Matrix sizes for spot images could be 128×128 or 256×256, while whole-body views are usually obtained in a matrix of 256×1.024 (24).

Computer acquisition, processing and display of images may be particularly helpful in paediatric populations because of the extreme range of normal uptake. Films of scintigrams photographed with different intensities may also be helpful if digital processing and review are not available.

When whole-body scanning is used, the count rate (usually the anterior chest or posterior thorax) should be determined before starting the definitive acquisition. The scanning speed should be adjusted so that routine anterior and posterior whole-body images obtained 2 to 5 h after injection each contain more than 1.5 million counts (22, 24, 25)

### **Interpretation of bone scans**

The interpretation of a bone scan requires familiarity with the normal and abnormal appearances. While abnormal bone scan appearances may be non-specific, noting the distribution and pattern of uptake, as well as additional clinical and radiological information usually enables the diagnosis to be made with a high degree of specificity. In certain circumstances, the bone scan will need to be interpreted alongside other imaging modalities, and rarely a biopsy

would have to be performed in order to arrive at a final diagnosis. Knowledge of the appearance of a normal bone scan and its normal variants and artefacts is essential to avoid interpretive errors, which could potentially lead to misdiagnosis (28, 29).

The appearance of a normal bone scan changes from infancy, childhood, adolescence, and mature adulthood. In the early neonatal period skeletal tracer uptake is not as avid as it is even a few months later (23). The striking feature of growing skeleton is the marked uptake of radiopharmaceutical in growth centres (epiphysial plates) (29), which are hotter than surrounding bone. The cranial sutures also show increased uptake compared to the rest of the skull. The most important feature of a normal bone scan is symmetry about the mid-line. The left and right halves of the skeleton should be virtually mirror images of each other. There should be fairly uniform uptake and distribution of radiopharmaceutical throughout the skeleton, except for regions of greater metabolic activity such as the joint margins and areas rich in trabecular bone e.g. the spinal vertebral bodies. Because diphosphonate is excreted by the urinary tract, tracer not taken up by the skeleton will be excreted in the urine. In normal patients the kidneys and bladder are therefore visualized. When interpreting bone scan images, adequate knowledge of disease pathophysiology, normal variants, artefacts and other specific properties of the patient's condition, along with subsequent correlation of scan abnormalities to the history, physical examination, previous studies, and other radiological modalities, is essential for determining the presence and significance of a scintigraphic lesion.

## Normal variants

The recognition of normal variants is essential to the effective interpretation of bone scans. In children, intense uptake is expected in the metaphyseal-epiphyseal areas of the long bones, this uptake diminishes with increasing age until epiphysial fusion is complete, the three 'hottest' centres in order are the distal femur, proximal tibia, and proximal humerus. The skull base and sutures show increased uptake in normal children (29) particularly between the sphenoid and the occipital bone. Additionally, due to non-ossification of the skull sutures, there may be a linear area of photopenia, the 'broken skull' appearance (30).

In normal adults, tracer uptake is generally much higher in the axial than appendicular skeleton. Due to variations in calvarial thickness, the skull shows uneven uptake especially along its margins, with increased uptake in the frontal skull bone due to hyperostosis frontalis interna seen predominately in older females (31). Other areas that show increased uptake of activity in the skull of normal adults are the anterior aspect of the mandible, and the external occipital protuberance, which may appear as hot spots on the lateral view of the skull. Normal structures that may appear relatively hotter than the rest of the skeleton are the costochondral junctions, inferior tips of scapulae, spinous processes, vertebrae, sternum, sternoclavicular joints, acromioclavicular joints, sacroiliac joints (29), ischio-pubic synchondrosis (32), and the sternomanubial joints at the angle of Louis (33).

### **Artefacts on bone scans**

Various artefacts can degrade the quality of bone scan images or may mimic certain pathological conditions, leading to false-positive results. Multiple factors contribute to the appearance of artefacts on bone scans, ranging from technical and instrumental factors, radiopharmaceutical preparation, patient related and iatrogenic factors.

#### Instrumental/camera factors:

Artefacts may appear as cold spots on the image which can result from poor condition of the detector crystal or a photomultiplier tube. Overwhelming scattered photon activity resulting in poor resolution of the skeleton may be due to instrument artefact such as a wrong energy window setting (25). Moving table artefacts appear as hot spots. The speed of the moving table of the camera becomes slower on the second run, causing increased count collection over the bone imaged during the second run, making the area over the camera field of view to appear hot (22, 25).

#### Patient factors:

Patient movement can result in artefacts that can masquerade as disease. Several objects or items from patient body or clothing can appear as cold spots in the final image e.g. wristwatches, necklaces, ear rings, belts, and items in the patient's pockets. Occasionally, food or water ingested by the patient shortly before scanning may appear as photopenic lesion on the left hypochondrium, the so called 'lunch syndrome' (34). Contamination with radioactive urine,

depending on the location, can cause a wide range of hot areas mimicking pathological processes.

#### Radiopharmaceutical factors:

The stomach, thyroid and salivary glands may appear on bone scans due to free pertechnetate from poor radiopharmaceutical labelling. Similarly the formation of colloid during radiopharmaceutical preparation can result in artefactual uptake in the liver and spleen that can mimic pathology.

#### Display factors:

X-ray film artefacts, computer conversion / processing bugs may occasionally produce artefacts on the images.

#### Iatrogenic artefacts:

Injection site activity or mis-injection can cause a hot spot at that site. Unintentional intra-arterial injection will cause intense tracer activity in the area of injection and distribution of the large portion of the injected radionuclide in the target as well as non-target tissues that receive blood supply from that artery (35). Other iatrogenic factors that may produce artefacts are prostheses, surgical implants, urine bags and catheters, surgical scars (36) previous radiation therapy, and drugs.





### **Incidental findings on bone scintigraphy**

Incidental scintigraphic findings on bone scans can be defined as lesions or findings that are clinically unexpected based on the information available prior to performing the scan. Most incidental findings on bone scintigraphy are caused by either concentration of bone seeking agents in non-skeletal (non-osseous) tissues, or photopenic lesions in the skeleton or non-skeletal organs such as the kidneys (37, 38). Several theories have been postulated on the possible mechanisms of localization of Tc-99m phosphates on tissues other than bones. Among the possible mechanisms is absorption onto soft tissue calcium. Following cell death there is influx of calcium into the intracellular space. This acts as a site for phosphate uptake. Binding of the phosphate by tissue hormones or enzyme receptors and tagging to denatured proteins can also occur (17). The presence of soft tissue iron deposits can also be seen on bone scans (18). Hyperaemia and increased capillary permeability with absorption on to immature collagen is another possibility. However, in certain disease conditions multiple mechanisms may be operating simultaneously, a typical example is in infarcted myocardium rhabdomyolysis (39).

Incidental findings on bone scans have been detected in a wide range of acquired, congenital, neoplastic and non-neoplastic musculoskeletal disorders, as well as resulting from invasive procedures. In clinical practice, incidental findings are most often related to the kidney and urinary tract. In a review of literature it has been shown that valuable new information on kidney morphology and function can be obtained in about 15% of patients having bone scintigraphy (40, 41). Of this, kidney asymmetry is the most common finding

and normally indicates non-function or chronic pyelonephritis. However, tracer accumulation in a dilated renal pelvis and ureter is common in bone scintigraphy. Interpretation remains notoriously difficult however because in adults urinary stasis secondary to congenital abnormalities of the pelvis or calyces, true pelvi-ureteric junction obstruction or ureteric obstruction secondary to prostatic, cervical or rectal carcinoma, can all give a similar appearance. Small focal areas of increased tracer accumulation in the kidney are usually due to stasis within the collecting system and may mimic a lesion on the 12<sup>th</sup> rib. Therefore, 24 hour delayed, or oblique views have been suggested to make this distinction (42).

Unexpected photopenic space occupying lesions in the kidney are also indicative of renal disease, usually representing a renal cyst or Wilm's tumour in the paediatric age group. Intense kidney uptake is commonly related to anti-cancer chemotherapy when it is thought to result from tubular damage. Congenital pelvic kidney, horse-shoe kidney, and unilateral absence of a kidney are the congenital kidney abnormalities commonly encountered incidentally on bone imaging. Absent or faint renal uptake is a quite unreliable sign of renal disease and is portrayed most dramatically in a 'super scan' of diffuse metastatic disease, particularly in carcinoma of the prostate, and other conditions, where the kidney images are often absent because of enhanced uptake of MDP by the abnormal bone.

Breast uptake is seen occasionally and can be ignored if it is bilateral and symmetrical; unilateral breast uptake necessitates further evaluation to exclude

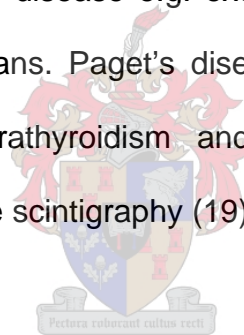
carcinoma. However, chronic cystic mastitis (43) and gynaecomastia (44) can show uptake of tracer, but these are usually symmetrical.

In the abdomen focal uptake in the liver is probably the most common finding and usually represents hepatic metastases from colon, lung, breast or prostate carcinoma. Hepatic infarcts (45) and amyloidosis (46) could also cause liver uptake. Splenic uptake in an individual invariably raises the possibility of unsuspected heterozygous sickle-cell disease (47). Splenic uptake has also been reported in thalassemia major (48) and patients with glucose-6-phosphate dehydrogenase deficiency (49). Gastric uptake may be due to free pertechnetate, calcifications, or milk alkaline syndrome (50). Diffuse lung uptake can occur in hypercalcaemic patients, particularly in hyperparathyroidism. Radiation therapy can also cause diffuse uptake in the lungs. Myocardial infarction, aneurysms, calcified valves, pericarditis, and endocarditis are a few among the causes of focal and or diffuse uptake in the heart or great vessels. Pericardial, pleural, ascitic fluid and fluid in the pouch of Douglas may all show varying degree of uptake on bone scans.

Uptake in the head has been reported in cerebrovascular accidents, brain abscess, arteriovenous malformations, cerebritis and subdural haematoma (51). In a review of the literature, several other unexpected or incidental findings have been reported; including Derby hat deformity (52), bilateral congenital dislocation of the hips (53), uretero-colic fistula (54), inguinal hernia (55), uptake in fibrous histiocytoma (56), and uptake in pedunculated uterine fibroids (57).

Non-skeletal uptake of bone scanning agents has been shown to provide valuable clinical information in patients undergoing bone scintigraphy (38). However, these findings are only diagnostic in certain specific circumstances and further investigation is usually required to arrive at a final diagnosis in the majority of cases. One must recognize the fact that abnormal soft tissue uptake can be problematic for the inexperienced observer, particularly since the distinction between normal and abnormal soft tissue uptake is often blurred. In general, the unexpected finding of soft tissue uptake in a recognizable pattern enhances the potential value of skeletal scintigraphy.

In the skeleton, incidental findings such as multiple rib and stress fractures have been diagnosed. Benign bone disease e.g. exostosis, osteitis pubis can be incidentally seen on bone scans. Paget's disease and other metabolic bone disease particularly hyperparathyroidism and brown tumours have been diagnosed incidentally on bone scintigraphy (19).



### **The use of whole body versus limited scanning of the skeleton**

In a review of literature, there have been few previous studies done to analyze the distribution of skeletal metastases in order to determine if whole body scintigraphy is necessary in all patients. In a study by Krishnamurthy et al. (58), titled *Distribution pattern of metastatic bone disease - A need for total body skeletal image*, the authors reviewed metastatic bone disease in 62 patients with breast, lung and prostate cancers. The results showed that 60% of the bone lesions were located in the axial and 40% in the appendicular skeleton. Of these, 4% of the lesions in the appendicular skeleton were found in bones of the

forearms, hand, leg and foot for all the tumour groups. The study did not include significant incidental findings. In another study (59) the authors analyzed the distribution pattern of skeletal metastases in 376 patients with different tumour types. The result showed that 50% of the lesions were detected in the thorax and vertebra, while the skull, pelvis and extremities accounted for 22%, 38% and 34% respectively, as an average for all tumour types. The authors did not include the percentage of lesions that would have been missed if regional imaging was employed. Incidental findings were also not included. In both studies whole body imaging was recommended. Wilson et al. (60) reviewed the distribution of skeletal metastases in 318 patients with breast and lung cancer. Eighty three percent of the lesions were detected in the thoracic region and 46% in the vertebra in both cancers. However, in the appendicular skeleton 7% of lesions were seen in breast cancer while 13% in pulmonary cancer. Percentages of missed lesions and incidental findings were not included in this study. In further consideration of the additional time spent in acquiring whole body bone scans, in a study (61) titled *Is skull view necessary in routine gamma camera bone scanning?*, the authors performed a retrospective review of 478 bone scans of patients with carcinoma of the breast, lungs, and prostate and other known carcinomas. When the scans were analyzed, 11 patients had abnormalities of the skull only. In four of these cases abnormalities were thought to be of dental origin. In one case, the referring clinician felt the abnormality was not significant and no further follow up was available. In two cases the results were equivocal. In only one patient out of the 478 was the view of the skull positively useful and this patient had a raised alkaline phosphate due to Paget's disease of the skull. It was therefore suggested that a

skull view was not necessary when scanning patients with breast, lung or prostate carcinomas, provided they have no clinical evidence of cranial pathology.

In sports related injuries, there were a limited number of studies available in the literature with respect to the imaging protocols. In a study entitled *Cost appropriateness of whole body vs limited bone imaging for focal sport injuries* (62), the author performed a retrospective review of 1271 bone scans. Of those only 17 (1%) were done to evaluate a local musculoskeletal injury as a result of participation in an organized or unorganized regular exercise program or sport. The results showed that eleven (65%) had abnormalities at anatomical sites not under evaluation. Six patients (35%) had evidence for occult fractures at the secondary sites not under evaluation. In two patients, the symptomatic site being evaluated was normal but an abnormality was located at another anatomic site. On the basis of these results, the author suggested that it appears to be cost-appropriate and medically justified to perform whole body bone imaging in amateur athletes being evaluated for focal musculoskeletal pain. It can however be argued that the number of patients in this study was small and that a larger study population is necessary to confirm these results.

In another study related to sports injury (63) the author performed a retrospective review of bone imaging of 40 players at the end of three successive playing seasons of the Australian rugby football team. All patients were males with an average age of 27 years. The clinical sites of trauma were imaged, as were the immediate adjacent bones and joints in order to assess associated trauma. Of the injuries detected, 67% of the total occurred at or

below the level of the knee. Fifty-five percent of these occurred in the tibia, fibulae and bones of the foot in a pattern reflecting the nature of the trauma. Clinically unsuspected pathology was found at a contralateral site in 54% of cases. The authors suggested that the structures above and below the sites of symptoms should be imaged. No studies could be found in the literature analyzing the distribution of lesions in patients with suspected osteomyelitis, prosthetic joint complications, or AVN.

From the above literature review, it is clear that existing publications addressing the question of using limited imaging of the skeleton for bone scintigraphy is deficient in terms of the number of studies, patient numbers, the indications, and a variable classification of bone lesions to particular anatomical regions and more importantly analysis of imaging acquisition time for different type and anatomical regions. While there are guidelines for bone scanning specifically addressing the imaging acquisitions that need to be taken into account when a department compiles its protocols (24, 25). For most indications there are no clear guidelines with respect to the imaging protocols. In our study, we will determine the pattern of distribution of skeletal lesions in larger groups of patients who had skeletal scintigraphy for a wide selection of clinical pathologies. Additionally we will incorporate significant incidental scintigraphic findings.

## **CHAPTER THREE**

### **MATERIALS AND METHODS**

#### **Study population**

A retrospective review was conducted of all the bone scan studies of patients who were referred for skeletal scintigraphy at this institution from January 2002 to December 2004. The patients were referred from primary, secondary, and tertiary centres from state and private sectors. If patients underwent more than one study during this period, only the first study was reviewed. However, the number of patients who were excluded was reported. Patient confidentiality was strictly maintained. As reports were retrospectively reviewed without revealing patient information, informed consent was not required.

#### **Interpretation of bone scintigraphy**

The bone scans were reported by Nuclear Medicine consultants, and registrars in training who had access to the clinical information and other investigations of the patient, as part of the routine work of the Nuclear Medicine department of our institution.

#### **Reviewing the studies**

We reviewed the clinical request forms and reports of all patients who had a bone scan during the three year period described above. Patients were then divided according to the bone scan pathology in the case of a known primary malignancy and by clinical indications in patients with suspected localized musculoskeletal disorders:



1. Patients with **malignancies** undergoing bone scanning to detect or monitor skeletal metastases. These were then further subdivided based on the primary malignancy as follows:

- 1.1 Breast carcinoma
- 1.2 Lung carcinoma
- 1.3 Prostate carcinoma
- 1.4 Renal carcinoma
- 1.5 Gastrointestinal carcinoma
- 1.6 Sarcoma
- 1.7 Myeloma
- 1.8 Lymphoma
- 1.9 Reproductive system carcinoma

Only primary malignancies with 30 or more studies were analysed for the purpose of this study. Study reports were analysed for the presence or absence of metastases. If the scan was interpreted as demonstrating metastatic disease, the anatomical location of the bone lesions was noted as being present or absent in the following 3 regions:

- a. Axial skeleton; this included the skeleton of the thorax, lumbar spine and pelvis.
- b. Limbs; this included the skeleton distal to the shoulder and hip joints.
- c. Skull and cervical spine

2. Patients undergoing bone scanning for suspected **infective bone disease**. Study reports were analysed for the presence or absence of sites of bony infection. If the scan was interpreted as demonstrating bony infection, the

anatomical location of the bone lesions was noted as being present or absent in the following 3 regions:

- a. Local skeleton; this included the ipsilateral or contralateral skeleton at the site considered to be within the field of view of a gamma camera positioned over the clinically suspected area of the disease.
- b. Regional skeleton, e.g. pelvis to toes for suspected lower limb disease.
- c. Remainder of the skeleton not included in b.

3. Patients undergoing bone scanning for the diagnosis of **lower limb stress fractures**.

4. Patients with **hip or knee prostheses** undergoing bone scanning for the diagnosis of infection and loosening.

5. Patients undergoing bone scanning for the assessment of **avascular necrosis of the head of femur**.

For indications 3 to 5, study reports were analysed for the presence or absence of sites of bony lesions. If the scan was interpreted as demonstrating bony lesions, the anatomical location of the bone lesions was noted as being present or absent in the following 3 regions:

- a. Local skeleton; this included the ipsilateral or contralateral skeleton at the site considered to be within the field of view of a gamma camera positioned over the clinically suspected area of the disease.
- b. Regional skeleton, i.e. pelvis to toes.
- c. Remainder of the skeleton not included in b.

**Clinically significant incidental findings:**


In all patients listed above we also determined the presence and site of significant incidental lesions. Significant incidental findings were defined as lesions or findings that were clinically unsuspected, and that their discovery was considered likely to result in a significant alteration of patient management. Therefore, normal variants or coexisting pathology such as degenerative changes were not considered to be significant incidental findings because their discovery was considered unlikely to affect patient management. Therefore the impact of these findings being missed due to the region in question not being imaged was likely to be small.

To assist in determining the true significance of the incidental lesions detected, and the possibility of false-positive results, available patient notes were reviewed in all the patients in whom incidental findings were detected. We then determined whether or not the referring physicians further investigated or treated the patients in response to the reported lesion.

**Survey of Scanning Protocols**

Finally, we designed a questionnaire (Appendix I) surveying a diverse variety of Nuclear Medicine practices about their imaging protocols for bone scanning for a variety of indications. This was to determine their practise with respect to performing a whole body scans, limited views, or regional views for similar

indications to those studied in this work. We also enquired about any reasons or explanations for the use of their protocols. The questionnaires were sent to private and academic nuclear medicine practices, inside and outside of South Africa. The results of this survey were then discussed in the light of the findings of this study and to determine if there is difference in imaging protocol between developing and developed countries.



## CHAPTER FOUR

### RESULTS

The bone scan reports of 3015 patients were included in the study. A total of 407 patients were excluded because they underwent more than one scan. Details of included indications, patient gender and ages are given in Table 1.

**Table 1: Numbers and demographic data of patients for each clinical indication**

Indication	Patients	Male	Female	Age range	Median age
<b>Bone metastases</b>					
Breast	1142	2 (0.1%)	1140 (99%)	26-82	54
Lung	338	224 (66%)	114 (34%)	36-79	57
Prostate	252	252 (100%)	0 (0%)	56-71	63
Renal	202	124 (62%)	78 (38%)	4-63	34
Gastrointestinal	113	88 (78%)	25 (22%)	14-57	36
Sarcomas	102	68 (67%)	34 (33%)	6-28	17
Myeloma	41	37 (90%)	3 (10%)	41-68	55
Lymphoma	33	18 (55%)	15 (45%)	21-53	37
Reproductive system	32	4 (12%)	28 (88%)	38-66	52
<b>Osteomyelitis</b>	264	148 (56%)	116 (44%)	5-15	14
<b>Stress fractures / shin splints</b>	362	231 (64%)	131 (36%)	30-44	37
<b>Joint prostheses</b>	112	72(65%)	40 (35%)	28-69	49
<b>Avascular necrosis</b>	22	6 (27%)	16(73%)	13-41	27
<b>Total</b>	<b>3015</b>	<b>1274 (42%)</b>	<b>1622 (58%)</b>	<b>4-82</b>	<b>42</b>

## **Patients undergoing bone scanning for the detection and monitoring of bone metastasis**

### **Breast cancer**

Of 1142 patients with breast carcinoma undergoing bone scanning, a total of 1050 patients had skeletal lesions interpreted as being bone metastases. The distribution of these lesions amongst these patients is given in Table 2.

Imaging of only the axial skeleton would have identified bony metastases in 1039 of the 1050 patients who had bone metastases (99%). In 4 patients significant incidental findings were found in the skull and limbs, outside of the area covered by axial imaging. In these patients abnormal thyroid uptake in 2 patients, and abnormal uptake in the maxillary sinus in 1 patient, and increased uptake in the lower limb attributed to Paget's disease were interpreted as requiring further evaluation or a possible modification of management. Combining these data a total of 14 out of 1142 (1%) of patients had significant findings that would not have been detected if axial imaging had been used instead of imaging the whole body.

Imaging of only the axial skeleton and skull would have resulted in the failure to detect of bony metastases in 2 out of 1142 patients (0.2%). In 1 patient a significant incidental finding was found in the limbs, outside of the area covered by axial and skull imaging. In this patient intense uptake in the lower limb interpreted as Paget's disease was found as a significant incidental finding requiring further evaluation or a possible modification of management. Combining these data a total of 3 out of 1142 (0.3%) of patients had significant

findings that would not have been detected if axial and skull imaging had been used instead of imaging the whole body.

### **Lung cancer**

Three hundred and thirty eight patients had lung cancer, of these 211 had metastasis. The distribution of these lesions amongst these patients is given in Table 2. Imaging of only the axial skeleton would have resulted in the detection of bony metastases being missed in 71 out of 338 patients (34%), and imaging of the axial skeleton and skull would have resulted in the detection of bony metastases being missed in 68 out of 338 patients (20%). In this group none of the patients had significant incidental findings.

### **Prostate cancer**

A total of 252 patients had prostate carcinoma. Of these 196 had lesions interpreted as skeletal metastases. The distribution of these lesions amongst these patients is given in Table 2. Imaging of the axial region and skull, or of the axial skeleton alone would have resulted in lesions being missed in 4 out of the 252 patients (2%). No significant incidental lesions were found.

### **Renal System cancers**

This group of 202 patients included patients with renal tumours in 186 and bladder cancer in 16. Of these 36 had lesions interpreted as bone metastases. The distribution of these lesions amongst these patients is given in Table 2. Imaging of only the axial skeleton would have resulted in the detection of bony metastases being missed in 8 out of 202 patients (4%). In one patient a

significant incidental finding was found outside of the area covered by axial imaging. In this patient abnormal uptake in the neck was interpreted as requiring further evaluation or a possible modification of management. Combining these data a total of 9 out of 202 (5%) of patients had significant findings that would not have been detected if axial imaging had been used instead of imaging the whole body.

Imaging of the axial skeleton and skull would have lead to the detection of bony metastases being missed in only 1 out of 202 patients (0.5%). No significant incidental findings were found in this group.

### **Gastrointestinal**

Of 113 patients with colo-rectal carcinoma in this category undergoing bone scanning, a total of 64 patients had skeletal lesions interpreted as being bone metastases. The distribution of these lesions amongst these patients is given in Table 2. Imaging of only the axial skeleton would have resulted in the failure to detect bony metastases in 11 out of 113 patients (10%). One patient had abnormal soft tissue uptake of the foot interpreted as a significant incidental finding, outside the area covered by axial imaging. Combining these data a total of 12 out of 113 (10%) of patients had significant findings that would not have been detected if axial imaging had been used instead of imaging the whole body.

Imaging of only the axial skeleton and skull would have resulted in the failure to detect of bony metastasis in 2 out of 113 patients (2%). Similarly, 1 patient had



abnormal soft tissue uptake of the foot interpreted as a significant incidental finding, outside of the area covered by the axial imaging. Combining these data a total of 3 out of 113 (3%) of patients had significant findings that would not have been detected if axial and skull imaging had been used instead of imaging the whole body.


### **Soft tissue Sarcomas**

Of 102 patients with sarcoma undergoing bone scanning, a total of 48 patients had skeletal lesions interpreted as being bone metastases. The distribution of these lesions amongst these patients is given in Table 2. Imaging of only the axial skeleton would have resulted in the failure to detect of bony metastases in 4 out of 102 patients (4%). In 2 patients significant incidental findings were found in the skull and limbs, outside of the area covered by axial imaging. In these patients abnormal thyroid uptake in 1 patient, and abnormal uptake in the skull in 1 patient, was interpreted as requiring further evaluation or a possible modification of management. Combining these data a total of 6 out of 102 (6%) of patients had significant findings that would not have been detected if axial imaging had been used instead of imaging the whole body.

Imaging of only the axial skeleton and skull would have resulted in the failure to detect of bony metastases in 3 out of 102 patients (3%). No significant incidental findings would have been missed.

## **Myeloma**

Of 41 patients with myeloma undergoing bone scanning, a total of 22 patients had skeletal lesions interpreted as being bone metastases. The distribution of these lesions amongst these patients is given in Table 2. Imaging of only the axial skeleton would have resulted in the failure to detect bony metastases in 12 out of 41 patients (29%). In 2 patients significant incidental findings were found in the skull and limbs, outside of the area covered by axial imaging. In these patients abnormal thyroid uptake in 1 patient, and abnormal uptake in the foot in 1 patient, was interpreted as requiring further evaluation or a possible modification of management. Combining these data a total of 14 out of 41 (34%) of patients had significant findings that would not have been detected if axial imaging had been used instead of imaging the whole body.



Imaging of only the axial skeleton and skull would have resulted in the failure to detect bony metastases in 5 out of 41 patients (12%). In one patient a significant incidental finding was found in the limbs, outside of the area covered by axial and skull imaging. In this patient abnormal uptake in the foot was interpreted as requiring further evaluation or a possible modification of management.

## **Lymphoma**

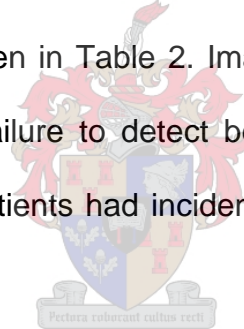
A total of 33 patients had lymphoma. Of these 28 had lesions interpreted as skeletal metastases. The distribution of these lesions amongst these patients is given in Table 2. Imaging of the axial region alone would have resulted in

lesions being missed in 1 out of the 33 patients (3%). No significant incidental lesions would have been missed.

Imaging of the axial skeleton and skull would have similarly resulted in missing 1 out of the 33 patients (3%). No significant incidental lesions would have been missed.

### **Reproductive System**

Of the 32 patients with reproductive system tumours, 19 had cervix carcinoma, 7 uterine carcinoma and 6 patients penile carcinoma. A total of 16 patients (50%) had lesions interpreted as metastases. The distribution of these lesions amongst these patients is given in Table 2. Imaging of only the axial skeleton would have resulted in the failure to detect bony metastases in 1 out of 32 patients (3%). None of the patients had incidental findings outside of the axial region.



Imaging of the axial skeleton and skull would have similarly resulted in missing 1 out of the 32 patients (3%), with no significant incidental lesions being missed.

**Table 2: Distributions of skeletal metastases on bone scan in patients with non-osseous primary malignancies**

Primary Malignancy	Total Number of patients	Number of patients with Metastases	Number of patients with metastatic skeletal lesions only detected in the indicated regions						
			Skull	Axial	Limbs	Axial & skull	Axial & limbs	Skull & limbs	Skull & axial & limbs
Breast	1142	1050	9 (1%)	864 (82%)	2 (0%)	156 (15%)	6 (1%)	0	13 (1%)
Lung	338	211	3 (1%)	124 (59%)	68 (32%)	1 (1%)	11 (5%)	0	4 (2%)
Prostate	252	196	0	179 (91%)	4 (2%)	0	9 (5%)	0	4 (2%)
Renal	202	36	7 (19%)	11 (31%)	1 (3%)	11 (31%)	0	5 (14%)	1 (3%)
Gastrointestinal	113	64	9 (14%)	21 (33%)	2 (3%)	27 (42%)	4 (6%)	0	1 (2%)
Sarcoma	102	48	1 (2%)	17 (36%)	3 (6%)	0	19 (40%)	5 (10%)	3 (6%)
Myeloma	41	22	7 (32%)	1 (4%)	5 (24%)	1 (4%)	0	7 (32%)	1 (4%)
Lymphoma	33	28	0	5 (18%)	1 (4%)	4 (14%)	18 (64%)	0	0
Reproductive system	32	16	0	6 (38%)	1 (6%)	0	9 (56%)	0	0
<b>Total</b>	<b>2255 (100%)</b>	<b>1671 (74%)</b>	<b>36 (2%)</b>	<b>1228 (73%)</b>	<b>87 (5%)</b>	<b>200 (12%)</b>	<b>76 (5%)</b>	<b>17 (1%)</b>	<b>27 (2%)</b>

### **Patients with suspected osteomyelitis**

A total of 264 patients were included in this group which was comprised of all patients undergoing bone scanning for the diagnosis and localization of suspected osteomyelitis. Lesions interpreted as being due to osteomyelitis were found in 119 patients (62%). A breakdown of the suspected local and corresponding regional areas of the skeleton is given in Table 3.

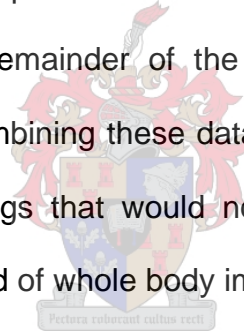
**Table 3: Skeletal regions of suspected osteomyelitis, based on clinical information**

<b>Region</b>	<b>Local</b>	<b>Number</b>
Upper Limbs	Upper arms	21
	Forearms	14
	Wrists and hands	0
Lower limbs	Femora	23
	Tibiae	138
	Ankles and Feet	7
Skull		0
Axillary Skeleton	Thorax	35
	Lumbar	17
	Pelvis	9
<b>Total</b>		<b>264</b>

Imaging of only the regional skeleton would have resulted in failure to detect osteomyelitis in 2 out of 264 patients (0.8%). In 5 patients significant incidental findings were noted in the remainder of the skeleton, outside of the area covered by regional imaging. These were 2 patients with unilateral asymmetric


breast uptake, 2 patients who showed abnormal uptake in the kidneys and 1 patient with intense uptake in the calvarium of the skull interpreted as requiring further evaluation or a possible modification of management. Combining these data a total of 7 out of 264 (3%) of patients had significant findings that would not have been detected if regional imaging had been used instead of imaging the whole body.

Imaging of only the local skeleton would have resulted in failure to detect osteomyelitis in 20 out of 264 patients (8%). In 2 patients significant incidental findings were noted on whole body imaging, outside of the area covered by local imaging. In the same 5 patients described above, significant incidental findings were noted in the remainder of the skeleton, outside of the area covered by local imaging. Combining these data a total of 27 out of 264 (10%) patients had significant findings that would not have been detected if local imaging had been used instead of whole body imaging.



## **Patients with suspected stress fractures and/or shin splints of the lower legs**

A total of 362 patients underwent whole body bone scans for suspected lower limb stress fractures or shin splints. Lesions interpreted as being due to stress fractures or shin splints were found in 261 patients (72%). Imaging of only the regional skeleton would have resulted in the detection of stress fractures or shin splints being missed in only 2 out of 362 patients (0.5%). In only 1 patient was a significant incidental finding noted in the remainder of the skeleton, outside of the area covered by regional imaging. In this patient intense asymmetric breast uptake was interpreted as requiring further evaluation or a possible modification of management. Combining these data a total of 3 out of 362 patients (1%) had significant findings that would not have been detected if regional imaging had been used instead of imaging the whole body.

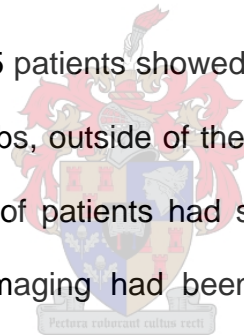


Imaging of only the local skeleton would have resulted in failure to detect stress fracture or shin splints in 37 out of 362 patients (10%). In 1 patient significant incidental findings were noted on whole body imaging, outside of the area covered by local imaging. In this patient abnormal uptake in the spleen was interpreted as requiring further evaluation. Combining these data a total of 39 out of 362 (11%) patients had significant findings that would not have been detected if local imaging had been used instead of whole body imaging.

### **Suspected Prosthetic Joint Complications**

A total of 112 patients had whole body bone scintigraphy for prosthetic joint complications. Studies interpreted as being positive for loosening and/or infection were found in 101 patients. All of this information was available using local imaging alone. Of these patients 1 patient showed an abnormal photopaenic lesion on the upper pole of the right kidney interpreted as a significant incidental finding, outside of the area covered by regional imaging. Therefore 1 out of 102 (1%) patients had a significant finding that would have been missed if regional imaging had been used instead of imaging the whole body.

Of the 112 patients however, 5 patients showed significant incidental findings in the remainder of the lower limbs, outside of the area covered by local imaging. Therefore 6 out of 112 (5%) of patients had significant findings which would have been missed if local imaging had been used instead of whole body imaging.

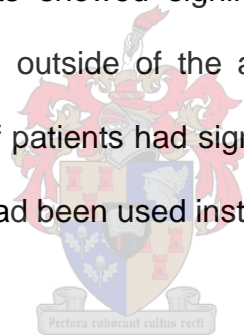




### **Patients with suspected avascular necrosis of femur head**


A total of 22 patients had whole body bone scintigraphy for suspected avascular necrosis of the head of the femur. Lesions interpreted as being positive for avascular necrosis of the femur were found in 14 patients (45%). All of this information was available using local imaging alone. Of the 22 patients 1 showed asymmetric left kidney uptake interpreted as a significant incidental finding outside of the area covered by regional imaging. Therefore 1 out of 22 (5%) patients had a significant finding that would have been missed if regional imaging had been used instead of imaging the whole body.

Of the 22 patients, 3 patients showed significant incidental findings in the remainder of the lower limbs, outside of the area covered by local imaging. Therefore 4 out of 22 (18%) of patients had significant findings that would have been missed if local imaging had been used instead of whole body imaging.



### **Incidental lesions**

Clinically unsuspected findings considered to possibly be significant to possibly require a change in patient management were found in 13 patients of the total number of patients in the study population (0.4%). We were able to review the records of 9 patients (70%). It was in only 3 patients that the lesions were clinically significant. In two patients Paget's disease was diagnosed and in 1 patient abnormal uptake in the left kidney was eventually diagnosed as renal cell carcinoma. There were 16 patients in whom lesions were interpreted as being caused by artefacts.



## Questionnaire

Of the 28 questionnaires sent out, we received 13 (46%) completed responses from institutions in South Africa, Namibia, Sudan, the United Kingdom, Belgium, and Saudi Arabia. Of the 13 responses received, 11 (85%) indicated that clinical indication is a consideration to not do whole body imaging. With respect to age, 12 out of 13 (93%) indicated that age is a consideration to not do whole body imaging.

In patients with suspected localized trauma, 4 out of the 13 (30%) centres perform whole body imaging, while 8 (62%) perform regional imaging, and only 1 centre (8%) performs local imaging.

For suspected complicated joint prostheses, 3 centres (23%) perform whole body and 10 (77%) perform regional imaging. None of the centres do local imaging for suspected joint complications.

In patients with suspected stress fractures and/or shin splints, of the 13 responders, 12 (92%) performed whole body imaging, while 1 (8%) performed regional imaging, and none perform local imaging.

In suspected avascular necrosis of bone, 12 (92%) responders perform whole body imaging, and 1 centre (8%) performs regional imaging. No centre does local imaging.

## CHAPTER FIVE

### DISCUSSION

Bone scintigraphy plays an important role in the diagnosis and evaluation of a wide variety of musculoskeletal disorders. It is the most frequently performed radionuclide examination, accounting for 40%-60% of the work in most nuclear medicine departments (2, 4).

Depending on the clinical indication for the bone scan, a whole body scan or a limited view of part of the skeleton may be imaged. There are however no universal guidelines for this. In many institutions, a whole body scan is performed for the majority of indications. For example when scanning to detect complications of a knee prosthesis, much time may be spent imaging the entire skeleton with probably little additional information being obtained. The additional time spent performing whole body imaging may be better used to image increased numbers of patients, particularly in a situation where resources are limited. This will reduce the waiting time for patients, the workload of the nuclear medicine practitioners, and improve the utilization of the equipment and technical staff. This is particularly relevant in much of Africa and elsewhere in the developing world. Even in developed countries budgetary constraints make optimal utilization of gamma camera time important.

While some literature exists, there is still no consensus on the use of limited imaging of the skeleton for different clinical indications. Several reports addressed the distribution of skeletal lesions for different clinical indications

using either the presence or absence of regional involvement (58, 59, 60, 63, 64), or the percentage of total lesions in these regions (65, 66). These studies are however limited to only some clinical indications, with particularly few studies in patients with localised musculoskeletal disorders. In most studies the patient numbers are also relatively limited (58, 61, 62), an important consideration when a small proportion of patients can have a significant impact on the choice of optimal protocol. Furthermore methodological differences make comparison of these studies difficult. This study was an attempt to overcome such limitations when using limited imaging protocols.

From most of the scans reports reviewed, the referring clinicians did not supply information on the indications for the bone scan. However, in general the patients are referred to study the presence of a known disease process (i.e. metastases or no metastases), or for a follow-up study to assess disease progression. In the latter case, a limited imaging protocol may not be adequate to evaluate progression, particularly in those pathologies that tend to spread beyond the axial skeleton.

As part of this study a small survey was performed of a diverse variety of Nuclear Medicine practices about their imaging protocols for bone scanning for a variety of indications. While not being intended to be exhaustive or representative, this was done to get some indication of the general practice with respect to performing a whole body scans, limited views, or regional views with bone scintigraphy for similar indications to those studied in this work. We also enquired about any reasons or explanations for the use of their protocols. It was

clear from the responses that while study indication and patient age are considerations in deciding on the use of localised imaging, there is no consensus on the indications or type of localised imaging in bone scintigraphy. Interestingly there were no obvious differences between developed and developing countries.

Because optimal utilization of imaging time is critical, particularly in centres with limited nuclear medicine facilities and a high patient workload, it is necessary to weigh an “acceptable” percentage of errors for missing significant lesions, against the decrease in study time, and consequent increase in patient throughput, for different clinical indications and imaging protocols. In most situations it is probably not useful to set fixed thresholds, but rather to utilize the results of this study in the light of the gamma camera availability and the frequency of the indication in a particular centre. Therefore in a centre with relatively adequate gamma camera facilities relatively strict thresholds should apply. Conversely in a centre where the patient workload completely outstrips the available gamma camera equipment, where the use of a limited imaging protocol may result in a far greater number of patients undergoing a bone scan within an acceptable waiting time, it can be argued that a higher percentage of errors may be acceptable. Another consideration is the type of camera equipment available. In a department with a single round headed camera, there is probably a greater benefit in performing limited imaging. The acceptable threshold for percentage error should also depend on the clinical indication in question. However, in patients being scanned for metastases a minimum should include anterior and posterior views of the axial skeleton and proximal limbs.

Distal limbs should be included if clinically indicated. If anterior and posterior views are equivocal, additional spot views may be helpful e.g. an oblique view of the ribs or vertex views of the skull. From our results it will be suggested that if one is solely concerned with determining if the patient does or does not have metastases, one approach would be to start by imaging the axial skeleton, if this reveals metastases one can stop. If not the skull should be imaged. If that shows metastases one can stop. If not the limbs should be scanned. However, because of the higher percentage of limb involvement in patients with lung cancer and myeloma, whole body imaging may be done from the outset in these cases.

In patients with cancer undergoing a bone scan for metastases, the non-detection of metastatic disease could have a profound impact on management and it may also increase the mortality and morbidity as well as increase the cost of managing complications (67) after consultations with a group of oncologists in our institution it was concluded that the implications of missing additional lesions in the skeleton in a patient already known to have bone metastases are probably limited since the skeleton is not the only site for metastatic deposits. It is however important to identify metastases when their non-detection can result in complications, for example a pathological fracture. However, most of these patients would have symptoms at that site. This highlights the need for a nuclear medicine practitioner to get additional clinical information from patients prior to imaging.

It is important ethically to be able to balance the small risk of missing pathology

using a limited imaging protocol against the increased patient throughput that should be achieved compared to whole body imaging. The issue has not been discussed in detail previously, and in centres with adequate imaging capacity it is likely that many limited imaging protocols may never be justifiable. Since whole body imaging does not result in an increased radiation exposure for the patient, the whole skeleton can be imaged without this being a consideration. However in a scenario where patient numbers far outstrip imaging capacity, it could be argued that if only a small gain is obtained from doing whole body imaging, that that imaging time would be more ethically used scanning additional patients who would otherwise not undergo bone scanning at all. While a scenario such as this may be unlikely in the developed world, it is likely to exist in many parts of the developing world. Furthermore in a patient with a suspected well localized benign musculoskeletal disorder, such as avascular necrosis of a femoral head, a higher threshold would probably be acceptable for the missed detection of incidental findings. However, the decision to utilise a limited imaging protocol has to be considered by each institution, taking its own patient population, resources and treatment regimens into account.

In a study where an aetiology cannot always be ascribed to all scan abnormalities, or patient's clinical condition, there is the potential to misclassify lesions. With several scan patterns it is particularly difficult for the interpreter to distinguish benign from malignant disease. These patterns include solitary lesions. Lesions interpreted as solitary metastases occurred in 4% of patients in this study. Of all patients with malignancies, the axial skeleton was the most frequently involved area for metastatic disease occurring in 73% of patients.



Our study showed 74% of patients with known primary malignancies referred for bone scanning had metastases, with an even higher proportion in patients with breast and prostate cancer. This may be a reflection of the health situation in our environment where patients often present to hospital late. It may also be related to delay in diagnosis, either due to delays to see specialists or with the booking of diagnostic procedures such as biopsies. The proportion of patients with metastases may be entirely different in other countries or different institutions in the same country.

It should be noted that our study could not determine the sensitivity and specificity of limited bone scanning, but was able to compare the value of limited views with results obtained using whole body scanning. In this case our “gold standard” can be regarded as the whole body view. Using this approach, there would not be situation where a lesion detected on limited imaging is not seen on the whole body scan and thus no false positive scans would occur using limited views. Consequently the positive predictive value of limited views would be identical to that of whole body imaging.

More importantly, a number of patients will be expected to have lesions interpreted as metastases on a whole body study with no lesions being present on the limited study. These false negative studies would in turn decrease the negative predictive value of the limited study relative to the whole body study. If the population has a high proportion of patients with metastases, this will lead to a relative increase in false negative studies compared to true negative studies, which in turn will lead to a relatively low negative predictive value. This is the

case with the breast carcinoma group in our study where 92% of patients had metastases based on whole body imaging. In this case performing only axial imaging resulted in 11 false negative studies and 92 true negatives, giving a negative predictive value of only 89%, a figure that is probably too low for this clinical context. It can however be argued that this figure is likely to be much better in a population without such a high prevalence of bone metastases. An example from our study is in patients with gastrointestinal cancers with 57% prevalence of metastases with a negative predictive value of 94% and soft tissue sarcoma having 47% metastases with negative predictive value of 95%

### **Breast cancer**

A total of 1050 patients had skeletal lesions interpreted as being bone metastases. Of the 1050 patients with bone metastases, skull metastases were found in 178 (17%) and limb lesions in 21 (2%). Lesions were found in only the skull in 1% of patients, and only in the limbs in 0.2% of patients. The metastatic distribution from breast cancer in this study indicates approximately 90% of patients had metastases to the axial skeleton alone. Previous studies (58, 66, 68), showed a similar proportion of skull lesions, but the percentage of lesions in the limbs was higher. A direct comparison of these studies is however impossible as these studies analyzed the data differently, looking at the proportion of lesions rather than patients. A more useful comparison is with that of Nunan et al. (61), which noted abnormalities only in the skull in 13 out of 425 patients (3%) with breast cancer. This is probably comparable to the 1% found in this study especially as these included non-malignant lesions.

Based on the findings of this study, imaging of the axial skeleton and skull rather than whole body would lead to a percentage error of only 0.3%. In patients with breast cancer imaging of only the axial skeleton would lead to a percentage error of 1%. Therefore it is acceptable to perform axial imaging alone, although it can be argued that excellent results can be achieved by the addition of skull imaging, while still achieving a significant decrease in study times.

### **Lung cancer**

A total of 211 patients had skeletal lesions interpreted as being bone metastases. Of the 211 patients with bone metastases, skull metastases were found in 8 (4%) and limb lesions in 83 (39%). Lesions were found in only the skull in 1% of patients, and only in the limbs in 20% of patients. Most previous studies (58, 67), showed a similar proportion of limb lesions, but the percentage of lesions in the skull was higher. One previous study (58) however showed concordance with the proportion of skull lesions, while the proportion of limb lesions was significantly lower. Again a direct comparison of these studies is however impossible as these studies analyzed the data differently, looking at the proportion of lesions rather than patients. The more comparable study of Nunan et al. (61), noted abnormalities only in the skull in 2 out of 260 patients (1%) with lung cancer. This is comparable to the 1% found in this study.

In lung cancer, 20% of the metastatic lesions were located in the limbs alone. Imaging the axial region only, and axial and skull regions only would lead to an unacceptable percentage error of 34% and 20% respectively. Whole body imaging is therefore obligatory for this group of patients.

### **Prostate cancer**

Lesions interpreted as metastases were found in 196 patients. Of the 196 patients with bone metastases, skull metastases were found in 4 (2%) and limb lesions in 17 (9%). None of the patients in the category had lesions in the skull only, 2% of patients had lesions only in the limbs. The skeletal distribution from prostate carcinoma was again higher in the axial skeleton with pelvic involvement highest of all the other reported primary malignancies. Previous studies (58, 67), showed a higher proportion of skull and limb lesions. A direct comparison of these studies is again impossible because of differences in methodology, but the higher proportion of skull and limb lesions may have been due to patients in these studies having more advanced disease. The study of Nunan et al. (61), noted abnormalities only in the skull in 2 out of 214 patients (1%) with breast cancer, which is probably comparable to this study which did not find skull only lesion.

Because there were no patients with lesions found only in the skull in patients with prostate cancer, there is no difference between imaging the axial skeleton alone, or imaging the axial skeleton and skull alone. Imaging of only the axial skeleton would result to an acceptable percentage error of 2%. Therefore under conditions of limited gamma camera capacity it is acceptable to perform axial imaging alone in patients with prostate carcinoma.

### **Renal cancers**

Lesions interpreted as metastases were found in 36 patients. Of the 36 patients with bone metastases, skull metastases were found in 24 (67%) and limb lesions in 7 (19%). Because kidney ureter, bladder and urethral cancers were

grouped as renal cancer in our study, comparison with previous studies is difficult. A previous study by Tofe et al. (67), showed a lower proportion of skull lesions, and a higher proportion of limb lesions. A direct comparison of these studies is again impossible because of differences in methodology and smaller sample size in previous study, and this may explain the differences in the proportions of skull and limb lesions.

Of all patients lesions were found in only the skull in 7 (4%) of patients, and only in the limbs in 1 patient (3%). Based on the findings of this study, imaging of the axial skeleton and skull would result to a percentage error of only 1%. Therefore under conditions of limited gamma camera capacity it is acceptable to perform axial and skull imaging in patients with cancer of the renal system.

### **Gastrointestinal cancers**

There were 113 patients with colo-rectal carcinoma. The distribution of skeletal metastasis showed lesions in the axial skeleton was in 33%, skull in 14%, and in the limbs in 3%. There was involvement of all three anatomical regions in 1 patient (2%). Lesions were found in only the skull in 8% of patients, and only in the limbs in 2% of patients. A previous study (58), showed a similar proportion of skull lesions, but the percentage of lesions in the limbs was lower. A direct comparison of these studies is however impossible as these studies analyzed the data differently, looking at the proportion of lesions rather than patients.

Of all patients, lesions were found only in the skull in 14%, and only in the limbs in 3 patients (3%) including the 1 patient where a significant incidental finding

was noted. Based on the findings of this study, imaging of the axial skeleton and skull would result to a percentage error of only 3%. Because of the high proportion of skull lesions, imaging of only the axial skeleton would result to a percentage of errors to 10%. Therefore under conditions of limited gamma camera capacity it is acceptable to perform axial and skull imaging in patients with cancer of the gastrointestinal tract.

### **Soft tissue sarcoma**

Of the 48 patients with bone metastases, skull metastases were found in 9 (19%) and limb lesions in 30 (62%). Lesions were found in only the skull in 1 patient (2%), and only in the limbs in 6% of patients. Previous studies (67), showed a lower proportion of skull and limb lesions. A direct comparison of these studies is again impossible as these studies analyzed the data differently, looking at the proportion of lesions rather than patients.

Based on the findings of this study, imaging of the axial skeleton and skull would lead to an acceptable percentage error of 6%.

### **Myeloma**

In patients with myeloma 32% of the lesions were found in the skull, 24% in the limbs and only 4% in the axial region. In the review of literature no available study was found that showed the distribution of skeletal metastasis in patients with myeloma.

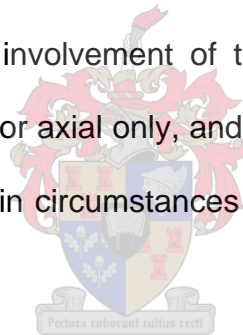
There is a significant percentage error of 32% when the axial region only is imaged and 24% when the axial skeleton and skull are imaged. Whole body

imaging is therefore obligatory for patients with myeloma

### **Lymphoma**

Of the 28 patients with bone metastases, skull metastases were found in 4 (14%) and limb lesions in 19 (67%). Axial and limb lesions accounted for 64%. Previous studies (67), showed a higher proportion of skull metastases. A direct comparison of these studies is again impossible for the reasons mentioned previously, but the higher proportion of skull may have been due to patients in these studies having more advanced disease.

Despite the high percentage involvement of the axial and limb regions, the percentage error was just 3% for axial only, and axial and skull imaging, making axial only imaging acceptable in circumstances of limited imaging capacity and high patient volumes.



### **Reproductive system**


There were 16 patients interpreted as having metastases in this group. Axial lesions were found in 38% of patients and axial plus limb lesions in 56%. None of the patients had a skull lesion. Because uterine, cervical and penile cancers were grouped as reproductive system cancer in our study, comparison with previous studies is difficult. However, a previous study by Tofe et al. (67), showed a lower proportion of skull lesions, and a higher proportion of limb lesions in patients with cancer of the cervix alone. A direct comparison of these studies is again impossible for the reasons given above, and this may explain

the differences in the proportions of skull and limb lesions.

The percentage error was just 3% for axial only, and axial and skull imaging, making axial only imaging acceptable in circumstances of limited imaging capacity and high patient volumes.

### **Patients with suspected osteomyelitis**

Significant lesions would have been missed in 3% of patients if regional imaging was used instead of whole body imaging. It is however interesting to note that imaging of only the regional skeleton would have resulted in failure to detect osteomyelitis in only 2 out of 264 patients (1%). Significant lesions would have been missed in 10% of patients with local imaging. It can therefore be argued based purely on these results that it is reasonable to perform regional imaging.



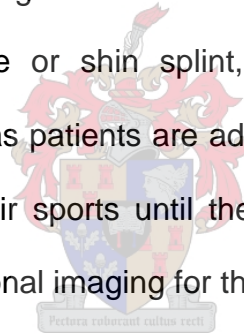
In available literature the author is unaware of any studies that have been done to analyze the distribution pattern of lesions in patients with suspected osteomyelitis. It has however been recommended that whole body imaging should be done because of the possibility of wide spread disease due to disseminated infection (69, 70). Furthermore, in this study in patients with suspected osteomyelitis in the majority of cases the site of suspected pathology was clinically difficult to localize, making local or regional imaging based on clinical suspicion difficult. Therefore given that these patients are generally children, thus requiring less imaging time, and the potentially serious implications of missing an area of osteomyelitis that may need urgent



decompression, it is recommended that whole body studies still be performed for this indication.

### **Suspected lower limb stress fractures and/or shin splints**

Imaging of only the regional skeleton would have resulted the detection of significant lesions being missed in only 1% of patients. Imaging of only the local skeleton however would have resulted in the detection of significant lesions being missed in 11% of patients. Our values are comparable to those of the previous study in the literature (62, 63). Furthermore it may seem unnecessary to diagnose shin splints or stress fractures outside of the region of suspected pathology if the symptomatic region that is covered by the camera field of view is positive for stress fracture or shin splint, since it will not change the management of the patients, as patients are advised to avoid excessive weight bearing or participation in their sports until the pain subsided. Therefore this study supports the use of regional imaging for these patients.



### **Prosthetic joint complications**

In the review of available literature no study was found that analyzed the use of limited imaging in prosthetic joint complications. In all of these patients the clinical question could be addressed by local imaging alone, as the location of the suspected pathology was known, and the value of imaging wider areas is only for the detection of significant incidental findings. In this group only 1% of patients had significant incidental findings that would have been missed if regional imaging had been used instead of imaging the whole body. However this figure increases to 5% if local imaging had been used instead of whole

body imaging. Regional imaging is therefore recommended.

### **Patients with avascular necrosis of femur head**

To our knowledge no study in available literature has been undertaken that analyzed the use of limited imaging in patients with avascular necrosis of the femur. In all of these patients the clinical question could be addressed by local imaging alone, as the location of the suspected pathology was known, and the value of imaging wider areas is only for the detection of significant incidental findings. In this group only 5% of patients had significant incidental findings that would have been missed if regional imaging had been used instead of imaging the whole body. However this figure increases to 18% if local imaging had been used instead of whole body. Regional imaging is therefore recommended.

### **STUDY LIMITATIONS**

The results of this study need to be considered in the light of a number of limitations. Firstly, this was a retrospective study in which bone scan reports over a two year period were reviewed. In reviewing the scintigraphic findings we were looking at bone scan reports and not rereading the scan images. Furthermore, because categorizing our patients based on clinical indication from patients' symptoms was not possible as the referring clinician often did not give detailed complaints of the patients, we therefore categorized the patients based on their primary pathology.

Secondly, anatomical boundaries were chosen to separate skeletal regions, e.g. the axial skeleton was separated from the limbs at the shoulder and hip joints

when analyzing the reports of whole body scan. This is not entirely comparable to performing limited views as in this situation the proximal limbs are likely to still be visible for interpretation. It can at least be argued that the error in this case would tend towards under estimating the value of limited views.

There is no consistent gold standard to determine the significance of incidental findings as adequate clinical follow up or additional tests were not available in many cases. Lesions therefore had to be considered significant if this was the interpretation of the bone scan report. Many of these lesions are likely to have not been clinically significant, and again the value of limited imaging is likely to have been underestimated as a result.

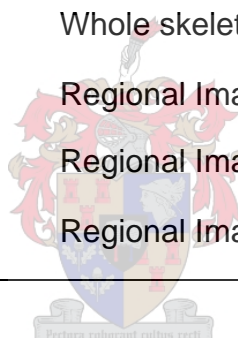
Lastly, we were reviewing only planar bone scan reports. Therefore, the information on additional views, dynamic studies and SPECT is not included in our study. This information is important as they contribute to patient's care as well as increasing the duration of image acquisition consequently increasing imaging time for each patient depending on the clinical indication.

## CONCLUSIONS AND RECOMMENDATIONS

Considering the time taken to perform a whole body bone scan and the shortage of Nuclear Medicine facilities coupled with a high patient load, especially in much of Africa, optimal utilization of available imaging acquisition time is critical under these circumstances. The data in this study indicated patterns of skeletal involvement which depended on the nature of the pathology. Further studies of additional patients based on specific clinical indications e.g. low back pain might provide a better indication of optimal imaging protocols based on these indications. The importance of considering the regional presence or absence of lesions, as well their number, in drawing conclusions about their distribution pattern within the skeleton is illustrated by the fact that while 74% of the patients with known primary malignancies had lesions interpreted as skeletal metastases, 73% of patient's had lesions which were identified by imaging the axial skeleton alone. Whereas in patients with suspected localized musculoskeletal disorder, 90% of the lesions were detected by imaging the region of the suspected pathology. Our study provides evidence that for many pathologies bone scan imaging protocols can be optimized in such a way that study times can be shortened while having a minimal effect on the accuracy of studies. While these recommendations have been drawn up in a department with a high patient workload and a limited gamma camera capacity in mind, much of the information obtained from this study can also be used to optimize bone scintigraphy protocols in nuclear medicine centres facing differing pressures.

**Table 4: Recommended bone scanning protocols by indication**

<b>Indication</b>	<b>Recommended protocol</b>
Breast Cancer	Axial skeleton
Lung Cancer	Whole skeleton
Prostate Cancer	Axial skeleton
Renal Cancer	Axial skeleton and skull
Gastrointestinal cancer	Axial skeleton and skull
Soft tissue sarcoma	Whole skeleton
Myeloma	Whole skeleton
Lymphoma	Axial skeleton
Reproductive system cancer	Axial skeleton
Osteomyelitis	Whole skeleton
Stress fractures/ shin splints	Regional Imaging
Joints prosthesis	Regional Imaging
Avascular necrosis	Regional Imaging



**APPENDIX I****QUESTIONNAIRE ON BONE SCANNING WITH Tc99m MDP**

Please tick the appropriate

1. Do you do a whole body bone scan in all patients irrespective of the clinical indication?

- a. YES
- b. NO

2. Do you do a whole body bone scan in all patients irrespective of their ages?

- a. YES
- b. NO

3. In evaluating prosthesis, which of the protocol do you do?

- a. Whole body view
- b. Limited view
- c. Regional view

4. What protocol do you do in sport related injuries?

- a. Whole body view
- b. Limited view
- c. Regional view



5. Do you do a whole body view in patients with localized trauma/pain?

- a. YES
- b. NO

6. What protocol do you do in assessment of suspected AVN of the hip?


- a. Whole body view
- b. Limited view
- c. Regional view

**Definitions:**

1. Whole body bone scan refers to imaging the entire body from head to toe in anterior and posterior views.

2. Limited view refers to imaging one anatomical region above and below the part in question. For example, imaging the feet and ankle should include the knee.

3. Regional imaging refers to imaging two anatomical regions of contralateral sites. For example, imaging the left hip should include the entire pelvis.



## REFERENCES

1. Subramanian G, McAfee JG: A new complex of Tc-99m for skeletal imaging. *Radiology* 1971; **99**:192-198
2. Muroff LR: Optimizing the performance and interpretation of bone scans. *Clin Nucl Med* 1981; **6**: 68-76
3. Merrick MV, Beales JS, Garvie N, Leonard RC: Evaluation of skeletal metastases. *Br J Radiol* 1992; **65**:803–806
4. Murray IPC, Eil PJ: Nuclear Medicine in clinical diagnosis and treatment. Volume 2; Churchill Livingstone, Edinburgh, 1994; p 909-910
5. Murray IPC, Eil PJ: Nuclear Medicine in clinical diagnosis and treatment, Volume 2; Churchill Livingstone, Edinburgh, 1994; p 925-931
6. Alazraki N, Dries F, Datz F, Lawrence P, Greenberg E, Taylor A: Value of a 24-hour image (four phase bone scan) in assessing osteomyelitis in patients with peripheral vascular disease. *J Nucl Med* 1985; **26**:711-717
7. Aigner RM, Fueger GE, Ritter G: Results of three phase scintigraphy and radiography in 20 cases of neonatal osteomyelitis. *Nucl Med Commun* 1996; **17**:20-28
8. Waxman AD, Bryan D, Siemsen JK: Bone scanning in drug abuse patients, early detection of haematogenous osteomyelitis. *J Nucl Med* 1973; **14**:647
9. Gelfand MJ, Silberstein EB: Radionuclide imaging. Use in diagnosis of osteomyelitis in children. *JAMA* 1977; **237**:245-247



10. Holder LE: Bone scintigraphy in skeletal trauma. *Radiol Clin North Am* 1993; **31**:739–781
11. Savelli G, Maffioli L, Maccauro M, et al.: Bone scintigraphy and the added value of SPECT in detecting skeletal lesions. *Q J Nucl Med* 2001; **45**:27–37
12. Han LJ, Au-Yong TK, Tong WC, et al.: Comparison of bone single-photon emission tomography and planar imaging in detection of vertebral metastases in patients with back pain. *Eur J Nucl Med* 1998; **25**:635–638
13. Alavi A, McCloskey JR, Steinberg ME: Early detection of avascular necrosis of the femoral head by <sup>99m</sup>Tc diphosphonate bone scan: a preliminary report. *Clin Orthop Relat Res* 1977; **127**: 137-139
14. Blair RJ, Schroeder ET, McAfee JG, et al.: Skeletal muscle uptake in both traumatic and non-traumatic rhabdomyolysis with acute renal failure. *J Nucl Med* 1975; **16**:515-516
15. Holder LE: Clinical bone imaging. *Radiology* 1990; **176**:607-614
16. Brill DR: Radionuclide imaging of non-neoplastic soft tissue. *Semin Nucl Med* 1981; **11**:277-288
17. Zimmer AM, Isitman AT, Holmes RA: Enzymatic inhibition of diphosphonate: A proposed mechanism of tissue uptake. *J Nucl Med* 1975; **16**:352-356
18. McRee J, Hambright P, Valk P: Chemistry of <sup>99m</sup>Tc tracers. II. In vitro conversion of tagged HEDP and pyrophosphate (bone-seekers) into gluconate (renal agent). Effects of Ca and Fe(ii) on in vivo distribution. *J Nucl Med* 1976; **17**:208-211

19. Mari C, Catafau A, Carrio I: Bone scintigraphy and metabolic disorders. *Q J Nucl Med* 1999; **43**:259–267
20. Leicht E, Berberich R, Lauffenburger T, Haas H: Tumoral calcinosis: Accumulation of bone-seeking tracers in the calcium deposits. *Eur J Nucl Med* 1979; **4**:419-421
21. Tondeur M, Ham HR: A case of false-positive bone imaging. *Clin Nucl Med* 1989; **14**:547
22. Rollo FD, Hoffer P: Comparison of whole-body-imaging methods. *Semin Nucl Med* 1977; **7**:315-322
23. Ljung B: The child in diagnostic nuclear medicine. *Eur J Nucl Med* 1997, **24**:683-690
24. Bombardieri E, Aktolun C, Baum RP, et al.: Procedure guidelines for tumour imaging. *Eur J Nucl Med Mol Imaging* 2003; **30**:BP99-BP106
25. Donohoe KJ, Brown ML, Collier BD, et al.: Society of Nuclear Medicine Procedure Guidelines for Bone Scintigraphy, version 3.0, approved June 20, 2003. [http://interactive.snm.org/docs/pg\\_ch34\\_0403.pdf](http://interactive.snm.org/docs/pg_ch34_0403.pdf).
26. O'Connor MK, Brown ML, Hung JC, Haystek RJ: The art of bone scintigraphy - technical aspects. *J Nucl Med* 1991; **32**:2332-2341
27. Shutter HE: Some special views in bone scanning. *Clin Nucl Med* 1980; **5**:172-173
28. Yun RU, Alavi A, David B, Beckerman C, Pinsay SM: Atlas of Nuclear medicine artifacts and variants. Second Edition; Year Book Medical Publishers, Chicago, 1996; p 23-47

29. Glasier CM, Seibert JJ, Williamson SL: The gamut of increased whole bone activity in bone scintigraphy in children. Clin Nucl Med 1987; **12**:192-197
30. Gate GF, Dore EK: Detection of craniosynostosis by bone scanning. Radiology 1975; **115**:665-671
31. Senda K, Itoh S: Evaluation of diffusely high uptake by the calvaria in bone scintigraphy. Ann Nucl Med 1987; **1**:23-26
32. Claweg KA, Dvorak AD, Wilmot M: Normal anatomical variant: Scintigraphy of the ischiopubic synchondrosis. J Nucl Med 1983; **24**:14-16
33. Fink-Bennett DM, Shapiro EE: The angle of Louis: potential pitfalls ("Louie's Hot Spot") in bone scan interpretation. Clin Nucl Med 1984; **9**:352-354
34. Croft BY, Teates CD: "Lunch syndrome", a bone scanning artifact: Case report. Clin Nucl Med 1978; **3**:137-138
35. Andrew GA, Theocheung JL: Unintentional intra-arterial injection of a bone imaging agent. Clin Nucl Med 1980; **5**:499
36. Siddiqui AR, Stokka CL: Uptake of Tc-99m methylene diphosphonate in a surgical scar. Clin Nucl Med 1980; **5**:274
37. Goris ML, Basso LV, Etcubanas E: Photopenic lesions in bone scintigraphy. Clin Nucl Med 1980; **5**:299-301
38. Gray HW: Soft tissue uptake of bone agents: Hard or soft data? Nucl Med Commun 1995; **16**:423-427
39. Dewanjee MK, Kahn PC: Mechanism of localization of 99mTc-labeled pyrophosphate and tetracycline in infarcted myocardium. J Nucl Med 1976; **17**:639-646

40. Adams KJ, Shuler SE, Witherspoon LR, Neely HR: A retrospective analysis of renal abnormalities detected on bone scans. Clin Nucl Med 1980; **5**:1-7
41. Chayes ZW, Strashun AM: Improved renal screening on bone scans. Clin Nucl Med 1980; **5**:94-97
42. Haden HT, Katz PG, Konerding KF: Detection of obstructive uropathy in bone scintigraphy. J Nucl Med 1988; **29**:1781-1785
43. Schmitt GH, Holmes RE, Isitman AT et al.: A proposed mechanism for Tc-99m polyphosphate and diphosphonate uptake by human breast tissue. Radiology 1974; **112**:733-738
44. Brill DR: Gynaecomastia demonstrated on the bone scan. J Urol 1977; **118**:62- 63
45. Lyons KP, Kuperus J, Green HW: Localization of Tc-99m pyrophosphate in the liver due to massive liver necrosis: Case report. J Nucl Med 1977; **18**:550-552
46. Vanek JA, Cook SA, Bukowski RM: Hepatic uptake of Tc-99m-labeled diphosphonate in amyloidosis: Case report. J Nucl Med 1977; **18**:1086-1088
47. Goy W, Crowe WJ: Splenic accumulation of Tc-99m diphosphate in a patient with sickle cell disease: Case report. J Nucl Med 1976; **17**:108-109
48. Howman-Giles RB, Gilday DL, Ash JM, Brown RG: Splenic accumulation of Tc-99m diphosphonate in thalassemia major. J Nucl Med 1978; **19**:976-977

49. Lieberman CM, Hemingway DL: Splenic visualization in a patient with glucose-6-phosphate dehydrogenase deficiency. *Clin Nucl Med* 1979; **4**:405-406
50. Delcourt E, Baudoux M, Neve P: Tc-99m-MDP bone scanning detection of gastric calcification. *Clin Nucl Med* 1980; **5**:546-547
51. Grames GM, Jansen C, Carlsen EN, et al.: The abnormal bone scan in intra-cranial lesions. *Radiology* 1975; **115**:129-134
52. Sty JR, Babbitt DP: Bone scintigraphy: Derby Hat deformity. *Clin Nucl Med* 1980; **5**:554-555
53. Rao BK, Lieberman LM: Bilateral congenital dislocation of hips: Diagnosis on a bone scans. *Clin Nucl Med* 1980; **5**:556-557
54. Rao BK, Pastakia BR, Lieberman LM: Uretero-colic fistula: Diagnosis on a bone scan. *Clin Nucl Med* 1980; **5**:178
55. Karvelis KC, Silverman ED: Inguinal hernia demonstrated incidentally during bone imaging. *Clin Nucl Med* 1988; **13**:129
56. Rosenthal L: Tc-99m-methylene diphosphonate concentration in soft tissue malignant fibrous histiocytoma. *Clin Nucl Med* 1978; **3**:58-61
57. Makhija MC, Brodie M: Demonstration of extremely large pedunculated uterine fibroids on bone scan. *Clin Nucl Med* 1981; **6**:384-385
58. Krishnamurthy GB, Tubis M, Hiss J, Bland WH: Distribution pattern of metastatic bone disease. A need for total body skeletal image. *JAMA* 1977; **237**:2504-2506
59. Bontoux D, Plazanet F, Azais I: Distribution of bone metastases of cancers. A scintigraphic study of 376 cases. *Bull Acad Natl Med* 1998; **182**(5):997-1008

60. Wilson MA, Calhoun FW: The distribution of skeletal metastases in breast and pulmonary cancer. Concise communication. J Nucl Med 1981; **22**:594-597
61. Nunan TO, Clarke SEM, Coakley AJ, Wells CP, Halls FM, Entwistle P: Is the skull view necessary in routine gamma camera bone scanning? Nucl Med Commun 1985; **6**:37-40
62. Nagle CE: Cost-appropriateness of whole body vs. limited bone imaging for suspected focal sports injuries. Clin Nucl Med 1986; **11**:469- 473
63. Frater CJ: Importance of positioning and frequency of unexpected scintigraphic findings in a high impact sport. Nucl Med Commun 2001; **22**:1231-1235
64. Rusu V, Boiculese LV, Stefanescu C, Hountis D, Costin M: A retrospective study of bone metastases distribution on 420 whole body scans. Rev Med Chir Soc Med Nat Isai 2004; **108**: 114-117
65. Belliveau RE, Spencer RP: Incidence and sites of bone lesions detected by 99mTc-polyphosphate scans in patients with tumours. Cancer 1975; **36**:359-363
66. Coleman RE, Bernier DR, Pasternak S, Siegel BA: Efficacy of skull imaging in routine bone scanning. J Nucl Med 1974; **15**:1185-1186
67. Krasnow AZ, Hellmann RS, Timins ME, Collier BD, Anderson T, Isitman AT: Diagnostic bone scanning in oncology. Semin Nucl Med 1997; **27**:107-141
68. Tofe AJ, Francis MD, Harvey WJ: Incidence of solitary skull and extremity involvement in whole body scintigrams. J Nucl Med 1976; **17**:755-756

69. Rao BR, Winebright JW, Bartow J: Value of total-body bone scan in a child with osteomyelitis. Clin Nucl Med 1980; **5**:559-560
70. Dich VQ, Nelson JD, Haltalin KC: Osteomyelitis in infants and children. A review of 163 cases. Am J Dis Child 1975; **129**:1273-1278

