

# Double atrial heart sound in a patient with 2:1 atrioventricular block

**Alfonso J. Pecoraro, Anton F. Doubell and Philip G. Herbst**

Division of Cardiology, Department of Medicine, Faculty of Health Sciences, University of Stellenbosch and Tygerberg Academic Hospital, Tygerberg, South Africa

**Address for correspondence:**

Alfonso J. Pecoraro  
Division of Cardiology  
Department of Medicine  
University of Stellenbosch and Tygerberg Academic Hospital  
PO Box 19063  
Tygerberg  
7505  
South Africa

**Email:**

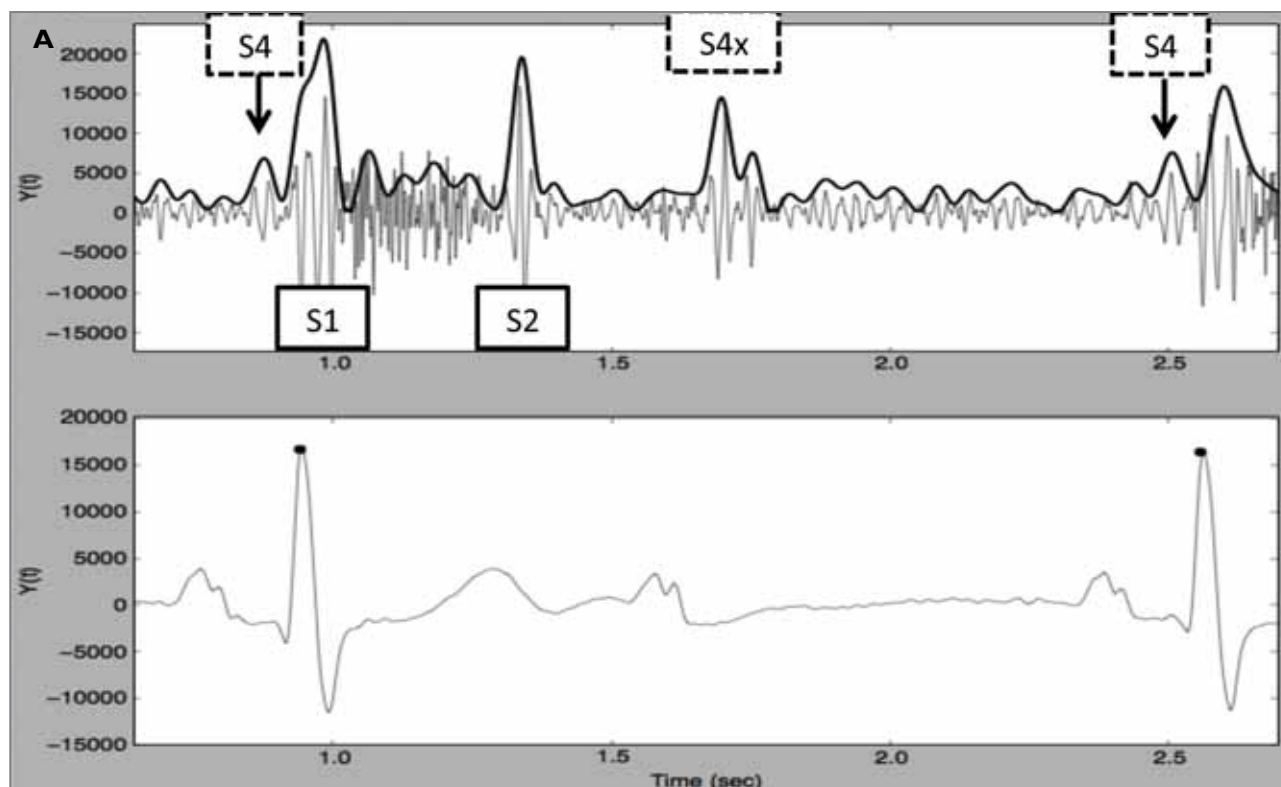
pecoraro@sun.ac.za

An 83-year-old lady presented to our cardiac unit with presyncope and progressive dyspnoea.

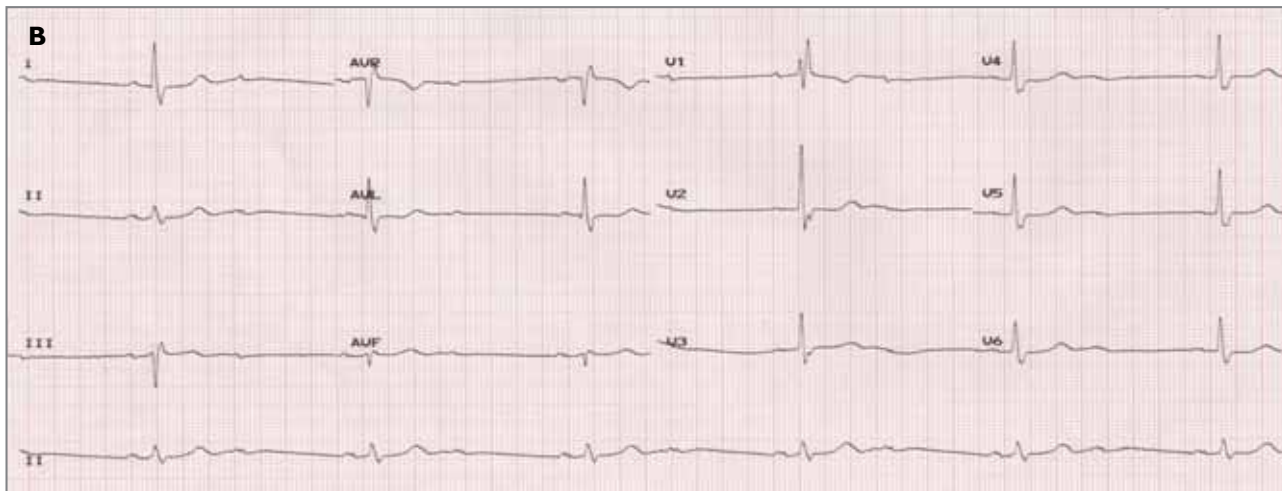
She had a regular bradycardia of 36 beats per minute with a slow-rising central pulse and normal jugular venous pressure without cannon A waves. Auscultation revealed a late-peaking, ejection systolic murmur (ESM) and soft second heart sound in keeping with severe aortic stenosis (AS). Interestingly, 2 added diastolic heart sounds were noted. A phonocardiogram with a simultaneous electrocardiogram (ECG) recording was undertaken using a mobile device. This revealed an early diastolic heart sound following a non-conducted P wave (S4x) in addition to a pre-systolic atrial heart sound (S4) and ESM (Panel A).

An S4 is associated with atrial contraction in the presence of a stiff, non-compliant ventricle (e.g. in severe AS). Electrocardiography confirmed the presence of 2:1 atrioventricular block explaining the additional S4 (Panel B).

New technologies are resurrecting classic teaching and diagnostic aids such as phonocardiography, that can be used to help solve clinical puzzles at the bedside.



**Panel A:** Phonocardiogram with simultaneous electrocardiogram (ECG) recording.



Panel B: 12 lead ECG recording.



CLICK TO PLAY HEART SOUND

